



A
TEXT-BOOK ON
SURGERY

GENERAL, OPERATIVE, AND MECHANICAL

BY *e*

JOHN A. WYETH, M. D.

PROFESSOR OF SURGERY IN THE NEW YORK POLYCLINIC; SURGEON TO MOUNT SINAI HOSPITAL;
CONSULTING SURGEON TO ST. ELIZABETH'S HOSPITAL; MEMBER OF THE NEW YORK PATHOLOGICAL SOCIETY;
OF THE NEW YORK SURGICAL SOCIETY; OF THE ACADEMY OF MEDICINE;
OF THE NEW YORK STATE MEDICAL ASSOCIATION; OF THE NEW YORK COUNTY MEDICAL SOCIETY;
HONORARY MEMBER OF THE TEXAS STATE MEDICAL ASSOCIATION;
OF THE COLLEGE OF PHYSICIANS AND SURGEONS OF LITTLE ROCK, ARKANSAS;
AUTHOR OF AN ESSAY ON THE SURGICAL ANATOMY OF THE TIBIO-TARSAL REGION,
WITH SPECIAL REFERENCE TO AMPUTATIONS AT THIS JOINT,
AWARDED THE JAMES R. WOOD ANNUAL PRIZE OF THE BELLEVUE ALUMNI ASSOCIATION, 1876;
AN ESSAY ON THE SURGICAL ANATOMY AND HISTORY OF THE CAROTID ARTERIES,
AWARDED THE FIRST PRIZE OF THE AMERICAN MEDICAL ASSOCIATION, 1878;
AN ESSAY ON THE SURGICAL ANATOMY AND HISTORY OF THE INNOMINATE AND SUBCLAVIAN ARTERIES,
AWARDED THE SECOND PRIZE OF THE AMERICAN MEDICAL ASSOCIATION, 1878, ETC.

SECOND EDITION
REVISED AND ENLARGED

NEW YORK
D. APPLETON AND COMPANY

1891




17230

COPYRIGHT, 1887, 1890,

By D. APPLETON AND COMPANY.

TO THE MEMORY OF MY FRIEND,
J. MARION SIMS, M.D.,
WHOSE BRILLIANT ACHIEVEMENTS CARRIED
THE FAME OF AMERICAN SURGERY
THROUGHOUT THE CIVILIZED WORLD,
THIS BOOK IS AFFECTIONATELY DEDICATED
BY THE AUTHOR.



Digitized by the Internet Archive
in 2011 with funding from
Open Knowledge Commons and Harvard Medical School

PREFACE TO THE SECOND EDITION.

IN revising this work scarcely a chapter remains untouched. While some are not materially altered, others are practically rewritten. In the chapter on Inflammation is embodied the latest accepted ideas of surgical septicæmia. The article on the Eye is new, and, in addition to the surgery of this organ, includes the study of Refraction, and the application of glasses in correcting errors in the visual apparatus. The most recent and approved methods of dealing with lesions of the abdominal viscera—viz., intestinal anastomosis, exsection of a portion of the alimentary canal, procedures for the radical cure of herniæ, cholecystotomy, etc.—have been added to the text. A new chapter on the Surgery of the Genito-Urinary Organs of Females is inserted. Supra-pubic cystotomy for stone or tumor of the bladder is given a prominence not hitherto accorded so valuable a procedure; and scarcely less useful are the plastic operations for the cure of urinary fistulæ. In the department of Diseases of the Rectum and Anus the latest methods of surgical interference are considered.

The author acknowledges gratefully the assistance received from his friends, Prof. David Webster, in the article on Refraction, and Dr. W. W. Van Arsdale, who is wholly responsible for the greatly improved index.

The drawings for many of the new cuts were done by Dr. Henry Macdonald, of New York city, whose thorough work is well attested.

THE AUTHOR.

PREFACE TO THE FIRST EDITION.

THE author has endeavored to give in the following pages the accepted facts in surgical pathology and diagnosis, together with the methods of treatment which modern surgery has introduced, or has elected as worthy of continued application from the practice and teaching of the past. In the effort to condense into a single volume, of about eight hundred pages, the essentials of the science and art of surgery, not only is a discussion of theories out of the question, but many measures of treatment—the comparative usefulness of which has been demonstrated—must of necessity be omitted.

In an age when books upon this subject are plentiful, this work was undertaken not without misgivings, yet with a determination to leave nothing undone which would add to its usefulness and make it an exponent of modern and progressive surgery. Such rapid advances are being made, that marvelous results are to-day achieved by measures unknown to the profession but a few months earlier. The introduction of *cocaine hydrochlorate* as a local anæsthetic marks an epoch in surgical practice; and yet this wonderful agent has scarcely been mentioned in works on surgery. Again, the *antiseptic method* of treating wounds, originated within the last few years, has brought with it such protection to life and usefulness, that it deserves a more thorough consideration than is often allotted it by surgical writers, and should be universally accepted and practiced.

The author believed that the general profession was not sufficiently impressed with the dangers in delaying surgical interference in lesions of the cavities and their viscera, notably the cranium, abdomen, and pelvis. These, and other considerations which will be found in the text, were among the reasons which led him to hope that this book

would prove acceptable to his fellow-workers, and especially to that numerous class of physicians who are compelled to do a general practice, and who can find neither time nor opportunity to select from the vast quantity of surgical literature the facts essential to the prompt and successful management of their cases. That this hope was not without foundation is attested by the reception accorded to the work by the medical press, and by the necessity of a second issue within three months after its publication.

To the many sources from which much needed help in its compilation and illustration was obtained—however accredited in the text—the author desires to acknowledge an especial indebtedness, and to the engravers, Messrs. H. Senior and Company, for the general excellence and prompt execution of their work. An examination of the volume will attest the liberality of the publishers, who have contributed greatly to its success.

THE AUTHOR.

April 20, 1887.

CONTENTS.

CHAPTER I.

PAGE

Surgical dressings—Ligatures and sutures—Preparation of material—Catgut, silk, silk-worm gut, silver wire—Antiseptic solutions—Corrosive sublimate, creoline, carbolic acid, iodoform, alcohol, chloride-of-zinc—Irrigators, sponges—Drains: rubber, bone, catgut, and horse-hair—Protective—Carbolized, sublimated, and iodoformized gauze—Borated and absorbent cotton—Peat—Sawdust—Jute—Wood-wool 1

CHAPTER II.

Bandaging—Materials and methods of preparing—Application of the various methods—Simple spiral, reverse spiral, figure-of-8 turn, figure-of-8 reverse—Special bandages—Hand and fingers—Fore-arm, arm, and shoulder—Toes, foot, leg, and thigh—Spica—Abdomen and thorax—Head and face—Knotted bandage—Handkerchief bandages 10

CHAPTER III.

Anæsthesia—Local anæsthesia—Cocaine—Ether-spray—General anæsthesia—Administration of ether by inhalation—By the rectum—Chloroform and chloroform narcosis 22

CHAPTER IV.

Surgical operations—Instruments—Operating-table—Furniture—Operating-gown—How to hold the scalpel—Hæmostasis—Tying the ligature—After-treatment of the case 35

CHAPTER V.

Inflammation—Venesection and blood-letting—Compression—Application of cold—Internal medication—Suppuration—Pus—Micrococci—Bacteria—Abscess—Treatment 54

CHAPTER VI.

Wounds—Process of repair—Cicatrization—The tourniquet—Closing wounds—The interrupted, continuous, mattress, quill, wire, and pin sutures—Transfusion—Intra-venous injection of a saline solution—Poisoned wounds—Snake-bites—Tarantula-poison—Wounds by bees, wasps, hornets, and centipedes—Hydrophobia—Glanders—Malignant pustule—Dissection wounds—Erysipelas—Dermatitis—Erythema—Cellulitis—Tetanus—Shot-wounds 68

CHAPTER VII.

Burns and scalds—Skin-grafting—Frost-bite—Furuncle—Carbuncle—Ulcers—Gangrene—Dry or senile gangrene—Hospital gangrene 93

CHAPTER VIII.

	PAGE
Amputations—Method of operating—Circular solid flap, with perpendicular slit—Oblique solid flaps by transfixion—The same by cutting from the surface inward—Skin-flaps, circular method—Modified circular—Oval—Double crescentic—Double rectangular—Mixed flaps—Open method—Special amputations—Fingers—Hand—Fore-arm—Elbow-joint—Arm—Shoulder—Toes—Through the metatarsus—Through the tarsus—Methods of Pirogoff, Chopart, Hey, Lisfranc, Le Fort, Lignerolles, and Hancock—Tibio-tarsal disarticulation—Method of Syme—Leg—Method of Stephen Smith—Knee-joint—Thigh—Hip-joint—Method of Erskine Mason, etc.	107

CHAPTER IX.

Surgical diseases and surgery of the lymphatic vessels, veins, and arteries—Lymphangitis—Adenitis—Phlebitis—Arteritis—Arterial thrombosis and embolism—Vascular tumors—Arterial varix—Cirsoid arterial tumor—Angiomata—Venous varix or varicose veins—Moles—Port-wine mark	162
--	-----

CHAPTER X.

Aneurism—Varicose aneurism—Aneurismal varix—Method of Tufnell and Valsalva—Ligature by the methods of Antyllus, Wardrop, Anel, Hunter, and Brasdor—Digital and mechanical pressure—Galvano-puncture, massage, flexion, introduction of wire, horse-hair, catgut, etc.—Special aneurisms—Aneurism of the thoracic aorta—Innominate—Common, external, and internal carotid arteries—Subclavian—Abdominal aorta—Iliac arteries—Femoral—Popliteal—Arterio-venous aneurism—Simultaneous deligation of left subclavian and left common carotid arteries for aneurism of the transverse arch of aorta	202
--	-----

CHAPTER XI.

Ligation of arteries—Innominate—Common, external, and internal carotid and internal jugular vein—Superior thyroid, lingual, facial, ascending pharyngeal, occipital, posterior auricular, temporal, and internal maxillary—Subclavian—Vertebral and internal mammary—Axillary—Brachial—Radial—Ulnar—Intercostal—Abdominal aorta—Iliac arteries—Gluteal, internal pudic, and sciatic—Femoral—Profunda femoris—Popliteal—Posterior tibial—Anterior tibial—Dorsalis pedis	234
--	-----

CHAPTER XII.

Surgical diseases and surgery of the bones—Ostitis—Osteo-periostitis—Osteomalacia—Rachitis—Fractures—Of the skull—Trepining—Nasal bones—Malar—Superior maxilla—Inferior maxilla—Clavicle—Acromion and coracoid process—Glenoid process—Spine of the scapula—Humerus—Condyles—Olecranon process—Ulna—Radius—Colles's fracture—Carpus—Metacarpus—Phalanges—Sternum—Ribs—Vertebræ—Sacrum—Coccyx—Os innominatum—Femur—Patella—Leg—Pott's fracture—Tarsus and metatarsus—Ununited fractures	275
--	-----

CHAPTER XIII.

Surgery of the articulations—Dislocations—Lower jaw—Clavicle—Shoulder-joint—Elbow-joint—Wrist-joint—Carpo-metacarpal joints—Phalanges—Hip-joint—Knee-joint—Patella—Tarsus—Vertebræ—Ribs—Diseases of the joints in general—Synovitis—Arthritis—Diseases of special joints—Hip-joint— <i>Morbus coxæ</i> —Knee-joint—Ankle-joint—Shoulder-joint—Elbow-joint—Wrist-joint—Exsections of the joints	325
--	-----

CHAPTER XIV.

Regional surgery—The head—Tumors of the scalp—Abscess—Pneumatocele—Encephalocoele—Meningocoele—Neoplasms of the meninges—Hydrocephalus—Wounds of the scalp—Of the	
---	--

	PAGE
brain—Cerebral localization—Surgery of the face—The eye—The eyelids—Lachrymal glands and ducts—The conjunctiva and cornea—Sclerotic—Iris—Choroid and ciliary body—Crystalline lens—The vitreous—The retina—Strabismus—Refraction—The ophthalmoscope—Testing for glasses—Ophthalmoscopy—Surgery of the ear—The nose—Plastic surgery of the nose—The lips and cheeks—Parotid gland and duct—Parotitis—Submaxillary gland—The jaws—Operation for removal of the upper jaw—The lower jaw—The teeth—The palate—The tongue and buccal cavity—Tonsils	382

CHAPTER XV.

The neck—Wounds—Abscess—Tumors—Thyroid body—The larynx and trachea—Thyrotomy—Laryngotomy—Tracheotomy—Intubation of the larynx—Foreign bodies in the air-passages—Laryngectomy—Neoplasms of the larynx and trachea—Pharynx—Œsophagus—Foreign bodies—Œsophagotomy for stricture—New formations—Œsophagectomy	491
--	-----

CHAPTER XVI.

Thorax—Mammary gland—Mastitis—Abscess—Hypertrophy—Tumors—Exsection of the clavicle—Empyæma—Wounds of the chest	513
--	-----

CHAPTER XVII.

Abdomen — Stomach — Gastrostomy — Pylorectomy — Gastrectomy — Gastro-pylorectomy—Gastro-enterostomy—Duodenum—Obstruction of the alimentary canal—Impaction of fecal matter—Foreign bodies—Intussusception—Volvulus—Constriction by bands—Adhesions—Omental and mesenteric slits—Diverticula—Neoplasms—Stricture—True hernia—Abdominal section for intestinal occlusion—Exsection of the intestine—Intestinal anastomosis—Hernia—Special forms of hernia—Inguinal, congenital, infantile, femoral, umbilical, ventral, diaphragmatic, gluteal, obturator, lumbar, and vaginal hernia—Radical cure of hernia—Stangulated hernia—Fecal fistula—Imperforate anus—Colostomy—Peritonitis—Abdominal abscess—Perityphlitis—The liver—The gall-bladder—The spleen—Wounds of the abdomen	526
--	-----

CHAPTER XVIII.

Rectum and anus—Atresia ani et recti—Pruritus ani—Foreign bodies—Fistula in ano et recto—Fissure—Ulcers—Stricture—Neoplasms of the rectum and anus—Neuralgia—Prolapsus—Hæmorrhoids	591
--	-----

CHAPTER XIX.

Genito-urinary organs—Kidneys—Suppression of urine—Nephrotomy and nephrectomy—Ureters—Bladder—Wounds—Infiltration of urine—Cystitis—Paralysis—Incontinence—Neoplasms—The urine—Stone—Lithotrity—Lithotomy—Prostate body—Spermatorrhœa—Aspermatism—Urethra—Gonorrhœa—Balanitis—Posthitis—Gonorrhœal rheumatism—Gleet—Stricture—Meatotomy—Internal urethrotomy—Dilatation—Modified internal urethrotomy—External urethrotomy or perineal section—SOUNDS—Foreign bodies in the urethra—Congenital and acquired malformations—Neoplasms—Cancer of the penis—Amputation—Humphrey's operation—Phimosis—Circumcision—Dilatation of the prepuce—Ulcers of the penis—Syphilis—Scrotum—Hydrocele—Varicocele—Epididymis—Testicle	619
---	-----

CHAPTER XX.

The genito-urinary organs in females—Lesions of the vulva and perinæum—Operations for lacerations of the perinæum—Diseases of the vulva—The vagina—Vaginitis—Vaginismus—Stricture—Narrowing the vagina—Vesico-vaginal fistula—Cervix uteri—Excision and am-	
---	--

	PAGE
putation of the cervix—Vaginal hysterectomy—Hysterotomy—Hysterectomy during pregnancy—Abdominal hysterectomy—The Fallopian tubes—The ovaries—Laparotomy for the removal of tumors of the ovary and Fallopian tubes	751

CHAPTER XXI.


Deformities of the spine—Torticollis—Lateral and rotary-lateral curvature—Scoliosis—Cyphosis—Spondylitis—Spina bifida—Deformities of the lower extremity—Preternatural mobility of the hip—Sub-trochanteric osteotomy—Genu valgum—Genu varum—Talipes—Polydactylus—Syndactylus—Hallux valgus—Hammer-toes—In-growing nail—Deformities of the upper extremity—Club-hand—Web-finger—Snap-finger—Phlegmon of the hand and fingers—Ganglion	779
---	-----

CHAPTER XXII.

Tumors—Carcinoma—Epithelioma—Lymphadenoma—Sarcoma—Papilloma—Adenoma—Cysts—Lipoma—Fibroma—Myxoma—Myoma—Neuroma—Angioma—Lymphangioma—Chondroma—Osteoma	837
--	-----

A

TEXT-BOOK ON SURGERY.



SURGICAL DRESSINGS.

THE materials used in the performance of a surgical operation, and in its after-treatment, form such an important part of the surgeon's outfit that I have determined to devote the initial chapter of this book to a description of the methods of preparing and preserving the apparatus needed for dressing wounds in the antiseptic practice of to-day.

This practice, which embodies the great principles of *cleanliness* and *carefulness* in surgery, is now so well established among the best surgeons in America and Europe that any argument in its favor, as compared with the methods of one or two decades ago, I consider to be wholly unnecessary.

Ligatures and Sutures.—Catgut, silk, silk-worm gut, and silver wire will meet every requirement in tying vessels and closing wounds. Catgut has practically superseded all other substances as a ligature. The conditions which would justify the application of a silk, metal, or any non-absorbable ligature to an artery are rarely present. Strings or cords made from animal tissues, as buckskin, ox-aorta, nerve, tendon, and whalebone, known under the general name of "broad ligatures," have been successfully employed in the occlusion of the larger vessels, but their use is limited in comparison with that of the violin-strings, which are easily obtained, prepared and preserved, and are, moreover, cheap.

In the preparation of catgut select four sizes of the best quality of violin-strings in about this proportion: one dozen each of the E and A strings, six D strings, and two or three harp-strings about twice as large as that of D, violin. The smaller sizes are most generally needed for the smaller vessels and bleeding points, the D string is best adapted to vessels as large as the radials, ulnars, or tibials, while the larger strings should be used upon the iliaes, subclavians, common carotids, and femorals.

Preparation.—Cut and remove the small red threads which are tied around each bunch, and place the catgut in a glass bottle or jar which

contains enough *pure oil of juniper-berries* to completely cover them. The vessel should be tightly corked to prevent evaporation. Within a few days the material is safely aseptic, and will remain so indefinitely if kept immersed in the fluid. It is advisable, however, to transfer the gut to pure alcohol after a week's immersion in the juniper oil and preserve it indefinitely in this liquid. Alcohol keeps this material clean and does not materially interfere with its strength.

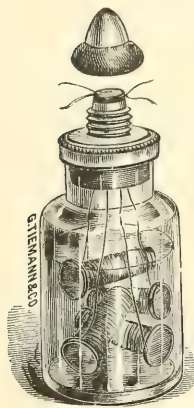

FIG. 1.

If oil of juniper can not be obtained, the alcohol may alone be used. Fig. 1 represents a convenient apparatus for holding these ligatures. It consists of a glass jar or bottle, with a wide mouth, in which a perforated cork is fitted. Within the bottle are several glass spools upon which the ligatures have been wound. The ends project through the perforation in the cork, and are held here by a smaller cork fitted into the perforation. Upon removing the smaller plug, the threads may be drawn out and cut off as required. Another vessel is pictured in Fig. 2. In this the ligatures are wound around a central shaft, which is pulled completely out of the bottle when the threads are needed.

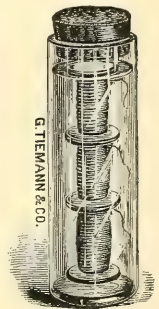


FIG. 2.

Chromic-acid Catgut.—When an animal ligature or suture which will resist absorption and hold its grasp upon the tissues longer than ordinary juniper or alcohol catgut is desired, this material should be submitted to the tanning action of chromic acid. The formula of Dr. F. L. Burt yields the best suture of this kind.

Take a 1 to 20 solution of carbolic acid in water (gr. xx of water by weight to gr. j of carbolic acid), and in this dissolve chromic acid in the proportion of gr. j of the crystals to gr. 5,000 by weight of the carbolic solution.

When this solution is ready, drop the violin strings in it and allow them to remain immersed until when lifted out the gut retains the same amber stain or color of the liquid. From four to six hours will usually suffice, but the test should be the color of the catgut. It should then be thoroughly dried and placed in clean, tight bottles. When about to be used it should be softened for about one half-hour in a 1 to 1,000 solution of sublimate or a 1 to 20 carbolic-acid solution. For such sutures the smaller strings are preferable. E violin is about the proper size. Thus prepared, catgut will resist absorption from one to three weeks.

Silk is invaluable for sutures. It is not to be used for ligatures, except in certain operations within the abdominal cavity, or in wounds which are to be treated by the open method. This material should be selected of all sizes. I prefer the twisted to the braided threads, although the latter is less likely to become tangled. The very finest *black iron-*

dyed silk is needed in the plastic surgery of the neck and face, in the white individual. White sutures often become so discolored that they are with difficulty found when the time for their removal arrives. The larger silk sutures, such as those employed in tying hæmorrhoidal masses, should be so strong that any ordinary force can not break them. Silk is rendered aseptic by boiling and then preserving in 1 to 20 carbolic-acid or 1 to 3,000 sublimate solution.

Silk-worm gut comes in bristles, or stiff threads, about ten inches in length. It serves as an excellent suture in any part of the economy, and is invaluable in the operation for cleft palate. It is not absorbable, is very strong, ties easily, and does not slip. It should be kept in an ordinary dry box, and need not be rendered aseptic for operations on the palate.

Silver wire is essential as a suture-material. Beyond the operations upon the genito-urinary organs of the female, where it is indispensable, it is preferable to silk in many wounds of other portions of the body. The sizes most required range from Nos. 24 to 31, inclusive. A most convenient way of carrying silver for immediate use is to cut it in pieces about ten inches in length, and place it in a metal cylinder (Fig. 3), which is divided into three or four compartments, and closed by a screw-top. Or the wire loops may be wrapped in protective or blotting-paper, and thus kept free from moisture in order to prevent rust. They are rendered aseptic by immersion in 1 to 20 carbolic acid one half-hour before using them.

Solutions.—For irrigating wounds, submerging instruments, and disinfecting in general, solutions of corrosive sublimate, creoline, carbolic acid, boric and salicylic acid, are necessary, and pure alcohol, iodoform, and chloride-of-zinc solutions may at times be used.

Koch has demonstrated that, as a germ-killer, *corrosive sublimate* excels all known agents. The sublimate solutions vary in the proportion of one part of the bichloride to five hundred parts of distilled water by weight, or 1 to 500, 1 to 1,000, 1 to 2,000, and 1 to 3,000 for use outside of the great cavities, and 1 to 8,000, 1 to 15,000, and 1 to 20,000 within the cavities.

The sublimate solutions are only used for irrigation and for disinfecting the hands, sponges, and gauze. All instruments are submerged in carbolic-acid solutions or in alcohol.

The stronger solutions, 1 to 500 and 1 to 1,000, are rarely employed in irrigation, and then only when the part exposed has been made bloodless by the Esmarch bandage. Even when thus employed for the disinfection of an abscess cavity, infected wound, ulcer, or sinus, the excess of sublimate should be immediately washed away by flooding the part with the 1 to 3,000 solution. In any ordinary operation no stronger sublimate than 1 to




FIG. 3.

3,000 will be required; a 1 to 18,000 solution may be used in the peritoneal cavity where the conditions are such that the fluid may run out or be removed at once by sponges. I have filled the entire abdominal cavity with warm sublimate, 1 to 18,000, mopping it out with sponges, and repeating this procedure three times without any bad symptom resulting. In the pleural cavity (empyema) much stronger solutions may be employed.

For convenience, any required solution may be made from the following: Corrosive sublimate, gr. xxx; water ℥j. Some add to this about gr. x of table-salt. One teaspoonful of this solution added to a pint of water approximates 1 to 2,000. Water containing lime should not be used. Tablets of corrosive sublimate are now manufactured, and are very convenient for transportation. Each tablet contains enough sublimate to make, when dissolved in a pint of water, a 1 to 1,000 solution. It is best to make fresh solutions when needed, for, unless kept tightly corked and away from light, they deteriorate in value.

Creoline, a product of coal-tar, has been accepted as a valuable antiseptic agent. It is a dark-brown colored liquid, not soluble in but forming with water a milky-looking mixture. It is especially recommended for the irrigation of wounds needing stimulation and in those exceptional cases where the sublimate solutions produce a troublesome dermatitis. The ordinary strength is 1 part of creoline to 200 parts of water.

Carbolic acid (1 to 20, or a 5-per-cent solution) is employed for the cleansing and submersion of all instruments used in a surgical operation. It is not used in irrigation on account of its irritating properties. The steam and carbolic spray so much in vogue a few years since is now only

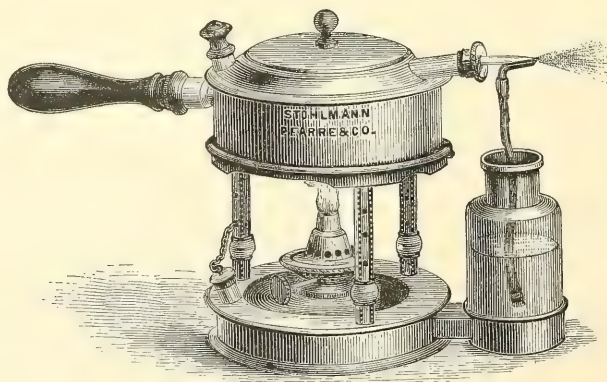


FIG. 4.—Weir's antiseptic spray-machine.

used to lay the dust, or as an aid toward the more thorough cleansing of operating-rooms and wards which are especially exposed to infection. The spray-machine (Fig. 4) is started one half-hour before the operation is to commence, and is allowed to run until that time. The strength of the solution in the bottle is 1 to 20.

As ordinarily sold, carbolic acid is dissolved in alcohol, and is about 95 per cent strong. In this condition an ounce by measurement is approximately an ounce by weight. To this quantity add water $\frac{3}{4}$ xx, which will make a 1 to 20, or 5-per-cent solution. All instruments are immersed in this solution a half-hour before the operation, except the blades of the knives, which should be dipped in only a minute or two before being used.

An exceedingly useful solution for irrigation about the eye, ear, in the pleural cavity, but especially applicable to the peritoneal cavity, is composed of acid salicylic, $\frac{3}{4}$ j; acid boric, $\frac{3}{4}$ vj; hot distilled water, $\frac{3}{4}$ xl—about two pints and a half (Thiersch's solution). If made with cold water, there will be a precipitate.

Pure alcohol may also be used for this purpose by operators who dislike the benumbing effects or disagreeable odor of the acid.

Iodoform, one part dissolved in seven parts of *ether*, is used at times to wash the parts where an operative wound is to be made. It is not an uncommon practice with some of the German surgeons to immerse all the ligatures and suture-material in this solution for about twenty minutes before the operation is begun.

Of the value of this agent in its dry and pulverized form in dressing wounds there is still considerable diversity of opinion. That its antiseptic qualities have been greatly overrated there is no doubt. It does not prevent infection by the germs of erysipelas or those of anthrax. It seems to be proved at this date that it does not destroy or neutralize any of the septic germs; in fact, unless sterilized—which may be done by washing it in 1 to 3,000 sublimate solution—it may convey septic products to wounds. Moreover, it is absorbable, and at times a violent and fatal poison. With these facts in view, its use should be guarded and limited. It should not, however, be totally discarded, for, according to Dr. W. W. Van Arsdale* and others, its property of destroying the ptomaines renders it useful as a deodorizer, especially on putrid and infected surfaces and on the mucous surfaces, or in wounds communicating with these cavities.

Chloride-of-zinc solution in water (1 to 12, about 8 per cent) may be used to wash out ulcers or old sinuses which are in the neighborhood of, or communicate with, the wound of operation. This and the iodoform solution are not, however, essential, and are now rarely employed.

Irrigators.—A rubber bag, capable of holding two quarts of solution, with extra long tubing attached, makes a convenient irrigator for use and transportation. The ordinary fountain-syringe, represented in Fig. 5, is commonly used. The nozzles should be of smooth glass, sufficiently heavy to resist breakage, about three or four inches in length, not more than a quarter of an inch in gross diameter, slightly pointed, and with a lumen of one eighth of an inch. Sublimate solution should not be allowed to remain in contact with rubber for any considerable time on account of

* "Annals of Surgery," March, 1889, p. 215.

its corrosive action. When an operation or dressing is completed, after the sublimate escapes, pure water should be run through the irrigator.

A good emergency irrigator is shown in Fig. 6. It is made by placing a perforated cork in an ordinary wine-bottle, fitting a piece of glass tube, or cane, or goose-quill into the perforation to which the rubber hose is attached. The bottom of the bottle is broken

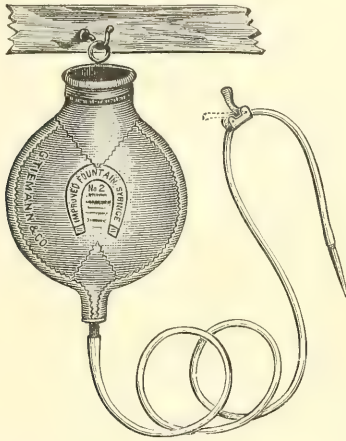


FIG. 5.

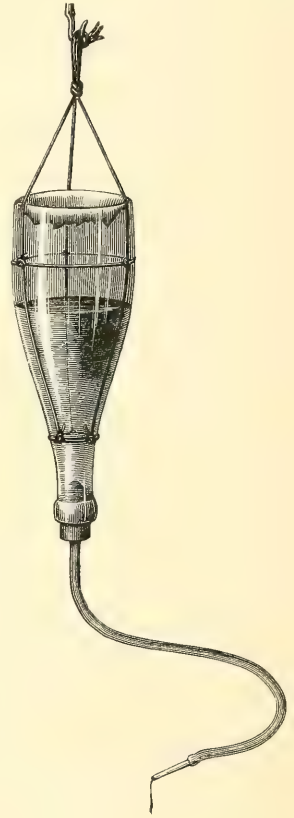


FIG. 6.—(Esmarch.)

in, and a string netting, thrown around for suspension, completes the apparatus. If there is no stop-spring to shut off the flow, it may be readily arrested by placing the nozzle in the upper end of the bottle. The assistant who attends to the irrigator can always regulate the flow by slight pressure of the tube between the thumb and finger, just where the nozzle is attached. Tin or brass vessels may also be employed, but the corrosive action of the mercury soon destroys the metal.

When no irrigator can be had, the sublimate solution may be poured on from a pitcher or cup.

For continuous irrigation, as in an amputation treated by the open method, a constant dripping may be secured by twisting a piece of muslin or cotton cloth into a loose wick-like string, moistening it, and placing one end in a vessel holding the solution, while the other hangs over the edge from a point where the fluid will fall on the wounded surface (Fig. 7).

Sponges.—In selecting sponges, secure those of softest and finest texture, measuring, when dry, from one to two and three inches in diameter, the greater number spherical in shape, with a half-dozen flat pieces a half-inch thick, three or four inches wide, and from six to ten inches long. When purchased in the rough they should be thoroughly whipped until all the sand is removed, and then washed in cold or lukewarm

water. Two methods may be employed for bleaching. The simpler way is to soak them for from six to eighteen hours in a mixture of one part

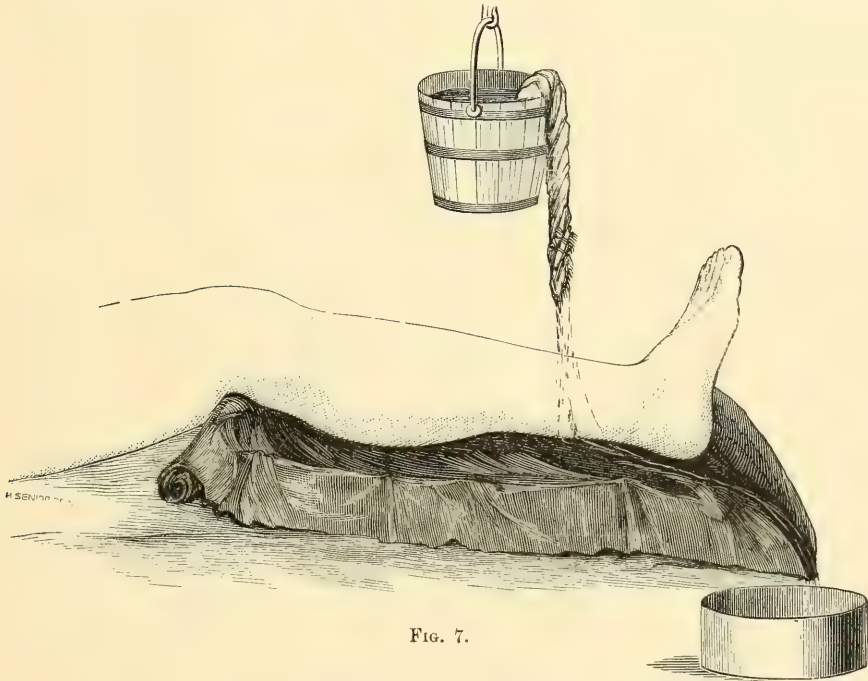


FIG. 7.

of liquor sodæ chlorinatæ to five of water, rinse them in clear cold water, and dry thoroughly. A more complicated but very efficacious method is the following:* Place the sponges in a solution of permanganate of potassa, 1 to 100 (about gr. v- \bar{z} j of water), for one half-hour; rinse in clear cold water, squeeze thoroughly, and immerse them in a solution of oxalic acid (1 to 50) for ten minutes. Rinse again in clear water, leave them there for one hour, and then dry quickly in a warm oven. Sponges may be kept dry either in tightly corked glass or stone jars, or wrapped up in protective, and put away in a clean drawer. They may also be kept indefinitely in a 1 to 20 carbolic-acid solution, but should not be kept any length of time in sublimate solution.† When a sponge has been once used it should be destroyed, unless the circumstances are such that other and fresh pieces can not be obtained for a succeeding operation. Even under such conditions, if they have been brought in contact with septic matter, it should be imperative to destroy the sponges and proceed without them, using clean cloths, or towels, or borated or absorbent cotton in their stead.

To cleanse sponges which have been used, wash them thoroughly in different changes of warm water (not hot), and, when they no

* To Mr. Angelo, druggist, of Fourth Avenue and Thirty-first Street, New York, I am indebted for this formula.

† Mr. Charles G. Am Ende, 168 Washington Street, Hoboken, New Jersey, prepares sponges that are soft, clean, and very satisfactory, as well as cheap.

longer discolor clear water, immerse them in 1 to 500 sublimate for one hour.

In all operations, sponges, before being used in the wound, should be dipped in 1 to 3,000 sublimate solution, and then squeezed as dry as possible.

Drains.—*Rubber tubing*, Neuber's *bone drains*, and twists of *catgut* or *horse-hair*, are chiefly to be relied upon in draining wounds. Rubber is most generally useful. The softest tubing should be selected, of various sizes, from that which has a lumen of one half-inch in diameter down to one sixteenth. Before it is inserted it should be bent over the finger, and with a pair of curved scissors clipped full of holes about a half-inch apart, as seen in Fig. 8. Rubber drains should be kept dry in clean jars, from which they are taken and placed in 1 to 20 carbolic acid solution when the operation for which they are needed is begun. When a wound is to be dressed only once—the "permanent dressing"—absorbable animal drains should be inserted. For this purpose Neuber's bone tubes (Fig. 9) are preferable. They are made from the bones of young and healthy animals. The crude bone is cut of proper length and size, bored out, turned on a lathe round and smooth, and perforated laterally. Immersion in 33-per-cent muriatic acid for twelve hours completely decalcifies them, after which they are kept (as recommended by the inventor) in 1 to 20 carbolic-acid solution, frequently renewed. I prefer to keep them in alcohol, 95 per cent, or oil of juniper, which preserves them aseptic and hardens them, rendering a too rapid absorption less likely. The tubes are from three to five inches long. There are four sizes: the caliber of No. 1 is six, No. 2 is five, No. 3 is four, and No. 4 three millimetres in diameter (one millimetre is approximately $\frac{1}{25}$ of an inch). The walls are from one to one and a half millimetre in thickness.

These drains can be prepared readily from the bones of fowls by scraping the periosteum off and the marrow out, soaking in muriatic acid (33-per-cent solution) as above, and then in ether for a few hours before transferring them to the alcohol.* Bone drains will be absorbed in from five to twenty days, and are excellent in permanent dressings.

Catgut or *horse-hair* twists or skeins are at times employed for draining small wounds, and are very satisfactory. The violin-strings are twisted into a bunch, as shown in Fig. 10, and laid in the wound at vari-




FIG. 8.



FIG. 9.



FIG. 10.

* If the bones used are from fowls which have been cooked, Macewen recommends that the hydrochloric-acid solution should be one to five of water, and that the tube, when inserted into the wound, should be threaded with horse-hair to prevent collapse from pressure, and to facilitate the removal of clots without taking out the tube and irritating the wound.

ous points, so as to project at the lower angles or in such positions as will secure the most perfect drainage. The hair is taken from the mane or tail, washed clean, and immersed for twenty-four hours in oil of juniper. It is twisted in the same manner as the catgut.

Protective.—Thin *rubber tissue*, *oil-silk*, or *Mackintosh cloth*, may be used to protect the part from atmospheric changes, and to prevent the evaporation and volatilization of the antiseptic agents. The former is preferable, and the oil-silk is next in order. Rubber tissue must be kept in a cool, dry spot, and should be dipped in 1 to 3,000 sublimate before it is applied.

Gauze.—Ordinary cotton muslin of light texture, commonly known as cheese-cloth, impregnated with corrosive sublimate or iodoform, is widely used as antiseptic gauze.

Carbolized gauze has passed out of use.

To make *sublimate gauze* proceed as follows: Cut a bolt of cheese-cloth into pieces a yard long, and place in boiling water for eight hours. Then rinse thoroughly in cold water, and bleach in liquor sodæ chlorinatæ (one part to five of water) for twenty-four hours. Rinse again in clear water, and leave the cloth in a tightly covered jar or tank of 1 to 500 sublimate indefinitely. When the gauze is about to be used, squeeze the water out of it and wet it in fresh 1 to 3,000 solution, and again squeeze it until it is only fairly moistened, not dripping, with the solution. Am Ende's sublimate pink gauze is an excellent preparation. It is stained with eosine, which is a color-test upon the purity of the gauze, for, if the mercury is decomposed or volatilized, the eosine goes with it and the gauze is left white.

Iodoformized gauze is made by moistening the washed cheese-cloth in 1 to 3,000 sublimate, sprinkling it with powdered iodoform from a pepper-box, and then working the powder into the meshes of the cloth until it is a golden-yellow color. It should be made fresh, although it may be preserved for one or two weeks in tight glass jars, wrapped in red or blue paper to prevent the decomposition of light.

Borated absorbent cotton is now almost indispensable in surgical practice. It is used not only to protect the part and to exercise compression, but, for purposes of cleansing and dressing wounds, it has entirely superseded sponges, and is not only cheaper, but preferable in every respect. It is so difficult to prepare, however, that the practitioner is almost compelled to patronize the manufacturer. When an emergency demands it, ordinary ginned cotton of clean fiber may be bleached and softened by treating it in the same way as given for the cheese-cloth. It can be charged with boracic acid by immersing it in a solution containing gr. xv to ʒj of water. It is then dried and wrapped in protective until needed for use.

Well-prepared borated cotton is, next to gauze, the most suitable *absorbent* of discharges from wounds. Beyond these two substances nothing is really needed. Pads or bags of *peat*, *sawdust*, *jute*, *wood-wool*, etc., are practically useless.

CHAPTER II.

BANDAGING.

BANDAGES are employed in surgical practice to retain dressings in position, to secure compression and support to any portion of the body, to maintain any required degree of immobility, and to render an extremity partially or completely bloodless.

They are made of cotton muslin of various degrees of fineness, crinoline, woolen goods, and India rubber. Cotton bandages are most generally employed, but, on account of the greater elasticity of flannel, these are preferable for certain special dressings. Crinoline is only used for plaster-of-Paris bandages. Martin's rubber bandage and Esmarch's bloodless tourniquet are very useful in maintaining the firm compression of a part, either as a means of support or of emptying the vessels.

The muslin should be soft, not starched, and of two kinds—a fairly heavy quality, and the light cheese-cloth. Both should be cut in pieces from eight to ten yards in length. The former can be torn; the latter must be cut. The selvage edge is removed, and the cloth divided into strips varying in width from four, three, two and a half, and two inches, with some one inch or less in width. For the chest and abdomen the wide bandages are needed, the two- and three-inch strips for the arms, legs, head, and neck, and the narrow strips for the hands and fingers. All the loose ravelings along the edges should be pulled off, and the bandages made into compact, smooth rollers.

Bandages may be rolled by hand, yet it is a tedious and tiresome business, and an utter waste of time, when the work can be better and more rapidly done by machinery.

In Fig. 11 is pictured a bandage-roller, simple in construction and cheap. It should be fastened to the edge of a solid table by screws or movable clamps. The end of the strip to be wound is passed in and out over the four bars at the base and apex of the machine, and then around the shaft, so that one edge of the bandage touches the end of the upright. As the crank is turned, the strip is held tightly, and, as it runs over the rods, wrinkling or folding is prevented. A home-made apparatus may be constructed as fol-

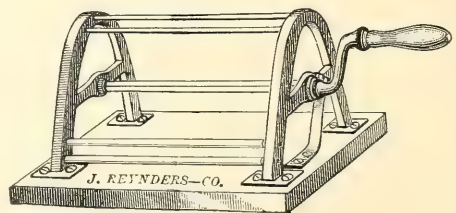


FIG. 11.

lows : Take a cigar-box, remove the top and one end, bore a hole in each side-piece near the open end, and through these pass a piece of telegraph-wire bent in the shape of a windlass and crank. Wires may be run through at other points to serve the same purpose as the four rods in the other machine.

In making plaster-of-Paris bandages, these same machines may be employed, but the crinoline must be loosely rolled, and the powdered plaster worked in with the hands so well and thoroughly that the meshes of the cloth can not be seen. Considerable experience is required to prepare a good plaster bandage, and a poor one will spoil a dressing. Plaster bandages should be made from fresh gypsum on the day they are to be applied. Cotton and flannel bandages should be kept in a chest or closet away from dust and moisture.

Methods of applying Bandages.—The various portions of the body may be bandaged by the *simple spiral*, *reverse spiral*, *simple figure-of-8*, and the *figure-of-8 reverse*.

The *simple spiral* turn is most useful in bandaging those parts of the body where there is no sudden increase in the diameter and volume of the part. It is impracticable under other circumstances.

Hold the bandage in the hand most convenient, with the back of the roller toward the limb (see Fig. 12); with the unoccupied hand take the

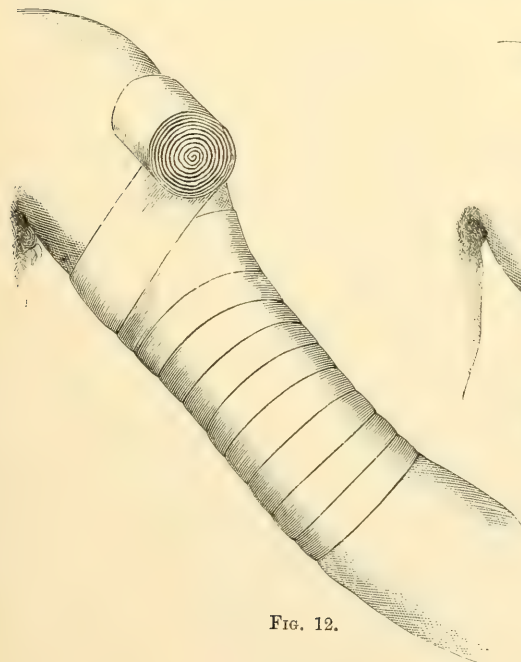


FIG. 12.

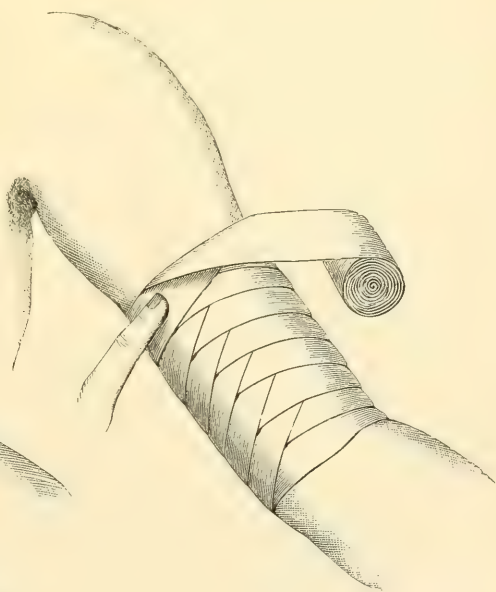


FIG. 13.

free end of the bandage, lay and hold it upon the inner border of the limb, and carry the turn by the front to the outer side of the part to be bandaged.

Having carried the roller twice around the part to secure it, ascend the limb spirally, leaving about one third of each turn uncovered by the last.

The *reverse-spiral* turn (Fig. 13) is applied as follows :

Taking the left arm to be bandaged, hold the roller in the right hand, with its convexity toward the limb, and carry it from the inner or ulnar border, by the front, to the outer or radial border, and thus around the arm by two circular turns to secure the roller. Then, having carried the bandage to the outer side, ascending the limb gradually, lay the thumb of the left hand upon the lower edge of the bandage, press it firmly against the limb to prevent slipping, loosen the roller considerably in the right hand, at the same time turning it one-half turn toward the operator. This process is to be repeated as often as necessary, keeping the reverses well upon the outer border and anterior aspect of the extremity.

The Simple Figure-of-8 Turn.—After the bandage is secured, as heretofore described, ascend the limb sharply, from the inner to the outer border, so that at this outer border the lower edge of the roller shall be several inches above the starting-point. Carry the roller directly across and *behind* the limb to the same point on the opposite side; then obliquely downward in front, crossing the ascending turn at a right angle. When the outer border is again reached, carry the roller behind and directly across the limb to the starting-point (see Fig. 14).

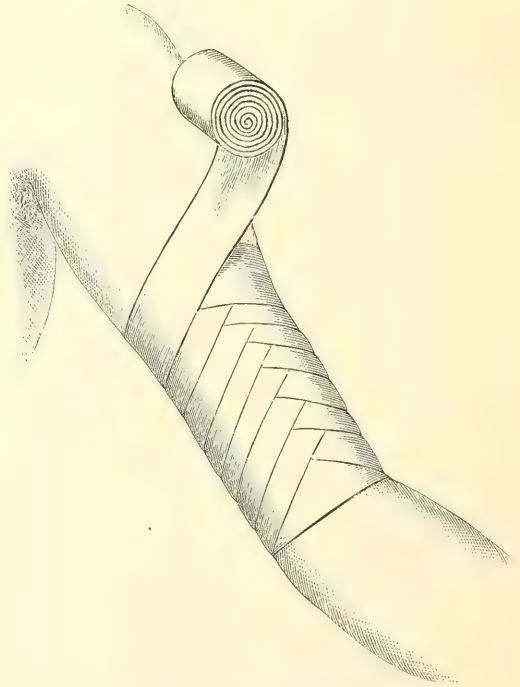


FIG. 14.—The figure-of-8 method.

The Figure-of-8 Reverse.—Commence exactly as for the simple figure-of-8 until the bandage has passed across the posterior aspect of the limb, and is about to descend obliquely along the inner aspect to the front. With the index-finger of the unoccupied hand hold the lower edge of the bandage tightly against the part, while the roller is slackened and turned half over in a direction away from the limb. This reverse in the figure-of-8 may also be made anteriorly, and, when the conformation of the part demands it, may be made both anteriorly and posteriorly.

Of these four methods, the *simple spiral* is more readily applied. When the diameter of the extremity increases rapidly it will not suffice, since it grasps the part at the upper edge of the roller while the lower stands out free and loose.

For all purposes the *spiral reverse* is more generally useful. In competent hands it can be applied to all portions of the body except where the members join the trunk, when it must give place to the *simple*

figure-of-8 turn. Thus, the *spica* at the groin and shoulder, the occiput and chin dressings, and the neck and shoulder bandages, must describe this shape. The *figure-of-8 reverse* is of great use in getting over the calf of the leg in very muscular subjects, where not infrequently all the other methods will fail to hold.

The important rule in bandaging is to *equalize the pressure from periphery to center*. The circumstances of the case will determine the degree of compression. It requires a great deal of study and practice to become expert in applying dressings. One should thoroughly familiarize one's self with each of the methods, for not infrequently a part to be dressed will require a combination of several methods. The question of how tight to apply the bandage may in part be left to the sense of the patient when an anæsthetic is not employed. After an extensive operation, in which Esmarch's bandage has been applied, a very considerable degree of compression is often required to prevent the oozing which otherwise would follow the use of this tourniquet. No amount of description will impart this sense to the inquirer; it can only come from personal experience. One precaution is imperative: the tips of the fingers or toes of the extremity bandaged must always be left open for observation, for if strangulation is threatened it will always be earliest indicated here. A watch should be set on every case where there is

ground for anxiety, with directions to slit the dressing with the appearance of any symptom of strangulation.

Special Bandages—The Hand and Fingers by the First Method (Fig. 15).—Take a roller between three fourths and one inch in width, and ten yards in length. Let the hand to be bandaged be pronated, and commence by taking two or three turns of the roller around the carpus, going from the radial over the back of the wrist to the ulnar side. Having in this manner secured the roller, carry it from the radial side of the wrist obliquely across the dorsum of the hand to the ulnar border of the root of the little finger, then spirally around the little finger two turns to its extremity. Next, return by careful spiral turns, or a spiral reverse, if necessary, to the root of the finger, covering it equal-

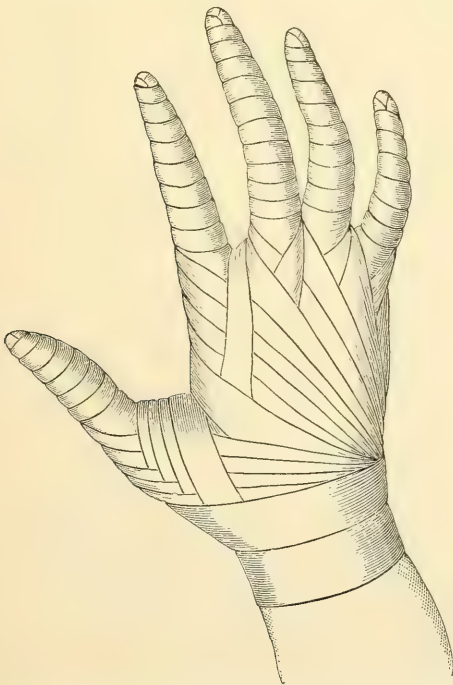


FIG. 15.—Hand-, thumb-, and finger-bandage. (The author's modification of the old method.)

ly and nicely. From the radial border of the base of the finger the bandage is carried over the back of the hand to the ulnar side of the carpus,

then under the wrist, by the front, to the radial side, and again over the dorsum of the hand around to the ulnar side of the same finger, repeating the figure-of-8, as before. Two turns are then thrown around the wrist to secure the former bandage, and the roller is carried in the same manner to the remaining fingers.

When the index-finger is reached, on account of the great space between its root and the thumb, it is advisable to make four or five extra figure-of-8 turns around its base, carrying the bandage a little lower with each successive layer toward the thumb.

Having reached the thumb, the roller is carried spirally to its extremity, as in the other fingers, but in returning, when the last, the interphalangeal, joint is reached, the figure-of-8 turn is commenced at this point, and continued until the ball of the thumb is completely covered.

This method may be applied to the thumb alone, or to any one or more of the fingers, when the remainder of the hand does not need to be bandaged, and is equally efficient in securing splints to these organs.

One objection to it, and a very formidable one to the practitioner, is the length of time necessary to apply it. A more rapid and almost equally effective way is the hand-bandage by the *second method* (Fig. 16).

Place pellets of cotton between the fingers, and a fair-sized tuft in the palm of the hand. Take a bandage from one to two inches in width, carry it one or two turns around the hand where the phalanges join the metacarpus, until it is secured, and then by nicely adjusted figure-of-8 turns (the crossings on the dorsal aspect of the fingers) cover the hand from the tips of the fingers back. When the bandage reaches the thumb in the crotch between it and the index, and begins to roll up, it should be clipped with the scissors deeper and deeper along the edge nearest the thumb with each successive turn until the cut extends to the middle of the roller. Then a split should be made in the middle parallel with its long axis, and the thumb stuck through this; the next split is nearer the distal edge, while with the succeeding turn it may be brought clear of the thumb on its carpal aspect. A spiral, with or without the reverse, will hold on the incline from the thumb to the carpus.

The Forearm, Arm, and Shoulder.—From the carpus to the elbow the spiral reverse or figure-of 8 will usually be required, on account of the pyramidal shape of the part. When the elbow is reached, if the right-angle position (Fig. 17) is determined upon, the figure-of-8 around the humerus and forearm will suffice to climb along the elbow; or the simple spiral, carried over the same ground in the flexure of the joint, and

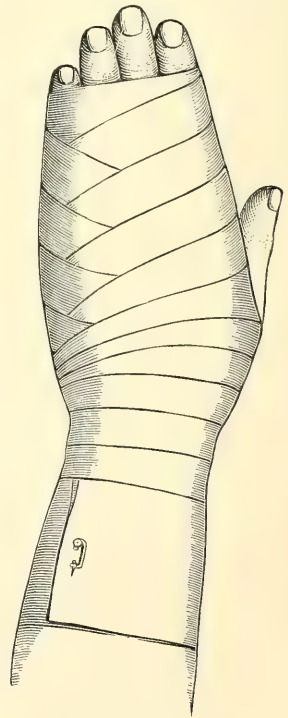


FIG. 16.

gradually ascending over the convexity, will accomplish the same purpose. For the arm the spiral, simple or reverse, will carry the bandage to the axilla.

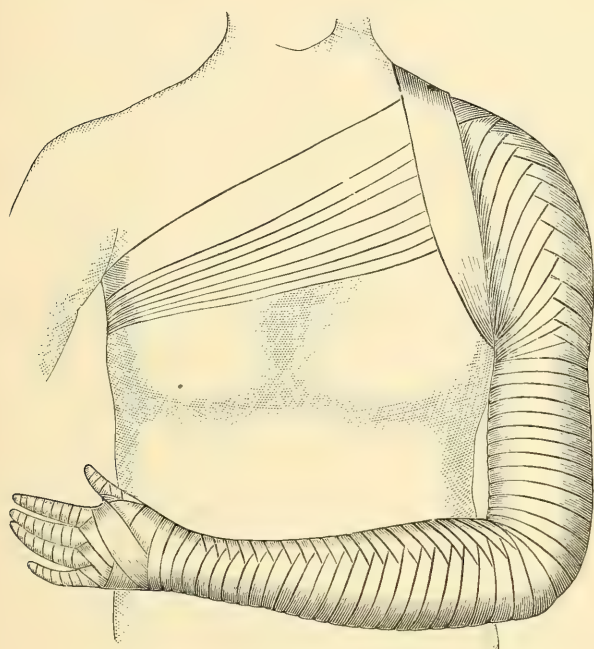


FIG. 17.

When the projection caused by the tendon of the pectoralis major is reached, the roller is carried from the inner side by the front, over the point of the shoulder, around the back, and underneath the opposite arm, across the chest to the anterior and outer surface of the humerus, then underneath the arm, making a figure-of-8 turn, one loop of which surrounds the arm, and the other the thorax. These turns are continued, gradually ascending until the root of the neck is reached. It is best to fill the axilla of both arms with

absorbent cotton to prevent chafing, when this dressing is to be worn for any length of time.

The Toes, Foot, Leg, and Thigh.—The great toe may be bandaged by carrying a narrow roller spirally around it, from the tip to the metatarso-phalangeal joint, and thence by a figure-of-8 around the ankle. This last turn should be several times repeated, in order to hold the dressing firmly. It is customary to include all of the toes in the general foot-bandage.

To bandage the foot, begin by placing bits of absorbent cotton between the toes. Take a roller from two to two and a half inches wide, and about ten yards long. Lay the

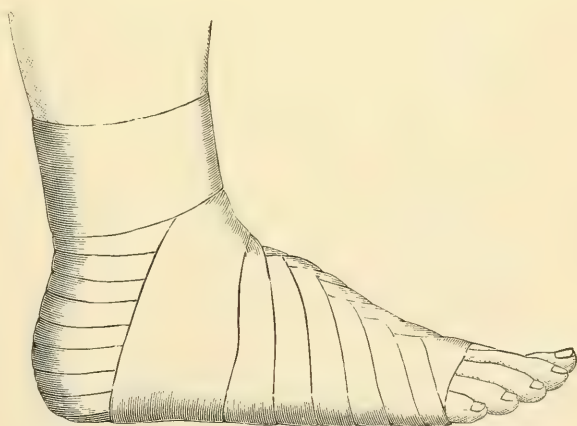


FIG. 18.—The author's foot-bandage with a single roller.

end of the bandage parallel with the axis of the leg, half-way between the two malleoli in front, and carry the roller by the inner side to the heel, so that the middle of the bandage will be over the center of the

heel's convexity, and on to the starting-point. Next, make another turn around the ankle, carrying the posterior edge of the bandage over the center of the turn that has just preceded it, and make one or two other turns in front of this until the heel is completely covered (Fig. 18).

The bandage is then carried around the heel in the same direction, so that its anterior border rests on the middle of the *first* turn, and the roller is carried from the fibular side of the heel across the dorsum of the foot to the tibial side of the great toe.

It then travels under the bases of the toes to the little toe, making a couple of complete turns around the foot at this point, and, when the roller has again reached the fibular side of the little toe, it is made to cross the dorsum of the foot obliquely to the tibial side of the heel, keeping the lower edge of the bandage about a quarter of an inch above the bottom of the heel. Repeat this figure-of-8 turn until the entire foot is thoroughly concealed. It is best to cut with the scissors each turn of the roller about half through just when it crosses the front of the ankle, so that the accumulation of the bandage at this point may not interfere with the movements of the ankle-joint.

The crossings of the figure-of-8 bandage on the dorsum of the foot should be kept a little to the fibular side of the median line.

When the ankle is reached, the bandage should be carried up the leg by the spiral reverse until the sudden prominence of the muscles of the calf is reached, when, if necessary, the figure-of-8 reverse should be practiced to just below the knee. From this point up to the trochanter the simple figure-of-8, spiral, or spiral reverse, may be employed, according to the shape of the limb.

When the level of the gluteal fold is reached, carry the roller obliquely upward and outward about half-way between the trochanter major and anterior iliac spine, on across the sacro-lumbar region to just above the upper margin of the iliac crest of the side opposite the limb being bandaged, thence downward across the abdomen and the groin to the front and outer side of the thigh, and back behind to the inner side at the point of starting. This manœuvre is repeated until the entire hip and groin are covered, when the roller is carried spirally around the pelvis

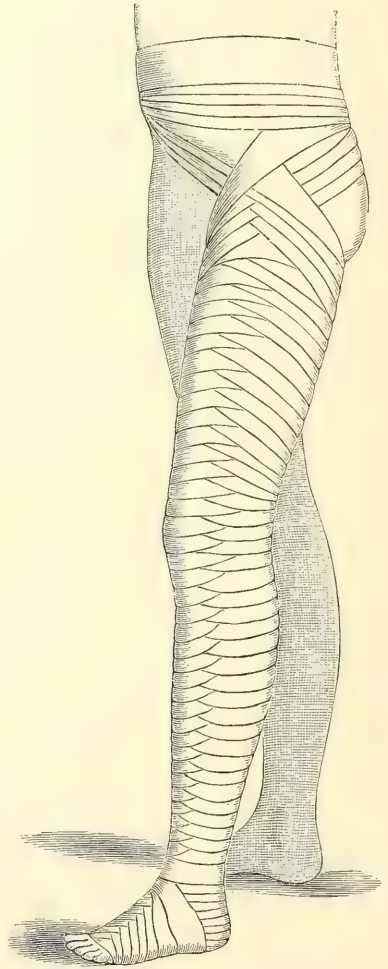


FIG. 19.

and abdomen as high as the umbilicus. The completed bandage is shown in Fig. 19. The portion of this bandage which goes around the thigh, groin, and pelvis is called the *single spica* for the groin, and is admirably adapted to the retention of a dressing upon a bubo or wound of this region, and also makes an efficient temporary compress for the support of an inguinal hernia. A *double spica* with a single roller may be made by carrying the roller, which has already partially covered in the groin and hip of one side, directly across the back to a point half-way between the trochanter and anterior iliac spine of the opposite side, over the front of the thigh to the inner side, and thence behind and outward, describing a figure-of-8 around the thigh and pelvis in a direction the reverse of the preceding (Fig. 20).

The abdomen and thorax should be bandaged by the simple or reverse spiral until the axilla is reached in the male, and the mammary gland in the female.

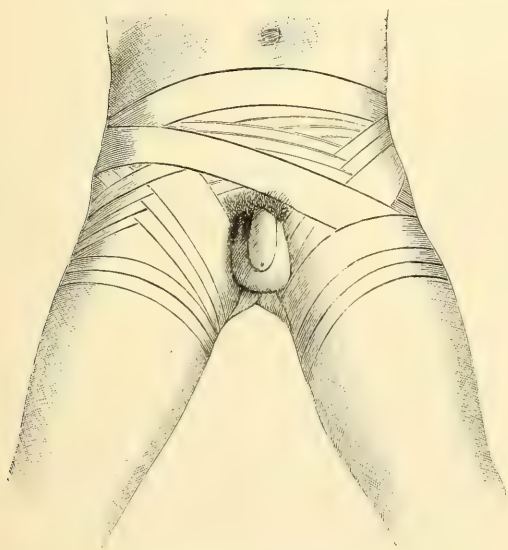


FIG. 20.—(After Fischer.)




FIG. 21.—(After Fischer.)

To bandage the mammary gland it is best to place a thin layer of absorbent cotton over this organ, and under the axilla as well. The roller, about three inches wide, should be carried two or three times around the thorax just below the breast, which, if pendulous, should be lifted well up toward the clavicle. If the right breast is to be bandaged, the operator, standing in front, should carry the roller from the patient's right to the left side, around the body, and then obliquely upward across the front of the chest, catching the under surface of the gland, passing over the left clavicle, making a figure-of-8 around the shoulder and axilla, and then across the back to the starting-point (see Fig. 21). It is now carried directly around the chest, and, when the circuit is completed, again travels obliquely upward on a plane about one inch higher than the preceding turn. This is repeated until the organ is entirely covered. When both

breasts require support, the second may be bandaged in the same way by an additional roller, or, as shown in Fig. 22, a single bandage may be thrown around the thorax and neck in figure-of-8 fashion, so as to support both organs.

Bandages for the Head and Face.—For retaining ice-caps, or other dressings to the head, the hood-bandage will be found convenient, while its modifications will suffice to keep a dressing upon any limited portion of the scalp (Fig. 23).

To apply this, take a roller twelve yards long and two and a half inches in width, rolled from both ends to the center. Holding one head of the roller in each hand, the surgeon, standing behind the patient and laying the middle of the bandage across the forehead just over the eyebrows, carries one roller in the right and the other in the left hand around the head, above

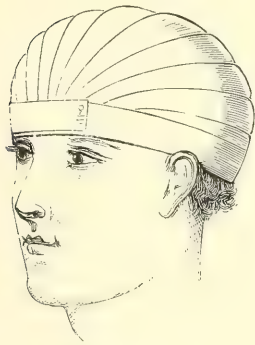


FIG. 23.

the ears, and crosses them under the occiput, so that the roller which went to the rear in the left hand will travel again to the front over the same path. The roller in the right hand is then carried over the head, in the median line, from the occiput to the nose, and at this point it is caught and held down by the encircling turn carried in the left hand. Then carry the roller which came over the median line of the head back again to the rear, so that its right edge will rest on the middle of the first turn. It is again caught under the encircling turn at the occiput, is carried to the front on the opposite side, and continues to travel from before backward in an ellipse that is constantly increasing, until it blends with the encircling turn upon the sides of the head, near the ears. Each successive turn of the elliptic should leave about one third of the turn that preceded it uncovered in the center. Of course, the ends will meet at the same point, before and behind, where the reverses are made.

If it is only required to maintain a dressing in the median line of the scalp, it will suffice to carry a circular turn or two around the head, just above the eyebrows and ears, and below the occiput, while an antero-posterior strip is pinned to this in front and behind.

The Head and Chin Bandage (Fig. 24) may be made to serve several purposes—namely, to retain a dressing on the chin and lower face, the same upon the scalp at any portion, and also for temporary fixation of the lower jaw after fracture of this bone. It is applied as follows:



FIG. 22.—(After Fischer.)

The end of a bandage from one inch and a half to two inches in width is held about half-way between the left ear and the occipital protuberance, while the roller is carried to the front and obliquely across the head, just in front of the right ear, under the chin, up in front of the left ear, then across the scalp, passing backward between the right ear and occiput to beneath this protuberance, when it is carried beneath the left ear straight across the front or labial aspect of the chin, and around by the right side to the point of commencing. This manœuvre should be repeated several times, and the dressing then completed by carrying the roller twice around the head above the ears and eyebrows, and beneath the occiput, and pinning a strip along the median line of the scalp at the various points where the turns cross each other.

Knotted Bandage.—This dressing (Fig. 25) is sometimes em-




FIG. 24.

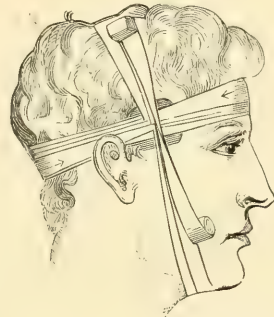

FIG. 25.—(After Berkeley Hill.)

ployed in the arrest of hæmorrhage from wounds of the temporal and other vessels of the scalp.

Take a piece of cork or wood, about an inch in diameter and one quarter of an inch in thickness, and wrap it with sublimate gauze or lint to make a compress. Apply this to the bleeding point, and lay over it the center of a double-headed roller, carrying the turns around the head, above the ears. They are then crossed over the compress, one end is carried under the chin, the other over the top of the head, and are again crossed on the opposite temple. Having carried the rollers again around the head, and crossed them firmly over the compress, the ends are pinned securely and cut off. A horizontal slip may then be pinned to the anterior, middle, and posterior slips of the knotted bandage, beginning in the median line on the forehead, then back to the center of the middle slip, and then to the slip underneath the occiput, to hold the dressing securely in position.

To bandage the eye (the left, for example), hold the end of the strip half-way between the right ear and occiput, and bring the roller forward over the left eye and malar eminence, and around backward beneath the ear and occiput to the point of starting, and repeat once. When the second turn arrives at the right ear it should pass above this and com-

pletely around the skull, just above the eyebrows and below the occiput, in order to secure the oblique turn. Complete the dressing by alternating between the horizontal and the oblique direction of the roller (Fig. 26).

For the upper lip a dressing is readily secured by a narrow bandage passing horizontally around

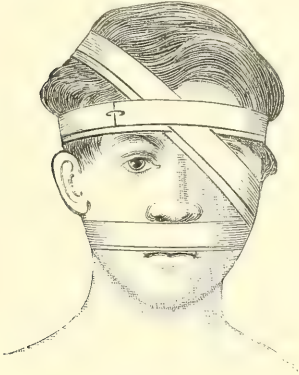

FIG. 26.—(After Esmarch.)



FIG. 27.

beneath the nose and ears, and held in place by the head-stall attachment, as in Fig. 24.

Handkerchief Bandages.—In addition to the foregoing, emergency dressings for different parts of the body may be extemporized from pieces of cloth cut in various shapes—the so-called *handkerchief bandages*.

Head and Face.—A simple hood (Fig. 27) may be made as follows: A piece of soft muslin is cut, 27 by 23 inches, folded over for 6 or 7 inches along its greatest measurement, and laid upon a table, with the short piece underneath. Place the index-finger at the middle of the folded edge, and turn the nearest corners toward the center, forming a pyramid. Now roll the remaining straight edge up until it is on a level with the edge which was turned under, and place upon the head, so that this edge will be put above the eyebrows, while the rolled portion comes across the occiput, and the ends are pinned beneath the chin. The conical tip may be pinned down, if desired.

The *four-tailed cap* is made from a piece of muslin, 45 inches long by 10 wide, split from each end to within 4 inches of the center. Each of the four tails is 5 inches in width. Lay the center of the piece across the vertex, carry the posterior tails forward over the ears, and tie them under the chin and the anterior backward beneath the occiput (Fig. 28).

The *head and face hood* is made as follows: A piece of soft, light cloth, 40 inches square, is

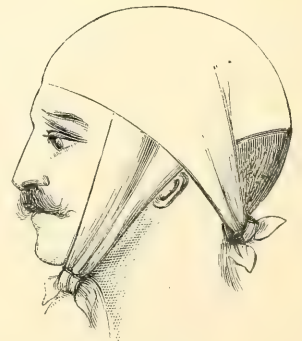

FIG. 28

folded and laid across the head in such a manner that the shortest fold which is on top comes to the level of the eyebrows, while the longer reaches to the tip of the nose (Fig. 29). The corners belonging to the




FIG. 29.—(After Esmarch.)



FIG. 30.—(After Esmarch.)

fold which is parallel with the line of the eyebrows are tied snugly beneath the chin. The longer fold is now turned up to the level of the eyebrows, while the corners belonging to it are drawn forward until freed, and are then carried back and tied beneath the occiput (Fig. 30).

For holding an ice-bag or dressing upon the head, the *skull-net*

(Fig. 31) will be found of use. It is made of cotton threads, is tightened around the head by a tape, which draws it together like the strings of a reticule, and is further secured by a strap tied under the chin.

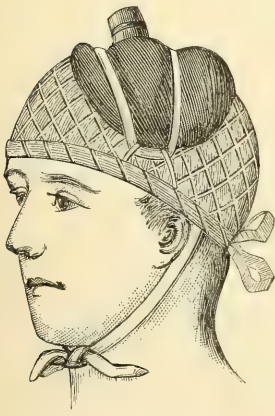

FIG. 31.—(After Esmarch.)

The *four-tailed dressing for the chin and lower jaw* is made by splitting a strip of muslin, 6 inches wide and 45 inches long, from each end to within $1\frac{1}{2}$ inch of the center,

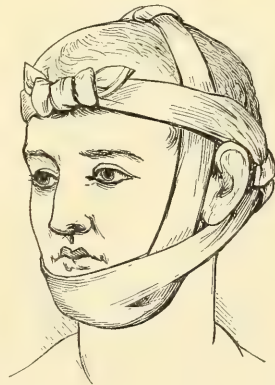

FIG. 32.

placing its middle over the chin, and turning the posterior tails upward in front of the ears to be tied over the vertex. The anterior tails are now carried back below the ears, crossed once, and pinned beneath the occiput, while the ends are carried upward and forward and tied upon the forehead (Fig. 32).

Other special dressings will be described in the chapters on Regional Surgery.

CHAPTER III.

ANÆSTHESIA.

ANÆSTHESIA means loss of sensibility. It may be *local* or *general*. In the former, the sensibility of a limited portion of the body is more or less completely lost, while the patient remains conscious; in the latter, both consciousness and sensibility are lost.

Local anæsthesia may be obtained in a remarkable degree by the judicious employment of the hydrochlorate of cocaine, for the application of which agent to surgical use the world will ever be indebted to the Austrian, Koller. The 2- and 4-per-cent solutions are chiefly used. An aseptic solution may be made by employing gr. j boric acid to ℥j of distilled water. To this add gr. xx hydrochlorate of cocaine, which is approximately a 4-per-cent solution. Applied to the cornea, conjunctiva, or any mucous surface, cocaine is rapidly absorbed, the capillaries are contracted, and the end organs of the sensory nerves paralyzed. Upon the unbroken integument it produces little or no effect. Injected into the tissues, it produces anæsthesia wherever it reaches—in bone, muscle, or the subcutaneous structures. Thrown into the substance of a nerve, or immediately around it, it is readily absorbed, and produces anæsthesia in all parts in the range of distribution of the nerve-trunk beyond the point of injection. The quantity which can be safely used has not yet been determined, and must vary with the susceptibility of the individual. Applied to the eye, there is no danger of absorption of a quantity capable of doing harm. Upon the mucous surfaces of the buccal cavity and pharynx several drachms of a 4-per-cent solution may be brushed with a camel's-hair pencil in the course of an operation lasting an hour, for here the excess is washed off and diluted with the saliva, which, of course, should not be swallowed. Injected into the deeper tissues, below the face and neck, from twenty to thirty minims of a 4-per-cent solution should be the limit within at least one hour before the dose is repeated, unless a good proportion of the liquid injected is allowed to escape by immediately incising in the line of injection. Within the distribution of the fifth nerve its administration should be especially cautious. Partial respiratory paralysis has occurred in several instances after the injection of fifteen minims of a 4-per-cent solution in the supra-orbital region, and in other portions of the face. Artificial respiration was necessary for about fifteen minutes. Chloroform or ether narcosis is believed to be unusually dangerous while a patient is under the influence of cocaine.

For the eye, drop two or three minims of a 4-per-cent solution into this organ every minute or two, until from five to ten minutes have elapsed. For light work, such as the removal of a foreign body, or touching the lids with blue-stone, the smaller quantity will suffice; for corneal section, iridectomy, etc., the anæsthesia should be more profound. In the mouth, it will suffice to paint the part to be anæsthetized with the 4-per-cent solution by means of a camel's-hair brush, every two or three minutes, for a half-hour before, and at intervals during the operation. In this way ulcers may be cauterized, or limited incisions made with perfect insensibility, and by the employment of this agent any irritable condition of the mouth and throat may be relieved. I have operated for cleft of the soft palate in an adult with perfect anæsthesia by this method.

In minor surgical operations upon the extremities, a prolonged and perfect anæsthesia may be secured by the method of Corning, which consists in injecting the fluid into the tissues of the part to be anæsthetized, waiting from two to five minutes for absorption of the solution by the vessels, and then keeping the cocaine in the tissues, by arresting the circulation, with a rubber tourniquet applied between the injection and the heart. The efficiency of this method has been amply demonstrated. The twenty or thirty minims of 4-per-cent solution should be distributed equally in the line of the incision. A single puncture with the hypodermic needle will suffice to allow the fluid to be thrown over an area an inch in length, and the effect is so rapid that the second puncture can be made through the anæsthetized skin. The needle, after passing through the integument, travels along just beneath it to its full length. One or two minims are then forced out, the needle withdrawn a quarter or half inch, and a like quantity discharged. If a deep incision is required, the needle should go into the deeper tissues. One advantage of this method is that a smaller quantity of cocaine will produce a greater degree of anæsthesia, and with less constitutional effect. When as much as thirty minims are used, the excess may be squeezed or pressed out of the part, or washed out with the irrigator. As to the length of time for which a tourniquet may safely remain holding the part beyond full of stagnant blood, I would say that a half-hour would be within the limit of safety. I have constricted the penis continuously for an hour in circumcision, the great toes on several occasions for more than half an hour in removing ingrowing nails, and the arm for half an hour in a number of cases. It is, however, not always necessary to entirely arrest the circulation of a part, for, if the elastic be applied close behind the part to be incised, the superficial compression will retard the flow at this point, while the deeper vessels and remote capillaries are not materially interfered with.

In minor operations upon the trunk, face, head, and neck, greater precaution must be taken, for here the solution is carried directly to the center. This is especially necessary in the head and face, for reasons above given.

If the precaution is taken to throw in a small quantity—say five or ten minims—in the line of the proposed dissection, and immediately incise and dissect as far as the zone of anæsthesia extends, so much of the injected cocaine escapes with the oozing that comparatively a small proportion

passes into the general circulation. By this practice I have made a great many operations requiring 3j-ij of a 4-per-cent solution without accident. The details to be observed in special operations, such as amputation of a finger or toe, circumcision, extirpation of ingrowing toenails, etc., will be given under the headings to which these various procedures belong.

Another method of producing local anæsthesia is by means of *ether spray*. For this purpose the ordinary Richardson's atomizer (Fig. 33) will suffice. In purchasing this apparatus, secure one with a silver tube—not of glass, for this is too fragile, nor of gutta-percha, which is always getting stopped up. The atomization of the ether, and the consequent rapid evaporation, produces an intense cold, retards temporarily the capillary circulation, and thus paralyzes the end organs of the sensory nerves.

Everything being in readiness, an assistant commences the atomization, holding the end of the tube from three to six inches distant from the skin, so that the shower of vapor will fall upon the area to be incised. The skin under the spray changes from the normal flush to a whitish purple, which, by a continuation or sudden increase of the force of the spray, will

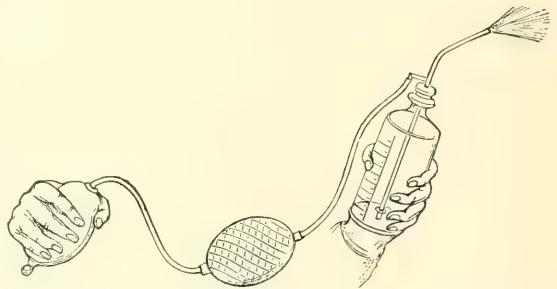


FIG. 33.—Richardson's atomizer, for the production of local anæsthesia.

turn white and become stiff and frozen. This last condition is to be avoided in general, for the reaction from it is painful and sloughing may occur, while a sufficient anæsthesia may be obtained without real freezing. When, by pinching with the forceps or pricking with the knife, insensibility is assured, the operation should begin, and the spray be continued. Ether spray can not be employed about the eye, on account of the irritation it produces, nor about the nose and mouth, on account of its being inhaled. It is in general inferior to cocaine anæsthesia, because the latter secures a more complete insensibility, and the reaction is far less painful. *Rhigoline* may be used instead of ether, but it is so difficult to obtain that it has been superseded by the ether.

A mixture of equal parts of cracked ice or snow, and salt, applied directly to a part or wrapped in a thin cloth and laid upon the skin, will produce perfect local anæsthesia, and is a fair substitute when neither the cocaine nor ether can be secured, and the emergency demands operative interference. For fear of over-freezing, the mixture should be lifted frequently and the part inspected.

General Anæsthesia.—For any simple operation which must of necessity be prolonged, and for all formidable procedures in surgery, complete and general narcosis should be secured. The deliberate conduct of an operation which is scarcely possible when a patient is not profoundly anæsthetized, gives an assurance of success not to be hoped for under

any other conditions ; and when to this is added the almost perfect freedom from danger in properly conducted general anæsthesia, how much more should the profession strive to educate the public out of the unfounded dread of taking an anæsthetic. It is this fear which induces many patients to conceal or silently bear a malady which, if operated upon early, would prove insignificant, but which, when left until pain, exhaustion, or impending death drives them to seek relief at the hands of the surgeon, is too often formidable. One cause, and the chief one, for this unfortunate condition of affairs, is the reckless employment of these agents, the lack of precaution in preparing a patient for narcosis, as well as in the method of administration. Of the various anæsthetics which have been introduced for surgical use, only two deserve to be considered, and in order of preference they are *ether* and *chloroform*.

Ether is so much safer than chloroform that it should be used in the large proportion of cases. The estimated death-rate after ether is 1 in 20,000, for chloroform 1 in 3,000. While the value of statistics may be questioned, and admitting that a certain number of cases perish after ether narcosis from uræmia or pneumonia, the proportion of fatal cases is still so largely with chloroform that ether should be selected as the safer agent. All of the minor objections to ether by the advocates of chloroform narcosis—namely, its slowness of action, irritation of the respiratory tract, nausea and vomiting, inflammability, extra quantity required, etc.—fade into insignificance when brought face to face with the fact that the number of lives sacrificed by chloroform are so largely in excess of those after ether narcosis.

In my opinion, *chloroform narcosis* is only justified under the following conditions :

1. In children under six years of age, where it is less apt to cause an accumulation of mucus in the trachea and bronchi than ether. Its more rapid and less irritating action renders it preferable in this class of patients.
2. In women in childbirth where the recumbent posture is imperative.
3. In an emergency where ether can not be obtained.
4. In a patient who has previously been in ether narcosis, in which dangerous symptoms were caused by the ether, or in which rigidity could not be overcome.
5. In an emergency where it becomes necessary to perform an operation within two or three hours after the ingestion of a quantity of solid food.
6. In some exceptional cases of laryngeal or tracheal stenosis.
7. In patients suffering from well-marked acute or chronic nephritis.
8. In cases of extensive bronchitis or pneumonitis with dyspnoea.

In all other conditions ether should be given. The slowness of its action is an objection unfounded in fact, for, if desired, ether narcosis can be effected within ten minutes. Nausea and vomiting are objections without value when the proper precautions are taken to prevent the ingestion of solid food or milk for eight hours before the administration begins. The inflammability of ether requires ordinary precaution in not allowing

a light or cautery point to be brought within five or six feet of the ether cone or flask. Although I have used ether many times with artificial light, I have never seen an accident, and do not hesitate to recommend its invariable employment for night-work. The question of bulk or quantity can only come up in remote military or frontier practice, where transportation is difficult.

The Administration of Ether.—Complete narcosis may be obtained from the vapor of ether administered by *inhalation*, or by being introduced into the rectum. The latter method is rarely practiced, except in operations about the mouth.

The following points are essential in the successful administration of ether: Only the best *quality* of *ether fortior* should be employed. That manufactured by Dr. Squibb is generally preferred in America. It should have a specific gravity not greater than 0.728, should boil violently when in a test-tube it is subjected to the heat of the hand, and a bit of glass is dropped into it. The *quantity* to be used will depend in part upon the length of time required for the performance of the operation, the construction of the inhaler, and the idiosyncrasy of the patient.

As ordinarily given with the Allis inhaler, which allows of a free admixture of air and considerable evaporation, to maintain complete narcosis for one hour will consume from twelve to sixteen ounces. The preparation of the patient is important. As just stated, solid or coagulable food should be forbidden for at least eight hours before an operation. The bowels should be moved by a laxative on the night before the anæsthetic is to be given, and, if necessary, by enema on the morning of the same day. Great care should always be given in the selection of proper nourishment for the patient for several days at least prior to the operation. Solid food, with the exception of the eight-hour limit, is not contra-indicated unless the abdominal viscera are involved in the operation. A half-hour before the anæsthesia is commenced, about two table-spoonfuls of rye whisky or brandy in a teacupful of water should be taken into the stomach. If the patient is unusually nervous and excitable, or suffering great pain or any marked irritation of the air-passages, from one fourth to one third of a grain of morphia should be injected hypodermically about twenty minutes before the inhalation. It is important to explain to the patient the action of the agent, and, above all, to impress upon him the entire absence of danger; that, although it will at first cause him to experience a sense of strangulation or suffocation, yet this will last only for a minute. Finally, artificial teeth or any loose substance should be removed from the mouth, and the clothing loosened about the neck, chest, and abdomen. Upon a table, within reach of the etherizer or his assistant, the following articles should be arranged in order:

1. A wedge- or screw-shaped piece of wood for forcing and holding the jaws apart (Fig. 34). A Sayre's periosteal elevator is a good substitute. 2. A Goodwil-



Fig. 34.—Hard-rubber oral screw.

lie's mouth-gag (Figs. 35 and 36) for keeping the jaws permanently separated if the emergency arises. The Mott-Heister gag will do as a substitute (Fig. 37). 3. A strong tenaculum or forceps, for drawing out

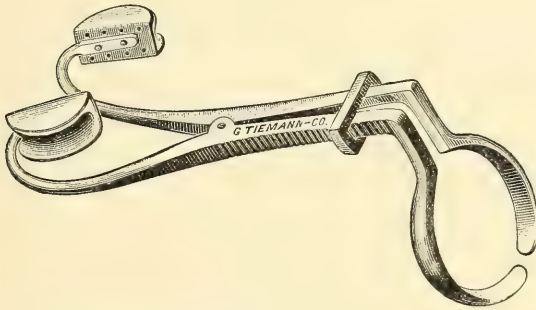


FIG. 35.
Goodwillie's mouth-gag.

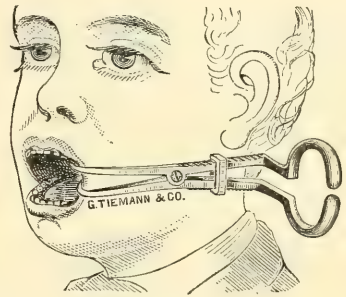


FIG. 36.
Goodwillie's mouth-gag in position.

the tongue. 4. A large-sized curved needle, armed with a good silk thread, for transfixion of the tongue if the emergency arises. 5. Two or three curved probangs with small sponges *tied* on, for mopping out the pharynx, throat, and mouth (see Fig. 43). 6.

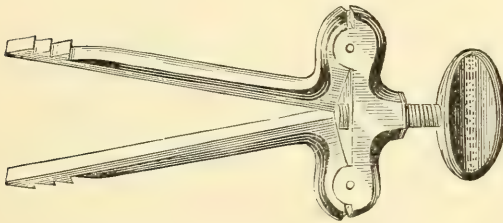


FIG. 37.—Mott-Heister speculum oris.

Several ounces of whisky or brandy undiluted: a hypodermic syringe filled with this and ready for use; an ordinary syringe for a whisky or warm-water enema. 7. An extra

can of ether. 8. A silver trachea-tube. 9. A pus-basin or pan, in case of vomiting. 10. When an operation which may involve great loss of blood is undertaken, a ten-ounce saline solution for transfusion. The formula is: Common salt, gr. xxx; carbonate of soda, gr. v; water, ℥ x.

If necessary, the ether may be poured directly from the can into the inhaler, but the bottle shown in Fig. 38 will be found very convenient, and, as it is graduated, the quantity used can be readily estimated.

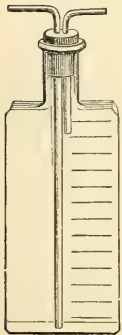


FIG. 38.

The Allis inhaler, until recently in common use, "consists of a wire framework sufficiently large to cover the lower part of the face. The wires are parallel, and about one eighth of an inch apart. Between the wires, from side to side, a strip of bandage two and a half inches wide

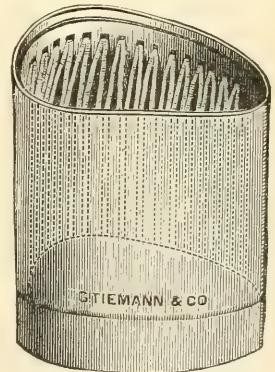


FIG. 39.—The Allis inhaler.

is passed. Its advantages are these: The ether being very thoroughly mixed with air, the patient does not suffer from the suffocation usually

felt at first inhaling ; there is a large evaporating surface. A very much smaller quantity of ether is used, and less escapes into the room than with the usual mode of giving this anæsthetic ; the ether can be dropped from a bottle on the distal end of the inhaler without removing it from the face ; the mask is soft and pliable, fitting accurately to the nose and mouth ; and, lastly, it is of very simple construction, and can not get out of order. Over this frame is drawn a piece of stout sheet India-rubber, or patent leather, which has been stitched together at the edges, so as to make a covering for the frame, projecting over one end two inches, to form the mask, and at the other one inch."

The great objections to this apparatus are—(1) the excessive quantity of ether necessary to produce and maintain anæsthesia, and (2) the contact of the cold vapor with the air-passages. Neither of these objections are present in the *Clover* inhaler, in which the minimum of ether is used, while the inspired vapor is warmed before it reaches the trachea. Although as yet not in general use, it is believed that this valuable inhaler will be more widely employed as its merits become known.

A very efficient inhaler is represented in Fig. 40, consisting of a rubber flange, or mouth- and nose-piece, about three inches in diameter and two in width, slipped over the larger end of an ordinary lamp-chimney. A sponge is placed in the expansion of the chimney, into which the ether is sprinkled, without removing the apparatus, and through which the proper quantity of air can pass in and out.

In an emergency an inhaler can be made by cutting a piece of pasteboard, twelve inches long by seven wide, shaping and pinning it into a cylinder, and lining it with a folded towel, or other cloth. A notch should be cut out to fit over the nose, and the edges softened by wetting. Thickly folded newspaper will serve the same purpose.

A hat-crown, with a segment removed and the top perforated, will answer. The cloth and paper *cone* should not be employed, being objectionable in not allowing a sufficient admixture of air, and in having to be lifted from the face when additional ether is required.

In commencing the administration, which should be done in a room away from the preparations for the operation, if the Allis or any *open* inhaler is used two or three *teaspoonfuls* of ether are sprinkled into the inhaler, and the apparatus held about two inches from the lips, the assistant standing at and above the patient's head. After a minute or two a like quantity is added, and the rim is now allowed to rest on the face. The patient is directed to breathe freely and to force all the air out of the lungs, to blow through the inhaler, and to inspire deeply. No talking should be permitted within hearing, except the

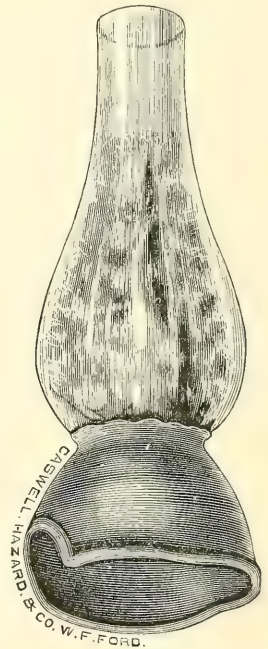


FIG. 40.
H. M. Sims's ether-inhaler.

words of direction and encouragement from the one in authority. If at the start an inhaler is surcharged with ether, and placed closely over the mouth and nose, the irritation is so great that spasm of the glottis, with violent coughing, occurs, and a sense of strangulation, which frightens the patient, and causes an unnecessary struggle and commotion. Indiscriminate conversation in the presence of a patient who is being anæsthetized should be forbidden, since it often induces boisterous conduct or unguarded expressions from the half-intoxicated subject. In the course of five or six minutes the degree of tolerance established will allow the addition of 3j to 3ij of the anæsthetic, and this may be repeated in three or four minutes. At this period, about ten or fifteen minutes after commencing the inhalation, the face becomes flushed from capillary distention, the pulse is considerably increased in power and frequency, accompanied by delirium varying in character and degree. If the patient should now begin to struggle and resist the inhalation, the assistants should hold the arms and legs firmly against the bed or table. When help is scarce, this feature should be anticipated, and a leather strap or rope passed around the table or bed and over the legs, just above and below the knees, which should be tightened at the proper time. The arms should be held against the bed close to the sides in full extension and supination. Every few minutes from 3ss to 3j of the anæsthetic should be sprinkled into the inhaler. In from fifteen to twenty minutes all movements of volition cease, the respirations are regular and soft, the pulse is slightly full and accelerated; the pupil, which at first contracted, is now dilated, and the finger, rubbed along the eyelashes or over the cornea and conjunctiva, produces no spasm of the orbicular muscle of the eye; the arms fall limp and helpless, and remain in any position in which they may be placed. The patient is now in the *second stage*, and it should be the aim of the etherizer to keep the narcosis just a little beyond consciousness. If he is thoroughly trained, this can almost always be done; and to the operator the sense of security from the danger of asphyxia, on the one hand, and the annoyance of the patient's becoming conscious, on the other, is invaluable. In operating without a tourniquet, the color of the blood which escapes should be noticed, for black blood indicates asphyxia, its sudden cessation heart-failure.

When in the course of narcosis the respiration becomes markedly irregular and infrequent, and the breathing stertorous in character, the indications are those of too profound paralysis, and the ether should be temporarily discontinued. Lividity of the face indicates asphyxia, and demands immediate attention. Asphyxia may occur from several causes, and in any stage of etherization. In the *first stage*, or stage of excitement, from *muscular fixation*, the respiratory muscles may be seized with tonic spasm, the chest and abdominal walls remain immovable, and the teeth clenched by contraction of the muscles of mastication. The veins of the forehead, face, and neck become enormously distended, and the skin blue. This condition is not infrequent in subjects addicted to chronic alcoholism. It is rare in other patients when the narcosis is gradu-

ally and carefully accomplished. It should be relieved by temporary discontinuance of the ether, forcible separation of the jaws by means of the screw-gag, or other instrument, pulling the tongue out of the mouth with

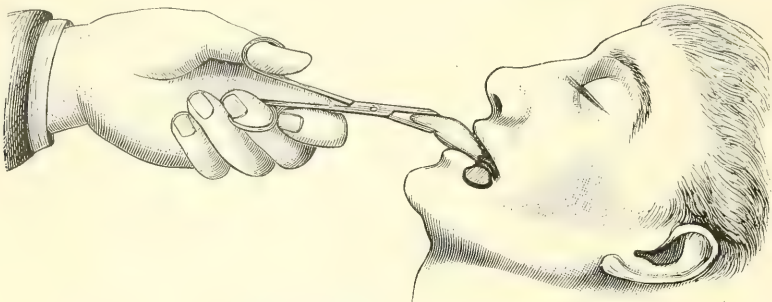


FIG. 41.—(Modified from Esmarch.)

a forceps or tenaculum (Fig. 41), and compression of the thorax by laying the hands spread out upon the lower antero-lateral surface of the ribs and pushing inward until the lungs are emptied, then allowing the ribs to expand. A few repetitions of this manœuvre will suffice, and the administration of the anæsthesia should be resumed.

In the *second stage*, or that of complete narcosis, respiration is frequently interfered with by the tongue gravitating backward upon the larynx. This can usually be corrected by placing the index-finger behind the angle of the jaw, and pressing this bone directly forward (Fig. 42). The hyoid bone, fastened to the chin by the genio-hyoid

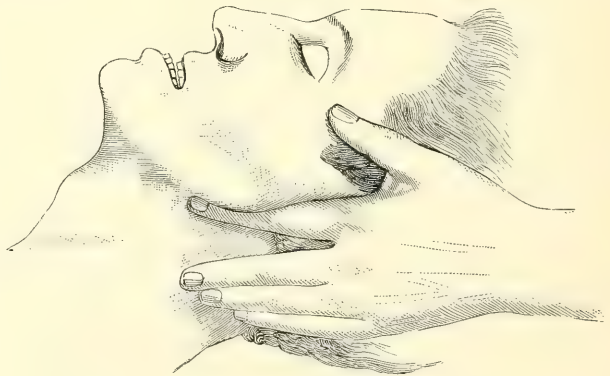


FIG. 42.—(Esmarch.)

muscles, is thus pulled forward, and the tongue is lifted from the larynx. If this does not succeed, the gag should be inserted, and the tongue held




FIG. 43.

out by the tenaculum, forceps, or silk thread. Whenever mucus accumulates in the pharynx and mouth, it should be mopped out by the sponges tied to

curved holders (Fig. 43). These should be carried well back to the larynx, and along the sides of the tongue and buccal walls. In operations about the mouth, or when in the stage of muscular spasm the

tongue has been wounded by the teeth, coagulated blood may get into the larynx, and require removal by the sponges.

When vomiting occurs in ether anæsthesia, it is preceded by a number of spasmodic movements of the muscles of deglutition and of the abdominal walls. Upon the supervention of these symptoms the patient should be turned well over to one side, and the head further rotated and depressed, so that any ejected matter will gravitate readily out of the mouth and into a basin held in readiness for this emergency. Not infrequently food ingested against the advice of the surgeon, or, in some instances, solids taken more than eight hours before an operation, remain in the stomach undigested, and are vomited during the anæsthesia. This accident occurs usually late in the narcosis, and is often caused either by elevating the patient's head too much, or by allowing him to come partially out of the narcosis. If a clot of blood, or any occluding substance, be carried into the larynx or trachea, and fatal asphyxia becomes imminent, proceed rapidly as follows: Direct the windows to be opened, so that all the oxygen possible may be admitted; slide the patient over the end of the table until the head hangs down, and tilt the foot of the table up by placing the lower legs upon a stool or chair. Direct an assistant to stimulate the respiratory movements by bi-manual compression of the thorax at intervals of from five to ten seconds, while the operator does a rapid tracheotomy and inserts the tube, grasping the edges of the wound with forceps to arrest bleeding. If a tube is not at hand, the windpipe should be held open by retractors, which will also compress the bleeding vessels. The method of

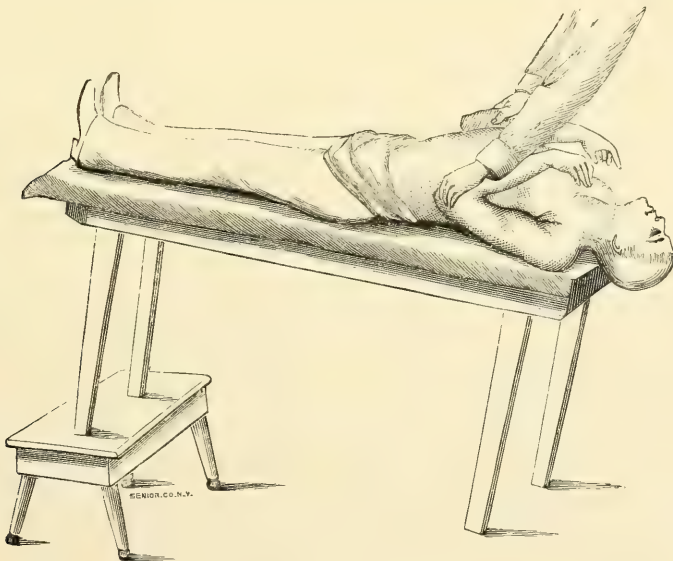


FIG. 44.

Sylvester should now be carried out: Standing at the patient's head, as he rests upon the inclined table, the operator seizes the arms, at or near the elbow, and presses them down upon the thoracic walls, thus forcibly emptying the lungs (Fig. 44), and immediately thereafter extends them

upward parallel with the long axis of the body, aiding in the free expansion of the chest (Fig. 45). This is repeated from ten to fifteen times a minute, and kept up by relays of assistants, if necessary, until voluntary

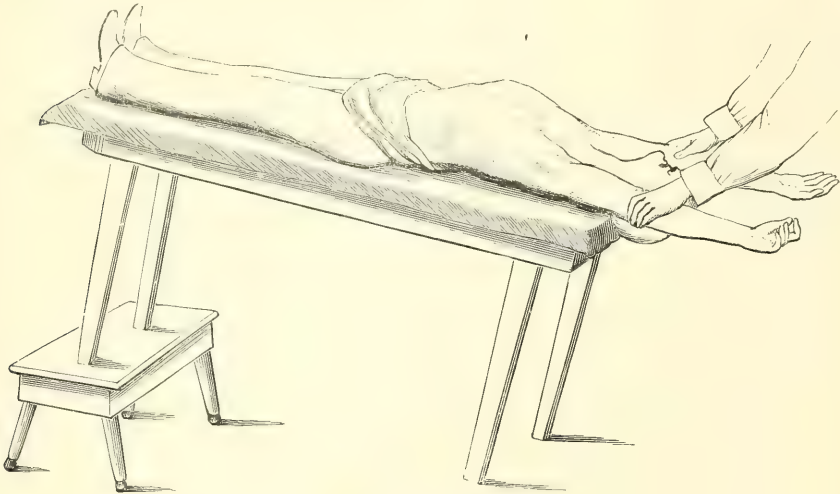


FIG. 45.

respiration is established, or the heart has ceased to beat. All this while the mouth should be kept open, and the tongue pulled forward and out of the mouth.

Heart-failure is exceedingly rare in the early stage of ether narcosis. A weak heart, as a rule, is stimulated by the anæsthetic. It is more apt to be a part of the later stage, and after a prolonged administration with loss of blood or the added shock of the operation. It is indicated by a gradual weakening in the force and an increased rapidity of the pulse, or by the rapid supervention of pallor from sudden stoppage of the heart. When the first condition prevails, pure rye whisky, or brandy, should be administered hypodermically, two or three syringefuls at once (each syringeful = 3 ss.), and repeated at intervals of a few minutes until improvement is noticed. A like result may be obtained by injecting a teacupful of warm water and whisky (equal parts) into the rectum. Elastic bandages should be thrown around the extremities in order to drive all the blood to the centers. When sudden syncope occurs, place the patient's head lower than the body by allowing it to hang over the upper end of the table, while the lower end is well elevated (Fig. 44). At the same time strike sharply upon the præcordial region with the palm of the hand, and shower the chest and epigastrium with cold water.

Ether narcosis may be also secured and maintained by administering this agent by the rectum. This method was introduced by Pirogoff about the year 1847. It consists in the introduction of the vapor of ether as follows: A graduated bottle is fitted with a perforated cork, through which passes a glass tube. To this pipe a rubber tube is attached, and at the other end is a glass tube for introduction into the anus. The anal tube being introduced well into the rectum, the bottle

of ether is placed in a flat-bottomed basin containing warm water, which causes rapid vaporization of the anæsthetic, the vapor passing into the rectum, where it is absorbed by the vessels. The quantity can be regulated by pressure upon the tube and removal of the warm water. An unpleasant sensation is at first experienced, and this is soon followed by the constitutional effects of the agent. Even when carefully employed, rectal etherization is a dangerous procedure. It should only be entertained in those rare cases of extensive dissections about the mouth, where the presence of the cone would dangerously prolong the operation. In one of my cases, after having successfully employed this method in some thirty instances, death resulted fifteen hours after the operation from shock. The patient had been primarily anæsthetized by inhalation, and the vapor was not carried into the rectum until the cone was removed from the mouth and nose. Only $\frac{3}{4}$ ss. was admitted to the bowel. The operation on the lip was completed in twenty minutes, and for the last five minutes the ether was entirely discontinued. The patient regained consciousness in an hour, and, although complaining of an uneasy sensation in the abdomen, his condition was considered good. Ten hours later severe ileo-colitis developed, followed by collapse and death. The autopsy showed very recent congestion of the kidneys. The walls of the lower portion of the ileum and all the large intestine were intensely injected. There was considerable blood in the cavity of the gut.

Chloroform.—Pure chloroform is a colorless volatile liquid, with a specific gravity of 1.480, not highly inflammable; it has a peculiar odor, at first sweetish to the taste, and afterward burning and pungent. Applied to the skin, and prevented from rapid evaporation, it produces redness and vesication. When shaken with pure sulphuric acid in equal parts, no discoloration ensues. *Impure* chloroform, on the other hand, colors the acid brown.

The preparations for chloroform narcosis differ in no essential features from those just given. Since this anæsthetic is more powerful, a

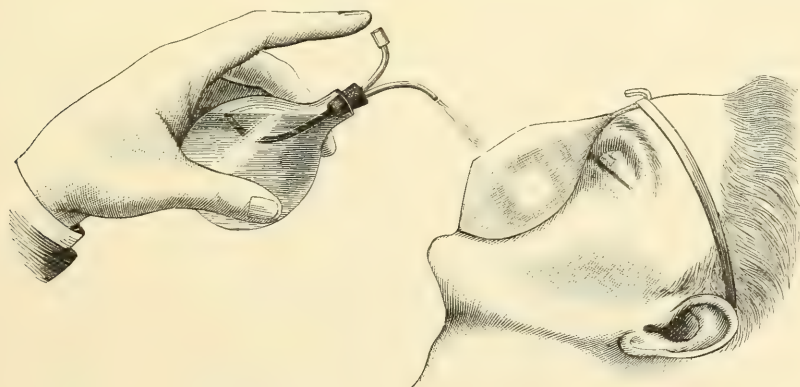


FIG. 46.—(Esmarch.)

much smaller quantity is used. A simple napkin folded into a square of five or six inches will suffice as an inhaler. The apparatus of Esmarch

(Fig. 46) is, however, preferable. It is composed of a wire frame shaped to fit over the nose and mouth, the center wire extending up an inch or more, and bent into a hook. Over this a piece of canton-flannel or soft cloth is stretched so tightly that the threads are parted sufficiently to allow the free passage of air through the covering. To the upper end or hook a tape is attached, and tied around the head in such a position that the inhaler falls over the mouth and nose. The administration is begun by pouring twelve or fifteen drops of the anæsthetic upon the inhaler or napkin. A free admixture of air is necessary. The napkin should not be held in contact with the lips or nose, for fear of shutting off the proper quantity of air. It is a wise precaution to cover the skin about the mouth and nose with vaseline to prevent the irritating effect of the chloroform. In two or three minutes the same quantity is renewed, and so on until sensibility and consciousness are lost. Chloroform narcosis may also be divided into three stages.

The *first* is the stage of excitation. In this the pulse is usually increased in force and frequency, the face is flushed, the pupil normal or contracted; delirium is present, and a condition of muscular rigidity ensues, varying in degree in different subjects. It is almost always well marked in patients of the alcohol habit. The *second stage* is that in which sensibility and consciousness are lost, yet in which the functions of the heart and respiratory organs are performed in an almost natural manner. The pupil is now dilated and arterial tension diminished. In the *third stage*, that of profound paralysis, the breathing becomes shallow and stertorous, the heart-beats rapid and weak, and the arterial tension is markedly diminished.

The *second* is the *operative stage*. The *third* should be avoided. Death during the inhalation of chloroform occurs from both heart and respiratory failure, and may take place in any stage of the narcosis. It is the heart, however, which fails in the vast majority of fatal cases, and this organ not infrequently suddenly and without warning ceases to beat. On the other hand, ether, when given in lethal doses, paralyzes the respiratory muscles, of which there are almost always premonitory symptoms that will not escape the acute observer and cautious surgeon. When natural respiration fails, artificial means may be readily employed and life saved by keeping up a sufficient quantity of air until the effects of the ether passes away. In heart-failure from chloroform there is little hope of restoration of function.

CHAPTER IV.

SURGICAL OPERATIONS.

Instruments.—Much of success in practice depends upon the possession of a variety of instruments which should be of the very best material, made after well-approved patterns, and as simple in construction as possible. The best instruments are now made with good-sized handles, not large enough to be cumbersome, but sufficiently large to be grasped firmly in the hand. For all knives, retractors, gouges, etc., the handles are made of vulcanized rubber, which is molten on to the steel, and does not therefore require to be riveted. This material is susceptible of a high polish, and is easily kept clean. All surfaces should be perfectly smooth and plain, even to the extent of omitting the stamp of the manufacturer. For amputations and ordinary operations on the soft parts and bones, the following articles are required :

For making flaps by transfixion, two *amputating-knives*. The largest of these (Fig. 47)* measures 17 inches over all, or 12 inches for the cutting blade, the width of which is five eighths of an inch. The rubber handle has a circumference of two and a half inches.

Fig. 48 represents a smaller knife of a similar pattern, the blade of which is only eight inches long by half an inch wide.

The *scalpels* are eight in number, the blades ranging from two and a half to three fourths of an inch in length.



FIG. 47.



FIG. 48.



FIG. 49.



FIG. 50.

The handles are large enough to be firmly held, and the end of each is shaped into a dry dissector (Figs. 49 and 50).

A probe-pointed and a sharp, *curved bistoury* (Figs.

* These cuts are made from the instruments in my general operating-case.

51 and 52), with blades of three and a half inches cutting edge, are invaluable instruments.

Two *lithotomy-knives* (Figs. 53 and 54), one probe-pointed, the other sharp, with blades of four inches cutting surface. The probe-pointed knife is for the lateral, the other for the median operation.

For the cutting part of the operation for cleft palate, three blades are needed. A *double-edged bistoury* for commencing the incision in trimming the

edge of the soft palate (Fig. 55), the cutting edge of which is five eighths of an inch long; a *curved probe-pointed bistoury* of one and a quarter



FIG. 55.



FIG. 56.



FIG. 57.

inch blade (Fig. 56), and a short blade turned at almost a right angle to the shaft ("*gum-lancet*") for dividing the mucous and periosteal tissues on the hard palate (Fig. 57).

For the subcutaneous section of tendons and fascia, a *probe-pointed tenotome*, the shaft and blade together measuring two inches, the cutting



FIG. 58.



FIG. 59.

edge of the blade three fourths of an inch long (Fig. 58), and a small *fascia-knife* (Fig. 59) for multiple division of the palmar or plantar fascia.

Retractors, or instruments for holding the edges and walls of wounds steady and out of the way, should have long shafts and handles, so that the hands of the assistants may not shut out the light, or otherwise interfere with the operator.

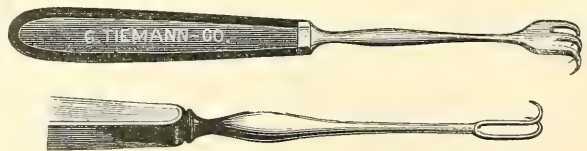


FIG. 60.

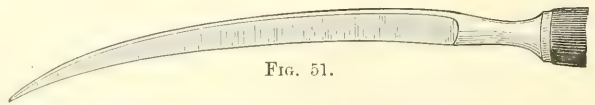


FIG. 51.

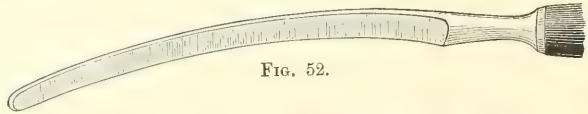


FIG. 52.



FIG. 53.—Little's lithotomy-knife.



FIG. 54.—Blizard's probe-pointed lithotomy-knife.

They should also have sharp or hooked claws for catching firm hold in tissues away from important vessels, organs, or nerves (Fig. 60), while others should be dull, and curved, or bent on the flat (Fig. 61).

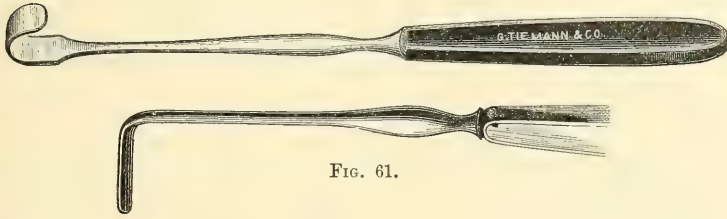


FIG. 61.

A *tenaculum* (Fig. 62) should be in every case.

The *aneurism-needle* (Fig. 63) will often serve a useful purpose as a retractor. The essential features of this important instrument are a capacious eye, a simple curve in one direction, and a dull point which can not be forced into the wall of a vessel.



FIG. 62.




FIG. 63.

The instruments for operations upon the bones are probably the most important in the surgeon's outfit. The list should include *saws, chisels, gouges, elevators, drills, forceps, an exsector, and a mallet and trephine.*

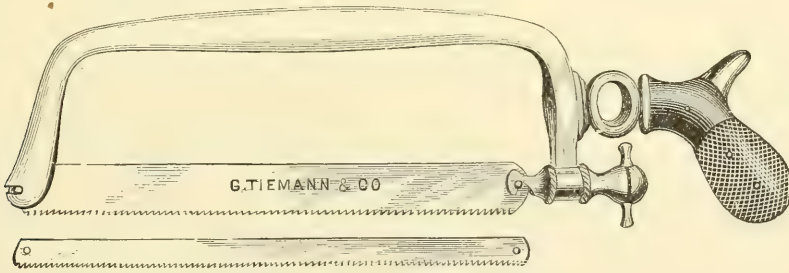


FIG. 64.—Bow-saw, with two blades.

Fig. 64 represents the most convenient *saw* for amputations and exsections of the knee- and elbow-joints. There are two blades, either of which may be adjusted at pleasure.

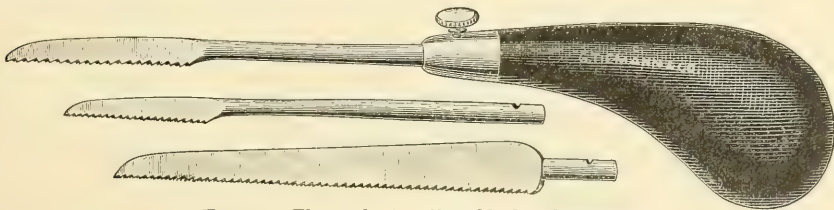


FIG. 65.—The author's adjustable key-hole saws.

For operations upon the bones of the face, as in exsection of the superior maxilla, or the osteoplastic operation for removal of the sphen-

palatine ganglion, etc., the adjustable key-hole saws (Fig. 65) are needed. There are three blades, which can be attached by a screw-catch to a single handle.

Chisels are of two kinds—those to be driven by a mallet or hammer, and hand-chisels, for cutting or gouging. They are straight-edged and curved. Fig. 66 is a half-size picture of Macewen's *osteotome*.




FIG. 66.




FIG. 67.

Two of these will be required, and should measure, respectively, one half and three eighths of an inch in width at the cutting edge. A convenient *hammer* for driving the chisel through is seen in Fig. 67.




FIG. 68.

Volkmann's *sharp spoons* or *scoops* (Fig. 68) are invaluable in certain operations.

The *scalloped gouges* (Fig. 69) are to be used with the hand without the mallet.

Sayre's *periosteal elevator* (Fig. 70) meets almost every requirement for lifting the periosteum, and is, besides, an excellent bone-elevator. For lifting the periosteum from the palate-bones, the three instruments of Goodwillie are very useful (Fig. 71).



FIG. 69.



FIG. 70.

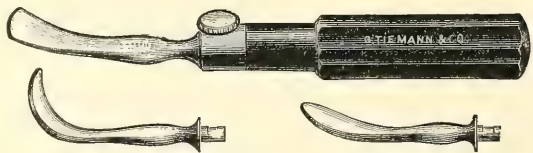


FIG. 71.

Bone-drills are not as often used now as in former years, yet they may be needed occasionally.

One or two are burred with as many plain-edged cutting drills (Fig. 72).

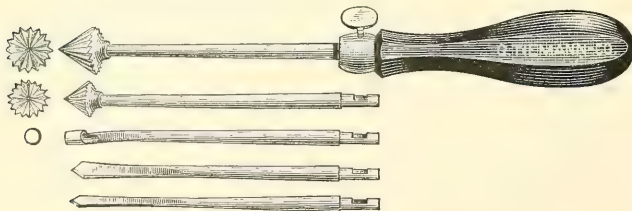


FIG. 72.

For purposes of economy in space, a single adjustable handle is arranged for all the drills.

Bone-forceps should be constructed for cutting, holding, and extracting uses.

Those that cut are of the two shapes shown in the accompanying illustrations (Figs. 73 and 74).

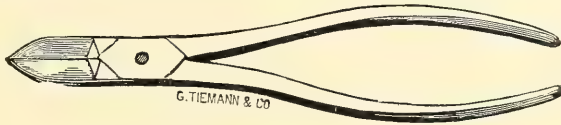


FIG. 73.

Hamilton's *sequestrum-forceps*, an excellent instrument, is shown in Fig. 75.

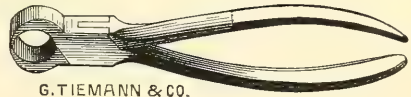


FIG. 74.

A *rongeur*, or *forceps-gouge*, is especially useful in operations upon the cranial bones, where any projecting angles may be gnawed off, the employment of a mallet and chisel being always contraindicated (Fig. 76).

Fig. 77 represents a strong *sequestrum-forceps*, and Fig. 78 the *lion-jawed forceps*, a necessary instrument for fixation.




FIG. 75.—Hamilton's sequestrum-forceps.




FIG. 76.



For exsections of the long bones, excepting the expansions of the femur and tibia, at the knee-joint, and in tarsotomy and other radical

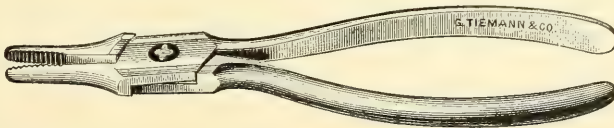


FIG. 77.—Improved sequestrum- and trepanning-forceps.

operations, which will be given in the text, the *exsector* (Fig. 79) is one of the most useful instruments known to this date. I have employed it

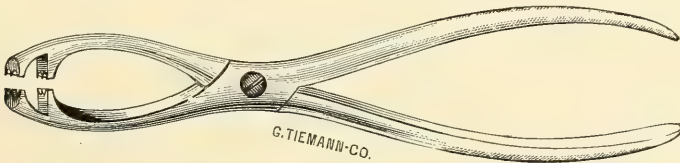


FIG. 78.

now in about all the exsections possible, and it has always met every requirement. Upon the very hardest bones, such as the inferior maxilla,

it is essential to have the saw well sharpened. The original instrument was modeled by Mr. Gowan, of London, but it was so complicated in its mechanism that I have had it extensively modified and at the same time simplified. As now manufactured, it consists of a four-jointed forceps, the jaws of which are at a right angle to the handles. At *h* is seen a shield which not only rotates, but is reversible and readily shifted to one or the other side. The saw, *t*, is chisel-shaped. The outer edge of the last tooth is dulled to prevent wounding the soft parts surrounding the

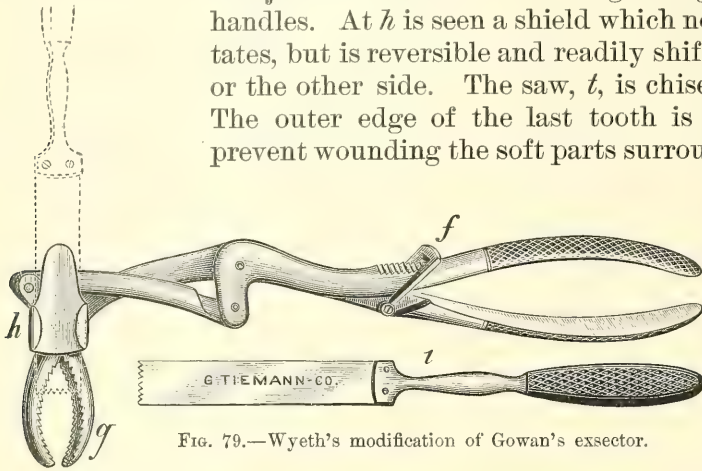


FIG. 79.—Wyeth's modification of Gowan's exsector.

bone. The handles are held closed by a clamp, *f*. After the periosteum has been lifted, separate the jaws to the required extent, and slip them on between the periosteum and bone until the latter is well in the grasp of the instrument. Close the handles sufficiently tight to hold the bone steady without crushing it, and lock them in the required position with the clamp. The saw is now slid into the flanges upon the shield until it rests upon the bone, when, by a short lateral sawing motion, it may be made to travel rapidly through the bone. A very little care will prevent the adjacent soft parts from being injured.

The best *trephine* for all purposes is that of Galt (Fig. 80), the burr of which is conical. A convenient size is one which measures five eighths of an inch in diameter at the cutting teeth, and gradually enlarges to



FIG. 80.

seven eighths of an inch in diameter at the base where the spiral teeth terminate. The mechanism of this instrument is such that, as soon as the resistance in front ceases, the side-teeth take hold so greedily that the further rotation of the trephine is difficult. The resistance is, however, not so great that it may not be overcome, and the teeth driven on into the dura mater and brain, yet it is sufficient to warn the operator that the section is complete.

For the prevention or arrest of hæmorrhage there are needed a *tourniquet*, *elastic ligatures*, various forms of *forceps*, and a wire *écraseur* or *clamp*.

Esmarch's *elastic bandage* (Fig. 81) has superseded all other tourniquets for operations upon the extremities. The rubber clamp usually sold with the bandage is useless. Each operating-case should be provided with two bandages of strong elastic material (I prefer plain white rubber) about two inches wide, and each bandage about four yards long. For simple constriction of a limb a good-sized rubber tube can not be surpassed.

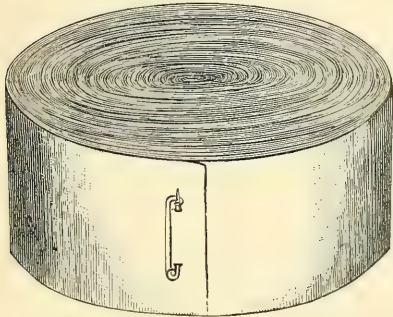


FIG. 81.

The *elastic ligature* is a solid cord of plain rubber about two feet long, and of different sizes, varying from one twelfth to one fifth of an inch in diameter.

Hæmostatic forceps should be of various shapes. The four varieties which I employ are illustrated in Fig. 82. A general operating-case should contain a total of at least sixteen forceps, and in the proportion of two fenestrated *mouse-tooth*, six broad, *solid-jawed*, four

slender-jawed, and four *scissor-clamps*; the first three have sliding catches, while the clamp has a spring-catch near the end of the handles. The mouse-tooth fenestrated forceps is for accurate adaptation to superficial vessels of small size, while the broad-jawed instrument is for grasping either large vessels or masses of bleeding tissue. The points should be club-shaped and perfectly smooth, so that when the ligature is tightened upon the instrument it will slide over its tip and on to the vessel. These pieces are five inches long and three eighths of an inch across the widest portions of the jaws. The sharp-pointed forceps are useful in picking up a vessel which has retracted or is deeply situated in a wound. The scissor-clamps may be used for applying the double ligatures in a dry dissection, or for temporary hæmostasis of smaller bleeding points which need to be compressed for a few minutes, and then remain permanently occluded.

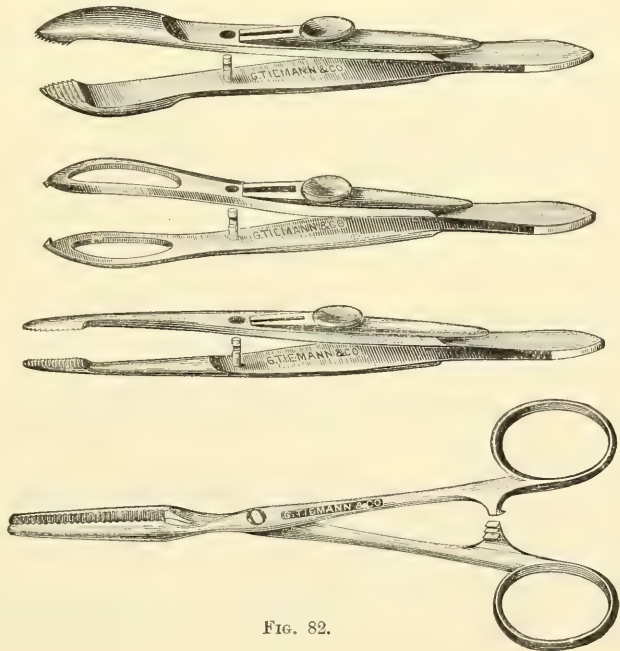


FIG. 82.

In operations in the various cavities, and in deep external wounds, as

well as for various purposes, to be given in detail hereafter, *sponge-holders*, similar to those represented in Fig. 83, can not be dispensed with. They should be solid in construction, 10 inches long, some straight and others curved.

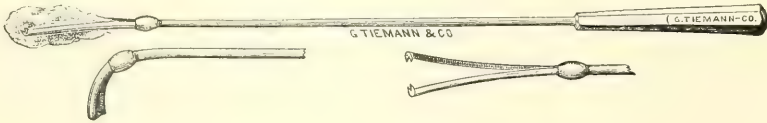


FIG. 83.

Every operating-case should also contain the following instruments:

At least five pairs of *scissors*—one pair 8 inches long, curved on the flat, with both points dull (Fig. 84); a similar instrument with sharp points; another 6 inches long, curved on the flat, with both points sharp, for removing sutures, etc. (Fig. 85); one straight *sharp-pointed* Sims's scissors, 8 inches long (Fig. 86); and a blunt-pointed, plain *dress-ing-scissors*, 6 inches long (Fig. 87). These should all be strong, with the exception of the small sharp-pointed pair, with the curve on the flat.

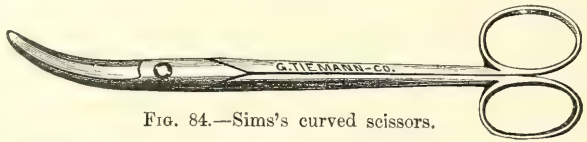


FIG. 84.—Sims's curved scissors.

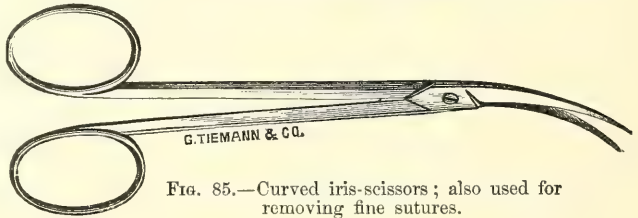


FIG. 85.—Curved iris-scissors; also used for removing fine sutures.

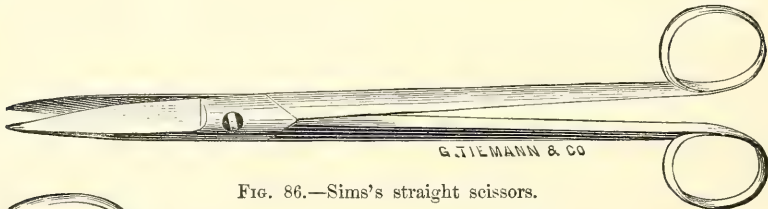


FIG. 86.—Sims's straight scissors.

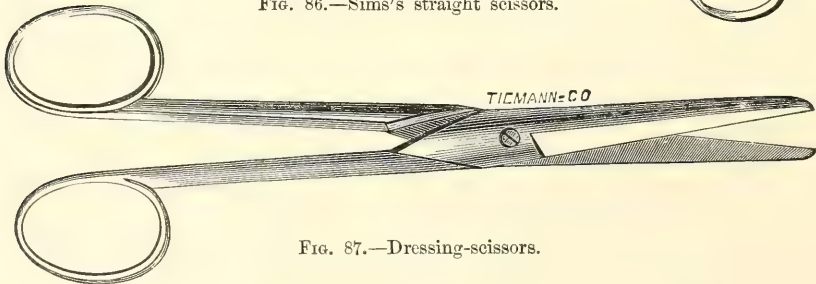


FIG. 87.—Dressing-scissors.

One sliding-catch *needle-holder*, the shape and mechanism of which are fully explained in Fig. 88. The point should have a plain and curved surface, for straight and curved needles (Figs. 89 to 93).

Two pairs of plain *anatomical forceps* (Fig. 94), fully 7 inches long, so



Fig. 88.—Wyeth's needle-holder.

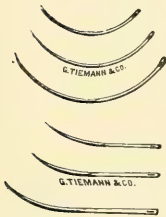


Fig. 89.—Assorted curved and half curved fine needles.

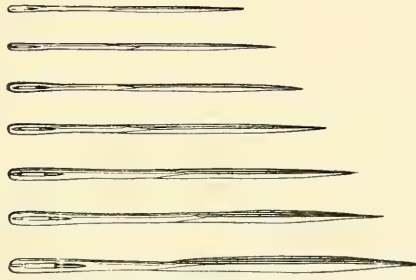


Fig. 92.—Wire suture-needles.

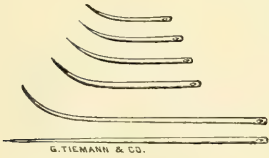


Fig. 90.—Emmett's needles, straight and half-curved.

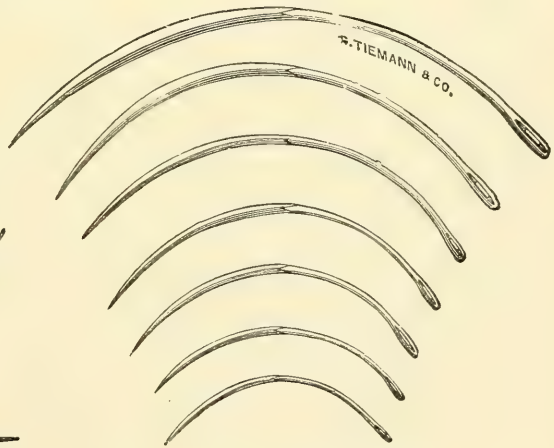


Fig. 93.—Full-curved suture-needles.

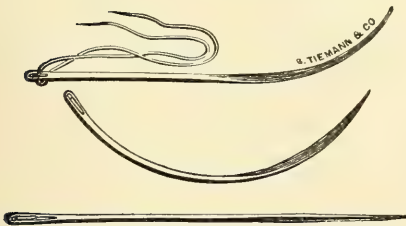


Fig. 91.—Straight and curved needles.

that the hand may be kept at a sufficient distance away from the wound; and one *mouse-tooth*, 8 inches long, with a sliding catch.

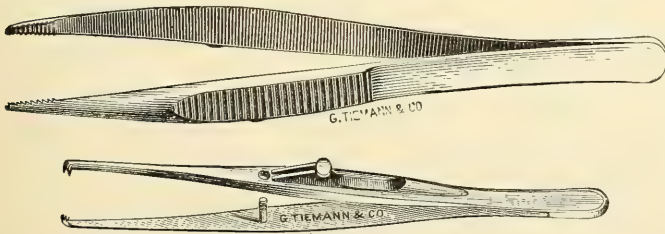


Fig. 94.



Fig. 95.—Nèlaton's bullet-probe, with porcelain head.

One Nèlaton's *porcelain-tipped bullet-probe* (Fig. 95), one *long silver probe*, with an eye at one end (Fig. 96), and one or two *galvanized copper probes*, from 10 to 12 inches long and from $\frac{1}{16}$ to $\frac{1}{8}$ inch in diameter (Fig. 97).

Two good-sized silver *grooved directors*, six to seven inches long and from one eighth to three sixteenths of an inch in width (Fig. 98).



FIG. 96.—Fluhrer's light flexible bulb-tipped probe.



FIG. 97.—Long silver probe.



FIG. 98.—Grooved director.

Other instruments will be given in the text, with the operations for which they are especially designed.

Place of Operation.—In the performance of a surgical operation, a clean room, good light, and a free supply of fresh air are of first importance. The supply of light, in order to be most effective, should fall upon the operating-table from points above the level of the patient. In the open air and in daylight, when protected from the direct rays of the sun, the best conditions for light and air prevail. Under shelter, a sky-light, or a tall, wide window, are preferable. At night, gas, lamps, candles, or torches, must often do the best service possible in an emergency. The Edison electric light, in which the incandescent carbon is held within an air-tight globe, furnishes the safest and most effective artificial light.

It is always desirable to control the temperature of an operating-room, and to keep it at a figure above that necessary, or even comfortable, to the operator and attendants. The patient's body is almost always in part exposed, and, in addition, is apt to be deprived of the normal body-heat by hæmorrhage and shock. Moreover, in the event of asphyxia, the rapid introduction of fresh air from the open windows may be imperative, and the temperature lowered to a dangerous degree, if the room is not provided with the proper means of heating.

The room in which an operation is to be performed should be large enough to hold all the necessary apparatus and furniture, and to allow the free and rapid movements of the attendants in the execution of orders. The floor should be of wood, tiles, asphalt, or marble, uncarpeted and clean; the walls and ceilings equally clean, and free from unnecessary drapery. In a dusty country the steam-spray (1 to 20 carbolic acid) should be used before and during an operation (see Fig. 4), and likewise in all conditions of exposure to infection, such as a room in or near which a contagious disease has once appeared, etc.

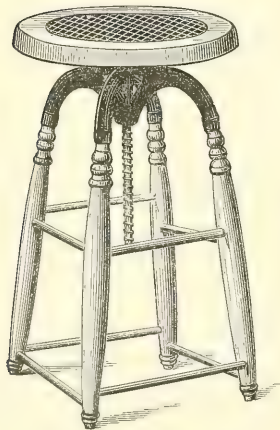


FIG. 99.—Adjustable stool.

The furniture required consists of an operating-table, at least two side-tables, or cabinets, for holding trays of instruments, sponges, dressings,

solutions, irrigators, etc. An adjustable stool (Fig. 99) for the surgeon should be among the accessories. An operating-table should be made of strong material, solidly put together, $6\frac{1}{2}$ feet long, 34 inches high, and 22 in width, padded with cotton, wool, hair, or felt, to the thickness of about one inch, and covered with some good water-proof material. In modern practice, with the free use of irrigating solutions, it is necessary to arrange the operating-table so that all fluids will be conducted into a vessel without wetting the patient beyond the field of operation. Dr.

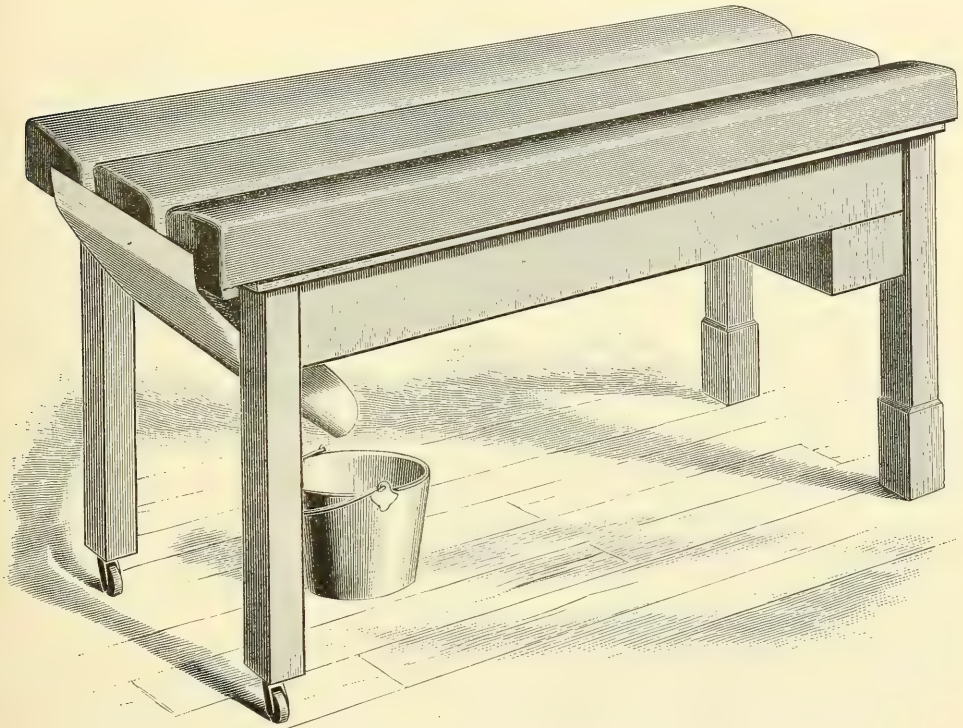


FIG. 100.—Ladinski's operating-table.

Ladinski's table (Fig. 100) fully answers these requirements. The surface of this excellent table is divided into a central padded ridge ten inches in width, and two lateral portions, each about seven inches wide, which slope sharply toward the two deep grooves or troughs, extending the entire length of the top. These grooves should be wide enough to permit of thorough cleansing. All the fluids used in irrigation flow from the field of operation into the troughs, and run off on the lower end through the tin gutter into a vessel beneath. In an emergency, a convenient covering for a table may be made as follows: Around two poles of a length equal to that of the table, and an inch or two in diameter, roll cotton-batting, or pieces of blanket, until the whole is about three inches in diameter. Two ordinary blankets rolled tightly will suffice. At intervals of a foot connect these side-bars by wisps of bandage-cloth long enough to hold the bars parallel with each other, and with the long edges of the table on which they rest. This skeleton, or

frame, is lashed securely to the table, and an oil-cloth laid over it (Fig. 101). If the head of the table is raised four or five inches on blocks, the patient rests in a kind of trough, along which the solutions are carried away from the parts of the body not to be irrigated.

When such a table is not convenient, one may be extemporized from an ordinary dining- or side-table, or two of these placed endwise. All household furniture so used should be thoroughly washed and scrubbed, and then covered with clean sheets. The side-tables for dressings should

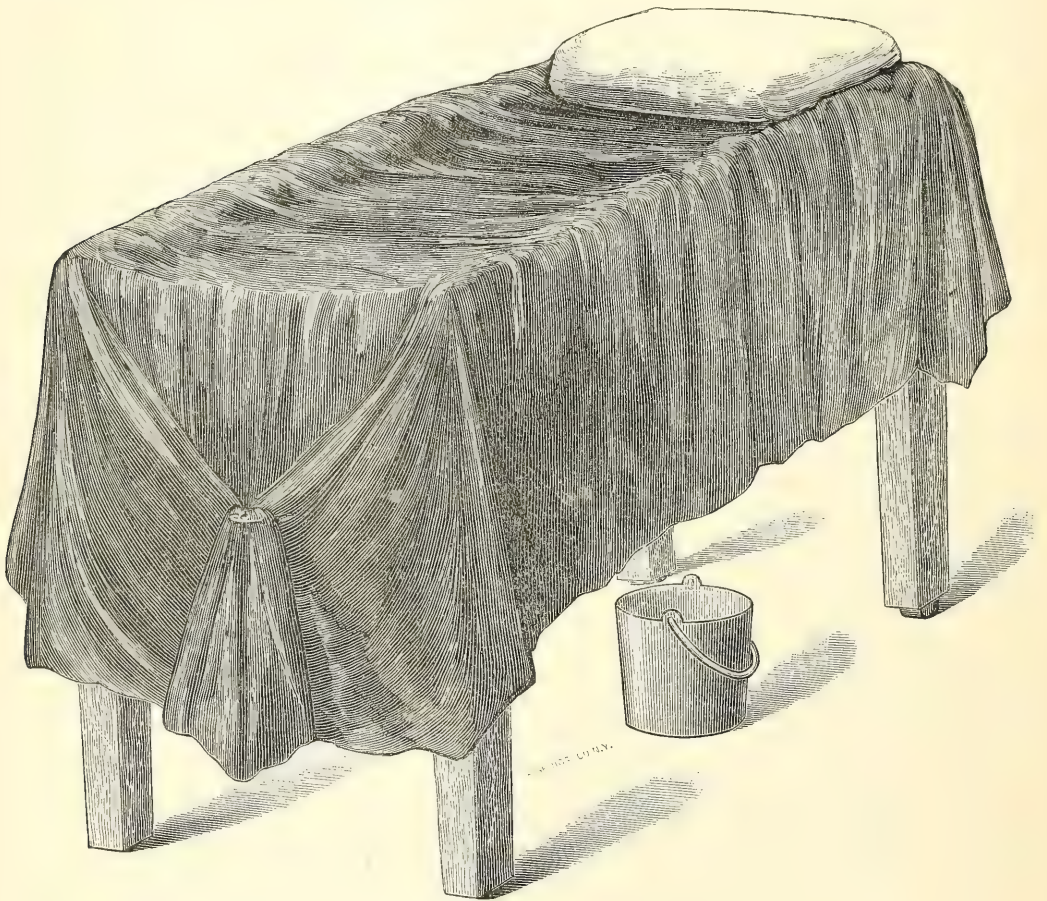


FIG. 101.

be also cleansed and covered with sheeting. It is always important to have plenty of room, so that the various articles and instruments may be arranged in the order in which they will be needed. A hard-wood cabinet (Fig. 102), about 3 by 2 feet (surface measurement), will serve an excellent purpose for holding trays of instruments, ligatures, etc., while the drawers supplied with materials in reserve may prove convenient at any stage of the operation.

The *trays* for holding instruments submerged in carbolic-acid solution should be made of porcelain or tin, not more than two inches deep, and of various lengths, to meet the requirements of the largest instruments.

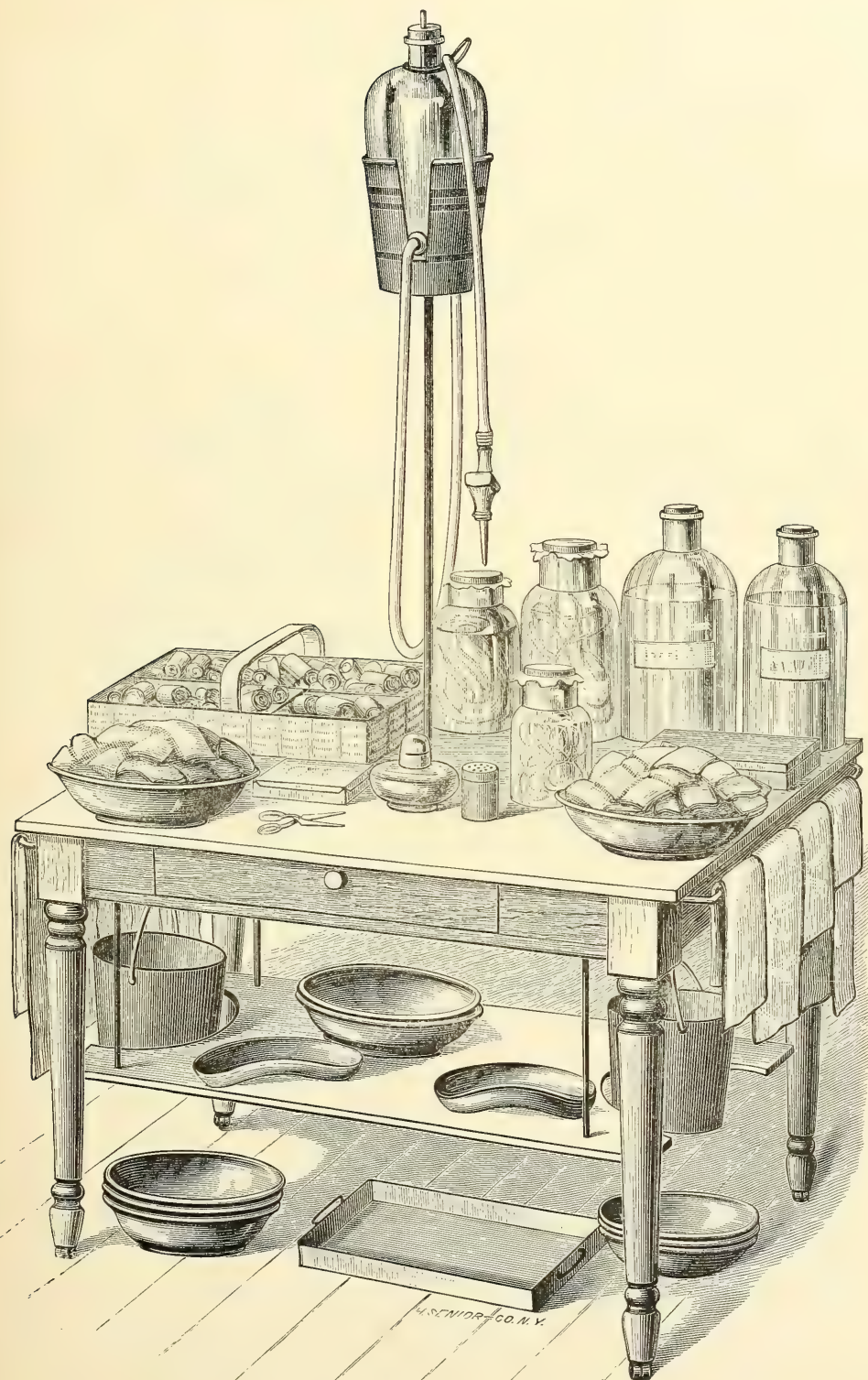


FIG. 102.

For purposes of convenience, the tin tray may be divided into compartments for the several outfits—one for the hæmostatic apparatus, another for knives, a third for bone instruments, and a fourth for odds and ends. Every basin so used, and each compartment, should have a turned corner like the mouth of a pitcher for readily emptying the solution when necessary (Figs. 103, 104, 105).

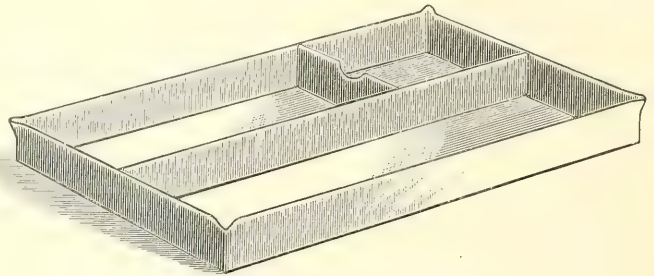


FIG. 103.—H. M. Sims's instrument-tray.




FIG. 104.

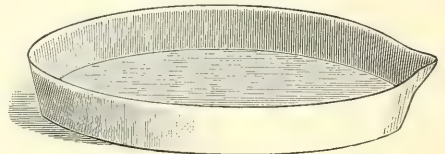


FIG. 105.

Pus-basins (Fig. 106) are very useful for receiving vomited matter or for catching pus, irrigating solutions, etc. Such vessels should be made of tin or brass, and not of hard rubber, for these are easily broken, and can not be repaired.




FIG. 106.

Larger vessels, such as bottles or pitchers, of glass or porcelain, or clean wood, should be filled with the various solutions to be used, and kept at a temperature between 100° and 110° F. As the operation is about to begin, the irrigator should be filled with sublimate (1 to 3,000), and the sponges placed in a warm solution of the same strength from which they are taken as required.

The dressings to be applied should be cut and laid in order, so that no delay may be experienced. Ligatures and sutures should also be cut beforehand and placed in appropriate receptacles, the catgut in oil of juniper, the silk or wire in 1 to 20 carbolic acid.

The preparation of a patient has a moral as well as a physical aspect. The surgeon and attendants should labor judiciously to dispel anxiety by assuring the patient of the safety of ether, and the freedom from pain which follows even the most extensive incisions. The question as to whether an unfavorable prognosis should be made known to the patient must be determined by the circumstances which prevail. The professional obligation is discharged when the nearest relations and friends are so informed. If the temperament of the individual is such that great depression would probably follow the knowledge of impending disaster, and thus add to the dangers of the case, it will be wise to advise the friends to withhold the information. The surroundings of all such pa-

tients should be as bright and cheerful as possible. Good light, food, and air, and kind attentions from friendly hands, add much to secure a successful issue.

The physical preparation may be general or special, and the time to be devoted to it must depend in great measure upon the nature of the disease or injury, and the condition of the individual. If a condition of marked sepsis prevails, delay is dangerous, for all efforts at nutrition will be more than offset by continued absorption of the poison. The same rule will apply in hæmorrhage not controllable by compression. In most instances, however, much good can be achieved by devoting several days, or even weeks, to increasing the nutrition of the tissues. Properly selected food and tonics, the regulation of the bowels, sound

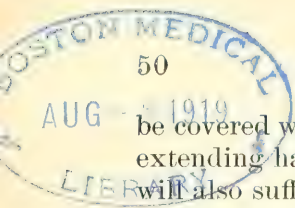
and refreshing sleep, and freedom from pain, are all essential. When the abdominal organs are to be exposed, especially in operations upon the alimentary canal and the removal of large tumors, solid food should be withheld for at least five days prior to the operation, and concentrated liquid nourishment, such as beef-juce and milk, taken in its stead. In addition to this, a laxative should be administered on the day before, and an enema on the morning of, the operation. Finally, just before the anæsthesia, the parts about the field of operation should be shaved and cleansed, provided that this is not painful to the patient. The other features of preparation have been given in the chapter on Anæsthesia.

The preparation of the surgeon and attendants is also of great importance, and is comprehended in the greatest possible *personal cleanliness*. No one should be admitted to the presence of the patient who has been in a room with a contagious disease within twenty-four hours, or who has not made a perfect change of clothing, and thoroughly washed all over. The nails should be closely trimmed and



FIG. 107.—Surgeon's water-proof operating-gown.

cleansed, the hands and arms washed with soap and water and brush, and afterward in 1 to 3,000 sublimate. The operator should wear a water-proof gown, long enough to reach to the feet. The arms should



be covered with sleeves of the same material, pinned at the shoulders and extending half-way between the elbow and wrist (Fig. 107). A linen coat will also suffice, but will not always protect the person from the irrigating solutions. The attendants should all be clad in clean gowns.

Everything being in readiness, and the patient anæsthetized, brought in, and placed upon the table, the following arrangement and assignment of duties should be made: The table must be so turned that the best light falls upon the field of operation. All parts of the body out of this field should be well wrapped up and protected from getting wet by blankets, and an oil-cloth over all. The parts within range of the operation, having previously been shaved and scrubbed with soap and water, are now washed with ether, and then with 1 to 3,000 sublimate. If the tourniquet is to be applied, say, to an extremity, towels dipped in warm sublimate, 1 to 3,000, are wrapped about the part, and the elastic bandage applied over these. When the bandage is removed up to the point where the limb is to remain constricted, this and all parts near the wound should be covered over with warm sublimate towels.

The assistants should be as follows: A trained etherizer, and a first assistant to sponge and immediately help the operator, who stands usually just opposite him. A second assistant, to stand conveniently to the instruments and the operator, whose duty it is to hand each instrument or article as called for with promptness, and as promptly to remove those which have been laid aside. A third assistant attends to the irrigation, regulating the supply at the indication of the chief. One supernumerary, for holding retractors, or performing any duty which may be required. A nurse to rinse the sponges and hand them to the first assistant. A second nurse to assist the etherizer. A supernumerary nurse for general usefulness.

When the knife (or other instrument) is lifted from the solution, the assistant, before handing it to the operator, shakes from it the few drops of fluid which adhere, for the acid irritates the skin and obscures to some extent the incision. Different methods of holding the scalpel in making an incision are represented in Figs. 108 and 109. Holding the handle between the thumb and middle finger, while the tip of the index-finger rests upon the back of

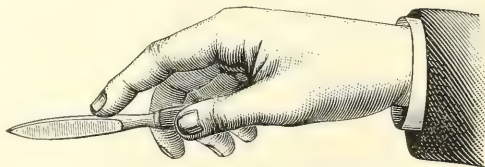


FIG. 108.

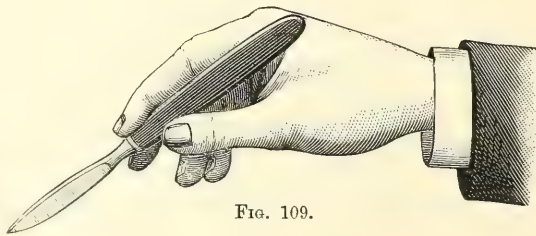


FIG. 109.

the blade, will be found most useful in cutting through the skin, and in rapid work in parts of the body away from the more important vessels and nerves, such as the removal of the breast. The advantages of this position are, that more of the cutting-edge is utilized, while the pressure

upon the blade carries it through the tougher tissues with less exertion. When, however, a careful dissection is required—as in clearing out the axillary space—the second method, similar to that in which a pen is held, is preferable. It is always necessary to stretch, and thus steady, the integument with the thumb and index of the other hand when an incision is made (Fig. 110).

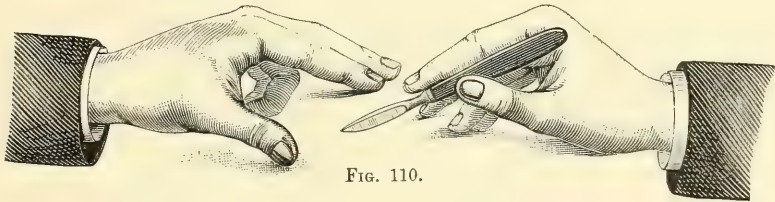


FIG. 110.

Irrigation may be continuous or interrupted, owing to the demands of each case. Operations in the joints, or near an ulcer, sinus, abscess, or any inflamed area, require exceptional precautions. In clean operations, such as an amputation in continuity, where no inflammation exists, or the removal of a benign tumor, etc., interrupted irrigation, or flushing the wound thoroughly every five minutes, will keep the wound aseptic.

In an operation which opens into any of the cavities the irrigator can not be used for fear that the solution may remain, and poisoning result from absorption of the corrosive sublimate. Asepsis must be here secured by mopping the surfaces of the wound with wet sponges. The stronger sublimate solutions can not be brought in contact with the eye without annoying inflammation resulting.

The methods of *hæmostasis* differ in different parts of the body, and under varying conditions. Thus, when amputating an extremity rendered bloodless by Esmarch's elastic bandage, or when the limb has been elevated and an ordinary tourniquet adjusted, the ligatures are not applied until the wound is completed and the bone divided. On the other hand, when operating without the tourniquet, it is essential that each bleeding point be secured as soon as possible; or that the vessels be tied with double ligatures and afterward divided between them. This excellent practice not only serves to prevent excessive loss of blood, but keeps the wound dry and clear, enabling the operator to make a more intelligent dissection. In order to be explicit in detail, take, for example, any major amputation by the bloodless method. The flaps having been made, the soft tissues are cut clearly through, and the bone divided with the saw. The stump is now thoroughly cleansed by irrigation, the cut surfaces dried off with sponges, and the ends of the vessels sought for in their known positions. In picking up the end of an artery or vein it is necessary to exclude all other tissues, and especially the nerves, from the grasp of the forceps and ligatures. To accomplish this, catch the vessel by one edge with a delicate-pointed forceps, draw it out from the wall of the wound, and from its sheath, and with a dull instrument, such as the point of a grooved director, strip the tissues backward from the artery until about one fourth of an inch of the tube is exposed. A large, round-pointed forceps (Fig. 82) may now be applied, and the liga-

ture tied over this. The ligature should be appropriate to the size of the vessel to be secured, as heretofore given. In making the knot, one of two methods may be selected, namely, the *single* knot, or the *double* or *friction* knot. The former is so well represented in Fig. 111 that it will not require description. A little practice will show the superiority of this over the *false* knot shown in Fig. 112, which is more apt to slip. In




Fig. 111.—Reef knot.




Fig. 112.—False knot.



Fig. 113.—Friction knot.

the *friction* or *double* knot (Fig. 113) the end of one side is passed twice under and over the other for the first loop, instead of once, as just given. When the ends of the ligature are drawn upon, and the vessel constricted, the first knot holds without danger of slipping until a second single knot is added to it. As to the application of one or the other of these loops, the single knot will suffice for all vessels which are freely exposed and superficial, where the surgeon can be assured that the first turn holds fast until the second has secured it. In deep wounds, where the knot must be run down with the finger-tips, as in the deligation of an artery in its continuity, the double knot should be preferred. After being tied, the ends are cut with the scissors about one quarter of an inch from the knot. As to how much force it is necessary or proper to exert in the application of a ligature to an artery it is impossible to say. This point will be fully discussed in the chapter on Surgery of the Arteries. It is always better to use too much than too little force, for one of the greatest possible annoyances to the operator is to be compelled to open a wound. When a vessel can not be otherwise found, its presence may be demonstrated by squeezing the flap and pressing out the small quantity of blood remaining in it. In this way all vessels of any size or consequence can be secured before the tourniquet is loosened. Before this is done the wound should be thoroughly irrigated, the flaps opened and filled with squeezed-out antiseptic sponges, the whole covered with warm sublimate towels, and compression made with the hands while the stump is elevated and the tourniquet loosened. After five or ten minutes the wound is opened and the sponges removed, one at a time. Any bleeding points which may have been overlooked will now be easily seen, and should be grasped with the forceps and tied. In applying the forceps to these points it is impossible to exclude the tissues immediately around the vessels from the grasp of the instrument and the ligature. When using the broad-shouldered forceps, if the catgut-thread is tied around the jaws of the instrument and the loop tightened, the thread slides along to the tip, and, in slipping off to constrict the bleeding vessel, pushes the other soft tissues to one side. In tying such a ligature care

must be taken not to pull upon one end with more force than the other, for by so doing the vessel is torn off ; and also to apply the force to the thread on a level with the tip of the forceps, for if this is not done the vessel is also pulled out of the wound and torn away.

When all hæmorrhage has ceased, except the slight oozing which may occur at any part of the wound, and always does come from the bone, the irrigation is repeated, and a drainage-tube (the bone-drains are preferable) inserted at each angle of the wound at a point where, with the part in the position in which it must rest during repair, the drainage of serum or other fluid will be free and uninterrupted. The flaps are adjusted by interrupted catgut sutures, and safety-pins placed in the ends of the tubes which project. The nozzle of the irrigator is now placed in the tube of one side and then the other, and the wound distended with 1 to 3,000 sublimate, which is then thoroughly pressed out and the dressing applied as follows :

A strip of sublimate gauze about two inches wide is button-holed, so as to fit over each of the tubes, and laid over the line of sutures, and on top of this several other pieces of the same size. The stump and thigh, up to the groin, is now enveloped in sublimate gauze in layers until the whole is about one inch thick. Over this a layer of absorbent cotton of the same thickness, and outside of this a sheet of protective which has been dipped in sublimate solution. The whole is held in position by bandages, which should be put on tight enough to hold the muscles quiet and arrest all oozing from the wound, and yet not press the flaps against the end of the bone, and thus cause sloughing. Such is the permanent antiseptic dressing, which remains unmolested unless pain or a rise in temperature indicates that, despite the precautions taken, inflammation and swelling or sepsis have occurred, or until the discharge from the wound has soaked through the dressings and has become offensive, having undergone decomposition beyond the zone of antiseptis.

The after-treatment of a patient who has undergone a major surgical operation will depend a good deal upon the character of the operation. The immediate care should be to maintain the vitality of the tissues, which has been endangered by the shock of the procedure and loss of blood, by judicious stimulation and relief from pain. A hypodermic injection of morphia guarantees relief from pain. If the pulse is weak, and the temperature low, an enema of whisky or the hypodermic administration of this agent will stimulate the heart, while hot applications will aid in the restoration of the normal temperature. One important point must not be lost sight of—namely, that after a surgical operation there is always a reaction, accompanied by increased heart-action and elevation of temperature, and that while stimulants are often necessary in the stage of depression, their administration should be guarded, so that they may not add to the fever of reaction.

As long as the effects of the anæsthesia last, a trained attendant should remain at the bedside to guard against the danger of asphyxia in case of vomiting, to restrain the patient from unnecessary movements, or it may be to guard against hæmorrhage.

CHAPTER V.

INFLAMMATION.

LITERALLY defined, inflammation means a preternatural heat. In surgery it is applied to a condition of animal tissues which are undergoing certain disturbances in nutrition which produce locally abnormal *hyperæmia, heat, redness, swelling, and pain*. Taken singly, none of these features of the inflammatory process can be said to express this morbid condition ; they must all be present.

It is well known that each of these conditions may exist without inflammation, and, indeed, some of them are present in purely physiological processes.

Thus, vascular tumors and the dilated capillary net-works of certain forms of *nævi*, though characterized by permanent hyperæmia and redness, are not inflammatory conditions. Blushing, which is associated as part of the expression of certain emotions, is accompanied with no other symptom of a morbid process than that of redness. The temperature of the blood in the hepatic vein in conditions strictly physiological has been registered as high as 107° F., and this extraordinary heat is not inflammatory.

Swelling is present in non-inflammatory processes, such as *œdema* and *emphysema*, while pain is not infrequent in certain neuroses, where all other symptoms of inflammation are absent. Whether the cause of inflammation be one of direct injury and irritation of a part, or whether it be due to lesions of the inhibitory nerves or trophic centers remote from the local expression of the morbid process, the pathological changes are practically the same. The activity and violence of the process will depend in part upon the character and extent of the injury, the presence of certain forms of micro-organisms or animal poisons, as well as upon the anatomical character of the part involved, together with the ability of the tissues to resist death, and to repair the damage inflicted.

The study of the phenomena of inflammation may, with propriety, be arranged in the following order: 1, irritation ; 2, contraction ; and 3, dilatation of the vessels ; 4, acceleration of the current and hyperæmia ; 5, retardation, partial or complete ; 6, redness ; 7, swelling ; 8, heat ; 9, pain ; 10, escape of vessel contents ; 11, general cell-proliferation ; 12, formation of pus ; 13, reorganization and repair ; 14, cicatrization.

It is known that when a vascular living animal tissue is subjected to irritation, the vessels in the zone of irritation undergo an instant con-

traction, and almost instantly thereafter become abnormally dilated. The cause of this contraction is supposed to be due to stimulus of the vaso-motor nerves, while the dilatation is explained as due to paralysis of the vessel-walls from injury to the inhibitory nerves, to changes in the walls proper, as the result of irritation, or to overstretching or rupture of the connective and elastic-tissue filaments which support the vessels from without. With these changes in the vessels which occur in such rapid succession, the blood-current is accelerated; hyperæmia ensues, and this, in turn, is followed by more or less complete blood-stasis. This last condition is most marked in the center of the inflamed zone, and when complete arrest occurs it is first seen here. At this stage leucocytes, in greatly increased proportion in the blood, appear in the venules and capillaries, to the walls of which they adhere, and through which they are seen to pass by active amœboid movement, until they wander free in the intervascular spaces (wandering or emigrant cells).

The bi-concave disks and *liquor sanguinis* also escape in the wake of the white corpuscles. It is held that the points of escape are in the intervals between the flat cells of which the vessel-walls are composed. In the area of complete stasis emigration does not occur.

Stasis is very probably due to a pathological change in the walls of the vessels, which in turn induces in the blood of the inflamed area certain changes whereby the "normal equilibrium existing between the blood and the containing vessels, which is physiologically essential to the integrity of the circulation, is impaired or lost." The presence of the white corpuscles should not be overlooked in seeking for an explanation of stasis, for paraglobulin, the coagulation factor of the blood, is the normal property of the leucocytes, and, as stated, they are present in increased numbers.

Redness, swelling, local increase of temperature and pain, occur with, and as a result of, inflammatory hyperæmia. The discoloration is due to hæmatin in increased quantity, not only within the vessels, but in the spaces between the capillaries. Tumefaction is due to increased blood-supply, to extravasation, dilatation of the lymph-channels, increase of lymph, and cell-proliferation. Abnormal heat is caused by increased cell activity and the abnormal condition of the blood within the inflamed area, while pain is due to pressure upon the end organs of the sensory nerves.

With the appearance of the leucocytes in increased numbers, and the escape of these into the intervascular spaces of the inflamed area, cell-proliferation occurs, resulting in the formation of a common embryonic tissue.

Examined microscopically, this embryonic tissue is seen to be composed of protoplasmic bodies or cells, spherical in shape, or slightly polygonal from reciprocal pressure, varying in size from about $\frac{1}{3500}$ to $\frac{1}{2500}$ of an inch, and often larger than this. They may be nucleated, but usually appear as slightly cloudy or granular protoplasmic bodies with no distinct nucleus or nucleolus.

Of the normal cells, which are most active in proliferation, and therefore chiefly involved in the formation of the new tissue, it is difficult in the present condition of pathological research to say. The followers of Cohnheim hold with him that the leucocyte is the chief factor in this

process. Others look to the connective-tissue cells as of equal importance with the leucocytes; while a third theory is that all cells of a part responding to the general stimulus of the inflammatory process undergo proliferation, and that the embryonic tissue is a common product.

From this it is probably a safe and wise deduction to consider that the chief rôle in the inflammatory process is played by the leucocytes; that they not only proliferate, but by their presence stimulate active nutritive changes and proliferation in the cells in general, and that the embryonic tissue is in truth a product of all these elements, varying in degree of fertility. This conclusion seems rational, since the normal rôle of every cell element of the body is one of proliferation and the formation of a new element to replace one which has finished its life-history; and it seems reasonable to infer that a more rapid proliferation of the same cells would occur under conditions of increased hyperæmia and nutrition.

The products of the inflammatory process may be organized into a permanent tissue, or, failing in this, may perish. With the tissues of the individual possessing the power to resist destruction the reparative process is rapid. Septic micro-organisms do not find conditions favorable to their development, and suppuration does not occur. The peculiar type of the new tissue is probably determined—(1) By the nature of the original cell from which it sprung. Thus the experiments of Goujon showed that the medullo-cells and myeloplaxes of bones in young animals, when injected into the muscular tissue, developed into bone even remote from the parent tissue. (2) By the location and function of the new tissue, as is shown in the development of exostoses from a common embryonic tissue near the insertion of tendon into bone.

When the inflammatory process is rapid and severe, the new tissue perishes suddenly, and with it occurs the rapid death or gangrene of the tissues involved. Under milder conditions the supply of nutrition may be more gradually diminished, and the embryonic cells undergo fatty degeneration and absorption. It is then said to have undergone resolution. Again, and not uncommonly, the cells of the new tissue, partly granular and partly unchanged, are found floating in a fluid, the *liquor puris*.

Symptoms.—In the milder forms of inflammation no symptoms may be observed beyond the local disturbance. In other and severer types the elevation of temperature is often well marked, and not infrequently preceded by or accompanied with a series of rigors, or a pronounced chill. This is especially apt to occur in erysipelas, dermatitis, and any form of phlegmon. The pulse is accelerated, the tongue is dry and coated, thirst, anorexia, and headache follow in the train of symptoms which are common in septic fever—the fever of inflammation.

Treatment.—The measures to be employed are local and general. The immediate indication is rest of the part inflamed. If one of the extremities is involved, an elevated position by means of a swinging cradle (Fig. 114), or upon a pillow, will, as a rule, give the greatest degree of comfort, especially in cases where, by reason of the swelling, the circulation in the

veins beyond the infiltrated portion is interfered with. In such conditions a flannel bandage, properly applied from the end of the extremity up to the inflamed area, will be advisable. If the swelling becomes so intense as to threaten gangrene, or even, by excessive tension of the part,

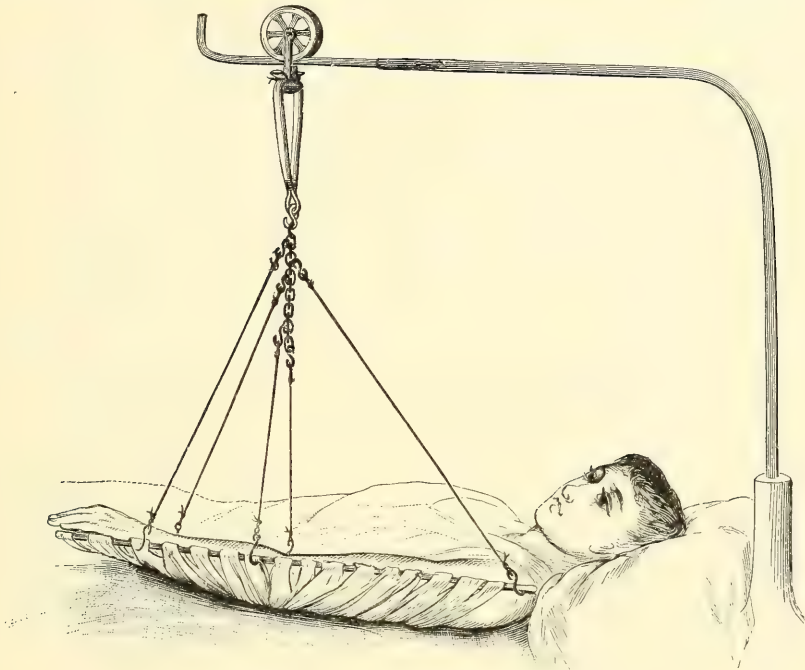


FIG. 114.—Fluhrer's swinging cradle (Mt. Sinai Hospital).

to give extreme pain, free incisions should be made parallel with the axis of the limb, extending well through to the deep fascia, and through this if necessary. These incisions, made so as not to divide the vessels, should be left open and treated with strict antisepsis.

Blood-letting, either by venesection or by leeches, or scarification and cupping, are to be employed in certain selected cases. In plethoric individuals, with high febrile movement and bounding pulse, venesection may be done with marked and immediate benefit. The operation should be performed in the median cephalic vein as follows (Fig. 115): Apply a bandage around the middle of the upper arm sufficiently tight to occlude the veins, but not to arrest the arterial circulation. Produce local anæsthesia at the point of incision by injecting from 5 to 10 minims of 4-percent cocaine beneath the skin in the line of the median cephalic vein (*not median basilic*). Ether spray, or salt and ice, may be employed if cocaine can not be obtained. Make an incision from a half-inch to one inch long, varying with the amount of subcutaneous fat, and directly over the vein until it is well exposed. With a curved pair of scissors now make a valvular slit about half through the vein. The amount of blood to be withdrawn will be determined by the impression made upon the radial pulse of the opposite arm, and in part by the sensation of the patient. From 8 to 16 ounces will usually suffice.

When ready to arrest the flow, place a pellet of absorbent cotton, moistened in 1 to 3,000 sublimate, over the wound, hold it firmly here, and then remove the ligature. A piece of sublimate gauze is now laid over the wound, and held in place by a moderately tight bandage.

If leeches are to be employed, from six to a dozen or more should be applied directly to the inflamed area. If a drop of blood is drawn out by the prick of a needle, or warm milk dropped on, they will take hold more readily. Once attached, they should be allowed to drop off of their own accord. If the oozing from the wound is too prolonged, it can be arrested by a sublimate compress.

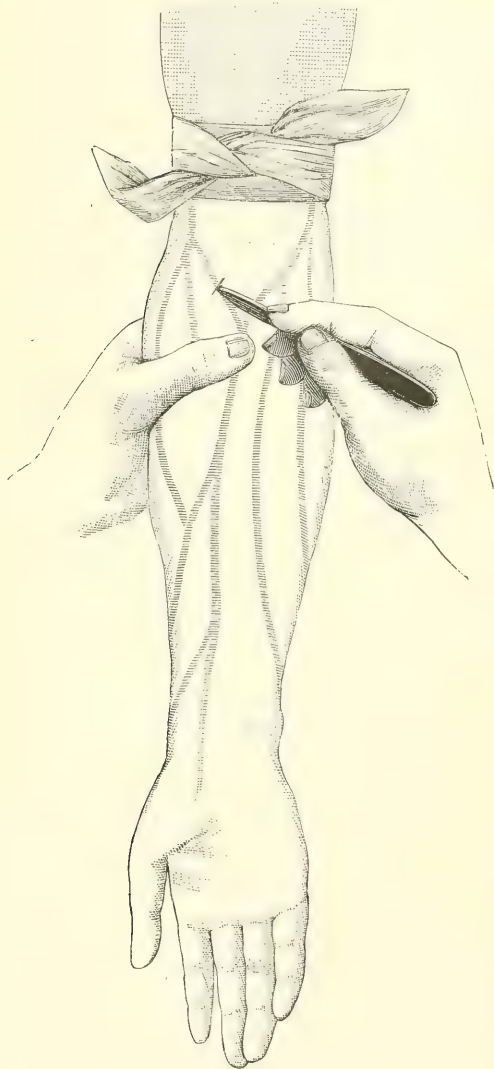


FIG. 115.—(Modified from Esmarch.)

inflamed at a point removed from the zone of inflammation, is impracticable and of doubtful benefit. The constriction of the artery without also partly occluding the vein is scarcely possible except by digital compression, or the use of the pole-compress, shown in the treatment of aneurism.

The local application of cold is of great benefit, and usually affords much comfort in the treatment of inflammation. One of the most useful and cleanly methods of applying it is to place crushed ice in the well-

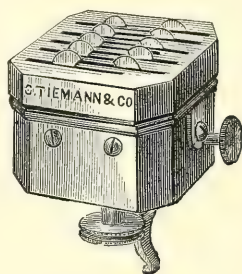


FIG. 116.—Ten-bladed scarificator.

Scarification is now rarely practiced, since freer incisions are to be preferred. When performed, it consists of making a series of small cuts into or through the inflamed integument by means of a number of lancets, driven by a spring with almost painless rapidity (Fig. 116).

Compression applied to the main artery, going to the part

known rubber ice-bag (Fig. 117). When these can not be obtained, the bladders and stomachs of animals, properly cleansed, can be substituted. Ice-water can be employed by means of an *irrigator*, with a stop-cock to regulate the flow, or by placing a pitcher or basin containing the water immediately above the part, and dipping into this a twist of soft cotton or linen cloth, allowing one end to hang directly over the inflamed area in such a position that the constant drip will fall upon it (see Fig. 7). Or a




FIG. 117.—(From Esmarch.)

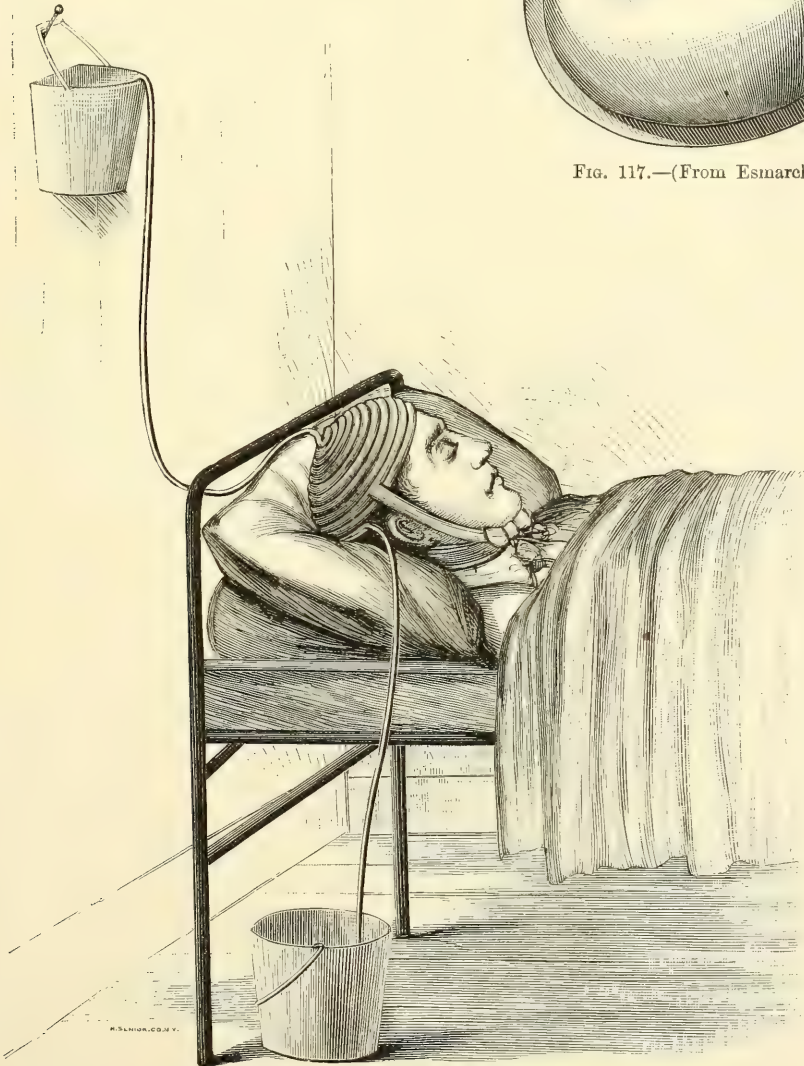


FIG. 118.—(Modified from Fischer.)

piece of tubing may be used as a siphon to the flow, regulated by a safety-pin clamp.

A coil of rubber tubing wound around or upon an inflamed surface, through which cold water is allowed to run continuously, is an effective method of applying cold (Fig. 118). This apparatus is objectionable in some instances on account of its weight. Submerging an inflamed extremity in a vessel of cold water may also be efficacious.

Heat may be applied by employing the same apparatus as for cold. The ice-bag may be filled with hot water, or hot irrigation used. Cloths rinsed in hot water and laid over the inflamed surface is one of the readiest and best methods of utilizing heat in the treatment of inflammation. Poultices of flaxseed-meal, or of bread, applied and kept moist and warm, are also useful local applications. A poultice used on a broken surface should be made with 1 to 10,000 sublimate solution.

In determining whether heat or cold will be used in any given case, the surgeon must be guided in part by the sensibility of the patient, for that which is most grateful to the part inflamed will usually produce the most satisfactory results.

Counter-irritants, such as blisters, sinapisms, or the cautery, are useful at times in the therapy of inflammation, especially in chronic processes in the joints and deeper tissues.

Internal Medication.—As far as the constitutional treatment of inflammation is concerned, each case will be a law unto itself. In the stronger and plethoric patients a saline or a calomel purge is indicated in the beginning of the process, and restricted diet should be insisted upon. For the more feeble class of cases, tonics, cod-liver oil, good air, and well-directed nourishment are essential. To counteract the high febrile movement and rapid pulse, antipyrine in doses of gr. x to xx, repeated in two hours, or antifebrine, gr. v to x, are excellent remedies. Aconite tincture, gtt. ij, and one drop additional every half-hour until the pulse falls, is also to be recommended. Quinia in doses of gr. x twice a day, or even oftener, in case of chills or rigors. Morphia, or one of the hypnotics, should be given when positively indicated by the patient's sufferings from pain or loss of sleep.

Suppuration—Micrococci—Bacilli—Bacteria—Septicæmia—Pyæmia—Traumatic Fever.—Inflammation without sepsis is, as just stated,

practically a physiological process. When, however, by *direct infection*—the wounded tissues being exposed to the air—or *indirect infection*, through imbibition, inspiration, or absorption from an abraded surface, these pathogenic micro-organisms enter the blood-current and find their way to the inflamed area, *suppuration* occurs.

The forms of organisms which are chiefly factors in this process are: (1) *Staphylococcus pyogenes aureus* (the

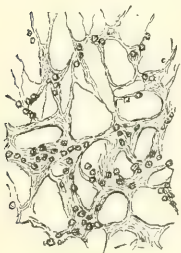


FIG. 119.
Staphylococcus pyogenes. (Pure culture.) (Modified from Landerer.)



FIG. 119 A.
Streptococcus pyogenes. (Pure culture.) (Modified from Landerer.)

pus-making, gold-colored, bunch [grape] coccus) (Fig. 119); (2) *Staphylococcus pyogenes albus* (or white coccus); (3) *Streptococcus pyogenes* (or chain coccus) (Fig. 119 A).

The white cocci are not so frequently met with as the gold-colored fungi. Under the microscope both of these varieties appear alike, and it is only in pure cultures that the yellow hue is observed, by which the *Staphylococcus pyogenes aureus* is recognized from the white variety.

In addition, in very foul pus and putrefying masses there is found a rod-shaped organism known as the *Bacillus saprogenes*, or bacterium of putrefaction (Fig. 119 B).

Whenever colonies of *Staphylococci* and *Streptococci* are established in the inflamed areas, liquefaction of the contiguous tissues takes place, the quantity of lymph and serum is augmented, and thus the *liquor puris* is supplied. In this fluid float the dead and dying leucocytes, embryonic cells, swarms of micro-organisms, and shreds of broken-down connective and other tissues.

By the rapid accumulation of pus, pressure upon and condensation of the surrounding tissues is greatly increased, and this, together with the rapid development of a peripheral embryonic tissue, forms the limiting membrane or *abscess-wall*. Not infrequently when the distention is rapid the vitality of the contiguous tissues is sacrificed by the occlusion of the outlying veins and arterioles. Coagulation in the veins (*thrombosis*) is of common occurrence.

Pus.—In its recent state, *pus* is a cream-like fluid, in specific gravity varying from 1.020 to 1.040, and at times higher. In closed cavities in the tissues it is usually alkaline in reaction, but when exposed to the atmosphere (and in some instances even within the tissues, where it is protected from the air) it becomes acid. Chemically it may contain paraglobulin, myosin, fatty acids, leucin, tyrosin, cholesterin, chloride of sodium, and phosphates. Healthy pus is odorless, but when decomposition has occurred the odor is often exceedingly offensive.

Examined microscopically, numerous corpuscles, varying in size from $\frac{1}{2000}$ to $\frac{1}{3500}$ of an inch, are seen floating in a transparent fluid—the *liquor puris*. These cells have no limiting membrane, contain one or several nuclei, and at times a number of fine granules, and can not be differentiated from the white blood-corpuscle or the common embryonic cell.

Another cell-like body found in pus, especially in older abscesses, or where a chronic inflammatory process has occurred, is the *granular cor-*

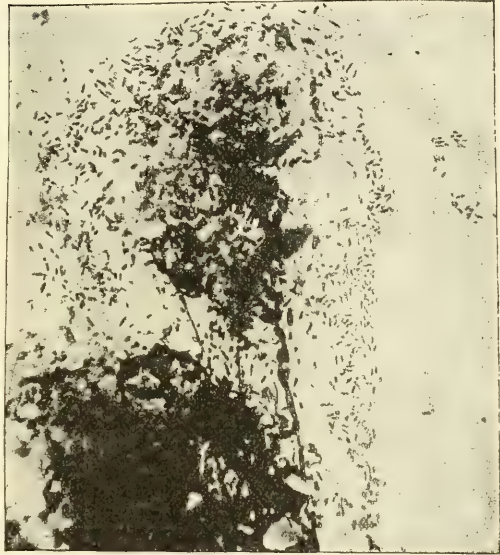


Fig. 119 B.—(After Koch.)

puscle, or, as it is more commonly called, the compound granular corpuscle. The pus-corpuscles proper are leucocytes and dead embryonic tissue-cells. The compound granular corpuscles are made up of an aggregation of granules, the detritus of leucocytes, embryonic tissue, or other

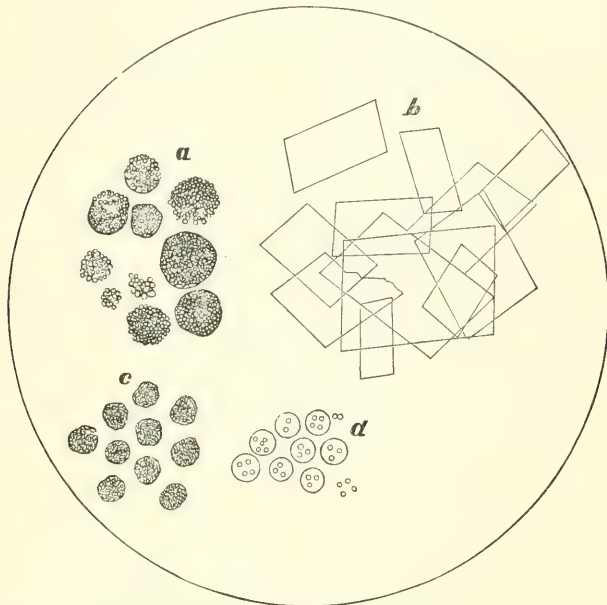


FIG. 120.—(Modified from Thomas.) *a*, Compound granular corpuscles. *b*, Crystals of cholesterol. *c*, Pus-cells. *d*, Same after addition of acetic acid.

cells, which have undergone fatty or granular metamorphosis. These adhere together in spherical or oval masses of all sizes, often as large as a dozen pus-cells together, or the granules may float free in the liquor puris. The differentiation of these elements is not difficult. Upon the addition of acetic acid the pus-corpuscles become swollen, and lose their granular, cloudy appearance, while their nuclei, otherwise scarcely recognizable, stand out in strong relief. Acetic acid does not affect the granular corpuscle, which, however, is soluble in ether. Pus-corpuscles proper are at times endowed with the amœboid movement. This is only true of the white blood-cell, which has not yet perished. The dead embryonic cells do not possess the power of motion.

These various elements of pus, as well as the cholesterol crystals, which are sometimes met with, are shown in Fig. 120.

Pus-corpuscles and the liquor puris from all acute abscesses, whether communicating with the atmosphere or not, contain also one or more of the micro-organisms above described (Figs. 120 A and 120 B). In rare instances pus loses its creamy-white color and assumes a bluish tint, due to the presence of a bacillus known as the “bacillus of blue pus.” This form of pus is not septic to a dangerous degree. All of these organisms usually disappear from abscesses of long standing—the *cold abscesses*.

The chief significance of these fungi—*Staph. pyo. aur.*, *Staph. pyo. alb.*, *Strepto. pyo.*—is that they give to pus a septic power, which pus free from these elements does not

cells, which have undergone fatty or granular metamorphosis. These adhere together in spherical or oval masses of all sizes, often as large as a dozen pus-cells together, or the granules may float free in the liquor puris. The differentiation of these elements is not difficult. Upon the addition of acetic acid the pus-corpuscles become swollen, and lose their granular, cloudy appearance, while their nuclei, otherwise scarcely recognizable, stand out in strong relief. Acetic

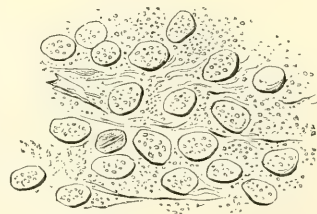


FIG. 120 A.—Pus from an acute abscess, showing pus-cells, shreds of broken-down connective tissue, and micrococci. (After Landerer.)

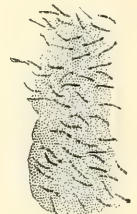

FIG. 120 B.—Bacilli of blue pus. (After Landerer.)

possess. As before stated, pus-corpuscles may disappear by granular metamorphosis, the liquor puris is carried off by the vessels, and in many abscesses of long standing nothing remains but a half-dried mass of cheesy-looking granular matter.

When pus collects in any part of the body in a recognizable quantity, such collection is called an *abscess*. If it is well defined, held in a given position by a limiting membrane or wall, it is a *circumscribed* abscess, and *diffuse* when it widely infiltrates the tissues. A rapid and recent collection of pus is called an *acute* abscess; a slow, chronic, and ancient collection, a *cold* abscess.

The limiting membrane or wall of a circumscribed abscess is a new formation of inflammatory origin, a granulation tissue, studded with capillary loops, as in the embryonic tissue of a wound undergoing repair (Fig. 121). It is in part a *pyogenic membrane*, since it furnishes the dead embryonic cells which float off into the abscess, while the leucocytes wander in from the capillary circulation.

A *diffuse abscess* results from the property which pus possesses under certain conditions of dissolving all connective and embryonic tissue, especially in those suffering from impaired nutrition. It thus meets with no barrier to its progress, and general infiltration of all the tissues of the part involved occurs.

A *chronic, subacute, or "cold abscess"* differs from the preceding in the slowness of its development, and usually in the absence of those symptoms of local and constitutional disturbance which characterize the acute formation of pus. They occur, as a rule, in diseases of bone and joints, and in individuals of low vitality. Cold abscess is not infrequent after caries of the spine and after adenitis of the axillary region.

Diagnosis.—The recognition of an acute abscess will depend upon certain symptoms of a local as well as a constitutional character. The sudden rise of temperature, preceded by a pronounced chill or a series of rigors, are symptoms of the formation of pus and beginning septic infection. The local signs are those of inflammation, which precedes as well as co-exists with the pus formation. Heat, pain, redness, and swelling are therefore among the earlier symptoms. Fluctuation is also present in well-advanced cases. The integument and subcutaneous tissues about an abscess are often œdematous and doughy, becoming pale, and pitting under the




FIG. 121.—(After Agnew.)



FIG. 122.—Exploring-needle and syringe.

finger. The positive test as to the presence of pus in quantity is *aspiration*. For this purpose the hypodermic syringe, with an extra large and long needle (Fig. 122), is invaluable. The following precautions should be practiced: The entire instrument should be thoroughly cleansed and

submerged in a 5-per-cent carbolic-acid solution. The skin at the point to be punctured should be washed with sublimate solution and ether, and the needle pushed in so as not to wound any vessels or nerves. If it has entered the cavity, upon withdrawing the piston the pus will escape into the chamber. The fluid, if any doubt exist, should then be placed under the microscope. As the needle is withdrawn, the wound should be covered with sublimate gauze, held in place with a roller or adhesive strip.

In cold abscess the inflammatory and septic phenomena are absent, and fluctuation may or may not be appreciable. Aspiration will determine the character of the swelling.

Treatment.—When an acute abscess, either circumscribed or diffuse, exists, it should be freely evacuated, and the sooner the better. When the abscess is situated in a portion of the body where there are no important vessels or organs in danger of being wounded, a sharp-pointed, curved bistoury should be carried through the wall, and the cavity opened by cutting outward. These minor operations may be done with cocaine anæsthesia. In the neck or other vascular regions, or where an abscess complicates a hernia or other important viscus, a careful dissection should be made from without inward. The point of greatest importance is to have the opening or openings in such a position that the drainage will be from the most dependent portion of the cavity. In cutting down upon an abscess it is often necessary to insert a small-sized aspirator-needle and determine the exact distance to the pus. The needle should be left in place as a guide. In some of these cases, in order to avoid hæmorrhage, a very good use may be made of the ordinary dressing-forceps, by closing the jaws of the instrument and pushing it through the tissues into the pus, and then stretching the puncture thus made by forcibly separating the handles.

As soon as an abscess is opened the nozzle of the irrigator should be introduced, and the cavity well washed out with sublimate (1 to 3,000). After this rubber drains should be inserted, and a thick dressing of sublimate gauze applied.

When an abscess occurs in parts of the body where it is desirable to avoid leaving a scar, as the neck or face, and where the symptoms of sepsis are not marked, a cure may be effected by means of the aspirator. For this operation the instrument represented in Fig. 123 is preferable.

It consists of a syringe, with a glass cylinder, armed with a double tip, a stop-cock, and two adjustable rubber tubes—to one of which the needle is tightly screwed. When about to be used, the apparatus should be thoroughly cleansed in 1 to 20 carbolic-acid solution, and, if the needle has been used in any suspicious matter, it should be heated to a red heat over a spirit-lamp, and cooled off in 1 to 20 carbolic-acid solution. The method of hyper-distention of an abscess with an antiseptic fluid was first prominently brought before the profession by Mr. Callender. The cylinder should be filled with the solution, and then, while holding the needle upward so that any air which may have entered by accident will escape first, the contents should be forced out until only about one third of the

cylinder is full. By this manœuvre the needle and tube are also filled with the solution, and the former is thrust into the cavity of the abscess and held steady by an assistant. The operator now withdraws the piston slowly, so as to give the contents sufficient time to fill the tube, which

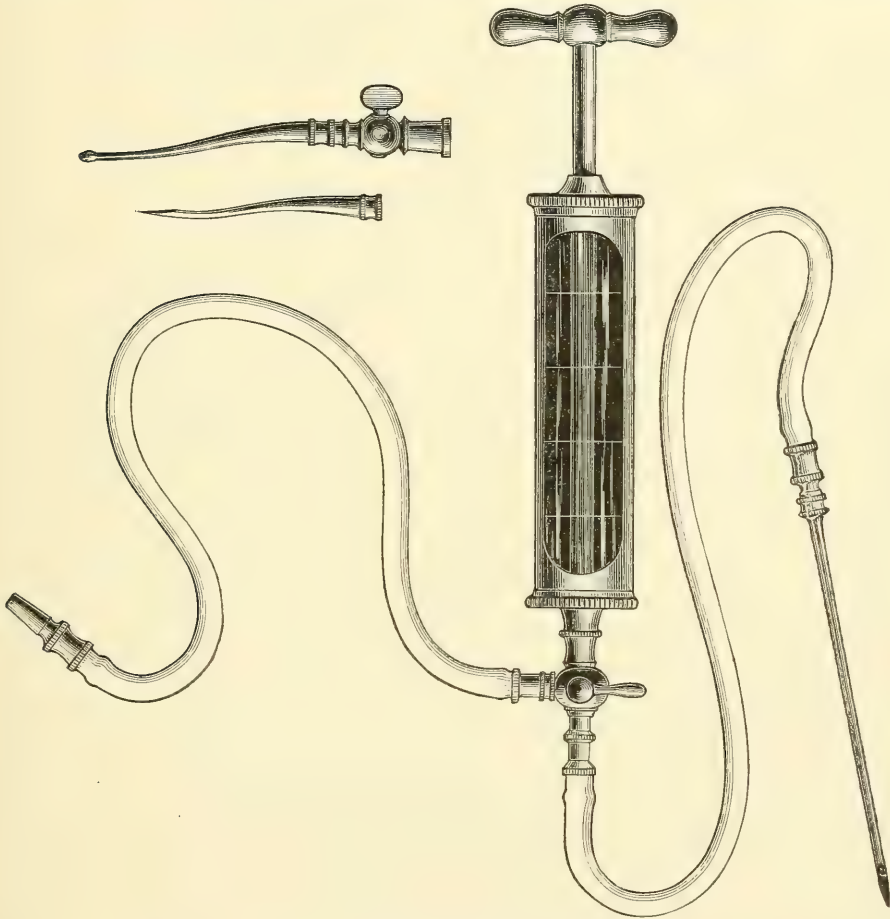


FIG. 123.—Combined aspirator and irrigator.

otherwise would collapse from atmospheric pressure. As soon as the cylinder is full the stop-cock is turned, so as to open the emptying tube, which motion also closes the one communicating with the abscess. The contents of the cylinder should now be emptied, and the evacuation continued until the pus ceases to flow. The syringe should now be filled with the 1 to 20 carbolic-acid solution, and the abscess injected until its walls are over-distended, when the fluid is withdrawn. This irrigation and hyper-distention may be repeated several times, until the fluid runs out clear. The needle is then removed, a plug of sublimate gauze placed over the puncture, a sublimate gauze, cotton, and protective dressing over this, and a bandage applied over all tight enough to compress the opposite walls of the abscess firmly together.

In aspiration of an abscess it is usually best to employ the large-sized

needle, for thick pus escapes with great difficulty through the small points. It is not infrequently necessary, even when a large needle is used, to dilute the contents of the sac by forcing in a quantity of the liquid before it can be brought out by the exhaustion. Some operators prefer to use sublimate (1 to 3,000) rather than carbolic acid. When mercury is employed, great care should be observed in thoroughly evacuating the sac before applying the dressing, for fear of poisoning by absorption. One operation is often sufficient to effect a cure by this method, and when carefully done to the exclusion of air, and with the thorough cleansing of the abscess, constitutional disturbance is rare. A second, and even a third, injection and irrigation may be tried. Should inflammation and sepsis follow, free incision should be practiced and thorough drainage established.

Cold Abscess.—Old abscesses which produce no deformity or marked discomfort to the patient may be left alone. If at any time symptoms of inflammation and sepsis supervene, prompt and free incision and irrigation should be done, and drainage maintained. When, by reason of its situation, it becomes advisable to operate upon a non-inflamed cold abscess, aspiration and irrigation should be performed in the same manner as above laid down.

Septicæmia (*σῆψις*, putrefaction; *αἷμα*, blood), or blood-poison, is caused by the presence in the blood and lymph-channels of certain derivatives of putrefactive changes, now known as *ptomaines*, and it is held that the presence of micro-organisms is essential to the production of these ptomaines, and their entrance into the blood is facilitated by the growth and migration of these organisms.

Pyæmia (*πύον*, pus) is a severe and usually fatal form of blood-poison, characterized by the formation of abscesses in various parts of the body, more or less remote from the center of suppuration and infection. Since these abscesses are caused by aggregations of micro-organisms, carried to the heart and thence disseminated, they are called *metastatic abscesses*. Pyæmia is therefore properly named "septicæmia with metastases."

Septicæmia following inflammation occurs in this manner. With the emigration of leucocytes and effusion of serum and lymph, the micro-organisms of suppuration appear in the inflamed area, and, rapidly multiplying, establish colonies in the connective-tissue spaces (Fig. 119). The tissues immediately adjacent to the colonies at once show signs of liquefaction, and the quantity of serum and lymph is notably increased. The various foci of liquefaction soon coalesce as the connective-tissue septa disappear, until there exists a single collection of fluid, the *liquor puris*, in which float living and dead leucocytes, dead embryonic cells, shreds of broken-down tissues, and shoals of micro-organisms are found.

As the quantity of pus is augmented, pressure upon the surrounding structures is increased. If the abscess be superficial the superjacent structures are protruded, often œdematous, and fluctuation may be recognized. At the periphery of the abscess myriads of cocci attack the bulwark of embryonic tissue (*abscess-wall*) in which the leucocytes are crowded. If the tissues are well nourished, and thus able to offer the

proper degree of resistance, the invasion of germs is arrested and the micro-organisms perish from starvation, or, as advanced by Metschnikoff, are eaten by the leucocytes and connective-tissue corpuscles (embryonic cells). That these elements act as *phagocytes* (eating-cells) requires further demonstration; that they are active agents in resisting septic invasion seems now demonstrated.

Weigert has compared the cells which form the shell around a suppurating area to an army resisting invasion, the sepsis-making micro-organisms the invading host, the abscess the battle-field, strewn with dead and dying of both combatants.

Under less favorable conditions the process of invasion is rapid, and at times overwhelming. Compression of the circumjacent tissues causes occlusion of the vessels (thrombosis) and sloughing. Cocci invade the lymph-channels and capillaries, and form colonies in the vein-clots. Liquefaction occurring in the *thrombi*, particles are drawn into the circulation, pass to the heart, and are distributed into the lungs. If the septic inflammation is in the area of the portal system the liver is usually first affected. Wherever the septic emboli lodge, secondary abscesses occur, germs pass through into the capillaries and venules of the lungs (or in the liver, the lobular and sub-lobular vessels), and general metastases may then occur.

It is exceedingly probable that septicæmia with metastases (pyæmia) takes place from infected thrombi. In the capillaries the colonies of cocci in mass can not be transported. They do invade and proliferate in the larger lymph vessels, but rapid general infection is here retarded by the sieve-like formation of the glands. Every clinician knows that these terrible onslaughts of pyæmia are, as a rule, sudden and overwhelming.

Again, in Mr. Bryant's analysis of 203 cases of pyæmia at Guy's Hospital, the lungs were involved in 187 instances, and in 78 of these, infarctions occurred in no other organs. Another fact not without weight in support of this argument is that, in suppuration in bone, metastatic septicæmia is more apt to occur than in the softer tissues. Here the resistance to expansion is so great that infiltration follows the Haversian canals, coagulation in the veins (thrombosis) takes place, invasions of micrococci occur, and septic particles pass off into the blood-current.

As above stated, the life-history of these organisms is short. For dangerous proliferation they require tissues of low vitality which are breaking down. Resisted properly, they perish and disappear. In cold abscesses they are not found.

Treatment.—The removal of the source of infection is the first and chief indication in treatment. Incision, drainage, antiseptic irrigation, are all-important factors in arresting sepsis. Reduction of temperature by antifebrine, gr. v, or antipyrine, gr. x-xv, every hour until the thermometer registers 101° F., or less, is as important as stimulation and careful nourishment.

CHAPTER VI.

WOUNDS.

A **WOUND** is a sudden solution of continuity in one or more of the tissues of the body. By common consent, such lesions in bone and cartilage are called *fractures*.

Wounds are *operative* and *accidental*, and may be classified under four leading heads, namely, *incised*, *punctured*, *lacerated*, and *contused*. Any breach of continuity may become inoculated with a virus, or venom; it is then a *poisoned* wound.

Perforating injuries, caused by missiles projected from guns, demand especial consideration as *gunshot* wounds. An *incised* wound is made by a clean cut with a sharp instrument. A *punctured* wound is caused by a narrow instrument which penetrates but does not cut laterally. A *lacerated* wound is made by a dull instrument which tears the tissues. A *contused* wound is one in which the tissues are more bruised than separated.

The changes which occur in the tissues during the infliction of a wound, and in the process of repair, are as follows: Take, as an example, an incised wound across the anterior aspect of the middle of the thigh.

As the section is made, the capillaries, arterioles, and venules within the field of irritation instantly contract, and immediately thereafter become dilated. With the impingement of the knife the tissues retract, and hæmorrhage occurs. The wound fills with blood, and, if no large vessels are divided, the bleeding may cease spontaneously by coagulation. The chief factor in rapid coagulation after a wound is the presence, in increased quantity, of the white corpuscles, which increase, as before stated, always takes place within the irritated zone. Under the abnormal conditions present, coagulation results from a combination of the paraglobulin of the leucocytes with the fibrinogen of the plasma. This process not only occurs in the blood extravasated, but extends along the capillaries back from the edge of the wound to the nearest anastomosis.

Immediately following these changes, hyperæmia, redness, swelling, heat, and pain occur in the edges of the wound, and general cell-proliferation ensues, as described in the preceding chapter on Inflammation. No repair of tissue is possible without this inflammatory process. It may be mild in degree, yet it must of necessity exist. A reunion of atom to atom, capillary to capillary, and a resumption of function without cell-proliferation, can not occur.

If the edges of the wound have not been approximated, the space left by the separation of the tissues begins to be filled in a few days with embryonic or granulation tissue. The same process of cell-proliferation occurs in the walls of the wound, and extends as far back as the zone of inflammation. The most essential feature of the earlier process of repair is the new formation of capillaries, upon which the integrity of the more advanced embryonic cells depends.

It has been stated that not only the white blood-cells, but all the stable cells of a part involved in an inflammatory process, take a more or less active part in the general proliferation which results in the formation of the common embryonic tissue. The cells of the capillary-walls are among the first to take part in this general proliferation. The new tissue projects in minute tufts or granulation buds from the sides and bottom of the wound. In this tissue the line of capillaries is advancing; but in general the supply of nutrition is not sufficient to maintain the vitality of the more advanced or superficial layers of cells, and these may perish by a process of granular degeneration, or, if more suddenly deprived of the necessary quantity of blood, by gangrene, more or less limited. The dead tissue floats off in the *liquor puris*, provided that the wound is infected and therefore suppurating.

The new formation of capillaries in the embryonic tissue of a wound undergoing repair may occur in any of the following ways: 1. From the nearest capillary arch or loop, one or more vascular buds are projected into the embryonic mass, as shown in Fig. 124. The contact

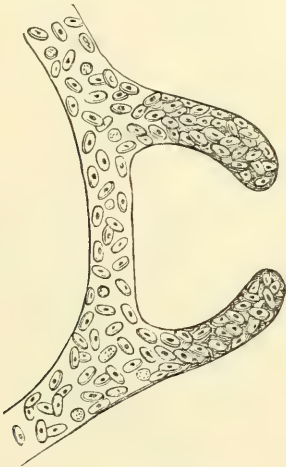


FIG. 124.—(After Paget.)

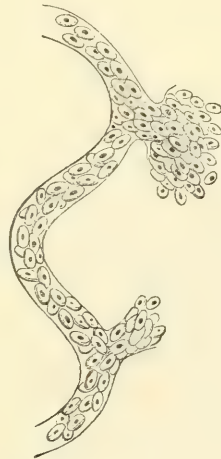

FIG. 125.—(After Paget.)

and fusion of these buds form new loops, which process continues until, as the process of repair nears completion, the arches from one side meet and fuse with those advancing from the other, and thus establish direct communication across the track of the wound. 2. It is also probable that some new capillaries are formed by canalization of anastomosing cells, a process analogous to the formation of vascular channels in the normal embryonic tissue, especially in those parts where the anastomosing plasmatic cells are found. 3. It is claimed by Ranvier that there are

developed special cells for vascular new formation, which he has called "vessel-forming cells." 4. By escape of leucocytes from the capillaries, these emigrant cells invade the new tissue, passing between the cells of the embryonic protoplasm. In their wake the red corpuscles and liquor sanguinis follow, and, by pressure upon the circumjacent embryonic cells, these become the investing membrane, and develop into the capillary-wall (Fig. 125).

With the establishment of a capillary system in the granulation tissue of a wound the process of contraction or cicatrization follows. As before stated, some of the embryonic cells undergo fatty degeneration and are absorbed, or die and are washed away in the fluid which exudes from the surfaces of the wound.

Other cells develop into connective-tissue elements, and form the contracting or cicatricial tissue of a wound. As shown in Fig. 126, the first

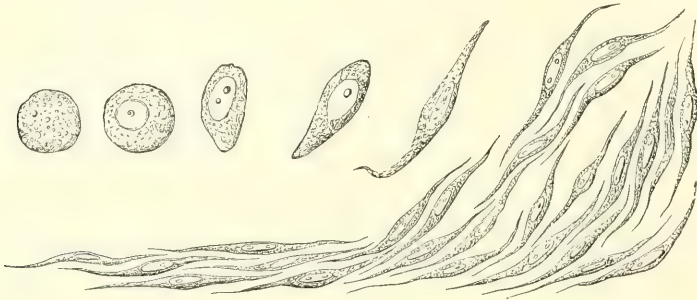


FIG. 126.—(After Paget.)

change is in the nucleus, which is more readily defined, assumes an oval shape, and shows within it one or more nucleoli. The cells become granular and more fusiform, finally changing into a series of wavy bundles of connective tissue (Paget). This process of attenuation or contraction is of course accompanied by obliteration of many of the new-formed capillaries, and a more than normal bleaching of the cicatrix, as is frequently observed in scars upon the integument, where, although the epithelium is reproduced, the hair and sebaceous follicles are not found.

In the process of repair in some wounds, especially in those which are slight and are subcutaneous, or are thoroughly cleansed and their walls brought and held in apposition by well-sustained pressure, reunion may be secured without pus-formation, with great rapidity, and without any constitutional disturbance. Cell-proliferation under such favorable conditions is limited, the process practically physiological, and, while many of the leucocytes and embryonic cells may die, the mode of death is by granular metamorphosis, with absorption of the granular matter. Finally, all wounds heal by one process of repair, and that involves *inflammation* and *cell-proliferation*. It may differ in degree of intensity as the injury is more or less severe, or as the tissues implicated are in a condition to resist disease.

Treatment.—The arrest of hæmorrhage is the first indication. Incised wounds bleed most freely, and are more dangerous in this particular than

lacerated and contused wounds. In one the vessels are smoothly severed, in the other the ends are torn in shreds. In the larger vessels retraction of the media and intima occurs, and coagulation is more readily effected.

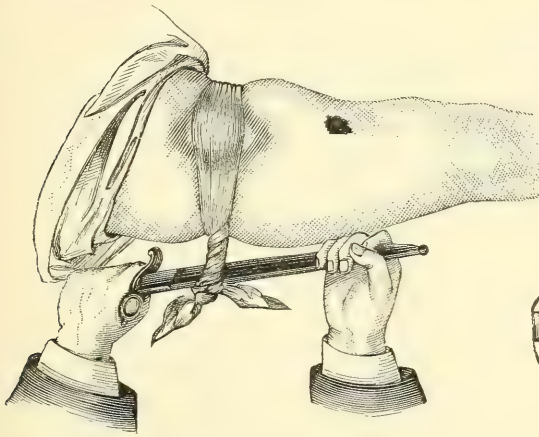


FIG. 127.—(After Esmarch.)

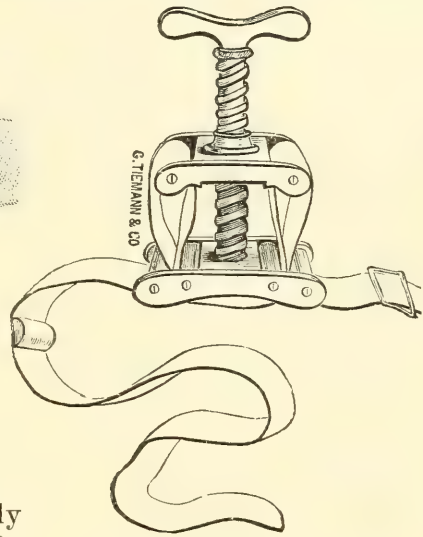


FIG. 128.—Petit's spiral tourniquet.

Punctured wounds do not bleed seriously unless the larger vessels are opened. On account of the extensive lacerations caused by missiles projected from guns, the same may be said of wounds of this class.

Hæmorrhage from an artery should be controlled by pressure over the main trunk, between the wound and the heart, until the ends of the

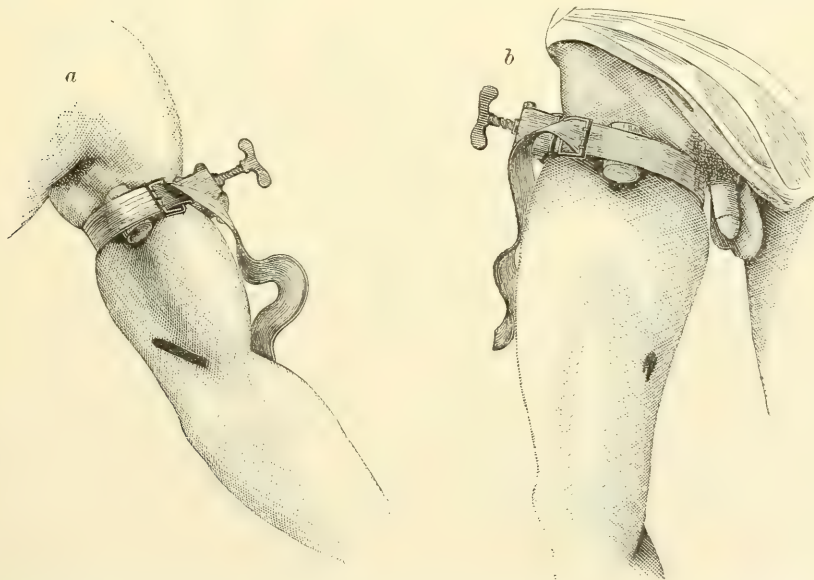


FIG. 129.—Petit's tourniquet applied in the brachial and femoral arteries. (After Esmarch.)

vessel can be secured with the catgut ligature. Venous hæmorrhage requires the elevation of a part (when an extremity is involved), and

pressure upon the distal side of the wound until the ligature can be applied to the bleeding point. While not so essential, it is best to tie both ends of a divided vein. Direct pressure in the seat of a wound will

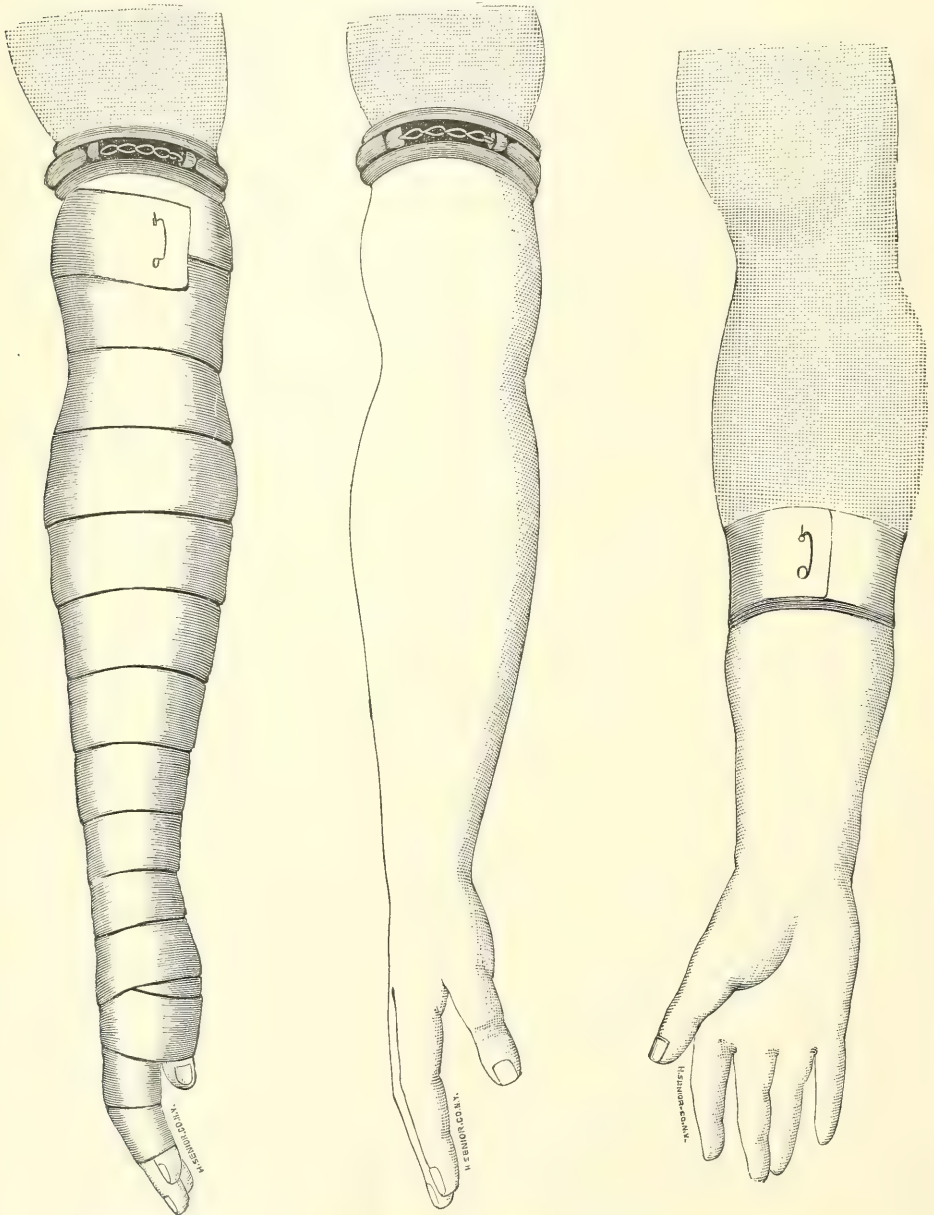


FIG. 130.—(After Esmarch.)

FIG. 131.—(After Esmarch.)

FIG. 132.—(After Esmarch.)

arrest ordinary hæmorrhage. When the bleeding is from an extremity, an emergency tourniquet may be made by tying a bridle-rein, rope, piece of cloth (as the leg of a pair of trousers, or coat-sleeve), or any other substance, around the part above the wound, and twisting this by means of

a stick, bayonet, sword, or gun-barrel, properly inserted (Fig. 127). The efficiency of this method of compression is increased by placing a pad over the main artery. Compression of an artery with the thumb or finger, or a padded key or stick, will be of service in any emergency where a tourniquet can not be had.

The tourniquet of Petit (Fig. 128) is one of the older and more useful instruments. Its application is illustrated in Fig. 129 (*a* and *b*).

Esmarch's elastic bandage, or tourniquet, is the most generally useful of all the constricting hæmostatic apparatus. It may be thrown around a part, between the bleeding point and the heart, or it may be applied from the tip of the extremity, and over and on the cardiac side of the wound, and here secured, while the portion beyond is removed. In this way the limb is rendered bloodless (Figs. 130, 131, 132). This excellent apparatus may be employed in compression of the iliacs (Fig. 133) and the abdominal aorta (Fig. 134).

When the immediate flow of blood is arrested by any of the foregoing methods, the permanent arrest of hæmorrhage must be secured by the ligature at the divided point. For this purpose the artery-forceps and the catgut-ligature, already described, will be found by far the most preferable. *Torsion* is not as safe as the ligature, and should not be

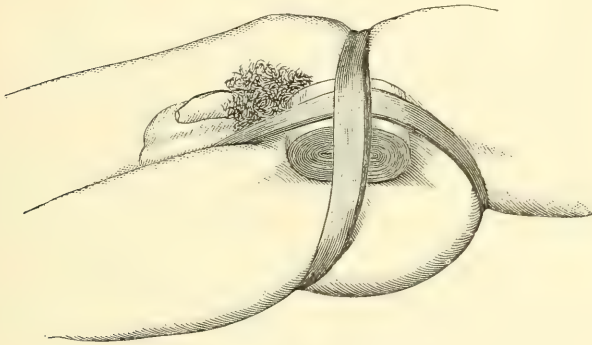


FIG. 133.—(After Esmarch.)

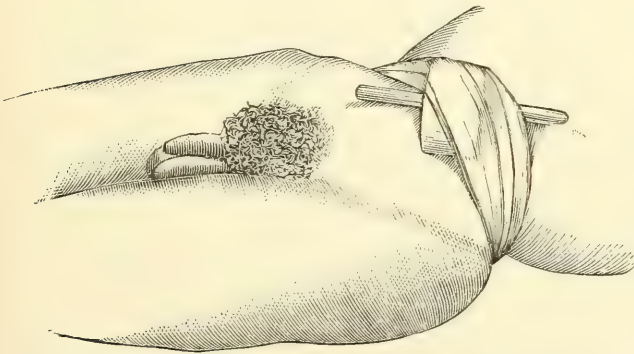


FIG. 134.—(After Esmarch.)

employed when catgut can be had. The *actual cautery*, packing with *styptic cotton*, and *acupressure* are methods never to be employed when anything else can be done. If a wound must be packed, and if sublimate gauze can not be had for this purpose, use clean linen or cotton cloth. *Cold* water, or water *heated* to about 120° to 130° F., will prove of value as a hæmostatic. Elevation of a part, and well-adjusted compression by dressing and bandage, will always be made available by the surgeon of experience. While the ligatures are being applied, and, in fact, before this time, the entire surface of the wound should be irrigated with 1 to

3,000 sublimate solution, and thoroughly cleansed of all clots or foreign matter. Next to sublimate, 1 to 20 carbolic acid is preferable, and, when neither of these solutions can be obtained, the purest water should be freely used, and this should first be boiled and allowed to cool to about 110° F. It rarely occurs in an extensive wound that all hæmorrhage can be stopped, for a general oozing takes place from capillaries too numerous to tie. Hæmorrhage of this character may be arrested by elevation of the part, or pressure either by approximation of the walls of the wound, by packing, or by general compression of the part with a bandage. If the edges are to be closed with sutures, the packing must be temporary. It is most successfully practiced by crowding the wound full of sponges, which have just been taken out of a basin of hot sublimate, and well pressed between the fingers. A hot sublimate towel is laid over these, and firm pressure made for about five or ten minutes with the hand or a roller. General compression of a limb is only well adapted to a wound which has been made or cleansed under Esmarch's bandage. After the important vessels are secured, the wound is closed, drainage-tubes inserted, a sublimate gauze dressing applied, and over this cotton wadding about one inch in thickness. A layer of protective is placed over this, and the necessary pressure employed by means of an ordinary roller. It is impossible to convey an idea of the amount of compression to be used in applying the roller. It should be tightly drawn, and as long as the tips of the toes or fingers are left out for constant inspection, so that any arrest of the circulation may be immediately discovered, no danger is incurred.

In closing a wound by sutures, the points of chief importance are to secure drainage and to bring all parts of the opposing surfaces together with equally distributed pressure. A wound which gapes at the top or bottom, or in the middle, is not well dressed. As for drainage, the material for which has been already discussed, the cardinal law is that, in the position in which the part must rest after the operation, the fluids should readily gravitate from the deepest portion of the wound out into the dressings. Before approximating wounded surfaces, if lacerations have occurred, the shreds of tissue, which will probably slough, should be trimmed off with the scissors, and the walls rendered as fresh and smooth as circumstances will admit. It is always desirable that the edges of the wound in the skin should be perfectly smooth, so that a close adaptation may be secured and an ugly scar avoided. This is especially essential upon the face, neck, and hands.

In closing shallow wounds, or those of not more than one or two inches in depth, it will usually suffice to pass the needle from one fourth to one half of an inch from the edge, and down into the tissues, so that it will emerge well down toward the bottom of the wound. It should now be entered in the opposite wall of the wound at the same depth, and brought up through the integument at a point corresponding to that where the needle originally entered. When a suture inserted in this manner is tied, it is readily seen that in approximating the wounded surfaces the pressure is equally distributed at the surface and in the

deeper portions. When important vessels and nerves are in relation to the walls of the divided tissues, great care should be taken to avoid transfixing these. In deeper wounds, an initial row of catgut sutures may be used by passing the curved needle into the tissues of the two sides well below the integument, and tying these before the superficial threads are inserted. These deep sutures are rarely necessary, however, since the surfaces may be held in apposition by the bandaging. Of the various forms of suture, that known as the *interrupted* is the most useful and satisfactory. As shown in Fig. 135, the stitches may all be on the same plane, or there may be a wide and deep, and an intermediate and more superficial row, as shown in Fig. 136. Whatever form is employed, care should be taken that as the knot is tightened the edges of both sides should be exactly on the same level. In order to effect this, it is often necessary to lift one side with a director or hook, or depress the other to the proper level with a dull instrument. No fat or shred of tissue should be allowed to bulge up between the edges, but should be pushed out of

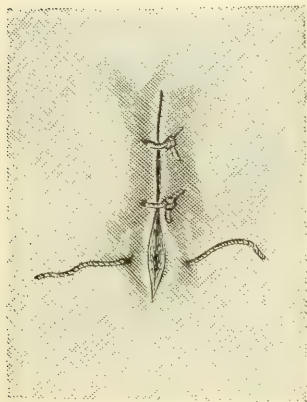


FIG. 135.

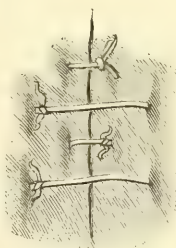


FIG. 136.




FIG. 137.

sight with a probe or forceps while the suture is tied. In order to prevent slipping, the first knot should be the double friction-loop (see page 51), which is the only one that will hold its grip while the second single loop is being tied to secure the knot. It is best to keep the knots away from the line of the approximated edges. In tightening the sutures the effort should be made to bring the lips of the wound together nicely without sufficient tension to pucker or wrinkle the skin, or to cause it to be infolded or to be turned white from too much pressure. When expedition rather than nice adjustment is desired, the *continuous* suture (Fig. 137) may be practiced. The needle is always passed at a right angle to the axis of the wound, although that part of the suture which is visible crosses it obliquely. The *mattress* suture, shown in Fig. 138, and the *quill* suture, at Fig. 139, are practically obsolete. They possess no advantages which do not belong to the *interrupted* or *continuous* methods.

The *silver-wire* suture is always interrupted. The application is well shown in Fig. 140. After the proper apposition is secured by the first

twist, made with the fingers down at the level of the skin, the ends should be clasped in an artery-forceps and turned eight or ten times.

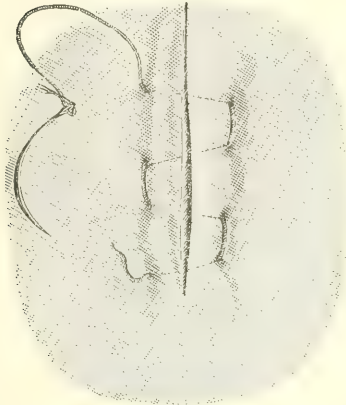


FIG. 138.




FIG. 139.

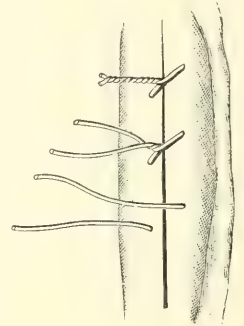


FIG. 140.

The *pin-suture* is still popular with a number of surgeons. Silver pins, or the ordinary iron pin of commerce, may be employed, and the adjustment of the opposing surfaces made more complete by throwing a silk or catgut interrupted loop, or figure-of-8, around the ends of the pin (Fig. 141), or a continuous figure-of-8 applied, as shown in Figs. 142 and 143.




FIG. 141.

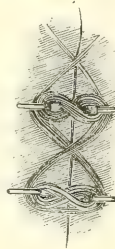


FIG. 142.

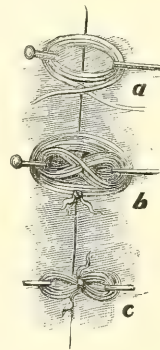


FIG. 143.

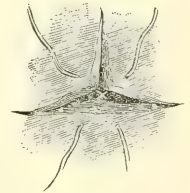


FIG. 144.

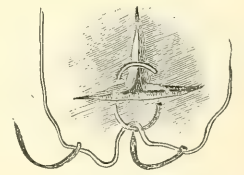


FIG. 145.

When it becomes necessary to close a three-cornered wound, a *cross-suture* (Fig. 144) may be utilized, or the *double-needled* suture (Fig. 145) may be substituted.

Superficial lesions may be closed by adhesive strips, although this method is less exact and less cleanly than the sutures. The strips should be cut narrow, and it is always necessary to have the parts to which they are to be applied dry and warm, else the plaster will not stick. The adhesive strips hold readily when warmed, as they are applied, or when moistened with turpentine. The strips may be dovetailed, or, while the

edges of the wound are held in apposition, laid directly across the line of approximation.

Another method, less frequently employed, yet useful at times, is to take a piece of plaster and fasten it to the skin parallel with the edge of the wound. A half-inch of this margin is folded back, and to this hooks are attached and elastic threads drawn directly across or in figure-of-8 fashion, graduating the pressure necessary to a proper apposition.

The *needles* for carrying sutures should be of various patterns, and of all sizes, for different purposes. Some are straight and round, others are lance-shaped; some should be crescentic, others straight for the half or two thirds of the shaft nearest the eye, and curved toward the point. In general a needle should not cut laterally while it is being introduced, since the lance-pointed variety not infrequently causes annoying hæmorrhage by division of vessels, which the round, or smooth needles would push to one side.

A good *needle-holder* is one of the most useful instruments of the operator's outfit. It should have a handle large enough to be well grasped without cramping the fingers, and strong enough to stand any required force. The instrument shown in Fig. 88 will be found to be very satisfactory. It is readily locked and unlocked, and is to be commended for having at the tip a copper grip for curved as well as straight needles, and an attachment for the Hagedorn or flat needle.

After the wound is closed, and the final irrigation made, the antiseptic dressing heretofore described should be applied.

When *hæmorrhage* has been so profuse that death from syncope is imminent, the head should be lowered so that gravity will aid the flow of blood to the brain in the hope of maintaining its functions. The administration of whisky by the mouth or hypodermically is indicated. If the bleeding is occurring internally, an effort must be made to confine as much blood as possible in the extremities, and to hold it there until, the pressure at the bleeding-point being relieved, stasis, coagulation, and arrest occur. This method I have practiced in several serious cases, and have seen its efficacy demonstrated. Both arms near the shoulder, and both thighs six inches below Poupert's ligament, are constricted by towels, cloths, or bandages of muslin or rubber, which are tightened just enough to retard or arrest the return venous circulation, and not to interfere with the outgoing current in the arteries. In this way several pounds of blood may be held away from the bleeding-point and turned into the circulation when the hæmorrhage ceases. Care must be taken not to produce fatal syncope by keeping too much from the brain, and also not to return too much of the pent-up volume into the circulation at once. Fluid extract of ergot, ℥ xxx, hypodermically, every fifteen minutes until ʒj to ʒij doses are given, is one of the best medical hæmostatics. If, despite these efforts, fatal syncope is imminent, *transfusion* is imperative.

The proper solution is: Sodium chloride, gr. xcij; liquor sodæ, ℥ xx; aquæ, O ij. From 8 to 40 ounces of this mixture at the temperature of the blood have been successfully introduced. This simple and efficient method of transfusion may be effected through a vein or an artery.

Bischoff injected $\frac{3}{4}$ xl into the radial artery of a woman, the operation lasting one hour, and the patient recovered. Szamann and many others have successfully employed this method by injecting into a vein. In a case in the practice of my colleague, Prof. Mundé, I introduced $\frac{3}{4}$ viij through the median-cephalic vein within ten minutes. This quantity was twice repeated in twelve hours. The apparatus I employed is shown in Fig. 146. It consists of a funnel, to the tip of which a rubber tube is attached. To the end of the tube is a canula for introduction into the vein. Open the vein, or utilize one already opened, in the wound if this is possible. Warm the solution to about 100° F., fill the apparatus, and allow a small quantity to escape through the pipette in order to be sure that no air is introduced. If then the stop-cock is turned, or the rubber tube compressed, the canula will be held full of fluid. After it is carried into the vein it should be held in place by a ligature tied around the vessel just behind the expansion at the nozzle. If the stop-cock is now turned on, the fluid gravitates into the vein. The quantity and rapidity of the injection may be regulated by pressure upon the tube, or by elevation of the funnel. The introduction should be slowly and gradually accomplished. Any ordinary syringe, if thoroughly cleansed, may be employed. Care should always be taken to prevent the introduction of air. The aspirator heretofore figured is an excellent instrument for transfusion into a vein or artery.

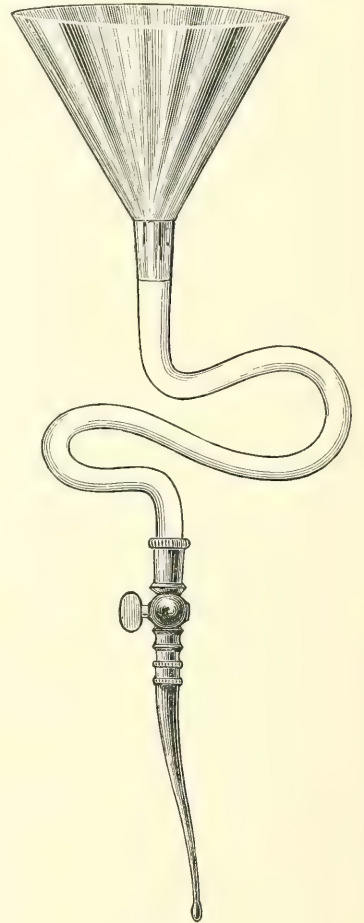


FIG. 146.

The older methods of transfusion with defibrinated blood, or direct transmission from the arm of the giver to that of the patient, are now completely superseded by the saline solution. Successful transfusion of simple water at the temperature of the blood has also been accomplished.

Poisoned Wounds.—When a *venom* or *virus* is introduced into the tissues through a solution of continuity, it is called a poisoned wound.

Snake-Bite.—The venom of certain reptiles carried into the circulation through a wound produces alarming and, at times, fatal results. The intensity of its action is in proportion to the quality and quantity of the poison absorbed, as well as to the rapidity of its introduction. Thus, the venom of the cobra and rattlesnake is more fatal than that of many other forms. Again, the venom lodged in the skin and subcutaneous areolar tissues, and absorbed by the lymph-vessels and capillaries, is far

less potent for evil than that which is injected into a vein, overwhelming the heart and sensorium by its rapid introduction.

The order of toxicity in serpent-venom, so far as known at this date, is as follows: 1. Cobra (*Naia tripudians*), a native of India; rattlesnake (*Crotalus durissus* and *C. adamanteus*), of southern North America; *Bothrop jararacassa* and *B. jararaca*, closely allied, according to Dr. Robert Fletcher,* in the intensity of its venom to its congener, the North American rattlesnake; American copper-head (*Trigonocephalus contortrix*); the American moccasin (*Toxicophis atrapiscus* and *T. piscivorus*); the spreading adder, of the order *Vipera berus*.

The venom of snakes is excreted by a gland situated near the eye. In the act of striking or biting it is forced by a compressor muscle along a channel, or groove, in the fang. In the quiescent state the fangs (one on either side) are folded backward, and are buried in grooves in the mucous membrane of the roof of the mouth. When ready for use, they are drawn forward by erector muscles. Rattlesnake-venom, according to Dr. S. Weir Mitchell,† has a specific gravity of 1.044, and an invariably acid reaction. Its color is from a greenish to a straw tint. Conjointly with Dr. Edward T. Reichert,‡ he has isolated three proteids—namely, venom-peptone, venom-globulin, and venom-albumen. Venom-globulin is intensely toxic, producing rapid extravasations of blood; venom-peptone is less poisonous, but produces, when injected into the breasts of pigeons, intense sloughing. The albumen-venom is not yet fully understood. Bromine, iodine, sodium, and potassium hydrate and potassium permanganate destroy chemically the toxic property of the venom of the rattlesnake, copper-head, and moccasin. Serpent-venom produces no poisonous effect in the tissues of the reptile which produces it, or in the tissues of any venom-producing reptile.

As just stated, the symptoms resulting from snake-bite in man vary with the toxicity of the venom, the amount introduced, and with the rapidity with which it is carried into the circulation. A keeper in the London Zoölogical Gardens was bitten on the nose by a cobra, and died in a little more than one hour.§ Dr. Wainwright, of New York city, died within six hours after being bitten by a rattlesnake. || Dr. G. A. Kunkler^ reports the case of a boy six years old, who died during a convulsion on the fourth day, after being bitten on the foot by a copper-head. The venom is seemingly as potent in cold as in warm weather. Dr. E. P. King ¶ treated a patient in whom well-marked toxic symptoms were developed after being bitten by a copper-head which, although torpid, had recovered its activity under the influence of heat. When the

* "American Journal of the Medical Sciences," July, 1883.

† Smithsonian Contributions, 1860. "New York Medical Journal," 1868.

‡ "Philadelphia Medical News," 1883.

Bryant's "Surgery."

|| Hamilton's "Surgery."

^ "Cincinnati Lancet and Observer," 1859. "American Journal of the Medical Sciences," April, 1883.

¶ "American Journal of the Medical Sciences," April, 1884, p. 428.

clothing intervenes, the venom is likely to be in part arrested, and the effect less severe.

Pain of a sharp or stinging character is usually felt in the wound. Fright or shock may mask this symptom. Swelling rapidly ensues, and in rattlesnake-bite ecchymosis is not uncommon. The swelling extends in all directions, but is most marked in the line of the lymphatics toward the center. Headache, fever, rigors, irregular breathing, and a low, feeble pulse, with nausea, may be present. Adenitis, abscess, or sloughing usually occur. If death does not ensue, the case may terminate favorably in two or three days, or last for weeks and months.

Treatment.—The immediate indication is the removal of the venom. Labial suction is an efficient method, and may be safely practiced, provided that there is no abrasion on the lips or contiguous mucous surfaces. Inoculation is more dangerous about the mouth and neck than elsewhere, since the great swelling may close the trachea or larynx. Next in order of readiness is free and immediate excision of the tissues within a radius of half or three fourths of an inch from the puncture, or free incisions may be made so that the flow of blood may wash the venom out.

Permanganate of potassium is probably the best chemical, and whisky (or alcohol in some other form) the best physiological antidote. Dr. de Lacerda,* of Brazil, recommends the immediate injection in and around the wound of a 1-per-cent (gr. v to ℥j) solution of the permanganate in water, and also an intra-venous injection if the venom has had time to enter the circulation. Dr. Robert Fletcher† states that Richards, of Calcutta, after repeating Lacerda's experiments, recommends a 5-per-cent solution in cobra-poison; ℥j to ℥iv of a solution, varying from gr. v to gr. x to water ℥j, would be about the safest treatment for rattlesnake-venom; and the weaker solutions for copper-head and moccasin bites. It must not be forgotten that this salt is toxic in overdoses. Vulpian produced death in a small dog with an injection of gr. viij. Whisky, or any form of alcohol, is a favorite cardiac stimulant, and may be taken in adults in large quantities without intoxication. Care must be taken in administering alcohol to children, since it has occasionally proved fatal.

When great swelling occurs, and gangrene is threatened on account of tension, free incisions or punctures should be made.

The venom of some of the lizard family, as the Gila monster‡ (*Heterodermia suspectum*) and the toad# (*Bufo vulgaris*), also possesses toxic properties. The treatment should be about the same as given above for serpent-venom, though not quite so energetic.

Venom introduced with the sting of the *scorpion* not infrequently causes death in the Orient, although the sting of the North American scorpion is not dangerous. I have failed to hear of a death from this

* "Gazette des hôpitaux," 1881, pp. 597 and 891. Also, a valuable paper by Dr. H. C. Yarow, "American Journal of the Medical Sciences," April, 1884.

† "American Journal of the Medical Sciences," July, 1883.

‡ Mitchell and Reichert, "Medical News," Philadelphia, 1883.

"Gazette des hôpitaux," 1881, p. 598.

accident, although I have made personal inquiry from numerous practitioners in the South and West, who have had much experience with these cases. In a personal experience, in which I was stung by a scorpion in the palm of the hand, no unpleasant symptom followed. As soon as the insect was brushed off, the venom was removed by sucking the wound, and by expression.

The venom of the *tarantula*, and other spiders, is occasionally fatal. In a private communication, Dr. Thomas A. Pope, of Texas, who has seen many cases of tarantula-bite, reports one fatal case. Death did not ensue, however, from the changes induced in the blood by the venom, but from asphyxia due to closure of the larynx and trachea from great swelling, the man having been bitten in the neck.

The swelling is usually severe, and an erythematous rash occurs about the second day. This may occupy one half or all of the body. Sloughing at the wound almost always occurs.

The stings of *bees*, *wasps*, *hornets*, etc., possess a venom which, while rarely fatal, is painful and annoying. The application of an alkaline solution will, if immediately used, neutralize the pain and the tendency to swelling. Clay moistened into a paste with the saliva is an effective remedy used by the negroes in the Southern States. The sting should be removed if it has remained in the wound. In the case of a negro child, three years old, who had just a minute or two before been stung by about forty bees, no serious symptom ensued. The treatment followed was brushing the insects off with a sheet, and thoroughly sponging the entire body with a solution of a teacupful of ordinary saleratus in two quarts of water.

The venom of the *centipede* scarcely deserves mention. I am told by physicians practicing in the sections infested by these *Myriapoda* that their toxic power is much exaggerated. The slight effects which follow their foot-marks and the bite of the tarantula should be treated by permanganate of potassium locally and stimulants internally.

Hydrophobia.—The bite of certain animals, as the wolf, dog, fox, and cat, is at times followed by alarming, and often fatal symptoms, due to the absorption of a specific virus. It was formerly thought that the saliva alone was the menstruum for this poison, but Pasteur* has recently claimed that he has produced rabies in animals inoculated with the cephalo-rachidian fluid, and the nerve-matter of the medulla oblongata of other animals suffering from this disease. He also claims that by successive cultures of the specific germ of this disease, and inoculations with the cultures, immunity from rabies may be secured. While any statement from this great scientist is entitled to credence—and while the report of the commission appointed by the French Government fully proves the success of Pasteur's method in animals—it is not yet fully determined that vaccination will give immunity to man, nor prevent the development of rabies after inoculation.

Hydrophobia may follow the bite of an animal seemingly in perfect

* "Gazette des hôpitaux," 1881, p. 502. *Ibid.*, 1884, p. 733.

health, as well as from one noticeably affected with rabies. In man and other animals it may occur at any season of the year, and in all climes. The wound inflicted always heals slowly, even without regard to the inoculation of the specific virus, for, in addition to being contused and lacerated, it is infected by contact with the saliva, which even in man Sternberg* has shown will produce fatal sepsis when injected into the tissues of animals.

The period of incubation in rabies in man varies from five days to as many months, and in exceptional instances to as long as one or two years. The symptoms of its approach are often vague. Pain in the track of the sensory nerves leading from the wound, and in and about the wound or scar, is given as among the earlier indications. Irregular heart-action occurs, together with respiratory disturbance of a convulsive character. The face expresses a sense of actual suffering, or of anxiety in the anticipation of impending disaster. Nausea, increased flow of saliva, and vomiting occur, and often are followed by general or partial convulsive movements. Death ensues usually between the second and fifth day. Prof. Flint† is of the opinion that no well-authenticated case has ended in recovery. In three out of seven cases examined by Southam‡ sugar was present in the urine, which fact indicates irritation of the medulla, and is corroborative of Pasteur's* statement that the gray matter of the brain and cord, and especially the medulla oblongata, is affected by the poison (microbes) of rabies.

Treatment.—Preventive measures are of first importance. If Pasteur is correct in his deductions—and there is little doubt of his success with animals—enforced inoculation (vaccination) of all dogs and cats should be practiced. The wound inflicted by any animal, and especially one either suspected or known to be suffering from rabies, should be immediately and freely excised, or the parts in and around the wound destroyed by the actual cautery, or by a penetrating escharotic. When situated upon a part of the body which can be brought in contact with the mouth, the blood, and with it the virus, may be removed by labial suction. After absorption has occurred, and with the appearance of the convulsive stage, chloral hydrate and opium by the stomach, and chloroform or ether by inhalation, may be given, as required. Cannabis Indica is reported as successful in a single case.||

Glanders.—This name has been given to a contagious disease which attacks animals, chiefly horses, and is communicated to man by inoculation of the peculiar virus upon a mucous membrane or a cutaneous wound. In horses the mucous membranes of the throat and nose are first affected, and this is followed by enlargement and breaking down of the lymphatic glands of the neck, and by symptoms of general sepsis, metastatic abscesses, and cutaneous ulcers. It is not only communicable from

* "American Journal of the Medical Sciences," 1882, p. 69.

† Flint's "Practice of Medicine."

‡ "Medical Record," vol. xxi, p. 128.

* *Loc. cit.*

|| "Medical Record," vol. xxi, p. 179.

an animal to man, but from one person to another. Schutz and Löffler, in Koch's laboratory, have recently announced the discovery of the *bacillus of glanders*, which is said to resemble the *bacillus tuberculosis*. These organisms were seen by Wassilieff in the blood of a man sick with this disease. Inoculated with this virus, the parts about a wound become rapidly inflamed and swollen. Cellulitis, lymphangitis, and adenitis ensue, with high febrile movement and the usual conditions of septicæmia. Inoculated upon a mucous surface, the morbid process is practically the same. The inflammation spreads rapidly, and the adenitis and ulcerations occur in man as in animals. In severe cases metastatic nodules occur in the skin, not infrequently breaking down into pustules. Abscesses may be general. In the severer cases death is the rule.

The indications in *treatment* are to support the tissues by all possible measures of nutrition. A wound freshly inoculated should be treated as advised in *rabies*.

Malignant Pustule.—This disease in man results from the inoculation of a peculiar virus which is found in the tissues of animals infected with a micro-organism, the *anthrax bacillus* (Fig. 147). This bacillus is believed to be the disease-germ. *Carnivora* are rarely susceptible. The virus is intensely toxic, and exceedingly contagious. By some it is held that an abrasion of the integument or mucous surfaces is not always necessary to the invasion of the germ.* The bite of an insect which has been feeding upon anthrax carrion, or the ingestion of infected meat, or the mere contact with the hair, wool, bones, or any part of an animal dead with anthrax, is dangerous.† Tanners, butchers, and furriers are more often the sufferers from this disease than others. The virus retains its potency almost indefinitely. Sheep allowed to graze in localities where carcasses of cattle dead with anthrax have been buried many years acquire the disease by ingestion of germs lodged upon the grass, and in the earth over these graves. Contagious from animal to animal, and from animal to man, it is likewise contagious from one individual to another. The face and hands are, on account of exposure, most frequently the seat of the inoculation. The *symptoms* are redness, swelling, induration, a throbbing sensation and pain at the point of contact of the virus. Within twenty-four hours an ulcer usually is developed in the center of the indurated area, soon followed by lymphangitis and adenitis. High temperature, rapid pulse, headache, nausea, and the usual condition of general septicæmia, follow as the disease progresses.

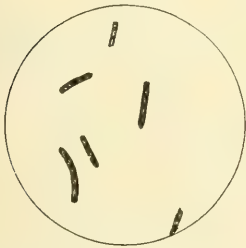

FIG. 147.—(After Sternberg.)

Microscopical research has demonstrated *bacilli*, in great numbers, not only in the tissues immediately around the seat of contagion, but, also in the later stages of the disease, a general dissemination of these organ-

* Agnew's "Surgery," vol. i, p. 214.

† "New York Medical Journal," 1884, p. 410.

isms. Hæmorrhagic infarctions and œdema are frequent symptoms. When the disease results from the ingestion of the poison, the diagnosis is difficult. Swelling and puffiness of the face have been observed, with high febrile movement and great prostration.

Treatment.—Local and constitutional measures are demanded—excision or free incision, and the application of a strong sublimate solution (1 to 1,000). Supporting measures are demanded when the infection is general and prostration is threatened.

Dissection Wounds.—A wound is not apt to become poisoned from contact with the tissues of a cadaver which has been thoroughly injected with chloride of zinc, arseniate of soda, or sublimate solution. Septic matter from non-injected subjects is always a source of danger when brought in contact with abrasions of the skin or mucous surfaces. The contents of the peritoneal and pleural cavities are especially virulent. The fluids from persons dead from any septic or malignant disease, such as erysipelas, small-pox, etc., are unusually dangerous. Patients suffering from suppurative arthritis, with general sepsis, are dangerous subjects. In a recent case of this nature in Mount Sinai Hospital, a colleague and one member of the house-staff and the nurse were all seriously inoculated from the same operation. Susceptibility varies with the individual. Some enjoy lasting immunity under all conditions of exposure, while others are easily inoculated.

Symptoms.—Inflammation and soreness at the wound are first noticed. In a few days lines of redness extend in the route of the lymphatics, and the arm (since the hand is usually the seat of the primary lesion) becomes painful, stiff, and hot. The epitrochlear and axillary glands enlarge, and in many cases suppurate. Rigors, fever, headache, aching of the joints, coated tongue, and other symptoms of sepsis follow. The patient may pass into a low typhoid state, or general metastatic abscesses may occur, ending in death.

Treatment.—Ablution of the wound in sublimate solution (1 to 500) and suction should be instantly performed, or suction alone may remove the poison. It should be kept open and washed frequently. Cold cloths or the ice-bag will be found very grateful in the lymphangitis and adenitis which follow the inoculation. Caustics, or covering in an abrasion with liquor gutta-perchæ, collodion, or plaster (except for protection against further inoculation), is an absurd and dangerous practice. If abscesses form, early incision is demanded. The constitutional remedies are quinia, tonics, stimulants, antipyrine, judicious feeding, and ventilation.

Erysipelas.—Erysipelas is a contagious as well as an infectious disease, caused by the invasion through an abrasion of the integument, or by the mucous surfaces, of a specific poison or virus. The presence of an almost constant micrococcus (chain-coccus of Fehleisen) in the inflammatory area of erysipelas has led some observers to consider this organism as the cause of the disease. That it has not been found, in some instances examined by careful investigators, might seem to disprove this theory. The weight of modern opinion is, however,

largely in favor of the existence of a special coccus of erysipelas. It may spread from one infected person directly to another, or indirectly by means of the clothing or hands of an intermediate party. It is characterized by an inflammation of the skin or mucous surfaces, of the subcutaneous and submucous tissues, and at times, passing the barrier of the deep fascia, it attacks the muscles and deeper organs. The period of incubation varies from eight to twelve hours to three or four days. For constitutional or even marked local symptoms to occur within twenty-four hours, however, after exposure of a wound to the virus, is the exception rather than the rule. In the large majority of cases the symptoms declare themselves usually between twenty-four and forty-eight hours. Locally the part becomes hot, throbbing, tense, and painful, especially on direct pressure. The color varies from a pale rose to a bright red hue. In well-marked cases the inflamed integument appears to be glazed, and the limit of redness is regularly and sharply defined. When the inflammatory process is rapid, and the integrity of the circulation markedly impaired, the bright flush of the skin gives way to a dull mottled discoloration. Pressed by the tip of the finger, the skin becomes pale, but the color returns and the indentation is soon effaced, except in those cases of marked œdema. Lymphangitis and occasionally phlebitis occur. The spread of these complications is indicated by lines of redness and tenderness leading in the route of these vessels. In some instances vesicles or bullæ form beneath the epidermis. An attack of erysipelas is almost always ushered in by one or more chills, or by different and recurring chilly sensations or rigors. The exacerbation of temperature varies from 100° to 104° or 105° F. The pulse is proportionately increased in frequency. The febrile movement and constitutional symptoms vary with the character of the attack. In simple *cutaneous* erysipelas the clinical history is usually mild. In the *cellulocutaneous* or *phlegmonous* variety severe and fatal sepsis is not uncommon. Gangrene is occasionally met with about the center of the inflamed zone, and, when attacking an extremity, the circulation may be arrested and the part beyond the disease sacrificed. The duration may be from seven to ten days in mild cases to several weeks in the severer and not fatal forms.

Diagnosis.—Erysipelas, within the first twenty-four or forty-eight hours of its appearance, may be taken for dermatitis, or simple erythema, phlebitis, lymphangitis, or cellulodermatitis.

Dermatitis occurs, as a rule, from local irritation, and is not accompanied by any of the constitutional disturbances which always occur with erysipelas. In simple inflammation of the skin the color is red, but it never has the glazed appearance which is always present in a typical erysipelas. *Erythema*, a mild form of dermatitis, may also be mistaken for erysipelas. In *erythema papulatum* the exposed and extensor surfaces, as the dorsum of the hand and the posterior aspect of the forearm, are apt to be involved. There is no wound of inoculation; very slight, if any, infiltration of the skin proper. Children and younger adults suffer most frequently. It lasts for only a few days, then fades away, leaving

a dry scale to indicate the location of the papule. Owing to the various shapes and the different shades of color assumed by the papules, and efflorescence of the erythema, it has been divided into *erythema annulare*, *erythema gyratum*, and *erythema iris*.*

In *erythema intertrigo* there is a general redness of the skin in parts subjected to friction or irritation from perspiration. *Erythema nodosum* is almost peculiar to chlorotic females. The color, at first bright red, soon changes to a dark hue. The patches are oval, elevated, and nodular.

Phlebitis and *lymphangitis* are more severe forms of inflammation than those just given, and are accompanied with constitutional symptoms not unlike those present in a typical erysipelas. The chief point of diagnostic value relates to the anatomical arrangement of the vessels, for in phlebitis and lymphangitis the lines of inflammation and discoloration travel along the course of the vessels without the general and wide-spread efflorescence of erysipelas.

Diffuse cellulitis occurring from a poisoned wound, as with a dissecting-knife, or after the bite of a serpent, will offer no difficulty in diagnosis. It may, however, occur without a recognized cause. The subcutaneous tissues are first attacked, and the skin may or may not be involved in the process of inflammation. There is swelling and painful tension of the part affected, and, if the process be uninterrupted, transudation of serum occurs, causing œdema, and giving a doughy feeling on pressure. Pus may be formed in quantity, and infiltration become extensive. This result is more apt to occur in diffuse non-specific cellulitis than in phlegmonous erysipelas. This condition, especially when the skin becomes involved, offers considerable difficulty to a positive diagnosis. If, however, the peculiar symptoms heretofore given be carefully considered, and a comparison instituted between them and the phenomena of the various diseases which may simulate or complicate erysipelas, it will be found that, in the great majority of cases, a correct diagnosis may be made.

Prognosis.—Simple cutaneous erysipelas, as a rule, is not a dangerous disease. In several epidemics in hospital practice I have never seen a fatal case. Occurring about the face, head, or neck, the prognosis is less favorable than when the inoculation occurs elsewhere. When it complicates a wound in a patient already prostrated by hæmorrhage or surgical fever, it may hasten a fatal issue. In phlegmonous or cellulocutaneous erysipelas the prognosis is not so favorable. Suppuration and the general infiltration of the tissues with pus and inflammatory products induce a condition of septicæmia often rapidly fatal.

Treatment.—In an outbreak of erysipelas the treatment in those attacked is both local and constitutional, while in others strict measures of prophylaxis should be instituted. Immediate isolation should be effected, and the greatest care observed to prevent contact with other subjects. All bedding, furniture, and apparatus used upon or about an

* Neumann, "Hand-Book of Skin Diseases." Bulkley. D. Appleton & Co., 1872.

erysipelatos patient should be burned, or thoroughly scrubbed and soaked in a solution of corrosive sublimate varying in strength from 1 to 500 to 1 to 1,000. Any instrument subjected to contamination should be submerged in 1 to 10 to 1 to 20 carbolic acid, and afterward thoroughly dried. The walls and floors of a ward or room in which an outbreak has occurred should be mopped and washed in the sublimate solution. The attendants upon such cases should be excluded from all possible contact with other individuals.

When a physician is compelled to visit a case of erysipelas, he should wear clothing which should be changed immediately after leaving the room, which precaution should be emphasized by a thorough disinfection of his hands, face, beard, and hair in 1 to 3,000 sublimate solution.

The local measures always include as of first importance the investment of the part involved with sublimate gauze and a moist dressing. Continuous irrigation of cold, tepid, or warm sublimate (1 to 5,000) may be added to the loose gauze dressing, or not, as may be determined by the demands of any case. This method is mainly prophylactic. Cold irrigation will be most generally grateful. Extreme heat or cold, however, should be used with caution in all cases where the circulation of the part is seriously impaired by the inflammatory process. When an extremity is affected, elevation of the part is indicated. Tension should always be relieved by puncture or incision, even when suppuration and pus infiltration are not evident. The method of freely puncturing or making multiple limited incisions in the infected area is lately highly recommended, and is worthy of trial. A loose aseptic gauze dressing should follow. The principle of drainage applies here as in other wounds, and the free outlet of all purulent matter is essential. Incisions, when practiced, should be in the direction of the veins of the part, so that these need not be divided, and should always extend deep enough to relieve tension and to give free exit to all septic matter. The method of injecting carbolic acid into the skin and subcutaneous tissues, at a distance of from one to two inches from the red limit of the erysipelatos flush, in order to check the further invasion of the disease, is of doubtful efficacy and propriety. The same should apply to "firing" with the actual cautery or lunar caustic for the same purpose.

The constitutional measures look to the support of the patient, and to the antagonism of the specific poison. Since constipation and gastric disturbance are the rule, a saline laxative should be given, but not to the extent of producing exhaustive diarrhœa. Purgation is not indicated in enfeebled and emaciated subjects. For the rapid pulse, tincture of aconite-root may be employed, and anti-pyrine, 10 to 20 grains every two or three hours until the temperature falls to about the normal. Tincture of the chloride of iron, 8 to 15 drops three or four times a day, has long enjoyed a high reputation in the treatment of this disease, and the same is true of quinia in full doses.

Tetanus.—Tetanus, or “lock-jaw,” is now believed to be an infectious disease due to the presence of a special bacillus, the bacilli of *tetanus*, or of Nicolaier. These organisms are invariably found in the tissues at the wound of infection, and appear as bristles or as pins, when they form spores (Baumgarten). They are found in the soil and in dusty particles floating in the air.

Lock-jaw has been produced in animals by inoculation with the tissues of man, the subject of tetanus. Whether the central lesion (*myelitis*) is directly due to the presence of these organisms, or to the absorption of certain ptomaines which are generated by their contact with the tissues, is, at this date, not definitely settled.

Any lesion, however small or seemingly insignificant, and upon any portion of the body, may serve as the starting-point of this affection. Wounds, however, of exposed surfaces, as of the hands, feet, and face, are especially liable to become infected.

The time which may elapse between the receipt of the injury and the appearance of the muscular spasms varies from a few hours to several

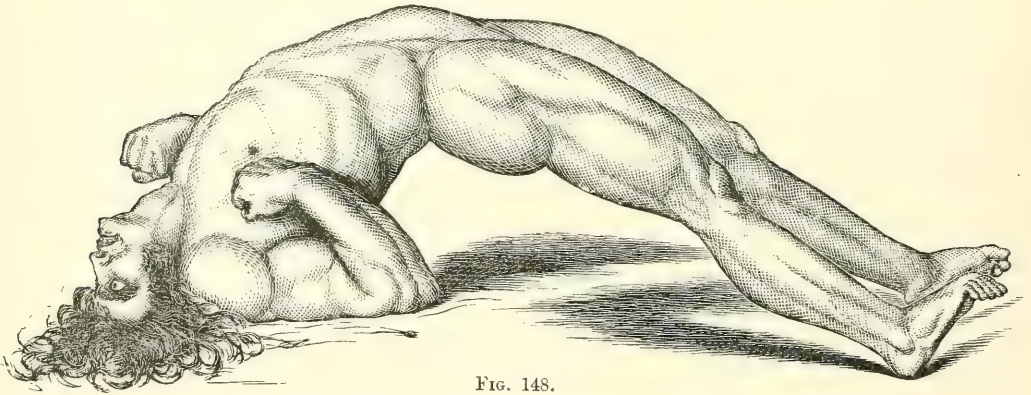


FIG. 148.

weeks ; usually within the first three weeks after the injury. The earlier symptoms refer to an unusual degree of irritation and pain in the wound, which is apt to be out of proportion to the degree of inflammation present. The sense of pain is often referred along the sensory tracts toward the centers. Irritability, a sense of unusual muscular excitability, a feeling of malaise and apprehension, are among the symptoms which precede the convulsive attacks. The muscles supplied by the motor filaments of the fifth nerve are among the earliest to respond to this abnormal stimulus, hence the commonly accepted term of *lock-jaw*. In the milder cases the tonic spasms may be altogether confined to these muscles. In severer cases the sense of distress is referred to the epigastric region, and this is followed by tonic muscular contraction, commencing with the diaphragm, and involving in quick succession the muscles of the jaws, larynx, and back of the neck and dorso-lumbar region. Respiration is interrupted, the expression of distress is extreme, the face becomes cyanotic, and death may occur from fixation of the respiratory muscles. The chief distortion is that of more or less complete extension of the spine (*opis-*

thotonos). An exaggerated illustration of this condition is given in Fig. 148, from the well-known picture of Sir Charles Bell. When the tonic spasms are confined to the anterior muscles, and the body is bent forward, the condition is known as *emprosthotonos*, and if curved laterally, *pleurothotonos*. The spasm continues until the muscles are unable longer to contract, when a gradual and partial relaxation occurs. Successive attacks follow rapidly, being precipitated by the slightest cause, as the jar communicated by walking upon the floor, or the contact of the hair or clothing upon the hyperæsthetic integument.

Notwithstanding the violent nature of this affection, the mind, in the great majority of cases, remains clear until carbonic-acid poisoning occurs from prolonged fixation of the respiratory muscles. The pulse and temperature vary between great extremes, records of the former running from the normal up to 160 beats per minute, and of the latter from 98.5° to 112° F. The intense heat which is premonitory of a fatal termination, and which continues for a considerable while after death, is supposed to be due to coagulation of the albuminoid principle of muscle, the myosin (Fricke). Death may take place in a single paroxysm, or the patient may survive a number of attacks.

Prognosis.—The danger of death diminishes if the patient survives the fifth day, although the vast majority of cases end fatally before this. The gravity of the prognosis usually depends upon the violence of the paroxysms, the rise in pulse and temperature being also proportional to the severity of the convulsions. The period which elapses between the receipt of the accident and the appearance of the tetanic spasms is not without importance in prognosis, the chances of recovery being increased with the longer interval. The death-rate in those cases in which tonic spasms occurred within two weeks after the injury is 62 per cent; from 14 to 21 days, 17 per cent; 21 to 44 days, 17 per cent; 50 per cent of all fatal cases terminate within 5 days after the first paroxysm; 33 per cent from the fifth to the tenth day.

Diagnosis.—Hysteria is more apt to be mistaken for tetanus than any other disease. In hysteria there is usually no elevation of temperature, and the symptoms of great and acute distress are wanting. Hysteria occurs chiefly in females; tetanus, in a large majority of cases, in the opposite sex. It may be necessary at times to differentiate between the tetanoid spasms of strychnia-poisoning and true tetanus.

Strychnia tetanus ensues within a few minutes after the poison has been taken; the muscles of the jaw are not first affected as in tetanus, and are not always rigid during the attack. The convulsive movements in strychnia-poison are of short duration, and complete relaxation occurs, while in tetanus the muscular rigidity is continuous.

Hydrophobia may be distinguished from tetanus in the character of the lesion which causes it, the peculiar clonic or interrupted spasm of the muscles, especially those of the larynx, and in the generally longer period of incubation in rabies.

Pathology.—The lesion of tetanus is believed to be a myelitis. The gray matter of the cord and medulla is found deeply injected, or it may

have undergone granular degeneration. In some instances no appreciable interference with the nutrition of the gray matter can be discovered.

Treatment.—The essential feature of treatment is the protection of all wounds from the dangers of infection by the thorough application of antiseptic dressings after the free use of the sublimate solution. Other local measures should be employed to reduce the irritation in the wound. Relief of all tension should be secured by incisions, if necessary, and free discharge should be maintained, if there is septic matter in the tissues.

Amputation when the wound is situated upon one of the extremities, stretching or division of the sensory nerve leading to the spine, excision of the wound, and other surgical measures, have been tried, but without a success which would warrant a repetition of these measures. The most perfect quiet is to be maintained, and the administration of concentrated nourishment must be insisted upon in the intervals of the attacks; and rectal alimentation should be practiced if there is inability to swallow.

Chloral hydrate in large doses has been successful in some cases. From thirty to forty grains have been given and repeated at intervals of one hour and a half.* The inhalation of chloroform is also highly recommended. The extract of cannabis Indica (Squires) in doses of gr. ss. every two hours, together with the application of ice to the spine, is a plan of treatment highly recommended.

Gunshot Wounds.—Wounds of this variety may properly be divided into those in *civil* and those in *military* practice. In civil life the wounds inflicted by the shot-gun, small-bore hunting-rifle, pocket-pistol, and toy guns, are much less dangerous than those made by the more formidable weapons employed in warfare.

With the exception of the charge projected by the shot-gun and the small hunting-rifle, all missiles now used are conoidal or oblong in shape (Fig. 149).

Projectiles fired from ordnance are both round and conoidal, solid and hollow, the latter being usually explosive. Grape, canister, bombs, and some solid shot, are spherical, while most of the shells are cylindro-conoidal.

A gunshot wound is always *contused* or *lacerated*. It may be *simple* or *complicated*: simple when the missile alone passes through the tissues; complicated when fragments of cartridge, wadding, powder, clothing, or other foreign matters are carried in with it.

The degree of laceration made by a gun-projectile is, as a rule, in an inverse ratio to the rapidity of its projection. It may also depend upon the shape of the missile, and the additional destruction caused by displaced fragments of bone, etc. A conoidal projectile is more destructive than one which is spherical, for when in its transit the point meets with resistance, it tends to turn over and over on its long axis, loses in great part its axial rotation, and thus plunges through the tissues. When a ball passes in and out of the body, it will be found that the wound of entrance is smaller than that of exit, and is seemingly much smaller

* Hammond, "Diseases of the Nervous System." D. Appleton & Co.

than the projectile. The infolding of the skin and its elasticity will account for the small size of the entrance. The diminution of the momentum, and the tumbling of the projectile as it plunges through the tissues, together with the non-resistance of the skin at the exit,

will account for the larger size of this opening. When a projectile passes completely through the tissues there is usually a single opening of exit. Occasionally the object is divided after entrance, and makes two or more holes of exit, or one part of the bullet may lodge and the other pass out.

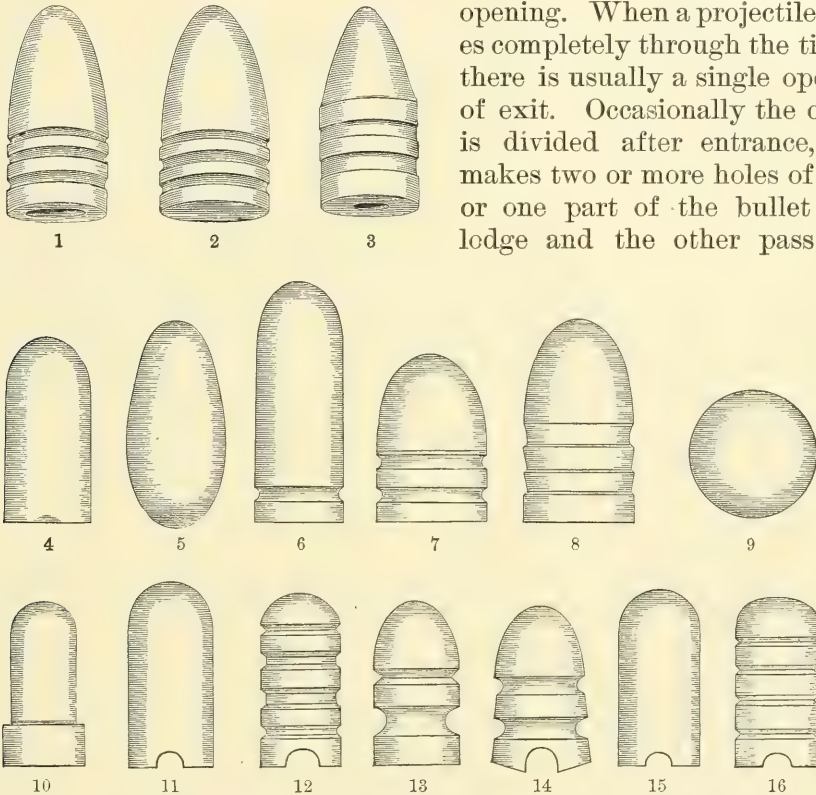


FIG. 149.—Table of weights (in grains) of the balls at present in use in the armies of various nations. With the exception of No. 6, the cuts approximate the actual size of the missiles. 1, Springfield rifle, 500 grains (Agnew). 2, Enfield rifle, 530 grains (Agnew). 3, Austrian rifle (old), 400 grains (Agnew). 4, Chassepot rifle, 387½ grains (Fischer). 5, Needle-gun, 530 grains (Agnew). 6, Mitrailleuse, 840 grains (Agnew). 7, Bavarian rifle, 386 grains (Fischer). 8, Snider rifle, about 400 grains. 9, Musket-ball, 480 grains (Agnew). 10, Belgian rifle, 385 grains (Fischer). 11, Martini-Henry rifle, 485 grains (Fischer). 12, Italian rifle, 310 grains (Fischer). 13, Netherland rifle, 337 grains (Fischer). 14, Austrian rifle (new), 372 grains (Fischer). 15, Russian rifle, 372 grains (Fischer). 16, Swiss rifle, 310 grains (Fischer).

Fragments of bone or teeth displaced by a missile may be driven out through the integument.

If the velocity of a missile is great, and the tissues traversed offer no special resistance, the wound of exit will be in the direct line of that of entrance. Bodies traveling with diminished velocity or meeting with formidable resistance will be deflected, and may pursue a most unexpected course. Instances are recorded of bullets which have made a half or the entire circuit of the body, passing just beneath the skin. Still more remarkable are the instances of extensive fracture of bones which have been produced without any evidence of injury to the integument. Longmore* relates the case of a soldier who had the whole shaft of the

* Holmes's "Surgery," vol. ii, p. 134. William Wood & Co., 1875.

humerus shattered by a cannon-ball, yet the skin remained as white and as sound as if it had not been touched. Numerous instances of similar lesions are recorded.

Treatment.—As with all other wounds, the arrest of hæmorrhage is the first indication in gunshot injuries. The various means to accomplish this end have already been given. It should be the recognized duty of the profession to instruct the general public in the use of the simpler means for arresting hæmorrhage. In military service each soldier should be taught by actual demonstration where and how to make compression in order to control the blood-supply to a part. In actual warfare the vessels should be outlined by nitrate-of-silver tracings, and with especial indications at those points where pressure will prove most efficient. The ready construction of a tourniquet by means of a belt, coat-sleeve, bridle-rein, etc., tied around the limb at the proper place, and then twisted by a bayonet, sword, gun-barrel, or stick, is an important lesson for an emergency. Next in order, and no less essential in the successful management of a gunshot wound, is *cleanliness* and *drainage*. In the best-regulated armies of to-day each soldier carries in his cartridge-box a well-protected ball of iodoformized gauze, with the instructions to lay this over the wound as soon as possible, and to hold it there by a belt or bandage until the surgeon arrives. In the antiseptic treatment of these injuries irrigation with 1 to 3,000 sublimate solution is thoroughly done. All foreign matter or fragments of bone or destroyed tissues are removed, bone, catgut, or rubber drains inserted, and the regulation antiseptic dressing applied.

When sublimate solution can not be had, 1 to 20 to 30 carbolic acid is next in order of preference; and, if neither of these articles is available, the freshest and purest water should be employed; and, when time allows, this should be boiled, and used at 110° F.

Following a serious gunshot or other injury (or at times a violent emotion without any appreciable lesion), a condition of prostration or partial collapse occurs, which is known as *shock*. Shock may be defined as a condition of collapse resulting from physical injury or mental emotion (one or both) whereby the functions of the nerve-centers are more or less completely suspended. The degree of shock is often determined by individual susceptibility, and is not always in proportion to the severity of the injury. The symptoms are pallor, coldness of the skin, thready, irregular, or rapid pulse, nausea, vomiting, clammy perspiration, and an anxious and fixed expression.

Judicious stimulation is the great indication, for, while reaction must be brought about, the quantity of stimulants should be kept at the possible minimum, for an excess will only add to the fever of reaction. Rye whisky by the mouth, rectum, or hypodermically, should be preferred.

Hot bottles, warmed blankets, friction, etc., are useful adjuvants in the treatment of shock.

The advisability of searching for a gunshot missile which has lodged in the body, or which has traversed any of the cavities, as well as the treatment of wounds of special organs, will be discussed hereafter.

CHAPTER VII.

BURNS AND SCALDS.—FROST-BITE.

Burns and *scalds* are classified in degrees varying from the mildest form, which produces a simple inflammation of the epidermis, to the most severe form, which destroys all the tissues or organs of a part. The gravity of the prognosis is usually in proportion to the extent of surface of the integument destroyed rather than to the depth of the destructive process. Burns of the head and face are most dangerous; those of the extremities least grave. Recovery is exceptional after destruction of one third of the cutaneous surface. Death may result from shock, ulcer of the duodenum, or exhaustion from prolonged suppuration and septic absorption.

The history of a slight burn or scald involving only a limited area of the integument, and not extending beyond the skin, is simply one of local disturbance. Cold-water immersion is the indication in treatment. When, however, a considerable extent of tissue is involved, symptoms of profound constitutional disturbance rapidly supervene. The patient is seized with chills or rigors, suffers excruciating pain, betrays in his expression the extreme anxiety felt as to his condition, and sinks into a condition of collapse, which is often the prelude to a fatal issue. When not rapidly fatal, the duration of this stage is from six to thirty-six hours. It is followed by the stage of reaction and inflammation. The character of the febrile movement depends upon the extent of the destruction of the tissues, and upon the concurrence of certain lesions of the thoracic and abdominal viscera. Inflammation of the duodenal glands, and the formation of ulcer with perforation, is not of infrequent occurrence during the second week after the accident. Peritonitis, pleuritis, or pneumonitis may add to the gravity of the prognosis. Laryngitis and bronchitis are apt to follow the efforts at inspiration in the presence of scalding steam.

Treatment.—The immediate indication is to relieve pain by the administration of morphia hypodermically, or some form of opium by the rectum or stomach. Stimulation with whisky or brandy by enema, or by the mouth, is also indicated to prevent collapse, or to modify the intensity of shock which is apt to follow a scald or burn. The use of both opium and alcohol should be made with a certain degree of caution, for there is danger from a too profound narcosis with the former, while alcohol in

excess will unnecessarily add to the fever of reaction, which always follows if the patient should rally from the shock.

The clothing should be carefully removed, and the burned surface shielded from the atmosphere by an immediate application of a mixture containing equal parts of linseed-oil and lime-water. If this preparation can not be obtained, a coating of ordinary white-lead, as mixed for use in painting dwellings, is an efficient protective when poured over the burn. Flour sprinkled over until all the excoriated surface is well hidden is a method of treatment which may be carried out in almost any emergency. Rubber-tissue protective laid over the raw surface, and cotton batting applied on top of this, is equally efficient. Lint dipped in 2-per-cent carbolyzed oil may be used directly on the wound. Any great degree of pressure should not be permitted upon the excoriated surfaces. In the not infrequent form of burn in which the back and posterior aspects of the extremities are chiefly involved, the prone position should be maintained.

When suppuration and sloughing commence, great cleanliness should be observed, to prevent the absorption of septic matter. The dressings should be changed as often as the thermometer indicates septicaemia, but not oftener. Absorbent cotton pellets moistened in 1 to 3,000 sublimate should be used in cleansing the burned surface. A mixture of vaseline (the white variety is preferable) and iodoform, in the proportion of 3 j of the former to 3 j of the latter, is a useful dressing in the stage of granulation. This should be applied on surgeon's lint, and covered over with rubber protective. It often becomes necessary to arrest exuberant granulations by the free use of lunar caustic, or the projecting buds may be clipped off with the scissors—a method objectionable, however, in the bleeding which always follows this practice. Compression by strips of adhesive (diachylon) plaster is a better method of repressing the overgrown granulation-tissue. When the destruction of integument has been so extensive that cicatrization can not be effected on account of the tension of the part involved, the transplantation of skin should be practiced. The various methods are *grafting*, *sliding*, or *transplantation in mass*.

Grafting may be done by clippings about one twentieth of an inch in diameter, and cut out so that only the epidermis and Malpighian layers are included. The epidermis is pinched up with a pair of mouse-toothed forceps, and clipped off close to the forceps with sharp curved scissors. A spot of the granulating surface free from pus is selected, and the graft laid on bottom-side down and pressed snugly into the granulating bed. A similar graft for every quarter-inch of surface will suffice. These should be left uncovered from one half to one hour. A layer of protective is then laid over the entire surface, and a light sublimate-gauze dressing applied, held on with a roller or adhesive strips. This dressing should remain unmolested for at least forty-eight hours, in order to give the grafts time to take hold, and, when the dressing is changed, great care should be taken to prevent their dislodgment. Water should not be used in the dressing. At the end of about the third day, if the graft has "taken," a bluish white spot will be seen, the color fading away gradu-

ally at the edges until it is merged in the general granulating mass. Grafts situated near the skin will unite and proliferate more rapidly and surely than those farther out in the wound.

When an extensive area is to be grafted over, the method of Thiersch should be employed. The granulating surface should be dry and thoroughly clean. With the patient anaesthetized, some spot of the body covering should be washed, shaved, and thoroughly disinfected. With a sharp razor, shave off in flakes or sheets the epidermal layer so thin that at all points it is clearly translucent—in fact, no thicker than the finest soft paper. Moistening the skin and instrument as the cutting is done will facilitate the lifting of a thinner section. These pieces are laid snugly upon the granulating surfaces until all are covered. They are held in position by adhesive strips and a moist aseptic dressing.

Dr. J. H. Girdner* has demonstrated that pieces of skin taken from a healthy man six hours after death by accident, "cut into a great many small pieces," and laid upon a healthy granulating surface, will become revitalized. The results of this demonstration are very valuable (Fig. 150).

Transplantations of skin in large pieces by entire removal, or with a pedicle left until the vascular supply is established between the granulating surface and the transplanted integument, may also be successfully accomplished. It is essential that the skin which is completely detached should be clipped or scraped on its under surface until only the Malpighian layer and epidermis are left. The presence of fat on the reticulated corium will prevent success. When sliding is attempted, it is essential that the pedicle should be of good width, and that the tension on it should not be great, so that the integrity of the blood-supply may not be interfered with, and sloughing ensue. Upon the face and neck, where the vascularity is so great, a smaller pedicle may be used, and greater tension employed than on other portions of the body.

When there is not sufficient integument immediately about a burn to supply the want, the flap may be secured from some other portion of the body. Thus in a case of extensive destruction of the integument on the front of the leg, I have succeeded in covering in the surface by turning a flap from the posterior aspect of the opposite leg, leaving a wide pedicle, and fastening the two members in an immovable position, so that the flap remained in its proper place and free from strain. After about ten days the pedicle may be divided. In the case of a boy who had been

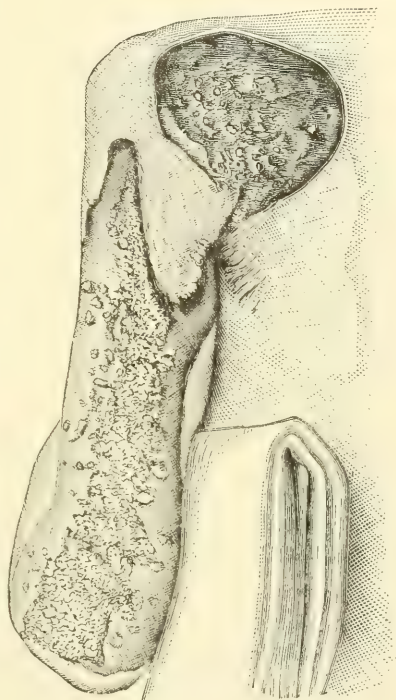


FIG. 150.

* "Medical Record," vol. xx, p. 119.

severely burned in the hand and forearm, and where the cicatricial contractions displaced the fingers, deformed the hand, and threatened amputation of the member by obstruction of the radial and ulnar, I did the following operation with success: All the cicatricial tissue about the wrist and arm was dissected off down to the tendons and bones, which were in good condition. Two parallel incisions, six or seven inches long and four inches apart, were then made from the ensiform cartilage down to the umbilicus, and the strip of skin dissected up in the middle and left attached at both ends. When the small amount of bleeding had been arrested, the hand was slid beneath this flap, the under surface of which was brought in contact with the raw surface, where the cicatricial tissue was removed from the arm and held in place by stitching the edges together with silk. Iodoform-sublimate dressing was applied, and the hand and arm held immovable by adhesive plaster. Fig. 151 shows the condition of the hand, and Fig. 152 the method of transplantation.

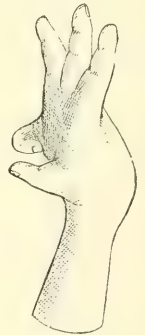

FIG. 151.

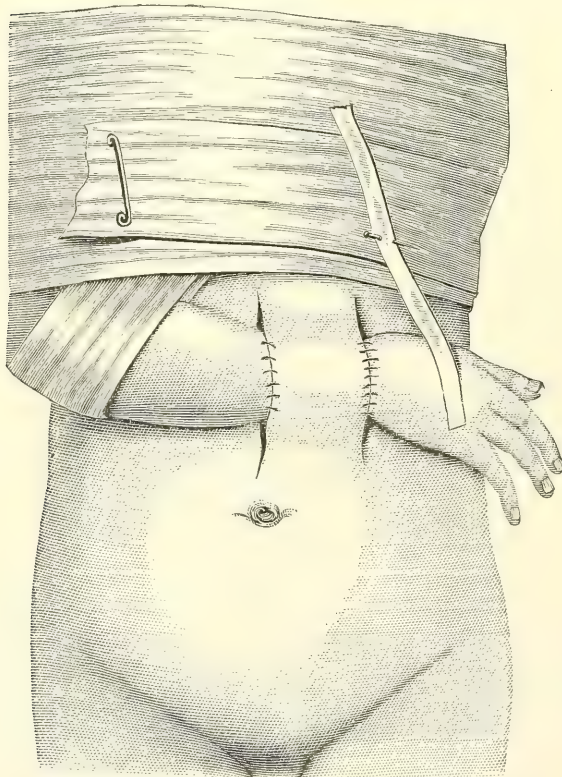


FIG. 152.—The author's case of transplantation from the abdomen to the arm.

On the tenth day the strip of skin was divided above and below, and the ribbon folded around the wrist and stitched in position. The operation succeeded, and amputation was avoided. A second similar operation was done to restore the integrity of the palm. In all cases of transplanting skin no more of the subcutaneous tissue should be lifted with the integument than is necessary for the vitality of the flap. In short flaps a very thin dissection should be effected; in longer pedicles a good deal of tissue should be left to insure the safety of the blood-vessels.

Transplanting in mass, in which the piece of integument, at least one inch in surface-measurement, is entirely severed from its original attachment, and laid upon the granulating surface, is not so successful as the preceding methods. The smaller grafts are much preferable. When this operation is done, the piece to be transferred should be trimmed or scraped so thin that nothing but the epidermis and Malpighian layer remains. Destruction of

tissue by *acids* or *alkalies* requires no special consideration beyond the adoption of measures to neutralize the excess of the agent in the part involved. The after-treatment does not differ from that of the granulating surfaces of burns and scalds from fire, boiling water, or steam.

Frost-Bite.—The effect of prolonged and extreme cold upon the animal tissues is to cause occlusion of the capillaries, loss of sensation, and death by gangrene. The *treatment* is to attempt a gradual restoration of the circulation by friction in a low temperature. A part of the body benumbed by cold should never be submitted suddenly to a high temperature, but should be bathed and rubbed in snow or cold water, the temperature of which is slowly elevated. When gangrene results, amputation is demanded after the line of demarkation is established.

Furuncle.—A boil is a circumscribed inflammation, commencing usually in the hair follicles and sebaceous glands, and extending to the subcutaneous tissues, in which it may at times originate. The chief cause is either a traumatic or idiopathic inflammation in the glandular apparatus of the skin, and the arrest of the nutrition of the part by obstruction of the capillaries by pressure from without or by embolism or thrombosis from within. The inflammation spreads to the surrounding tissues, and localized gangrene ensues. Boils occur very frequently during the history of certain diseases, as diabetes mellitus, tuberculosis, scrofula, derangements of nutrition, etc.

The diagnosis is not difficult, being chiefly between carbuncle and the localized necrosis in certain forms of syphilitic gumma of the skin. From carbuncle it may be differentiated by the more acute inflammatory process of the furuncle, the single point of suppuration, the well-defined limit of the redness, and the acute character of the pain. In carbuncle the inflammation extends more widely and deeper, the induration is greater, there are several points of suppuration, and the febrile symptoms more appreciable. The syphilitic lesions will be recognized from the history of the disease. The *treatment* looks to an early relief from tension in the integument, and the separation and discharge of the slough and pus. Incision should be performed at once. The judicious use of cocaine hypodermically will prevent pain, and much suffering will be avoided by prompt action. The application of cold or heat is at times useful. Poultices are almost universally employed to soften the skin and hasten the discharge of the dead tissue. It is a waste of time to wait for so slow a process. After incision a warm, moist sublimate flaxseed poultice or dressing should be applied, and continued until a cure is effected.

The constitutional treatment should be directed to the correction of any existing dyscrasia. The preparations of iron and mercury are, in my opinion, the best general remedies. Tonics, good food, regulation of the alimentary apparatus, and good hygiene, are essential. Sulphide of calcium, gr. $\frac{1}{10}$ to $\frac{1}{4}$, three or four times a day; arsenic, the iodides, cod-liver oil, with the hypophosphites of lime and soda, are among the remedies most recommended.

Carbuncle.—This disease—which, as Prof. A. R. Robinson * remarks, has been misnamed “*anthrax*”—is characterized by an inflammatory process of a low order, involving chiefly the skin and the connective tissues immediately beneath it, and in some instances extending into the deeper organs. Carbuncle is a disease of malnutrition. The process is akin to that of furuncle, though indicative of a more depraved condition of the tissues. The cause is capillary thrombosis or embolism and subsequent inflammation spreading from the necrotic focus. Gangrene always occurs, and the inflamed area breaks down in several places, giving discharge to pus usually in small quantity, as well as to dead tissue. It is apt to occur as a complication of the same diseases with which furuncles are seen—diabetes mellitus, tuberculosis, scrofula, etc. It is apt to occur in parts of the economy subjected to more than ordinary irritation, as the back of the neck, where the collar presses, and in the gluteal region.

The *symptoms* of this affection are a sense of malaise, loss of appetite, headache, fever, varying in intensity, which is followed by or accompanied with a deep-seated and severe pain in and about the local expression of the disease. The skin at this point becomes tense, injected, doughy to the touch, throbbing and painful; the epidermis becomes lifted at various spots in the inflamed area, vesicles form, localized gangrene occurs, and the dead matter sloughs away. Not infrequently the necrotic process rapidly extends through the areolar tissue beneath the skin some time before the integument breaks down. The extent of necrosis varies under different conditions, and may be general or limited. The constitutional symptoms are determined by the amount of septic absorption and the degree of pain experienced.

The process of repair is by granulation, the development of an embryonic tissue which advances from the sides and bottom of the cavity as the slough is carried away. As to the length of time carbuncle may last, nothing positive can be stated. Usually from three to seven weeks; at times, when the process is subacute, several months.

The *prognosis* depends upon the condition of the patient, the age, the location and extent of the lesion, and the ability of the capillaries and lymphatics to resist septic absorption. Occurring in diabetes or any dangerous malady, it hastens a fatal issue. Situated upon the face, the gravity of the prognosis is increased. This is in great part due to the intense pain which follows an invasion of that part of the body in which the trifacial nerve is distributed. When located on the thorax, the pleura may become involved, thereby causing a grave complication.

The *treatment* should look to the immediate improvement of the patient's vitality by all available means. The local treatment should be directed to the relief of tension, the arrest of the invasion, and the discharge of septic matter.

The only possible objection to early and free incision is hæmorrhage, and the operator has only to decide between the danger of sepsis from delayed drainage on the one hand, and that of loss of blood on the other. To my mind, the fear of hæmorrhage is unfounded, and should not cause a delay in making the incisions. The patient should be anæsthetized,

* “Manual of Dermatology,” 1884.

and the indurated mass incised well down to the bottom in several directions. Crucial cuts, or several parallel incisions, or lines radiating from the center, may be made as the location and size of the carbuncle may indicate. If undermining has been extensive, drainage-tubes should be employed. Hæmorrhage may be controlled by packing with sublimate gauze. The after-treatment should be hot or warm, sublimate-gauze dressings applied loosely, and covered in with protective or oil-silk. Poultices, if employed, should be made with sublimate solution, as heretofore directed.

Ulcers.—An ulcer is the result of molecular death in the integument or mucous membrane, and the underlying areolar or submucous tissue. The process of necrobiosis may at times extend below the deep fascia. Of whatever variety, an ulcer is caused by a failure of nutrition in the part affected. The arrest of nutrition may be local, as in the ulcer of chancroid or with a varicose condition of the veins, or constitutional, as in the late manifestations of syphilis, in scorbutus, etc. Occurring with a dyscrasia, ulcers are even then more apt to occur in parts of the body subjected to abnormal interference with the circulation.

Specific ulcers will be considered with the diseases of which they form a part. *Ulcers* may be divided into two clinical groups—the *active* and *indolent*. In one, the material for repair is in excess; in the other, it is deficient. The most frequent seat of ulcer is upon the anterior aspect of the tibia at its middle and lower portions. They occur almost always in the aged, and chiefly among the poorly fed and laboring classes, where the erect posture is of necessity maintained for many successive hours. Varicosities of the veins of the lower extremities must be put down as the most common non-specific cause of ulcers.

The *treatment* of ulcers must be directed to the cause of the tissue destruction. In varicosities the integrity of the circulation should be restored by supporting the vessels by mechanical means, or relieving the overpressure by position. For the former the elastic stocking, properly adjusted, is invaluable. Martin's elastic bandage is an excellent apparatus, but requires considerable care in its even and skillful application. When neither of these methods is available, pressure may be successfully employed by means of flannel or muslin bandages. An elevated position of the foot and leg should be maintained in all ulcers of the lower extremities.

An *indolent* ulcer demands stimulation. This may be effected by the oakum-dressing. Soft, clean oakum should be well soaked in 1 to 3,000 sublimate, squeezed out, laid over the ulcer, and held well in place by a roller. It should be changed every three or four days. Sublimate gauze is also an efficient stimulating dress-

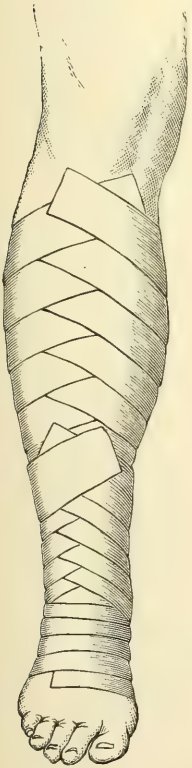


FIG. 153.

ing. Either of these methods should take the place of the old practice of burning such ulcers with escharotics. Supporting the edges of the sore with well-adjusted strips of diachylon plaster is also a commendable practice. The strips should be cut about three fourths of an inch wide, and crossed in a spiral manner (Fig. 153).

Irritable ulcers require rest and soothing applications. Iodoform-vaseline ointment (3j to ℥j) will be found of value. It should be applied on soft cotton-flannel or lint, and not strapped down tightly. The constitutional treatment of all patients suffering from ulcers is of first importance.

Gangrene is death of a part of the body from the gradual or sudden arrest of its nutrition. It is usually applied to the process of mortification in the softer structures. The analogous condition of bone is called *necrosis*. Animal tissues have two modes of dying—the one is *molecular*, or death by granular metamorphosis, in which no trace of the anatomical or histological properties of the tissues remains; the other is death *in bulk*, in which, although the tissues deprived of life undergo rapid decomposition and ultimate disintegration, they retain for a time something of their original form. It is to denote this last variety of tissue-death that the term *gangrene* is employed.

There are three varieties—namely, the *acute*, or *moist*; the *chronic*, *senile*, or *dry*; and the *contagious*, *phagedenic*, or *hospital* gangrene.

Acute Gangrene.—The chief cause of moist gangrene is the sudden obstruction of the afferent or efferent vessels of a part. Whether the artery is alone occluded, as by an embolus, the ligature, or an accidental solution of its continuity; or whether the venous current is arrested while the artery is permeable; or whether the arrest in both systems is simultaneous, as by the constriction of a finger with a ring, or in the case of a strangulated hernia—the part beyond the lesion is charged with blood which, arrested in its flow, loses its vitality and takes an early part in the work of decomposition which ensues.

When an *artery* is obliterated, the vitality of the tissues on the peripheral side of the occlusion depends upon the integrity of the collateral circulation. If the occlusion is gradual, the enlargement of the collateral branches is usually sufficient to carry the necessary supply of blood. There is scarcely a point in the arterial system where a collateral route may not be established, provided the process of obliteration is not too sudden, and the blood has not, by reason of constitutional disturbance, been deprived of its nutritive properties. When these conditions do not prevail, mortification ensues with a rapidity proportionate to the partial or total arrest of nutrition. Pallor is the immediate and earliest symptom of arterial obstruction, followed by coldness of the skin, and pain, which is usually not acute. Beginning in the parts farthest removed from the heart, the phenomena of death extend toward the center until the border-line is reached between the living and dying tissues. Congestion and swelling are not marked features of arterial gangrene. The normal contractility of the tissues, an elevated position, and the influence of the return current in veins with which those of the

part involved communicate, tend to empty the vessels beyond the seat of obstruction. Of necessity, however, a considerable quantity of blood remains, and when its flow is arrested its function is lost, and its elements join in the general decomposition which ensues. In the putrefactive process, gases, notably sulphuretted hydrogen and those resulting from decomposition of the fatty tissue, are evolved, and the coloring-matter of the blood is liberated. Myosin, the albuminous principle of muscle, coagulates, giving a temporary sense of rigidity, and the serum which remained in the vessels undergoes transudation, and is generally distributed among the tissues. Cutaneous sensibility is soon lost, and the momentary pallor gives way to a grayish hue, which deepens into a greenish-black color. Though not so marked as in the condition resulting from venous occlusion, the skin and subcutaneous tissues become infiltrated with fluid and gases, giving a doughy feel upon pressure, and at times the peculiar crackling of emphysema. Serum and hydrogen, in the effort to escape, may at various points be caught under the impervious epidermis, which is lifted up into blisters. In resisting gangrene, certain tissues retain their anatomical features longer than others. Bone and tendon are slow to disappear, and at times the arteries will resist destructive change, when the tissues through which they pass have been entirely destroyed.

In a case which recently came under my observation, through the courtesy of Prof. Fluhrer, at Mount Sinai Hospital, in which gangrene was induced by a plaster-of-Paris dressing (applied in another institution for supposed fracture of the humerus), mortification was present first in the thumb and the tip of the index-finger, gradually involving the other fingers and the back of the hand to the carpus, where the process seemed arrested in an apparent line of demarkation in the integument. The gangrene continued, however, beneath the skin, involving the extensor muscles, which, after amputation above the elbow, were found to have entirely disappeared, while much of the integument over them retained its vitality. When once inaugurated, mortification extends to a point where nutritive changes in the tissues are sufficiently active to resist death. The irritation of the dead tissues produces inflammation and the formation of a zone of embryonic tissue between the living and dead structures. The line between this embryonic zone and the blackened slough is called the *line of demarkation*.

The line of demarkation is, as a rule, irregular in extent. When a part has been constricted until death ensues, the line of separation may be a well-defined circumference; but in arterial occlusion this is a rare exception.

Following the phenomena above detailed, rapid putrefactive changes occur; the soft parts drop away in offensive sloughs, leaving the bone projecting from the stump of this *natural amputation*.

The symptoms of gangrene from *venous* obstruction differ in some essential features from mortification after *arterial* occlusion.

Engorgement is more marked, since the cardiac and arterial forces are at work in packing the tissues beyond the obstruction with blood. The

skin is of a purplish hue from the start, pain is intense, and the swelling great, and, until coagulation is accomplished, there is a sense of throbbing in the affected part. There is at first an elevation of temperature, which, however, is of short duration. Blisters are more numerous, and putrefaction occurs more rapidly.

Gangrene from combined arterial and venous occlusion has its type in a strangulated hernia, or in mortification of a finger which has been constricted by a ring. In this variety, arrest of the circulation and coagulation of the blood are more abrupt. The remaining features of this form of mortification do not differ materially from those heretofore described.

Treatment of Moist Gangrene.—When an artery is obstructed, the first indication is to remove the obstruction. Failing in this, to promote the establishment of a collateral circulation, and to maintain the temperature of the part affected. The position of the limb should be such that pressure upon the structures through which the anastomotic branches run should be avoided. Cotton-batting should be carefully wrapped about the part to the thickness of several inches, and oil-silk or rubber-tissue protective wrapped around this. No pressure by bandages should be employed. The application of hot water, directly or by bottles, is to be deprecated, for heat is now known to produce capillary contraction. The extremity may be slightly lowered, in order to invite the flow of blood, although care should be taken to prevent obstruction of the veins.

While these *local* measures are being adopted, certain *constitutional* remedies may be indicated. These relate primarily to cardiac stimulation, opium to relieve pain and palliate shock, and to an early improvement in the nutritive quality of the blood; the administration of alcohol and beef-juice, and the careful combination of those articles of food which are acceptable to the patient, and are known to be rich in nitrogen. Any intercurrent disease or complication will indicate a modification of the treatment to suit the emergency. As death progresses and the sloughing begins, all structures which can be removed easily and without pain should be cut away with dressing forceps and scissors. Iodoform, freely sprinkled over the sloughs, will prove a good deodorizer, or the dead part may be kept wrapped in sublimate gauze, soaked in 1 to 500 solution, and kept moist by protective. When the line of demarkation is formed, sublimate gauze (1 to 1,000) may be laid around this locality, to guard against septic absorption.

Hæmorrhage is rare in this variety of gangrene, yet when it does occur it demands the ligature or compression.

The treatment of gangrene where the vein alone is obstructed, in which, as has been stated, the condition of engorgement is extreme, demands the elevation of the part in order to facilitate the escape of blood through the venous channels. The tension of the part may at times demand incisions through the deep fascia. The same precautions as to temperature must be taken here. The constitutional treatment will be less stimulating, yet supporting, and the local management of the dead part will be the same as given.

When all the vessels are subjected to pressure, it is essential to relieve the constriction as early as possible. However, the vitality of an organ seemingly dead should not be despaired of, since restoration of function after prolonged strangulation is occasionally witnessed. When, as in phlegmonous or other inflammation, the tension is so extreme that gangrene is threatened by pressure of the exudation upon the capillaries or larger vessels, free incisions should be made, parallel with the general direction of the vessels, and of sufficient depth and number to relieve the tension. When, as in threatened gangrene of a finger, the swelling is severe, increasing, as it does, the tension of the organ and its own destruction, incisions are also demanded, and may prevent mortification before the constricting body is removed.

Chronic, Senile, or Dry Gangrene.—Dry gangrene may occur in any period of life. Although children and adults are occasionally attacked, it is in the vast majority of cases a disease of the aged; hence it is called *senile* gangrene.

Calcareous degeneration of the arteries, which is given as a cause of senile gangrene, is of itself a result of general impairment of nutrition; and it is to this failure of the heart to force the proper quantity and quality of blood to the tissues that we must look for the cause of this disease.

With a circulating fluid so deficient in nutrition, and a heart so crippled in its action that its function is illy performed, it is not difficult to understand that the pressure of a shoe, a contusion of the foot, or the lodgment of atheromatous or calcareous particles in the terminal arterioles or capillaries, would precipitate a morbid process, scarcely awaiting even an accident for its inauguration.

Symptoms.—In many cases of dry gangrene there is no history of an injury. Symptoms of constitutional debility from general impairment of nutrition usually precede the local expression of the disease. The lower extremities are most frequently affected. The patient suffers at times from coldness of the hands and feet. Shooting pains are not infrequently felt, and cramps occur in the muscles of the feet and calf of the leg. In exceptional cases there are none of the above premonitory symptoms, the first indication being the appearance of a brown or black discoloration on the foot or toe, or an insignificant excoriation may be the starting-point of the morbid process.

From this the disease travels in the direction of the heart with varying rapidity. If the condition of anæmia is extreme, there will be no inflammatory discoloration in front of the advancing line of mortification, the skin changing from its normal pale color into the black, dead hue of the mummified part. The putrescent odor of wet gangrene is absent, and, instead of the swollen, doughy appearance of acute mortification, the part involved becomes hard and shriveled. The march of the disease is comparatively slow, and not infrequently death from exhaustion ensues before the line of demarkation is formed. In exceptional instances the disease confines itself to the toes, or anterior part of the foot.

Treatment.—The part affected should at once be enveloped in cotton-

batting and oil-silk or protective, and placed in a position consistent with the comfort of the patient. No operative procedure is justifiable until a well-defined line of demarkation is established, unless septic absorption occurs to threaten the safety of the patient. The most important treatment is directed to the nutrition of the individual and the increased vigor of the heart. Opium, to relieve pain, is as much of a necessity as stimulants and food.

Contagious, Phagedenic, or Hospital Gangrene.—Although this disease occurs most frequently in hospitals crowded with wounded, where ventilation and drainage are deficient, instances are recorded of outbreaks where the most careful sanitary regulations had been enforced. No season of the year offers an immunity from its ravages, although a warm, moist atmosphere is most favorable to its development. It is intensely contagious. The inoculation may be effected not only through instruments, sponges, dressings, or the hands of the attendants, but through the medium of the atmosphere. As to its infectious character there exists a difference of opinion. It is held by observers equally competent and experienced that an abrasion is essential to the introduction of the disease, and, on the other hand, that it may result from inhalation of the germs, the vesicle and ulcer appearing as a local expression of the systemic infection. The epidemics of phagedenic gangrene may vary in severity. Appearing in a malignant form, it suffers no wound to escape, while less frequently only isolated cases may occur. While a healthy condition of the individual will favor a recovery from the effects of this malady, it affords no exemption from its inoculation upon the wounded surface. It may be ingrafted upon any form of abrasion, at any stage in the process of repair.

Symptoms.—The effects of this disease may be studied as *local* and *constitutional*.

When a recent puncture, or fresh and minute abrasion, is attacked, the first symptoms are the formation of a vesicle and the appearance of a limited zone of redness at its base. The rupture of the vesicle gives escape to a thin, serous fluid, and the excoriated base becomes covered with a grayish mold. The infected part becomes painful and swollen, and, if the disease is not immediately arrested in its progress, a rapid dissolution of the tissues ensues. The skin breaks down, leaving precipitous margins to the diseased area. The underlying tissues are destroyed more rapidly than the integument, which frequently becomes undermined to such an extent that, if repeated careful explorations are not made, the true condition of the part may escape observation.

If at the time of inoculation the wound is covered with a granulating surface, it will be observed that at various points the granulation-tissue loses its florid color, becomes pale, and this pallor is immediately followed by the appearance of a grayish-black mold, which rapidly spreads over the entire wound. The normal secretion gives way to a dirty, watery discharge. The odor emanating from the gangrenous sore is exceedingly offensive and peculiar.

The *constitutional* symptoms are those of acute septicæmia, and are

wholly dependent upon the absorption of poisonous material at the seat of the disease—headache, pain in the part affected, irregular febrile movement, hectic suffusion, followed by cold perspiration, rapid and weak pulse, and, as the malady progresses, great prostration, diarrhœa, delirium, and death, which results usually in from one to three weeks.

Prognosis.—Once the dread and scourge of civil as well as military hospitals, contagious gangrene, in the achievement of modern surgery, has taken its place as a complication of a wound annoying and painful rather than dangerous to the life of the individual. A fatal termination may ensue when the wound is contiguous to important vessels, where hæmorrhage may occur, either from death of the tissues from gangrene, or their destruction by caustics in the effort to arrest the disease. The prognosis may also be grave when, from the nature of the injury, the deeper portions of the slough can not be reached, and drainage secured. Under such conditions death is apt to ensue from septic absorption.

Treatment.—In the perfect application of aseptic methods it is not possible for hospital gangrene to occur. The prophylactic treatment is the investment of all wounds with sublimate or other aseptic gauze dressings. As soon as a wound is attacked with gangrene it should be mopped with pure bromine or undiluted nitric acid. Care should be taken not to allow the escharotic to run over and burn the uninvaded skin. If the neighboring integument is protected with vaseline this accident may be prevented. If the disease has been in progress for one or two days, and the wound is covered in with the pulpy mold peculiar to this malady, the entire wound should be scraped out with a Volkmann's spoon, and the acid or bromine thoroughly applied. When the skin has been undermined, or the deeper tissues, as the muscles, involved, free incisions should be made in order to expose every portion of the diseased tissue to the action of the caustic. After this a plug of iodoform gauze should be laid in the bottom of the wound, and a pile of loose sublimate gauze (1 to 1,000) added to this. Where a penetrating wound, as a bullet or puncture, has become infected under conditions that will not permit incision, the entire track of wounded tissue must be subjected to the process of cauterization and disinfection. In order to accomplish this, the opening or openings of the wound may be enlarged, the cavity scraped thoroughly with sponges fastened to holders, and then the entire track inundated with bromine. Ether should be administered to relieve the pain of the applications, and opium afterward.

The constitutional treatment looks to the nourishment of the patient. Stimulants are indicated, and, in order to facilitate prompt assimilation, peptonized foods are of great value. In this, as in other diseases where it is essential to increase the general nutrition by artificial means, I have found the following method of administration invaluable:

On one day, three times in twenty-four hours, one tablespoonful of a fifty-per-cent. emulsion of cod-liver oil, the dose to contain one grain each of hypophosphite of lime and soda. On the second day, thirty

to forty minims of the elixir of iron, quinine, and strychnine; and on the third day, one tablespoonful of Wyeth's beef, iron, and wine. Alternating in this manner, these remedies are tolerated for a longer time and produce a better result than when one article is administered day after day.

The sanitary management of a case is of the greatest importance. Isolation of the cases attacked, and the immediate removal of other patients from the same ward, tent, or locality, is urgent. All instruments should be disinfected in 10-per-cent carbolic-acid solution, or boiled for one hour, and all sponges, dressings, etc., instantly burned. The floor, walls, and ceiling of a hospital-ward in which a case of phagedenic gangrene has occurred should be washed and irrigated with 1 to 1,000 sublimate solution, and the mattresses burned.

CHAPTER VIII.

AMPUTATIONS.

AN amputation is the complete separation of any projecting organ or member from the body. While the term may be applied to operations in which the breast, penis, scrotum, cervix uteri, etc., are cut away, by long usage and common consent it is now restricted to removal of the extremities or their subdivisions.

An amputation may be *accidental*, as when a limb is torn, cut, or crushed off by machinery; *natural*, when, as in senile gangrene from gradual failure of the heart, or pathological changes in the arteries, the dead portion is separated at the line of demarkation; or *surgical*, when scientifically performed.

When in an amputation the line of section is through the substance of the bone, the operation is said to be in *continuity*, and when through an articulation, in *contiguity*. The removal of a part which is useless or deformed, the presence of which, however, does not threaten the life of the individual, is called an amputation of *expediency*; under more urgent conditions, the operation is one of *necessity*. Amputations of necessity are further subdivided into those after *accident* and those after *disease*.

In amputations after accident, the period in which the operation may be performed is divided into the *immediate*, *primary*, and *secondary*. An *immediate* amputation is done during the prevalence of shock, and usually within from two to six hours after the receipt of the injury necessitating the operation; *primary*, after reaction from shock, and before inflammation is established—usually within twenty-four hours after the injury; *secondary*, when performed after this limit, and during the prevalence of inflammation.

The danger of death after amputation depends chiefly upon the *character* of the injury, and the *location* of the line of section. The prognosis becomes grave in proportion to the exhaustion of the patient as a result of hæmorrhage, shock, sepsis, or of any dyscrasia or intercurrent disease.

As to the *line of section*, there are practically no exceptions to the law that the rate of mortality is proportionate to the diameter of the part divided and the proximity of the section to the trunk. Thus, amputations of the lower extremity are more fatal than those of the upper, those of the hip more fatal than through the middle and lower third or through the leg, while the same comparison holds good from the shoulder out.

As to the *age* of the patient, it may be said that the death-rate gradually increases with each decade of life.

Operations of *expediency*, when properly performed, may be considered as practically free from danger, for the reasons that the general condition of the patient is good, and the section through clean and healthy tissues. Amputations after *non-malignant disease*, such as destructive arthritis and osteitis, are comparatively free from danger, provided that general sepsis and consequent exhaustion have not occurred prior to the operation. Amputations necessitated by malignant neoplasms are especially dangerous only in proportion to the degree of malignancy in the tumor, together with the general deterioration of the tissues as a result of the prevailing cachexia.

Amputations after accident are most fatal, and the statistics show that primary operations are, in general, more dangerous than those done in the secondary period.

Lastly, the value of the *bloodless* operation, together with the safety from inflammation and sepsis, which a thorough knowledge and practice of the *antiseptic method* guarantees, can not be overestimated in diminishing the death-rate after amputation. The employment of Es-march's bandage, the deligation of the vessels, the use of sublimate irrigation, and the permanent antiseptic dressings, have been heretofore described.

Amputations are much less frequent now than formerly, and there is little doubt that, in the present rapid advance in the science of surgery, and the greater perfection in its art, the time is not far removed when amputations for other cause than gangrene will be comparatively rare. To the consummation of this hope the education of the laity becomes the first duty of the practitioner. Very few deformities would lead to the necessity of amputation if in their incipiency the services of a skillful surgeon were obtained. And this is equally true of those lesions of the joints and bones for which the necessity of amputation would be exceptional if, at the earliest symptoms of disease, the proper treatment were instituted. Even when, from neglect, extensive necrosis or destructive arthritis shall have occurred, exsections of the diseased tissues should always be preferred to amputation, notwithstanding the shortening which may result, for a stiff joint and a short limb, capable of even limited motion and body support or function, is far better than the most perfect prothetic apparatus.

Malignant or non-malignant neoplasms often unnecessarily lead to amputation when an early and wide excision of the growth would in great probability have arrested the disease and saved the limb. In cases even of doubtful diagnosis, in the earlier days of the appearance of the tumor, the benefit of the doubt should be given to the ultimate safety of the part, and the knife freely used.

As to the propriety of performing an immediate amputation after injury, it is exceedingly questionable. The conditions which would justify this practice will rarely prevail. Even primary operations should be exceptional in this age when the value of drainage is so fully appreciated,

and the danger of sepsis diminished by the faithful employment of that cleanliness which is found in the antiseptic method.

In extensive lacerations of the soft parts and fracture of bone, the indications in treatment entitled to the first consideration may be stated as being: arrest of hæmorrhage by the catgut ligature or direct pressure, through drainage, iodoform and sublimate dressings, fixation of the part—usually in an elevated swing (Figs. 7, 114, 164)—with constant irrigation as a last resort. If, despite all these precautions, septicæmia should occur, or gangrene result, amputation is necessitated.

The first general law in performing an amputation is that no more of the member should be cut away than is absolutely essential to the safety of the patient. Any exception to this rule will be given along with the special amputation to which it may apply.

While it is always desirable to make an amputation wound through healthy tissues, this should not be done at the expense of the part involved, for flaps made through inflamed tissues heal readily enough, and offer no element of danger to the life of the patient when properly drained.

Method of Operating.—In making an amputation, no matter what shape the incisions may take, the point of first importance is, that the soft parts which are to form the covering or hood for the bone shall be long enough to be free from tension after the sutures are adjusted and the dressing completed. It is always wiser to err on the safe side, and make the flaps a little too long than too short, for it is a simple matter to trim them down to the proper length. In doing this, some allowance must always be made for the additional retraction which occurs after the tourniquet is removed and consciousness is restored.

The direction of the line of incision, and the shape of the cuff or flaps, will depend in part upon the shape of the limb at the point of section, as well as the condition of the soft tissues from which the covering is to be made.

While the rule just given—namely, to have plenty of flap—is essential, it is scarcely of less importance to guard against all interference with the nutrition of the integument which covers in the stump. To this end rough handling, and the employment of strong and irritating solutions, should be avoided. In general, that flap will unite most readily, and prove most satisfactory, in the formation of which the normal relation of the skin to the subcutaneous soft tissues is least disturbed.

It is always preferable to divide the skin, muscles, vessels, and other soft tissues squarely across, and not obliquely, as must of necessity be done in forming flaps by transfixion. The *solid-flap* method is applicable to most amputations in patients of slight muscular development, and with little or no subcutaneous areolar tissue, for a closely dissected skin-flap in this class of cases is objectionable, on account of the danger of sloughing. When the soft tissues at the line of section are very thick, and when the integument is well guarded by a fair quantity of underlying fat, the solid flap will be found objectionable, and flaps composed of skin and the subcutaneous tissues, down to the deep fascia, prefer-

able. The circular *skin-flap*, or some modification of this method, will be found, in general, most useful and satisfactory.

The methods of amputating an extremity may therefore be: First, *solid flap*, composed of all the soft tissues lifted from the periosteum; second, *skin-flap*, composed of the integument and the subcutaneous tissue, down to the deep fascia; third, *mixed flap*, composed of skin on one side, and of all the soft tissues on the other.

Flaps composed of the integument, together with all the underlying soft tissues, may be made by the circular method, forming a single cuff, or by the double-beveled flap, made by transfixion and cutting from within out, or by cutting directly down from the surface.

Circular Solid Flap, with Perpendicular Slit—First Method.—Supposing that the section is through the right humerus, at the junction of the middle and lower thirds, proceed as follows: Place the patient so that the member to be removed projects well over the edge of the table. Envelop the rest of the body with necessary wraps, and cover all in with rubber-cloth, so arranged that the irrigating fluid will not reach any portion but the arm. If folded properly into a trough-shape, the solution will be conducted into a vessel beside the table. The entire hand and arm should be washed with soap and water, cleanly shaved for six inches above and below the line of section, and in succession washed with sulphuric ether and a solution of corrosive sublimate (1 to 3,000). If any inflamed or suppurating surfaces are exposed, close to the line of amputation, these should be irrigated with sublimate, and thoroughly scraped out and again irrigated, after the Esmarch bandage has been applied. Towels wet in warm (1 to 3,000) sublimate solution are now wrapped about the hand, forearm, and arm, the extremity elevated, in order to facilitate gravitation of blood toward the center, and the Esmarch bandage tightly applied, from the finger-tips to the axilla. As soon as the constricting band is secured at or close to the axilla, the bandage beyond is removed, and all exposed parts not in the field of operation covered with fresh, warm sublimate towels. The assignment of positions about the table are shown in Fig. 154. The *operator* stands so that the non-preferred hand (usually the left) grasps the member between the line of section and the trunk, and thus steadying the tissues, the instruments are used by the right hand. The *first* assistant stands where he can most easily reach the wound, for purposes of sponging, retracting flaps, etc.; the *second* is placed directly between the operator and the instrument-trays; the *third* attends to the anæsthetic, holding the cone so that the expired air and ether vapor will not annoy the operator; the *fourth* holds the member to be removed, grasping the elbow with his left hand, and the wrist and forearm with the right; the *fifth* attends to the irrigator; the *sixth* and *seventh* are intrusted with the sponges, one of whom holds in one hand a basin of freshly squeezed out sponges, and in the other a second basin for those which have become soiled or bloody. Both should be within easy reach of the first assistant. The duty of the seventh assistant is chiefly to rinse the sponges, procure fresh towels, etc. When possible, it is always convenient to have two extra orderlies or

nurses—one for waiting upon the anæsthetizer, and the other for purposes of general utility.

Operation—First Method.—With the left hand slide the skin toward the shoulder, and at a point sufficiently below the line of section through

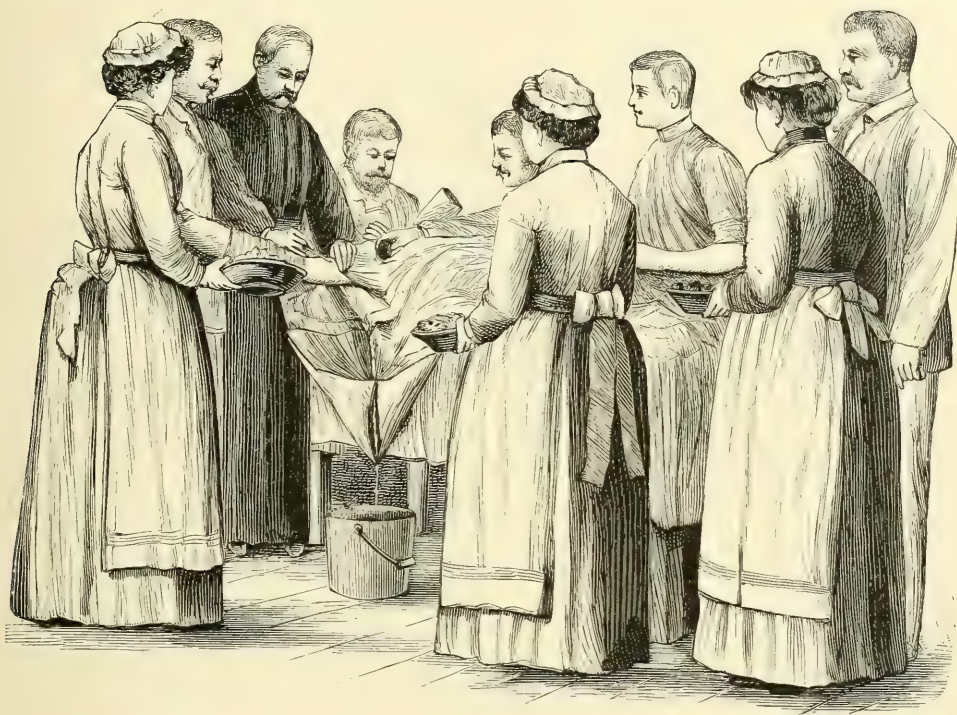

FIG. 154.

the bone to afford ample covering (something more than one half the diameter of the limb, measured where the saw is to be applied), make a circular cut around the member, dividing the skin and subcutaneous fat down to the deep fascia (Fig. 155). The upper margin of this wound is retracted toward the body as far as possible, and, at this line of retraction,

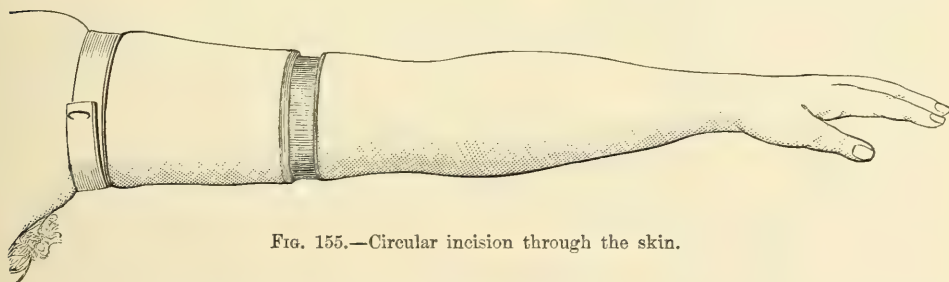


FIG. 155.—Circular incision through the skin.

with the same knife (a good scalpel is preferable) cut all the remaining soft tissues squarely down to the periosteum (Fig. 156). An incision is next made, parallel with the axis of the humerus, on the outer (or non-vascular) side of the arm, dividing everything to the periosteum, and extending up to the point where the bone is to be sawn through (Fig.

157). With a dry dissector (the handle of the scalpel will usually suffice)—only using a sharp instrument where necessary—lift the tissues closely

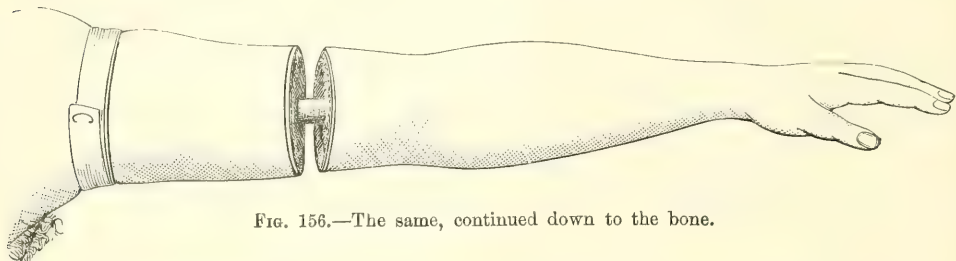


FIG. 156.—The same, continued down to the bone.

from the periosteum until the solid cuff can be folded back (without over-traction or bruising) sufficiently to expose the bone at the point of

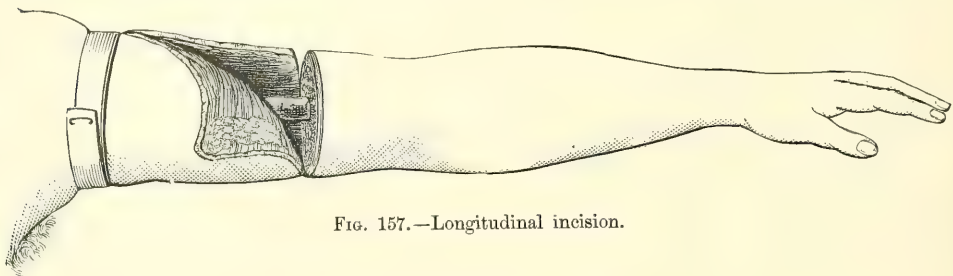


FIG. 157.—Longitudinal incision.

section. A towel moistened in 1 to 3,000 sublimate (or a split retractor) is now wrapped about the cuff or flap and the bone, so that the tissues

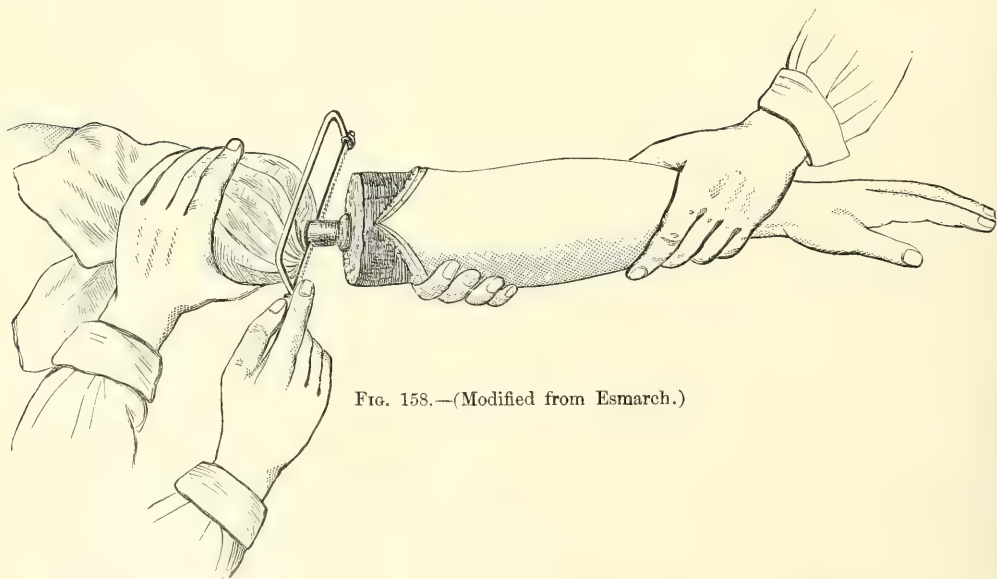


FIG. 158.—(Modified from Esmarch.)

which compose the flap may not be bruised or torn by the saw, and at the same time be protected from having the bone-dust scattered over the cut surface (Fig. 158).

In applying the saw, it is best to place the center of this instrument against the bone close up to the retractor, always holding its blade in such relation to the bone that the sawn surface will be perpendicular to the axis of the bone. A few short strokes will suffice to cut a trench or hold for the saw, which may then be more rapidly used. The operator steadies the member with his left hand on the central side of the wound, while the assistant holds the extremity. As the section is about being completed, he is directed to cease all traction, simply supporting the weight of the limb, and thus splintering may be avoided. The last few strokes of the saw should be lightly and carefully made, to avoid the same accident. The retractor is allowed to remain after the bone is divided and the amputated part removed, and until, with a bone-cutter or cartilage-knife, the circumference of the cut surface is smoothed and rounded off. In doing this, the force applied should always be toward the center of the bone, to prevent stripping up the periosteum or splintering.

The practice of dissecting a periosteal cuff, at one time recommended for the purpose of covering over the end of the bone, is now justly abandoned. While it succeeded in some instances, in many it gave rise to great annoyance, necessitating a second operation on account of exostosis or necrosis. The retractor is now removed, the stump irrigated, and the surface then thoroughly dried with sponges, so that the vessels may be secured. The larger arteries and veins may be readily found, and the ends seized with the forceps. All the tissues should be carefully stripped from these by a blunt instrument (grooved director), and, when the catgut is thus applied, the operator is sure that no nerve-tissue is caught along with the vessel. For the larger vessels the double or friction loop (Fig. 113) should be employed; the single knot will suffice for the smaller. When ligatures have been applied to all the vessels which can be recognized by the eye, other "bleeding points" may be discovered by grasping the limb a few inches above the line of section and then forcing out the small quantity of blood which remains after Esmarch's bandage. As it oozes out over the cut surface, its point of exit may be caught up by the broad-jawed forceps, and in doing this it is usually necessary to pick up a small bit of whatever tissue may be immediately about the vessel. In tying a catgut thread around these vessels, the loop should be tightened upon the jaws of the instrument on the slope nearest the point, for as it is further tightened it grasps the metal closely and slides over the end, including no tissue but that already in the grasp of the forceps. Having proceeded thus far, the stump being elevated, the wound should be filled with clean warm sponges, covered with sublimate towels, and firmly compressed by the operator while the assistant removes the tourniquet. After waiting two or three minutes for the vessels to fill, one by one the sponges are carefully removed, and any bleeding points caught with the forceps. When these shall have been tied, the wound should again be flooded with warm 1 to 3,000 sublimate, packed with sponges well squeezed out, the whole covered in with sublimate towels, and bimanual compression employed for five minutes, when it will be seen that all bleeding has practically

ceased. The general oozing, especially that from the end of the bone, may be controlled by pressure and position after the sutures are applied.

In sewing up the cuff, alternate deep and superficial sutures should be employed; the former, about half an inch apart, should enter the skin from one half to three fourths of an inch from the edge of the wound, pass about the same depth through all the tissues, and emerge at the same distance from the wound on the opposite side. The intervening row should be half way between the deeper sutures, and should be introduced to a depth of one fourth of an inch. In tying the sutures the double or friction knot should be employed for the first loop, for this holds and keeps the edges from separating while the second knot is being tied. The knots should be kept to one side of the line of apposition. A considerable degree of care is essential in bringing the edges nicely and accurately in apposition, for if the skin is infolded and the epidermal surfaces brought in contact, bad union will result, and the same is true if any of the subcutaneous tissues project between the edges. As the threads are being tightened, infolding may be obviated by lifting the edges with a grooved director, while the same instrument may be employed to push any projecting fat or other tissues back under the skin. In tying the knots, the degree of traction should just be sufficient to bring the plane surfaces of the wound together without wrinkling. The drainage-tubes should be inserted as the wound is being closed, and should be numerous enough to drain the cuff at all points. In clean amputations Neuber's bone-drains should always be used. In cutting through inflamed or infiltrated tissues, the rubber tubes are safer. If (as is preferable) the stump is kept elevated after the operation, it will be necessary to bring at least one of the tubes out at the upper end of the longitudinal incision, while another may project at the tip of the stump. No matter what style of flap is used, the tubes should always lead from the deepest portion of the wound, and have exit at such declination that the free outflow of all fluids will take place into the dressings. A safety-pin should be passed through one side of the tube to prevent its being pressed into the wound by the bandaging, or a suture may serve to hold it in position. The nozzle of the irrigator should now be introduced into one of the tubes and the cuff flooded until the water runs out clear and until the entire flap has been well distended. The excess of the solution is squeezed out, a strip of iodoformized gauze is wound around the tubes (not obstructing their caliber), and carried along the line of approximation, extending about three fourths of an inch on either side. Or a narrow piece of disinfected protective may be substituted as a covering for the line of sutures. The stump is now wiped off with sponges and immediately enveloped with sublimate gauze to the thickness of about one inch. This should be applied in layers, starting from well above the end of the stump, by carrying a layer around the limb, and following this with a second, which overlaps the first about two inches, and so on until the last layer projects well beyond the end of the stump. Over the end a large, thick sheet of gauze is laid. A layer of absorbent cotton, about one inch thick, is now wrapped around

and over the end, and this enveloped by a large sheet of rubber-tissue protective. A roller is carried over all to hold the dressing in place, and to make compression sufficient to arrest oozing. It is impossible to say how much pressure should be employed, since this knowledge can only come from practice, but the bandage should be fairly tight. Over-pressure at the tip should be avoided, especially where the flap folds down on the end of the bone. As the last bandage is being applied, a short splint, the end of which projects a couple of inches beyond the stump, should be inserted. This steadies the limb, and is useful in keeping the stump elevated, especially when an amputation is made near the trunk. If the last roller is made wet before being applied, it will be less liable to slip.

Such a dressing, under the strict antiseptic method, is not usually removed before the tenth or twentieth day, and in the majority of cases where an amputation is made through comparatively healthy tissues a single dressing is sufficient. The indications for its removal are hæmorrhage of an alarming nature, great pain, high febrile movement (not counting the reactionary fever which follows within twenty-four hours after the operation), and excessive discharge beyond the zone of antiseptics, with decomposition.

Ordinary bleeding may be controlled and permanently arrested by an extra tight roller, or Esmarch bandage, loosely applied for an hour or two. A rise in the temperature of 102° to 103° on the second day, or later, suggests inflammation and sepsis. Lastly, when the serum or fluids from the stump seep under the dressing and decompose, the change is necessitated on account of the odor. When a new dressing is made, the same antiseptic precautions should be employed.

Second Method—Oblique Solid Flaps by Transfixion.—Seize the arm with the left hand so that, as all the soft tissues are pinched up on its anterior aspect, the thumb and index-finger on opposite sides will be just above the point at which it has been decided to divide the bone. The point of a long knife is pushed from the outer side (right arm) horizontally down until it impinges upon the center of the bone; the handle is depressed, the point grazes over the bone, the handle is now elevated, and

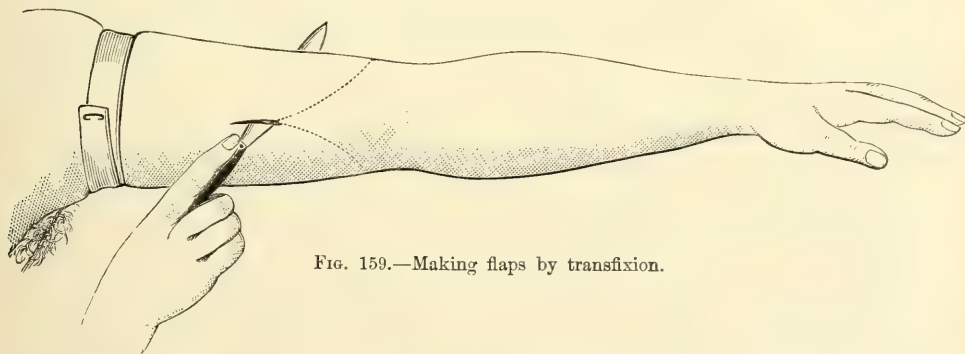


FIG. 159.—Making flaps by transfixion.

the point made to project exactly opposite and on the same plane with the point of entrance (Fig. 159). By a long sawing movement the knife is made to cut directly along the bone until within from one half to one inch of the

limit of the flap, when it is turned rather abruptly out, shaping a blunt, rounded flap. This is held back by the operator's left hand, the point of the knife is insinuated between the muscles and the bone, is made to glide along the posterior surface of the bone, and to come out at or very near the periosteum on the opposite side. A second symmetrical flap is made in the same way as the first. The retractor is applied, and the operation and dressing completed as before.

In making an amputation by transfixion, it is usually advised to cut the non-vascular flap first; but, with a safe tourniquet applied, this precaution is unnecessary.

Third Method—Oblique Solid Flaps, by cutting from the Surface.—Cutting from the surface toward the bone, the first crescentic incision outlines one flap and goes down to the deep fascia (Fig. 160). After the skin

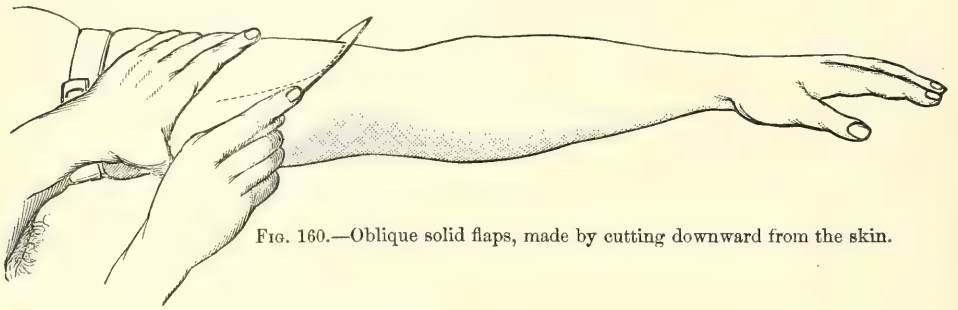


FIG. 160.—Oblique solid flaps, made by cutting downward from the skin.

retracts, the muscles and remaining soft tissues are divided from its edge obliquely down to the point of section through the bone. The opposite flap is made in the same manner, and the operation completed as before.

Skin-Flaps — Circular, Modified Circular, Oval, Double Crescentic, and Double Rectangular.

First Method—Circular.—Before commencing the incision, grasp the arm firmly near the line of incision, and slide the integument upward as far as it will go. In doing this operation, a good scalpel is preferable to the long knife. The incision should go straight down to the fascia which covers the muscles, and directly around the limb by successive strokes with the scalpel, so that the radius of the circle described will be at an angle of 90° with the axis of the humerus (Fig. 161 *a*). When this is completed, catch the edge of the flap with a mouse-tooth dissecting-forceps, put the connective tissues which attach it to the fascia about the muscles on the stretch by pulling the skin upward, and with well-directed strokes or touches with the point of the knife, which should be kept from wounding the skin, raise the flap throughout the entire circumference of the wound. As this dissection proceeds, the loosened sleeve of integument may be rolled up until the point where the muscles and bone are to be divided is reached (Fig. 161 *b*). Just at the margin of the reflected flap the soft tissues are now divided straight down to the bone, the line of section being

perpendicular to the axis of the limb. The periosteum should next be cut through in the circumference of the bone where the saw is to enter.

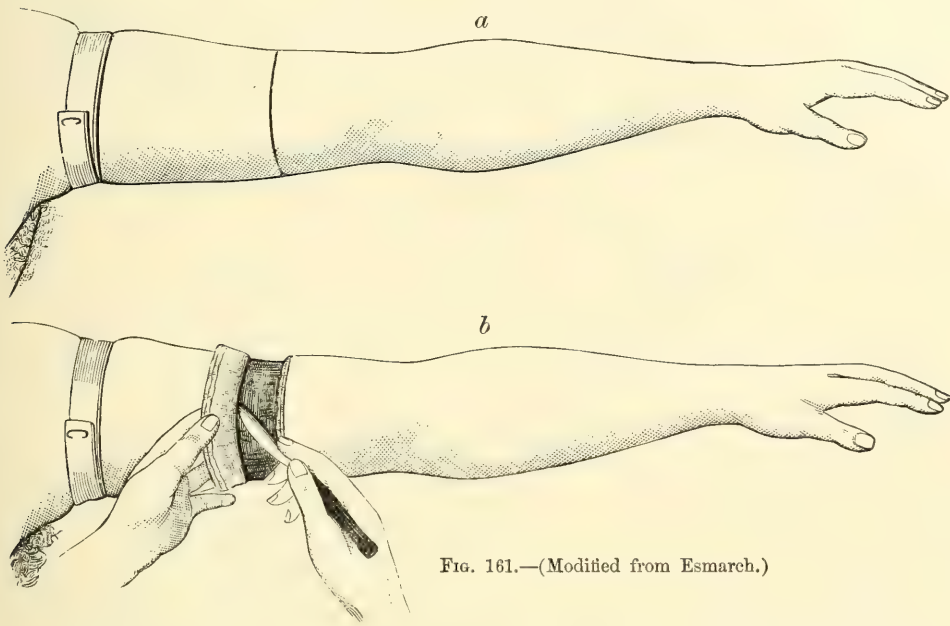


FIG. 161.—(Modified from Esmarch.)

Second Method—Modified Circular.—When, on account of the large diameter of the member, the flap requires to be dissected up for more than two inches, the foregoing method may be modified by a perpendicular incision through to the muscles. This renders the dissection more rapid.

Third Method—Oval.—It not infrequently occurs that the condition of the soft parts near the line of amputation will not permit of an incision directly around the limb without a too great sacrifice of the member. Under such circumstances, an oval or elliptical incision may be made, and in this way integument enough secured to cover in the stump. The longitudinal slit may be added to this operation.

Fourth Method—Double Crescentic.—The circular operation may be further modified by making two crescentic skin-flaps of equal size, the

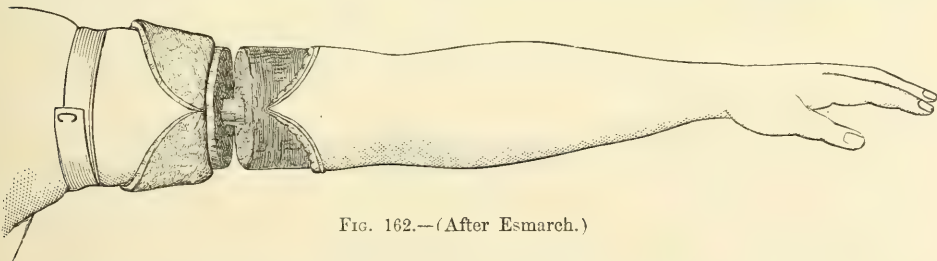


FIG. 162.—(After Esmarch.)

bases of these being at the line of section of muscle and bone. The same precautions as given above are necessary to secure enough integument to form a hood for the stump (Fig. 162).

Fifth Method—Double Rectangular.—The first step is to go around the limb just as if a circular operation were intended. This being done, two incisions, one on either side and exactly opposite to each other, are made perpendicular to the circular cut, and extending up the limb to a point on a level with the line of section through the muscles and bone (Fig. 163). The two flaps are now dissected up to this line, and the

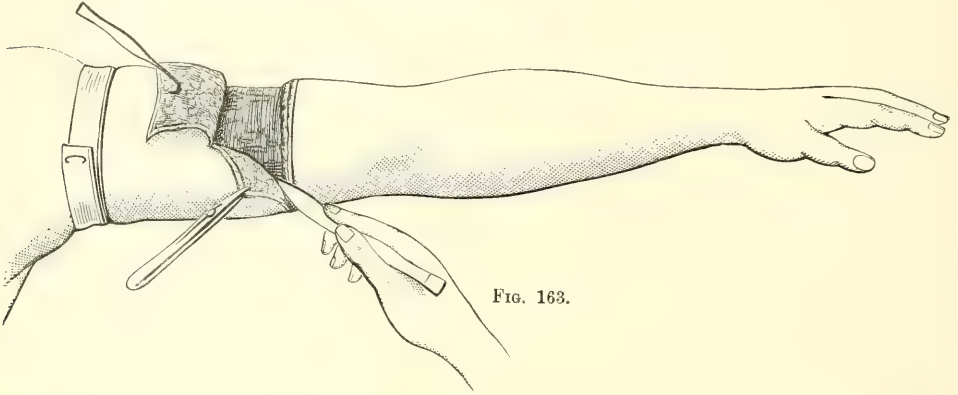


FIG. 163.

amputation completed as before. The commendable features of this procedure are the rapidity with which it may be accomplished, the small degree of violence inflicted in manipulating the flaps, and the readiness with which a stump is drained when the proximal angles of the lateral incisions are used as outlets for the tubes.

Mixed Flaps, composed of integument alone on one side and of all the soft tissues on the other, are the least commendable of all methods. The proper apposition of surfaces so uneven is difficult. When from any cause this operation is adopted, care must be taken to give proper support to the heavy solid flap to prevent dragging upon the sutures.

Résumé.—In thin and emaciated subjects the *solid* flaps should be preferred to the *skin* flaps, for the reasons that the nutrition of the skin is least disturbed by this method. In limbs of large diameter and a goodly quantity of subcutaneous tissue, the skin-flaps are preferable, since a covering under such conditions can be obtained with less sacrifice in the length of the bone. Of the solid flaps, the circular method is better than the oblique, since it divides all the tissues squarely. In making oblique flaps, transfixion is better than cutting from without inward. Of the skin-flaps, the circular incision should be preferred to the other methods where the limb is not very large; the double rectangular flaps where the stump is to be elevated and there is a large surface to drain.

Open Method.—When an amputation is made through tissues infiltrated with pus or other inflammatory products, where, in the judgment of the surgeon, the dangers of sepsis would be increased if the wound were closed, the open method should be employed, with constant or interrupted irrigation.

Before the days of antiseptis the success of this method was thoroughly demonstrated by Prof. James R. Wood and Prof. Dennis, in Bellevue Hospital, where the rate of mortality after amputations, in wards which had been recently vacated on account of puerperal fever, was reduced to the minimum in the history of that hospital. I have employed this method in a number of septic cases with great satisfaction.

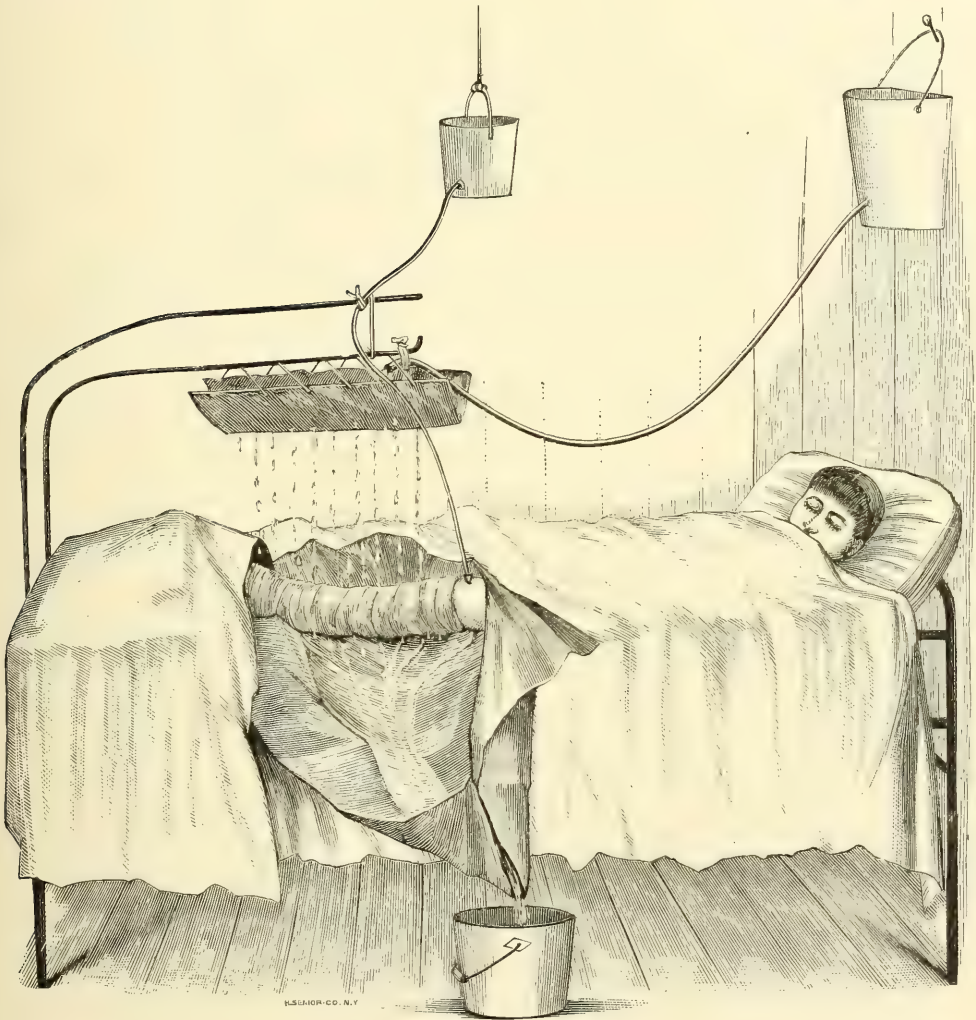


FIG. 164.

In performing the amputation, the flaps must be so shaped that irrigation can be easily accomplished without moving the stump. A circular cut, with a longitudinal incision on the upper surface, or bilateral flaps, are preferable. When the patient is put to bed the stump is placed in a position suitable for drainage, and rests upon an oil-cloth so arranged that the irrigating fluid runs away from the patient and into a basin at the bedside. The flaps should at first be held well open by a wad of sublimate gauze, and the stump loosely enveloped in a thin layer of this

material, so arranged that, as the water drips on it, it will pass through the gauze and over the raw surface.

Fig. 164 shows a ready-made irrigator in use in my service at Mount Sinai Hospital. A piece of sheet-tin, about a foot wide and of any required length, is shaped into a trough, the bottom of which is punched full of holes with an awl. A rubber tube leads the water from a tank into this trough, from which it trickles on to the wound in any required quantity. Or, as represented in the cut, the tube—which, in the case of the patient from whom the drawing was made, conveyed the irrigating fluid into a suppurating knee-joint—may also be employed to carry the water into the wound.

Pure water should be used for irrigation. The danger of absorption from an extensive granulating surface precludes the sublimate or carbolic-acid solutions.

The only objection to which this method is open is the slowness with which the process of repair goes on in its employment. This is, however, an objection of little weight when the ultimate recovery of the patient is secured. As soon as the temperature shows an absence of sepsis the irrigation may cease, and the granulating flaps may be approximated gradually by bandages or adhesive strips.

SPECIAL AMPUTATIONS.

Hand and Fingers.—A primary amputation of any portion of the hand is rarely justifiable. If there is only a small strip of tissue, the integrity of which is evident, an effort at the restoration of the nutrition and function of the part beyond should be attempted. If any doubt exists as to the result, the benefit of this should be given to the side of conservatism. It is essential to arrest hæmorrhage, cleanse the wounds under strict antisepsis, and especially by thorough immersion in a basin of warm sublimate solution (1 to 3,000), secure drainage, and place the parts in the best position for usefulness in case of recovery. Amputation may be done when necessitated by gangrene or necrosis.

Fingers—Interphalangeal Operations.—Between the second and third phalanges of the fingers, proceed as follows: Flex the terminal phalanx at about an angle of 90° to the axis of the second bone, and, one eighth of an inch anterior to the angle on the dorsal aspect, with a small, sharp-pointed scalpel make a transverse incision, extending half-way down the sides of the finger. From this point carry the incision forward, parallel with the axis of the digit, to within a quarter of an inch of the end, then across the palmar aspect of the tip to the opposite side, finishing the incision at the angle of the transverse cut (Fig. 165).

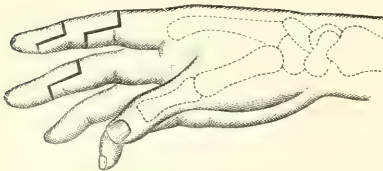


FIG. 165.

Dissect the palmar flap up, keeping close to the bone, lifting the flexor tendon, with the skin, back to the articulation; divide the tendon opposite the joint,

and disarticulate. The flap is now turned back, trimmed with the scissors to fit nicely, and stitched with silk or catgut sutures. By this method the acute tactile sense of the palmar aspect of the finger is preserved, and adds to the usefulness of the stump. This, and other amputations of the fingers, may be made without general anæsthesia, and with perfect insensibility, by the local use of cocaine. Just anterior to the metacarpo-phalangeal joint insert on each lateral aspect of the finger the needle of a hypodermic syringe, and inject in the entire circumference of the finger twenty minims of a 4-per-cent solution of cocaine hydrochlorate. One minute later constrict the root of the digit with an elastic ligature. In this way a painless and bloodless operation may be performed. If the insensibility is not complete at all points of the incision, inject additional cocaine, and by massage distribute it through the tissues.

In dressing these amputations the pressure on the end of the stump should be light, for fear of slough in the long flap. Usually no vessels need to be tied. The covering of cartilage does not require to be scraped or sawn off. When only a slight portion of the anterior tip of the second phalanx is involved in a destructive osteitis or injury, the remaining portion should not be sacrificed by a disarticulation at the posterior interphalangeal joint. The line of section through the bone should be about at the junction of the middle and anterior third of the phalanx. The incisions and flap are made as in the preceding operation.

In amputation with disarticulation at the posterior interphalangeal joint, flex at an angle of 90° , make a transverse incision over the dorsum of the finger, from one eighth to one fourth of an inch in front of the angle, which includes half the circumference of the member. From the ends of this line carry the incision directly forward on each lateral aspect of the finger to the crease on the palmar surface opposite the anterior interphalangeal joint. A second transverse incision in this fold completes the rectangular flap, which is now dissected back, and the disarticulation effected by placing the ligaments on the stretch and dividing these with a narrow, sharp scalpel. If any difficulty is found in entering the joint from the sides or front, it may be easily done by division of the extensor tendons over the dorsum, for these take the place of posterior ligaments. The method of amputation, as given for the operation at or near the articulation of the first and second phalanges of the finger, applies also to the thumb in amputation at the last joint, or through the first phalanx, within one fourth of an inch of its anterior extremity. This plan of making the flaps is far superior to that advised by Erichsen, Esmarch, and other authors who recommend cutting down and through the joint from the dorsum, and then forward along the palmar aspect of the phalanx, making the disarticulation and flap with a single stroke. In the first place, this is done with no little difficulty, for, however thin the blade, the character of the joint will scarcely allow an easy passage to the knife. Secondly, by the method of transfixion the flap is apt to be cut too pointed and beveled at the end.

At the Metacarpo-Phalangeal Joint—Thumb.—When the condition of the soft parts will permit, proceed as follows :

First Method.—Just over the joint, and in the middle of the dorsal aspect of the thumb, commence an incision and carry it along the surface next to the index-finger until half the circumference of the member is included. Along the dorsal and palmar aspects carry parallel incisions forward until near the interphalangeal joint, and connect these by a straight transverse cut across the palmar surface. Dissect the flap back, divide all tendons opposite the joint, disarticulate, tie the *dorsales pollicis* (one on either side of the back of the thumb), and the *arteria princeps pollicis*, which lies along the side of the metacarpal bone nearest the index-finger and divides into its terminal branches opposite the metacarpo-phalangeal joint. When the flap is stitched, the scar will be in good part concealed on the ulnar aspect of the stump.

Second Method.—A transverse dorsal incision is made over the articulation, extending half around and ending at opposite points on the external and internal lateral aspects of the thumb. Parallel lateral incisions are

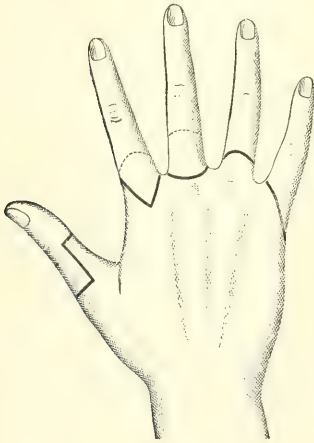


FIG. 166.

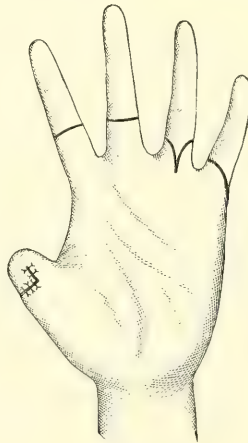


FIG. 167.

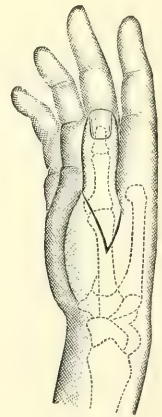


FIG. 168.

made as far forward as the interphalangeal joint, and the anterior extremities of these are joined by a transverse palmar cut (Fig. 166). The end of the metacarpal bone of the thumb should be left undisturbed, when not necrosed, when there is sound skin enough to cover it in. Under other conditions it may be divided with a fine saw or the exsector. The question of the appearance of the stump should be secondary to the usefulness of the member. It is especially important to a laborer that the end of the metacarpal bone of the thumb be preserved (Fig. 167). When the operation is performed upon one not compelled to do manual work, a more symmetrical appearance may be obtained by an oblique section of the metacarpal bone about half an inch behind the articular surface. When this is intended, the incision through the skin should be such that the long part of the flap is obtained from the radial and palmar aspect of the thumb, while the line of sutures is situated well on the dorsal surface of the stump (Fig. 168).

Index-Finger—At the Metacarpo-Phalangeal Joint—First Method.

—When possible, the following method should be adopted, the object being to preserve the tactile sense and to leave the scar less prominent :

From the ulnar side of the knuckle, and just over the joint, make an incision which extends from this point forward as far as the web between the index and middle finger, and, in case of a large knuckle, a little beyond this point at the side of the digit. From the anterior end of this incision make a second cut directly across the palmar aspect of the phalanx until the middle of the radial side of the finger is reached, and complete the flap by cutting in a straight line from this point to the commencement of the first incision. When the disarticulation is completed, the *dorsalis* and *radialis indicis* arteries, and the *external digital* branches, tied with fine catgut, the corner of the flap is carried into the receding angle on the dorsal surface of the metacarpal bone and secured by sutures. When the head of the metacarpus is to be removed, the section of this bone should be slightly oblique, and the line of incision a partial oval, beginning at the web between the two fingers, and traveling along the crease formed by flexion of the finger on the metacarpus well up on the dorsum of this bone, about three fourths of an inch back of the joint. An incision, almost in a straight line, should now be made between the ends of this curved line (Fig. 166). Dissect the flaps clear and without making a disarticulation, expose the bone, and with a fine saw divide it obliquely from before backward, and from the ulnar toward the radial aspect. In amputation of the middle or the ring finger, the following method should be preferred :



FIG. 169.—(After Esmarch.)

Middle Finger.—Locate the articulation exactly, and over this point make a transverse incision extending on either side to the middle of the depression between this digit and the index- and ring-fingers (Fig. 166). From either end of this cut carry a lateral incision directly forward about

half way up the first phalanx, and connect these by a transverse incision across the palmar aspect of the digit (Fig. 167). Disarticulate and fold the palmar end of the flap back upon the dorsal transverse incision where it is stitched.

Another method is the oval incision, shown in Figs. 169 and 170. By the first method the tactile surface is better preserved. The head of the metacarpal bone should be left intact for the laboring classes. When the round expansion of this bone is removed, the gap between the index and ring-fingers is not so wide. The bone should be sawed squarely across a half inch behind the articular surface. All that has been said of this digit applies with equal force to the ring-finger.

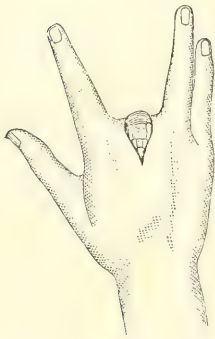


FIG. 170.—(After Esmarch.)

Little Finger.—The method recommended in amputation of the index at the metacarpal joint should be preferred in removing the little finger at the same level. The flap should be so shaped that the cicatrix will fall on the dorsum and toward the ring-finger. When the metacarpal bone is to be divided it should be cut with a slight obliquity. In this operation the oval incision shown in Fig. 171 should be made.

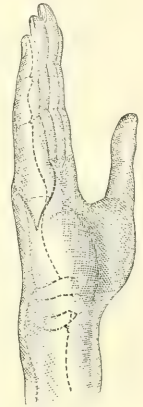


FIG. 171.

When two or more fingers require to be removed at the metacarpo-phalangeal joint, each one may be amputated by the methods described as especially suited to it, or a common antero-posterior flap may be made. As to the propriety of removing the ends of the metacarpal bones, the same rules apply as already given for the single amputations.

Through the Metacarpus.—When the end of the metacarpus can not be saved, these bones should be divided at any point three fourths of an inch or more anterior to the carpo-metacarpal articulation. If the injury extends behind this line, it is better to disarticulate at the carpo-metacarpal junction. In amputation through the metacarpus, the flap should be made chiefly from the palmar tissues, so that the line of sutures and the scar will be well on the dorsum of the hand, and as much of the tactile sense preserved as is possible.

Carpo-Metacarpal Disarticulation.—When all the bones of the metacarpus require to be removed, on account of a lesion not involving the anterior row of the carpus, the amputation should be made through the metacarpo-carpal line. If the anterior row is involved, the entire carpus should be removed. When the thumb is intact, and the metacarpal bones of the four fingers require removal, the incision as given by Esmarch should be followed. A curved incision is made across the palm, beginning at the middle of the web between the thumb and index-finger, and carried outward to the ulnar side of the base of the fifth metacarpal bone (Fig. 172). The dorsal incision commences at the web between the thumb and finger, and is carried obliquely upward toward the carpus

until the junction of the middle and upper third of the metacarpal bone of the index-finger is reached, whence it travels across the back of the hand to join the end of the palmar incision (Figs. 173, 174).

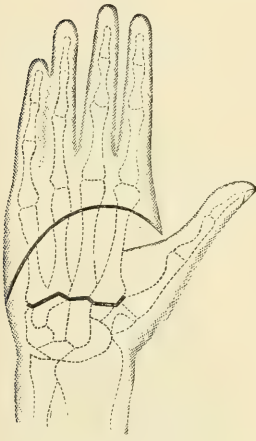


FIG. 172.

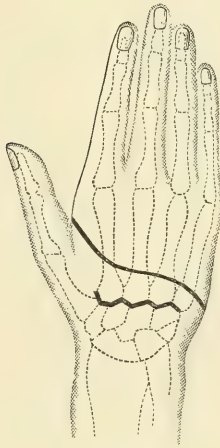


FIG. 173.

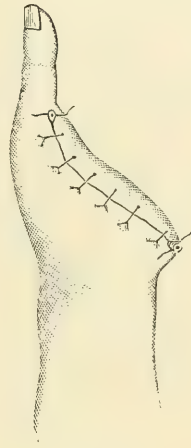


FIG. 174.

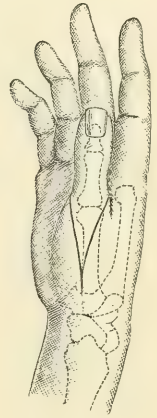


FIG. 175.

Amputation of the thumb with disarticulation at the carpo-metacarpal junction should be done as follows: Just over the carpo-metacarpal joint on the dorsal aspect of the hand commence an incision, and carry it directly along the metacarpal bone until half way to the metacarpo-phalangeal articulation, from which point it is made to travel along the groove between the thumb and index-finger to the middle of the web between these two members, thence on around the base of the thumb until the dorsal incision is reached (Fig. 175). In the case shown in

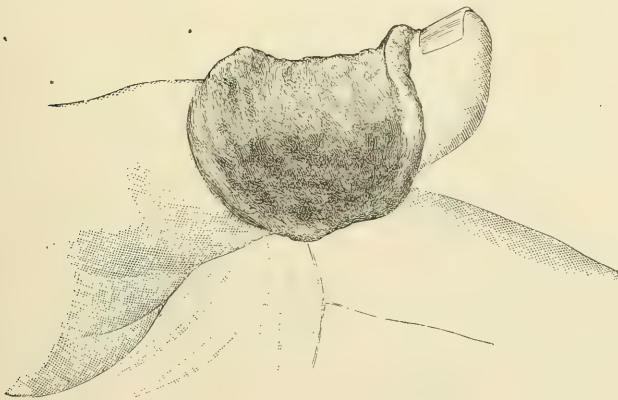

FIG. 176.—Epithelioma of thumb.
(From a patient at Mt. Sinai Hospital.)



FIG. 177.—The same, after amputation at the carpo-metacarpal joint.

Figs. 176 and 177 this operation was performed. In amputation of the little finger, at the carpo-metacarpal joint, a similar incision is made (Fig. 178).

The character of the injury, the general condition of the individual,

the vitality of the parts involved, may necessitate various modifications of the foregoing methods. In the surgery of the hand, the rule in practice should be never to amputate when possible to avoid it, and never to remove any more than is absolutely necessary. Fig. 179 is that of an amputation after an injury from the explosion of a shot-gun, in which the thumb, index, and middle fingers, and their respective metacarpal bones, were blown off. The line of incision was a lateral one, and the disarticulation was at the carpo-metacarpal joint.

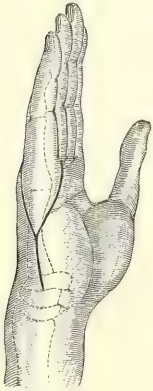


FIG. 178.

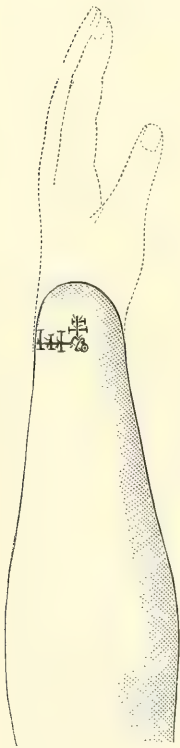


FIG. 180.

Radio-Carpal Joint.—In amputation at the wrist the carpus should be removed, even when all the bones of this group are not involved. The line of incision will depend upon the extent of the healthy tissues available for forming the covering to the stump. The long palmar and short dorsal flaps are preferable on account of the finer tactile sense of the covering thus secured. Moreover, the vitality of the palm is so great that, if ordinary precautions are observed in its dissection, sloughing will not occur.

First Method.—Place the thumb and finger of the left hand respectively upon the styloid of the radius and ulna, and make an incision across the dorsal surface of the wrist

which shall divide everything straight down to the bones and into the cavity of the joint. This incision reaches half-way down the lateral aspects of the wrist. At the radial end of this cut enter the scalpel, and, in shaping the long flap, follow the center of the dorsum of the metacarpal bone of the thumb as far as the metacarpo-phalangeal articulation. From this point cut directly across the palm to the ulnar side of the fifth metacarpal bone, and back along this to join the dorsal incision. Dissect the flap closely from the flexor tendons, and divide all tendons opposite the wrist-joint. Apply a cloth retractor, and saw through the styloid of the radius and ulna just at the level of the articular surface of the radius, but not necessarily taking a section from this surface.

The *radial, ulnar, anterior, and posterior carpal* vessels are tied, the palmar flap is trimmed down to fit snugly, and stitched in proper position. The drainage-tubes come out on either side (Fig. 180).



FIG. 179.

Second Method.—If the condition of the soft tissues is such that the long palmar flap can not be obtained, the circular incision shown in Figs. 181 and 182 may be practiced. It is always advisable to make a longitudinal split in the cuff along its ulnar aspect. Under other conditions, a

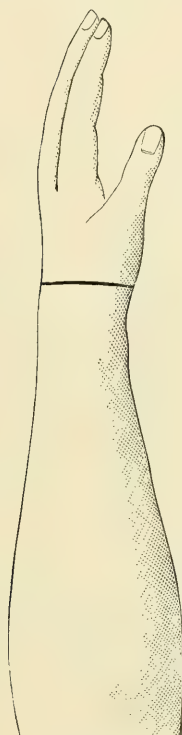


FIG. 181.

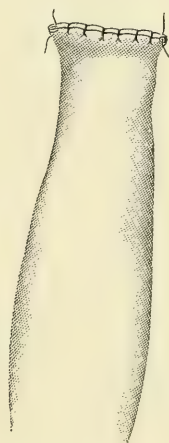

FIG. 182.—Showing cuff stitched and exit of drains after the circular method. (After Es-march.)

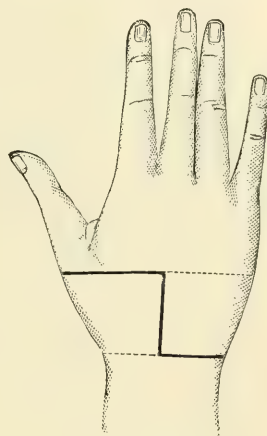


FIG. 183.

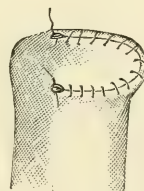


FIG. 184.

lateral flap may be utilized, after the third method (Figs. 183, 184), in the flap from the thumb side; or the fourth method in which the flap is taken from the ulnar aspect of the hand.

Forearm above the Wrist.—In amputations through the forearm, the circular or modified circular skin-flaps are, in general, preferable. The exceptions are in cases of marked emaciation when the solid flaps are indicated.

The anatomical relations of the parts concerned are admirably shown in Figs. 185, 186, 187, and 188, which, with only slight modifications, I have copied from Prof. Braune's magnificent work.

When the line of amputation is so close to the elbow-joint that division of the bones is necessitated within an inch of the articular surface of the head of the radius, the operation to be preferred is a disarticulation at the elbow, with removal of the olecranon. When the bones can be preserved at the level of the lower border of the bicipital tuberosity of the radius, the joint should not be invaded.

Amputation at this level (Fig. 188) should be made subject to the rules just given for other portions of the forearm between the wrist and the insertion of the *biceps humeri*.

At the Elbow-Joint—First Method.—Make a circular incision through the skin from one inch to one inch and a half below the level of the internal condyle. Along the posterior aspect of the

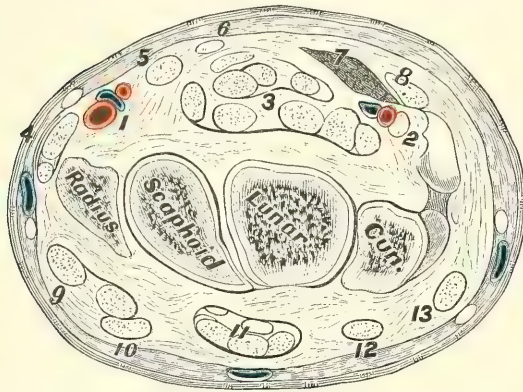


FIG. 185.*—Transverse section through the right upper extremity, one fourth of an inch anterior to the plane of the radio-carpal articulation. Looking at the surface of the stump. 1, Radial artery and veins. 2, Ulnar artery, veins, and nerve. 3, Tendons of deep and superficial flexors. 4, Tendon of extensor ossis metacarpi and primi internodii pollicis. 5, Flexor carpi radialis. 6, Palmaris longus. 7, Fibers of the flexor brevis minimi digiti, from the annular ligament. 8, Flexor carpi ulnaris. 9, 10, Extensor carpi radialis longior et brevior, and tendon of secundi internodii pollicis. 11, Extensor communis digitorum. 12, Extensor minimi digiti. 13, Extensor carpi radialis. Superficial veins and nerves are seen in the subcutaneous tissues.

the ulna make a second incision, splitting the sleeve of skin as far back as the end of the olecranon. Dissect up the flap from the muscles and deep fascial attachment until the joint is exposed in front, and the olecranon posteriorly. Extend the forearm fully, enter the articulation between the head of the radius and the humerus, disarticulate, and saw off the articular surface at the level of the lower portion of the internal condyle. The drainage is from the highest point in the perpendicular incision.

Second Method.—Make a circular incision down to the

deep fascia from one to two inches anterior to the tip of the internal condyle of the humerus, and, when the skin has retracted, at the level of the line of retraction divide all the tissues to the bones. Along the posterior surface of the ulna make an incision extending as high as the olecranon process. Dissect the soft tissues neatly from the periosteum and capsule back to the condyles on the lateral and anterior aspects of the humerus, and along the olecranon somewhat higher, in order to facilitate disarticulation and the complete removal of the synovial bursa, beneath the insertion of the triceps. When the disarticulation is completed, apply a cloth retractor and saw a portion of the articular surface off at the same level as

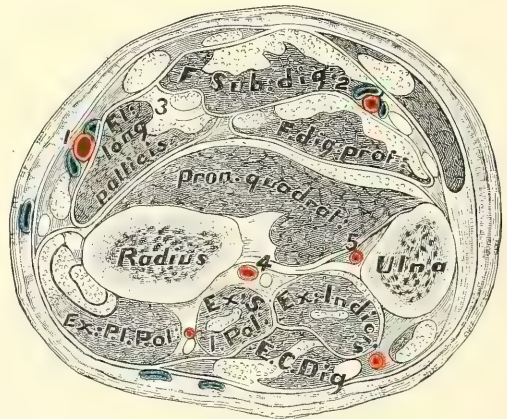


FIG. 186.—Transverse section showing the relations of the tissues divided in amputation through the lower third of the right forearm. Looking from below upward. 1, Radial artery and veins. Just below this, tendon of supinator longus, radial nerve, and close to the radius the tendons of the extensor ossis metacarpi pollicis and extensor carpi radialis longior et brevior. 2, Ulnar artery, veins, and nerve. 3, Median nerve. 4, 5, The posterior and anterior interosseous arteries.

* All of these cuts represent the surface nearest the patient's body, i. e., the surface over which the vessels are searched for after an amputation.

given in the preceding operation. The flaps are now sutured, leaving the drainage-tube out at the upper limit of the incision, over the olecranon.

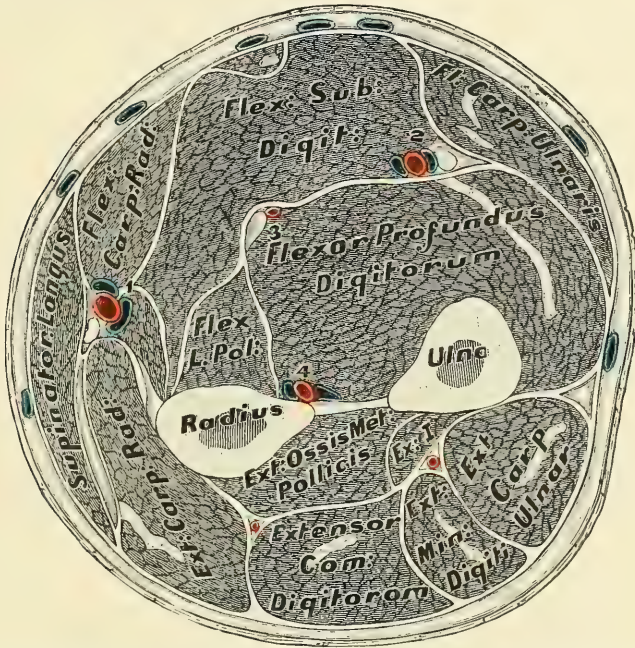


FIG. 187.—Transverse section through the middle of the right forearm. Looking from the periphery toward the center. Showing the relations of the tissues divided in amputation at this point. 1, Radial artery, veins, and nerve. 2, Ulnar ditto. 3, Median nerve. 4, Anterior interosseous vessels.

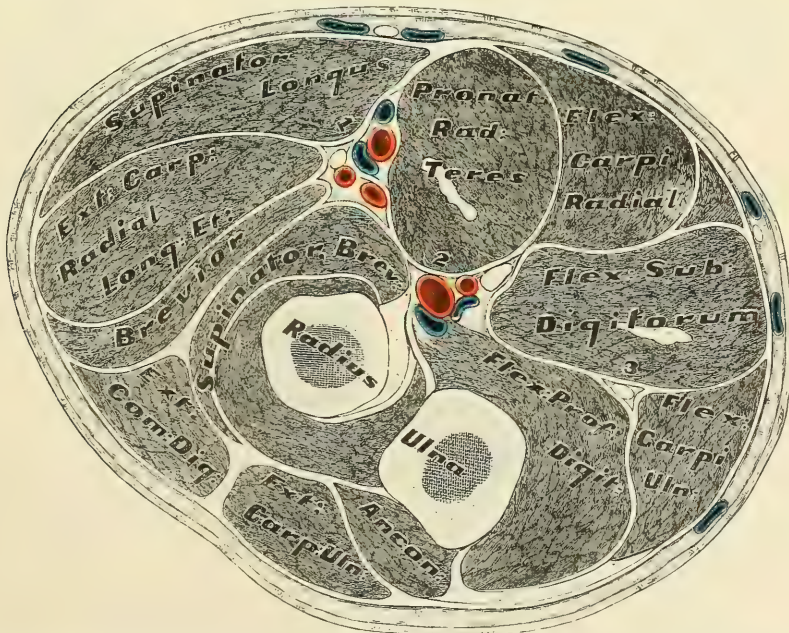


FIG. 188.—Transverse section through the upper third of the right forearm. Looking from the periphery toward the center. 1, Radial artery, muscular branches, veins, and radial nerve. 2, Ulnar and interosseous arteries, veins, and median nerve. 3, Ulnar nerve. The tendon of insertion of the biceps is seen with the radius.

Fig. 189 shows the anatomical relations near the line of section of the soft parts involved in this amputation.

In no amputation is the superiority of the circular or modified circular *skin-flap* over the mixed flap of older operators more evident than the one under consideration. In the mixed operation, where the anterior flap was made by transfixion, cutting obliquely forward and outward, the large vessels were not evenly divided, nor was it without considerable care that the opposing flaps could be properly adjusted. The older method, in which the olecranon process was left in position, the saw passing through the neck of this process at the level of the lower portion of the articular surface of the humerus as soon as the joint was opened, has also been discarded. It has been demonstrated that nothing was gained by leaving the insertion of the triceps intact, while a second operation was occasionally necessary on account of necrosis of the olecranon.

Removal of a portion of the articular surface is not always advised by surgical writers. While it is true that the stump will heal as readily when the cartilage is scraped from the bone as when the saw is used, the latter is preferable, not only from the standpoint of appearance, but also that of usefulness.

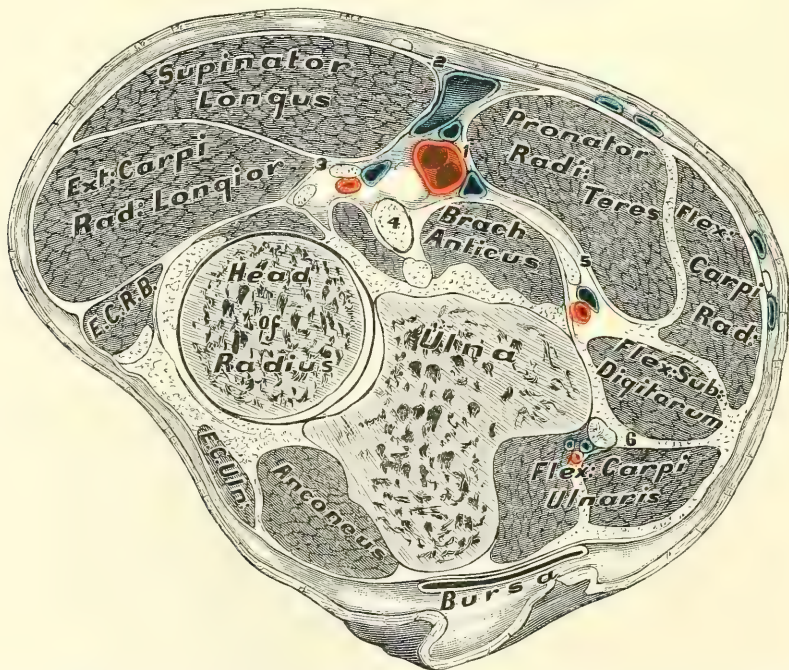

FIG. 189.—Transverse section of right arm just below the elbow-joint. Looking at the surface nearest the body. 1, Brachial artery at the point of division into ulnar and radial. 2, Median basilic vein communicating with brachial. 3, The radial and interosseous divisions of the musculo-spiral nerve and radial recurrent artery. 4, Tendon of biceps. 5, Median nerve and anterior ulnar recurrent artery. 6, Ulnar nerve and posterior ulnar recurrent artery.

Arm below the Shoulder-Joint.—The circular skin-flap is always preferable, except in cases of extreme emaciation, when, as heretofore given, the solid flaps are recommended.

First Method.—Make a circular cut down to the muscles, and a

longitudinal incision to the same depth along the outer side of the arm. Dissect the sleeve of skin carefully up to the line of section of the humerus, and at this point divide the muscles and bone. Drainage is effected in the manner shown in Fig. 190.

The anatomical relations in the several regions of the arm are shown in Figs. 191, 192, and 193.

When the line of amputation is so near the shoulder-joint that section of the bone is required at the anatomical neck, the head of the humerus should be disarticulated.

Second Method.—Make a circular cut through the skin at a point sufficiently below the line of section through the humerus to permit a suitable covering. Allow the skin to retract up the arm, and at this point divide everything smoothly and squarely down to the bone. Render the skin and muscles tense,

push the point of the scalpel down to the bone on the outer side of the arm, and lay the flap open by an incision which is parallel with the axis of the humerus. Dissect the tissues closely from the periosteum up to the point where the saw is to be applied, and, after protecting

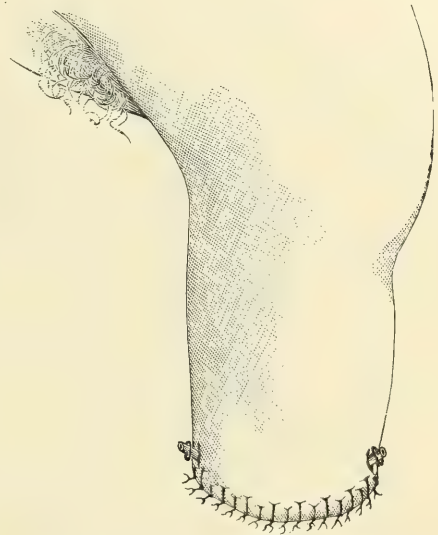


FIG. 190.—Showing sutures applied and exit of drains in amputation at the lower and middle thirds of the humerus.

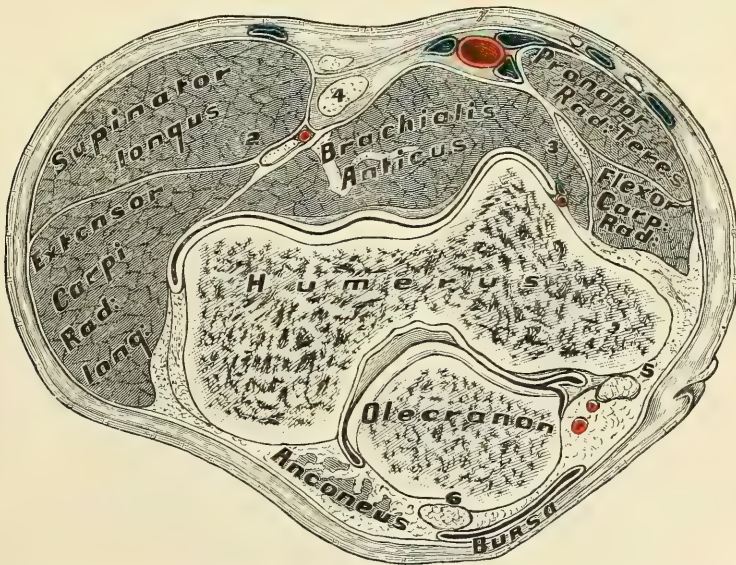

FIG. 191.—Section through the condyloid expansion of the right arm. Looking at the surface nearest the body. 1, Brachial artery and veins, and the median basilic vein. 2, Musculo-spiral nerve and superior profunda artery about the point of anastomosis with the radial recurrent. 3, Median nerve. 4, Biceps tendon. 5, Ulnar nerve. 6, Triceps tendon.

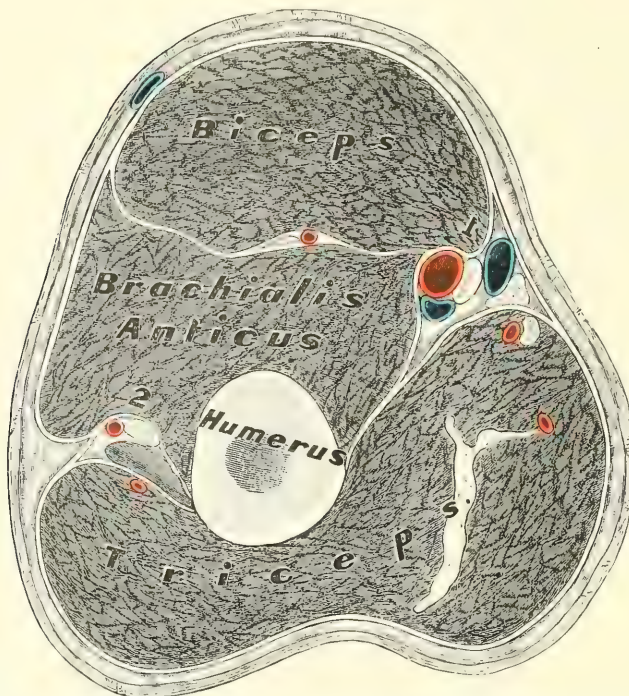


FIG. 192.—Transverse section through junction of middle and lower thirds of right arm. Looking from below upward. 1, Brachial artery, vein, median nerve, and basilic vein. Near by the ulnar nerve and inferior profunda artery. 2, Musculo-spiral nerve, superior profunda artery, and supinator longus muscle. Cephalic vein to outer side of the biceps muscle.

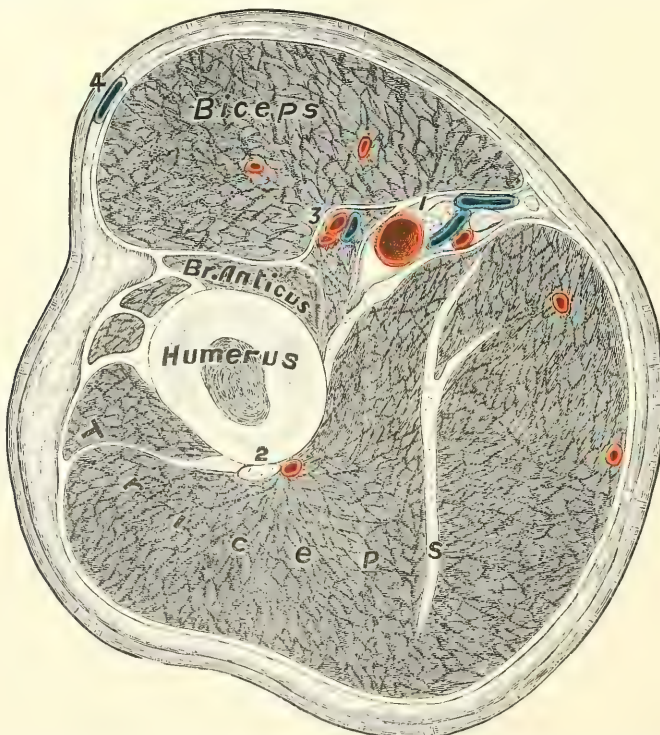


FIG. 193.—Transverse section showing the relations of parts divided in amputation just above the middle of the humerus. Right side. Looking toward the center. 1, Brachial artery. Near this the median nerve and brachial veins. Internal to it the ulnar nerve and inferior profunda artery. More superficial, the basilic vein. 2, Musculo-spiral nerve and superior profunda artery. 3, Nutrient artery in the substance of the coraco-brachialis muscle. 4, Cephalic vein.

the soft parts with a retractor, divide the bone. The drainage should be from the upper extremity of the perpendicular cut, which, with the stump properly elevated, will be the most dependent portion of the wound. An extra tube may be inserted at the end of the stump.

At the Shoulder-Joint—First Method.—The patient should be placed so that the shoulder is near the corner of the table and convenient to the operator. After rendering the extremity bloodless, apply the elastic tourniquet around the axilla and over the clavicle and spine of the scapula. Holding the arm so that the internal condyle points directly to the patient's side, enter a long, sharp scalpel directly down to the capsule of the joint, just at the articulation of the clavicle with the acromion process, and expose the head and upper part of the humerus by a per-

pendicular incision, which splits the deltoid down to its insertion. At the lower end of this incision make a circular cut through the skin, and, allowing it to retract, divide at this line the remaining soft tissues down to the bone. In order to prevent any bleeding, in case the tourniquet should not be sufficiently tight, an assistant should be ready to grasp the flap just below the tourniquet, or press the subclavian against the first rib. The entire flap is now dissected up from the periosteum and capsule, and disarticulation ac-

complished by cutting the capsule as close to the margin of the glenoid cavity as possible (Fig. 194). The vessels are now secured, and the wound sutured and drained, as shown in Fig. 195. This method is a modification of the old operation of Larrey,* to which it

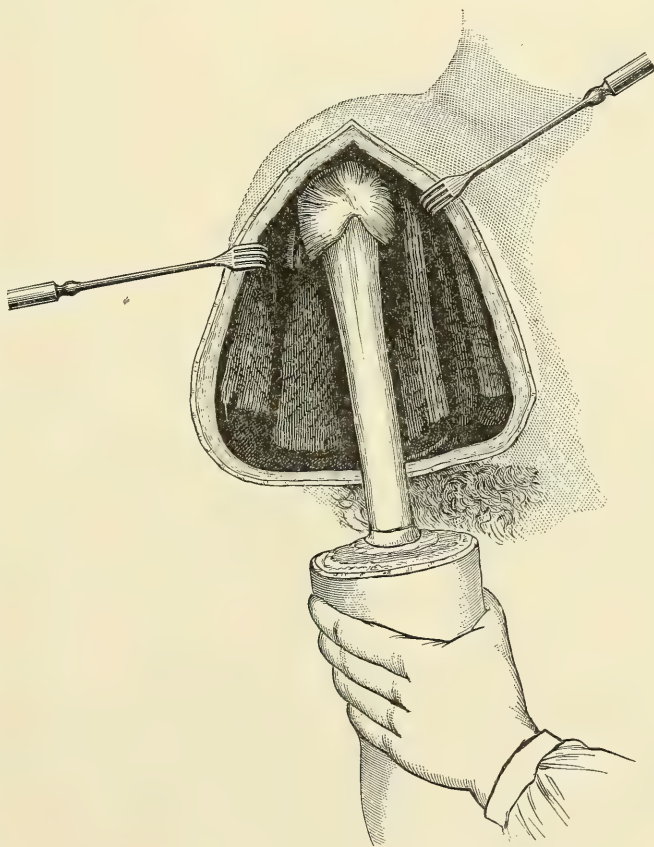


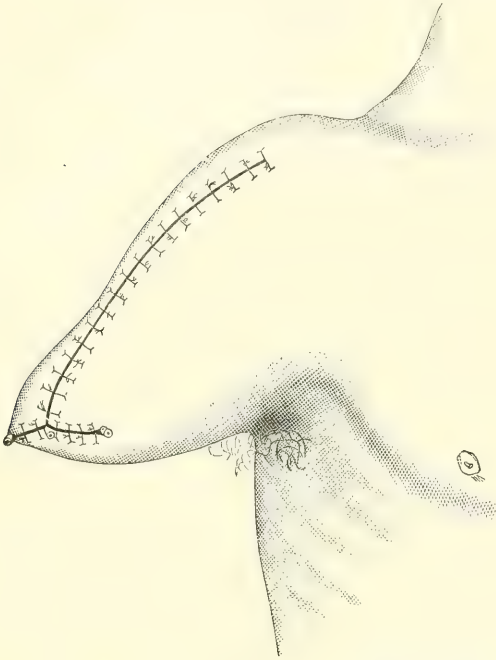
FIG. 194.

* *Larrey's Method.*—A straight incision, dividing all the tissues down through the capsule to the bone, extending from the tip of the acromion process to about one inch below the articular surface of the head of the humerus. From the center of this cut an incision on either side

is much superior. Esmarch has still further modified this amputation by sawing the bone immediately after the circular incision is completed, and then disarticulating.

Amputation of All or Portions of the Scapula and Clavicle.—When it becomes necessary to remove all or parts of these bones, the deligation of the subclavian artery in its third division should be first accomplished.

As this amputation is occasionally necessitated by reason of malignant neoplasm, involving the integument, it may be found impossible to secure flaps sufficient to cover the exposed surface. Under such conditions the wound should be allowed to heal by granulation and a subsequent plastic operation done to cover in the stump.



LOWER EXTREMITY.

Amputation of the Toes.—The same methods given for the fingers should be employed in amputation of the toes. The long plantar flap is preferable in these operations, not so much for the preservation of the more perfect tactile sense of this surface in covering the stump, but chiefly to bring the cicatrix on top and away from pressure. When an amputation is necessitated for a lesion near the articulation between the first and second phalanges in which only the anterior extremity of the first

of the arm, running obliquely downward and forward, dividing all the tissues down to the periosteum, and extending about two thirds of the distance from the apex of the shoulder to the axilla. Elevate the tissues so as to fully expose the joint, press the arm upward, in order to dislocate the head of the bone through the incision in the capsule, carry a long, thin knife across and through the capsule, and complete the oval flap by cutting along the under surface of the humerus in the line of the oblique incisions already made.

Dupuytren's Method.—Place the arm to be amputated at a right angle to the trunk, grasp and raise the deltoid with the left hand, and transfix the shoulder from before backward with a long knife, which is introduced anterior to the axillary vessels, perforates the capsule, and emerges on the posterior aspect of the arm. A long (*deltoid*) flap is now made by cutting downward, close to the bone, to near the deltoid tubercle. While an assistant holds this flap up out of the way, the arm is carried to the side of the body, and the humerus pressed upward, in order to facilitate its dislocation. The long head of the biceps, and the tendons, inserted into the tuberosities, are now divided, and, if necessary, the incision in the capsule lengthened. After the luxation is accomplished, insert the knife as in the operation of Larrey, making the posterior flap by the same manœuvre.

[Many other methods have been devised for the performance of this operation, but the method first given meets all the indications so fully that it must supersede all others.]

phalanx is involved, section through the bone should be preferred to disarticulation at the metatarso-phalangeal joint, provided that the line of section is through the anterior third of the phalanx. Disarticulation of two or more consecutive toes at the metatarso-phalangeal joint may be effected by a continuous incision. Amputation of all the toes at this articulation is performed as follows: Grasp and forcibly flex the toes, and make an incision, commencing just posterior to the inner aspect of the metatarsal joint of the great toe, curving forward along the side of

the first phalanx to a point as far advanced as the web between the toes, and then across the base of each digit on this plane until the outer side of the metatarsal bone of the fifth toe is reached at a point corresponding to that at which the incision was begun. With the toes now fully extended, a symmetrical flap is next cut along the plantar aspect by an incision which almost merges into the first line at the anterior margin of the web (Figs. 196, 197). Dissect up each flap as far back as the metatarso-phalangeal articulation, leaving the tendons to be divided at this point. The disarticulation may be best effected with a strong narrow scalpel, while the ligaments are made tense by forced flexion.

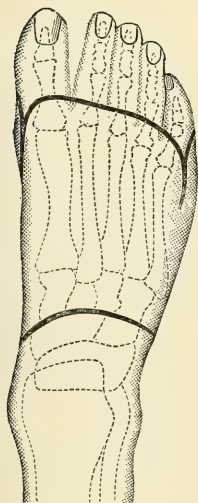


FIG. 196.

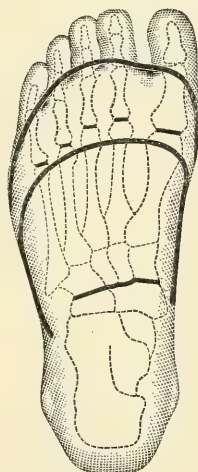


FIG. 197.

Second Method.—A separate amputation may be made for each toe.

Through the Metatarsus.—When the loss of tissue requires an amputation behind the metatarso-phalangeal articulation, section of one, or even all, of the metatarsal bones should be effected rather than unnecessarily sacrifice any portion of the foot by disarticulation at the tarso-metatarsal joint. The line of section should always be as near the anterior extremity as possible, and when it falls within three fourths of an inch from the tarso-metatarsal joint, a disarticulation should be made at this point.

Amputation through the entire metatarsus should be made with a long plantar and short dorsal flap, so that the scar will fall on the dorsum of the foot and away from pressure. The dorsal incision should be made almost directly across the foot, and on a line with the plane of section through the bones. The plantar flap should begin on the inner side of the first metatarsal bone, and follow this forward as far as is necessary to secure a flap of sufficient length. It is always wise to make this a little too long, so that it may be trimmed down and made to fit nicely as the sutures are being adjusted. The incision is next carried across the sole of the foot to the outer surface of the metatarsal bone of the little toe, and back along this to the point of junction with the end of the dorsal cut. All of the tissues should be divided directly down to the bones in this incision, and the flap dissected up, keeping the knife-

point always in contact with the periosteum, so that the vessels may be avoided. After the bones are sawn through, the lower flap is turned into position and suitably trimmed. The vessels are next secured, the sutures applied, and the drainage tubes brought out at each side.

At the Tarso-Metatarsal Articulation—First Metatarsal.—Amputation of the great toe, with disarticulation of its metatarsal bone at the tarsal joint, is effected as follows: At a point about half an inch behind the articulation of the metatarsal bone with the internal cuneiform, and immediately between the dorsal and internal lateral aspects of this bone, commence an incision which is carried forward to the phalangeal junction. Thence it is continued around the base of the toe, across its plantar surface, and back through the web between the first and second digits, and back to the end of the straight incision over the metatarso-phalangeal joint (Fig. 198). Dissect the soft parts closely from the bone, taking care not to wound the plantar vessels, and disarticulate. The preservation of the posterior portion of the first metatarsal bone is always desirable, on account of its giving insertion to the peroneus-longus and partially to the tibialis-anticus muscle, the former being a strong supporter of the transverse arch of the foot, and the latter offering the chief resistance to the sural muscles.

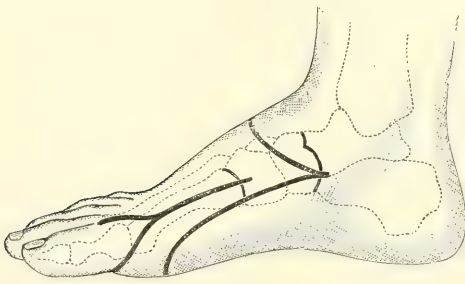


FIG. 198.

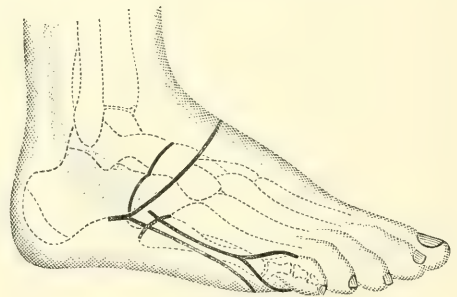


FIG. 199.

Fifth Metatarsal.—One fourth of an inch behind the tubercle of the fifth metatarsal, and over the center of the dorsal aspect of this bone, commence an incision, which is carried directly forward until near the first phalanx, when an oval is described around the base of the little toe (Fig. 199). Keep close to the bone in the dissection. The disarticulation is more easily effected by division of the peroneus brevis and peroneus tertius, and by entering the articulation from the outer side. The importance of the posterior portion of this bone is less than that of the metatarsal bone of the great toe, but it should never be needlessly sacrificed.

One or more of the intervening metatarsal bones may be removed in an amputation of their respective toes in practically the same manner as the preceding. The incision should be begun far enough behind the tarso-metatarsal joint to thoroughly expose the ligaments and facilitate disarticulation—not an easy process when only a single bone is to be removed. The incision should be made exactly along the middle line of the dorsal aspect.

Amputation of the entire metatarsus should always be made through the articular plane (Lisfranc). The modification of this procedure by Hey, which consisted in disarticulating the four outer metatarsal bones and sawing the end of the internal cuneiform off at the line of the second metatarsal bone, is altogether unnecessary.

Method—Dorsal Incision.—Place the thumb and index of one hand respectively half an inch behind the articulations of the first and fifth metatarsal bones with the cuneiform and cuboid, and at the most convenient one of these points commence the dorsal incision, carrying it

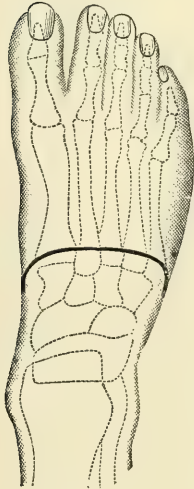


FIG. 200.

directly forward to the base of the metatarsus, and then across the foot one fourth of an inch in front of the tarso-metatarsal articulation, finishing at the opposite side (Fig. 200). This incision should have a slight forward convexity, and should divide all tissues down to the bones. Dissect the flap closely from the periosteum to about one fourth of an inch behind the line of articulation.

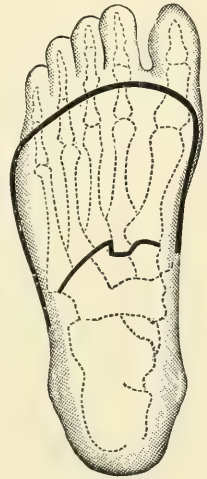


FIG. 201.

Plantar Flap.—From the same point as for the dorsal incision, carry the knife directly forward on the lateral aspect of the metatarsal bone to the metatarso-phalangeal joint, where the line of incision should

begin to describe a curve until the interdigital web is reached, along which it travels across the foot, and thence back along the opposite metatarsal bone to the level of the tarsus (Fig. 201).

This flap should be lifted by deep dissection, keeping close to the under surface of the bones, in order to interfere as little as possible with the vascular supply. An assistant should now hold both flaps well back, while with a narrow, short scalpel the disarticulation is effected as follows :

Grasp the metatarsus with one hand and forcibly depress it until the ligaments are put upon the stretch. Enter the knife just behind the tip of the fifth metatarsal bone and carry it inward with a slight forward inclination, disarticulating on this plane, and in succession the fifth, fourth, and third bones, until the knife is arrested by the outer surface of the second metatarsal. The line of this articulation is almost parallel with that just followed, but it is placed from one eighth to one fourth of an inch posterior to it, and may be readily found by moving the metatarsal bone upon the cuneiform. The joint between the metatarsal bone of the great toe and the internal cuneiform is about one fourth of an inch anterior to that of its fellow, being continuous with the line of the three outer bones. The flaps should now be trimmed and nicely fitted, and any ragged ends of tendons clipped off by the scissors, after which the

vessels are tied and the sutures adjusted, leaving the drainage-tubes out at each angle.

One point of precaution is essential, namely, to avoid division of that part of the tendon of the tibialis anticus which is inserted into the internal cuneiform near its metatarsal articulation. One of the objections to this operation is the elevation of the heel, and the consequent depression of the stump by the action of the sural muscles,

which action is practically unopposed if the insertion of the tibialis anticus is divided. Should this occur, or should the heel be too greatly elevated, the tendo Achillis should be divided as in talipes equinas. The line of section through the internal cuneiform bone is shown in Fig. 202. This—the operation of Hey—is objectionable, for two reasons. In the first place, it cuts away a part of the bony framework of the foot, which need not be sacrificed; and, secondly, it severs the attachment of the tibialis-anticus muscle.

Through the Tarsus.—When removal of any part of the anterior row of tarsal bones is required, the following rules should be adopted: If the internal cuneiform is involved only on its anterior articular surface, it may be sawn through on the line of Hey (Fig. 202). If the middle or external cuneiform is involved only to a limited extent upon its anterior portion, as much as one fourth of an inch of this surface may be sawn or scraped off. Behind this limit a disarticulation from the scaphoid should be made. Through the cuboid the section should pass,

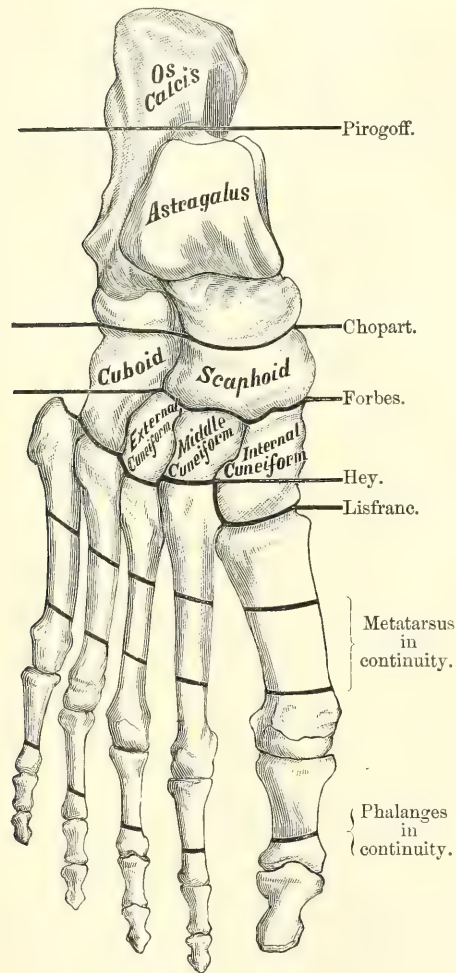


FIG. 202.

as first advised by Dr. S. F. Forbes, of Toledo, Ohio (who performed this operation in 1863), through the middle of this bone on the line of the anterior surface of the scaphoid (Fig. 202).

Forbes's Method.—Disarticulation of the three cuneiform bones from the scaphoid, and section of the cuboid parallel with the plane of the anterior surface of the scaphoid (Fig. 202). The dorsal and plantar incisions are slightly anterior to and practically the same as in Chopart's amputation. The dissection should be made closely from the bones, and

the flaps trimmed and adjusted as in the preceding operation. Section of tendo Achillis may be done later, if necessary.

Medio-Tarsal—Operation of Chopart.—The dorsal incision is begun on a level with and an inch posterior to the tip of the base of the fifth metatarsal bone (for the adult foot). This point is about one fourth of an inch behind the articulation between the cuboid and calcaneum (Figs. 199, 203).

With a slight forward convexity the incision is carried across the top of the foot to the posterior margin of the tuberosity of the scaphoid, and then directly back from one fourth to half an inch (Fig. 198). The skin, tendons, vessels, and nerves are divided on this line, and the flap lifted until the joints between the astragalus and scaphoid and the calcaneum and cuboid are well exposed.

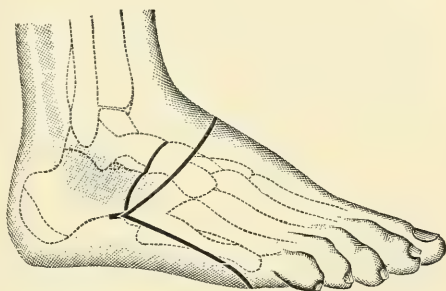


FIG. 203.

From the ends of this first incision a long plantar flap is fashioned by cutting forward, as in shaping the flap for the operation of Lisfranc (Figs. 198, 199). Disarticulation is effected with a short, strong scalpel, while forcible extension is employed. The flaps are now to be properly trimmed, and the vessels secured. Division of the tendo Achillis may be done later. When required, this operation may be modified by sawing off the anterior half-inch of the astragalus and calcaneum. The incisions are practically the same.

Calcaneo-Astragaloid Disarticulation.—This operation was first suggested by Lignerolles, first performed by Textor, but brought into prominence by Malgaigne. When in an amputation of the foot at the medio-tarsal joint it is discovered that the *os calcis* must also be removed, and if the astragalus is sound, the subastragaloid operation should be preferred to the amputation of Syme at the tibio-tarsal joint. By this method a shortening of about two inches is prevented, and, although the under surface of the astragalus is uneven, experience has shown that the pressure is safely distributed, and a useful stump results. Moreover, the degree of mobility maintained at the tibio-astragaloid articulation adds to the ease and comfort of locomotion.

Seize the foot with the left hand, and with a strong scalpel commence the incision by dividing the skin and tendo Achillis just at the level of the upper surface of the *os calcis*. From this point the incision is continued along the fibular side of the foot forward, dividing everything down to the bone, and curving slightly downward until, as it passes below the tip of the external malleolus, it is four tenths of an inch below this point (Fig. 204). The line of incision is now carried directly forward until near the tuberosity at the base of the fifth metatarsal bone, where it curves to the dorsum of the foot, crossing to the inner side over the anterior edge of the scaphoid, and then straight down and under the foot a half-inch beyond the middle of the sole (Figs. 205, 206). From this point a straight incision is made directly back to the point of beginning at the inner edge of

the tendo Achillis (Fig. 206). Lift the plantar flap by deep and careful dissection from the bone, leaving nothing but the periosteum, until the

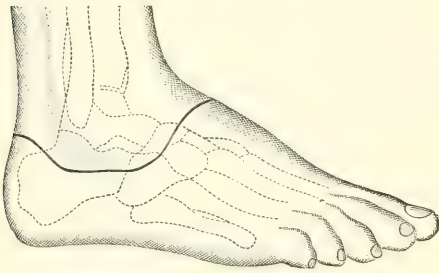


FIG. 204.—(After Malgaigne.)

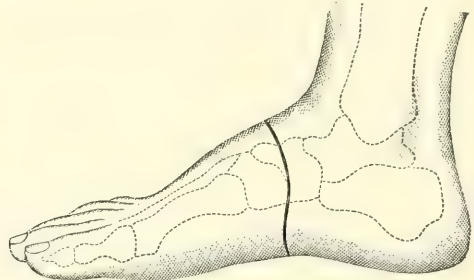

FIG. 205.—(After Malgaigne.)

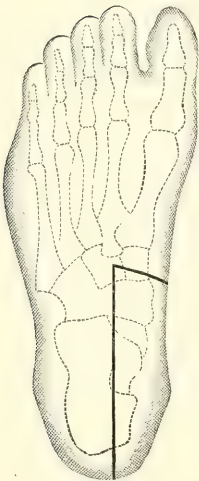


FIG. 206.—(After Malgaigne.)

calcaneo-astragaloid articulation is well exposed. The flaps being held by an assistant, the disarticulation is begun by opening the astragalo-scaphoid joint and removing the anterior part of the foot at the mediotarsal joint. The *os calcis* should now be seized with a lion-tooth forceps, and the disarticulation of this bone effected. The exposed tendons should be smoothly divided with the scissors at the higher portions of the incision. After deligation of the vessels the flap is properly trimmed and sutured, the cicatrix falling upon the dorsal and external lateral aspects of the stump.*

* Hancock's modification of this procedure, or the subastragaloid-osteoplastic amputation, is as follows: One incision begins beneath and at the posterior angle of the outer malleolus, and is carried along the outer surface of the foot to a point a half-inch anterior to the projecting base of the fifth metatarsal bone. A second incision is made

along the inner border of the foot, commencing posteriorly about the center of the internal malleolus and terminating anteriorly at a spot opposite the end of the external incision. The anterior ends of both cuts are joined by a curved incision made with its convexity forward across the plantar aspect of the foot, and dividing all the tissues well down to the bone. Reflect this flap back as far as the projections at the under surface and in front of the tuberosity of the *os calcis*; and make a fourth incision across the dorsum of the foot immediately behind the head of the astragalus. Apply the saw upon the under surface of the calcaneum a little anterior to its center, and cut through the bone obliquely from below upward and backward (Fig. 207).

With the knife enter the mediotarsal joint, pass the instrument under the head of the astragalus, and, cutting from before backward, sever the interosseous ligament and detach the anterior part of the foot, together with the segment of the *os calcis*. Saw off the head of the astragalus, and with a sharp bone-cutter (or saw) remove the two articular cartilages (and a thin slice of bone) from the under surface of the astragalus. As the flaps are adjusted, the sawn surface of the calcaneum is brought into apposition with the under surface of the astragalus. See "Lancet," September, 1866, p. 257.

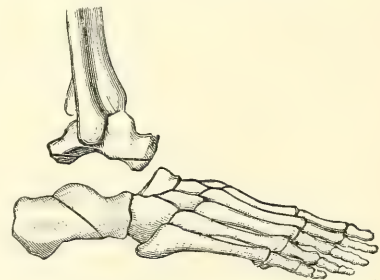


FIG. 207.—Section of *os calcis* and astragalus in Hancock's operation.

Amputation of the Foot—Tibio-Tarsal (Syme's).—When the astragalus must be removed, together with the foot, the amputation of Syme, which involves a disarticulation of the tibio-astragaloid joint, and a subsequent section of the articular surfaces of the tibia and fibula, should be made. In its successful performance certain precautions are necessary, chief among which is the preservation of the proper vascular supply to the posterior flap. The failure to appreciate the importance of making the plantar incision far enough forward, as laid down by Syme, has brought this procedure somewhat into disrepute, for Prof. Stephen Smith, in his comprehensive report, says the necessity for re-amputation is 3 per cent greater in this than in any other amputation.

In my "Prize Essay," published in 1876,* I demonstrated that the arterial distribution to the calcaneo-plantar flap was chiefly derived from the external plantar artery, and from the posterior tibial so near the bifurcation of this vessel into its terminal branches, that any line of incision in the formation of this flap which necessitated the application of a ligature at or very near its bifurcation was not justifiable. I do not doubt that the sloughing so often met with at this point is caused by carrying this incision too far back toward the tuberosity of the calcaneum. The arterial supply is shown in Fig. 208, from my "Essays in Surgical Anatomy and Surgery." †

Modified Procedure.—With the foot held at an angle of 90° to the axis of the leg, place the thumb at the tip of one malleolus, and the index at the other, and from the center of the malleolus internus carry an incision directly across the sole of the foot to a point one fourth of an inch anterior to the tip of the malleolus externus. This incision should divide all the tissues to the bones, and, as will be seen in Figs. 209 and 210, its perpendicular portion descends in a direction slightly anterior to

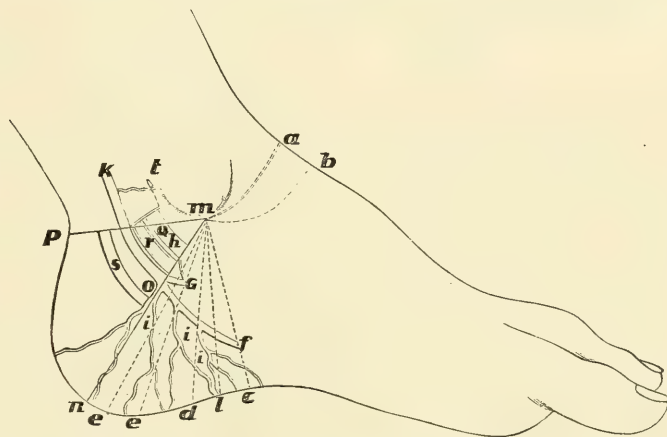


FIG. 208.—Diagram showing the arterial supply to the calcanean region, on the tibial side of the foot. (Drawn by the author, from the average of eighty-seven dissections.) *m*, Internal malleolus. *pmcn*, Tibio-tarsal quadrilateral, the surgical region of this articulation. *k*, Posterior tibial artery. *o*, Its point of bifurcation into *g*, Internal plantar, and *f*, External plantar artery. *iii*, Calcanean branches of external plantar. *t*, Articular branches from posterior tibial. *h*, Articular branch from internal plantar. *g*, Tendon of tibialis posterior muscle. *r*, Tendon of flexor longus digitorum. *s*, Tendon of flexor longus pollicis. *mc*, The line of incision of Gross. *ml, md, me, me*, Lines of incision showing that the nearer the incision approaches the heel, the more danger is incurred of cutting off the principal blood-supply to the calcanean flap, in amputation. *mn*, Line crossing the usual point of bifurcation of the posterior tibial. *ma, mb*, Anterior incision.

* "American Journal of the Medical Sciences," April, 1876.

† William Wood & Co., 1879.

the axis of the tibia. The ends of this cut are united by a second, which arches sharply upward about on the line of section of the bones, and should also divide tendons and all intervening structures, opening into the joint. The foot should now be firmly grasped and extended, so as

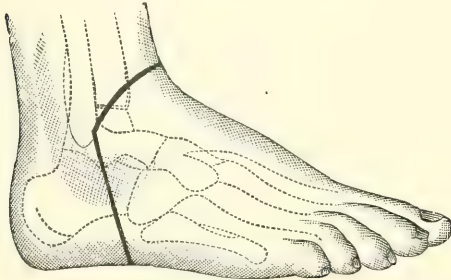


Fig. 209.

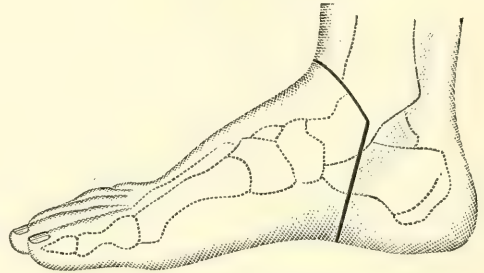


Fig. 210.

to make tense the anterior ligament of the ankle, which is easily divided. Carrying the knife to either side of the articular surfaces of the astragalus, the lateral ligaments are cut, and the joint thus widely exposed. An assistant now holds and depresses the foot, while the operator carefully dissects the tissues closely from the astragalus and calcaneum. Care should be taken not to bruise the flap by too great traction. In dissecting along the inner surface of the ankle, the knife should be kept close to the bones, so that when the lesser process of the calcaneum is reached it will slide behind and under this process, passing between it and the flexor tendon and the vessels. If this precaution is not taken, the arteries may be wounded and the nutrition of the flap seriously im-

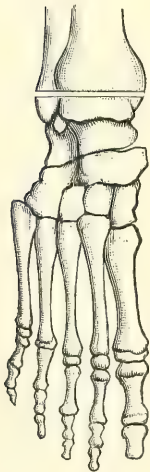


Fig. 211.

paired. As the dissection proceeds, the foot is further depressed, and the tendo Achillis separated from its insertion into the tuberosity of the calcaneum, in doing which care must be taken not to button-hole the flap. The posterior portion of the *os calcis* may now be brought through the joint, and the dissection continued in this direction or finished by working back along the under surface of this bone. After the foot is removed, the flaps are lifted from the tibia and fibula until a section of these bones can be made just on the level of the anterior articular margin of the tibia (Fig. 211). It is not necessary to remove the articular surface. The flaps should now be

trimmed and fitted, and the vessels tied. As the sutures are applied, it will be noticed that there is a redundancy of tissue in the long flap, leaving a cup-shaped cavity; but this can be thoroughly drained from the angles of the wound, and disappears when the stump is healed (Fig. 212).



Fig. 212. — Stump after Syme's amputation. (After Malgaigne.)

Syme's amputation at the ankle has been modified by the osteoplastic operations of Pirogoff, Le Fort, Gunther, and others.

Pirogoff's Method.—The dorsal and plantar incisions are made from the same points, and are practically the same as in Syme's amputation. However, in order to avoid redundancy of the soft tissues and to expose the calcaneum back to the line of section of this bone, the lower incision

should, when it reaches the sole of the foot, be carried back about three fourths of an inch nearer the heel than in Syme's method. The dorsal incision does not ascend so high upon the ankle by the same distance. The joint is opened through the anterior incision, and the lateral ligaments divided until the anterior upper surface of the *os calcis* can be displaced forward through the articulation, when it is sawn through on

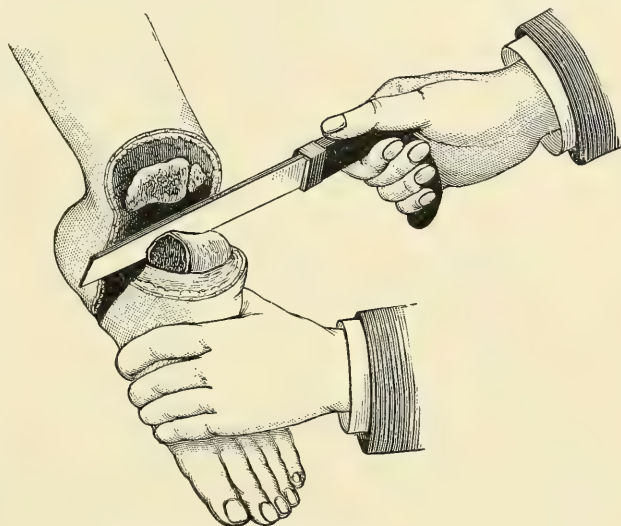


FIG. 213.—(After Esmarch.)

the line indicated in Fig. 214, the instrument running parallel with the edges of the incision. The soft parts are now carefully lifted from the articular ends of the tibia and fibula, and these bones divided horizontally so that all the articular cartilage is removed by the section. The angle described by these two lines of section is about 90° (Fig. 214). The flaps are adjusted so that the plane of the calcaneum is brought snugly

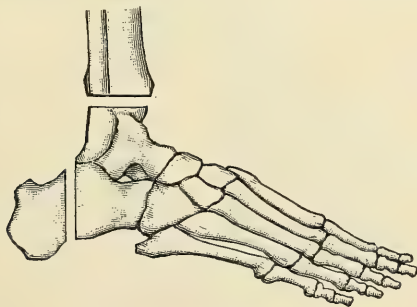


FIG. 214.—(After Esmarch.)

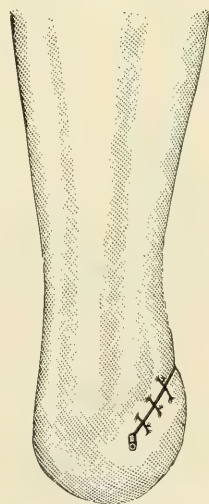


FIG. 215.—Stump after Pirogoff's amputation. (After Malgaigne.)

in apposition with that of the tibia and fibula. The drainage should be from the dependent angles of the wound (Fig. 215).

Le Fort's Method.—Three fourths of an inch below the external

malleolus commence an incision which is carried directly forward to within half an inch of the calcaneo-cuboid articulation. From this point it describes a curve with an anterior convexity over the dorsum of the foot, following the line of the astragalo-scaploid joint until the inner border of the foot is reached (Fig. 216), when it is carried back and ended at a point about one inch in front of the tip of the internal malleolus, which point is directly between the tuberosity of the scaphoid and the tip of the mal-

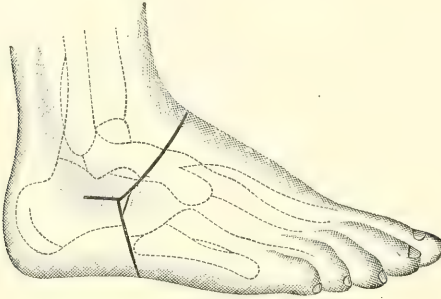


FIG. 216.—(After Le Fort.)

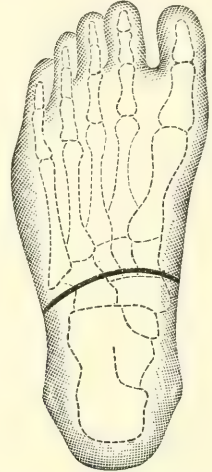


FIG. 217.—(After Le Fort.)

leolus. From the anterior limit of the straight incision below the external malleolus describe a plantar flap also with a forward convexity across the sole of the foot, as shown in Fig. 217. Dissect up the dorsal flap, in order to expose the tibio-tarsal joint, taking great care in lifting the inner angle not to wound the tibial and plantar arteries. The disarticulation of

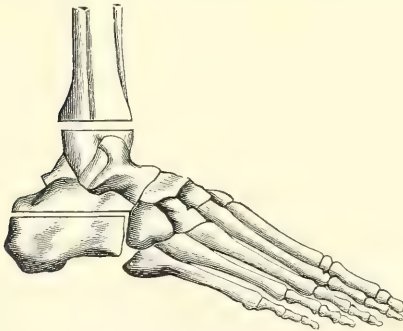


FIG. 218.—(After Le Fort.)

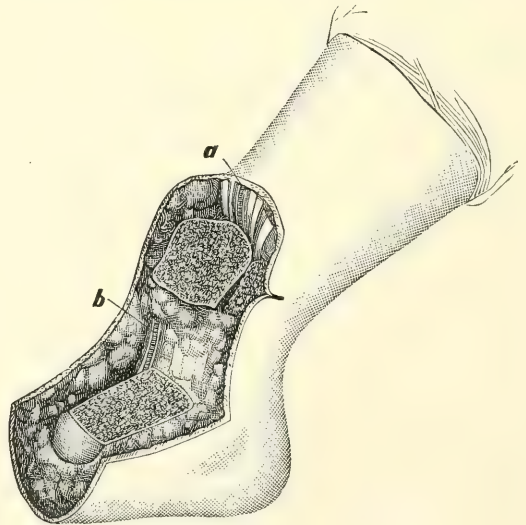


FIG. 219.—(After Le Fort.)

the astragalus from the calcaneum is next effected by introducing a thin knife from the fibular side between these bones, and dividing the interosseous ligament. Then remove the front of the foot at the medio-tarsal joint, and complete the disarticulation of the astragalus, and with the saw remove the upper segment of the calcaneum on the level of its articular surface (Figs. 218, 219). The tibia and fibula

are now horizontally divided just at the level of the articular plane of the tibia, as in Syme's operation (Fig. 212). In adjusting the flaps, the sawn surface of the calcaneum is brought into apposition with that of the tibia (Fig. 220). Or, having exposed the tibio-tarsal joint, divide the ligaments, disarticulate, as in Syme's operation, and, having drawn the astragalus and calcaneum forward until the upper



FIG. 220.—Stump after Le Fort's amputation. (Le Fort.)

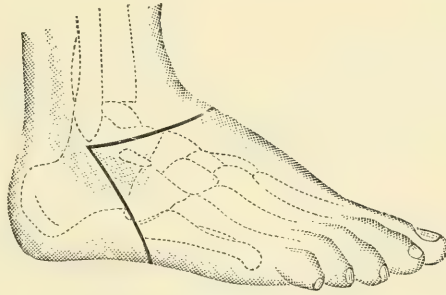


FIG. 221.

portion of the *os calcis* is exposed, insert a key-hole saw behind the tuberosity, and saw through this bone on the line already indicated.

Gunther's modification of this procedure is shown in Figs. 221, 222, 223, 224, 225, taken from Esmarch's hand-book, and the crescentic section

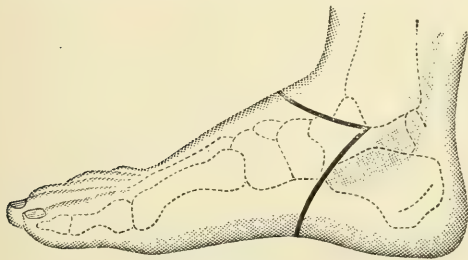

FIG. 222.

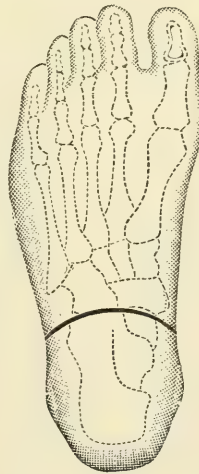


FIG. 223.

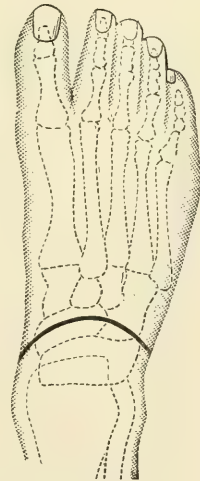


FIG. 224.

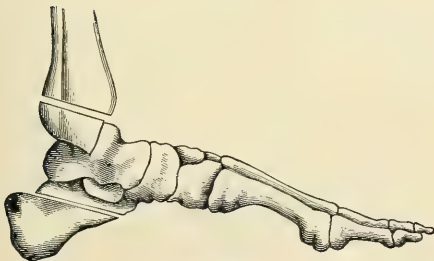


FIG. 225.

of the bones, as practiced by P. Bruns, is seen in Fig. 226, from the same source.

Summary.—In amputations of the foot the following rules should be observed: The terminal phalanges of all the toes should be removed by disarticulation when it becomes necessary to remove a portion of the entire thickness of these bones. The same rule applies to all the second

phalanges, except that of the great toe, which should be sawn through at any point anterior to its middle. If a section posterior to this is required, disarticulate from the metatarsal bone. What has been said of

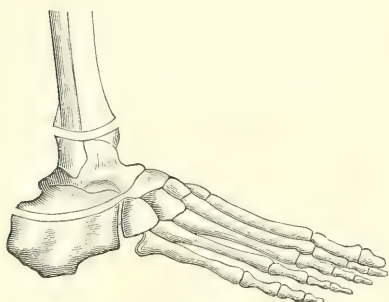


FIG. 226.

the second phalanx of the great toe applies with equal force to the proximal phalanges of all the other toes.

None of the metatarsal bones should be disarticulated from the tarsus when a section is possible not less than three fourths of an inch anterior to each tarso-metatarsal joint.

When a section posterior to this line is required, a tarso-metatarsal disarticulation should be effected. *Hey's* operation is only justifiable when the

anterior face of the internal cuneiform is diseased. As much as the anterior fourth of each cuneiform bone, and the anterior half of the cuboid, may be sawn off, in preference to the sacrifice of the bony frame-work, by Forbes's or Chopart's operation.

When the cuneiform bones must be removed, and the posterior half of the cuboid is sound, Forbes's operation should be preferred to Chopart's. Chopart's procedure is next in order. The sub-astragaloid operation should always be preferred to a tibio-tarsal (*Syme's*) amputation. If the condition of the parts is such that the vitality of the flap is assured, the operations of *Le Fort* and *Pirogoff*, carefully and skillfully done, should be preferred to the tibio-tarsal disarticulation.

Even at the risk of a second operation being required, an effort to preserve the greatest possible portion of the foot is justifiable, except when it may seriously threaten the life of the patient. The value of a surface accustomed to pressure can only be thoroughly appreciated in the after-adjustment of an artificial apparatus.

Leg.—Amputation at any portion of the leg above the line of section, in *Syme's* operation, should be made by one of two methods.

1. *Modified Circular Skin-Flap.*—At a sufficient distance beyond the point at which the bones are to be divided make a circular cut through to the deep fascia, split the flap directly over the fibula, up to the point of section through the bones, and carefully dissect up the cuff. When the flap is reflected, at the level of its base divide all the soft tissues squarely down to the bones, which are next sawn through. The spine of the tibia should be trimmed down, to prevent too acute pressure and sloughing of the skin at this point, a not infrequent occurrence when this precaution is omitted. The drainage is at the fibular side, and, as the leg should be elevated, the tube should come out at the highest point of the perpendicular incision. When the bones are sawn through within six inches of the knee-joint, the remainder of the fibula should be excised.

2. *Method of Prof. Stephen Smith.*—Commence an incision in the center of the anterior surface, and carry it downward along the side of

the leg, so as to make a slightly curved flap, with its convexity below ; when the incision passes over the prominent part of the leg toward the posterior surface, incline it upward until the middle of the limb is reached, where it should be continued directly up to the point at which the bone is to be divided ; make a similar incision on the opposite side (Fig. 227) ; the flaps, consisting of the skin and fascia, are dissected up-

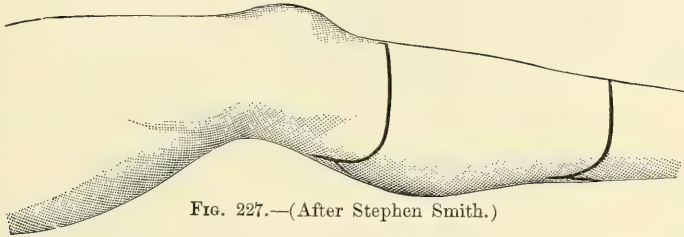


FIG. 227.—(After Stephen Smith.)

ward about an inch, at which point the muscles are divided squarely down to the bones. After the bones are divided, the hood is brought over the stump and sutured, leaving the drainage at the upper part of the posterior incision.

In very emaciated subjects, to forestall the liability of sloughing in the flaps, the first circular cut should go directly through all the tissues down to the bones, and the perpendicular incision along the fibula also down to this bone. All the tissues should then be lifted closely from the periosteum and interosseous membrane, forming a solid flap, reflected up to the point at which the bones are to be divided.

When the line of amputation approaches nearer than three inches from the upper articular surface of the tibia, a complete disarticulation at the knee should be performed. At or below this point the upper portion of the bone should be preserved, and the fibula exsected. After recovery from the operation it will be found that the tibia is flexed upon the femur, so that, in the adjustment of an artificial limb, the chief pressure may be comfortably borne upon the normal tissues in front of the patella and the tuberosity of the tibia. The greater pressure in any prothetic apparatus used after amputation, at or above the knee, falls upon the ischio-perineal region.*

* The older operations, which consisted in making a long and a short flap on opposite sides of the leg, are now fallen into general disuse. The requirements will be better fulfilled by any one of the methods already described than by the more complicated methods of Teale, Lee, Sedillot, and others.

Method of Teale—Long and Short Rectangular Flaps.—The long flap, folding over the end of the bone, is formed of parts generally devoid of large blood-vessels and nerves, which structures are left in the short flap. The size of the long flap is determined by the circumference of the limb at the place of amputation, its length and breadth being each equal

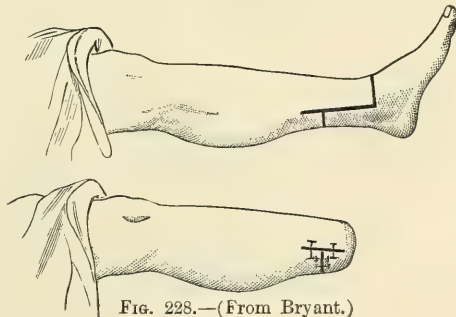


FIG. 228.—(From Bryant.)

the circumference of the limb at the place of amputation, its length and breadth being each equal

Knee-Joint.—First Method—Modified Circular Skin-Flap.—About three inches below the patella make a circular sweep around the leg,

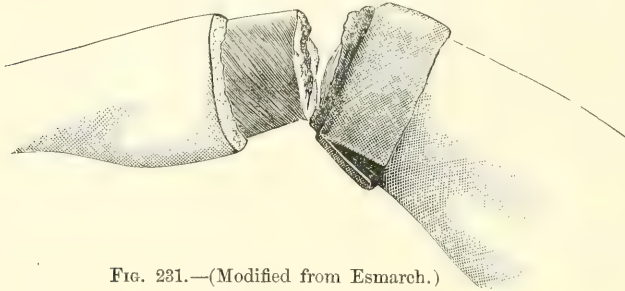


FIG. 231.—(Modified from Esmarch.)



FIG. 232.—(After Esmarch.)

dividing the skin and fascia. Join this by a perpendicular incision in the middle line of the posterior aspect of the limb, extending through the skin and fascia, and at least as high as to the level of the top of the patella. Dissect

the skin back carefully, keeping close to the anterior surface of the patella, as the skin over this bone is usually very thin. It is not necessary to dissect the cuff as high on the lateral and posterior aspects as in front, since the anterior incision is made to allow

to half the circumference of the limb at this point. The short flap is one fourth as long as the other. The incisions and stump, after Teale's method, are shown in Fig. 228.

Sedillot's Method—Long Fibular, Short Tibial, Flap.—Opposite the point at which the bones are to be divided insert a long, thin, amputating-knife, the point of which shall graze the spine of the tibia and the outer surface of the fibula, and come out through the outer

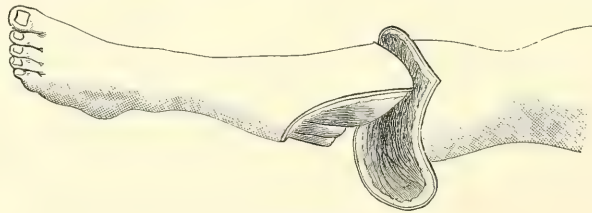


FIG. 229.

aspect of the calf. Cut downward close to the bones, and make a long, rounded flap. The short flap is made by an incision with a slight downward convexity (Fig. 229).

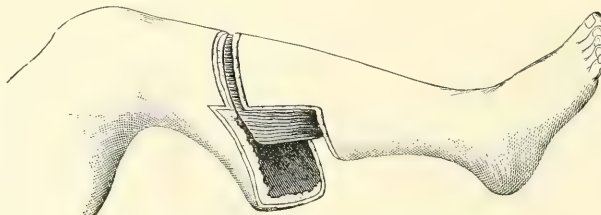


FIG. 230.—(Ashhurst's "Encyclopædia.")

Lee's Method.—The length of the flaps is determined as in Teale's amputation. The long flap is posterior, and includes the skin and sural muscles. The deep muscles and the vessels are divided squarely at the base of the flap (Fig. 230).

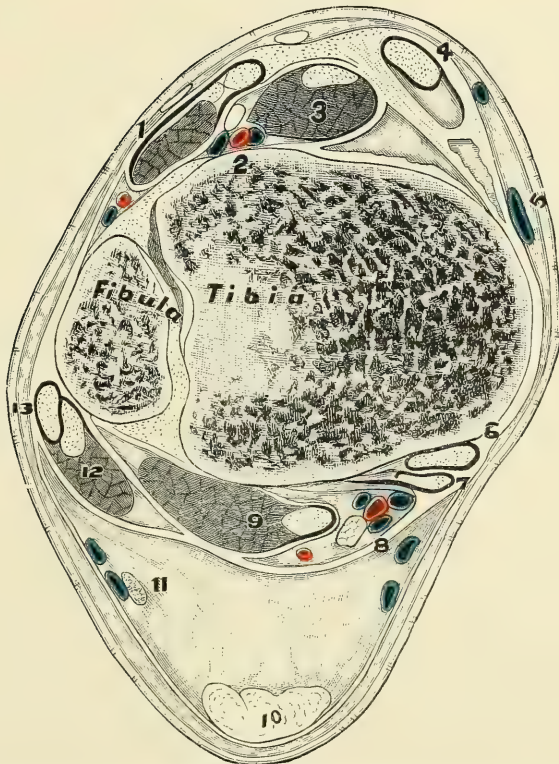


FIG. 233.—Transverse section of the right leg just above the ankle-joint, showing the relation of the parts on the plane of section through the malleoli in Syme's, Pirogoff's, Le Fort's, Gunther's, and Bruns's amputations. Looking at the surface nearest the body. 1, Extensor longus digitorum. 2, Anterior tibial vessels and nerve. 3, Extensor proprius pollicis. 4, Tibialis anticus. 5, Internal saphena vein. 6, Tibialis posticus. 7, Flexor longus digitorum. 8, Posterior tibial artery, veins, and nerve. 9, Flexor longus pollicis. 10, Tendo Achillis. 11, External cutaneous nerve. 12, Peroneus brevis. 13, Peroneus longus.

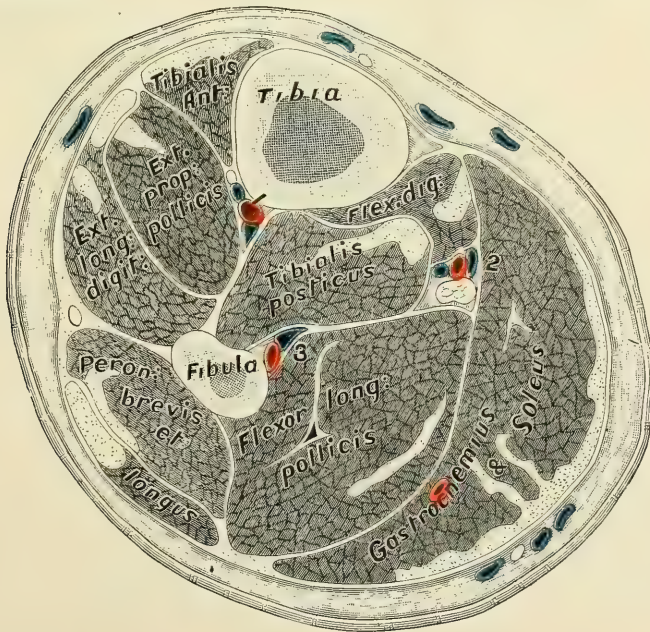

FIG. 234.—Section through lower third of right leg. Looking toward the center. 1, Anterior tibial nerve, artery, and veins. 2, Posterior tibial artery, veins, and nerve. 3, Peroneal artery and veins.

of the removal of the patella and dissection of the synovial sac just above it. Divide the tendon of the quadriceps at the upper limit of the patella, turn this down, cut the lateral ligaments and capsule along the edges of the condyles of the femur, flex the leg strongly on the thigh, divide the crucial ligaments, and, as soon as the posterior ligament of Winslow is exposed, introduce a long knife and remove the leg by cutting squarely through the soft tissues at the back of the articulation (Fig. 231). A cloth retractor is now applied and a slice of bone

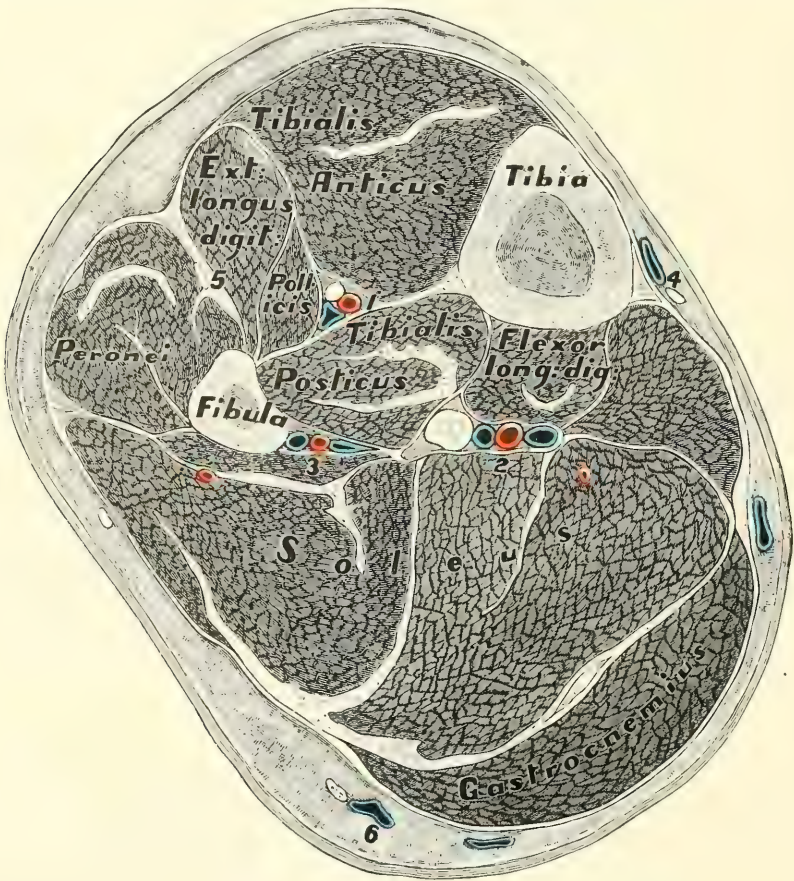


FIG. 235.—Section through the middle of the right leg. Looking from below upward. 1, Anterior tibial artery, veins, and nerve. 2, Posterior tibial artery, veins, and nerve. 3, Peroneal artery and veins. 4, Long saphena vein and nerve. 5, Musculo-cutaneous nerve. 6, Short saphena vein and nerve.

removed with the saw, leaving a smooth surface. Should the articular end of the femur be diseased, the section may be made high enough to remove this, provided the saw does not enter the medullary canal. With the cutting-forceps round off the sharp edges of bone, tie the vessels, and close the flap as in Fig. 232.

Second Method (Operation of Prof. Stephen Smith).—With a large scalpel commence an incision about an inch below the tubercle of the tibia, and cut to the bone; carry it downward and forward beyond the curve of the side of the leg, thence inward and backward to the middle

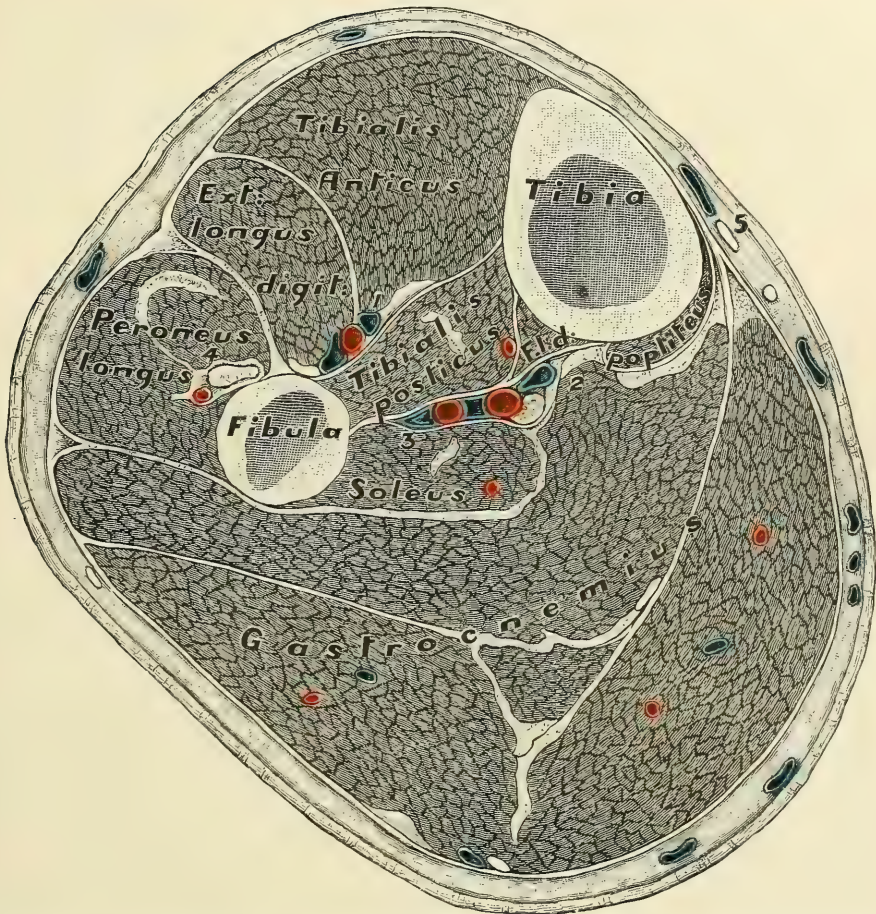

FIG. 236.—Section through upper third of right leg. Surface nearest the body. 1, Anterior tibial vessels and nerve. 2, Posterior ditto. 3, Peroneal vessels. 4, Musculo-cutaneous nerve. 5, Internal saphena vein and nerve.

of the leg, thence upward to the middle of the popliteal space; repeat this incision upon the opposite side; raise the flap, consisting of all the tissues, down to the bone until the articulation is reached, divide the ligaments, and remove the leg as in the previous operation (Fig. 237). The flap should be lifted from the patella, and this bone removed.

“Care should be taken that the incision is inclined moderately forward down to the curve of the side of the leg, to secure ample covering for the condyles, and that upon the internal aspect it should have additional fullness for the purpose of insuring sufficient flap for the internal or larger condyle” (Smith).*

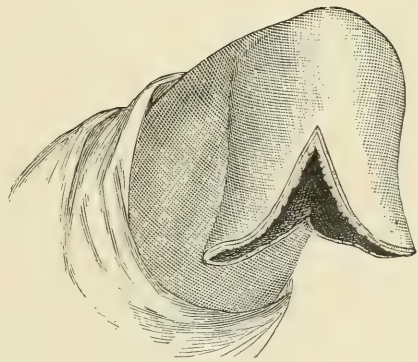


FIG. 237.

* The method of Carden—namely, long anterior skin-flap, and the short posterior skin and muscular flap, made by the long knife carried through the joint—is inferior in every respect to

After the flaps are stitched the drainage-tube makes its exit through the upper posterior angle of the wound.

When in amputation near the knee the femur is the seat of osteomyelitis, the indications are to thoroughly cleanse the canal by means of a long Volkmann's spoon and irrigate with sublimate solution; introduce a long drainage-tube the full length of the canal and bring this out through the flap exactly in line with the axis of the canal (Fig. 237 A).

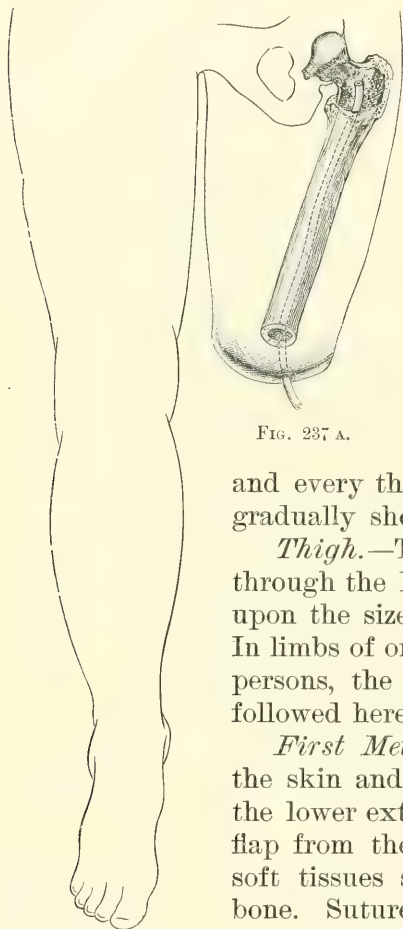


FIG. 237 A.

In this way the danger of a higher amputation is avoided and a longer stump secured. In two instances of amputation just above the knee, after exsection of this joint in which osteomyelitis occurred in the femur, I carried out this practice successfully.

Irrigation through the tube should be practiced about the seventh day and every three or four days after this, and the tube gradually shortened.

Thigh.—The method to be selected in amputations through the lower two thirds of the thigh will depend upon the size of the member at the point of election. In limbs of ordinary size, and particularly in emaciated persons, the operation advised in the arm should be followed here.

First Method.—Make a circular incision through the skin and fascia, joined by a perpendicular cut on the lower external aspect of the limb. Dissect up the flap from the muscles, and divide all the remaining soft tissues squarely at the point of section of the bone. Suture the flap, and drain from the outer upper (and, if necessary, lower) angle.

Second Method.—Below the line of section through the femur, at a distance sufficient to furnish an ample flap, by a circular incision divide the integument down to the muscles, allow the skin to retract, and at the line of retraction divide the remaining soft tissues down to the bone.

either of the foregoing operations. Carden recommended section through the condyles. Gritti introduced an osteoplastic modification by making a long rectangular skin-flap from the front of the knee and leg, which is dissected up deeply, lifting the patella in the flap. Behind, a short flap is made similar to that in *Carden's* method. Section is made through the bone about an inch above the tip of the internal condyle, and the articular surface of the patella is then sawn off. This procedure may be best accomplished by grasping the flap with the left hand and stretching it over the knuckles, so that the articular surface of the patella looks directly upward, where it is fixed quite immovably. As the flaps are adjusted, the sawn surface of this bone is brought into contact with that of the femur. Some operators secure it here by transfixing with an ivory pin. The whole procedure is not only difficult and tedious, but wholly unnecessary.

On the anterior and external aspect of the thigh, by a perpendicular incision extending as high as the point of section of the bone, divide everything to the bone, and from the periosteum, with a dry dissector, lift the solid flap. Apply the cloth retractor and saw through the bone. As the stump is placed in an elevated position, with the thigh also

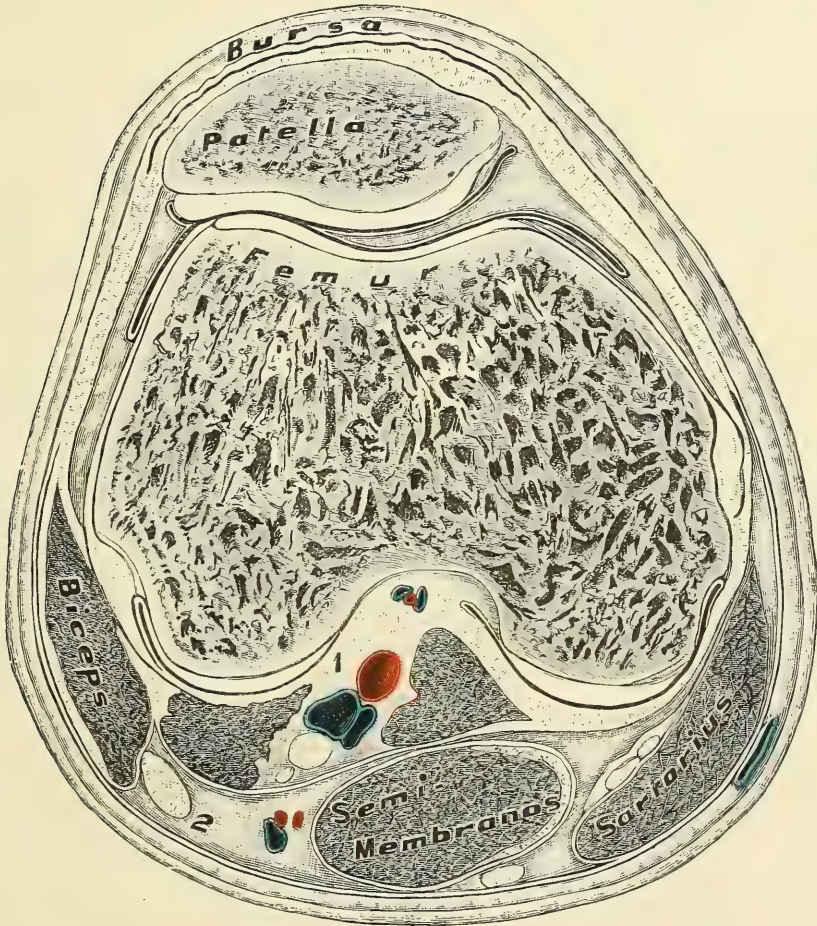


FIG. 238.—Section through the right femur at the condyles and at the middle of the patella. Looking at the central surface as exposed after amputation at this point. 1, Popliteal artery, vein, and internal popliteal nerve. 2, External popliteal or peroneal nerve. The capsule and the synovial cavities are admirably shown, as well as the *bursa mucosa patellae*.

abducted and rotated outward, the drainage is naturally at the upper angle of the perpendicular incision.

At the Hip.—Proceed as follows: Place the patient so that the hip at which the operation is to be performed projects well over the corner of the table. The member to be amputated is emptied of blood by elevation and the Esmarch bandage, and is held by an assistant while the opposite thigh is abducted and allowed to drop over the end of the table, the foot resting upon a stool. Hæmorrhage may in great part be controlled by placing a compress upon the iliac, as it runs along the rim of the pelvis, and holding this down and in position by a strong rubber

tube, carried obliquely around the groin from the perinæum, above the anterior spine, and over the crest of the ilium. An abdominal tourniquet should be applied, so as to compress the aorta at a point one inch to the left of the umbilicus. This need not be tightened unless compression below proves inadequate.*

Operation.—Half way between the anterior-superior spine of the ilium and the upper surface of the trochanter major (the extremity being held parallel with the axis of the body, and the foot normally everted) introduce a strong scalpel straight down to the bone, and by a single incision divide all the tissues along the head and neck, over the middle of the great trochanter, and down the outer aspect of the femur for three or four inches, and as much as six if possible, below the tip of the trochanter. Arrest the bleeding as the operation proceeds. Dissect the tendons

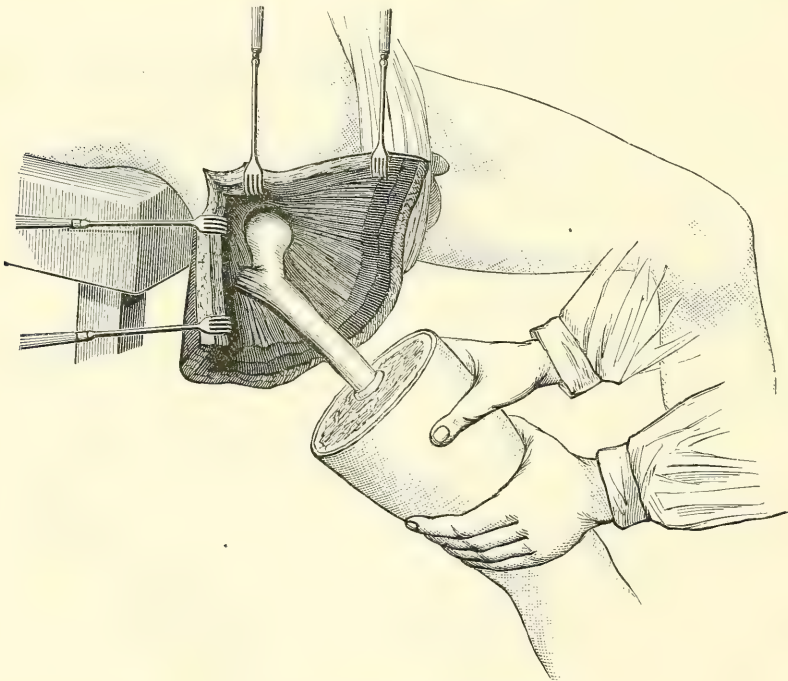


FIG. 239.—(Modified from Esmarch.)

from their insertion into and near the trochanter, using the cutting edge of the knife only when necessary, preference being given to lifting the soft parts from the periosteum and capsule with the dry dissector. With strong hook retractors the edges of the wound are separated, the joint exposed, the capsule and ligamentum teres divided, and disarticulation effected. The soft parts are now still farther lifted from the bone, to a point at least six inches below the trochanter. The entire mass of soft

* If no other means is at hand, the iliac may be compressed by introducing a padded staff into the rectum, and over this vessel as it runs along the pelvic rim.

Trendelenburg recommended transfixion by means of a round steel pin, which is passed between the head of the femur and the femoral vessels. Compression is maintained by the elastic bandage, thrown over the end in figure-of-8 fashion.

tissues is now constricted by a second elastic tube, or ligature, as close to the body as possible, and this intrusted to an assistant, whose hands also grasp that part of the flap in which the large vessels are located. At a point as low as possible, or about six inches from the trochanter, make a circular sweep around the thigh, dividing the skin, and allow this to retract. On this level the amputation is to be completed by passing a long knife behind the bone, cutting squarely back through all the remaining tissues (Fig. 239). As rapidly as possible all the larger vessels are grasped with forceps, after which the ligatures are applied. The drainage should be from the cavity of the acetabulum, out at the upper angle, and at each of the two lower angles of this stump.

Second Method.—Six or seven inches below the trochanter make a circular incision through the skin and fascia, and allow this to retract. At the level of the retracted skin divide all the tissues down to the bone, and saw through the femur at this level, as in Dieffenbach's procedure.

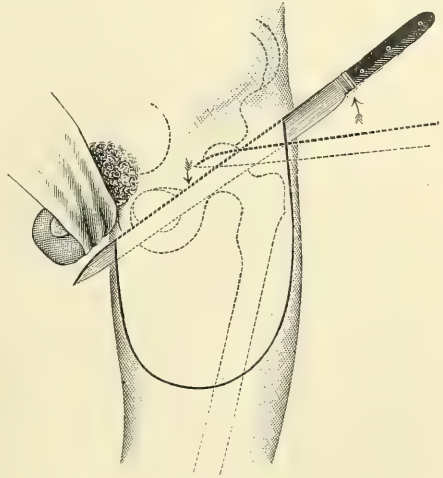


FIG. 240.—(After Esmarch.)

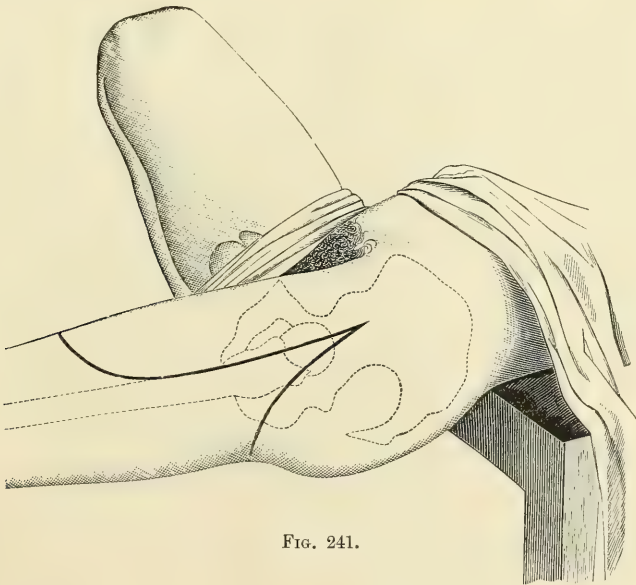


FIG. 241.

Secure all vessels at once, and disarticulate by the same incision as practiced in the preceding operation.

Third Method (Erskine Mason's Operation).*—The circulation is con-

* "New York Medical Journal," December, 1876.

trolled by the abdominal tourniquet, Esmarch's bandage having been applied up to the line of incision. About seven inches below the level of the joint make a circular incision through the skin, turn and dissect this up as high as the head of the femur. With the scalpel divide the

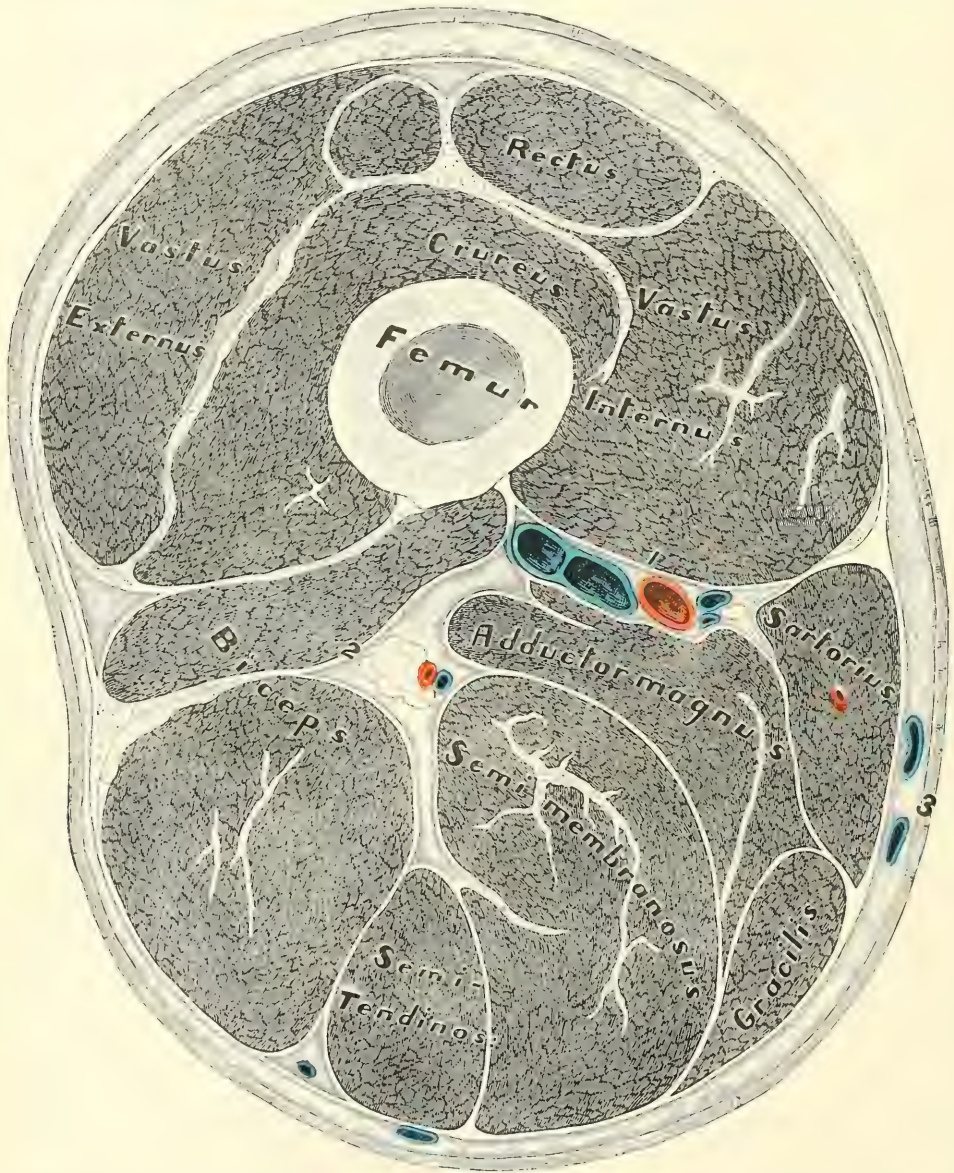


FIG. 242.—Section through right thigh at Hunter's canal. Looking at the surface attached to the body. 1, Femoral vessels and long saphenous nerve. 2, Great sciatic nerve and arteria comes. 3, Long saphena vein.

muscles on this plane, open the capsule, and dislocate the femur. The anterior vessels should be first secured.

Fourth Method—Transfixion.—A knife, the blade of which should be at least fifteen inches long, is introduced half-way between the trochanter major and the anterior-superior iliac spine, the thigh being

slightly abducted and the foot in the normal degree of eversion. The blade is held at an angle of 90° to the axis of the body, until the point is felt to strike and pass into the capsule of the joint, when the handle is elevated, so that the knife is parallel with Poupart's ligament, and so directed that its point will emerge on the inner aspect of the thigh, near the perinæum (Fig. 240). As the last step in this manœuvre is being effected the thigh should be slightly flexed on the abdomen, in order to

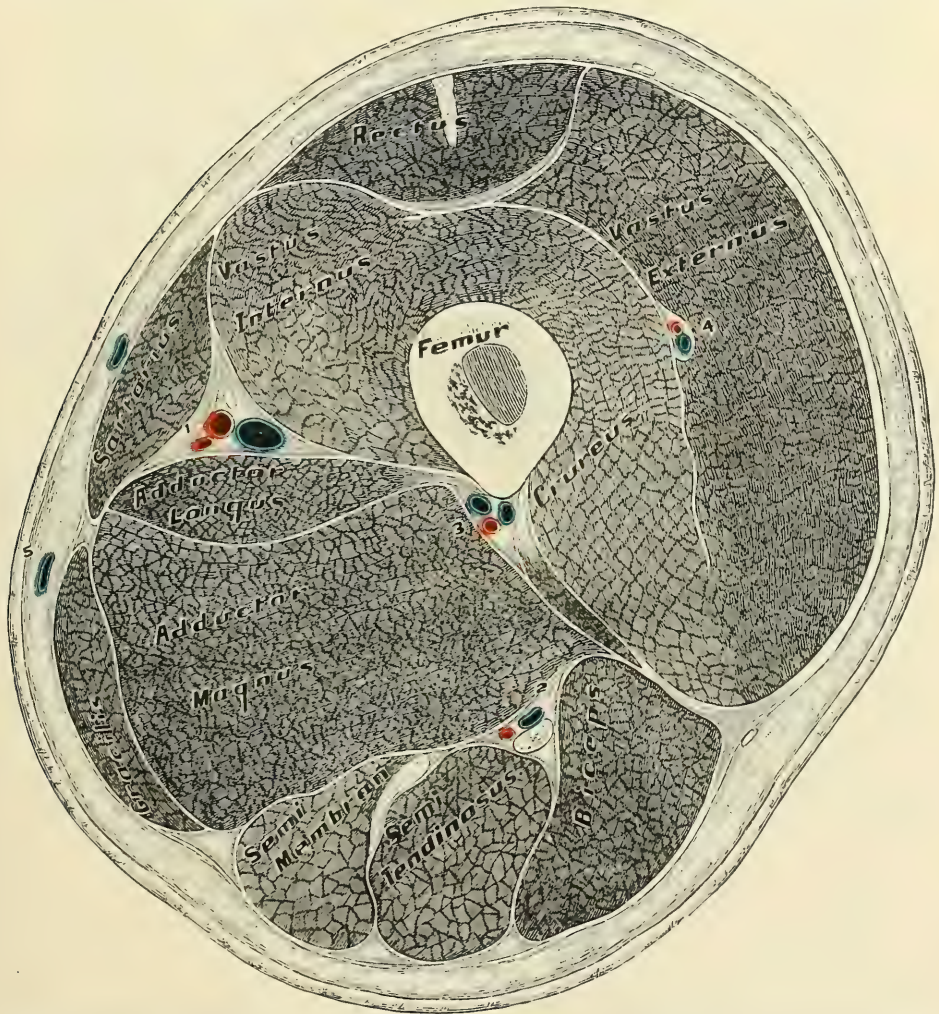


FIG. 243.—Section through left thigh at its middle. Looking at the surface attached to the body. 1, Superficial femoral artery, vein, and saphenous nerve. 2, Great sciatic nerve, and the arteria comes nervi ischiadici. 3, Terminal branch of profunda femoris. 4, Descending branch of external circumflex. 5, Long saphenous vein.

relax the tissues here and allow the knife to pass well beneath the great vessels. Two precautions are necessary, namely, not to push the knife-point into the obturator foramen, and also to avoid wounding the scrotum or labium. By to-and-fro sweeps of the knife, which is made to pass along upon the bone for about seven inches, a flap about eight inches in length is cut on the anterior and inner aspect of the thigh. As soon as

the knife shall have traveled downward a sufficient distance to permit it, an assistant should insert his middle- and index-fingers into the wound, and, with the aid of the thumbs applied externally, control the vessels by direct pressure. The two femoral arteries and veins should be at once secured.

The capsule should now be divided with a short, strong scalpel, the head of the bone forcibly luxated, the long knife laid across the wound behind the caput femoris, and a short flap formed by cutting along the

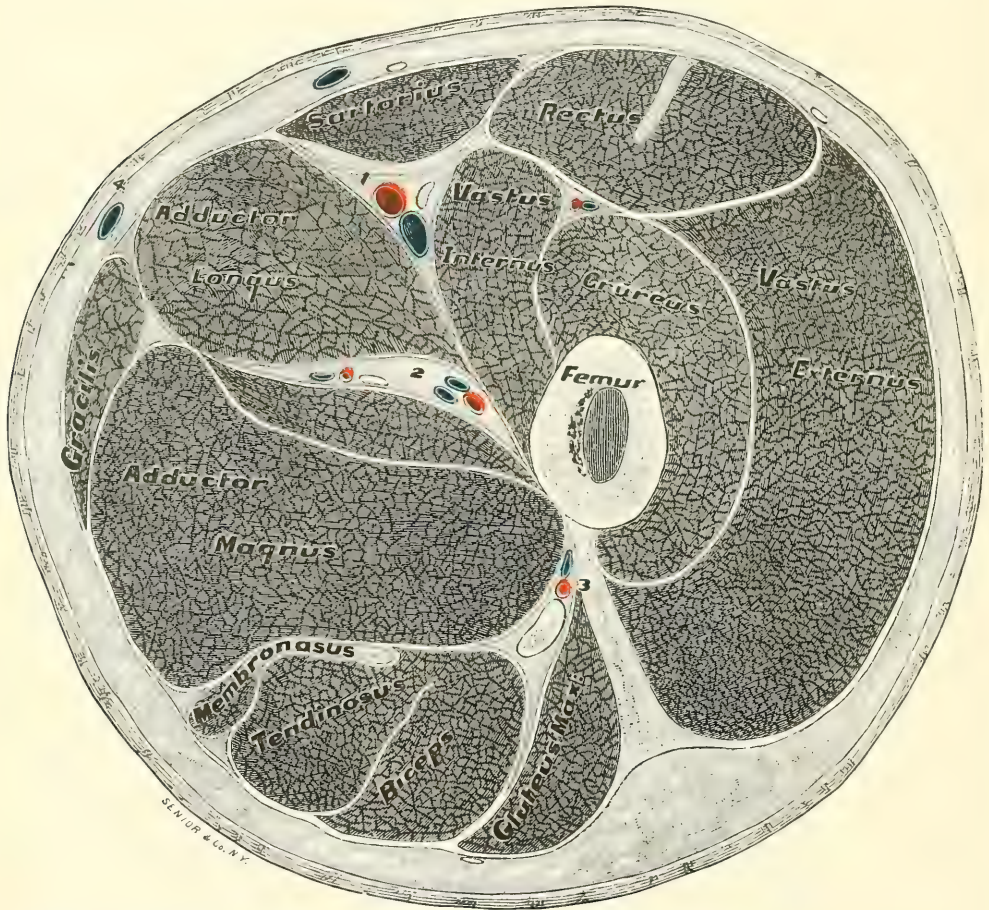


FIG. 244.—Section through left thigh in the upper third. 1, Superficial femoral artery, vein, and saphena nerve. 2, Deep femoral vessels; near by the obturator nerve and vessels. 3, Sciatic nerve and vessels.

posterior surface of the femur as far down as one inch beyond the gluteal fold (Fig. 241).

Of these various procedures at the hip, the first, although requiring more time for its performance, should be preferred, since the greatest of all dangers in this operation—hæmorrhage—is practically avoided. In fat subjects, or where the muscular development is very great, the procedure of Mason should be followed. When rapidity of execution is essential, the fourth, or transfixion method, is preferable.

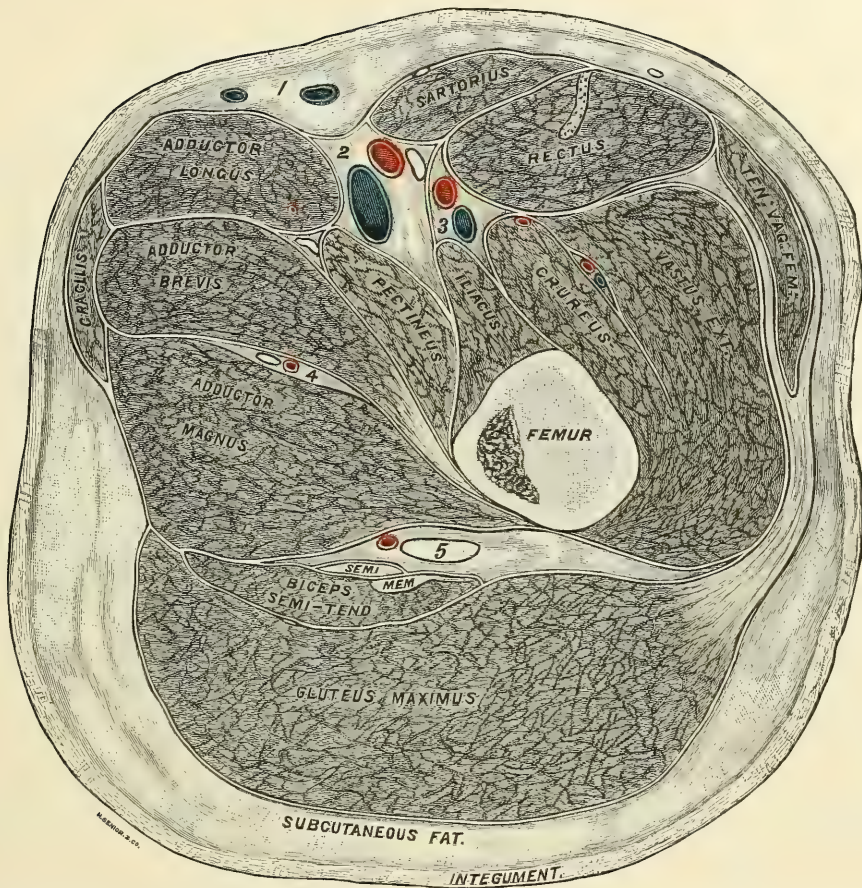


FIG. 245.—Transverse section of left thigh through lesser trochanter. Looking from below upward. 1, Saphenous vein. 2, Superficial femoral vein and artery. 3, Profunda femoral vein and artery, anterior crural nerve between the two arteries. 4, Obturator nerve and artery. 5, Sciatic nerve and artery.

NOTE.—The following summaries, compiled by Dr. F. C. Sheppard, are taken from Prof. Ashhurst's article in the "Encyclopædia of Surgery."* It is safe to assert that the improved methods of hæmostasis and antiseptics will yield a lighter rate of mortality, in both military and civil practice, than that shown by a study of these tables.

I. Summary of Two Hundred and Thirty-eight Cases of Hip-joint Amputation in Military Practice.

NATURE OF OPERATION.	Recovered.	Died.	Undetermined.	Total.	Mortality per cent.
Primary	7	89	0	96	92.7
Intermediate	4	59	0	63	93.6
Secondary	10	17	0	27	62.9
Reamputation of thigh-stump....	4	3	0	7	42.8
Not stated	5	39	1	45	88.6
Total number of cases.....	30	207	1	238	87.3

* William Wood & Co., New York, 1881.

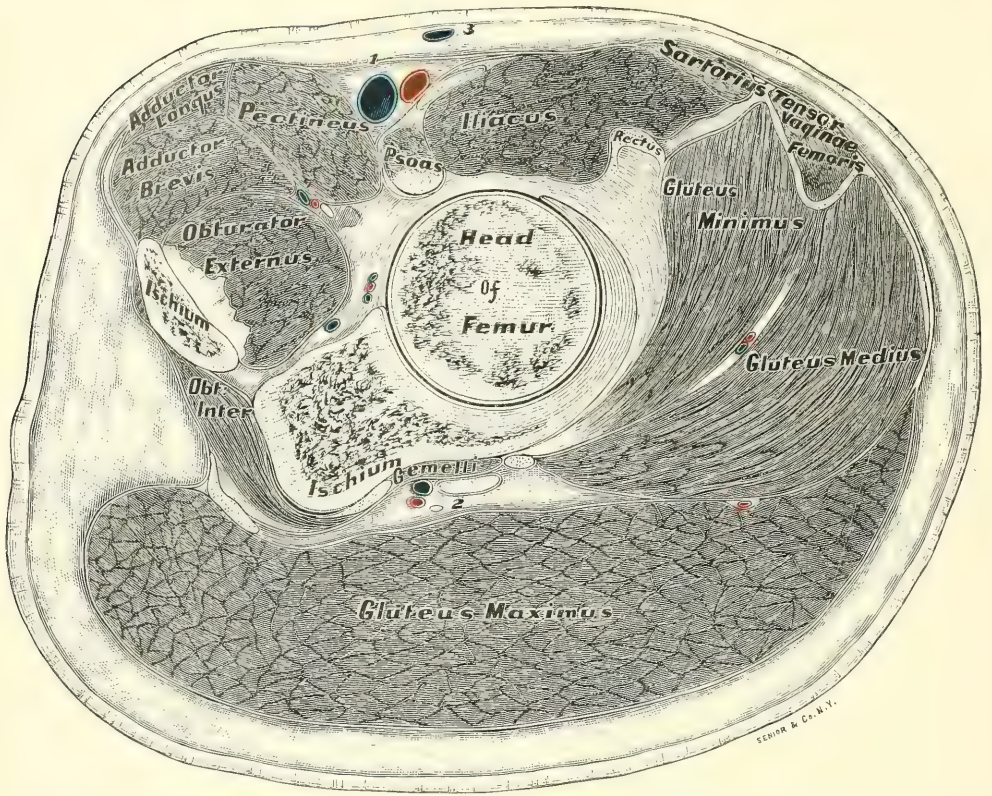


FIG. 246.—Section through the left hip. Looking from below upward. Reduced from life size. 1, Femoral vein, artery, and crural nerve in order from within outward. 2, Great sciatic nerve, artery, and vein. 3, Epigastric vein. 4, Vessels to acetabulum.

II. Summary of Seventy-one Cases of Hip-joint Amputation for Injury in Civil Practice.

NATURE OF OPERATION.	Recovered.	Died.	Total.	Mortality per cent.
Primary.....	6	25	31	80·6
Intermediate.....	5	7	12	58·3
Secondary.....	5	6	11	54·5
Reamputation of thigh-stump.....	4	1	5	20·0
Not stated.....	4	8	12	66·6
Total number of cases.....	24	47	71	66·1

III. Summary of Two Hundred and Seventy-six Cases of Hip-joint Amputation for Disease.

NATURE OF OPERATION.	Recovered.	Died.	Undetermined.	Total.	Mortality per cent
Amputation of entire limb.....	136	95	14	245	41·1
Reamputation of thigh-stump.....	20	10	1	31	33·3
Total number of cases.....	156	105	15	276	40·2

IV. *Summary of Forty-eight Cases of Hip-joint Amputation for Unknown Causes.*

	Recovered.	Died.	Undetermined.	Total.	Mortality per cent.*
Number of cases.....	10	34	4	48	77·2

V. *General Summary of Six Hundred and Thirty-three Cases of Hip-joint Amputation for all Causes.*

NATURE OF CASE.	Recovered.	Died.	Undetermined.	Total.	Mortality per cent.
Pathological.....	156	105	15	276	40·2
Traumatic.....	54	254	1	309	82·4
Cause unknown.....	10	34	4	48	77·2
Total.....	220	393	20	633	64·1

* Undetermined cases omitted in computing percentages.

CHAPTER IX.

THE SURGICAL DISEASES, AND SURGERY OF THE LYMPHATIC VESSELS, VEINS, AND ARTERIES.

THE LYMPHATIC SYSTEM.—LYMPHANGITIS.

THE pathological conditions in inflammation of the lymphatic vessels closely resemble those of the veins, with which they are intimately associated. The histology of the two systems is almost identical. One essential point of difference, and one which has a pathological significance, is that the lymphatic vessels are practically closed tubes, since at varying intervals in their route to the center each trunk breaks up into small and smaller branches, until they end in closed capillaries in the substance of a lymphatic gland. Although it is not yet positively proven that there is no direct communication between the afferent and efferent vessels, the weight of evidence is in favor of the theory that the vessels end and begin as closed tubes. It follows that whatever of septic or inflammatory matter may pass into these vessels, it can not rapidly enter the systemic circulation. Each lymphatic gland is a sieve which arrests its progress and modifies its effect. In the venous system, however, there is no resistance to rapid and direct systemic infection. We conclude, then, on anatomical grounds, as well as from clinical experience, that the effects of phlebitis are more rapidly felt, and in general more disastrous, than those of lymphangitis.

Lymphangitis means an inflammation of all the structures which make up the wall of a lymph-carrying vessel; the endothelial lining, the muscular and connective tissues, are involved. Hyperæmia and thickening occur, with or without coagulation of the lymph and occlusion of the ducts. As in other inflammatory processes, the native and wandering cells undergo proliferation, and form in the extra-vascular spaces a common embryonic tissue, which, under certain favorable conditions, may undergo granular metamorphosis and absorption (resolution), or, if the process be violent and the tissues of a low order of vitality, suppuration may occur. Lymphangitis may be traumatic in origin, or result as a part of some idiopathic inflammation. It may also be described as an acute, subacute, and chronic disease, involving the superficial or deep vessels, or both.

The *symptoms* of acute lymphangitis, while varying in intensity proportionate to the virulence of the cause and the condition of the tissues

affected, are the same in the essential features in every case. Following an inoculation with any septic matter, within a few hours there is a sense of uneasiness and burning in the immediate vicinity of the wound. Pain is not usually severe until the swelling is well marked. At the end of from twenty-four to thirty-six hours the injection of the superficial vessels which lead from the local inflammation toward the center may be recognized. These red lines give a peculiar sensation to the touch. While the outline of the vessel can rarely be made out by palpation, there is often an appreciable thickening and tension in the tissues immediately over and around it. Pain is present in some instances, while in others even direct and strong pressure causes little or no disturbance. When the nearest gland or plexus is reached by the inflammatory process, by pressure upon these a sharp sense of pain is experienced. The febrile movement, which may ensue within twenty-four hours, though usually not well marked at this early period, is generally introduced by a chill or a series of chilly sensations, characterized by pallor and the "picked-goose" roughness of the skin. The temperature rises rapidly above the normal, and may reach a high degree. Nausea, vomiting, delirium, and the train of symptoms which accompany septicæmia may follow; but this is, fortunately, the exception. If the conditions are unfavorable to the progress of the disease, the temperature declines gradually, resolution occurs, and the symptoms of inflammation disappear in from one to two weeks.

In the *diagnosis* of *lymphangitis* it is well to bear in mind that in *phlebitis* the lines of red discoloration are wider than in the disease under consideration, that there is a more general condition of œdema, that the lines of inflammation follow well-known and appreciable veins, that these veins are very painful to pressure, and that they are easily recognized as hard, semi-elastic, knotty cords.

In *erythema*, *erysipelas*, and *dermatitis* the discoloration is deep and diffuse, and the superficial lymphangitis which exists can not be made out in the general staining. It is evident, however, in one unfailing symptom—*adenitis* in the glands in the direct route of the vessels.

The *treatment* is *local* and *general*. Cold applications are preferable, if cold is agreeable to the patient. Employ the ice or cold-water bag, or cold cloths. Heat may be applied in a similar manner. The sense of comfort experienced is the only criterion in determining the employment of these agencies. The lead and opium wash is a valuable remedy. When an extremity is affected it should be kept in perfect repose and in an elevated position. If suppuration occurs, the pus should be evacuated. If cellulitis and great tension complicate the lymphangitis, make free parallel incisions to obviate threatened strangulation. The constitutional remedies look to the regulation of the alimentary apparatus—quinia, iron, etc., and, above all, pure air and cheerful surroundings.

Subacute and *chronic* lymphangitis are associated with forms of general systemic infection, as in syphilis, which is typical of the subacute variety, and in "Hodgkin's disease" and the so-called scrofulous dyscrasia, which are chronic forms of this disease.

Adenitis, or inflammation of a lymphatic gland, usually exists with the disease just considered, or it may be independent of it.

The *pathological changes* vary as the process is *acute*, *subacute*, or *chronic*. In acute adenitis the cells of the reticulum and the leucocytes proliferate with great rapidity, resulting in pressure upon, and occlusion of, the periglandular blood-vessels, and consequent suppuration. In the subacute and chronic forms the proliferation is confined chiefly to the connective-tissue cells of the reticulum, or net-work of the gland, causing an abnormal thickening of the stroma, and a diminution of the corpuscular elements of the gland.

Acute adenitis may result from a blow, from excessive muscular action, or, as above stated, it may follow an acute lymphangitis.

The *symptoms* are a sense of soreness and tension, sharp throbbing pain, increased on slight pressure, swelling, and redness of the superjacent skin. The suppuration commences in the center of the gland, and gradually extends until the tissues around are involved. The constitutional symptoms are similar to those given in lymphangitis. If the inflammatory process be of the subacute form, the enlargement is more gradual, and pain and the other symptoms of acute adenitis are absent. Later in the history of this process fatty and caseous degenerations may occur, ending in resolution. In chronic adenitis the tumors are more solid and firmer to the touch, since the enlargement is due in greater part to the proliferation and hyperplasia of the connective-tissue stroma.

In the *treatment of acute adenitis* perfect quiet must be enforced. Local applications are indicated as in lymphangitis. If suppuration is evident, early incision is indicated. Frequently one after another of the glands in a group breaks down in the process of suppuration, forming sinuses which undermine the neighboring tissues, when it is necessary to lay each abscess open freely and scrape out every particle of diseased tissue with a Volkmann's spoon. Thus treated, the wound should be packed with sublimate gauze, and treated as an open wound throughout. If recovery does not follow, a thorough dissection should remove the diseased glands.

Chronic enlargements of the lymphatic glands require chiefly constitutional treatment. Local measures may be deemed advisable, in order to protect the part from pressure. Plasters of mercury, belladonna, or galbanum, are among the most useful remedies of this kind. Painting with tincture of iodine is painful, and of doubtful benefit. Among constitutional remedies the protoiodide of mercury, combined with tonics and proper alimentation, will in general prove most satisfactory. Extirpation is indicated when, after the faithful administration of constitutional remedies, the tumors continue to increase. In malignant and tubercular adenitis, operation should be undertaken at once.

Wounds of the lymphatic vessels may occur in common with solutions of continuity in other tissues. The escape of lymph, and occlusion of the vessels involved, back to the first collateral branch, is the rule, as with the blood-vessels. If the vessel be large, as when the deeper channels of the leg or the thoracic duct is divided, the ligature or compression of the

distal end is necessary to prevent a lymph fistula. It has been demonstrated that the lymph and chyle can be carried into the circulation by collateral routes, after occlusion even of the thoracic duct.

Varicosities occur at times in the lymphatic vessels, as in the veins. The causes and treatment are essentially the same. As a result of obstruction, in some instances, *cystic dilatations* occur, which, according to Bellamy,* are usually found in the tongue, lips, and about the neck. Hydromata of the neck are at times congenital. In their structure they are trabeculated, the caverns filled with lymph. The location is beneath the occiput, and the tumor is symmetrical, the cyst of each side of the median line being lined with lymphatic endothelia.

New formations (lymphomata) of lymphatic vessels occur occasionally, and blood-vessels developing in these give rise to a mixed new growth, known as lympho-angioma.

PHLEBITIS.†

DEFINITION AND MORBID ANATOMY.—*Phlebitis* means an inflammation of all the tissues which enter into the formation of the walls of a vein. *Endophlebitis*, *mesophlebitis*, and *periphlebitis* are terms used to designate the inflammatory process involving respectively the internal, middle, and external layers of the venous wall.

The progress of inflammation in the tissues of veins is closely analogous to that of the same process in all other structures, namely, irritation, hyperæmia, tumefaction, infiltration of the extra-vascular spaces with emigrant, embryonic, and pus cells; the process terminating in cicatrization (often with adhesions), calcareous degeneration, suppuration, or gangrene. The mode of termination will depend upon the severity of the attack, the character of the lesion, and the power of resistance and recuperation existing in the tissues. The inflammatory process involves a tubular structure, the walls of which are composed of an inner layer (*intima*), made up of flat, polygonal cells (the endothelia), a middle layer chiefly made up of elastic tissue, and an outer layer, containing elastic loops, connective tissue, and unstriped muscle. Blood-vessels and nerves traverse the outer and middle tunics, following the bundles of connective tissue.

The cells of the lining membrane are smaller than the arterial endothelia, and are imbedded in a fibrillated, intercellular substance (Cornil and Ranvier). The elastic and muscular tissues are less developed than in the arteries (Heitzmann). These are so irregularly arranged that any division into middle and external coats is, in great part, artificial and imaginary. Moreover, many of the veins contain no muscular tissue,

* "Encyclopædia of Surgery," vol. iii, p. 34, Ashhurst. William Wood & Co., 1883.

† That portion of this chapter between pages 161 and 198 is taken from my article in the "International Encyclopædia of Surgery," edited by Prof. John Ashhurst, Jr., M. D.; published by Messrs. William Wood & Co., of New York city, for whose kind permission to introduce it in this book in its original form the author begs to make his sincere acknowledgment.

while their connective tissue varies in quantity in different parts of the body. The sinuses of the dura mater, the veins in bones, and those of the retina, have no muscular fibers, while the jugulars, subclavians, and venæ cavæ have a relatively small quantity, or are entirely devoid of this tissue. Again, the arrangement of the muscular tissue differs in different veins. The inferior vena cava and the portal and renal veins have an inner, circular, and an external, longitudinal layer, while the femoral and popliteal veins have the longitudinal fibers more internal. This tissue is still more complicated in the saphenous veins, where the internal layers are arranged longitudinally, with a number of alternating, or transverse and longitudinal, layers placed externally to these.

The elastic layer begins immediately external to the basement substance which supports the endothelial layer, and is here somewhat isolated and well defined; but from the external surface of this central, elastic lamina springs a net-work of elastic fibers, through the loops and in the meshes of which are woven the muscular and connective-tissue fibers.

The vasa vasorum follow the connective-tissue bundles in their distribution to the tissues of the wall down to the elastic layer. Nerves from the sympathetic system have been demonstrated in the larger veins.

The valves are delicate reduplications of the internal coat, having a well-defined, elastic reticulum, especially on their distal or convex surface (Heitzmann), and muscular fibers at the point of attachment to the venous wall.

The vascular area—the outer and middle layers—is first concerned in the inflammatory process. The endothelial tunic, as a result of these structural changes, is subsequently involved in the process. It then appears cloudy, thickened, and rough, and may become separated in shreds. (Frey.)

In the vascular area, during the earlier stages, the capillaries of the vasa vasorum become swollen, the white corpuscles migrate into the extra-vascular spaces, and the normal connective-tissue cells are stimulated into rapid proliferation, resulting in a thickening of the wall, due to the presence of these embryonic cells, and the excessive hyperæmia. As in arteritis, the vitality of the endothelial tunic becomes impaired, and it is more or less projected into the cavity of the vein, the endothelia undergoing rapid proliferation. After a few days, granulation-buds push out from this embryonic tissue of the endothelia, and new capillaries are developed in the granulation-masses, anastomosing and becoming a part of the circulation of the vasa vasorum, as well as leading into the coagulum which occupies the caliber of the vein.

At the point of contact of the outer surface of the thickened endothelial layer with the internal surface of the middle (elastic) layer, large sinuses are developed, which receive the blood from the capillaries of the middle tunic. These sinuses are lined with an endothelial layer, which rests upon the contiguous connective tissue. From these large vessels fine capillaries are given off, which permeate the thickened internal layer, and some of which pass into the organizing coagulum.

When a thrombus, caused by the sudden coagulation of the blood in a vein, is examined in its recent state, it is found to be composed of successive laminæ of fibrin and corpuscles, and the more recent of these laminæ are external. When the vein is first occluded by this sudden coagulation of the blood, the pressure from behind is so great that the coagulum is compressed toward its center, while the current, more and more impeded in its progress, flows between the periphery of the clot and the inner surface of the vessel, adding, layer by layer, fresh deposits of coagulation upon the thrombus. A microscopical examination of such thrombi reveals a vast number of white corpuscles in various stages of fatty degeneration, with layers of fibrin intervening.

Experiments have shown that not only does the inflammatory process, by reason of its invasion of the intima, produce changes in the blood which lead to stasis, but that there is also a dangerous endosmosis of septic matter, which is swept along toward the heart and lodged in the capillaries of the various organs (*emboli*), producing infarctions, abscesses, and, almost invariably, irreparable damage. The adhesion of the intima, and the formation of a fibrinous clot—which may completely occlude the vessel (*occlusion thrombus*), or may merely plaster over the endothelial tunic (*peripheral thrombus*)—are efforts toward prevention of this endosmosis.

The process of repair in tissues capable of successful resistance, in venous inflammation, is one of organization of the embryonic cells, fibrillation, and contraction, resulting in partial or complete occlusion. In tissues of low and impaired vitality, the progress of the inflammation is rapidly toward suppuration, usually terminating in septic fever and death. Microscopical sections from such specimens of phlebitis show that the leucocytes and embryonic cells have undergone retrogressive changes, and that the tissues are infiltrated with pus corpuscles. Gangrenous spots are not infrequent, often opening into the caliber of the vessel, and allowing the influx of septic products, or the efflux of blood.

Since phlebitis is a frequent cause of thrombosis, and since venous thrombosis is the most frequent form of intra-vascular coagulation, a consideration of the pathogeny and pathology of this process must naturally find a place here. Virchow has endeavored to show that primitive phlebitis is extremely rare, and that, when a clot is produced in a vein which is inflamed, the coagulation has more often preceded than followed the inflammation. Cornil and Ranvier, from whom the above account is taken, do not accept this theory.

Fibrin, the immediate factor in coagulation of the blood, does not exist as such in the normal condition of this fluid. Under healthful conditions, the blood would circulate always without any deposit of fibrillated fibrin in the economy. According to Denis, the normal plasma of the blood can be separated into a semi-solid substance, *plasmine*, and a liquid, *serine*. Plasmine is further separable into *fibrin* and *metalbumen*, and it is held that the coagulation of the blood is due to the conversion of plasmine into fibrin. Foster holds that coagulation is the result of the interaction of two bodies, *paraglobulin* and *fibrinogen*, brought about

by the agency of a third body, *fibrin-ferment*. A. Schmidt has carried experimentation further, and is led to believe that paraglobulin and fibrin-ferment both originate in the white blood-corpuscles. This theory is exceedingly seductive, and it can not be denied that actual pathology proves that around and within inflammatory areas where white blood-corpuscles are most abundant, coagulation and fibrillation are more apt to occur, and a study of thrombi, which have been gradually formed, reveals alternating layers of white corpuscles and fibrillated fibrin. (Green.)

What may be the principle in the blood which is the factor of coagulation, or what reaction it may be which precipitates the fibrin, we can not in the present condition of science positively assert. The facts, however, "point to the conclusion that when blood is contained in healthy, living blood-vessels, a certain relation or equilibrium exists between the blood and the containing vessels, of such a nature that, as long as this equilibrium is maintained, the blood remains fluid; but when this equilibrium is disturbed by events in the blood or blood-vessels (or by the removal of the blood), it undergoes changes which result in coagulation." (Foster.)

So delicate is the sensibility of the blood to mechanical irritation or hindrance in its flow, that the slightest injury or roughening of the endothelial lining membrane may produce a deposit of fibrillated fibrin. A delicate needle, or wire, or thread, thrust into the lumen of a healthy vessel, precipitates coagulation upon the foreign body. The white corpuscles are found clustered in great numbers on the foreign body, and, when the mass is examined with the microscope, the corpuscles seem to serve as starting-points for the development of fibrin. (Reichert.)

CAUSES AND CLINICAL HISTORY OF PHLEBITIS.—Phlebitis has been termed traumatic and idiopathic, and the latter term has been applied indiscriminately to all forms of phlebitis not directly due to an appreciable lesion.

Idiopathic phlebitis is comparatively a rare affection (Virchow). It may occur without a traumatism, as from exposure to cold, or as a sequel to fevers and varicosities (Hamilton). It may occur as a complication of syphilis (Hutchinson), or as a result of the gouty diathesis (Paget). From whatever cause it may proceed, idiopathic phlebitis usually affects the veins of the lower extremities.

Traumatic phlebitis may be caused by a partial or complete solution of continuity of the venous walls, by contiguity of inflamed tissues, or by violent muscular action and pressure.

The inflammation of the uterine sinuses during and after parturition, which Cornil and Ranvier style "la phlébite spontanée," is really a form of traumatic phlebitis, due to the irritation resulting from pressure and muscular action.

Phlebitis has been described as acute and chronic (Gross); adhesive and suppurative (Bryant); gouty and diffuse (Hamilton). These terms but express varying conditions of one pathological process, and whether this inflammatory process shall result in adhesion or suppuration, shall become diffused, or shall assume a chronic form, will depend solely upon

the character and cause of the disease, and upon the capacity of the tissues to resist its progress.

I. IDIOPATHIC PHLEBITIS. 1. *Syphilitic Phlebitis*.—Mr. Hutchinson has called attention to the very few cases of syphilitic phlebitis which have been recorded, and yet he says that most surgeons are familiar with the fact that inflammations around varices, and even about otherwise healthy veins, are not infrequent in syphilitic subjects.* Mr. Hutchinson further says: "I think also that I have seen several cases in which the thrombosis and phlebitis were attended by other conditions sufficiently peculiar to justify a belief that they were of specific origin. In some there has been great excess of inflammation, a large hard mass forming in the cellular tissue, and threatening to slough, much as subcutaneous gummata often do. These cases are much benefited by the iodide of potassium, so far as prevention of sloughing is concerned, but the thrombotic plugging remains." †

2. *Gouty Phlebitis*.—Subjects (says Mr. Bryant) who are gouty from hereditary or acquired causes are liable to phlebitis. Paget has described the affection in his "Clinical Lectures," and Mr. Gay has written upon it. In such cases the phlebitis may have no intrinsic characters by which to distinguish it, yet not rarely it has peculiar marks, especially in its symmetry, apparent metastases, and frequent recurrences. Like other forms, it is more common in the lower than in the upper extremities, yet it may be found anywhere. It affects the superficial rather than the deep veins, and often occurs in patches, affecting on one day, for example, a short piece of the saphenous vein, and the next another portion of the same vein, some other distant vein, or a corresponding piece of the opposite vein.

The inflamed portions of the vein usually feel hard and are painful to the touch. The soft parts covering the vein become slightly thickened, and often have a dusky, reddish tint. When the deep veins are involved, œdema appears, with the well-recognized results of obstruction: the limb becomes big, clumsy, featureless, heavy, and stiff; its skin is cool, and may be pale, but more often has a slightly livid tint, which may be recognized by comparison with the other limb; and it has mottlings from small cutaneous veins, visibly distended. The limb, thus enlarged, feels œdematous throughout, but firm and tight-skinned, not yielding easily to pressure, and not pitting very deeply.

The constitutional symptoms associated with this affection vary from some slight febrile condition to those met with in acute gout. Complete recovery may take place in this as in other forms of phlebitis, the veins becoming pervious in some cases and obstructed in others. The risks of embolism are also the same. (Bryant.)

3. *Acute Idiopathic Phlebitis* (not gouty or syphilitic).—This form of venous inflammation—caused, as has been said, by exposure to cold, due to the presence of a varicosity, or coming in the course of a severe febrile attack—may involve one or more veins. The disease travels along

* J. H. C. Simes and J. William White, in Cornil on Syphilis.

† Ibid.

the vessels in the direction of the heart. The veins become swollen, and are hard to the touch, resembling the normal veins when the return circulation is momentarily arrested, though more cord-like in feel and less elastic. Their course can be traced by the dull-red color of the skin immediately over the diseased vessels. Pain is generally constant, and is rendered more acute by pressure. The œdema of the parts on the distal side of the lesion is commensurate with the obstruction to the return circulation caused by the inflammatory process. The febrile movement varies with the violence of the attack, the rapidity of its progress, the intensity of the inflammation, and the capacity of the tissues to resist invasion. In the severe forms, the clinical history is similar to that of traumatic phlebitis, which will be fully described hereafter. Idiopathic phlebitis is not as dangerous to life as the traumatic variety. It may run a short course, and the patient recover promptly, or it may assume a subacute or chronic form, and remain indefinitely.

II. TRAUMATIC PHLEBITIS.—When a vein is injured, inflammation will result, if the vessel is penetrated to its cavity, or suffers a solution of continuity in any portion of its wall. Examples of traumatic phlebitis, resulting in thrombosis and occlusion of the popliteal vein, are known to have been caused by prolonged forced flexion of the leg on the thigh. The simplest form of traumatic phlebitis is that resulting from the operation of venesection. No matter what may be the character of the traumatism, the pathological process is the same. The mode of termination of this process will depend upon the extent and severity of the lesion, and upon the recuperative powers of the tissues involved. Traumatic phlebitis extends from the original lesion along the vessels in the direction of the heart. In the deeper veins it is with difficulty recognized in the earlier stages. The course of the inflammation is marked by a dull, coppery-red staining. Pain is invariably present, and upon pressure is acute. In severe cases the tumefaction spreads from the vessels to the surrounding tissues. Œdema of the parts on the distal side of the lesion will occur in a degree commensurate with the interference with the return circulation. The febrile movement is that of septic fever: chills or rigors, flushes of heat ending in cold and exhausting sweats, sleeplessness, hectic, anxious expression, and often the “pyæmic breath.” The rectal temperature is variable and high; the pulse is thready and rapid, reaching in some instances 160. Sudden and dangerous symptoms may arise in the course of the disease, when particles from the venous thrombi are carried toward the heart. These usually lodge in the lungs, giving rise to sudden pulmonary complications, the result of infarction. The liver, in phlebitis of the veins which go into the portal circulation, is frequently the seat of embolic abscess. Hæmorrhage from perforation of the venous wall, by ulceration or gangrene, is another source of danger in severe cases of phlebitis.

Treatment of Phlebitis.—Positive and complete rest is the first great essential in the treatment of phlebitis. Manipulation or movement is dangerous, since interference will not only exaggerate the inflammatory

process, but may possibly cause the separation of thrombi and produce infinite harm in remote organs. If the disease should assume the suppurative form, the inflammation being diffuse and the œdema severe, free incisions parallel to the veins should be made in order to secure drainage. A wet dressing should be applied, and the wounds frequently irrigated with 1 to 10,000 sublimate solution until the more urgent symptoms have disappeared. Quinia is indicated, not only on account of its well-known tonic and antifebrile properties—although not strictly antiseptic in its action, the bacteria of septic fluids resisting its action to a great extent (Bartholow)—but because it exercises an inhibitory influence upon the emigrant corpuscles (Binz), important factors, as Conheim has shown, in the inflammatory process. The use of iron, careful feeding, and a free supply of pure air, will complete the constitutional treatment. If an extremity is involved it should be slightly elevated to favor the return circulation.

ARTERITIS.

Arteritis is a term applied to an inflammatory process which involves the entire thickness of the arterial wall. When the inflammatory change is confined to the inner coat, or intima, it is designated as *endarteritis*; when to the outer coat, or adventitia, as *periarteritis*; and when to the middle coat, or media, as *mesarteritis*.

Endarteritis, which does not rapidly disappear soon after its inception, is apt to result in lesions of the media and adventitia, and in like manner a lesion of the external tunic will in all probability involve, by the extension of the morbid process, the other coats.

There are, however, certain well-defined, circumscribed lesions of the separate tunics. Endarteritis is, as an isolated lesion, capable of demonstration. We shall see that a superficial inflammation of the endothelia, with its resultant fatty degeneration, is not infrequent. Again, mesarteritis exists as a primary and separate inflammation, for primary calcification (denied by some pathologists), which is strictly a disease of the tunica media, precipitates an inflammation in this middle tunic. And since atheroma and other arterial lesions are due to interference with the blood-supply through the vasa vasorum, or to defect in the quality of the blood distributed to the adventitia through which the vessels ramify, we must recognize a periarteritis as the initial stage of this lesion.

Inflammation may be established in any or all parts of the arterial system. One form of arteritis will involve the larger trunks, while another will pass these without molestation, and establish itself in the distant arterioles. Simple endarteritis is most apt to occur in the aorta and arteries of the second magnitude, while syphilitic arteritis, the most marked feature of which is an endarteritis, rarely attacks the larger trunks, chiefly confining itself to the more or less complete occlusion of the small and smallest arteries.

The internal coat of the larger arteries is composed of two parts: 1. An endothelial lining membrane, consisting of a single layer of flat, po-

lygonal, nucleated cells, slightly elongated in the axis of the vessel; in edge view, these cells appear spindle-shaped, on account of the elevation of the nucleus at its center (Heitzmann); 2. A subendothelial layer of flattened, nucleated, anastomosing cells resting in a fibrillated basement substance, the direction of the fibrillæ being generally parallel with the long axis of the artery (Cornil and Ranvier). In the smaller arteries this layer is exceedingly fine, while in the aorta it is comparatively thick, being composed of two distinct layers. Here the internal of these two layers is longitudinal, the external transverse in direction. The middle coat in the larger arteries, such as the aorta and carotids, is composed of elastic laminae and of fibers, forming by their anastomoses a continuous system, and holding in the meshes of their loops the muscular tissue, transverse in its direction, and a relatively small amount of connective tissue (Cornil and Ranvier). According to C. Toldt, the muscle-fibers of the middle coat are wanting in the initial portion of the aorta, in the pulmonary artery, and in the arterioles of the retina. In the descending aorta, the common iliac, and the popliteal, small bundles in an oblique or longitudinal direction are interspersed between the circular ones, and in other arteries, such as the renal and spermatic, at the inner boundary of the muscular coat, scanty longitudinal bundles occur, which by some are considered to belong to the inner coat. At times, in the corresponding arteries of different persons, differences are observed in the distribution of the muscles of the middle coat (Heitzmann). On the side nearest the inner coat the middle tunic is limited by a denser and more defined elastic lamina, which shows, however, on transverse section, a festooned appearance—very important in the study of the pathology of arteritis—and is named the internal layer of the elastic coat. Upon the side of the tunica media nearest the external coat the elastic fibers pass outward, interlacing freely with the connective tissue of the adventitia. In the femoral, brachial, and other arteries of middle size, the middle coat possesses only one layer, namely, the internal elastic. The muscular fibers are transverse in direction, and form themselves into flattened bundles, separated by connective-tissue bundles and by elastic fibrillæ, which are continuous on the one hand with the inner, elastic layer, and on the other with the elastic net-work interwoven with the adventitia. There are no vessels in the middle and internal coats. In the external coat are found arteries, capillaries, veins, lymphatics, and nerves.

The small arteries have a middle coat, formed of involuntary muscle-cells, so interwoven that they form a continuous membrane (Cornil and Ranvier). C. Heitzmann* describes this layer as seemingly twined round the artery. The adventitia here is composed of small bundles of connective tissue, arranged in the main in a longitudinal direction.

Pathogeny of Arteritis.—The causes of arteritis are numerous. The most frequently recognized form is that resulting from injury, and known as *traumatic arteritis*. The pathogeny of the *non-traumatic (idiopathic) arteritis* embraces every form of dyscrasia. It follows in the train of

* "Microscopical Morphology of the Animal Body in Health and Disease," New York, 1883.

syphilis, rheumatism, gout, alcoholism, and nephritis with great regularity, and may occur as a result of any morbid process which poisons the blood or impairs its nutritive qualities. These varieties will be considered under special headings.

The sequelæ of arteritis, as far as the arteries are concerned, may be fatty infiltration and degeneration, atheroma, secondary calcification, occlusion, dilatation, aneurism, suppuration, ulceration, and rupture. Remotely, partial or complete loss of function of the organs beyond the lesion, and partial or general necrosis or necrobiosis. I shall consider arteritis under two great heads, *traumatic* and *non-traumatic*, subdividing these as their pathogeny or pathology may justify in the consideration of each separate type.

I. TRAUMATIC ARTERITIS.—Arteritis may result from violence, either from without or from within. External violence will produce an inflammation of all the tunics of an artery, in the majority of cases, while violence from within is more apt to cause an endarteritis. *Arteritis from external causes* is never an uncomplicated injury. The perivascular tissue is of necessity involved in the inflammatory process. In the arteritis resulting from deligation of an artery, from the forcible compression of a vessel, as in bending the knee, from the pressure of a tumor, or from a blow in the track of the artery, there is always an accompanying inflammation of the surrounding, injured tissues.

The pathology of traumatic arteritis does not differ greatly from the inflammatory process which occurs in other vascular tissues. Immediately following the injury there is a marked increase in the vascularity of the adventitia. The vasa vasorum become swollen, the white blood-corpuscles crowd into the capillaries, and pass into the extra-vascular spaces, while a rapid proliferation of the normal cell-elements of the arterial tunics takes place. The connective-tissue cells of the adventitia, the white corpuscles, and the flat and polar cells of the intima, all take part in the morbid process. The walls of the vessel become abnormally thickened, while, owing to the projection inward of the intima, the

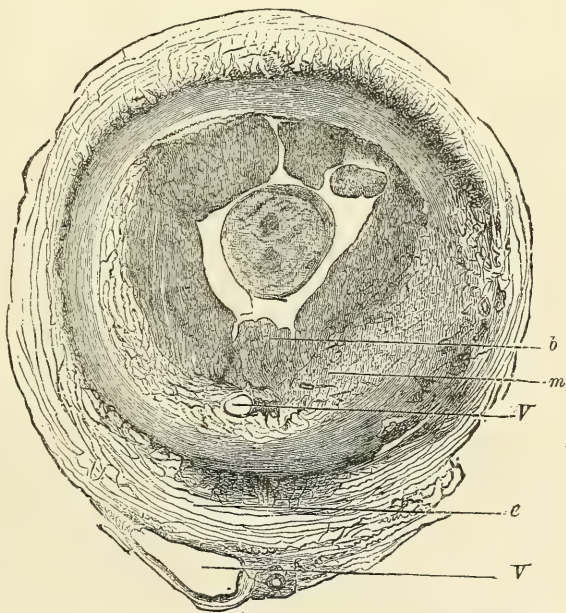


FIG. 247.—Traumatic arteritis. Transverse section of the carotid artery of a dog, fifteen days after ligature; *b*, granulation buds formed from projection of the intima. In the center of the figure one of these buds has been completely cut across; *m*, portion of the media modified by the inflammatory process; *c*, adventitia; *V V*, vessels cut across, one of which is newly formed in the intima. Magnified 15 diameters. (After Cornil and Ranvier.)

caliber of the vessel is diminished. If the intima has been broken or bruised by the injury, the encroachment upon the caliber of the vessel

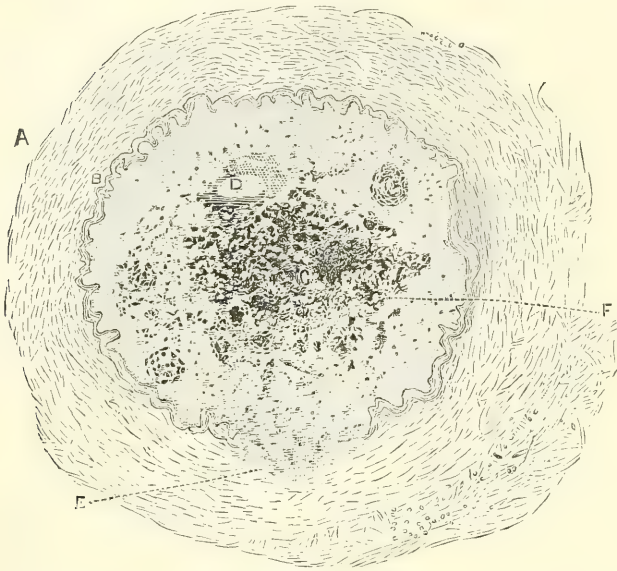


FIG. 248.—Endarteritis obliterans, not syphilitic. Transverse section of the basilar; A, muscular layer; B, elastic layer. The lumen of the artery is entirely filled with a new formation, which has become canalized by new vessels at D D F; c, blood pigment; E, hyaline material, part of the new formation encroaching on the media at E, and seen elsewhere. (Drawn by Dr. W. L. Wardwell, from a specimen borrowed from Prof. W. H. Welch. Magnified 60 diameters.)

will be more rapid, for, in addition to the mass of embryonic tissue pushing into the lumen of the artery, there will be a deposit of fibrin upon the roughened and projecting internal tunic. The white corpuscles in the passing blood-current adhere to the inflamed surface, and undergo a change which causes a liberation of the fibrino-plastic matter which they contain, and a deposit of fibrillated fibrin. This coagulum is found to consist of alternate layers of leucocytes and fibrin. In the mean time, if the inflammation be not so

severe that rapid necrosis occurs from the sudden arrest of the blood-supply through the vasa vasorum, new-formed capillaries push through the mass of embryonic cells, into the “granulation buds” which project into the lumen of the vessel (Fig. 247).

This form of arteritis may result in permanent occlusion of the vessel (*endarteritis obliterans*), or the function of the artery may be restored. If occlusion occurs, it results from the organization of the embryonic cells into a new tissue which undergoes fibrillation and contraction (a process of cicatrization) to such an extent that the new-formed capillaries are more or less occluded, and the artery shrinks to become a fibrous cord (Fig. 248). Or the coagulum may undergo fatty degeneration, and be swept away with the current of blood, the vessel remaining pervious and bearing but little trace of the inflammatory process through which it has passed. The microscopical appearances of a localized traumatic arteritis are typically represented in Fig. 249, which is copied from a section made from the carotid of a horse. The animal was in a healthy condition at the time of the operation. I tied the artery with a broad carbolized ligature, the sciatic nerve of a calf. In the fifth week the animal was killed. The artery was pervious. The location of the ligature was easily recognized by the peculiar, whitish, pearly appearance of the intima at the point of tying, where it was slightly elevated. The adventitia did not show any changes to the naked eye. The ligature had evidently slipped

soon after the operation, probably within a few hours. The intima was not broken, but simply bruised within the grasp of the ligature. Active proliferation of the cells of the intima had resulted from this irritation. Not only is the intima seen to bulge into the lumen of the vessel, but the

mass of embryonic tissue encroaches outward upon the media, which is thinner at this point than elsewhere. At one point the media has entirely disappeared, leaving the intima and externa in actual contact. The adventitia has not undergone much change. A few inflammatory corpuscles are found among the connective-tissue bundles. If, after an injury which induces arteritis, the vessel be not occluded throughout the extent of the lesion, and the injury or resulting inflammation be so severe and intense that rapid occlusion of the capillaries

in the arterial wall takes place, suppuration and ulceration of the wall occur, with hæmorrhage. Or septic matter may pass into the vessel from the surrounding, inflamed tissue, and lead to infarction and pyæmia. The same condition may result from an extension of inflammation from the surrounding tissues into the arterial wall, as in phagedæna.

Treatment.—No unvarying plan of treatment can be laid out for traumatic arteritis. The circumstances of each case must be separately considered. To prevent gangrene, and to guard against hæmorrhage, are the indications most to be regarded. Rest, position, quiet, and careful nutrition, are the most important points of treatment.

Traumatic arteritis resulting from *causes within the vessels* usually begins as an endarteritis. It may never involve any other tunic than the intima. Many cases of acute traumatic endarteritis are described as idiopathic inflammations. They are none the less due to violence—to the impinging force of the blood-current; for this lesion occurs at those points in the arterial system where the pressure is greatest. Endarteritis and the fatty degeneration resulting from it (Figs. 250, 251) are most frequently seen in the sinus magnus of the aorta, in the transverse segment of the arch of the aorta, at the aortic bifurcation into the two common iliacs, and in the arch of the innominate. The arteries of athletes, which are subjected to prolonged distention, resulting from violent muscular exercise, are prone to suffer from this disease.

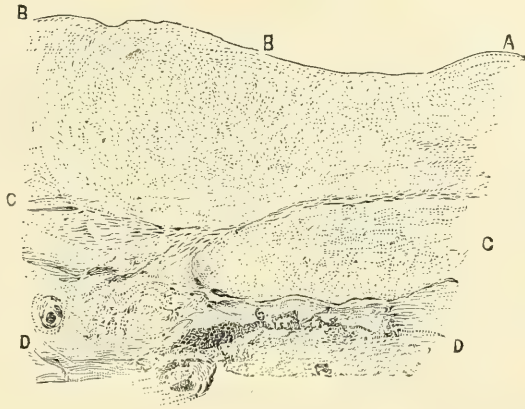


FIG. 249.—Traumatic endarteritis. Section from the common carotid of a horse, tied with a broad nerve-ligature, showing at BB the proliferation of the intima. The inflammatory new formation is projected into the lumen of the vessel, and has caused partial atrophy of the media, C; A B, the intima; BB, portion of the intima in the grasp of the ligature; D, the adventitia, slightly changed, with small-cell infiltration. (Drawn by Dr. W. L. Wardwell, from the author's specimen. Magnified about 40 diameters.)

Vegetations from the heart may produce endarteritis when they are extensive enough to pass through the aortic valves. Fragments from whatever source, carried along the vessels, produce arteritis at the point of lodgment.

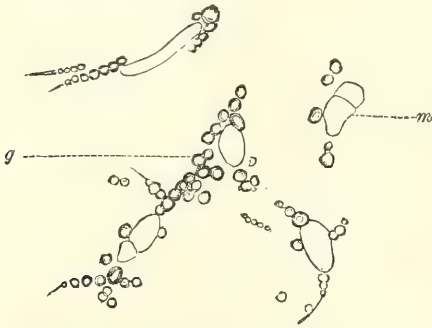


FIG. 250.—Arteritis with fatty degeneration of the intima of the aorta. The nuclei of the normal cells are represented by the larger bodies, one of which is seen at *m*; the smaller bodies, as at *g*, are fatty granules. Magnified 400 diameters. (From Cornil and Ranvier.)

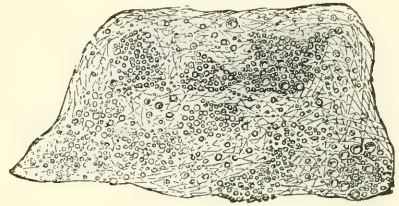


FIG. 251.—A form of fatty degeneration after arteritis. Fatty degeneration of the internal coat of the aorta. Minute yellowish-white patches scattered over the lining membrane of the vessel. A very thin layer peeled off and magnified 200 diameters, showing fat molecules and the distribution of fat in the intima. (From Green.)

If we examine the intima of an artery which has been the seat of recent endarteritis, it will be seen to be swollen, and thicker and softer than in healthy vessels. The swelling is not usually general and continuous, but occurs in patches or hillocks of quite regular contour, which project into the lumen of the vessel. The intima is usually injected, and reddish in color, though, according to Cornil and Ranvier, when the inflammation has been of a very severe type, the swollen intima is paler than normal. If the inflammation be of recent origin, these patches will present an unbroken surface; but if softening has occurred, the centers of the elevations break down, resulting in erosions or ulcers, as they have been styled by some pathologists. Green says that they are due to softening of the intercellular substance, and that the cells and granular matter, becoming loose from this softening, are washed out by the blood-current. These erosions resemble considerably the superficial erosions found often in the mucous membrane of the stomach. At times they are covered over with a layer of fibrin, which, upon close inspection, is found to be composed of one or more laminae of fibrillated fibrin, with corpuscular elements entangled in or resting between them.

Beneath the projecting intima is found a mass of inflammation-tissue, consisting of embryonic and large anastomosing cells resembling the normal connective-tissue cells of the most external structure of the intima. Hyperplasia of the normal cell-elements is more marked as we approach the inner layers of cells of which the intima is composed, the proliferation growing gradually less extensive as the elastic lamina is neared. This condition is a feature of acute endarteritis, and differs both from the inflammation of the atheromatous process and from syphilitic endarteritis.

This mass of new-formed embryonic tissue is, in all probability, the immediate result of proliferation of the normal cell-elements of the intima.

Emigrant corpuscles could only reach this location by traversing the media, for as yet the capillaries have not been projected into the inner tunic. Nor is it probable that leucocytes, from the blood-current within the artery involved, migrate through the endothelia into the proliferating mass.

The adventitia does not long remain undisturbed by the pathological changes which have occurred in the intima. It takes on an inflammatory process in a varying degree, and this tunic is found thickened from the proliferation of its connective-tissue cells. If the process be obstinate and persistent, a true arteritis is developed, and all the pathological conditions which have been described on a previous page may be present.

The media is not greatly altered in the early stages of endarteritis or periarteritis, though in calcification it is apt to be first attacked, as it is likewise in fatty infiltration and degeneration.

Acute endarteritis may terminate in recovery, leaving no permanent trace of its having existed, or it may pass into a chronic inflammation, which usually ends in fatty degeneration.

This degeneration begins in the endarteritis proper, and travels toward the media. The appearances of an artery which has undergone this change are well shown in Fig. 252.

Fatty degeneration, in its microscopic appearances, resembles very much the atheroma which is, at times, found in the intima. It can, however, by gentle and careful scraping, be removed, revealing the more or less normal tissues underneath, while in advanced atheroma, which involves the deeper structures first, no trace of the normal tissues can be discovered.

Chronic arteritis may follow an acute endarteritis, as has been indicated above, although the chronic arterial lesions, as a rule, begin with periarteritis or mesarteritis.

II. NON-TRAUMATIC OR IDIOPATHIC ARTERITIS.—The inflammatory process in idiopathic arteritis differs only in degree from that heretofore described as occurring in traumatic arteritis. When not due to syphilis, gout, rheumatism, nephritis, or some dyscrasia, it is usually a part of an inflammation of the tissues immediately surrounding an artery. The process commences in the adventitia, and is analogous to that of traumatic arteritis.

Atheroma and Calcification.—One of the frequent and most serious terminations of chronic arteritis, no matter what may have produced the

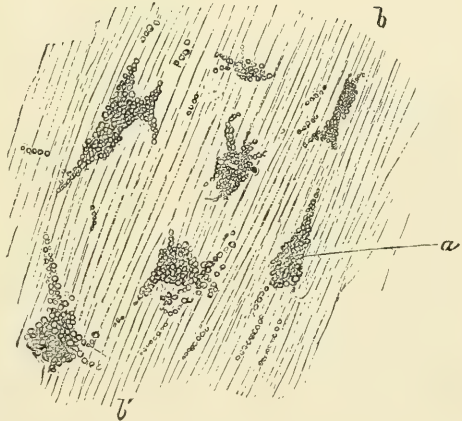


FIG. 252.—Arteritis with fatty degeneration. Fatty degeneration of the internal coat of the arteries from a thin layer stripped from this membrane. *a*, Fat granules in irregular patches over the surface. The granules have resulted from fatty degeneration of the cells of the intima. *b*, Fibrillated tissue. Magnified 200 diameters. (Cornil and Ranvier.)

arterial lesion, is the condition known as atheromatous degeneration (Fig. 253). It is essentially a disease of malnutrition. It is a senile change, not of necessity co-existent with another disease. It is, as will be proved hereafter, prone to attack the arteries, especially those of the brain, in

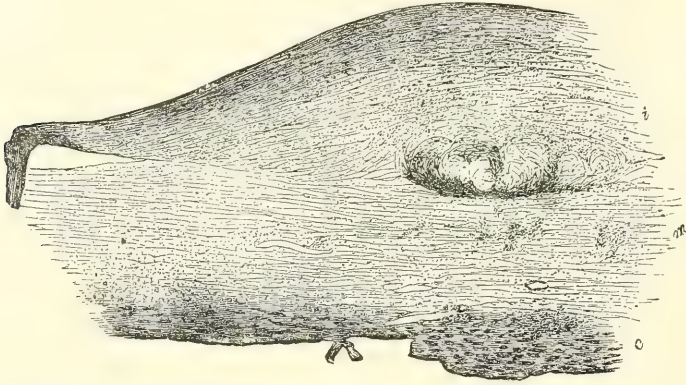


FIG. 253.—Atheroma following arteritis. Section of aorta undergoing the atheromatous change, showing the cellular infiltration of the deeper layers of the inner coat, and consequent bulging inward of the intima. The new tissue has undergone more or less fatty degeneration. There is some cellular infiltration of the middle coat. *i*, the internal; *m*, the middle; *e*, the external tunic. Magnified 50 diameters and reduced one half. (Green.)

syphilis, and the larger arteries in other affections. The fatty degeneration of endarteritis is a primary lesion, that of chronic arteritis is secondary. The one is local, the other general. Recovery from the one is possible, and the danger of death is slight. Shreds of fatty material may be carried by the blood and lodged in the cerebral or other remote vessels, doing great injury; but this accident is rare. The possibilities of chronic arteritis with atheroma are always grave. Above the dangers of thrombosis and embolism, and of calcification, are those of aneurism and of hæmorrhage. The early recognition of this condition, though exceedingly difficult, is no less important. Atheroma commences in the deeper tissues of the arterial wall, and, advancing in the line of blood-supply, taps the sources of nutrition of the deeper tunics, causing their loss of function, death, and disappearance. It is a true necrobiosis.

The fatty degeneration of atheroma not only involves the innermost layer of the intima (as does that form of degeneration which follows endarteritis), but the muscular-fiber cells undergo complete metamorphosis, while the elastic lamina is the seat of extensive infiltration. In severe cases the work of destruction is complete, the normal tissues disappearing, and leaving nothing but a granular *débris*.

Atheroma does not usually destroy an extensive area of the intima. The patches may be numerous, but not large. The molecular disintegration is confined to certain well-defined spots, in the center of which is found the softened, broken-down "pulp" which has given rise to the term "atheroma." Examined under the microscope, the contents of these pulp-cavities will be found to consist of fat granules, granular corpuscles, and cholesterin crystals, exactly analogous to those sometimes found in abscesses of long duration. Shreds of fibrous tissue may

be present. It can be readily conceived how the rupture of one or more of these pulp-cavities, together with the weakened state of the middle and outer coats, would lead to the formation of aneurism. This danger is not so imminent when the inflammatory process has advanced slowly, for the reason that secondary calcification (a conservative process) is more apt to take place. The same may be said of primary calcification where the lime salts are deposited in the "coagulation necrosis" of the media.

The atheromatous and calcareous degenerations may exist in the same location and at the same time. While the cell-structure of the intima is being transformed into granular matter, the fibrillated basement substance nearest the media is the seat of calcareous deposit, at first granular, the granules adhering to form clusters or flakes. At the same time, the nuclei of the muscular-fiber cells are filled in and around with calcareous matter. The entire muscular coat may be converted into a calcified cylinder, or, as is most usual, the process may be confined to isolated patches. In either case, the entire thickness of the wall may eventually undergo the same morbid changes.

When the layer of cells between the calcareous deposits and the blood-current has been broken down by the atheromatous process, it may disappear in the blood and leave the flakes of calcareous matter exposed to view from within. These in turn may be carried away, or they may be undermined by the blood-current and lead to aneurismal pouches by dissection. With atheroma, calcareous degeneration may invade the entire arterial system, the arteries of the extremities becoming brittle and unyielding. The smaller arteries are most apt to be involved, especially those of the brain.

In many cases of atheromatous and calcareous degeneration in the aged, enormous dilatations occur. The dilatation is not uniform, as a rule, but the walls of the dilated artery (usually the aorta and the arteries of the second class) are pouched in many places. The calcareous matter will be found to be thickest in those portions of the wall which are less dilated, while the dilated pouches have undergone a more complete fatty degeneration. This condition is commonly known as *arteritis deformans*.

The middle coat may be in places entirely destroyed, when the changed intima will be joined with the adventitia by a connective-tissue new-formation, which (see Fig. 247) contains vessels passing directly to the intima. Loss of the elastic tunic is one of the immediate causes of spontaneous aneurism (Cornil and Ranvier).

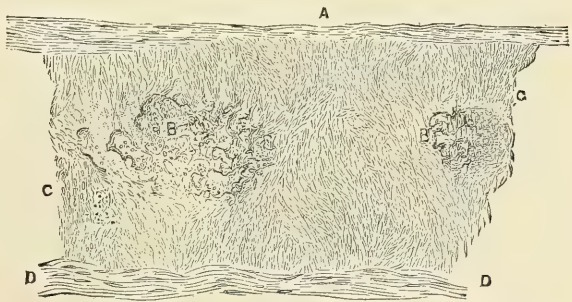


FIG. 254.—Showing calcareous degeneration of the media. A, intima; c c, media; D, adventitia; B B, calcareous patches. Ulnar artery. Magnified about 60 diameters. (From a specimen prepared by Dr. W. L. Wardwell.)

This condition of atrophy of the elastic lamina is well shown in Fig. 254, which was drawn from one of my specimens.

Calcification of arteries has been especially studied by Dr. W. L. Wardwell, of New York city, in Conheim's Laboratory. His experience

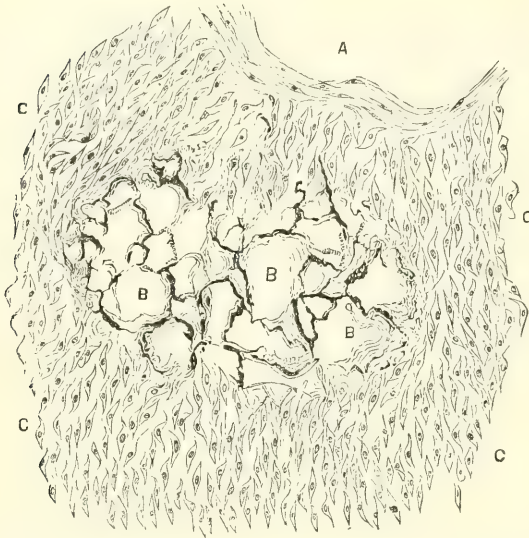


FIG. 255.—Arteritis with primary calcification. Section from human radial artery, showing at B primary calcification of the media, C, A, the intima comparatively unchanged. (Drawn from specimens prepared by Dr. W. L. Wardwell, at Conheim's Laboratory. Magnified about 350 diameters.)

includes examinations made from twenty-five cases at the request of Conheim, who assents to his conclusions. Dr. Wardwell says all authorities recognize a morbid change in the arteries known as calcification, and the majority look upon it as a change secondary to atheroma or endarteritis. Few of these recognize a primary calcification not dependent upon a preceding inflammation. This condition is, however, the chief change in the senile calcification of arteries. The microscopic appearances of primary calcification are well shown in Fig. 255.

Conheim states that in senile arterial calcification sometimes the media, sometimes the intima (its outermost layer), is affected, and that in them the lime salts are deposited. Moreover, that this deposit of lime takes place here because these tunics have been subjected to the greatest strain.

Weigert* describes a "hitherto undescribed" process known as *coagulation necrosis*. Beginning with the theory of Schmidt concerning the coagulation of the blood, in which the white corpuscles play the leading part, he argues that all tissues have the power of spontaneously coagulating, it being necessary for such an occurrence that the cells should die, give up their ferment and fibrino-plastic material, and then become saturated with a fibrinogen-holding lymph. This morbid process he holds may occur in tissues the most diverse in character, as in cheesy glands, infarcts of the spleen or kidneys, tumors, the inflammatory material around parasites, tubercle, etc. Macroscopically, these coagulated spots have a peculiar, stiff appearance, and, microscopically, they are recognized by the fact that the cell nuclei have disappeared, and can not be made to appear by reagents or by the material used for staining in microscopical examination.

Following the line of research indicated by Conheim and Weigert, it may be concluded: 1. That in the arteries of middle-aged or old persons

* Virchow's "Archiv," Bd. lxxix, S. 87.

there are often found spots of diseased tissue which present all the appearances of having undergone a “*coagulation necrosis.*”

2. That in these spots there is a tendency to the deposition of lime salts.

3. That in primary calcification the media is always first affected, the intima and adventitia only secondarily and by contiguity.

4. That this change is independent of a preceding inflammation.

5. That, on the contrary, these calcified spots act as foreign bodies, setting up a secondary inflammation in their vicinity, and leading sometimes to thickening of the intima.

6. That one of the changes in atheroma of the arteries is coagulation-necrosis, that lime salts are often deposited in such necrotic spots, that the position of such spots is in the intima instead of the media, viz., in the newly formed inflammatory tissue.

7. That primary calcification attacks the small arteries rather than the larger, and especially those portions of the arteries which are subjected to the greatest strain.*

These conditions are shown in Figs. 256 and 257.

Syphilitic Arteritis.

—Arteritis is a part of the pathology of syphilis. The first danger to life in this disease comes from the changes in the capacity of the arteries. No part of the arterial system is exempt, though the most serious lesions are found in the vessels of the brain, and next in the aorta. They become grave in the larger trunks on account of the atheroma resulting from the syphilitic poison (induc-

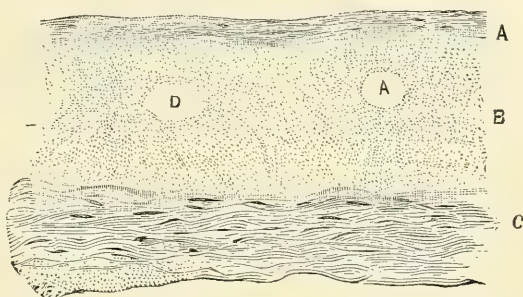


FIG. 256.—Arteritis with coagulation-necrosis. Section from human artery treated with acetic acid, showing at *d* spots of coagulation-necrosis which contained calcareous salts before being treated with the acid; *A*, intima; *B*, media; *C*, adventitia. (Drawn from specimen prepared by Dr. W. L. Wardwell. Magnified about 40 diameters.)

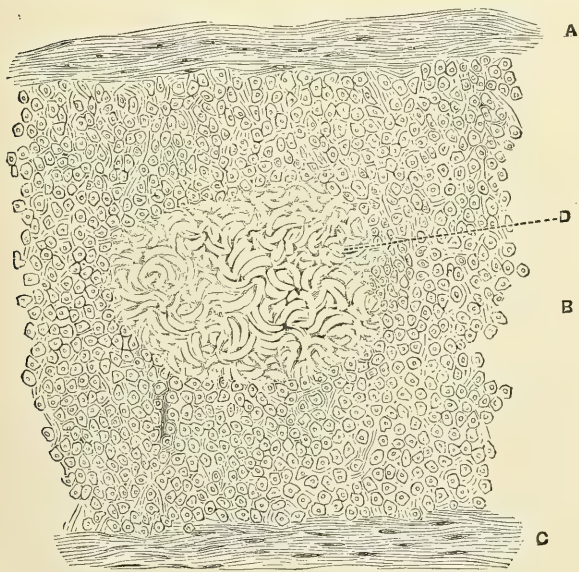


FIG. 257.—Posterior tibial artery. Section showing coagulation-necrosis. *A*, intima; *B*, media; *C*, adventitia; *D*, spot of coagulation-necrosis. Magnified 360 diameters. (From a specimen prepared by Dr. W. L. Wardwell.)

* For these conclusions the author is indebted to Dr. W. L. Wardwell.

ing aneurism), and in the smaller arteries (especially those of the brain) from occlusion or atheroma.

Even in the initial lesion of syphilis (the chancre), according to Biesiadecki, the capillaries of the papillæ have in their thickened walls many nuclei, some of which are seen to project into the lumen of the vessel.

The arteries of the base of the brain, especially the basilar and those at the commencement of the fissure of Sylvius, are often seriously involved. I have seen two cases in private practice in which death resulted from anæmia of the medulla, due to a more or less complete thrombosis of the basilar artery. A patient of Dr. Weber's, to whom I was called, died in my presence. A few days previous to his death he had complained of dizziness, and of a sensation as of insects crawling over the integument of the extremities. Death was quite sudden, and was due to respiratory failure. He became quickly unconscious, the respiratory movements were irregular, and co-ordination of movement between the expiratory and inspiratory muscles was seemingly lost. The mode of death was different from anything I had ever witnessed. At the autopsy, the basilar, just where it divided into the two posterior cerebrals, was found almost completely occluded by a thrombus. There was no other lesion which could have accounted for death. Syphilis had existed for several years.

In the second case syphilis had existed for nineteen years, with right hemiplegia for the last sixteen years of life.

This patient was under my care for nearly five years. She would never consent to take the iodides or any medicine. Her mind was clear up to the time I last saw her before death, which occurred suddenly one night. I did not see her until life was extinct, but, from the description of the mode of death given me by Dr. F. J. Ives, who was present, I was led to express the belief that a similar condition existed as in the case first referred to. On examination, I found a thrombosis of the basilar artery in exactly the same location. Fig. 258 represents a section of the artery

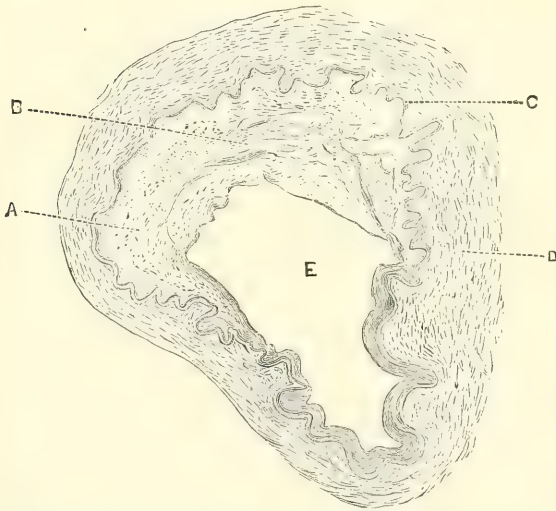


FIG. 258.—Syphilitic arteritis. Section of basilar; E, lumen of vessel about two thirds filled with new formation at A B; c, media; D, muscular layer and adventitia. From a patient dead from syphilis. (Specimen of the author's, drawn by Dr. Wardwell. Magnified about 40 diameters.)

near the thrombus. The lumen of the vessel is seen to be about two thirds occluded. The adventitia is slightly thickened, and the cell-elements in it are distinctly fusiform, and regularly parallel with each other and with

the contour of the adventitia. The wavy elastic layer is easily recognized, and in that portion of the artery in which the syphilitic inflammatory material is deposited the waves of the media are more numerous and shorter than in other portions of the vessel. In the center of the mass, occupying a portion of the caliber of the artery, is found a hyaline-looking spot which took the carmine stain more readily than the general mass of the thrombus. It contains embryonic cells in about the same quantity as the surrounding tissue. The adventitia is not regularly thickened, being three or four times as deep in some portions as in others, and presenting in the section a nodulated appearance. Viewed with a magnifying power of about five hundred diameters, that portion of the arterial wall external to the wavy line (the elastic layer), seen in Fig. 258, presents the following appearance :

In the most external limit of the section of the adventitia there are found clusters of inflammatory corpuscles, true embryonic cells, round, and larger than the cells found in any other portion of the specimen external to the elastic lamina. These cells are somewhat smaller in size than those found in the new-formed tissue of the intima, though they differ in shape, since those in the intima appear both round and fusiform, while the cells in the outer edge of the externa appear almost invariably round. It may be possible that they are fusiform cells cut transversely in the section ; though after careful examination I am led to conclude that they are round. At various points these cells do not exist, the external layer being that of fusiform cells arranged with great regularity parallel to the contour of the wall of the artery. Where the wall of the vessel external to the elastic lamina is thickest, these spindle cells are more numerous, and have a greater transverse diameter than at the narrower portions, where they seem to have elongated and become thinner—seemingly a true process of fibrillation and contraction of embryonic (inflammatory) cells.

Continuing the examination farther inward, as the white, wavy, elastic zone is crossed, just within and almost in exact apposition with this is a somewhat irregular and thin layer of cells, fusiform in section, varying in depth from a single row to two or three rows, and in some points entirely absent. These are doubtless a remnant of the original endothelia of the intima ; just internal to these, and in fact continuous with them, is the great mass of new-formed, inflammatory tissue which juts into the lumen of the vessel. This mass is composed of large, mostly fusiform, cells, distinctly nucleated and occupying about as much space as the intercellular substance in which they are imbedded.

Syphilitic arteritis has been made the subject of special study by Cornil, Heubner, Greenfield, Barlow, Buzzard, Davidson, Simes, White, and others.

Greenfield, in the "Transactions of the London Pathological Society for 1877," gives an analysis of 22 cases of visceral syphilis.

Of the 22 patients, 13 were females, 9 males. Their ages varied from 23 to 50 years. Of the females, 4 were between the ages of 23 and 25, 1

was 35, 1 was 38, the remainder between 40 and 50. Of the males, 4 were between 30 and 40, the rest between 40 and 50.

These patients did not all die from syphilis, some perishing from other and concomitant diseases. Of those who died from the effects of syphilis, the greater number were comparatively young. Of the four females under twenty-five years of age, two died from the effects of thrombosis of the cerebral arteries, one from syphilitic disease of the larynx, and one from accident. Of the six males under forty, one died from syphilitic disease of the cerebral arteries, one from gummata of the brain and dura mater, one from pneumonia due to syphilitic disease of the larynx and trachea, one from renal disease consequent upon stricture, and another by accident.

In the total of twenty-two cases, the condition of the vascular system was noted in all but six. In one case there was no lesion of the arteries. In the remaining fifteen cases the arteries were more or less seriously involved. In other words, out of sixteen cases in which the condition of the arteries was noted, in fifteen these vessels were diseased.

The author says that the condition of the aorta and large vessels, as regards atheroma, is of importance in connection with the dependence of aneurism upon syphilis, and that, as regards the smaller vessels, the nature of the disease of the cerebral arteries is of the greatest interest. In three females, aged twenty-three, twenty-five, and twenty-five, there was marked atheroma of the aorta. In one, the atheroma was general in the aorta and its larger branches, the condition being that of diffused, irregular swelling, with but little fatty degeneration. In one female, aged twenty-five, in the first part of the arch of the aorta were several patches, rounded, prominent in the center, and thicker than usual. On section these appeared homogeneous, and presented scarcely any fatty degeneration. Throughout the rest of the aorta there was general atheroma, with no peculiar characters. In another female, aged thirty-five, there were large patches of endarteritis deformans in the abdominal aorta.

In several other cases there was marked atheroma, and in most cases where there was no renal disease the patches were much raised, sometimes almost hemispherical, at other times with sharply defined edges of gelatinous appearance and pearly luster; and on section there was but little fatty degeneration or calcification.

Whether in these cases the disease would have gone on to the formation of aneurism, can not of course be decided; but it is evident that a marked tendency to the occurrence of endarteritis deformans at an early age, and in an advanced degree, exists in visceral syphilis.

The cerebral arteries were very markedly affected with syphilitic disease in five cases, and in a sixth were probably diseased.

As to the pathological changes which syphilitic arteritis causes, they are given by Dr. Greenfield in two cases of disease of the cerebral arteries.

The specimens were taken from the middle cerebral and basilar arteries. They are typical, and probably represent two different stages of the process. In the first case the disease is seen in the earlier form, in which it consists almost entirely of a cell-growth which has as yet under-

gone but little organization. In the second case considerable changes have occurred, and a large part of the new growth is converted into more or less fully developed connective tissue. In the specimen sketched in Fig. 259, the artery is seen to be somewhat irregular in shape, this being due to obliquity of the section. The lumen (*a*) is very small, but is clearly defined, rounded, and free from thrombus.

The outer coat appears somewhat thickened, and is infiltrated in continuity with the pia mater (*f*). The muscular coat (*d*) is distinctly seen at the upper and lower parts of the section, elsewhere being somewhat infiltrated, and not clearly separated from the adventitia. The fenestrated membrane is clearly seen at *b*, where it is indicated by the dark lines; it could be clearly traced, on altering the focus, all around the vessel, lying as usual immediately internal to the muscular layers, and separating them from the inner coat. It is to that part of the vessel lying between *a* and *b* (Fig. 259) that attention must be specially directed, the thickened inner coat constituting the essential feature and the peculiarly characteristic element of the morbid change. With a higher power, the thickening of the inner coat is seen to consist entirely of a cell-growth which closely resembles granulation-tissue. In the deeper parts, nearest the fenestrated membrane, the cells appear to be flattened, running parallel with the elastic layer, growing, however, more irregular in disposition toward the center. No distinct transition-line can be discovered between this deeper layer and the central part, in which, however, the cells appear to be larger, often branching and more loosely arranged, with more numerous capillaries running among them. Many of the cells in the intermediate layer appear to be rounded; but it is not improbable that

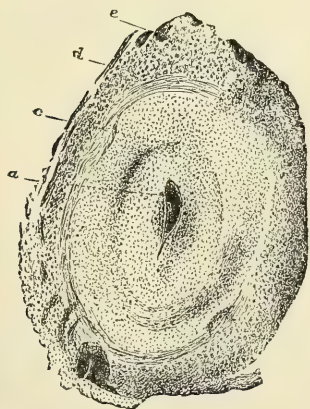


FIG. 259.—Syphilitic arteritis. Shows section of small cerebral artery near a gumma, magnified 30 diameters. *a*, lumen of vessel; *b*, boundary of inner middle coats; *c*, thickened inner coat; *d*, middle coat; *e*, external coat; *f*, infiltrated pia mater. (After Greenfield.)

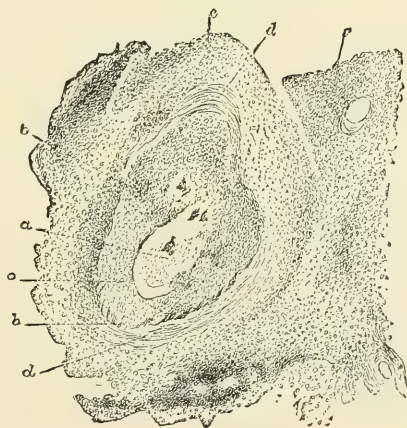


FIG. 260.—Syphilitic arteritis. Section of small artery of cerebellum, magnified 30 diameters. *a*, lumen of vessel; *c*, thickened inner coat; *d*, muscular coat; *e*, outer coat. (After Greenfield.)

they are fusiform cells cut transversely. In many parts of the thickened intima the capillaries are numerous and of large size.

Toward the lumen of the vessel the cells again assume a flattened or

fusiform shape, and several layers of these cells closely packed together form the innermost part of the new growth, the most internal, superficial layer (that in immediate contact with the blood-current) forming a continuous layer, which corresponds in its functions to normal endothelium.

The other specimen (Fig. 260) appears to have undergone different changes. The coats of the vessel are enormously thickened, and the lumen of the vessel correspondingly diminished, so as to become a narrow chink (the section is somewhat obliquely made). The thickening of the wall is found to present great variations, at points of the vessel not farther apart than one twelfth of an inch, other sections at that distance from the one represented in the cut not being more than one half as thick, the external diameter of the vessel remaining almost constant. The adventitia (*e*) is slightly thickened and infiltrated by a cell-growth. The muscular coat (*d*) is of pretty uniform thickness, except at some points where invaded with cell-infiltration from the adventitia. The inner coat is enormously thickened, and presents the appearance of two concentric rings, the boundary between which is more or less defined. Examined with a higher power (Fig. 261), the lumen of the vessel is

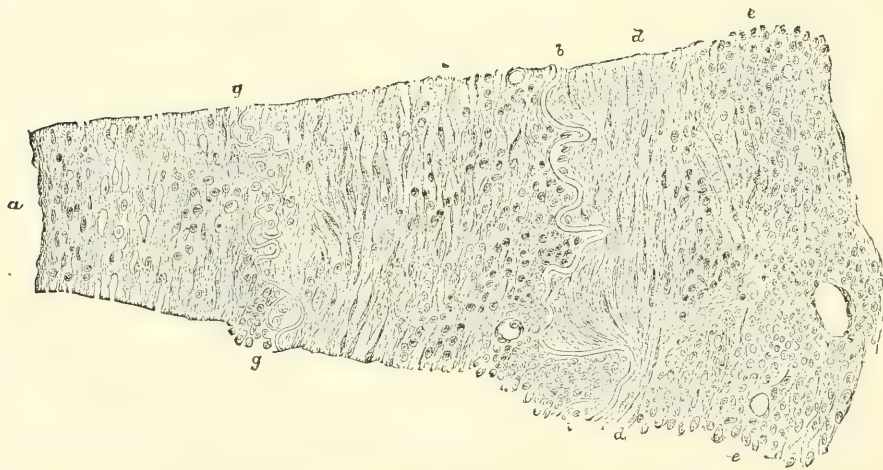


FIG. 261.—Syphilitic arteritis. Segment of the preceding specimen, magnified 170 diameters. *a*, lumen of vessel; *b*, fenestrated membrane; *c*, *e*, thickened intima; *d*, muscular coat; *v*, adventitia; *g*, new-formed imperfect elastic lamina. (After Greenfield.)

found free from thrombus. The membrana fenestrata is well defined. The muscular layer presents very much its normal appearance at some points, except that the fiber-cells are somewhat granular. At some points it is encroached upon by the cell-growth from the outer coat, between which and the muscular coat there is no distinct line of demarkation. The outer coat is somewhat irregularly thickened by cell-growth, which is especially abundant around the vasa vasorum, which are very numerous and much more developed than usual. At some points small vessels traverse the muscular and elastic coats, going into the deeper portions of the thickened intima.

The inner coat measures twice the thickness of the outer and middle

coats together. Starting from the fenestrated membrane, in its neighborhood there is found a rather abundant cell-growth traversed by capillaries. Nearer the intima is found a fibrous tissue, formed of elongated, fusiform cells and delicate, interlacing fibrils of connective tissue, the whole constituting an imperfectly developed fibrous tissue. Internal to this are seen more numerous, rounded cells, some of which are of larger size. Nearer to the lumen are seen elongated, oval nuclei, smaller and more highly refractile, and more closely packed together (Greenfield). It will be seen, by reference to my own case already given, that in the changes which occurred in the intima it was analogous to Dr. Greenfield's first case, while in the irregular, nodulated condition of the muscular layer it was analogous to his second.

According to Greenfield, the inflammatory matter in and around the perivascular canals in syphilis is entirely different from that in tubercular infiltration of these canals.

In vessels examined by Barlow, the same changes are reported as those given above (Figs. 262, 263). The adventitia and muscular coats

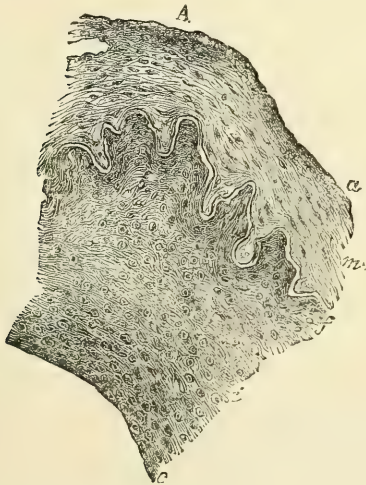

FIG. 262.—Syphilitic arteritis. Transverse section of a segment of the middle cerebral artery of a syphilitic patient. *b*, the thickened intima; *e*, the endothelium; *f*, the fenestrated membrane; *m*, the muscular coat; *a*, the adventitia. (From Barlow's Specimens, Green's "Pathology.")

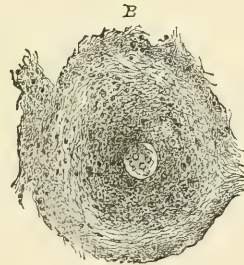

FIG. 263.—Syphilitic arteritis. Section from a small artery of the pia mater cut transversely, showing the inner coat much thickened, a diminution of the lumen of the vessel, and a considerable infiltration of the adventitia. A clot is seen to occupy a great part of the lumen of the vessel. (From Barlow's Specimens, Green's "Pathology.")

were more or less affected, "but obviously the principal changes have taken place in the intima." Davidson and Buzzard are led to the same conclusions with the foregoing, as is Green in his "Pathology and Morbid Anatomy."

Rheumatic Arteritis.—Arteritis may occur in connection with acute rheumatism. Bryant states that this is a rare form of disease. Rheumatic endocarditis is not so rare, and it is possible that endarteritis may exist in the aorta in many cases of endocarditis. This and the arteritis of gout and nephritis (Fig. 264) belong to the domain of medicine rather than to that of surgery, and will not therefore be considered in this work.

The *treatment of arteritis* resolves itself simply into the treatment of the disease of which it is a part. It would be useless to increase the

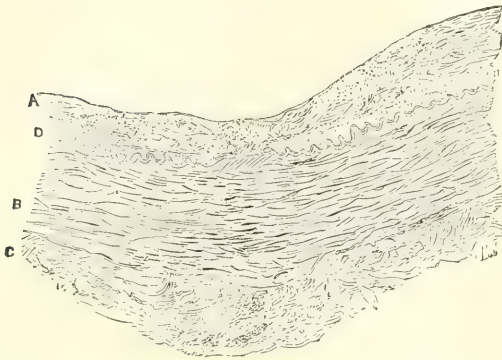


FIG. 264.—Arteritis with chronic nephritis. Section from posterior tibial artery of patient dead from Bright's disease, showing at A a great thickening of the intima, the result of chronic endarteritis. The elastic lamina, D, unchanged. The muscular layer, B, slightly thickened. C, adventitia greatly thickened at places by small-cell infiltration. Drawn from specimens prepared by Dr. W. L. Wardwell, at Conheim's Laboratory. (Magnified about 40 diameters.)

length of this article by a recapitulation of the various methods and remedies which have been employed. If the pathogeny and pathology of the affection are understood, its therapy is not difficult.

Arterial Thrombosis and Embolism.—Though not as frequent as in phlebitis, thrombosis and embolism often result from arteritis. The pathology of thrombosis has been given in the section on phlebitis. The process in the arteries is closely analogous to that in the veins.

The perfect type of thrombosis from acute, traumatic arteritis, is found after the application of an occluding ligature around an artery.

By reason of arrest of the blood-current and disturbance of the equilibrium normally existing between the blood and the containing vessels, coagulation takes place on the cardiac side of the ligature, extending back as a rule to the first collateral branch. Immediately following the injury to the vessel, the process of inflammation—true arteritis—commences. The tension of the ligature to such a degree as to divide the

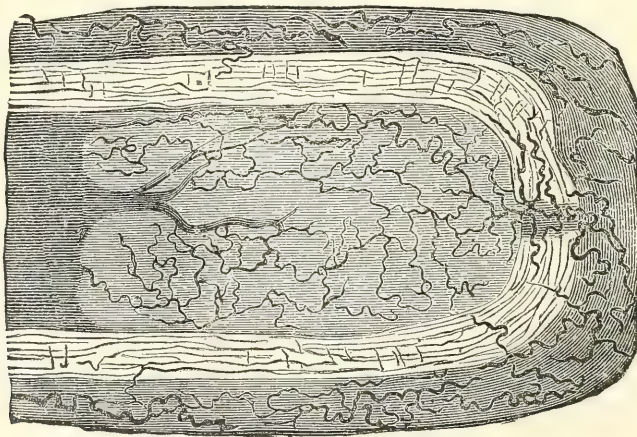


FIG. 265.—Longitudinal section of the artery of a dog fifty days after the ligature. Clot injected. Magnified 40 diameters. (After O. Weber.)

inner or middle coat, or both, is unnecessary. I have tied arteries (carotid and subclavian) in human beings, and in horses and dogs, and have speci-

mens which demonstrate successful occlusion of the vessel without division of either of the three tunics. Scarpa advanced this idea years ago, but surgeons generally have decried it.

The coagulation thrombus disappears by fatty degeneration. The permanent occlusion is due to new-formed tissue springing from the normal cells of the intima and the leucocytes. O. Weber held that the clot became organized into a true tissue, into which blood-vessels were projected from the vasa vasorum (Fig. 265). But Cornil and Ranvier long since disproved this assertion of Weber. Bubnoff held that the white blood-corpuscles emigrated through the walls of the ligatured vessel, permeated the clot, and caused its organization; but Durante (Cornil and Ranvier) has demonstrated that the leucocytes only traverse the walls of the vessel when this has been tied with a double ligature, causing a death of the included vessel, and that the leucocytes travel through this dead tissue. They do not permeate the walls of an otherwise healthy artery which has been tied with a single ligature.

Cell-proliferation takes place rapidly in the intima; granulation-buds project into the territory occupied by the clot (Fig. 266); blood-vessels derived from the vasa vasorum permeate the projecting granulation-tissue, invade the clot, meet with live vessels from the opposite side, and join with these in a continuous circulation; the embryonic tissue organizes, gradually contracts (process of cicatrization), and the walls of the vessel are permanently occluded by this fibrillation. Afterward the new-formed vessels disappear to a great degree, being obliterated by the process of contraction.

Fig. 249, from a section of the carotid of a horse, shows how this rapid proliferation of the normal cells of the intima occurs when the intima has not been divided. There was in this case simply an irritation of the intima, a bruising, the result of jamming together the opposing surfaces of the intima by means of a broad (not cutting) ligature.

Thrombosis from acute arteritis is rare. Chronic arteritis is not infrequently the cause of occlusion. Syphilitic arteritis is apt to develop thrombosis of the cerebral arteries. Arterial thrombosis (excluding the vessels to the brain and walls of the heart) is not as dangerous to life as venous thrombosis.

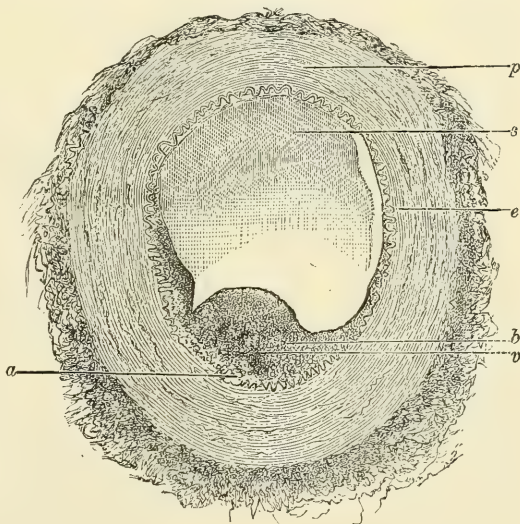


FIG. 266.—Traumatic endarteritis. Transverse section of the femoral artery of a dog eight days after the application of a ligature. *e*, the elastic lamina; *p*, the media; *b*, granulation-bud projecting from the intima into the lumen; *v*, new-formed vessel running through the inflammatory tissue. At *a* the elastic layer has partly disappeared. Magnified 30 diameters. (From Cornil and Ranvier.)

The process is usually so gradual that the collateral circulation is established before occlusion of the main trunk occurs. This may, indeed, escape observation until the enlarging superficial arteries attract attention.

The thrombus formed under such conditions differs from the organized thrombus at the seat of a ligature, inasmuch as the passing blood-current furnishes fibrin-making white corpuscles with accompanying fibrin-deposit in the one, while this can not occur after a ligature is applied.

The causes of thrombosis may be summed up as follows: 1. Occlusion of the vessel as by a ligature. 2. Inflammation of the intima (arteritis). 3. Dilatation of the vessels (as in aneurism). 4. An abnormal condition of the blood. 5. Heart failure. 6. Narrowing of the caliber of an artery by pressure.

VASCULAR TUMORS.

We may recognize six varieties of vascular tumor, apart from true aneurism. These are: 1. Arterial varix; 2. Cirroid arterial tumor, or cirroid aneurism; 3. Arterial cutaneous tumor; 4. Capillary cutaneous tumor; 5. Venous cutaneous tumor (these three varieties are usually classed together under the name of *angeiomata*); and 6. Venous varix, or simply varix (varicose vein).

Arterial Varix may be defined as a dilatation and elongation of an artery of the second magnitude (as the external iliac or common carotid), of the third (as the external carotid or posterior tibial), or of the fourth (as the temporal, facial, superior thyroid, or palmar branches of the radial and ulnar). Cruveilhier has reported a case of *arterial varix* of the external iliac artery. I have made one dissection of *arterial varix* of the superior thyroid artery, in which this vessel was greatly elongated, and as large as the external or internal carotid. It was tortuous, but not sacculated, the dilatation being general. Tillaux* reports a case of *cirroid aneurism* of the hand, with dilatation of the arteries of the forearm and humeral region.

Treatment.—Arterial varix may be treated by compression, or by the ligature, when such a procedure becomes necessary. In a case which I saw after the patient's death, and in which the superior thyroid artery was involved, the ligature would have been advisable. The artery was in a healthy condition, with the exception of its increased length and caliber.

When connected with *cirroid arterial tumors*, the solidification of these by ligature, cautery, or injection, will usually cure or palliate the arterial varix.

Cirroid Arterial Tumor, or Cirroid Aneurism.—The *cirroid arterial tumor* I would define, after Robin and Gosselin, as being an elongation and dilatation of the terminal subcutaneous arterioles (normally of a diameter of about one fiftieth of an inch). These tumors may be general

* "Gaz. des hôpitaux," 1882, p. 1083.

or circumscribed. A single arteriole may be affected, as shown in a drawing in the Museum of St. George's Hospital, copied in Holmes's "System of Surgery," or many arterioles may be involved, as in Mussey's remarkable case.

The term *cirroid aneurism* was introduced by Breschet, in a paper presented to the Academy of Medicine, at Paris, in 1832. By him it was applied to the condition of varicosity involving the larger arterial trunks, their branches, and the terminal arterioles. Robin, at a later date, introduced the name of *cirroid arterial tumors*, and defined these as varicosities of the terminal (subcutaneous) arterioles.

English writers have adopted the term employed by Breschet. By them it is usually considered "a form of disease which consists in a simultaneous elongation and dilatation of an artery. The structure of its wall exhibits in the beginning no alteration, although the coats become thinned during the progress of the enlargement. The middle coat of the artery is especially affected. It becomes pale and thin, so that the arteries look like veins. The dilatation is commonly equal throughout the circumference of the artery. In more severe cases the artery is greatly dilated, and presents unequal, saccular pouches, which are in fact so many true aneurisms, projecting usually toward the surface of the skin" (Holmes).

Gosselin * adopts the nomenclature of Robin, and considers the disease heretofore known as cirroid aneurism as only involving the terminal arterioles. The causes of *cirroid arterial tumors* are not positively known. They occur most frequently upon exposed surfaces of the body, as on the neck, head, and hands. The face and head are most frequently the seat of all forms of vascular subcutaneous and cutaneous tumors. Excluding those of the orbit, I have collected more than ninety cases in which the carotid arteries were tied for these lesions.

Polaiillon reports fourteen cases of cirroid aneurism of the hand. The influence of exposure of an unprotected surface to atmospheric changes is worthy of consideration. Either peripheral or central disturbances of the functions of the vaso-motor nerves may lead to loss of tone in the muscular walls of the arteries. Frost-bite and blows have been mentioned as causes of cirroid aneurism. Berger reports a case of cirroid tumor of the hand caused by irritation, from constant pressure of an instrument which the patient used in his trade. The disease may also be congenital, or may result from the increased growth of a cutaneous nævus. Gosselin cites two cases of this kind. He holds that the presence of nævus indicates a congenital predisposition to vascular dilatation, and is not sure but that a subcutaneous arterial dilatation, at first not recognized, may exist simultaneously.

According to Holmes, cirroid arterial tumor occurs most frequently between the ages of fifteen and thirty. Wardrop's patient, whose case is given by Gosselin as one of cirroid arterial growth, was operated upon the sixth week after birth. Wardrop gives the case as one of "erectile

* "Archives générales de médecine," 1867.

tumor." Chelius operated for "aneurismal varix of the temporal region" in a child of twelve months.

Symptoms.—The *clinical history* of cirroid arterial tumors does not commence with the pathological changes which occur in the terminal arterioles. Dilatation begins before there is any appreciable projection of the skin, or pulsation, or twisting of the arterioles. At a later period the physical signs are present, and the diagnosis easy. Direct pressure will arrest the pulsation and empty the tumor. The consistency of these tumors varies with the amount of the connective tissue developed around the arterioles, as a result of the inflammatory process. Petit describes the sensation imparted to the palm of the hand pressed upon an arterial cirroid as similar to the vermicular motion of a mass of earth-worms.

With the stethoscope, a bruit de souffle is distinctly audible. Pain is not constant, and is only due to the pressure of the growth upon the cutaneous nerves. As the tumor progresses in size, more marked inflammatory changes occur; adhesions to the skin take place; and ulcerations, with alarming hæmorrhages, are not infrequent. In some instances, especially in cirroid tumor of the scalp, pressure of the growth upon the calvaria may interfere with the nutrition of the skull.

Treatment.—It may be said of the treatment of cirroid arterial tumors, in common with arterial, capillary, and venous cutaneous tumors, that no method is as safe or sure as direct local treatment. The study of a large number of cases leads me to this conclusion. For a long time deligation of the main trunk or trunks was the favorite practice. Sometimes this was done to arrest hæmorrhage due to ulceration or accident, in some few cases to arrest hæmorrhage after or during an attempt at removal, but most frequently the intention was to cut off the blood-supply. Since the vast majority of vascular tumors occupy the neck, face, and scalp, the carotids have been often tied in the treatment of these growths. In my "Essays in Surgical Anatomy and Surgery"* I have collected 98 cases of ligation of the carotid for vascular growth above the clavicle, and chiefly of the head. This number does not include 60 cases of pulsating vascular tumor within the orbit. The results are not such as to encourage the careful operator in a repetition of the procedure.

Even in the nine cases in which both common trunks were tied,† only one was cured (not, however, until after compression was made over the tumor), and two were improved. Mussey's patient was only improved after the second ligation, but was cured after a bloody excision. The tumor was exceedingly large, and the dilated arteries were tied one by one. More than twenty ligatures were applied, and the hæmorrhage is said to have been dangerously profuse.

Other surgeons besides Mussey ‡ who have practiced excision of cirroid arterial and other "vascular tumors" are Busch,‡ Heine,‡ Graefe,‡

* New York, 1879.

† The operators were Blackman, Gunderloch and Müller, Kuhl, Mussey, Pirogoff, Robert, Rodgers and Van Buren, Ullman, and Warren.

‡ See the author's "Essays in Surgical Anatomy and Surgery," New York, 1879.

Holmes's "System of Surgery," second edition, vol. iii, p. 540.

Gibson,* Buchanan,† Sydney Jones,‡ Warren,§ Weitzer,* Guéniot,* and Hart.* The latter froze the tumor, and cut well into sound tissue; little blood was lost. The late Prof. Spence, of Edinburgh, cured a deep-seated erectile tumor of the hand by galvano-puncture. || Nélaton operated in a cirroid tumor of the forehead in a similar way, and with like success.

Barwell operates upon vascular tumors by what is termed the *scarless method*.^A Having carefully made out the limits of the tumor, a needle armed with a silver wire is passed under the skin, and subcutaneously around the outskirts of the tumor, to a point opposite the place of entrance. The needle is again introduced at the point from which it has just emerged, and is carried around the remainder of the tumor, and out at the first point of entrance. The base of the tumor is thus looped by a wire which can be tightened beneath the skin at will. Barwell uses a slot of vulcanized rubber, which he slides down upon the wire to tighten it around the tumor. If the growth be very large, he advises the needle to be brought out at frequent intervals.

Direct local compression has been tried by patient and expert surgeons, but has not met with success.

Gosselin◇ in his classical paper reports several successful cases in which he employed hypodermic injections of perchloride of iron into the mass. This idea was original with Broca, who applied the styptic endermically with success. Pitha, of Prague, and Schuh, following Broca, thus cured three cases (Gosselin). Berger‡ reports a case of cirroid aneurism of the hand treated by this method. Velpeau, Gherini, and Demarquay have performed the same operation. In Demarquay's case, the radial and ulnar arteries had been tied.

The method of procedure is as follows: The tumor must be compressed, so that, while the circulation ceases, the growth remains full of blood. This condition must be maintained for at least ten minutes after the injection. The syringe being filled, the air is carefully excluded, and the needle is introduced about a quarter of an inch into the mass, when the solution is discharged. Kneading, to disseminate the fluid, is then practiced, and the finger is placed upon the hole made by the needle, or the needle and syringe may be left in, during the ten minutes.

Pain is immediately present, and persists for several hours. After an interval of ten or fifteen days, the operation may be repeated, if necessary. Eight or more operations have been required to effect a final cure. Ulceration may follow, but it is usually limited. At times, unhealthy granulations bud up from these ulcerating patches, requiring repeated burning with nitrate of silver or with the actual cautery.

* Holmes's "System of Surgery," second edition, vol. iii, p. 540.

† "British Medical Journal," June, 1875, p. 835.

‡ "Lancet," 1882.

§ See the author's "Essays in Surgical Anatomy and Surgery," New York, 1879.

|| "Medical Times and Gazette," August 21, 1875, p. 209.

△ "Lancet," May 8, 1875, p. 642.

◇ "Archives gén. de médecine," tom. ii, 1867, pp. 636-659.

‡ "Gazette des hôpitaux," 1882, p. 1082.

In one of Gosselin's cases, hæmorrhage was so frequent and persistent that deligation of the parent vessel—the femoral—was at one time considered; but this was happily avoided by repeated use of the actual cautery.*

The results of this method of treating cirroid vascular tumors are gratifying, and the operation is worthy of repetition. In growths of small size I should prefer to try the method of Barwell, and, if this failed, then the injection of perchloride of iron or other coagulating solution. The success achieved by Spence and Nélaton with galvano-puncture was such as to justify further trial of this method.

Cases of spontaneous cure of vascular tumors are reported. Dr. Krackowizer presented to the New York Pathological Society a patient in whom pulsation had entirely ceased in a cirroid tumor which was contracted, solid, and shriveled at various points; the peculiar rustling noise, also, of which the patient had complained, was now entirely absent when he was quiet. The man was forty-five years of age; the tumor was congenital, and had grown to a considerable size, but without pain or hæmorrhage. Dr. Krackowizer referred to two other cases recorded by Orfila and Chevalier.

* Gosselin's cases were three in number:

CASE I.—*Cirroid Arterial Tumor of the Left Leg.*—The patient was a woman, aged twenty-five. At birth she had a small red stain or spot in the skin at the upper and anterior part of the left leg, which up to her twelfth year had grown about as large as an almond. At fifteen she first noticed that pulsation began in it. After this date it grew more rapidly, projecting, however, very slightly from the surface, until, at the age of twenty-two, it began to ulcerate without any assignable cause. Hæmorrhage occurred, which ceased by compression, but not until syncope had ensued. Repeated bleedings occurred up to her twenty-fifth year, when the injections were commenced. From July 12th to August 23d, seven injections were made. Ulceration began, and frequent hæmorrhages occurred between October 12th and 18th, which were arrested by the actual cautery and compression. Cure resulted at the end of eleven months.

CASE II.—*Cirroid Arterial Tumor of the Forehead with Arterial Varices; Hæmorrhage during Many Years; Four Injections of Perchloride of Iron; Cure.*—Patient was a man, aged thirty-nine; was born with a red mark on his forehead, which disappeared at his tenth year. About nineteen years later, when in his twenty-ninth year, a tumor was noticed in the same place, about as large as a cherry-stone, and two years later he felt it begin to pulsate. After that time it continued to grow, and was the source of frequent hæmorrhages without any direct injury or known cause. The patient had controlled the bleeding by compression. At the time of operation, the growth was about two inches in diameter, and projected from the skin about one third of an inch. February 12th, while pressure was made on both primitive carotids, injections were made with two syringes, one needle being introduced on each side of the tumor. The compression of the carotids was continued ten minutes. The tumor still pulsated at points. Compress applied; pain was severe during the day of operation and the next day following. Operation repeated on the 1st of March. March 13th, tumor was solid and without pulsation throughout two thirds of its extent. Two injections made. March 20th, tumor began to ulcerate at two limited points, which were soon filled with exuberant granulations. These resisted alcoholic dressings and the application of nitrate of silver. March 24th, pulsation reappeared at one point, and the injection was repeated. May 20th, the granulations persisting, actual cautery was applied. Same on June 6th. July 8th, patient discharged, cured.

CASE III does not differ materially from the two preceding cases, either as to its clinical history or as to its treatment.

Angeiomata.—The three next varieties of “vascular tumor,” which may be grouped together under the name of *Angeiomata*, are: (1) The *Arterial Cutaneous Tumor*, or *Aneurism by Anastomosis*, composed of dilatations or elongations of the arterioles, either normal or new-formed, in the skin; (2) the *Capillary Cutaneous Tumor*, consisting of dilatations and elongations of the normal or new-formed capillaries of the skin; and (3) the *Venous Cutaneous Tumor* (*Cavernous Nævus*), composed of dilatations of the normal or new-formed venous radicles of the skin.

The angeiomata are considered by some writers as strictly new-formations of blood-vessels. There is little doubt, however, that many vascular tumors are chiefly made up of normal vessels which have undergone dilatation or hypertrophy. Other names that have been given to angeiomata are congenital nævus, erectile tumor, telangiectasis or plexiform angeioma, aneurism by anastomosis, ecchymoma, cavernous nævus, and fungus hæmatodes. According to Depaul, one third of the children born in one of the eleemosynary institutions at Paris had congenital nævi, the greater number of which disappeared spontaneously during the first few months of life. They occur chiefly in the skin, and are especially apt to appear on the forehead, face, ears, and neck.

Structure and Symptoms.—Angeiomata commonly form flattened, slightly projecting tumors, varying in size from a mere speck to as much as an inch in diameter, and are composed of new-formed, dilated, freely anastomosing capillaries, arterioles, and veins, in irregular, labyrinthine masses. They vary in color, being at times grayish-blue or red. Often the only indication of their presence is the appearance of a diffuse redness over a considerable surface. Examined microscopically, the walls of the vessels are crowded with cells, and the vessels are imbedded in a network of fibrous and adipose tissue. The superficial and deep cutaneous vessels—including the vessels of the hair-follicles, sweat-glands, and adipose tissue—join in the formation of these tumors. The disease may extend into the muscles and deeper tissues.

The majority of angeiomata are soft and yielding, and can be emptied by pressure; but when of great vascularity and long standing, when there has been an extensive proliferation of the perivascular connective tissue, pressure will not cause their disappearance. Some are very painful, and others entirely free from sensibility.

Venous cutaneous tumors are composed, in great part, of new-formed, erectile tissue, analogous to that found in the corpora cavernosa. Their structure is white and dense, the caverns communicating freely with each other. In rare instances they are known to contain chalky concretions, which are known as *phlebolites*. The circulation is active in these tumors, and their volume variable.

The walls of the sinuses contain a dense, fibrous stroma, involuntary muscular tissue, and striated muscular fibers when the tumor is encroaching on the muscles. They are lined by the same endothelium as the normal veins. In specimens removed and immediately immersed in alcohol, it is found that the blood presents the same appearances as the normal, with the exception that the white corpuscles are less numerous

(Fig. 267). They do not adhere to the walls of the vessels. This is considered as proof of a rapid circulation, since in veins where the circulation is weakened or retarded the leucocytes tend to adhere to the walls. After excision, the vessels contract, forcing out their contents, and the mass shrinks to a comparatively small size.

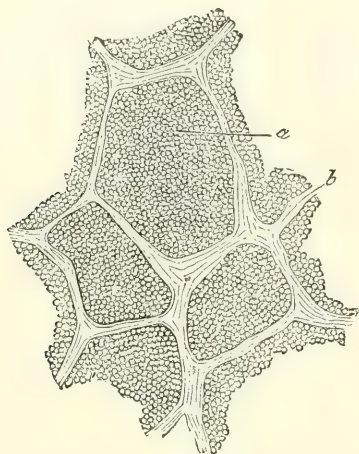


FIG. 267.—Cavernous angioma of the liver. Section made after the tumor had been immediately submerged in alcohol. *a*, cavernous spaces filled with blood-corpuscles; *b*, fibrous walls of the sinuses. Magnified 150 diameters. (From Cornil and Ranvier.)

These tumors are not all erectile, and some which have been erectile for a time lose this property. Gross describes a form of nævoid tumor as *nævoid elephantiasis*, consisting of a hypertrophied condition of the skin and subcutaneous connective tissue. The affection, which is either congenital or comes on soon after birth, is found usually in the lower extremities, though it may occur elsewhere.

The theories as to the origin of these neoplasms are various. Some hold that simple dilatation of contiguous veins occurs when, the sacculated vessels coming in contact, the walls are absorbed, and thus many cavities, which formerly were separate, may form one or more large, multilocular, cavernous tumors. These dilatations occur not only in the skin and subcutaneous tissues, but also in bone and

muscle. No tissue can be considered exempt. Rokitansky holds that they originate in the areolar tissue, from embryonic, new-formation tissue, and that the vascularization of this new tissue is one of the last processes of its development. He compares the alveoli of the cavernous angioma to those of carcinoma.

Rindfleisch believes that the appearance of these tumors is preceded by a proliferation of embryonic material in the intervascular spaces, and that this material, undergoing the usual process of cicatrization and contraction, causes a shrinkage in the intervascular areas, when the vessels dilate to occupy the space left vacant by the contracting tissues (Billroth).

Cornil and Ranvier say that in the active development of angiomatata there is a proliferation of embryonic tissue, rich in new-formed vessels, which, increasing rapidly in size, come in contact and communicate with each other by absorption of contiguous surfaces.

Angiomatata may develop in fatty and other neoplasms. Billroth mentions a case in which a large cavernous angioma was found in a lipoma removed from the scapular region. They have been known to originate as a result of injury. Gross cites a case, reported by Dr. J. Mason Warren, of a man thirty-six years old, who had a large aneurism by anastomosis, situated on the lobe of the ear, which resulted from a frost-bite which the patient had suffered in his sixteenth year. In addition to the tissues already mentioned in which angiomatata are developed may be mentioned the spleen, kidney, liver, and lung. The liver is fre-

quently, the lung very rarely, involved. In bones, this disease exhibits the same erectile characters as in other structures (Fig. 268). It occurs in the flat bones by preference, especially those of the cranium, jaws, and scapula, being often very painful, and grave as to prognosis. *Angeiomata* are not infrequently situated on the labia of women. Holmes Coote has observed serous cysts in connection with these vascular growths. An explanation of their formation is, that communication of a portion of one dilated vessel with other vessels is cut off, and that the corpuscles and coloring matter of the blood disappear, the serum remaining as a cystic fluid.




FIG. 268.—Aneurism by anastomosis in parietal bone. (Erichsen.)

The question of the relation of these tumors to carcinomata and sarcomata is worthy of consideration. J. Müller has reported a malignant (recurrent) *angeioma*. A case of melanotic degeneration of a congenital *nævus* in a woman aged forty has been reported by Dr. Styles. The vascular dilatations in osteo-sarcomata, and in other forms of carcinoma and sarcoma, are analogous to those found in cavernous *angeiomata*. Some of the malignant tumors pulsate like the *angeiomata*. An *angeioma* may be diffuse or encapsulated.

The *prognosis* depends upon the size and location of the neoplasm.

The *diagnosis* is not difficult in the superficial tumors, but in those deeply situated, and in the track of large vessels, the differentiation from aneurism is not easy.

The arterial and capillary cutaneous tumors are almost always congenital; the venous tumors are rarely so. *Angeiomata* may be distinguished from osteo-sarcomata, which have perceptible pulsation, by the crackling impression conveyed to the sense of touch from the malignant tumors of bone.

Several consecutive telangiectases may occur in the same individual. Hutchinson, of London, reports the case of a child which had over one hundred *nævi*, all distinct and superficial. Vascular tumors on the scalp have an element of danger not present in *angeiomata* elsewhere, in that they at times grow to such an extent as to cause necrosis of the calvaria.

Treatment.—*Angeiomata* have been known to heal without surgical interference, as a result of an idiopathic inflammation. Transfixion and multiple deligation is one of the most radical and successful methods of treatment. Direct and prolonged pressure has been employed, though not with encouraging results. Perforation with hot needles, either with or without the galvanic current, injection of coagulating fluids, particularly Monsel's solution, 50 per cent carbolic acid, or of ergot, local applications of nitric acid or other escharotics, and extirpation by the knife.

have all been practiced. Vaccination over the growth has effected a cure in a few cases.

In treating superficial angeiomata, not too extensive, and not situated where the cicatrix would prove a deformity, 50 per cent carbolic-acid injections may be employed. In many cases coagulation of the blood-contents and ultimate absorption will occur without a scar. A quicker method of cure is removed with the knife, the incision extending well away from the margins of the tumor in healthy tissues. Hæmorrhage is to be controlled by pressure, rapid use of forceps, or preliminary ligature.

Angeioma of the face, or of any exposed surface where a scar is to be avoided, is best relieved by the clean cut of the knife, since the cicatrix is less deforming than that produced by other modes of treatment. I have removed a number of these growths from the scalp and face. The incision should be made one fourth of an inch from the edge of the tumor, cutting only through healthy tissue. When this precaution is taken, hæmorrhage is not dangerous. Of course the operation is not justifiable if telangiectasis involves more surface than can be covered by stretching or sliding the sound integument, or when it requires removal of the eyelid, ala nasi, or too much of the lip or ear. In such instances galvano-cautery needles or frequent and limited injections should be employed. In cavernous tumors of large size the following method, recommended by Prof. Esmarch, of Kiel, may be successfully employed :

Immerse a middle-sized silk thread for one half hour in tinct. ferri. chlor.; remove and dry. A round, straight, or slightly curved needle is armed with this thread and passed through the tumor in all directions at intervals of about one fourth of an inch. The first series of threads should be passed through the deeper portions and parallel. If the nævus is considerably elevated, a second layer should be inserted at a right angle to the first. The threads are cut off a half-inch from the surface of the tumor and left in position. A light sublimate or carbolated gauze dressing should be laid on, and over this a layer of borated cotton, held in place without too much compression by a bandage.

In from two to four days complete coagulation occurs and the threads are to be removed. If absorption is not rapid, the coagulated mass may be removed by dissection. By this procedure I succeeded in consolidating and removing an enormous cavernous nævus of the face. The disfigurement was very slight.

Venous Varix, Varix, or Varicose Vein.—This variety of “vascular tumor” consists of a dilatation and elongation of the deep or subcutaneous veins. This condition may exist in any portion of the body, even in the bones (Cornil and Ranvier). It may involve a small portion of one vein, superficial or deep, or, as is most usual, a chain of veins. It is most frequently observed in the superficial veins, though Verneuil says that varix is really as common in the deep-seated as in the superficial vessels (Bryant). It is especially prone to occur in the saphena veins. Hæmorrhoids and varicoceles are common forms of varix. Unusual types are the dilatation of the jugulars from stenosis of the vena cava descendens, and that of the superficial abdominal veins from stenosis of the ascending

cava. Such conditions are described by some authors as simple hypertrophies or dilatations of veins. Any long-continued dilatation constitutes a varix. Hyperplasia of the normal tissues of the venous wall is the natural sequence of prolonged pressure and increased function. The hypertrophy of the wall is not always equal to the resistance of the increased pressure; hence sacculated pouches occur when the vessel-wall becomes much thinner than normal, not infrequently resulting in rupture. Varix is of frequent occurrence in women who have had repeated pregnancies (Billroth).

Poorly-fed and hard-worked persons, especially those who work in the upright posture, are more prone to varix than others. There can be no doubt that gravitation is the chief and immediate cause of this disease. The veins most subject to the greatest, prolonged blood-weight, and least protected by pressure, are involved in the great majority of cases. Paralysis of the muscular walls, either by atrophy of the muscles or interference with the function of the *nervi vasorum*, may cause varix. This is proved by the fact that a small segment of a single vein in the upper portion of the body, where the anastomosis is free and gravitation can not be considered as a factor in the dilatation, may be the seat of this affection.

In well-marked *varix* the veins are greatly increased in caliber and in length, so that they seem coiled and twisted upon themselves in knotted masses. They are narrowed in caliber at frequent intervals, these contractions opening into expanded pouches, in general appearance not unlike the sacculated large intestine. The valves are wholly inefficient, often flattened against the wall, or at times partially destroyed. At the level of the valves the walls are exceptionally thickened. The thickening is due to a multiplication of the muscular elements and hyperplasia of the connective tissue. The connective-tissue new formation is abundantly distributed in the meshes of the elastic net-work, and the bundles of fibers are usually arranged parallel with the long axis of the vessel. This accounts for the longitudinal ridges seen on the inner surface of the affected veins (Cornil and Ranvier). Even the nutrient vessels of the walls of these varicose veins—the *vasa vasorum*—have undergone hypertrophy, and are themselves the seat of varix, forming at times venous caverns in the wall of the vessel, which communicate with the vein. The internal tunic is not, properly speaking, thickened, except at the points of attachment of the valves, or when a thrombus has formed.

Immediately external to the middle elastic tunic, the muscular tissue appears increased in quantity, arranged in transverse and perpendicular laminae, separated by bundles of hypertrophied connective tissue, which are not infrequently stained with granular pigment. Calcareous deposits occur primarily within or between these connective-tissue bundles (Cornil and Ranvier).*

Hypertrophy of the connective and other tissues in the immediate vicinity of a varix of long standing presents the usual appearances of

* In the arteries, these deposits occur first around and within the nucleus of the unstriped muscle, and gradually increase until they fill the cell, which becomes converted into a small calcareous flake (Green). See section on "Arteritis."

elephantiasis. Small spots of ulceration occur as a result of malnutrition, and, coalescing, form the large and obstinate ulcers seen so frequently in varix of the legs. The veins become greatly elongated and assume different shapes, irregularly sinuous or corkscrew-like, twisted upon their axes, and frequently, on account of perivascular inflammation, matted together by new-formed connective tissue into venous tumors. Occlusion of varicose veins may result from thrombosis, and a cure may thus ensue. Frequently concretions are found in varicose veins, at times adherent to the walls. These concretions are called *phlebolithes* or *phlebolites* (Dunghlison). They are laminated on section, and are said to contain by analysis 20 per cent of protein matter, with phosphate and sulphate of lime and sulphate of potassium (Franklin and Bryant), and, according to Gross, a trace of oxide of iron. They are found most frequently in the veins of the pelvis, about the bladder and prostate, especially when the latter is enlarged. Hodgson says that they are formed in other tissues, and work their way into the vessels. This theory would seem to receive a partial support from the statement just made, that they are most frequently found near the prostate, and when this organ is diseased. It is well known that small calculi are frequent in this body. Phlebolites are also found in veins not subject to varix. Cruveilhier believed that they were developed from coagula (Holmes).

Treatment.—Varicose veins are to be treated chiefly by artificial support to the weakened and dilated walls. Eczema and the various forms of ulcer occurring in connection with varix are relieved by proper support. The varix, however, is not often cured by this means alone, which is merely palliative. Martin's elastic bandage is of great use. Bandages of muslin or flannel, properly applied, give great relief. The elastic silk apparatus, for constant, equable pressure, cleanliness, and comfort, can not be surpassed in the treatment of varix. The relief of pressure by position is always advisable. All supporting apparatus should be removed at bedtime and adjusted before rising. The only method of radical cure is by occlusion. The use of a subcutaneous catgut ligature, passed at several points under and not through the veins, is the most approved method. With careful antisepsis and the use of cocaine this procedure is painless and not dangerous. The cases are, however, exceedingly rare where such procedures are necessary.

MOLES.

Closely connected with the more superficial forms of vascular tumor are the abnormal, circumscribed hypertrophies of the skin, which are known as *moles*. They may be, and usually are, congenital, or they may be developed at any period of extra-uterine life. All portions of the cutaneous surface may be the seat of this form of hypertrophy, but the exposed surfaces, such as the face, neck, and hands, are most frequently affected. The hypertrophy which constitutes the mole may

involve all or any one of the tissues which enter into the anatomy of the integument. The most frequent variety is that which occupies the face, as a simple elevation from which a few stiff hairs grow. It is not stained with pigment, and differs very slightly, if at all, in color from the normal skin. The lesion here is a true hypertrophy of all the tissues of the skin, chiefly in the derma and papillary layer. The vascularity is slightly increased, and the sebaceous glands connected with the hair-follicles take part in the hypertrophy. On other portions of the body this form of mole (*nævus vulgaris*) will have no hairs growing from its surface.

Nævus pigmentosus is not usually a thickening of the entire cutis, as is the simple mole just described, but its pathological condition is an excessive deposit of pigment in the Malpighian layer and in the epidermis. It varies in color from a slate-gray to a blue, mahogany, reddish-brown, or wine-color. At times the pigment mole will extend over a large area, occupying as much as one third or one half of the face. The lobule of the ear, and the integument between the eyes and over the temple, is the most common location of this deformity. Another name for these spots is "*port-wine mark*."

When the hypertrophied area of skin is studded with hairs, it is known as *nævus pilosus*, or hairy mole. It follows from the name that this form of hypertrophy can only occur on those portions of the cutis in which the hairs grow. The plantar surfaces of the feet and the palms of the hands are never affected. They may or may not be stained with pigment. The majority of hairy moles are not colored.

Moles, whether simple, hairy, or pigmented, are benign. As a result of irritation, they may inflame and become ulcerated, or may develop into malignant growths. Carcinomata, especially of the melanotic variety, are frequently described as having resulted from inflamed pigment moles. Alarming hæmorrhage has been known to occur from a mole more than usually vascular, in which ulceration had been established by friction of the clothing.

Treatment.—As long as no deformity or inconvenience results from these formations, it is better to let them alone. When situated upon the face, of such size or position that they become offensive to the eye, they may be removed by simple excision. The incision should be elliptical, and well away from the growth, going entirely through the thickness of the skin. The wound should be closed with fine sutures, or drawn nicely together with adhesive strips. The simplest method of procedure is to produce local anæsthesia by cocaine, and operate quickly. *Port-wine marks* may also be excised.

If a mole should at any time take on inflammatory action, or give any indication of malignant proliferation, immediate excision would be imperative, and the incision should be wide of the supposed area of the disease. The employment of caustics or irritants of any kind is to be deprecated, as they would increase the tendency to malignant change in these growths.

CHAPTER X.

ANEURISM.

AN aneurism is a sacculated tumor, the cavity of which communicates with an artery, and in rare instances also with a vein.

They may be classified as *spherical*, *fusiform*, and *dissecting*.

A *spherical* aneurism is one in which the tumor is well defined, the diameter of its cavity being larger than the diameter of the opening of communication with the vessel. It may spring from any portion of the arterial wall (Fig. 269, *e*), or, in rare instances, the vessel-walls may yield in all directions to form the tumor (Fig. 269, *c*).

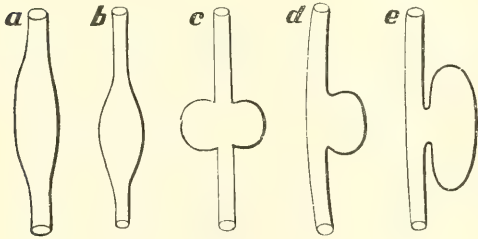


FIG. 269.

A *fusiform* aneurism is one in which there is a gradual and general dilatation of an artery in its entire circumference (Fig. 269, *a, b*). A spherical aneurism may occasionally develop from the wall of a fusiform dilatation.

A *dissecting* aneurism is one in which, owing to pathological changes in the intima, with necrosis, the blood insinuates itself between the inner coat and the adventitia, dissects the intima from the media and adventitia, and re-enters the vessel at a distant opening.

Aneurisms are further divided into the *true* and *false*. To the former belong all tumors the walls of which are composed of the walls of the vessels from which they spring; to the latter belong those tumors the walls of which are composed of inflammatory new-formed tissue.

Cause.—A true aneurism is always preceded by *arteritis*, which results in atheromatous degeneration of the normal elements which compose the arterial wall.

The *pathology* of arteritis and the relation of this condition to various dyscrasias—as syphilis, nephritis, gout, rheumatism, etc.—have been fully dwelt on in a preceding chapter. These are among the diseases which are favorable to the development of aneurism. The relation of violence to these tumors must not be lost sight of. No matter how severe the dyscrasia and the general condition of arteritis, which is a part of it, it is well known that in the large majority of cases aneurisms develop at those points in the arterial system which are subjected to the greatest

violence from heart-action, or muscular or mechanical pressure. Thus the arch of the aorta, and that portion of the arch in the direct axis of the left ventricle, is very prone to aneurism, as are the great vessels near their origin from the aortic curve. The popliteal arteries, subjected as they are to violence in forced flexion of the legs, are frequently the seat of aneurismal dilatations.

From a study of the various conditions which produce aneurisms, it is evident that the normal wall of an artery can not form the sac of the aneurism. Some of the normal anatomical elements may be present in the sac, but the integrity of the whole is impaired; and it may be that, in the progress of an aneurism which began in atheromatous degeneration of a part of the elements of the vessel-wall, all of these elements will eventually disappear, being replaced by an inflammatory new formation.

A sacculated aneurism may in rare instances communicate with a vein (*varicose aneurism*) (Fig. 270). The direct communication of a vein and artery without a sac is known as *aneurismal varix* (Fig. 271).

If an aneurismal tumor be examined, it will be found to contain coagulated blood in all stages of fibrillation. The peripheral portion of the clot is composed of irregular laminæ, and, if examined with the microscope, the laminated appearance is found to be due to alternate layers of white corpuscles, and upon these a deposit of fibrin (a condition which goes to sustain the theory of A. Schmidt, already cited, that fibrin ferment, the coagulation factor of the blood, is resident in the leucocytes). As the center of the tumor is approached, the coagulation is evidently more recent, while in the cavity of the aneurism a soft post-mortem clot is usually found.

Fusiform aneurism occurs most frequently in the thoracic aorta, with especial preference for the arch. It may affect the entire aorta, and the great vessels derived from it. Not only is the diameter of the arteries increased, but the hypertrophy results in a considerable increase in their length. Not infrequently a group of fusiform expansions may be seen with strips of sound and non-dilated artery intervening. Calcareous deposits occur in patches, and seem to give strength to the walls, since those portions give way more readily which are not the seat of calcification.

Coagulation is not apt to occur, as in sacculated aneurisms; in fact, it is a rare condition. Fusiform aneurisms develop slowly, and, as a rule, are painful and dangerous only when, by reason of their large growth, they exercise undue pressure upon important organs. Thus, in dilatation of the transverse arch, or of the right subclavian, spasm of the glottis occurs from irritation of the recurrent laryngeal nerves, or respiration and deglutition may be seriously embarrassed by direct compres-

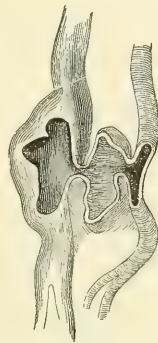


FIG. 270.
Varicose aneurism.

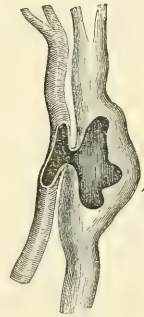


FIG. 271.
Aneurismal varix.

sion of the trachea or œsophagus. Fusiform dilatation of the abdominal aorta may produce serious results from disturbance of the vaso-motor system, by compression of the sympathetic ganglia near the diaphragm, by partial or complete occlusion of the thoracic duct, etc.

Dissecting aneurisms are rare as compared with the other two varieties. The dissection or lifting of the thin lining membrane of the artery from the media usually occurs in the long axis of the vessel. If the middle and outer coats do not become involved in the degeneration which has affected the inner coat, this form of aneurism may continue indefinitely, without leading to a fatal termination, although the danger of embolism can not be overlooked.

If the other layers give way, a sacculated aneurism is formed, with the adventitia for the sac, or rupture may occur, leading to fatal extravasation.

A *false*, or so-called "*diffuse*," aneurism results from the solution of continuity in all the coats of the vessel-wall, and the sudden diffusion of blood into the peri-arterial tissues. The extravasation continues until the resistance of the surrounding tissues is equal to the pressure of the column of blood within the vessel. As a result of the extravasation, an inflammatory process, of variable intensity, is established, which results in the formation of a limiting membrane, or aneurismal sac.

The *prognosis* in aneurism varies under widely differing conditions. In general it is a grave affection, the gravity depending, in a great degree, upon the location and character of the tumor and the physical condition of the individual affected. An aneurism of the cranial cavity will produce rapidly serious effects by compression of the brain. The gravity of a prognosis diminishes as the location of the tumor is removed from the cavities. Aneurism (especially the sacculated variety) of the aorta, innominate, subclavian, or iliac arteries, is an exceedingly dangerous affection, while the same condition in the distal arteries yields readily and safely to surgical interference in the great majority of cases. The prognosis may also, in part, depend upon the degree of discomfort experienced by the patient, from the effects of pressure upon contiguous organs. Neuralgia of the most painful and obstinate kind, resulting from pressure of the tumor upon a neighboring nerve, may hasten a fatal termination by loss of sleep and rest, and the general impairment of nutrition. Occlusion of the accompanying vein may occur, producing œdema and gangrene. Again, the gravity of the prognosis is increased when, by reason of its location, the sac of an aneurism is in contact with a bony surface, since rupture is not infrequently precipitated by attrition against the roughened bone.

The *symptoms* of aneurism are, in great part, *local*. They refer to the direct development and effect of the tumor. A sense of unusual throbbing pain, more or less severe, and swelling in the line of an artery (when the aneurism is outside of a cavity) which pulsates with the cardiac systole, which, when not resting upon a hard surface, is expansile in all directions, and which gives to the sense of touch a *tremor* not easily

described but readily appreciated, are symptoms which point in general to the diagnosis of aneurism. The stethoscope, applied to the tumor, conveys to the ear the peculiar sound ("bruit") caused by the passage of the blood-current from the narrow vessel into the expanded aneurismal sac and out again. If the tumor be situated upon one of the arteries of the extremities, compression upon the cardiac side will cause a cessation of the pulse-tremor and bruit, and diminution of the swelling, while pressure upon the distal side will temporarily exaggerate these symptoms.

When an aneurism is developed as a result of a wound of an artery, the immediate symptoms of hæmorrhage and swelling, with the pulsating character of the tumor, will clearly indicate its presence. The differentiation is chiefly between solid or cystic tumors, which develop along the line of the artery, and are lifted by the arterial pulsation. Abscesses, or serous cysts, are the most difficult to recognize. In the formation of an abscess there is a previous history of inflammation. An aneurismal tumor expands equally in all directions, while any other tumor travels with the arterial pulse in one direction only—that of least resistance. In cases of great difficulty of diagnosis it will be justifiable to aspirate the tumor with the finest hypodermic needle.

Left to nature, the progress of an aneurism is, with rare exceptions, to a fatal termination. The deposit of fibrillated fibrin within, and the inflammatory new-formed tissue without, may retard, but rarely arrests, the progress of the disease. Added to the danger of death from rupture of the sac, or compression of neighboring organs, is that of inflammation and sloughing of the tumor and its contents. The hope of recovery is in the gradual deposition of fibrin within the sac, causing its ultimate occlusion, or that of the vessel or vessels immediately connected with it. The danger of gangrene in the parts beyond the tumor is lessened with the gradual establishment of the collateral circulation, while the sac and its contents are less apt to inflame than when the occlusion is sudden and the clot recent.

The *treatment* of aneurism is *constitutional* and *local*. The constitutional treatment is directed toward the judicious support of the physical powers of the patient, the relief from pain, and the production of a condition of the blood favorable to a deposit of fibrillated fibrin in the tumor.

The local measures are directed to the mechanical control and arrest, either gradual or immediate, of the circulation in the aneurism, with the same end in view, namely, the formation of fibrin within the sac.

Constitutional measures alone offer little hope of a cure, and are applicable only to cases where the dangers of operative interference are sufficient to contra-indicate any surgical procedure. In this plan of treatment rest in bed is the first and essential requirement. In conjunction with this there may be administered certain remedies which diminish the rapidity of the circulation, or affect the blood-vessels or blood in such a manner that the gradual deposit of fibrin in the sac is produced. *Val-salva's* method of rest in bed, venesection, and gradual starvation, in

order to slacken the blood-current and thus cause coagulation in the aneurism, is now almost entirely abandoned. Though heroic, this plan of treatment is not without good results, as will be shown in the report of cases of special aneurism on a future page.*

Tufnell modified *Valsalva's* method by omitting blood-letting and substituting a restricted diet, with the minimum of fluids. Rest in the recumbent position must be rigidly enforced. Among the remedies which have been recommended for internal administration, iodide of potassium, fluid extract of ergot, alone or with infusion of digitalis, and tincture of the chloride of iron, are worthy of consideration.

Among the many surgical procedures instituted for the relief of aneurism, those two which deserve the first consideration are *compression* and the *ligature*. In the results achieved in their various methods of application all other treatment may be practically excluded.

Compression may be employed on the cardiac side of an aneurism, close to the tumor, without an intervening collateral branch, or at a dis-

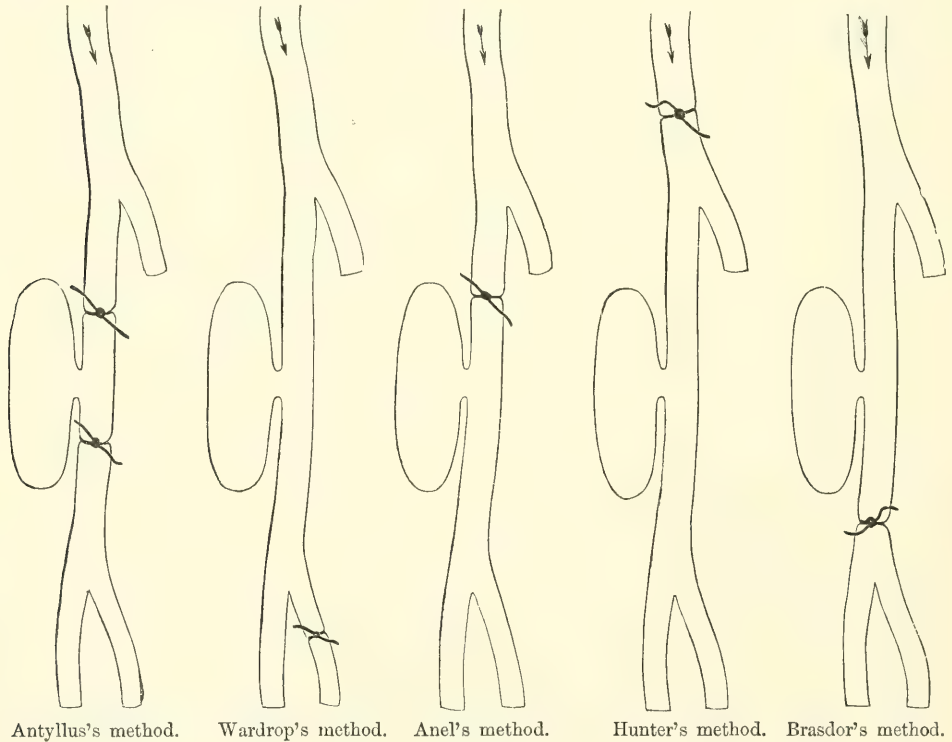


FIG. 272.

tance from the sac, with one or more intervening branches. It may be employed on the distal side, with or without intervening anastomosis, or directly to the surface and back of the tumor, or, again, on both peripheral and central sides, with or without direct compression of the aneurism.

The *ligature* may be applied on the *cardiac side* of the tumor, there

* See "Subclavian Aneurism," fourteen cases by *Valsalva's* method.

being one or more branches given off between the ligature and the sac (Hunter's method), or without an intervening branch (Anel), or on the *distal side* without (Brasdor), or with (Wardrop) an intervening branch, or close to the tumor on both the distal and cardiac side, with or without extirpation of the tumor (Antyllus) (Fig. 272).

When interrupted pressure upon the main trunk, on the cardiac side of an aneurism, is possible, it is the first method of treatment to be adopted. It can only be contra-indicated when the tumor is so near to the great cavities from which the arteries emerge that there is not sufficient room for its accomplishment, or when, on account of the anatomical arrangement of contiguous nerves and veins, compression is painful or inexpedient, or when, as will occur only in exceptional instances, rupture is imminent; then the ligature is demanded.

Compression may be *manual* or *instrumental*, and *continuous* or *interrupted*.

Given a popliteal aneurism, as an illustration, compression on the cardiac side, with an intervening branch, may be employed as follows:

Digital or Manual.—The patient, being placed in a position comfortable to himself and convenient to the operator, is, if the necessity demands, put under the influence of an opiate or anæsthetic. Compression is then made with the pulp of the thumb laid upon the femoral artery, just where it crosses the rim of the pelvis, until pulsation in the tumor is diminished or arrested. Additional force is gained by pressing the thumb or fingers of the opposite hand on the dorsum of the thumb first

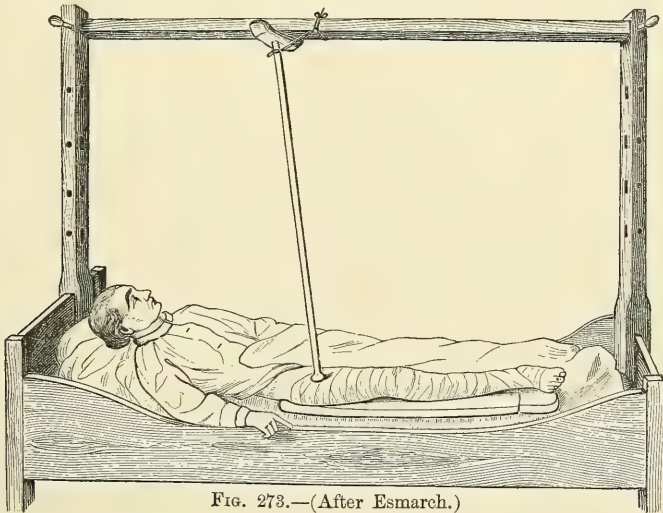


FIG. 273.—(After Esmarch.)

employed. When from fatigue further compression is impossible, the operator is relieved by the next of the detail, and so on. After a lapse of from two or three hours to at times as much as three days, the tumor ceases to pulsate, becomes firm and inelastic, and remains permanently occluded.

Mechanical.—A method less tiresome to the operator, no more annoying to the patient, and almost, if not equally, as effective, is as follows: One or two sticks of hard wood about an inch in diameter, and from four to six feet in length (small-sized hoop-poles or a crutch will suffice), are covered at one end with an India-rubber tip, or compress of some soft substance. The other end is tied to the ceiling with a string or to a bar over the bed, and allowed to descend until the tipped extremity rests with the required weight upon the vessel to be compressed (Fig. 273). It may be convenient to employ two poles, so that one may press a few inches lower down than the other. If one is employed, the assistant or patient can be directed to change the point of pressure at intervals, in

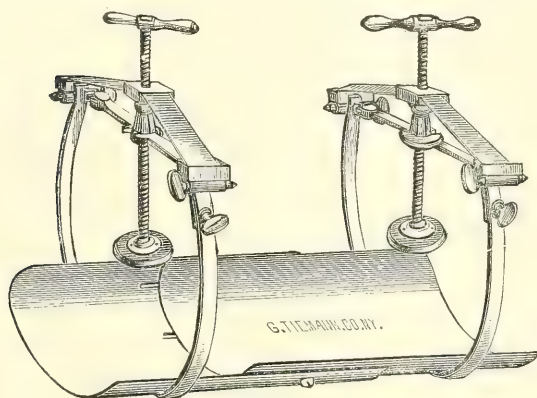


FIG. 274.

order to prevent pain or excoriation. For this same purpose the late Prof. Alpheus B. Crosby successfully employed an elastic tube partially filled with shot to give it the requisite weight. The tube was suspended above the bed and the pressure regulated by the quantity of shot.

Various tourniquets, with one, two, or three compression-pads, have been used with the same object in view,

and with varying success. Among the better of these instruments is Dr. Briddon's compressor (Fig. 274). Compression with the mechanism just described may also be employed on the *distal* side of the aneurism, although with less hope of success than in pressure on the cardiac side, which is among the most successful of the conservative methods at the surgeon's command.

Direct pressure upon the aneurismal tumor has been employed in a few instances with a fair degree of success. Six cases of subclavian aneurism treated in this manner will be given hereafter, with description of the mechanism.

Pressure on both the distal and cardiac sides, with or without direct pressure on the tumor, has been practiced by the employment of Es-march's bandage. The patient being anæsthetized, the bandage is applied, beginning at the extremity, and emptying the vessels by using sufficient force in its application, until the lower border of the tumor is reached. In passing over the aneurism, about one half the pressure is employed, it being intended to leave a certain quantity of blood within the sac. As soon as the upper boundary is reached, the same degree of pressure is applied as below, and the bandage is left on, or the tubing may be tightened around the limb above, and the bandage removed. Cures have been effected within an hour by this practice, while the compression has been exercised for several hours with negative, and in some

instances with fatal results. The method is inferior to digital or mechanical compression on the cardiac side of the tumor, and is decidedly more dangerous.

Esmarch reports two cases of femoral aneurism in which the bandage failed, while the pole or stick compressors were subsequently successful in each instance.

In the application of the ligature the method of Hunter is generally preferable. The advantages of this method over that of Anel may be enumerated as follows: The ligature is applied at a distance from the aneurism where the artery is more apt to be in a healthy condition, thus diminishing the danger of secondary hæmorrhage. The existence of one or more collateral branches between the ligature and the tumor renders the process of coagulation in the sac less rapid, and consequently less liable to inflammation and sloughing. The only objection to this method of operating is the possibility of failure due to too free anastomosis, whereby the necessary diminution of the circulation is prevented.

The method of Anel is at this date rarely performed, except in those instances where, on account of the location of the tumor, other methods are impossible.

Deligation upon both sides of, and close to, the tumor (method of Antyllus) is not a recognized practice except in peculiar cases, where other and less radical methods have failed. It is especially adapted to cases of aneurismal tumors which have numerous anastomoses connecting directly with the cavity of the sac, as is not infrequent in popliteal aneurism. That part of the operation of Antyllus which consisted in incision of the tumor and packing the sac is seldom considered necessary, the double ligature being sufficient.

The operations of deligation upon the distal side of an aneurism, so close to the tumor that no collateral branch intervenes (Brasdor), or at a point more remote with one or more collateral branches intervening (Wardrop), are procedures which have been frequently employed, especially within the last few years. Preference is given to Wardrop's operation over that of Brasdor, for the same reasons advanced in favor of Hunter's operation, as compared to that of Anel on the cardiac side, to which it may be likened. There is no evidence that Brasdor ever did more than suggest the distal operation. Deschamp was the first to perform it (Oct. 6, 1798), but without success. Wardrop modified the operation and established it by successful practice in 1825.* The general results of this procedure have been such as to encourage its repetition, although the manner in which a *partial* arrest of the circulation through an aneurism by deligation on the distal side of the tumor induces coagulation in the sac is difficult of explanation.

As has been said in the chapter on "Surgical Dressings," none but *animal ligatures* should be applied to arteries. Antiseptic catgut of the largest size for the larger vessels will be found most convenient.

* See article by the author, "American Journal of the Medical Sciences," January, 1881, p. 155; and "Prize Essay of the American Medical Association," 1878, p. 94.

Barwell's* ox-aorta ligatures are safe and efficient, as are those made from nerves and first used upon the living subject by myself. I have used the broad ox-aorta (Mr. Barwell's) ligature successfully in tying the common carotid and the subclavian arteries, and have twice deligated the common carotid with success, employing the sciatic nerve of a calf; † but the readiness with which catgut is obtained, and the ease and comparative safety of its application, especially with the aid of antiseptic precautions, have led me to give to it the preference.

Other methods of treatment of aneurisms which have almost, if not entirely, fallen into disuse are *galvano-puncture*, *massage or kneading*, *flexion*, the *introduction of horse-hair or wire into the sac*, *acupuncture*, and the *injection of a coagulating substance into the sac or the tissues around it*. In my opinion, the circumstances which would justify any of these methods are so rare—if, indeed, they ever exist—that they scarcely deserve recognition in practical surgery. An exception may be made in the use of wire or horse-hair in cases of large abdominal or thoracic aneurisms where death is imminent and the ligature impossible.

In *galvano-puncture* one or more needles, connected with both poles of a galvanic battery, are introduced into the cavity of the sac on opposite side or points of the tumor. They do not touch within the aneurism, the circuit being completed by the blood. A twenty-four-cell battery may be used, beginning with a few cells and gradually increasing the strength of the current until the usual pain is felt at the negative pole, or until signs of coagulation are evident. The objections to this method are that the clot is of rapid formation, may not be permanent, and may inflame and suppurate, causing death from hæmorrhage or septicæmia.

Massage or kneading has been successfully performed in a few instances. The aneurism is manipulated with the intention of detaching from the sac enough of the fibrillated clot to plug up the efferent vessel and thereby practically tie the artery on the distal side (Brasdor). It is a safer and surer method than galvano-puncture, though of doubtful propriety except in small aneurisms situated in the arms or legs. The danger of embolism in the cerebral circulation is too great to justify this or any similar procedure upon an aneurism connected with a vessel leading toward the brain.

Flexion or posture is practically a method of *direct compression*, using the normal tissues for a pad. It is employed in popliteal aneurism, where the knee is flexed and fastened so as to compress and partially occlude the tumor between the tibia and fibula, and the femur. It is a justifiable method in rare instances. The same practice may be instituted at the elbow, but is impracticable at the axilla on account of the arrangement of the nerves.

The introduction of *watch-spring wire*, *horse-hair*, *catgut-coil*, or any other foreign solid substance into the cavity of an aneurism will, as

* See article by the author in "Archives of Medicine," June, 1882. G. P. Putnam's Sons, New York.

† Ibid.

above given, rarely be justifiable except as a last resort in cases where the ligature or compression is impossible. For its execution a pointed canula is usually employed, which, having been introduced into the sac, the wire or gut is pushed through. The quantity used varies from two or three feet up to several yards. More of the catgut may be introduced than of the metal, and the animal ligature should always be preferred if this procedure is adopted.

Acupuncture is the operation of introducing needles into the cavity of the sac, and allowing them to remain for several hours until coagulation ensues. It is not a scientific procedure, and the same must be said of the *injection of ergot*, the *iron solutions*, or any coagulating substance into the cavity of the tissues around an aneurism.

SPECIAL ANEURISMS.

Aneurism of the Thoracic Aorta.—The ascending and transverse portions of the arch are most frequently affected. If the dilatation is *fusiform*, both of these segments are apt to be involved; if it is a *sacculated* aneurism, it is usually confined to one or the other segment. Sacculated aneurism of the ascending arch high up, or of the transverse arch, usually involves the orifice of one or more of the great vessels which originate here, although, as in the specimen figured below (see Fig. 275), not infrequently the mouth of the sac opens close to these vessels, but does not involve them.

The diagnosis of aneurism of the arch is generally obscure until the dilatation has advanced to such an extent that pressure-symptoms are evident. Pain of varying intensity may be present in the earlier stages of development of both fusiform and sacculated aneurism. A symptom of great diagnostic value is disturbance of the laryngeal muscles, due to pressure upon the recurrent laryngeal nerve of the left side. This occurs in dilatation of the transverse or descending segment of the arch. The aneurismal bruit may be recognized as soon as the sacculation is well advanced. Interference with respiration, or deglutition, or the return circulation in the veins, is among other and important pressure-symptoms.

The appearance of a tumor with an expansile pulsation synchronous with the cardiac systole, in the upper thoracic region, determines the diagnosis of aneurism. The differentiation of dilatation of the arch, from a similar condition of the innominate, left carotid, or left subclavian in the thorax, is difficult, and at times impossible. A number of errors in diagnosis by competent and honest observers are on record.

The following points will aid in arriving at a diagnosis: The tumor in aneurism of the ascending arch is usually first appreciated to the right of the sternum, between the clavicle and the third rib. The pressure-symptoms do not affect the voice until the tumor is recognizable in the right side of the root of the neck, where it involves the right recurrent laryngeal nerve. Respiration may be interfered with, or cough produced by

compression of the right bronchus. This condition will be recognized by the hissing râles distributed over the area of the right lung. Aneurism of the transverse arch is usually first recognized to the left of the sternum on about the same plane as for the ascending segment. Laryngoscopical examination will demonstrate that whatever of muscular paresis exists is confined to the left vocal bands. If the tumor rises into the neck, its appearance will have been preceded by pressure-symptoms of longer duration and greater severity than in either innominate, carotid, or subclavian aneurism.

Innominate aneurism usually appears at the upper margin of the sternum in the space between the two tendons of origin of the right sterno-mastoid muscle, or in the interclavicular notch. The disturbance of the circulation through this vessel so affected may be recognized by the difference in the force and character of the pulse-wave in the radial arteries of the two arms. In *aortic* aneurism, when the innominate is not compressed by the tumor, the pulse-wave will be the same in both arms. It must, however, be borne in mind that in sacculated aneurisms, springing, as they not infrequently do, from the arch in immediate proximity to the orifice of the innominate, and rising to the root of the neck, in front of or behind this artery, a positive diagnosis is scarcely possible. The pressure on the innominate may retard or weaken the right radial pulse, when this vessel is not involved, while the aneurismal bruit is present in the exact location of this vessel.

Aneurism of the left carotid artery will first appear at the left sternoclavicular articulation in the line of this vessel. The murmur will be transmitted toward the distribution of this vessel, and will not be heard in its fellow opposite.

When the left subclavian is involved, the swelling will usually appear to the left of the sterno-mastoid muscle, and the pulse in the left radial will differ from that of the right. When the descending aorta is the seat of aneurism, the diagnosis is still more obscure. The peculiar murmur is most easily recognized by placing the stethoscope to the left of the vertebral column in the interscapular space. The chief pressure-symptoms are those which affect deglutition and lift the heart forward.

The *clinical history* of aneurism of the thoracic aorta usually ends in the death of the individual. In addition to the symptoms given in the method of diagnosis, the gradual expansion of the tumor leads to more painful and graver conditions. Anxiety, loss of sleep, pain, and cough usually prostrate the patient; erosions of the ribs, sternum, clavicles, and vertebræ occur, and sloughing, septic absorption, or hæmorrhage may produce a fatal termination.

The *medical treatment* is rest in bed, and the safe and judicious combination of Valsalva's and Tufnell's methods as given. The *surgical* treatment is of the most heroic order, and should not be instituted until a reasonable trial of the other methods has proved them as inefficient, as death is inevitable. This treatment is the deligation of one or more of the great vessels which are derived directly or indirectly from the arch—i. e., *the distal operation*.

That this operation is justifiable, under certain conditions, has been demonstrated. Among a number of cases in the statistics of this procedure, the following are from personal experience :

On the 21st of September, 1880, I tied the right carotid and subclavian arteries simultaneously for the relief of an aneurism of the ascending portion of the aorta.* The history of the aneurism dated back sixteen months. Having developed rapidly, it projected through the right second intercostal space, causing such pain that the operation was undertaken.

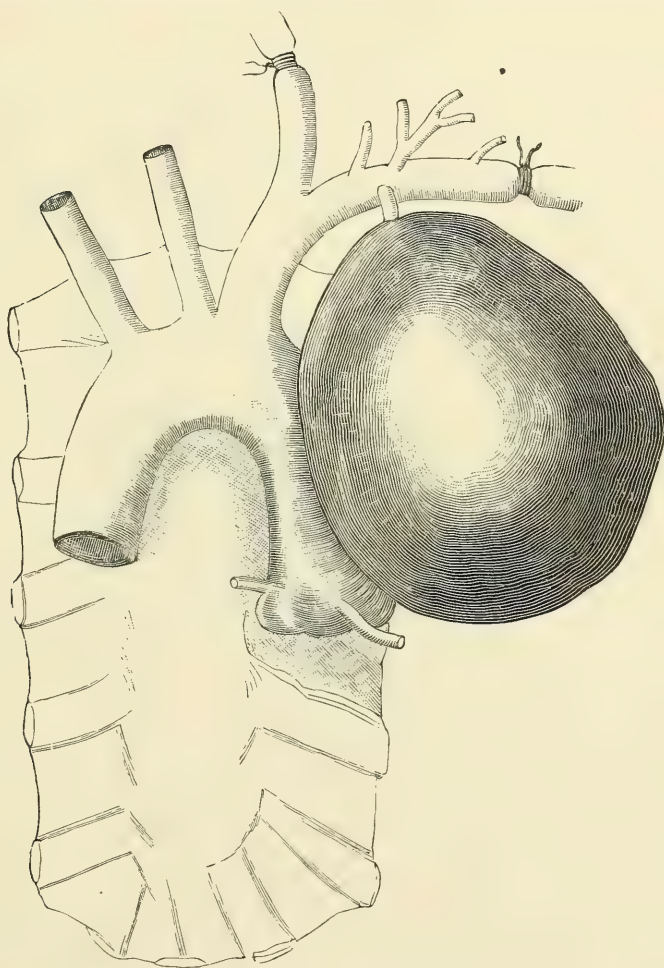


FIG. 275.—The author's case of aneurism of the ascending aorta.

This was the second operation which had knowingly been undertaken for the relief of aneurism of the ascending aorta. The ligatures used were of ox-aorta, and were as large as the median nerve in an adult. Despite the prostrated condition of the patient, she recovered, the tumor diminished perceptibly in size, became more solid, and her general condition was much improved. One month after the operation she was dis-

* For a full report of this, and all the other cases up to that date, see paper by the author in "American Journal of the Medical Sciences," January, 1881.

charged from the hospital, traveled to a neighboring State, where she died, one year later, from acute diarrhœa. I secured an autopsy, which revealed an aneurism (Figs. 275, 276) as large as an orange springing from the ascending aorta, at its junction with the transverse segment. The orifice of the tumor was an oval, about half an inch by one inch in extent. The tumor was solidified with permanent clot on its lateral and posterior aspects. On the upper anterior surface, which had worn away the sternum and second rib, the sac was thin, with a recent clot which

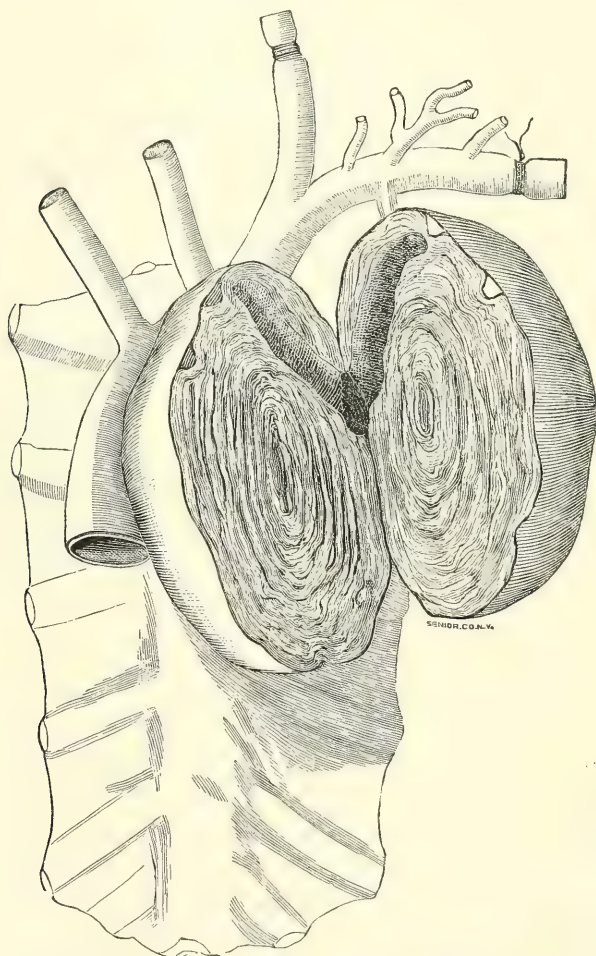


FIG. 276.—Section through the long diameter of the tumor.

filled a cavity not quite an inch in diameter. The tumor was practically solidified, and had this patient not returned to her dissipated practices (alcoholism), I do not doubt that her recovery would have been complete.

Prof. H. B. Sands performed the same operation, in 1866, for a supposed innominate aneurism.* The tumor diminished after the operation, and visible pulsation ceased. The patient died, thirteen months later, from the pressure of the tumor which sprang from the junction of

* See "American Journal of the Medical Sciences," January, 1881.

the ascending and transverse segments, just in front of the innominate. C. F. Maunder's patient died, on the fifth day, from occlusion of the aorta by a clot which projected from the aneurismal sac. The tumor sprang from transverse segment, a little to the left of the innominate.* Heath's patient lived four years after the double distal ligature. The aneurism diminished in size, and the general condition was much improved. The sac ultimately burst, with a fatal result. The tumor originated from the ascending aorta.† Mr. Richard Barwell and Mr. Lediard have also performed this operation for aneurism of the arch. Mr. Barwell's patient died fifteen months after the operation, dying from dissipation and "general wearing out." The aneurism was completely filled with laminated clot. Mr. Lediard's patient survived ten months.‡

Hobart tied the right subclavian in its first division, and the right common carotid, for a supposed innominate aneurism. Fatal hæmorrhage occurred from the seat of ligature on the carotid on the sixteenth day. The autopsy showed a pyriform aneurism originating from the aorta, just to the left of the innominate. The sac was filled with a firm coagulum.*

Thus, of seven cases of simultaneous deligation of the right carotid and right subclavian arteries, two died on the fifth and sixteenth days, respectively, from the effect of the operation. The remaining five recovered, with evident improvement. A point of great interest is to notice the *effects of the operation upon the tumor*.

In my case there was no immediate change in the aneurism. Within twenty-two hours the diminution was evident, and by the fourth day it had shrunk from an elevation of one inch and a half above, down almost to the level of the skin upon the thorax. In Sands's case "the tumor diminished after the operation, and visible pulsation ceased." There was no diminution in Maunder's case, but after death the sac was almost completely filled with recent clot, which had even occluded the aorta. In Heath's case "the tumor gradually diminished in size." The symptoms so far disappeared in Barwell's patient that that surgeon informed me, "The aneurism is, judging from symptoms, cured." In Lediard's case the "laryngeal symptoms disappeared; the tumor had a more consolidated feeling." The sac in Hobart's case "was filled with firm coagulum."

The evidence in these cases—which are all I have been able to collect—in which the right subclavian and right carotid arteries were simultaneously tied for aneurism of the arch of the aorta, involving the last portion of the ascending segment, or the first portion of the transverse segment, or both, points to the conclusion that, in *sacculated aneurism affecting the arterial limit just given, the double distal ligature tends to produce consolidation of the tumor, and to relieve the symptoms of distress caused by its presence.* ||

* See "American Journal of the Medical Sciences," January, 1881.

† Ibid.

‡ Author's article on Distal Ligature for Aneurisms near the Heart, "American Journal of the Medical Sciences," January, 1881.

Ibid.

|| See author's case of deligation of the left subclavian and left common carotid arteries for aneurism of the transverse portion of the arch, page 233.

In the study of cases in which one or the other primitive carotid has been tied for uncomplicated aortic aneurism I am enabled to collect but nine instances. In the limits of a text-book it will be impossible to give a detail of such cases, however interesting to the student. I refer him to my article on this subject in the "American Journal of the Medical Sciences," January, 1881. The operators were Montgomery, T. Holmes, Barwell, Tillanus, Rigen, O'Shaugnessy, Annandale, Heath, and Bryant. The *left carotid* was tied in six cases, and all recovered. Montgomery's patient died, four months after operation, from purulent pericarditis. The tumor had solidified and sloughed. Holmes's case was much improved, and, in answer to my inquiry concerning this case, in 1880, five years after the operation, he writes that the patient is still living, that there is pulsation and bruit in the thoracic portion of the aneurism, but there is no longer any tumor perceptible in the neck.

Barwell's case was greatly relieved, dying four months later of another affection. Tillanus's operation was followed by recovery and diminution of the tumor, dying suddenly five months later (probably from cerebral embolism). The sac was completely filled with coagulum. Rigen tied the carotid, February 21, 1829. The patient was relieved, and the tumor diminished considerably in volume. On May 9th was operated on for strangulated hernia, and died June 13th, as was supposed, from asthma. The tumor was solidified. In Heath's case the relief for a long period was marked and undoubted. The patient lived nearly four years, dying ultimately of rupture of the sac.

O'Shaugnessy tied the right carotid, with fatal rupture of the aneurism into the mediastinum on the tenth day. Annandale performed the same operation with immediate relief and success. Mr. Bryant's patient died on the tenth day. The right carotid was tied, with no effect on the aneurism. The results in these instances also lead me to conclude that, in sacculated aneurisms of the aorta, near the origin of the innominate and left carotid, deligation of one carotid, especially the left, is a justifiable procedure when the conservative method of rest and restricted diet has failed.

Aneurism of the thoracic aorta beyond the transverse segment is not amenable to surgical treatment.

Aneurism of the Innominate Artery.—The symptoms of this formidable lesion have been given on a preceding page. It is frequently complicated with aneurismal dilatation of the aorta, or of the two vessels into which it usually bifurcates. It will be interesting to study the results of operative procedures under the following subdivisions :

1. *Innominate Aneurism.* 2. *Aortic innominate Aneurism.*—For innominate aneurism, (a) the double simultaneous distal ligature (carotid and third division of the subclavian); (b) the double non-simultaneous distal operation; (c) distal deligation of the carotid artery alone; (d) distal deligation of the subclavian artery alone.

Simultaneous Deligation of the Right Common Carotid and the Right Subclavian Artery (Third Division) for the Relief of Innominate

*Aneurism.**—Prof. J. L. Little performed this operation in 1877. The patient recovered, was much improved, and died from pleuritis, not associated with the aneurism, three years later. The carotid and subclavian were slightly involved. Durham's patient died on the sixth day, as was reported, from "shock." The possibility of cerebral embolism is worthy of consideration in explaining the sudden death of this patient. M'Carthy's case died, on the fifteenth day, from hæmorrhage on the proximal side of the subclavian ligature. Prof. Eliot's patient died, on the twenty-sixth day, from hæmorrhage from the sac. Prof. L. A. Stimson's patient recovered, with marked improvement and consolidation of the aneurism. The tumor became very much smaller, and the symptoms were relieved. Death occurred, twenty-one months after the operation, from phthisis. The sac was filled with firm clot. In the case operated upon by Prof. R. F. Weir, death resulted, from rupture of the sac, on the fifteenth day. Rossi's patient died on the sixth day, most probably from cerebral anæmia, since, at the necropsy, the left vertebral was the only pervious artery leading to the brain. Ensor's case ended in death, from rupture of the sac, on the sixty-fifth day. Barwell operated, with recovery and marked improvement. King's patient died, from hæmorrhage from the aneurism near the carotid ligature, on the one hundred and eleventh day. Gerster's case recovered, with gradual improvement.†

Of these eleven cases, recovery, with a cure more or less perfect, took place in four, while death occurred in seven. It is very probable that, if in some of these fatal cases the operation had been performed earlier, the rate of mortality would have been lower.

The double distal operation, with varying intervals between the deligation of the carotid and the subclavian arteries, has been performed in the following instances: Prof. A. B. Mott tied the subclavian artery in a patient who had had the right carotid deligated one year previously. The patient died, three years after the last operation, from phthisis. The aneurism was cured. In Heath's case the carotid was first tied, with temporary amelioration of symptoms. Two years later the subclavian was operated upon. The aneurismal bruit disappeared, and the urgent symptoms disappeared. Four months later the patient died from traumatic pleuritis, caused by a fall while drunk. The tumor was consolidated. In Wickham's case the interval was two months and nine days. Immediate and temporary relief followed both operations. Death ensued from rupture of the sac on the forty-fourth day. Malgaigne's patient was not materially benefited by the first operation. Three months later the subclavian was tied, followed by death, from rupture of the sac, on the twenty-first day.

A glance at these cases, and a careful study of their more complete histories, can not but impress one with the gravity of the surgical procedure under consideration. The postural, dietetic, and medicinal method should be thoroughly tried in all cases where the disease has not

* For more complete details, see preceding reference.

† "German Hospital Records," 1883-'84, New York city.

progressed so far that death is imminent from pressure, or the suffering so intense that life becomes intolerable. Under these last conditions the operation is justifiable. If the conservative method, after a courageous and faithful trial, does not arrest the disease, then again the operation is demanded. There is little choice between the simultaneous deligation and the operation with an interval. The carotid should always be first tied, to prevent the danger of cerebral embolism.

Innominate Aneurism treated by Deligation of the Carotid, or the Subclavian. (The Single Distal Operation.)—The records of surgical literature contain fourteen instances in which, for the relief of aneurism involving the innominate artery alone, the distal ligature was applied to the right carotid.

In Hutton's case death occurred, on the seventh day, from rupture of the sac; Neumeister's on the fifth day, from cerebral complications. One of Valentine Mott's patients died, from hæmorrhage from the carotid, on the twentieth day. In Porta's case, which ended fatally in forty hours, the sac was found to have involved the origins of the right carotid and subclavian arteries. A similar condition was observed in the case operated upon by Vilardebo, which terminated fatally on the twenty-first day. Fergusson's patient died on the seventh day. The autopsy showed that the origin of the subclavian was also involved. The case by Butcher ended in death on the fourth day. The innominate was the seat of a fusiform dilatation, while the sacculated aneurism was found to exist in the third portion of the subclavian artery. Holmes reports a case by Ordile, of Naples, which also proved fatal.

A case by Scott was temporarily benefited, but did not long survive, dying from rupture of the sac. Nussbaum's patient was not benefited, and died from the progress of the disease. The case of Morrison, in which the aneurism involved the origin of the carotid, recovered, with improvement, but died suddenly one year and eight months later, after prolonged exertion. A second case by V. Mott recovered, with marked temporary improvement, but death ensued from pressure of the *consolidated tumor* on the trachea. Pirogoff's patient recovered, improved. The history of this case ceases after two months and a half.

In one single instance (Evans's) a cure was effected, and this after suppuration occurred in the sac, which discharged twenty-four ounces of pus.

Of the fourteen cases, eight ended fatally. Seven of these died between the second and twenty-first day, and in one of these it is evident that death was caused by the consolidation of the aneurism.

Another surgical procedure for the relief of innominate aneurism, which has received the sanction of eminent practitioners, is that of single deligation of the subclavian artery in its third division. The operators are Wardrop, Broca, and Thomas Bryant. Each case recovered, with marked improvement. Wardrop's patient lived two years, and died partly from the effect of pressure of the aneurism and partly from general systemic failure. The tumor was firmly solidified, with the exception of a small central channel which led into the carotid. Broca's case died,

from pulmonary gangrene, five months later. Consolidation was also almost complete in this case. Bryant's patient was living one year after the operation, and there was evidence of solidification in the tumor.

While it is scarcely possible to base a definite opinion upon a study of such a limited number of cases, the evidence seems to be in favor of the operation of tying the subclavian in preference to the carotid for innominate aneurism. It would be natural to infer that the danger from cerebral embolism would be great after such a procedure, yet it evidently did not occur in either of these instances.

Deligation of the right carotid alone is demonstrated to be so dangerous an operation that I should hesitate to perform it until all other expedients had failed.

In aneurism involving both the innominate and the aortic arch, the double distal operation is recorded in eight instances. In the following cases the two vessels were tied at the same operation, excepting one in which there was an interval of only twenty-four hours. Mr. Barwell, in one instance, with a recovery and very great improvement. The patient died, nineteen months later, from bronchitis. The tumor was firmly consolidated. The same surgeon, in a second case (with an interval of twenty-four hours), with recovery and great improvement. Death from broncho-pneumonia three months later. The tumor, as large as a tennis-ball, was solid, excepting a central globular cavity one inch in diameter. The same surgeon, in a third case, which ended fatally, from asphyxia, in thirty hours. Mr. Holmes's patient died from exhaustion two months after operation. The sac was full of recent clot. Mr. Lane's case terminated fatally within three months, from rupture of the sac. The patient operated upon by Mr. Hodges died, with symptoms of broncho-pneumonia, on the twelfth day. There was no sacculated aneurism, but an extensive fusiform dilatation of the innominate and aorta. Ransohoff's case ended fatally, from asphyxia, in seven days. In one instance Mr. Bickersteth operated, with an interval of forty-nine days, but without benefit, as the patient died from the progress of the disease in three months.

The results in these cases do not encourage a repetition of this operation in well-marked instances of aorto-innominate aneurism. The conservative methods offer the best hope of palliation.

The deligation of one of the primitive carotids has been performed in six instances for the relief of aneurism involving the innominate, complicated with dilatation of the aorta or the first portion of the right subclavian or carotid. Pirogoff tied the left carotid in two cases. One died within a week, from hemiplegia and coma; the sac was completely filled with clot. The other recovered, and was improved up to two months, when the history ceases. In the remaining four cases the right carotid was tied. The operation by Hewson terminated fatally on the tenth day, from asphyxia, due to pressure from the consolidated tumor. The two terminal branches of the innominate were also involved. Campbell's patient suffered a like fate, from the same cause, while Key's was also fatal in four hours, from coma. Hutchison's died on the forty-first

day, from asphyxia, due to pressure of the enlarged and consolidated aneurism.

Thus, in six cases, five died within a few days after the operation, and three of these seem to have ended fatally from consolidation of the aneurism, the very object for which it was performed.

Aneurism of the Common Carotid Artery.—Aneurism of the carotid may occur in any part of the course of this vessel, being in rare instances intra-thoracic (when the left trunk is involved).

The diagnosis of aneurism of the left carotid, low down, depends upon the presence of the aneurismal bruit at the spot of the tumor, this murmur being carried along in the distribution of the artery. Pressure-symptoms are referable to laryngeal interference from compression upon the pneumogastric; or distention of the left internal jugular, and in rare instances the left subclavian vein. The presence of the swelling is usually first recognized in the space between the two tendons of origin of the left sterno-mastoid muscle. Aneurism of the right carotid, within the first inch of its course, gives rise to the ordinary symptoms of this lesion, just beneath the sterno-mastoid muscle, at and immediately above its clavicular origin.

Aneurism of the vertebral artery, in its lower portion, may be differentiated from that of the carotid by compression of this latter vessel high up. If the thumb be placed over the carotid, at its bifurcation, and pressed firmly and directly backward against the vertebral column, such compression will not affect the circulation in the sac of a vertebral aneurism, while if involving the carotid it would be visibly affected. Then, again, vertebral aneurism is, in nearly every instance, of traumatic origin, and the traumatism is usually a stab wound, while aneurism of the carotid is almost always idiopathic.

In the differential diagnosis of these two lesions higher in the neck, the same method is applicable. It should not be forgotten, in the effort to form a diagnosis, that careless manipulation of a cervical aneurism is not allowable, on account of the danger of detaching a clot, which may pass up into the brain. If the tumor involve the carotid or its branches, compression of the primitive trunk, low down, will arrest the pulsation in the sac. This is best accomplished by relaxing the sterno-mastoid muscle of that side, and grasping the vessel between the thumb and finger carried behind the muscle. On account of the deep seat of the vertebral artery its compression by this manœuvre is impossible. This last vessel may be compressed by placing the thumb one inch directly below the transverse process of the sixth cervical vertebra, and pressing backward. Above this point it is impossible, since the vessel runs into the vertebral foramina.

The treatment of carotid aneurism is surgical and palliative. The last method refers to the postural, dietetic, and medicinal treatment of aneurisms in general. The only surgical procedure which should be recommended is the ligature. While it is true that some cases are recorded as cured by digital compression, I can not but consider this method as dangerous, for the reason that, in the process of consolidation where the cir-

ulation is only temporarily interrupted, cerebral embolism may occur. The animal ligature, with antiseptic cleanliness, offers the safest means at our disposal. The operation varies with the seat of the tumor. It may be divided into deligation upon the *distal* and *cardiac* side of the aneurism.

The distal ligature has been applied in seven recorded instances—five on the right and two on the left carotid. Two deaths occurred from hæmorrhage; one from the distal side of the (silk) ligature on the sixty-first day, the second case from rupture of the aneurism on the sixty-seventh day. A third case recovered, but the progress of the disease was not arrested, and death followed the rupture of the sac on the ninety-first day. The remaining four cases were either much improved or cured. The use of the catgut ligature would probably have saved the patient operated upon by Lambert, in which silk was used, causing death from hæmorrhage on the sixty-first day.

Deligation upon the cardiac side is always preferable when a sufficient extent of sound artery can be secured around which to apply the ligature. In my "Essays on the Surgery and Anatomy of the Great Vessels of the Neck" I have recorded 106 cases in which the artery was tied on the cardiac side of the aneurism; 69 recovered; rate of mortality, 35 per cent. For aneurism of the external carotid or its branches, 17 recoveries and 5 deaths. Of the 17 recoveries 16 were cured. For aneurism involving the common carotid alone, the death-rate was 44 per cent. When the aneurism involves the common, external, and internal carotids, the ligature should be applied to the common trunk, on the cardiac side, while the distal ligature may be applied to the external trunk, at the same time securing the larger branches derived from this vessel between the ligature and the bifurcation. By this operation the circulation through the tumor, and in the direction of the brain, is practically arrested.

Aneurism of the external carotid demands the deligation of this vessel and no other, when by a careful dissection it is discovered that there is a half or three quarters of an inch of this trunk between the bifurcation and the sac. In two instances I have placed the ligature around the external carotid exactly at the crotch of bifurcation, tying also the superior thyroid branch. Both cases recovered without accident. In the event that this method is impracticable, the common trunk must be tied.

Aneurism of the internal carotid, in the neck, should be treated by the deligation of this vessel, between the sac and the common trunk, if possible. When a sufficient surface of healthy artery can not be obtained, the common and external carotids should be tied, together with all branches derived from the external, on the cardiac side of the ligature. I performed this operation in one instance, resulting in the rapid and permanent cure of a large extra-cranial aneurism of the internal carotid. The common trunk was first tied with a nerve ligature, after which catgut was applied to the superior thyroid, and external carotid, just above its origin.

Aneurism of the internal carotid may occur in the cavernous or cerebral portions of this vessel. In the petrous canal dilatation is practically impossible. Not infrequently an arterio-cavernous aneurism occurs

the giving way of the septum between these two vessels. The cause may be traumatic, as in fracture at the base of the skull, or the communication may be established without appreciable cause.

The symptoms of aneurismal dilatation here are of two kinds: those referable to pressure upon the brain and nerves, and those due to interference with the return venous current through the ophthalmic vein. If the arterio-venous communication has occurred, exophthalmus is marked, and the eyeball is projected forward with each arterial pulse. Singing in the ears, dizziness, with varying loss of function due to pressure, are other symptoms of this condition.

The ophthalmic artery may be the seat of aneurism, within the cranial cavity or in the orbit. True sacculated intra-orbital aneurism of this artery is extremely rare, only two cases being recorded,* although pulsating tumors, as arterio-venous aneurisms, angiomas, cirroid arterial tumors, etc., are not infrequent in this locality. The chief point in the diagnosis, and the one which has an important bearing in treatment, is compression of the carotid. If pulsation ceases, and the other symptoms disappear, the indication is direct that the ligature should be applied to this vessel. The common trunk should be tied, in order to cut off the free communication between the branches of the external carotid and the ophthalmic in the orbit. In my *Essays* are given fifty-two instances in which this operation was done for pulsating non-malignant tumors of the orbit, with a death-rate of $11\frac{1}{2}$ per cent.† About 75 per cent of recoveries after this operation result in cures. In severe cases extirpation may be necessitated.

Aneurism of any branch or branches of the external carotid should be treated by compression on the cardiac side, when this is practicable, or by the ligature of the trunk involved, or the external trunk.

Aneurism of the Subclavian Arteries.—The subclavian arteries may be affected in any portion of their extent, although, on account of the pressure exercised by the two scaleni muscles, between which their second portion lies, this division is less frequently involved in aneurismal dilatation. The seat of this disease is by preference in the third portion, the first division being next in order. Exposure to violence or muscular effort undoubtedly has much to do with the development of subclavian aneurism, since males are very much more frequently affected than females, while the tumor is found on the *right* side, in the great majority of cases.

The first portion of the right subclavian is not infrequently involved in the progress of an innominate aneurism. Upon the left side aneurism of the thoracic portion of this vessel is rare.

Subclavian aneurism, as it usually develops, is first recognized as a pulsating tumor, felt rather than seen behind the clavicle, and to the outer side, or behind the sterno-mastoid muscle. It may be mistaken for a glandular or other tumor of the softer tissues. The symptoms which

* Prof. Sattler's classical paper in Graefe and Saemisch's "Handbuch der gesammter Augenheilkunde," Leipzig, 1880.

† "Prize Essays of the American Medical Association, 1878," William Wood & Co., New York.

have been already detailed will serve as a guide to proper differentiation. Difficulty may arise, even after the aneurismal character of the swelling has been recognized, in determining from what vessel the tumor springs. As has been said, the progress of aortic aneurism gives rise to pulsation and pressure symptoms, located in the thorax for a considerable period prior to the approach or appearance of the tumor at the root of the neck. In fact, aneurism of the aorta, in many instances, produces death before it attains such magnitude. On the right side, this knowledge will aid materially in recognizing the seat of the lesion, and, fortunately, aneurism of the arch and subclavian occurs most often on this side of the body. The differentiation of aneurism of the thoracic portion of the left artery, from the same lesion of the arch, near the origin of the subclavian, is somewhat more difficult. When the tumor involves the subclavian its appearance in the neck is more rapid than in aortic aneurism, while interference with the return circulation in the arm, which may appear early in the history of subclavian aneurism, is rare when the aorta is the seat of this lesion. Again, in aneurism of the second or third portion of the arch, which does not involve the subclavian, the pulse-wave in the left radial will be of equal force and synchronous with that of the right side.

The treatment of subclavian aneurism is a subject of great importance, and one which, from a study of a number of cases, has led to great diversity of opinion and practice.

The methods may be divided into the surgical; the postural, medical, and dietetic; and the palliative or expectant. The employment of any of these means will, again, be in great part determined by the portion of the artery involved in the disease. The surgical treatment comprises the ligature on the cardiac or distal side; compression on the distal side, or applied directly to the sac; and massage.

The *innominate* artery has been tied on account of subclavian aneurism seventeen times with sixteen deaths.

The operators and results were as follows: V. Mott, died twenty-sixth day, hæmorrhage from distal side. Graefe, died sixty-seventh day, hæmorrhage from distal side of ligature. Norman, died third day, hæmorrhage. Arendt, eighth day, pneumonia. Hall, fifth day, exhaustion and *venesection*. Bland, eighteenth day, hæmorrhage from distal side of ligature. Lizars, twenty-second day, hæmorrhage from distal side. Gore, seventeenth day, hæmorrhage from cardiac side of ligature. Cooper, eighth day. Cooper, thirty-fourth day, hæmorrhage. Pirogoff, two days, pneumonia. A. B. Mott, twenty-third day, hæmorrhage, sac burst into pleura. Bickersteth, sixth day, hæmorrhage from distal side of ligature. Thomson, forty-second day, hæmorrhage from distal side of ligature. Smyth, recovered, after ligature of innominate and carotid at first operation, and the vertebral fifty-four days later, to arrest violent bleeding. This patient died, ten years later, from hæmorrhage from the sac of the old aneurism. Thomson, died forty-second day, exhaustion from repeated hæmorrhage from distal side of ligature. Bull, thirty-third day, hæmorrhage from proximal side of ligature on thirtieth and thirty-third days; right carotid and vertebral also tied at same time with the innominate.

The *subclavian* artery has been tied in its *first* surgical division for the relief of aneurism involving this vessel, or its third portion, conjointly with the first part of the axillary (subclavio-axillary), in the following instances: Colles, death on fourth day, from hæmorrhage at seat of ligature. V. Mott, death on eighteenth day, hæmorrhage. Bayer, death in twenty-four hours, from bursting of sac. Hayden, death on twelfth day, from hæmorrhage at seat of ligature. O'Reilly, death on thirteenth day, hæmorrhage. Partridge, death on fourth day, pericarditis, pleuritis, pyæmia. Liston, death on thirty-sixth day, hæmorrhage from distal side. Rodgers, death on fifteenth day, hæmorrhage from distal side of ligature. Auvert, death on eleventh day, hæmorrhage, distal side. Auvert, death on twenty-second day, hæmorrhage from distal side. Liston, death on thirteenth day, hæmorrhage (right carotid tied at same time). Parker, death on forty-second day, hæmorrhage from distal side of ligature (right carotid tied at same operation). Of these twelve cases all died soon after the ligature. Only in one case (Rodgers) was the left subclavian tied.

For subclavian or subclavio-axillary aneurism the ligature has been applied in the *second* portion in four cases. Liston, death on fourteenth day, hæmorrhage at seat of ligature. Nichols, recovered, cured. Auchincloss, death on third day, from cerebral complications. Warren, recovered, cured. Gay, death on ninth day, bronchitis and pneumonia. Giving four cases, with two deaths and two cures.

Deligation of the subclavian artery, in its third portion, for subclavio-axillary or axillary aneurism, has been performed one hundred and thirteen times, with forty-seven deaths.* Naturally the mortality is greater in proportion to the proximity of the aneurism to the heart and to the seat of the ligature. Thus, in thirty-four of these cases the disease involved the third portion of the subclavian or the axillary, or both (properly named subclavio-axillary aneurism). As a result of the operation exactly one half perished. Of the seventeen recoveries, thirteen are reported cured.

For aneurism of the axillary proper I have the histories of seventy-nine cases in which the ligature has been applied to the third portion of the subclavian, with thirty deaths, forty-nine recoveries, and forty-six of these reported as cured. In seven of the fatal cases the aneurism was traumatic, and resulted from gunshot wounds (six in military, one in civil practice).

The value of the expectant plan may be estimated in the following cases:

SYNOPSIS OF 22 CASES OF SUBCLAVIAN ANEURISM IN WHICH "NO TREATMENT" WAS UNDERTAKEN.

18 deaths, 4 spontaneous cures.

Eighteen fatal cases. Dates of death after tumor was noticed (and when surgical interference might have been undertaken).

* Author's Essays, already cited.

- 1 case. Aneurism had existed for "some time." Died twelve weeks after admission to hospital.
- 1 case. Not known how long aneurism had existed.
- 1 case. Lived "some months." Died of exhaustion and suppuration caused by pressure of sac.
- 1 case. Died of rupture of sac twenty-four years after recognition of aneurism.
- 1 case. Died from asphyxia caused by pressure of sac, eight years.
- 1 case. Died from external rupture of sac two years and eight months after recognition of aneurism.
- 1 case. Died from exhaustion from pressure of sac, two years after recognition.
- 1 case. Died from dyspnoea from pressure of sac, two years after recognition.
- 1 case. Died from dyspnoea and exhaustion from pressure of sac, one year and a half after recognition.
- 1 case. Died from rupture of sac into lungs, one year and a half after recognition.
- 1 case. Died from rupture of sac into lungs eight months and a half after recognition.
- 1 case. Died from rupture of sac into tissues, becoming diffused, and causing death by pressure, five months and a half after recognition.
- 1 case. Died from rupture of sac, death by pressure, five months after recognition.
- 1 case. Died suddenly (probably from cerebral clot) one year and a half after recognition.
- 1 case. Died suddenly, cause not stated, not rupture of sac.
- 2 cases. Died from rupture of popliteal aneurisms.
- 1 case. Died from typhoid pneumonia, three years after recognition.

Of the four cures, three remained well; one died about four years later from rupture of an aortic aneurism. Of these eighteen fatal cases in which no treatment was undertaken, three died of other disease than the aneurism.

Of the thirteen cases in which the duration of life is noted after the recognition of the aneurism, the sum total is forty-seven years and nine months.

The sum of life in the thirteen cases after deligation of the innominate is about eight months, a difference in favor of non-interference (in an equal number of cases) of about forty-seven years of life.

SYNOPSIS OF 14 CASES TREATED BY VALSALVA'S METHOD.

(More or less modified.)

- 1 case. M.; R. Subclavian aneurism. Size, hen's egg. Venesection; cold and lead lotion locally. Recovered. Two and a half years later was working as a carter in the city.
- 1 case. M.; R. Subclavian. Immense size. Venesection. Cold and astringents locally. Tumor reduced in size and firmer; lost sight of while in process of cure.
- 1 case. M.; R. Subclavian (syphilitic). Valsalva's method and antisiphilitics. Cure complete.
- 1 case. M.; R.; age forty-five. Subclavian (syphilitic). Valsalva's method and antisiphilitics. Cured and seen well six years later.

- 1 case. M. ; age forty-two. Subclavian. Venesection. Digitalis. Rest. Marked improvement, so that patient left hospital and was lost sight of.
- 1 case. M. ; age fifty. Subclavian. Was treated for an intercurrent attack of rheumatism by rest, strict diet, and antiphlogistics. Cured.
- 1 case. M. ; age thirty-nine. Subclavio-axillary (Pancoast's case). Valsalva's method had been tried and considered a failure. Operation determined on. Carried into operating-room. Patient fell into collapse and operation was postponed. Recovered cured. (It is stated that a large dose of aconite had been given by mistake just before the operation was to have taken place.)
- 1 case. M. ; age thirty-seven. Subclavian. Venesection. Valsalva's method and careful and persistent direct compression for one year and a half. Cured.
- 1 case. M. ; age fifty-one. Subclavio-axillary (by Pelletan). Valsalva's method. Cured.
- 5 cases treated by this method (in part) were fatal. Venesection was not practiced except in one case. Only local and constitutional treatment. All died within twelve months of the recorded recognition of the disease ; one from ulceration into trachea, hæmoptysis, and exhaustion ; two from external bursting of sac ; two from exhaustion and coma (with pressure on the trachea in one case).

Summary.—Fourteen cases. Cured, seven ; improved, and in process of cure when lost sight of, two ; died, five. No venesection in four of five fatal cases. One successful case modified by direct pressure.

SYNOPSIS OF 6 CASES TREATED BY DIRECT PRESSURE UPON THE SAC (MODIFICATIONS GIVEN).

(*All subclavian aneurism.*)

- 1 case. M. ; forty-six years ; R. Leather "cup" molded over tumor and held in place by figure-of-8 straps around shoulders and axilla. Cured in fourteen months. Did light work during treatment, and had no other medication.
- 1 case. M. ; thirty-nine years ; L. Enormous size. Treated by cold and pressure "in turns." Small cannon-ball suspended so as to press comfortably. Discharged relieved. Some months later violent inflammation (from fall), suppuration, rupture of sac ; discharged two quarts of pus and blood. Cured. Debility of arm probably permanent.
- 1 case. M. ; forty-one years. (Thirteen months' duration.) Kept in bed, on back ; ice locally ; restricted diet. Third day air-cushion for twelve hours, with intermissions amounting to three hours. Every half-hour interval of ice. Treatment for seven days. Tumor began to subside, and was cured in twelve months.
- 1 case. (T. Holmes.) ("Lancet," February 12, 1876, p. 237.) Subclavian. Treated by direct pressure from rubber-ball. Cured.
- 1 case. (Dupuytren.) Direct pressure. Resulted fatally.
- 1 case. (Porter.) Exposed axillary and passed needle under it. Thirty-five days later exposed innominate and passed the "acupressure needle" under it. Died from hæmorrhage from innominate on tenth day.

(In one case given in preceding table, direct pressure was practiced with Valsalva's method.)

Summary.—Five cases of “direct pressure” (without operative procedures). Cured, four; died, one.

SYNOPSIS OF CASES OF MASSAGE OR KNEADING IN THE TREATMENT OF
SUBCLAVIAN ANEURISM.

Of this method there are six cases.

Three cured; viz., by Fergusson, Little, and Porter.

Three died; viz., by Fergusson, Hilton, and Morgan.

(See “Guy's Hospital Reports,” vol. xvi, p. 42 *et seq.*)

In addition, Mr. Bryant, in his “Practice of Surgery,” p. 190, gives a case by Dutoit, of Berne, in which a subclavian aneurism was cured by injection of ergotin around the sac under the skin, and digital compression.

Poland cured one case by digital pressure on cardiac side. A third case was tried for forty-six hours and abandoned on account of pain from pressure. The patient died from exhaustion. Paget tried mechanical pressure in a fourth case, but abandoned it as a hopeless undertaking. A fifth case by Verneuil was improved, but lost sight of before a cure was effected.

From the study of the foregoing history of subclavian, subclavio-axillary, and axillary aneurism, I have reached the following conclusions:

Deligation of the innominate artery, or the subclavian in its first surgical division, are operations so dangerous that they should be undertaken only in extreme conditions.

The first indication in the treatment of these lesions is pressure, judiciously applied. If possible, the compression should be exercised between the tumor and the heart. Next in preference, direct pressure upon the body of the aneurism. Perfect and persistent rest should be enforced, and with this the method of Tuffnel offers the surest and safest means of palliation and cure.

In making direct compression, the elastic ball introduced by Mr. Holmes seems best adapted. This should be applied gradually, in order to accustom the patient to its presence. Massage is so inferior to the plan just detailed that it may be omitted from practice.

Should all these means fail after a persistent trial, should the sac by ulceration open and threaten instantaneous death, or should the surgeon, from the appearances, judge that this accident was on the eve of occurring, ligature of the innominate should be performed, provided that the ligature could not be applied to the subclavian proper.

When the aneurism involves the last portion of the subclavian or the axillary, the ligature may be applied to the third division of the subclavian. Compression should always be tried in these, as in all other cases, before resorting to the ligature.

Aneurism of the brachial, radial, and ulnar arteries, or their branches, is comparatively rare, and when seen is almost always the result of a wound. The diagnosis is not difficult. The treatment required is digital or mechanical compression on the cardiac side of the tumor. If this fail.

direct compression of the sac may be added, and, if a thorough trial of these two methods is not successful, a catgut ligature should be applied, after the method of Hunter.

Aneurism of the Vertebral Artery.—Aneurism of the vertebral is almost always the result of a punctured wound. A rare exception to this rule is the case of idiopathic aneurism of both vertebrae reported by Dr. Anderton, of New York city.* It occurs most frequently in that portion of the vessel between the atlas and the transverse process of the sixth cervical. The chief point in diagnosis is the differentiation between the lesion in question and carotid aneurism.

The difficulty of distinguishing vertebral from carotid aneurism in the neck arises from the fact that direct pressure from before backward, in the lower portion of the neck, will interfere with or arrest pulsation in aneurisms of *both* vessels.

If, however, the head be flexed upon the chest, and the sterno-mastoid muscle thus relaxed, the *carotid* can be compressed by grasping the muscle between the thumb and finger, which are pressed deeply behind the outer and inner borders. This will not involve the vertebral.

Again, if the *carotid* be forcibly compressed by the thumb, backward and inward, against the vertebral column, at any point above the transverse process of the sixth cervical, the *vertebral* will not be included, since it is protected by the processes.

In my Essays are recorded five cases in which the common carotid was tied for supposed carotid, but in reality vertebral, aneurism. All ended fatally.

In the treatment of this lesion direct pressure may be employed, since prolonged compression of the artery before it enters the foramen in the sixth transverse process is impossible. One successful result of this method is recorded. If the disease continues to increase, deligation of the vessel in its first portion may be effected. This is a very difficult operation, and has rarely been attempted. The only operators so far are Smyth, Parker, Alexander, and myself.

Aneurism of the *internal mammary*, and other smaller branches of the subclavian, does not demand separate consideration. Aneurism of the *intercostal* arteries occurs in rare instances, usually as a result of fracture of a rib or a stab-wound.

Aneurism of the Abdominal Aorta.—Aneurismal dilatation of this section of the aorta occurs most frequently near the diaphragm. The entire vessel may be the seat of fusiform aneurism. Females are less frequently attacked than the opposite sex. In corpulent persons the diagnosis is difficult. Tumors of the central organs, as the stomach, pancreas, transverse colon, and the superjacent mesentery, may be mistaken for aneurism. On the other hand, in emaciated persons, unnatural expansion of the aorta during the cardiac systole has led to a mistake in diagnosis. The history of the development of the tumor, the presence of the aneurismal tremor and bruit, and the recognized general expansion of

* "Medical Record," vol. xx, p. 354.

the sac, with the arterial pulse, will enable the careful observer to arrive at a correct diagnosis.

The treatment is chiefly expectant. The method of Tuffnel, combined with interrupted compression by means of the tourniquet, should be employed. Pressure may be cardiac, direct, or distal, the former being preferable, if the location of the tumor renders it possible. If operative interference is demanded, the introduction of juniperized catgut ligatures through the canula, heretofore described, would be advisable. Anæsthesia is required, and the duration of compression may vary from fifteen minutes to one hour. Deligation of the aorta for aneurism of the same is scarcely possible.

Aneurism of the Branches of the Abdominal Aorta.—Aneurism of any of the visceral or parietal branches of the abdominal aorta may occur. The location of the tumor and the characteristic symptoms of aneurism will point to the vessel affected. When treatment is necessary, the same method should be employed as for aneurism of the main trunk. Exploration under strict antisepsis may be made, and deligation with the animal ligature practiced, if the tumor is sufficiently removed from the aorta to allow the application of the ligature to non-diseased tissue.

Aneurism of the Iliac Arteries.—Aneurism of the common, external, or internal iliac arteries is, fortunately, of rare occurrence. The diagnosis may be made by a study of the history of the individual case, and by abdominal palpation, coupled with physical exploration by the rectum or vagina.

In the treatment of aneurism of the common iliac, compression of the abdominal aorta should be faithfully tried. With this may be combined the treatment by rest and restricted diet, and carefully graduated direct pressure. Should these methods prove useless, and death be imminent from rapid expansion and threatened rupture of the sac, deligation of the abdominal aorta may be performed, or the external iliac or femoral may be tied.

The abdominal aorta has been tied in the following cases of iliac aneurism : *

No.	Operator.	Date.	Sex.	Age.	Result.
1	Astley Cooper.	1817	M.	38	Died in forty hours. Ligature applied three fourths of an inch above bifurcation of aorta. Tumor measured eight inches in long axis.
2	James.....	1829	M.	44	Died in three and one half hours. Femoral tied thirty-three days before aorta. Tumor increased in size and aorta tied. Ligature applied seven eighths of an inch above bifurcation.
3	Murray.....	1834	M.	33	Died in twenty-three hours. Tumor extended as high as the umbilicus. External iliac involved. Gangrene was threatened. Ligature half an inch above bifurcation.
4	Monteiro.....	1842	M.	31	Died in ten days. Large diffuse aneurism of femoral. Aorta ulcerated at seat of ligature, and death took place from hæmorrhage.
5	South.....	1856	M.	28	Died in forty-three hours. External and common iliac involved.
6	McGuire.....	1868	M.	30	Died in eleven hours. Sac, which involved <i>both</i> common iliacs, burst during operation, when a hasty ligature was thrown around the aorta.
7	Watson.....	1869	M.	?	Died in sixty-five hours. Nine weeks after ligature of common iliac hæmorrhage occurred, when aorta, external and internal iliacs were tied. No hæmorrhage after operation.
8	Stokes.....	1869	M.	50	Died in twelve hours. Right common and external iliac and femoral involved.

* Gross's "System of Surgery."

When the aneurism is located upon the external iliac, compression with the tourniquet may be employed over the aorta or common iliac artery. Prof. Sands has advised and practiced digital pressure of the common iliac by means of the hand introduced into the rectum. Pressure from within the rectum may also be accomplished by means of a bougie or piece of wood properly padded (Davy's method). As a last resort the common iliac may be tied. This operation, though dangerous, has been successfully accomplished in several instances in late years. A patient recently operated upon by Dr. Lange, of New York, recovered and was cured. Aneurism of the internal trunk is amenable to treatment by compression of the aorta or common iliac, or by deligation of the primitive trunk.

Aneurism of the branches of this vessel usually occurs in the gluteal and sciatic. The origin is almost invariably traumatic. The earliest symptoms are referable to the presence of the tumor. It must be distinguished from abscess or hernia. Aspiration would determine the presence of the former, and the symptoms of hernia, with absence of pulsation, would indicate the escape of the viscera through the great sciatic foramen. The treatment is difficult and often ineffectual. Direct compression should be first tried. Incision into the sac, turning out the clot, and tying both ends, has been successful in four of six cases reported by Fischer. The ligature may also be applied between the sac and the point of exit of the artery, or, as a last effort, the common iliac may be tied.

Aneurism of the Femoral Arteries.—Aneurism of the *superficial femoral* artery is comparatively frequent. It occurs by preference in the upper half of the artery, and in males in the great majority of instances. In rare instances the disease is symmetrical.

The diagnosis is not difficult, since the expansile pulsation of the tumor can, in most cases, be readily appreciated by palpation. A tumor in the line of the artery, with the characteristic pulsation, tremor, and murmur, all of which signs disappear when the iliac artery or aorta is firmly compressed, point almost unerringly to a diagnosis. The greatest danger of error lies in the presence of an abscess. Abscess is, however, of rare occurrence in this region, except as a sequence of spinal caries or hip-joint disease, and these conditions, existing with the other common symptoms of the development of abscess, would lead to its recognition. If doubt should still exist, after even the most careful survey of the case, the hypodermic needle would settle the diagnosis.

Treatment.—Aneurism of the *femoral* artery will, in the vast majority of cases, yield to judicious and patient compression. When the tumor extends as high as Poupert's ligament, or above this point, the chances of success are diminished, since pressure will have to be applied to the *common* or *external* iliac or the *aorta*. Under such conditions direct compression, by means of Holmes's elastic ball, applied so gradually that inflammation of the sac will not be precipitated, should be first faithfully tried. Ligature of the *common* or *external* iliac should be deferred until all other remedies have failed, and, when there is a choice between these two procedures, the deligation of the *external iliac* should be preferred,

on account of the anastomoses of the branches of the *internal iliac* with the vessels of the thigh. Direct compression of the sac was once successfully practiced by Dr. Brown, of Boston, in a case of femoral aneurism at Poupart's ligament. The weight employed may be as much as twelve pounds. Iron balls were used in this case. The patient was confined to bed for ten months. When the tumor is so far away from Poupart's ligament that digital or mechanical compression of the femoral upon the os pubis is possible, this treatment should be adopted. Extreme flexion of the thigh upon the abdomen has succeeded in producing a cure in a few instances. Direct pressure upon the tumor, with the limb extended, is less painful and equally efficacious. When the necessity for the application of the ligature occurs, the effort should be made to reach the artery below the origin of the *profunda femoris*, since the danger of gangrene is much less if this great collateral route is open.

The treatment of aneurism of the lower portion of the *femoral* does not materially differ from the above.

Aneurism of the *profunda femoris* is rare, occurring usually as a complication of this condition in the *common* trunk, or as a result of a punctured wound.

The treatment will include pressure on the cardiac side, or direct compression, and, as a last resort, ligature of the common femoral, or iliac.

Aneurism of the Popliteal Artery.—About one fourth of all aneurisms occur in this vessel. Subjected, by reason of its unfortunate location, to the accidents of compression in extreme flexion of the leg, it frequently suffers those pathological changes which end in aneurismal dilatation, and is only second in order of frequency to the aortic arch, which yields to the violence of the cardiac systole. As with aneurism in other locations, it occurs most frequently in males, and in the active period of life, being rare in childhood and youth, and most common in the years from twenty-five to fifty.

Diagnosis.—On account of the infrequency of tumors in this region, other than aneurism, the diagnosis is not difficult. The characteristic symptoms of this malady will determine its differentiation from glandular enlargements, exostoses, over-distended bursæ, or abscess.

Treatment.—In the treatment of popliteal aneurism the patient should be placed in the recumbent posture, with the leg of the affected side slightly flexed. A soft mattress should be used, and the thigh and leg held in a comfortable and fixed position by means of a pillow under the popliteal space, and sand-bags laterally. Under the influence of an opiate, or in extreme cases complete etherization, digital or mechanical pressure should be employed upon that portion of the artery lying in Scarpa's triangle (Fig. 273). Within this limit the point of compression may be shifted, in order to prevent too great local irritation.

In obstinate cases compression on the cardiac side may be re-enforced by forced flexion of the leg on the thigh, or by direct pressure upon the tumor. The instances will be exceedingly rare where a patient and skillful employment of these methods of compression will not succeed in

effecting a cure. Consolidation may result in one or two hours, or it may require several hours or days. Acupressure and massage are not to be employed. The elastic bandage of Esmarch has not given results which would justify its further use. When compression, either on the cardiac side or directly upon the aneurism, fails, the deligation of the femoral, in the extreme lower angle of Scarpa's space, is demanded.

Aneurism beyond the Popliteal.—Aneurism of the peroneal or tibial arteries, or their branches, is rare. In diagnosis and treatment this lesion, when situated in this portion of the arterial system, requires little or no special consideration. When the tumor is so situated that the vessel immediately involved can not be occluded by compression, this may be directed to the femoral, or, in aneurisms of small size, direct pressure may be sufficient to effect a cure. The ligature will be demanded if other methods fail.

Arterio-venous Aneurism.—*Arterio-venous* aneurisms are of two kinds. In one variety the communication is direct, the contiguous walls of the artery and vein being closely adherent immediately around the opening leading from one vessel to the other. This is called *direct arterio-venous* aneurism, or *aneurismal varix*.

When a sac intervenes it is called an *indirect arterio-venous* or *varicose aneurism* (Fig. 271).

The cause is usually traumatic, resulting most frequently from punctured wounds, although any inflammatory process which induces necrosis of the arterial and venous walls may lead to this form of aneurism. In exceptional instances the communication has either not been established, or at least has escaped observation for several years after the injury. This lesion may occur in any portion of the economy. In former years it was observed most frequently in front of the elbow-joint, where it was produced by the accidental puncture of the brachial in the operation of venesection. It occurs not infrequently in the neck, as a result of wound of the *carotid* artery and *internal jugular* vein.

The chief points in the differential diagnosis between varicose aneurism and aneurismal varix are the presence of a tumor and the peculiar aneurismal *bruit* and tremor, which conditions exist in the former.

In both varieties of this disease the veins become greatly distended and tortuous, and pulsate forcibly with each contraction of the heart, while the pulsation in the artery beyond the lesion is perceptibly diminished.

In the treatment of varicose aneurism, compression of the artery should be employed on both sides of the tumor, while direct pressure should be made upon the sac, between the two vessels. When, from the location of the lesion, this method is not feasible, or when, after a faithful trial, it has failed to produce a consolidation of the aneurism, the ligature will be required. Catgut should be used, one thread being passed around the artery just above, and another just below the tumor. When so situated that the vein involved in the lesion is not necessary to the integrity of the part, as in the forearm, this may also be secured on the distal side of the foramen of communication.

Operative interference in cases of *aneurismal varix* is not so frequently indicated as in *varicose aneurism*, owing to the comparatively slow progress of the disease. Experience has shown that deligation of the affected artery is far more dangerous in this condition than in the indirect variety. Fatal secondary hæmorrhage is recorded in a number of instances, while in others gangrene has resulted from closure of the artery. Compression should be employed as in the treatment of the form just considered. When the lesion is situated in the vessels of an extremity much comfort may be secured by the employment of an elastic bandage or stocking, as in the treatment of venous varix. As a last resort, amputation may be practiced.

*The Author's Case of Deligation of the Left Subclavian and Left Common Carotid Arteries.**—In February, 1889, under chloroform narcosis, I tied with catgut ligatures the left common carotid and left subclavian artery (third division) for the cure of aneurism of the transverse arch. The patient, male, forty-eight years old, had syphilis seventeen years before, had neglected treatment, and syphilitic arteritis ensued. Symptoms of aneurism appeared about two years before date of operation. The iodides had been faithfully tried, but the symptoms of pressure by the tumor increased, and the operation was done as a last resort. He died seventy-two hours later from suppression of urine and asphyxia, due to syphilitic gummata, involving chiefly the right lung, which was almost entirely solidified. Commencing with the origin of the left carotid and extending beyond that of the left subclavian was situated a spherical aneurism about three inches in diameter filled with firm clot almost wholly organized. It pressed heavily on the trachea and œsophagus and the left recurrent laryngeal nerve. It extended from the seventh cervical to the second dorsal vertebra (Fig. 276 A). This aneurism was practically cured, and the organized clot had without doubt resulted from the medical and expectant treatment. The smaller proportion of softer and recent clot was produced by the ligature.

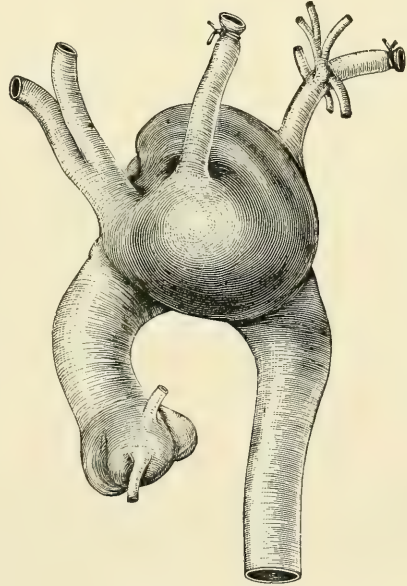


FIG. 276 A.—The author's case of deligation of the left carotid and left subclavian arteries for aneurism of the transverse portion of the arch.

* A recent and successful case of deligation of the right common carotid and subclavian arteries for aneurism of the arch is reported by Dr. F. T. Meriwether, of Asheville, N. C., in "Annals of Surgery," May, 1889.

CHAPTER XI.

LIGATION OF ARTERIES.

Operative Surgery of the Arteries.—In tying an artery, all of the details of the antiseptic method given heretofore should be scrupulously carried out. While the incision should be along the line of the artery,

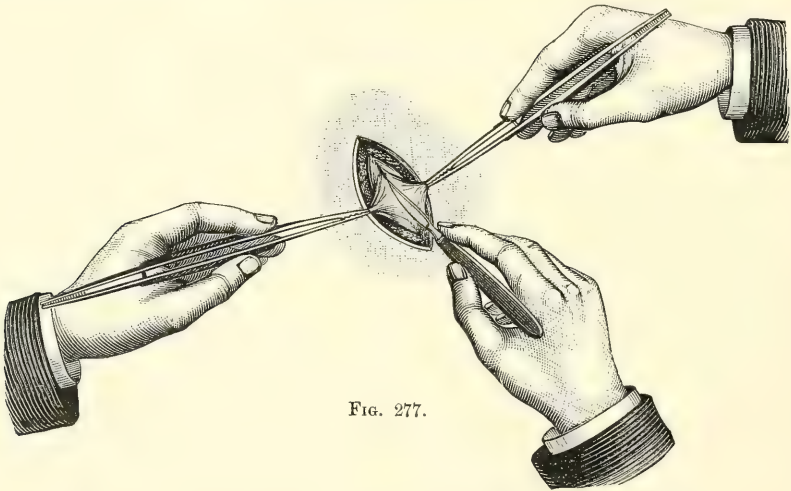


FIG. 277.

it should lean as far from the accompanying vein as possible. In approaching the vessel after the skin is divided, the fascia and all inter-

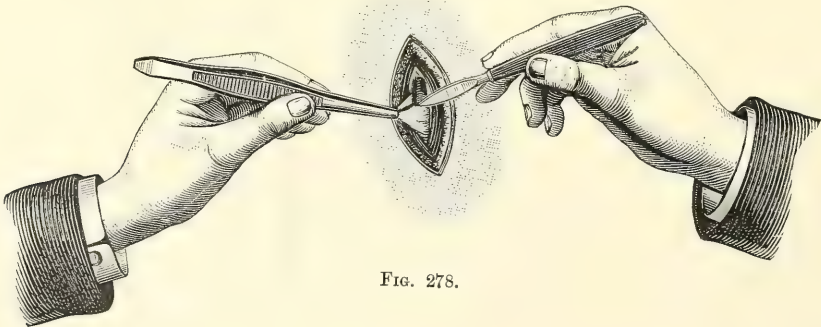


FIG. 278.

vening tissues should be grasped between two long, delicate dissecting forceps (Figs. 277, 278), until the sheath is reached, and this is opened

in the same manner. As soon as the wall of the artery is exposed the sharp-pointed instruments should be laid aside. A dull-pointed aneurism-needle (Fig. 63), or a flexible silver probe, should now be passed between the sheath and the vessel, and carried carefully around the artery, keeping the point close to the wall of the vessel. When a nerve or vein is in close relation, the instrument should be introduced on the side nearest these, thus insuring their exclusion. The dull-pointed probe, bent to the proper curve, may be used to great advantage in almost all operations upon the arteries. After the point is carried around the vessel and brought up out of the sheath, the ligature may be tied over the slight bulbous expansion of this instrument, which, when withdrawn, leaves the ligature around the vessel. The force employed should be sufficient to occlude the vessel, yet not enough to inflict unnecessary violence upon its walls. The ends of the string should be cut off for one fourth to one half of an inch from the knot, and the wound closed for a permanent dressing.

Ligation of the Innominate Artery—Anatomy.—The *arteria-innominata* is derived from the transverse segment of the arch of the aorta, immediately in front of the trachea, just behind the middle of the sternum, at a level varying from one half to one and a half inches below the upper margin of the manubrium.

From this origin it travels obliquely upward, backward, and to the right (crossing the trachea from its center), and bifurcates, near the upper margin of the clavicle, between the *sternal* and *clavicular* origins of the *sterno-mastoideus* into the *carotid* and *subclavian arteries*, the first of these coming from its anterior aspect, the last a direct continuation of the *arch of the innominate*. The *innominata* in rare instances originates to the left of the trachea; more frequently it is given off before it reaches the windpipe. As a rule, it is longer in females than in males.

In twenty-eight cases in which I measured the distance of the origin of the innominate from the commencement of the aorta, the average was three inches and a half. In thirty-seven measurements made to determine the length of the innominate artery, the average was one inch and a half, the shortest specimens being three fourths and the longest two inches.

Operation.—Place a firm cushion crosswise beneath the shoulder-blades, so that the head will fall well back, and thus draw the artery upward. Have an assistant draw the arm and shoulder of the right side forcibly downward, while the chin is elevated and the face turned slightly to the left.

With the patient completely anæsthetized, and every arrangement made for expedition, make, from the center of the interclavicular notch, an incision about three inches in extent along the clavicle. A second incision, commencing at the inner border of the sterno-mastoideus, about two inches and a half above the clavicle, is made to unite with the first incision at the middle of the interclavicular notch. Dissect the flap upward until the sterno-mastoid muscle is exposed, the sternal and two

thirds of the clavicular origins of which should be divided upon a grooved director carefully introduced. Superficial to the muscle some small veins will be found, and underneath its clavicular portion is the junction of

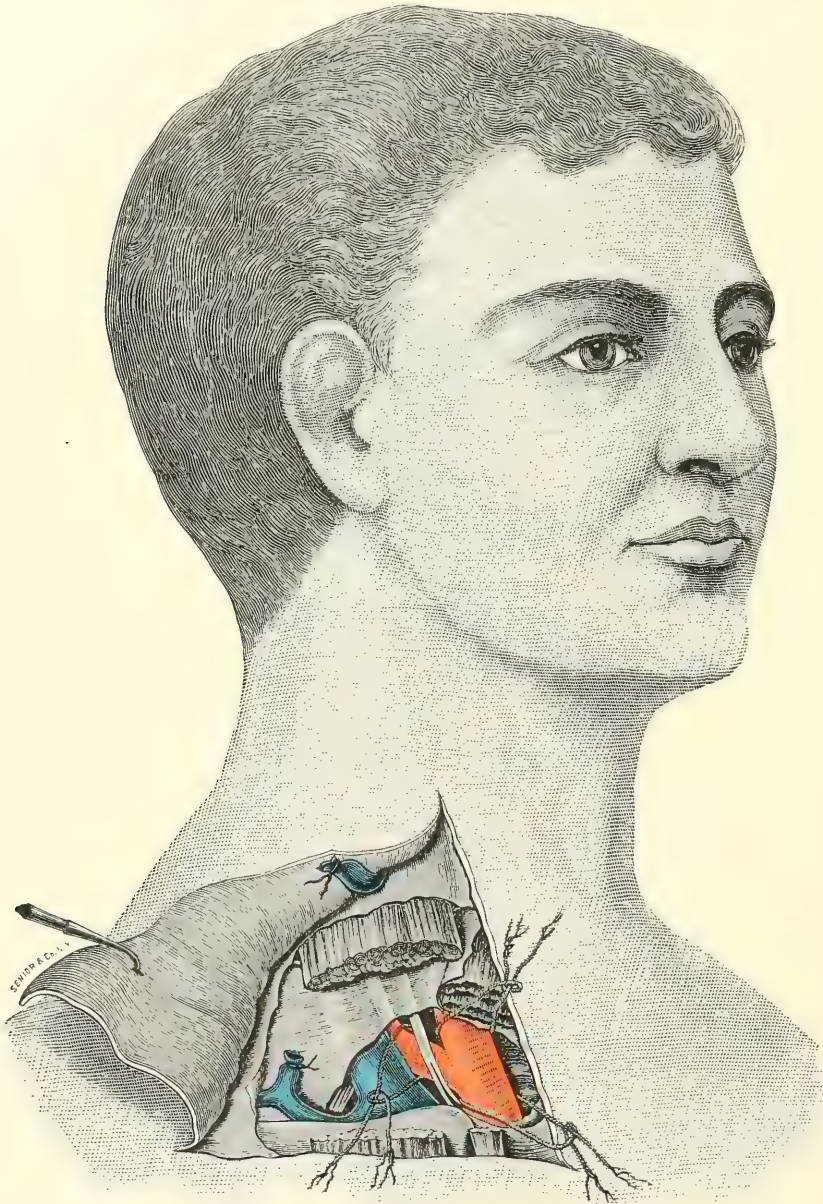


FIG. 279.—Showing the relations of the parts involved in deligation of the innominate artery; the right subclavian and carotid in their first divisions.

the subclavian and jugular veins, in dangerous proximity. The anterior jugular veins will be seen immediately beneath the muscle, and should be tied and divided. Dissecting carefully, with the handle of the scalpel, the connective and areolar tissue in which these veins are imbedded, the

origins of the *sterno-hyoid* and *sterno-thyroid* muscles will be reached, and, when these are divided carefully upon the director, the right carotid will be seen near the center of the wound. Following this down, the *arteria innominata* will be found just behind the *sterno-clavicular* articulation (Fig. 279). Being exposed with the scalpel-handle, or any dry dissector not likely to wound the vessel, the aneurism-needle should be passed from right to left behind the artery, care being taken to avoid wounding the right *vena innominata* and the *pneumogastric nerve*, or puncturing the *pleura*, in which the artery is *partly imbedded*. It is well to bear in mind that the left innominate vein crosses this artery, although usually very low down. When the aorta is situated low in the *thorax*, it may be necessary to remove the sternal end of the clavicle and a segment of the sternum, as was done by Cooper, of San Francisco, in two instances.

An element of danger in this operation is the origin of an abnormal branch from the innominate. In the cases of Lizars and V. Mott this anomaly existed, and death was caused by *hæmorrhage at the seat of the ligature*. In thirty-four consecutive subjects which I examined as to this feature, I found an abnormal branch to be derived from the innominate in five. When the necessity for occlusion of the *arteria innominata* arises, and the conditions are such as to permit it, the following method should be followed: The right common carotid should first be tied, one inch above its origin. By a careful dissection the first division of the subclavian and its branches should then be exposed, drawing the internal jugular to the outer side until the vertebral is secured. Avoiding the phrenic nerve, as it descends to the inner side of the scalenus anticus, the internal mammary and branches of the thyroid axis should be secured, and finally a ligature of large, smooth catgut, or prepared nerve placed around the subclavian artery, about the middle of its first portion. A careful study of the anatomy and surgery of this region leads me to conclude that this procedure, though difficult of execution, offers a better prospect of success than deligation of the larger and primitive trunk, nearer the heart.

In the operation and after-treatment of the wound the most careful antisepsis should be practiced, and perfect drainage maintained.

Ligation of the Common Carotid Arteries and the Internal Jugular Vein—Anatomy.—In one hundred and twenty dissections I found the *common carotid* artery to bifurcate on a level with the notch between the two *alæ* of the thyroid cartilage in one hundred and sixteen. The anomalies of this vessel are so rare that they do not deserve mention in this work.

Operation.—A firm cushion should be placed under the shoulders and lower part of the neck, with the chin elevated, and the face turned in the direction away from the side upon which the operation is to be performed. A line extending from the tragus of the ear to the *sterno-clavicular* articulation will cover, and be parallel with, the *internal* and *common carotid* arteries in their surgical length. This line will strike the center of bifurcation of the primitive carotid almost invariably on a level with the upper border of the thyroid cartilage, and the anterior edge of the *sterno-mastoideus* from one inch and a quarter to one and a half

below this level. The point of election is about one inch below this bifurcation, and at the upper border of the anterior belly of the omo-hyoid muscle.

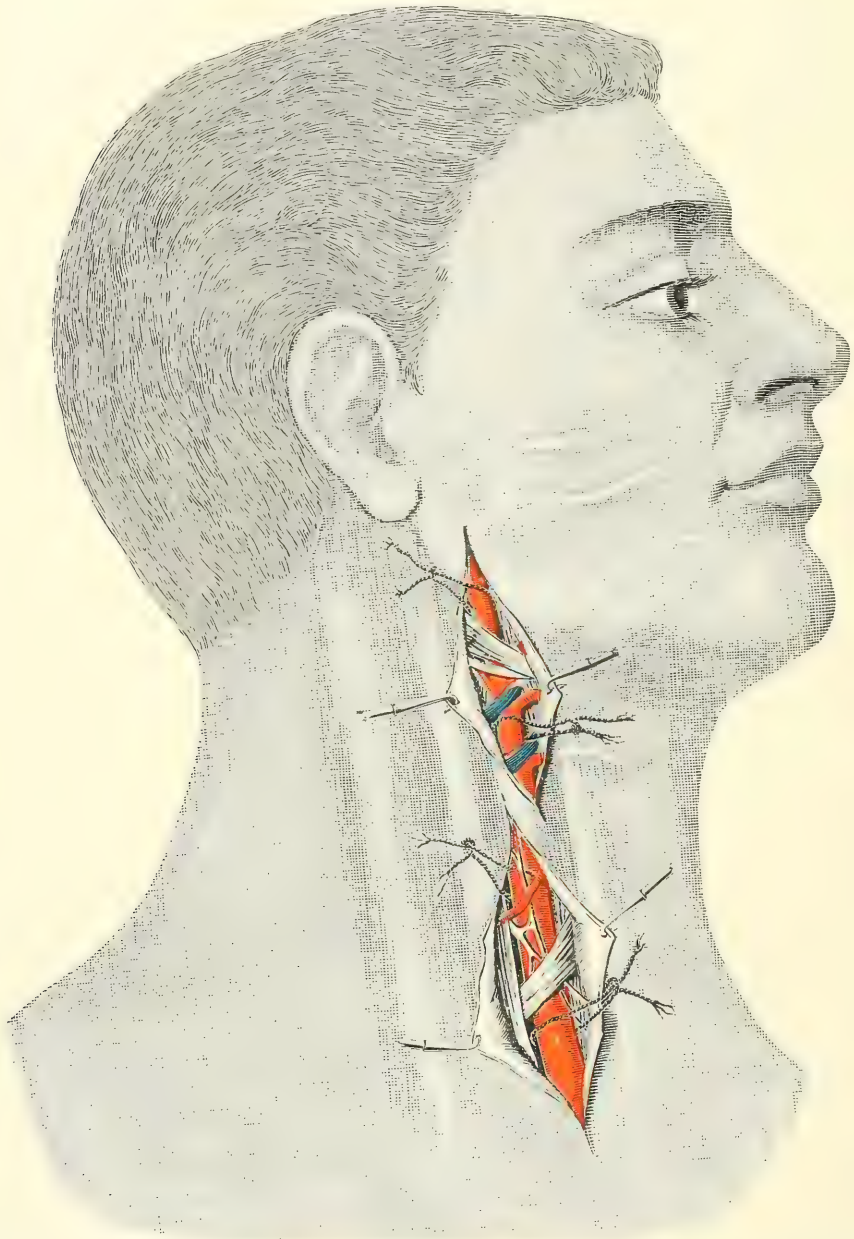


FIG. 280.—Showing lines of incision and relation of parts involved in deligation of the common carotid, above and below the anterior belly of the omo-hyoid, and the external carotid below the lingual and above the facial.

The incision, being made with its direction as above given, its center about one inch below the bifurcation, extending from one-and-a-half to two inches above and below this point, will divide first the integument,

and with this the thin *platysma myoides*, some filaments of the *superficialis colli* nerve, of no importance, and some small veins passing from the *anterior*, either to the *internal* or *external jugular veins*. About the center of the wound the edge of the *mastoideus* will be seen, and below this (usually) the anterior belly of the *omo-hyoideus* (Fig. 280, lower half). The sheath of the *carotid* and *jugular vein* is now exposed, often crossed by the *thyroid veins*, and the *cervicalis descendens* artery, the *descendens noni* nerve almost invariably lying upon the center of the sheath, being parallel with the axis of the *common* and *internal carotids*. In two instances I have seen the *superior thyroid* artery turn directly down, in front of the *common* trunk, for an inch or more, and then turn abruptly inward to be distributed to the thyroid body. Under such abnormal conditions this vessel would probably be divided. The *communicans noni* is occasionally found crossing the sheath from without inward, to anastomose with the *descendens*. These nerves will be drawn to the outer or inner side of the wound, as is most convenient. The sheath should be opened on its *tracheal* side, as far as possible from the *jugular vein*, and the needle passed from without inward, being kept close to the artery in order to avoid wounding the *vein* or including the *pneumogastric* or *sympathetic nerves*. The sheath should be well opened, and the artery clearly exposed, so that the needle may be manipulated with more of certainty and less danger from these too common and unfortunate accidents. In several instances the artery has been transfixed; the *jugular* has been wounded; the *pneumogastric* or *sympathetic* nerves included in the ligature, for want of precision in separating the artery from the vein. Certainly the danger of slough in the artery is not so great as the dangers above enumerated. Just as the needle is being introduced, pressure above upon the vein would empty it of blood, and of course diminish the danger of wounding it.

The operation of tying the carotid, just below or behind the *omo-hyoid*, is practically the same as that just described (Fig. 280).

In order to secure this vessel at the root of the neck, an incision should be made in the carotid line, extending from the sterno-clavicular articulation upward a distance of three or four inches, and between the two heads of origin of the sterno-mastoid muscle. This will divide the integument, superficial fascia, platysma, and deep fascia, and some descending superficial nerves. The fibers of the sterno-mastoid may be separated and held to either side by retractors. Immediately beneath it will be found the anterior jugular vein, and some small branches emptying into it. If not easily displaced, they should be secured with a double ligature, and divided between the threads. The fibers of the sterno-hyoid or sterno-thyroid muscles should next be divided on a grooved director, and turned aside or separated in the line of the artery. The vessel will be seen deeply situated in the line already given. The ligature should be passed from the outer side. Or an L-shaped incision, similar to that made for deligation of the innominate (Fig. 279), may be made, and the carotid found by separating the sternal tendon of the *mastoideus* muscle and turning this outward. For the left carotid see Fig. 281.

The approach to the vessel in this region should be very cautious, especially upon the left side of the neck, since the internal jugular vein crosses from the outer to the inner side by the front. On the right side

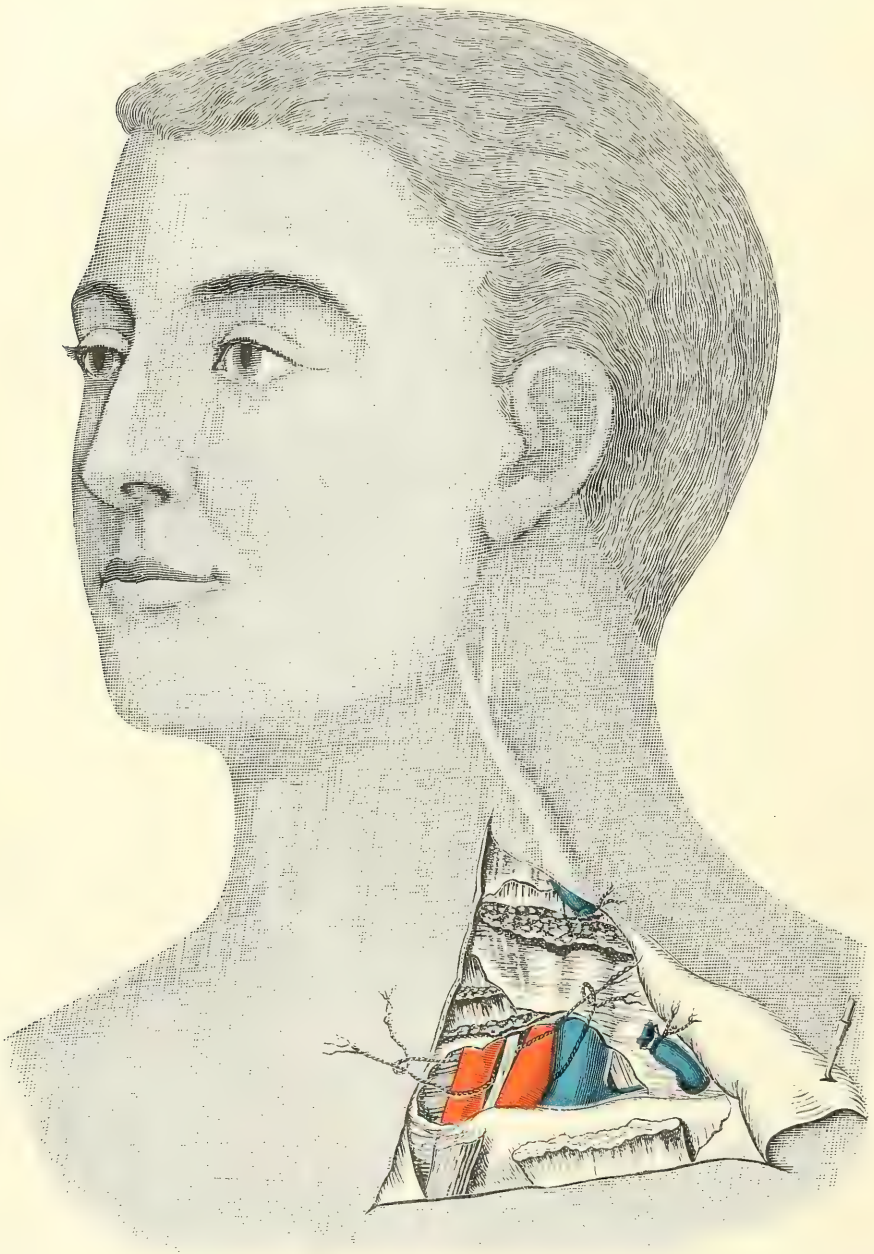


FIG. 281.—Showing the relations of parts involved in deligation of the left carotid, at the root of the neck, and the left subclavian in its first surgical division.

the vein is a little more external. The pneumogastric nerve lies behind and to the outer side of the artery, while the inferior thyroid artery and sympathetic nerve are more deeply situated. The aneurism-needle

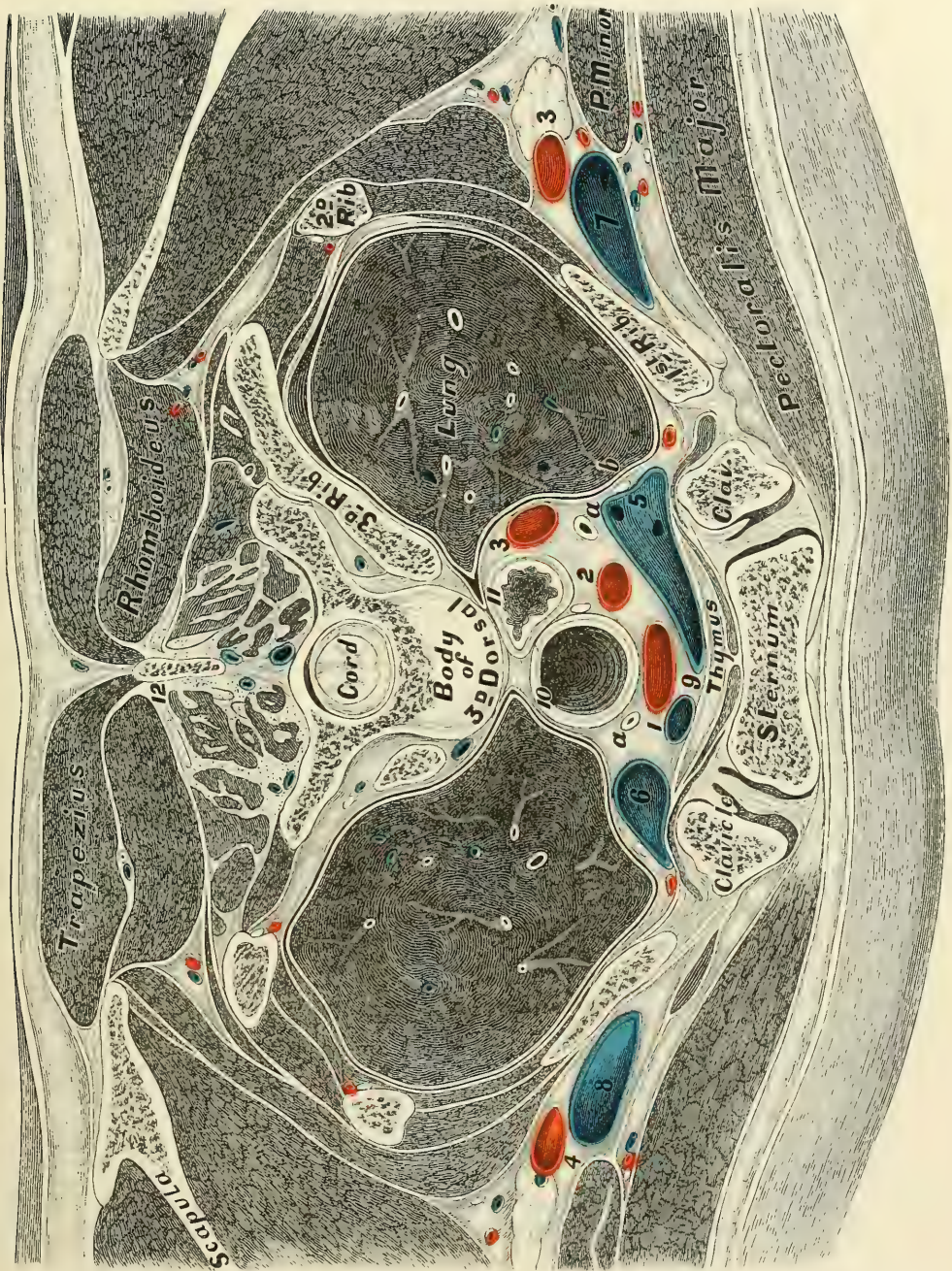


FIG. 282.—Showing the relations of the important organs at the root of the neck and apex of the thorax. Frozen horizontal section at the level of the third dorsal vertebra. (After Braune.) 1, Innominate. 2, Left carotid. 3, Left subclavian. 4, Right subclavian arteries. 5, 6, Left and right innominate veins. 7 and 8, Subclavian veins. 9, Inferior thyroid vein. 10, Trachea. 11, Esophagus. 12, Spinous process of second dorsal vertebra. *a a*, Pneumogastric nerves. *b*, Phrenic nerves.

should be passed around the artery, from the outer toward the inner side.

In the "Prize Essay" of the American Medical Association for 1878 I collected histories of 789 cases in which the common carotid artery had been tied for all causes, of which 323, or 41 per cent, died. An analysis of these cases is impossible here. I do not believe that the death-rate will ever again reach this alarming figure. The introduction of animal ligatures and antiseptics have already greatly diminished the death-rate in operations upon the arteries.

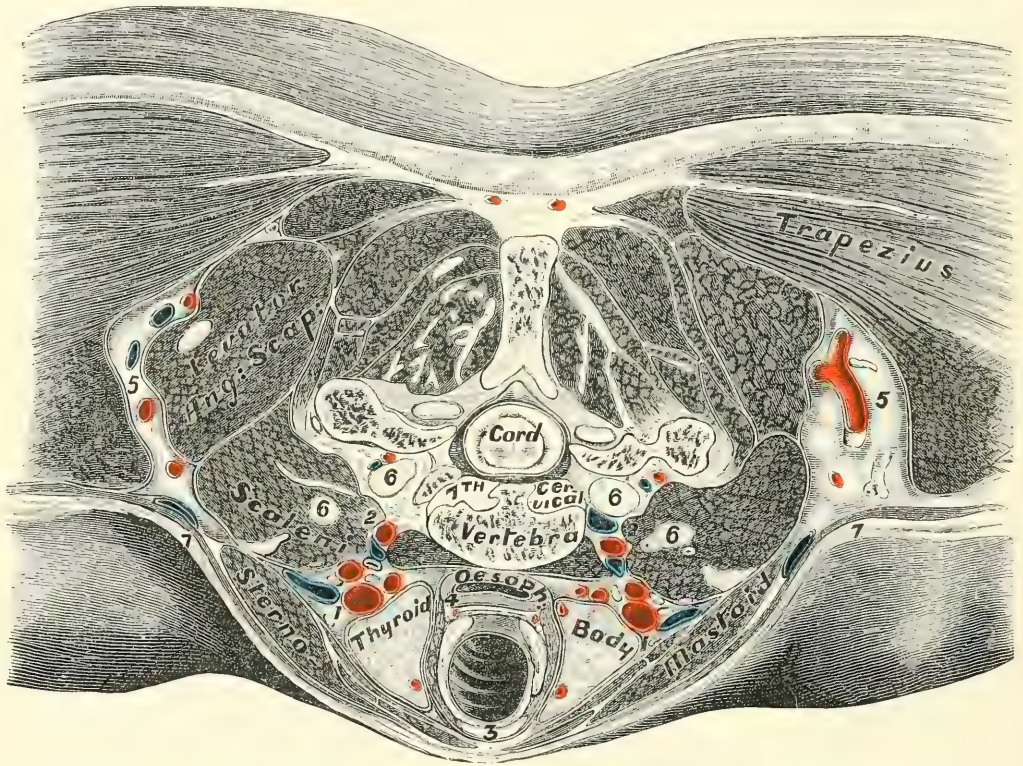


FIG. 283.—Horizontal section at the level of the seventh cervical vertebra. 1, 1, The right and left common carotid arteries and the internal jugular veins. 2, The right and left vertebral arteries and veins. Directly between the vertebral and carotid arteries is seen the sympathetic nerve and the inferior thyroid artery and some of its branches. The pneumogastric nerves are seen between and slightly posterior to the internal jugular veins and the common carotids. 3, Trachea. 4, Oesophagus. 5, Transversalis colli artery and veins and descending branches of the subclavian artery. 6, Cords of brachial plexus. 7, 7, External jugular vein. (After Braune.)

Thirty-four cases are on record in which both trunks were tied, of which twenty-five recovered.*

Ligation of the Internal Carotid Artery—Anatomy.—This vessel is a direct continuation of the common trunk, and, while straight in its lower portion, it becomes slightly tortuous as it approaches the carotid canal. An abnormal branch was found to be derived from its first portion in seven of one hundred and twenty dissections.

Operation.—The position is the same as for tying the common trunk.

* *Op. cit.* See also Riegner's case, "Centralblatt für Chirurgie," No. 26, 1884.

The incision should be made in the carotid line, with its center from one half to three quarters of an inch above the upper border of the *thyroid cartilage*. The same structures will be divided superficially, and the veins will be seen superficial to the artery. As shown in *C*, Fig. 285, they

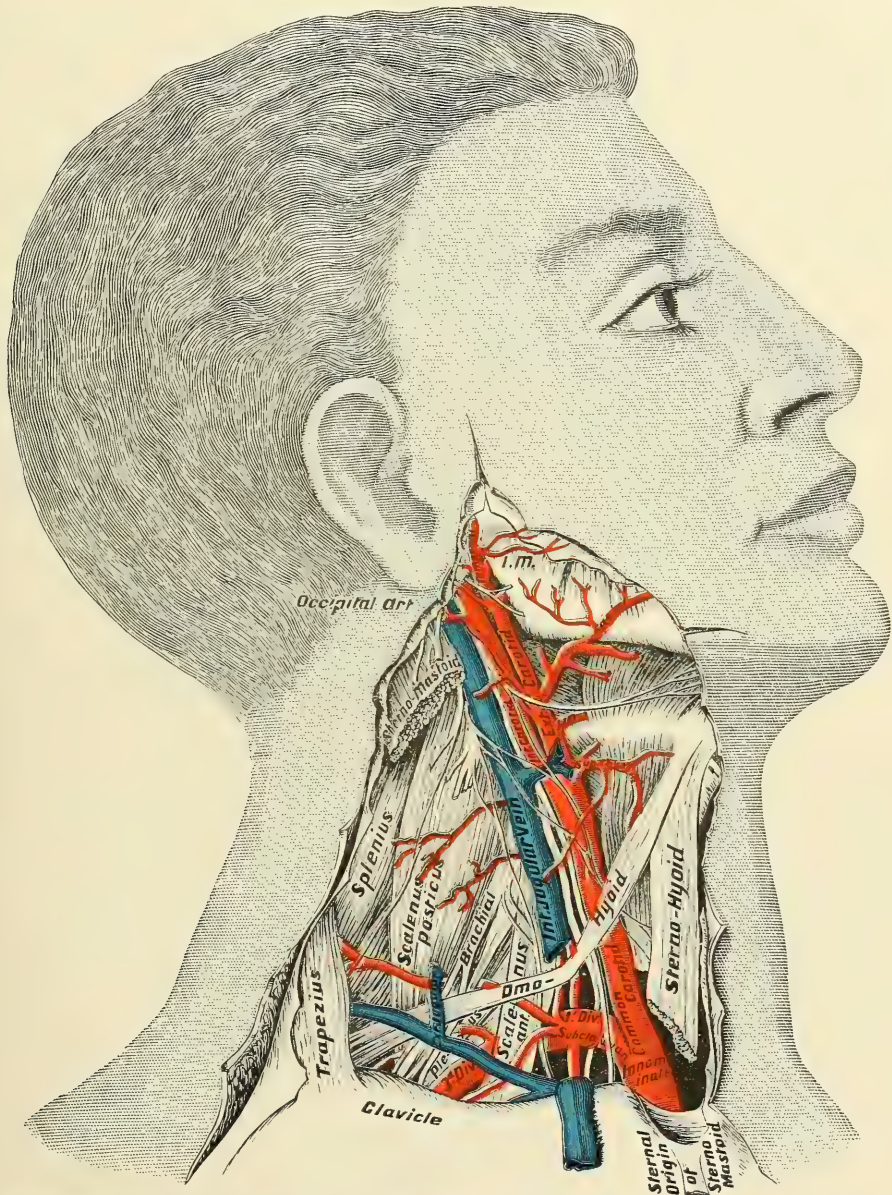


FIG. 284.—The usual relation of the contents of the surgical triangles of the neck. From the author's dissections.

may cross the internal carotid almost at a right angle, or (as in *A* or *B*) they may empty into a single trunk, and run parallel with the *external carotid*. This last is the most usual way, but it will be scarcely possible to ligate the *internal carotid* without ligature and division of some of

these veins. The *descendens-noni* nerve will be seen running along the artery, the *hypoglossal* crossing it about one inch from the bifurcation. The vessel being exposed, the needle is introduced on the out-

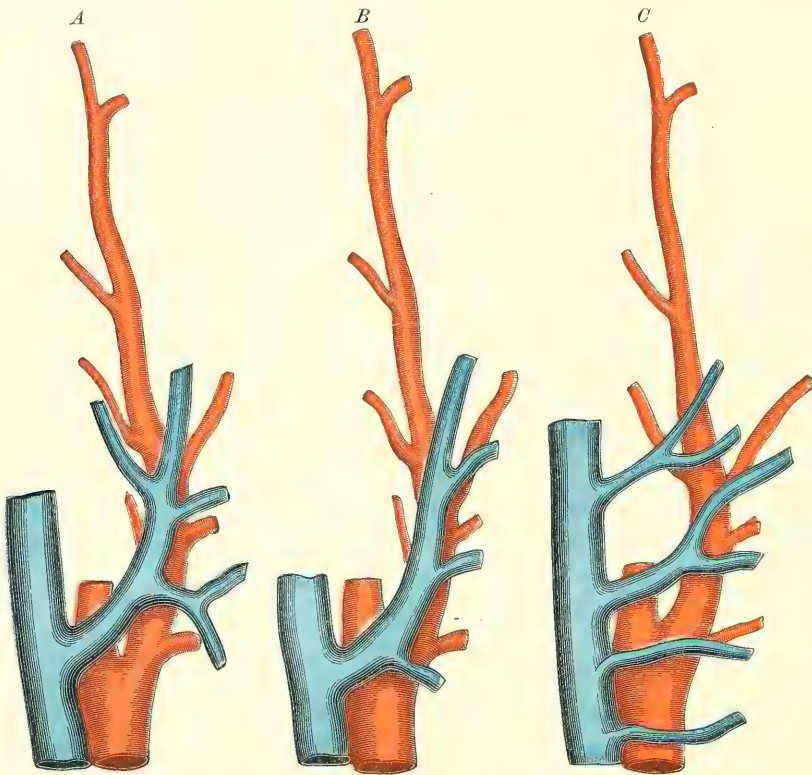


FIG. 285.—Relation of the veins to the carotids. (Life size.)

er side, avoiding the *jugular vein* and *pneumogastric* nerve externally, the *external carotid* internally, and the *hypoglossal* nerve superficially. The *pharyngea ascendens* is in intimate relation to the *internal carotid*, running parallel with it on its inner aspect. Occasionally the first cervical ganglion of the sympathetic extends as low as this point. It will be avoided by keeping the needle close to the artery.

The internal carotid artery has been tied nineteen times, with twelve recoveries.* In six of the fatal cases the common trunk had been previously and ineffectually secured, and in the remaining case I tied the common, external, and internal carotids, in removing an immense tumor which involved these vessels. The patient died from shock in eighteen hours.

Ligation of the External Carotid Artery.—From the extensive distribution of its branches to the exposed portions of the neck and face, the *external carotid* artery demands a more careful consideration than any single vessel of the human body.

* *Op. cit.*

Anatomy.—Leaving the *common* trunk at the upper border of the *thyroid cartilage*, well forward of the anterior border of the *sternomastoid* muscle, this vessel arches forward and upward (its concavity looking toward the lobule of the ear) until, on an average of $\cdot92$ inch above the bifurcation, after giving off the *facial* branch, it turns obliquely upward and backward to a point opposite the insertion of the *external pterygoid* muscle into the neck of the condyle of the lower jaw, where it terminates by dividing into the *temporal* and *internal maxillary* arteries.

Eight regular branches belong to this vessel (though some anatomists, among whom are Hyrtl, Wilson, and Richardson, describe nine). On its anterior aspect arise from below, upward, the *thyroidea superior*, *lingualis*, *maxillaris externa*, and *maxillaris interna*. On its posterior and internal aspect the *pharyngea ascendens*, and posteriorly the *occipitalis*, *auricularis*, and *temporalis*.

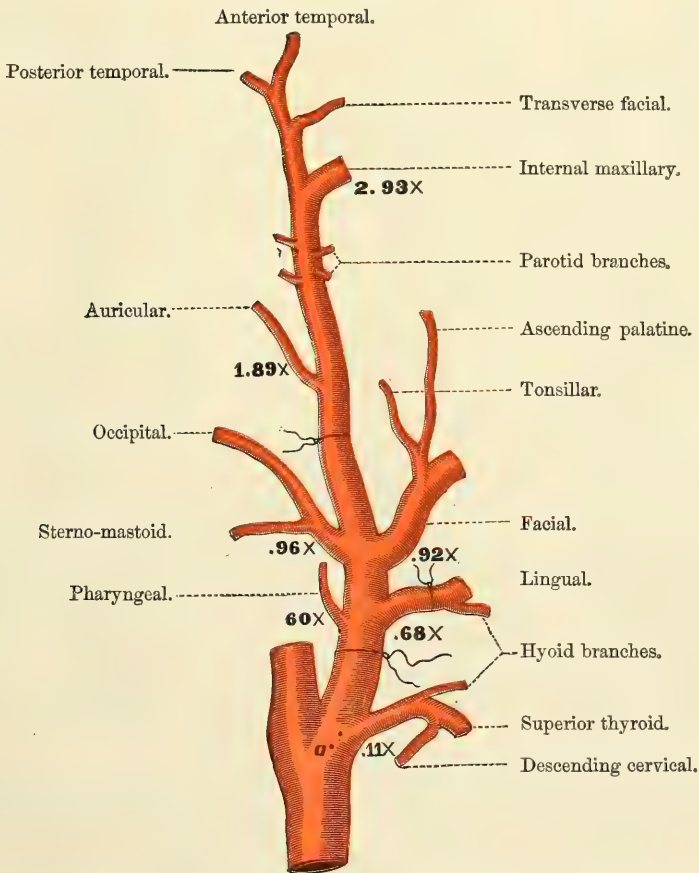


FIG. 286.—The external carotid and its branches. The average arrangement of one hundred and twenty-one dissections by the author. (Life size.)

The usual arrangement of these branches is seen in Fig. 286, which is the average of one hundred and twenty-one dissections. Abnormal deviations from this relation of the branches to the parent trunk

occur occasionally, and types of these may be seen in Figs. 287 and 288. The relations of the veins to these arteries are shown in Fig. 285.

Operation.—The external carotid may be tied in the majority of cases at two points, viz., between the origins of the *thyroidea superior* and *lingualis*, about one quarter of an inch above the septum of bifurcation (see Fig. 286), or between the origins of the *maxillaris externa* and *auricularis*, about one inch and a half above the *thyroid cartilage*. At the lower point of election the operation is the same as for ligature of the *internal carotid* on the same plane, except that the *external carotid* is usually from one quarter to one half inch nearer the median line than the *internal*.

Notwithstanding that the analysis of one hundred and twenty-one consecutive dissections has convinced me of the propriety of ligaturing

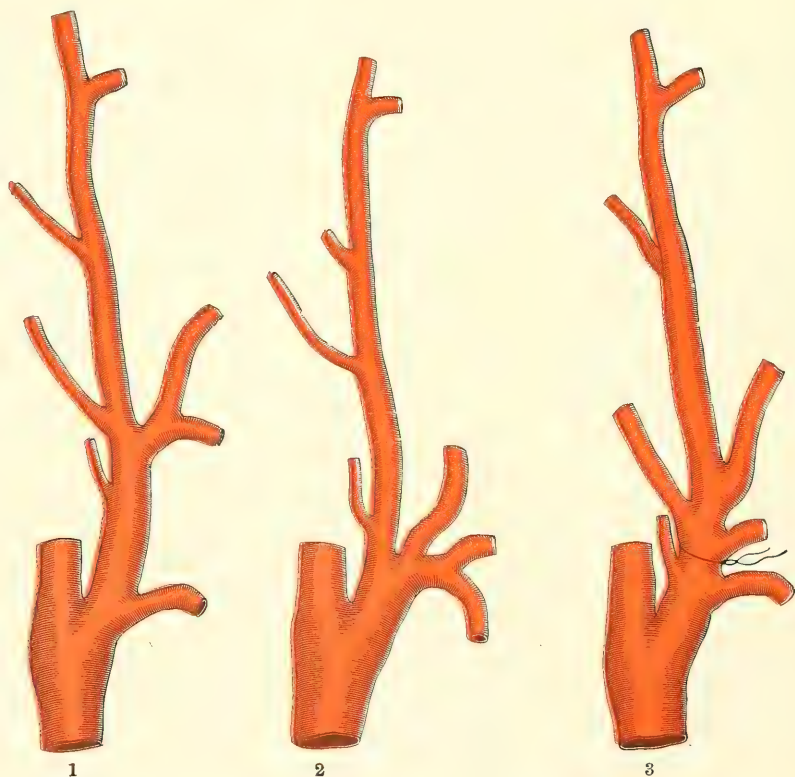


FIG. 287.—Unusual arrangement of the branches of the external carotid. 1, The lingual and facial from a common origin. 2, The lingual and facial superior thyroid from a common origin. 3, Close relation of first five branches to each other.

this vessel, and that the history of the cases in which it has been tied shows a rate of mortality far below that of ligature of the *common carotid*, yet the proximity of large and important branches to each other, or to the bifurcation of the *common carotid* in many instances, makes it of the utmost importance that the surgeon should proceed with great care and discretion. The wound should be thoroughly cleansed, and the vessel

examined with scrupulous care above and below the ligature, and any collateral branch or branches within less than one quarter of an inch should be also secured.

Should the artery be found to be normal (as in Fig. 286), I would place the ligature nearer the *lingualis* than the bifurcation, and tie this vessel separately. If (as in Fig. 287, 3) a rare form should exist, I would ligature close to these branches, and tie each of them in its turn. This same conservative rule must apply to every case.

The operation at or above the posterior belly of the digastric is comparatively safer, and is applicable to all lesions above this point. The incision should extend from the lobule of the ear along the ramus of the jaw, down to the level of the thyroid cartilage. Cutting through the superficial structures, the artery will be found just behind the posterior belly of the digastric muscle.

Above this level—that is, after the artery enters the parotid gland—it is so situated that it should not be cut down upon. The incision would involve the *facial nerve*, causing paralysis of the muscles of expression. In malignant disease of the parotid, where this gland is removed, the vessel may as well be secured here as not, since the operation itself usually destroys the *facial nerve*.

It is a remarkable fact that, notwithstanding the close proximity of the branches of the *carotid*, in a number of instances in which it has been ligatured without the precaution of securing immediate collateral branches, there has not followed secondary hæmorrhage. No explanation of this fact has appeared so definite as the one given by Prof. H. B. Sands, “which takes into account the remarkable reparative power of the tissues surrounding this vessel. Suppuration is extremely rare, the wounded tissues soon become consolidated by plastic material, and secondary hæmorrhage is prevented by changes occurring *outside of*, as much as by changes taking place *within*, the vessel ligatured.”

On account of the importance of maintaining the integrity of the circulation to the brain, ligation of the common carotid, for a lesion in the distribution of the external carotid, should never be performed when a sufficient distance remains between the lesion and the bifurcation of the common trunk to allow of the application of the ligature. I have the histories of ninety-three cases of ligation of the external carotid, in sixty-nine of which this vessel alone was tied. Of these sixty-nine cases only three died, while

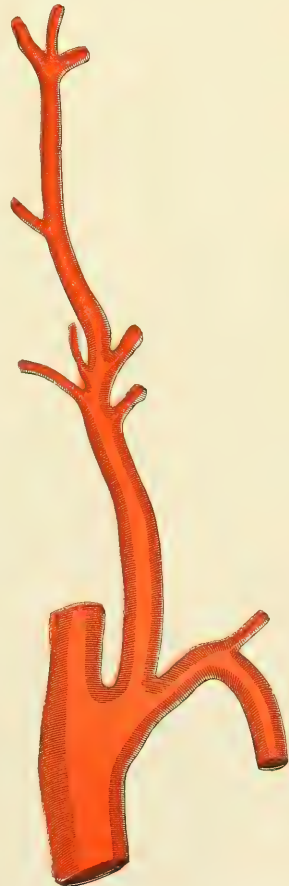


FIG. 288.—An enlarged superior thyroid artery.

the death-rate after ligation of the common trunk, for the same period, was 41 per cent.

Ligation of the Superior Thyroid Artery—Anatomy.—This branch was present in every instance in one hundred and twenty-one dissections. It originated almost invariably on a level with the thyroid notch. In one of twenty-five cases it will be found to have a common origin with the lingual, or the lingual and facial. See Fig. 287, 1, 2.

Operation.—With the neck in the surgical position, i. e., with the head thrown back and the face turned to the opposite side, make an incision two inches long, parallel with, and one fourth of an inch in front of, the *carotid line*. The center of this incision must be on a level with the thyroid notch. Immediately beneath the skin and *platysma myoides* will be seen the *thyroid, lingual, hyoid*, and other veins, which may assume either of the forms or relations shown in Fig. 285, A, B, being most common. These being tied and divided, the artery will be found opposite the point above indicated.

The thyro-hyoid nerve will occasionally be seen passing across this artery, although usually nearer the median line. The external laryngeal passes beneath it.

Ligation of the Lingual Artery—Anatomy.—From its origin, usually opposite the cornu of the hyoid bone, it ascends obliquely upward and inward, and is superficial until it passes underneath the *stylo-hyoideus* and *digastricus* (posterior belly), and then more deeply behind the *hyo-glossus*.

In two of one hundred and twenty-one cases it originated in common with the superior thyroid, and in two other instances with this vessel and the facial. In thirty-one of one hundred and twenty-one cases it arose from a trunk common to it and the facial, being abnormally associated in one in every three and a half dissections.

Operation.—The *lingual* artery may be secured either below the digastric or above this point, where it passes beneath the *hyo-glossus*.

For the low operation make an incision as in the case of the *superior thyroid*, except that its center should be *opposite the os hyoides*. The artery will be found in the *lingual triangle*, bounded posteriorly by the *external carotid*, above by the *digastric* muscle, below by the *os hyoides*. The *middle constrictor* muscle is behind it; the *platysma myoides* in front, and under this the veins above noted. The hypoglossal nerve is usually *just above* it as it crosses the *carotid*, while the *thyro-hyoid* branch of this nerve crosses the artery on its way to the muscle it supplies.

The high operation is one of considerable difficulty. The face should be well turned to the opposite side, the chin elevated, and held perfectly immovable. Beginning immediately over the *os hyoides*, near the median line of the neck, an incision is made outward, and parallel with this bone as far as the great cornu, where it is curved upward to the angle of the jaw (Fig. 289). This crescentic flap is turned up, and with it the sub-maxillary gland, in a groove on the under surface of which

the facial artery runs. As soon as the hyoid bone is exposed it should be fixed with a tenaculum and drawn steadily down. The posterior

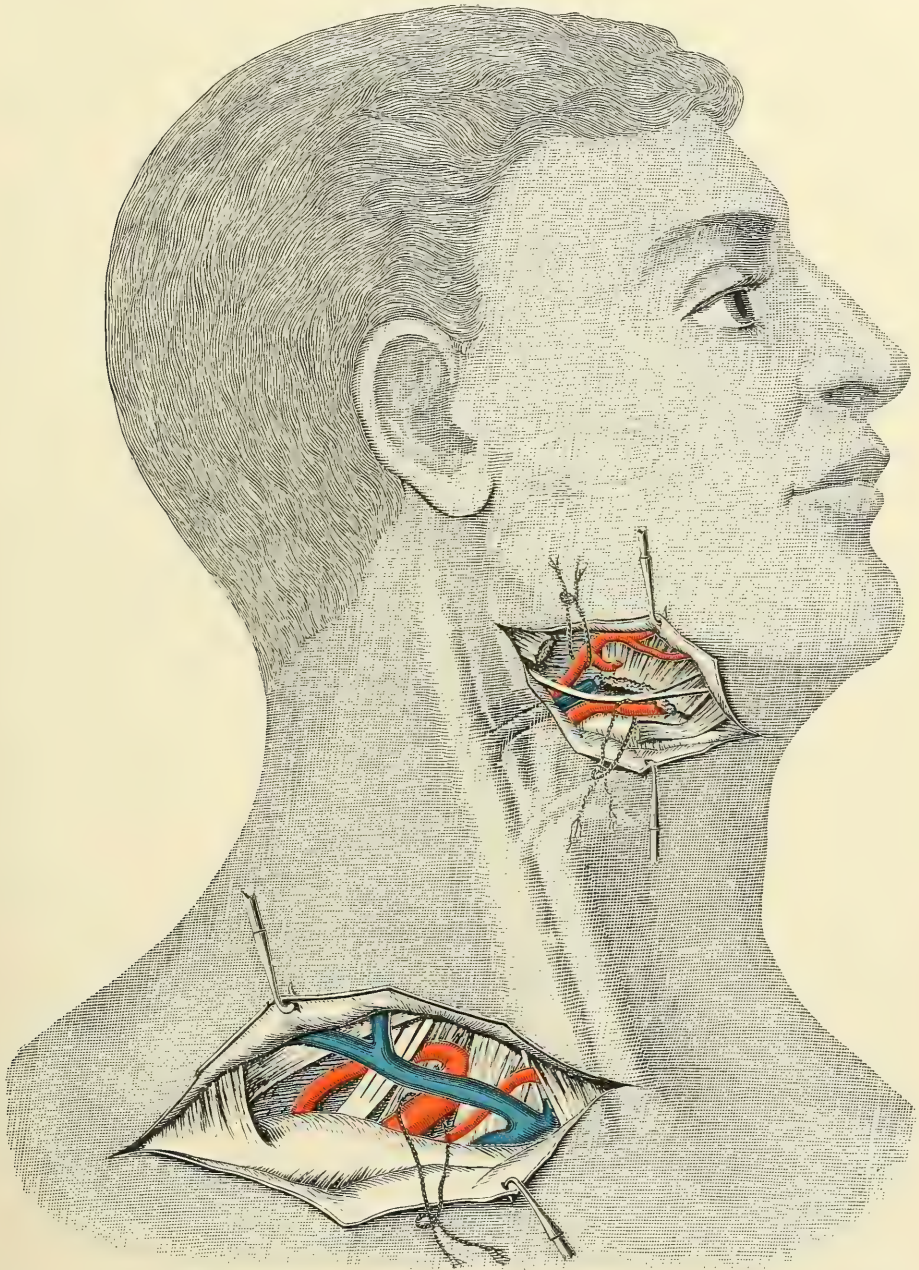


FIG. 289.—Ligation of the right subclavian in its third surgical division; the facial in the neck and the lingual beneath the hyo-glossus muscle.

belly of the digastric will now be seen passing obliquely downward and forward to the central tendon in the hyoid bone. Passing beneath this muscle, and superficial to the hyo-glossus, is seen the hypoglos-

sal nerve, which runs parallel with and above the artery. Depress the posterior belly of the digastric, insert a director beneath the posterior fibers of the hyo-glossus, and divide these. The artery will be found just beneath this muscle, resting upon the middle constrictor of the pharynx.

The ligation of this artery is frequently practiced preliminary to excision of the tongue for malignant disease, and occasionally to arrest hæmorrhage.

Ligation of the Facial Artery—Anatomy.—The facial artery was present in one hundred and twenty of one hundred and twenty-one dissections. In the instance in which it was missing its facial distribution was taken by the *transverse facial* from the *temporal*, and its cervical by branches from the *lingual* and the *external carotid*. Its origin is usually about one fourth of an inch above the *lingual*. It is the longest branch of the *external carotid*. In thirty-one of one hundred and twenty cases it arose in common with the *lingual*, and in two instances it was from a trunk in common with this artery and the *superior thyroid*.

Operation.—In its cervical distribution this vessel will require to be tied at or near its origin from the *carotid*. The incision along the axis of the *carotid*, as given before, with its center a quarter of an inch above the hyoid bone, will lead to the facial. The posterior belly of the *digastricus* will be found with its center usually above the origin, but soon crossing the artery. The ninth nerve is just below. For lesion of this vessel in the face it can be readily secured as it crosses the *inferior maxilla* in the depression at the anterior border of the *masseter* (Fig. 290). Before making the incision, which should be parallel with the horizontal portion of the inferior maxilla, the skin should be well pulled up from the neck, so that, after-healing, the cicatrix will fall below the jaw.

Ligation of the Ascending Pharyngeal—Anatomy.—This artery was derived from the *external carotid* in one hundred and eleven of one hundred and twenty-one cases, and from the *internal carotid* in four others. It usually comes off at a point opposite the origin of the *lingual*, and occasionally from the bifurcation of the *primitive carotid*. A pharyngeal branch is not uncommon from the occipital.

Operation.—The *external carotid* must be exposed by an incision the center of which is opposite the level of the hyoid bone. The vessel will be seen ascending between, and parallel with, the *external* and *internal carotids*.

One fatal case is recorded from hæmorrhage after a wound of the *ascending pharyngeal*.

Ligation of the Occipital Artery—Anatomy.—The *occipital* was present in one hundred and twenty of one hundred and twenty-one dissections, and it was found to be opposite the facial in the majority of cases. In the subject in which it was missing, a large branch from the *inferior thyroid* (not the *ascending cervical*) took its distribution. Not

infrequently the *posterior auricular* or a *pharyngeal* branch arose from this vessel.

Operation.—It may be secured near its origin, or behind the mastoid process. For the low operation, make an incision in the *carotid line*, the center of which is about one inch above the thyroid notch. After divid-

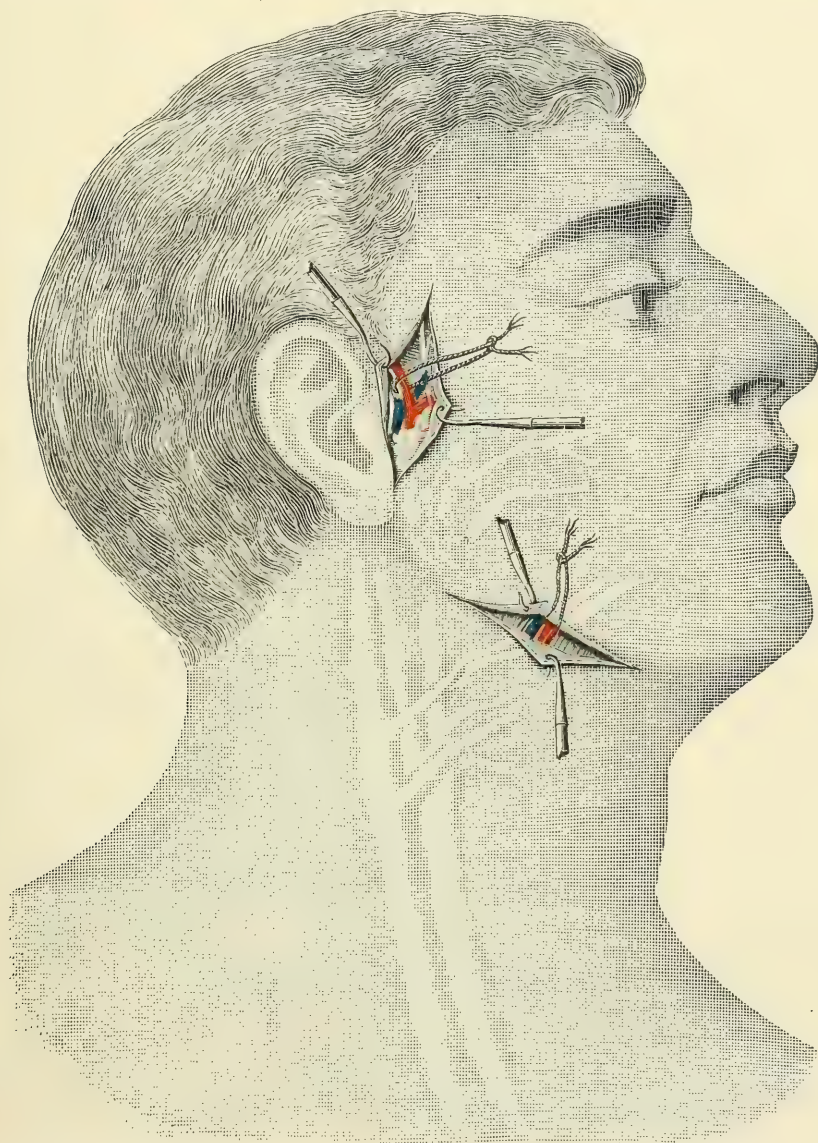


FIG. 290.—Ligation of the posterior temporal at the zygoma, and of the facial upon the inferior maxilla.

ing the deep fascia the hypoglossal nerve will be seen, which, if followed backward, will lead unerringly to the artery, underneath which it winds. The posterior belly of the digastric muscle will usually require to be lifted upward.

Behind the mastoid the occipital may be tied where it passes beneath

the cranial attachment of the sterno-mastoid muscle (Fig. 291). From one half to three fourths of an inch behind the mastoid process an incision about two inches long should be made, extending upward and backward. The aponeurosis of the sterno-mastoid muscle is divided on a director, and the artery exposed. The constant relation of this vessel

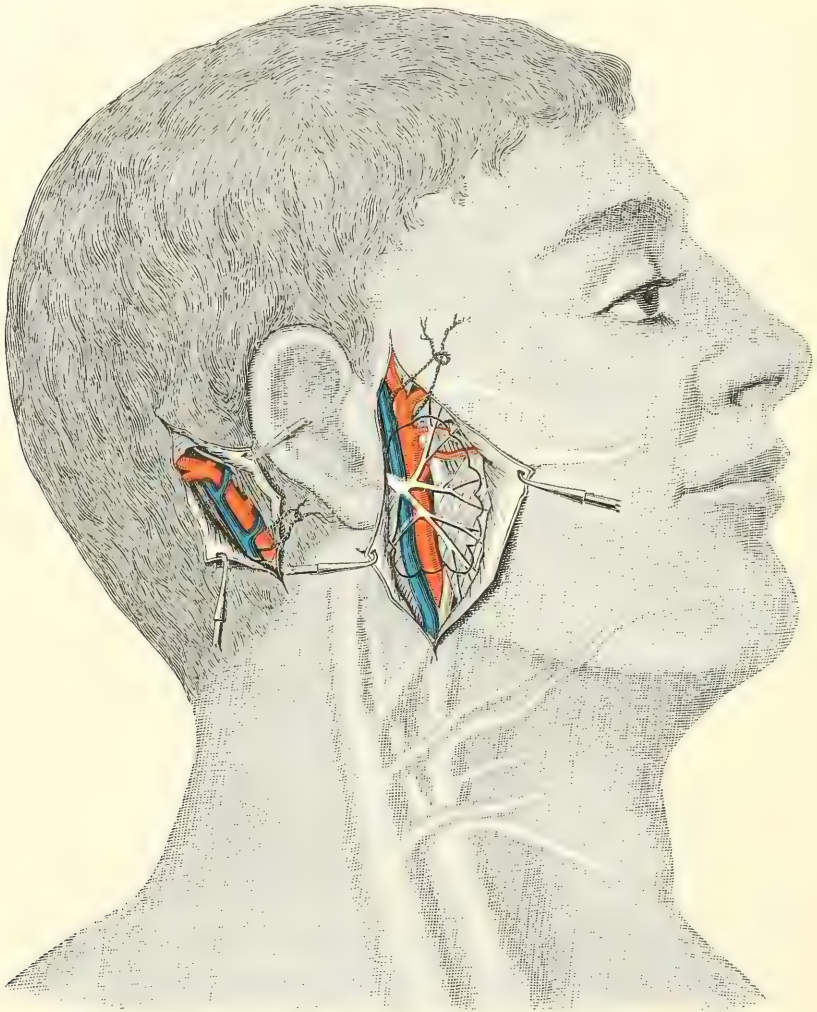


FIG. 291.—Ligation of the occipital behind the mastoid process and the common temporal near the zygoma, also showing the relations of the facial nerve to the terminal portion of the external carotid.

to the groove on the under surface of the mastoid process will serve as a valuable guide.

The *common carotid* has been tied in several instances for lesions of the *occipital*. This should never be done.

Ligation of the Posterior Auricular—Anatomy.—In eleven of one hundred and twenty-one dissections this vessel arose from the *occipital*, and in four it was absent. Its origin is usually one inch and four fifths above the thyroid notch.

For anatomical reasons, in lesions of this artery the *external carotid* should be tied, just above the posterior belly of the digastric, between its origin and that of the *occipital*. It runs under the parotid gland, is crossed by the facial nerve, and has beneath it the spinal accessory.

Ligation of the Temporal and Internal Maxillary Arteries—Anatomy.—The *temporal* and *internal maxillary* arteries begin at the terminal bifurcation of the *external carotid*, in the substance of the parotid gland, at an average distance of two inches and nine tenths from the thyroid notch.

Operation.—The *temporal* artery may be secured by a perpendicular incision immediately in front of the tragus of the ear, where it crosses the zygoma superficially (Fig. 291). For lesions of this vessel above the temporal fossa, and often in wounds in this region, the ligature will be unnecessary, since direct compression, by means of the knotted bandage, will suffice. When either this artery or the *internal maxillary* are wounded in the substance of the parotid gland, the *external carotid* should be tied at the posterior belly of the digastric. The same procedure is indicated in lesions of the *internal maxillary*, in its deeper portions.

Ligation of the Internal Jugular Vein.—The intimate relation of this vein to the *internal* and *common carotid* arteries renders it accessible by the same incisions laid down for the ligation of the arteries. The vein is contiguous to the artery, and is external and slightly superficial to it. On the left side, at the root of the neck, the jugular comes more to the front, while on the right side it tends to the outer side.

The rules which apply to the ligation of arteries apply with equal force to the ligation of veins. The jugulars should be encircled with an animal ligature, not tied with a lateral loop, as has been practiced. The aneurism-needle should be passed from the inner side.*

The anterior, external, and posterior jugular, and other veins of the neck, do not demand especial consideration. When, in operations in the neck, it becomes necessary to divide them, a double catgut should be applied, and the vessel divided between the two ligatures.

The Subclavian Arteries and their Branches—Anatomy.—The *right subclavian*, larger, shorter, and more superficial at its origin than the left, is derived from the *innominate behind* the origin of the carotid, about the level of the upper margin of the clavicle (more frequently above than below this line), behind the interval between the two tendons of the *sterno-mastoideus*. It is the direct continuation backward, upward, and outward of the *arch of the innominate*, and is continuous with the *axillary artery*, at the lower edge of the first rib. Its average length is 2·83 inches.

The *left subclavian*, derived 1·23 inch beyond, to the left of, and more deeply situated in the thorax than, the *innominate*, travels almost verti-

* See Prof. S. W. Gross's admirable article in "American Journal of the Medical Sciences," 1867.

cally upward, until it mounts above the upper surface of the first rib, when it curves very abruptly outward and downward, passing behind the scalenus anticus and thence to the lower edge of the first rib. Its length, in the average, is 3·74 inches.

Each subclavian has three *surgical divisions*. The *first division* of the right artery is from its origin from the *innominate* to the inner bor-

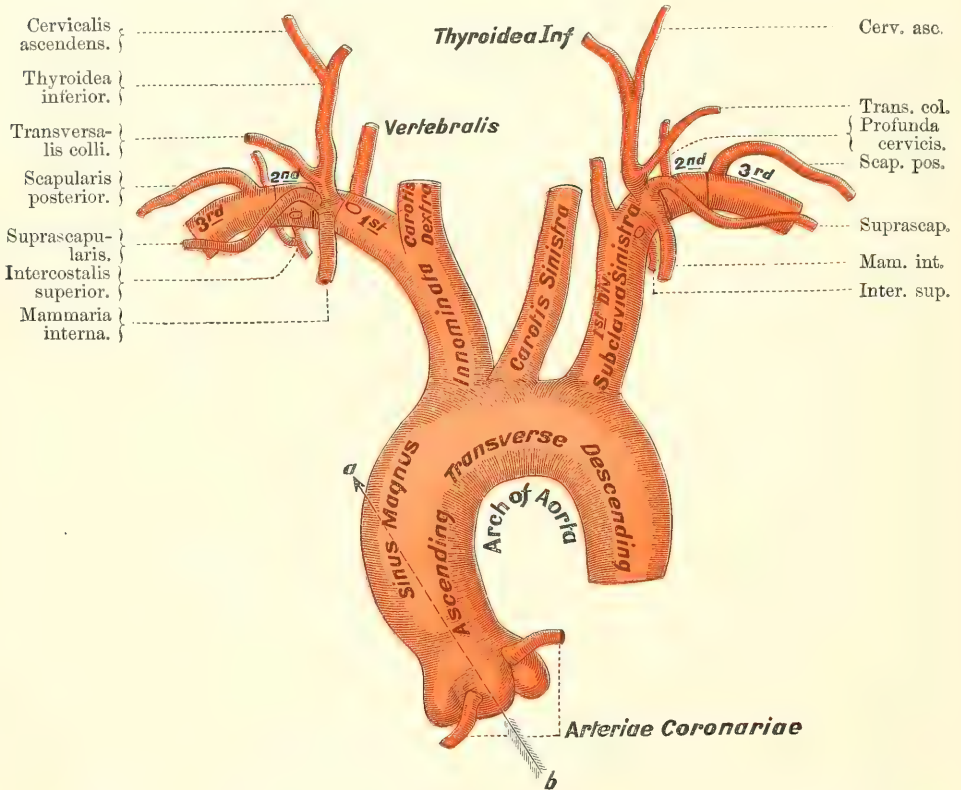


FIG. 292.—Relation of the great vessels to each other at their origins from the arch of the aorta, and the relation of the branches of the subclavian arteries to each other. From the author's dissections.

der of the *scalenus anticus*. That of the left artery, from its origin at the arch of the aorta to the inner border of the *left scalenus anticus* (Fig. 292).

The second and third portions of both vessels are identical as regards direction and relation, being different in the origins of their respective branches. The *second surgical division* of each is entirely to the *inner side of the inner border* of the first rib. The *third portion* rests chiefly on the upper surface of the first rib, and extends from the outer border of the scalenus anticus to the lower border of this rib.

The *first portion* of the *right subclavian* varies from three fourths to one inch and a half in length, the average length being 1·15 inch.

The *first portion* of the *left artery* varies from one inch and a half to three inches, the average length being 2·06 inches.

The *second portion* of the *right subclavian* averaged $\cdot 58$ inch, the same division of the *left subclavian* being $\cdot 56$ inch in length.

The *third portion* of the *right artery* is a little less; the same division of the *left subclavian* a little more than $1\cdot 11$ inch in length.

Nine important branches arise directly or indirectly from the *subclavian* arteries: the *vertebral*, *internal mammary*, *transversalis colli*, *suprascapular*, *inferior thyroid*, *cervicalis ascendens*, *superior intercostal*, *profunda cervicis*, and *posterior scapular*.

The *right vertebral*, the branch most constant in origin, arises from the superior and posterior aspect of the main trunk (Fig. 293) and passes upward to the vertebral foramen, in the sixth cervical vertebra; at times to the fifth; less frequently to the fourth. The relation of this branch is important. In the vast majority of subjects it will be found between one fourth and three fourths of an inch to the inner side of the inner margin of the scalenus anticus.

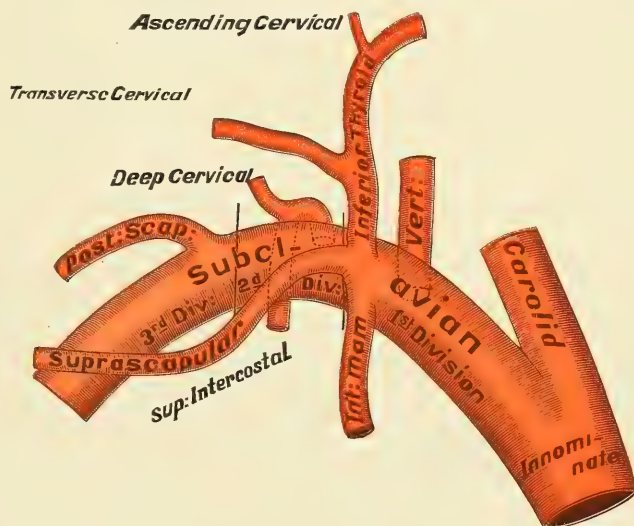


FIG. 293.—Plan of the right subclavian artery and its branches. From the author's dissections. (After Quain.)

The *left vertebral* (Fig. 292) arises, in 4 per cent of cases, from the aorta. In most subjects it will be found within three fourths of an inch of the left scalenus muscle.

The *internal mammary* artery arises at the inner border of the scalenus anticus. It is occasionally from the thyroid axis. The phrenic nerve passes usually in front, occasionally behind it. Behind the costal cartilages it runs parallel with the edge of the sternum, about half an inch external to it.

The *thyroid axis* arises also just within the scalenus. The *inferior thyroid* branch arises from the axis, in almost every case on the left side. On the right, in twenty-six cases examined, it originated from the *innominate* in three, and directly from the subclavian in three instances. It passes upward (inclining at first a little inward) until it arrives at a point between the third and seventh (incomplete) rings of the trachea, where it turns abruptly inward, going behind the *common carotid* and *jugular*, in front of the *vertebral*, and is distributed chiefly to the lower portion of the thyroid body.

The *transversalis colli* passes outward in front of the *scalenus muscle* and the *phrenic nerve*, underneath the *omo-hyoid*, and in front of or

between the cords of the brachial plexus, and is distributed to the *trapezius* muscle, sending a branch in the direction of the posterior border of the scapula, which anastomoses with the *posterior scapular* artery; and, when this last vessel is not present, this descending branch is continued along the border of the scapula to anastomose with the subscapular branch of the axillary.

The *suprascapular artery*, intimately associated with the preceding, travels suddenly downward and outward from its origin near the inner edge of the *scalenus anticus*, passes between the *subclavian artery* and *vein*, in front of the *phrenic nerve*, crosses in front of the third division of the main trunk, and goes to the suprascapular fossa under the protection of the clavicle, anastomosing with the *dorsalis scapulae* of the *subscapularis*. It gives off a branch (frequently wounded in operations in this vicinity) which passes behind the *sterno-mastoideus* and along the upper border of the manubrium. (It is not usually mentioned.)

The right *superior intercostal* artery comes from the second division of the subclavian in almost every instance; occasionally from the first. The left is usually from the first division.

The *posterior scapular*, one of the most important branches of the subclavian, in a surgical view, since it must be in dangerous proximity to a ligature applied in the third surgical division (not given in many standard text-books, except as an occasional branch of this artery), was present in thirty-six of fifty-two dissections, or 69 per cent. It was present in nineteen of twenty-six on the *right* side, and in seventeen of twenty-six on the left. In twenty-three of the thirty-six cases in which it was present it was derived from the third division; in the remaining thirteen, from the second division, close to its outer limit. On the *right* side 74 per cent came from the subclavian, within one fourth of an inch to the outer and inner side of the external border of the *scalenus* muscle; 26 per cent external to this.

On the *left* side 82 per cent were within one fourth of an inch to the outer and inner side of the line dividing the middle and external thirds of the main trunk; 18 per cent were to the outer side of this. The tendency of this important branch is to originate near the *scalenus*, i. e., within one fourth of an inch of its outer edge. When this vessel is present the *transversalis colli* is small, and when absent the descending branch of the *transversalis* takes its distribution. Passing outward behind the most superficial cords of the brachial plexus, it turns sharply downward, along the posterior border of the scapula, to anastomose with the *subscapular* branch of the *axillary*.

Operation—The Right Subclavian in its First Surgical Division.—The incisions are the same as for the *arteria-innominata* (Fig. 279). When the sterno-hyoid and sterno-thyroid muscles have been divided on the director, the *internal jugular vein* will be seen directly in front of the artery. It may be drawn to the inner side (or outer, if more convenient), carefully using for this purpose a dull retractor. Care must be exercised not to injure the pleura which rises against the

artery in deep inspiration. A dull-pointed aneurism-needle may now be passed around the vessel, taking care not to wound the subclavian or innominate vein, or the recurrent laryngeal nerve. The *vertebral*, *internal mammary*, and branches of the *thyroid axis*, should also be secured.

The conditions which will justify this operation will rarely occur, yet, when the operation is demanded, every source of danger from hæmorrhage should be avoided. The necessity of securing the carotid at the same operation must be determined by the operator. I am of the opinion that it is safer to occlude this vessel also.

The *subclavian* artery has been tied in its first surgical division eighteen times, and all fatal. In five of these cases the common carotid was also tied. In only one case was the left subclavian tied. Of the thirteen single operations, two (Ayres and Bullen) were for the arrest of hæmorrhage from shot wounds in military practice, with one death in half an hour and one on the eighth day, from hæmorrhage. The other eleven cases are given on page 225. In only five of these thirteen cases is the source of hæmorrhage stated, and in each of these the bleeding was from the *distal* side of the ligature, the proximal side being closed.* A knowledge of this fact leads me to insist upon the ligation of the vertebral and other branches of the first division.

In five instances the right carotid was also tied simultaneously by Liston, Parker, Hobart, Cruveilhier, and Kühl. In three of these, fatal hæmorrhage ensued from the distal side of the ligature.

The left *subclavian* artery was tied in its first division once by Rodgers, and fatal hæmorrhage occurred from the *distal* end of the artery.

Ligation of the Left Subclavian Artery in its First Surgical Division—Operation.—From a point on the clavicle one fourth the distance from the center of the interclavicular notch to the acromion process commence an incision, and carry it to the inner border of the sternal tendon of the mastoid muscle. From the inner extremity of this line carry a second incision for three inches along the anterior border of the sternomastoideus. In dissecting this flap lift with it the mastoid muscle divided upon the director, then divide the sterno-hyoid and thyroid muscles, and feel for the pulsation of the artery, which ascends deeply behind and a little outside the sterno-clavicular articulation. The *internal jugular* vein will be drawn outward, and, passing the finger along the inner border of the *scalenus* muscle, the artery will be felt to pulsate (Fig. 281). The *thoracic duct* usually is to the right of and a little behind the artery opposite the upper border of the *sternum*. On a level with the insertion of the *scalenus* it arches to the left, crosses in front of the *subclavian*, in front of the *scalenus*, behind the *internal jugular*, and curves downward to empty into the *subclavian* at its junction with the *jugular* to form the left *innominate* vein. On account of the intimate relations of the *thoracic duct* to the left *subclavian* artery as this vessel goes behind

* The author's "Essays," William Wood & Co., 1878.

the *scalenus*, the ligature should not be attempted close to this muscle, nor should the dissection be carried fully to the *scalenus*. The artery should be tied as low down as possible, the *duct* being less likely to be injured here, since in passing behind the aorta it is deeper than the artery. It will be found behind and to the right, the pneumogastric in front and to the right, the left *vena innominata* crossing in front, while the pleura is directly behind.

The *vertebral* and other branches of the left subclavian are in such proximity to the thoracic duct that it will be dangerous to attempt to tie them at this point.

Ligation of the Subclavian Arteries in their Second and Third Surgical Divisions—Operation.—The procedure is essentially the same on the two sides. Place the shoulders upon a cushion, pull downward on the arm of the side to be operated upon, and turn the patient's face to the opposite side. Find the location of the scalenus anticus, as in the preceding operation. Slide the skin well down upon the clavicle, and along this bone make an incision three or four inches in length, commencing one inch to the inner side of the scalenus muscle and terminating near the anterior edge of the trapezius. Allowing the skin to resume its normal relations, the incision will be carried above the clavicle. Upon a director divide the outermost of the clavicular fibers of the mastoid muscle. The internal *jugular vein*, seen in the anterior portion of the wound, will be carefully drawn to the inner side, the operator keeping well above the junction of this with the subclavian, and thus avoiding the *lymphatic duct*.

A prominent plexus or group of veins, viz., the *external jugular, transversalis colli*, and *suprascapular*, will be seen traversing the wound, coming from their respective origins, toward the *subclavian*, near the *jugular*. These should be secured with a double ligature, and divided, or held aside. Dissecting carefully, the *suprascapular* and *transversalis colli* arteries will be observed running, in general, in the direction of the first incision. The posterior belly of the *omo-hyoid* may be found in the upper margin of the wound, crossing the scalenus at about a right angle. The *transversalis colli* and the *suprascapular* may be secured or held to one side, the finger passed along the scalenus until the tubercle on the first rib is felt, immediately behind which the artery will be found. If it shall have been determined to tie the artery in its second portion, the *scalenus anticus* muscle will be cut upon a director, the operator being careful to avoid the *phrenic nerve*, which crosses the muscle in front, coming from above downward and inward. (It is between the layers of the sheath of this muscle.) The ligature is next passed around the artery from before backward, care being taken not to wound the pleura.

If the third division of the artery is to be secured, the part of the above operation relating to the division of the *scalenus* will be omitted. The nearest cord of the brachial plexus must be carefully excluded, posteriorly to the artery; the subclavian vein in front and below (Fig. 289).

The *subclavian arteries* have been tied behind the *scalenus anticus* thirteen times, with four recoveries. All of the fatal cases were on the right side.

In one of the "Prize Essays" of the American Medical Association I published the histories of two hundred and fifty-one ligations of the subclavian artery in its third surgical division, of which one hundred and thirty-four ended fatally. As far as these histories relate to aneurism they have been given. A study of the remaining cases led me to conclude that in all lesions causing dangerous hæmorrhage in the upper brachial or axillary regions an effort should be made to control the bleeding at the seat of injury. Failing in this, deligation of the subclavian, in its third division, is demanded.

Ligation of the Vertebral Artery—Operation.—Locate by pressure the carotid tubercle (the transverse process of the sixth cervical vertebra). The point at which the artery is to be secured is one inch directly below this bony prominence, which must be the center of a perpendicular incision, four inches in length. Commence the incision at the outer border of the sterno-mastoid muscle, where the external jugular vein crosses. The internal jugular is seen and drawn inward. The transverse cervical artery, and one or two smaller veins, are met with next, and drawn to the outer side of the wound. The *scalenus anticus* muscle is now brought into view, and to the inner side of this a depression between this muscle and the *longus colli*. In this sulcus the artery lies, the vein being in front of it. In my case I had to tie the vein with a double ligature, divide, and turn the ends aside in order to secure the artery.

Ligation of the Internal Mammary—Operation.—This vessel may be secured, as has been described, close to the parent trunk, or it may be tied in one of the intercostal spaces. In the third or fourth space make an incision, about two inches in length, obliquely from without inward and downward, the center of which should be about half an inch external to the edge of the sternum. Divide the fibers of the *pectoralis major* and the intercostal muscle, and clear away the tissues with a blunt-pointed instrument. The artery, with its *venæ comites*, will be seen in front of the fibers of the *triangularis sterni*, which separates it from the pleura on the right and the mediastinum on the left side. In separating the veins from the artery, care should be taken not to break through the thin structure between the vessel and the cavity.

The other branches of the *subclavian* artery do not require especial consideration. The *inferior thyroid* is often tied in the removal of goitre. I have, in six operations, found and deligated it prior to ablation of a bronchocele. It will usually be seen on the tracheal side of the *common carotid*, just below the anterior belly of the *omohyoid*.

Ligation of the Axillary Artery—Anatomy.—This artery may be tied at any part of its course. On account, however, of the difficulty of approach of that portion beneath the *pectoralis minor*, it is usually

secured in the axilla, below this point, or between the upper margin of this muscle and the lower border of the first rib.

Operation.—With the head thrown back and the shoulders elevated, allow the arm to remain by the side of the body. About two inches from the sternal end of the clavicle, and half an inch below its inferior border, carry an incision outward, parallel with this bone, a distance of from three to four inches. This incision may divide a superficial vein which passes from the cephalic over the clavicle. The clavicular fibers of the pectoralis major and the costo-coracoid membrane are divided upon the director. The axillary vein will then be seen in the anterior portion of the wound, lying in front of the artery, which may be felt to pulsate, or seen just external to it. More external still may be seen the anterior cord of the brachial plexus, while in the lower portion of the wound the cephalic vein crosses over to empty into the axillary, below the clavicle. Beneath the clavicle the subclavius muscle may be seen. The needle should be passed from before backward. If necessary, a second incision may be made, beginning in the center of the first and carried in the direction of the axilla, as recommended by Chamberlain.

This operation is somewhat more difficult than ligation of the *subclavian* in its third division, but it is preferable, on account of being farther removed from the heart. Delpech advised an incision beginning at the junction of the middle and outer third of the clavicle, and separating the deltoid and pectoralis muscles.

Operation below the Pectoralis Minor.—Shave and cleanse the axilla, and extend the arm at a right angle to the body. Divide the dis-

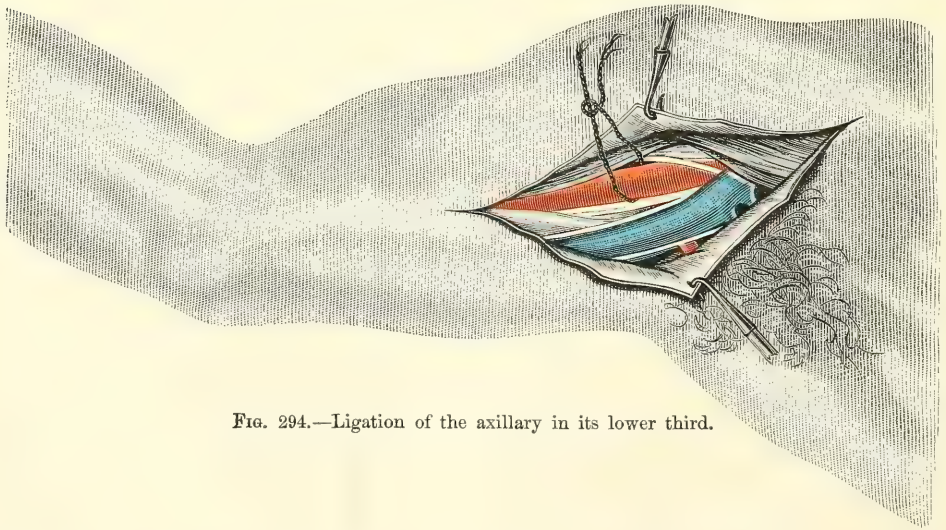


FIG. 294.—Ligation of the axillary in its lower third.

tance between the two folds of the axilla into thirds, and the junction of the anterior and middle thirds will indicate the position of the artery. On this line make an incision in the axis of the arm, well up into the axilla. Cutting through the skin and fasciæ, the contents of this space will

be seen. The vein lies internal to the artery, often overlapping it, and should be drawn carefully backward. The median nerve overlies the artery, or is on its anterior aspect, and should be drawn forward when the needle is passed from behind forward (Fig. 294).

Ligation of the Brachial Artery
—Anatomy.—This artery lies in the furrow along the inner border of the coraco-brachialis and biceps muscles, tending more and more to the front as it nears the elbow-joint. In the lower half or three fourths of its course it has its venæ comites on either side, with occasional communications across the track of the artery. The median nerve crosses it by the front, from the outer side, on its way to the forearm, while the basilic vein is well to the inner side. As this vein passes up toward the axilla it pierces the deep fascia, and lies on the inner side and close to the artery, joining with the venæ comites to form a single large trunk.

Operation.—A line drawn from the junction of the middle and anterior thirds of the axillary space (as above given) to the middle of the elbow-joint, in front, will pass over the brachial artery in its entire length. The place of election is the middle of the arm. At this point make an incision, three inches in length, over the artery and in its axis. Dividing the skin and deep fascia, the white cord of the median nerve will be first seen, on the outer side of the brachial, overlapping the companion vein on this side. Just internal to this is the artery, with the other accompanying vein and the basilic in close relation (Fig. 295). The ligature should be passed from the inner toward the outer side. The op-



FIG. 295.—Ligation of the brachial near the middle and the lower third.

eration above this point is essentially the same. In the lower third of the arm proceed as follows: On a level with the condyles of the humerus, and between the median basilic vein and the tendon of the biceps, commence an incision, which is carried upward three inches in the brachial line. Cutting through the deep fascia, the artery is readily found to the radial side of the median nerve, and surrounded by its veins (Fig. 297). The needle is passed from the inner side. Occasionally the brachial artery is double, while more frequently it bifurcates into the radial and ulnar, at a varying distance above the elbow.

Ligation of the Ulnar and Radial Arteries.—The *radial* artery may be tied immediately above the wrist, or in the upper third of the arm.

Operation at the Wrist.—A vertical incision, one inch and a half long, is made in the center of the depression, between the outer border of the radius and the radial border of the extensor carpi radialis muscle. Immediately beneath the deep fascia the artery will be observed, with its *venæ comites*, from which it is separated and tied (Fig. 296).

To find the artery in the upper third, draw a line from the middle of the elbow-joint, in front, to the styloid process of the radius. Along this line make an incision, about three inches in length, avoiding the superficial veins, if possible. Cutting directly down, the artery will be found between the supinator longus externally and the pronator radii teres on the ulnar side. The radial nerve is well to the radial side, and the *venæ comites* on either side (Fig. 297).

The *ulnar* artery may be tied at the bend of the elbow, and near the wrist. As it passes beneath the pronator radii teres and flexor muscles, it is so deeply situated that an attempt to deligate it here is not justifiable. Above this point it may be secured by a downward extension of the incision given for ligation of the brachial at the bend of the elbow (Fig. 297).

Near the wrist-joint an incision should be made about a quarter of an inch to the radial side of the tendon of the flexor carpi ulnaris muscle. This incision should commence one inch above the level of the pisiform bone, and extend upward one inch. The ulnar nerve will be seen partly concealed by the tendon, while the artery and its accompanying veins are immediately on its radial side (Fig. 296).

Ligation of the Intercostal Arteries—Anatomy.—The artery lies behind and near the lower border of the rib, the vein above, and the nerve below it. From near the angle of the rib to the vertebral column it is separated from the thoracic cavity by the pleura alone, but in front of this it runs between the two layers of intercostal muscles.

Operation.—An incision should be made just along the lower border of the rib. After passing through the outer plane of intercostal muscles the artery may be seen and secured. Or, failing in this, take a long, curved aneurism-needle, and through a puncture near the lower border of the rib pass it behind the artery and around the

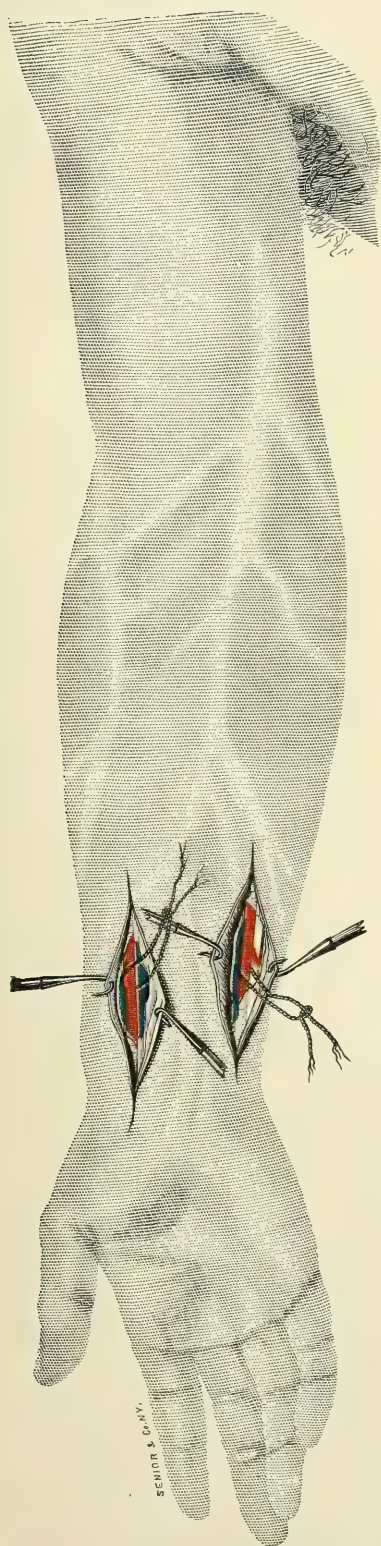


FIG. 296.—Ligation of the ulnar and radial arteries of the wrist.

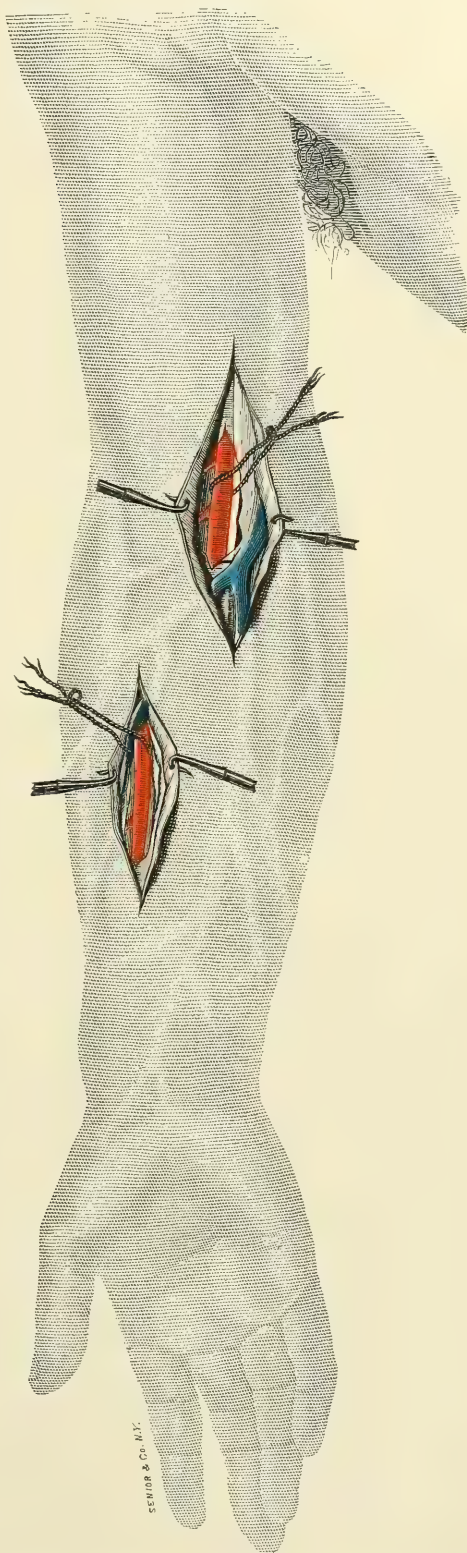


FIG. 297.—Ligation of the radial in the middle of the forearm and of the brachial at the bend of the elbow

rib, taking care not to puncture the pleura. When the point of the needle is felt at the upper margin of the bone, another puncture is made to allow its escape. The needle is now armed with a strong cat-gut and withdrawn. A pellet of sublimate gauze is laid over the skin, between the points of exit and entrance, around which the ligature is tied. In exceptional cases it may be necessary to remove a portion of the rib.

Ligation of the Abdominal Aorta—Anatomy.—The aorta usually bifurcates upon the body of the fourth lumbar vertebra, a little to the left of the median line. This point is on a level with the highest point of the iliac crests, and is a little to the left of and below the umbilicus. The point of election is one inch above the bifurcation.

Operation, Median.—In the *linea alba* make an incision, six inches long, the center of which corresponds to the umbilicus. When within an inch of the navel, curve to the left three fourths of an inch, and one inch farther on regain the middle line. Divide all the tissues down to the parietal peritonæum, and then arrest all bleeding before opening this. After opening into the cavity, the transverse colon should be displaced upward, and the small intestines brought out through the wound and secured in a soft rubber cloth, kept warm with sublimate towels. With the finger-nail or a blunt director scratch through the peritonæum and expose the aorta, around which a large animal (or silk) ligature should be passed from the right side.

Lateral Incision.—From the free end of the left eleventh rib commence an incision, which carry downward to within three fourths of an inch of the anterior superior iliac spine, thence parallel with Poupart's ligament to its middle. Divide the three abdominal muscles down to the parietal peritonæum. When this is reached, use the fingers, the nails of which have been closely pared, and lift the peritonæum from the posterior abdominal wall. Passing over the posterior iliac crests and into the iliac fossa, the ridge formed by the *psœ* muscles is reached and must be crossed. The lumbar nerves and ureter should be avoided, and, by a free dilatation of the wound and concentration of light, the aorta may be seen and tied, about three inches above the lumbo-sacral junction. Of these two procedures the former is anatomically and surgically preferable.*

Ligation of the Common Iliac Artery—Anatomy.—The common iliac arteries extend from the left side of the body of the fourth lumbar to the sacro-lumbar junction. It is crossed by the ureter in front, near its bifurcation, and by some filaments of the sympathetic nerve higher up. The left common iliac vein lies wholly internal, and is on a plane somewhat deeper than the artery. The inferior mesenteric vein crosses the left artery, but is within the peritoneal folds. The right iliac artery crosses in front of both the iliac veins, passing at a right angle to the left vein and obliquely over the right, until

* The abdominal aorta has been tied ten times, all fatal.

near its termination the artery is in front of and external to the vein (Fig. 298).

Operation—Anterior Incision.—Make an incision in the linea alba extending from about one inch above to about five inches below the umbilicus. Avoid the umbilicus as directed in the ligation of the aorta. Arrest all bleeding before the parietal peritonæum is opened. When this is done, draw the small intestines out through the wound and protect them in a




FIG. 298.—Dissection showing the relation of the right common external and internal iliac arteries and veins. The ureter is seen crossing the iliac near the bifurcation.

soft, clean rubber cloth, kept warm by sublimate towels. The posterior wall of the peritonæum is scratched through by means of two dissecting-forceps and the aneurism-needle passed from within out.

Lateral Incision.—Same as for the aorta.* The anterior incision is preferable.

Ligation of the Internal and External Iliac Arteries—Anatomy.—The *internal iliac* artery, less than two inches in length, has the ureter in front, its accompanying vein and the lumbo-sacral nerve behind.

Operation.—Through the Peritonæum.—Proceed as in the same operation for the primitive iliac. If necessary, a transverse incision may be added to that in the linea alba.

Behind the Peritonæum.—One inch and a half internal to the anterior superior spine of the ilium begin an incision, which travels downward and inward across the track of the external iliac. Be careful not to carry the deep incision far enough internally to divide the epigastric artery. Cut down to the parietal peritonæum, and separate this from its attach-

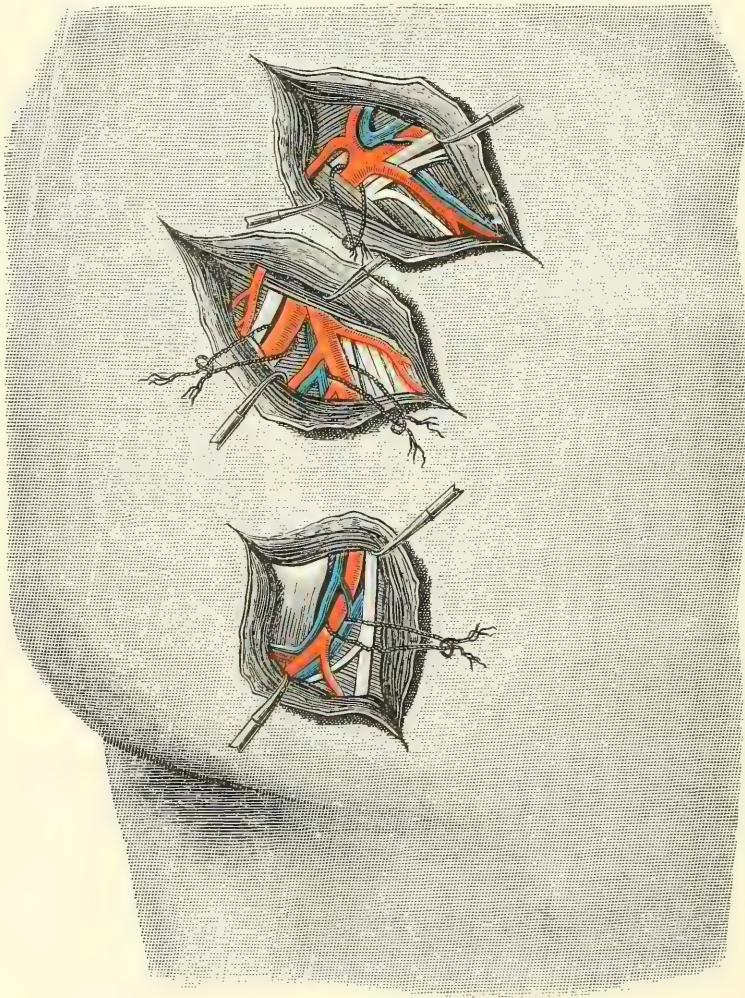


FIG. 299.—Ligation of the gluteal, internal pudic, and sciatic arteries.

* This artery has been tied about seventy times. For aneurism about 33 per cent recovered, while for hæmorrhage almost every case ended fatally.

ment to the abdominal wall and iliac fossa, along the iliac artery. When the bifurcation is reached, draw firmly with a retractor upon the upper lip of the wound and pass the needle from the inner side.* This operation may be demanded in sciatic or gluteal aneurism, or hæmorrhage from these vessels. The former method is preferable.

The Gluteal Artery.—Make a five-inch incision, on a line extending from the spine of the last lumbar vertebra to the trochanter major. The center of this line will indicate the point at which the artery emerges. Separate with a dull instrument the fibers of the gluteus maximus, displace anteriorly the gluteus medius, and find the groove between the minimus and the pyriformis. Follow this groove upward to the bony edge of the notch, and the artery and veins will be found (Fig. 299, upper incision).

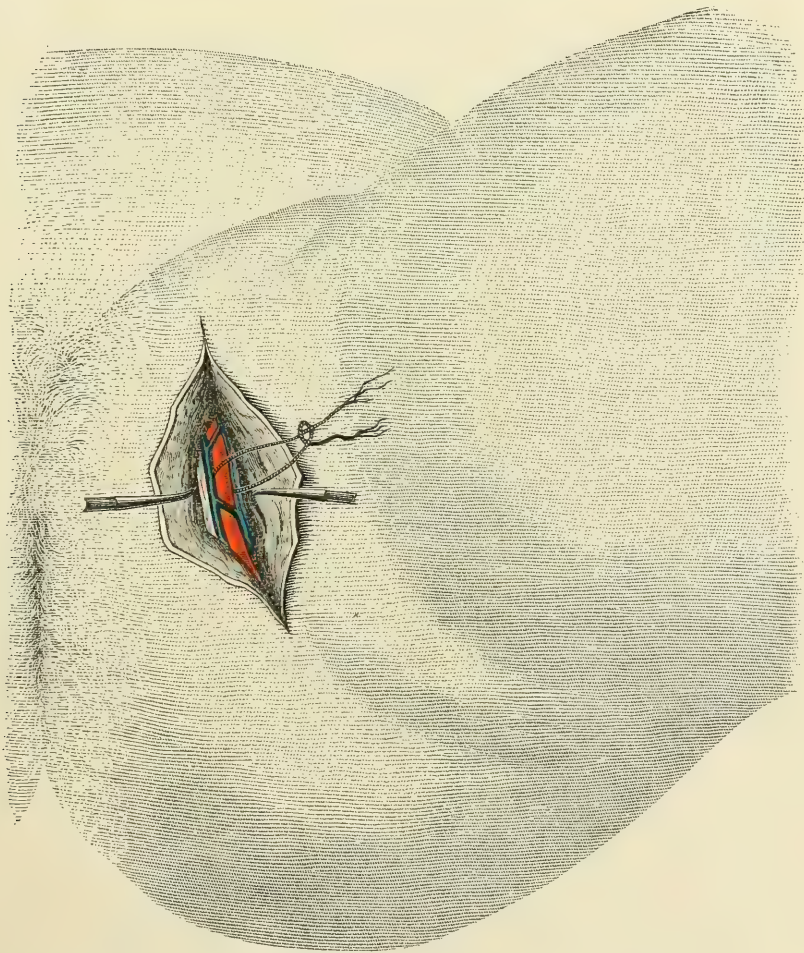


FIG. 300.—Ligation of the internal pudic in the perinæum.

The Sciatic.—Make an incision, five inches long, on a line from the middle of the sacral spines to the trochanter major. Separate the fibers of the gluteus maximus and find the lower border of the pyriformis. The

* The internal iliac has been tied about thirty times, with a death-rate of 66 per cent.

great cord of the sciatic nerve will now be seen emerging from beneath the muscle, and immediately in front of this the small sciatic nerve and the sciatic artery. The *internal pudic* artery is just anterior to this, upon the spine of the ischium (Fig. 299, middle incision). The sciatic artery may also be secured opposite the *tuber ischii*, along the outer border of which it runs (Fig. 299, lower incision).

The Internal Pudic in the Perinæum.—With the patient supine and the thigh abducted,

make an incision in a line with the symphysis pubis and tuber ischii. The artery will be found as it runs along the inner margin of the ramus of the pubis (Fig. 300).

Ligation of the External Iliac in its Lower Portion.—The *external iliac* has in relation to it the accompanying vein internally. The spermatic vessels cross it, and in the male the vas deferens is internal to it at the inguinal ring.

Operation.—One inch to the inner side of the anterior superior spine of the ilium commence an incision, which is carried in the direction of the middle of Poupart's ligament, and terminates one inch above this point, without entering the internal ring. Divide the three muscles down to the transversalis fascia, arrest all bleeding, divide the fascia carefully, retract the upper lip of the wound, and lift the peritonæum from the iliac

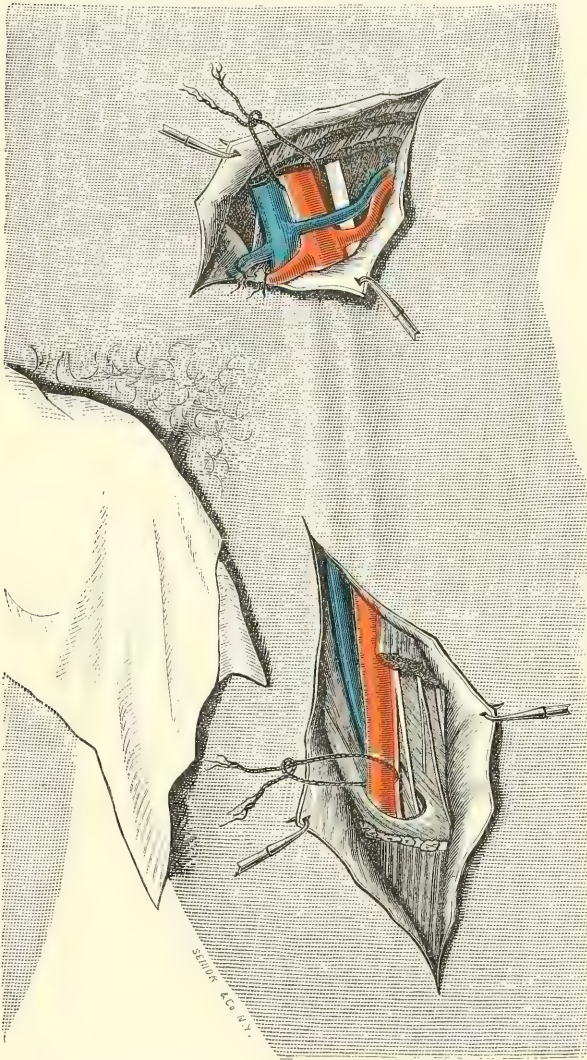


FIG. 301.—Ligation of the external iliac in its lower portion, and of the femoral in Hunter's canal.

fossa and artery (Fig. 301). Displace any overlying lymphatics and introduce the needle from the inner side.*

* Ligation of the external iliac has proved fatal in almost every instance in which it was tied for hæmorrhage. For aneurism about 67 per cent recover.

The deep *circumflex* and the *epigastric* branches, which arise about half an inch above the ligament, may also be tied by this incision. In its upper portion this vessel may be secured by the same operation as for the common iliac.

Ligation of the Femoral Artery—Anatomy.—At Poupart's ligament the vein is on the same plane as the artery, and immediately internal to it. One quarter of an inch to the outer side, and deeper than the artery, lies the anterior crural nerve. One inch and a half from the ligament the *profunda femoris* arises from the outer aspect of the common trunk, and from one to two inches lower passes behind the superficial femoral. Four inches from Poupart's ligament the relations have changed to such

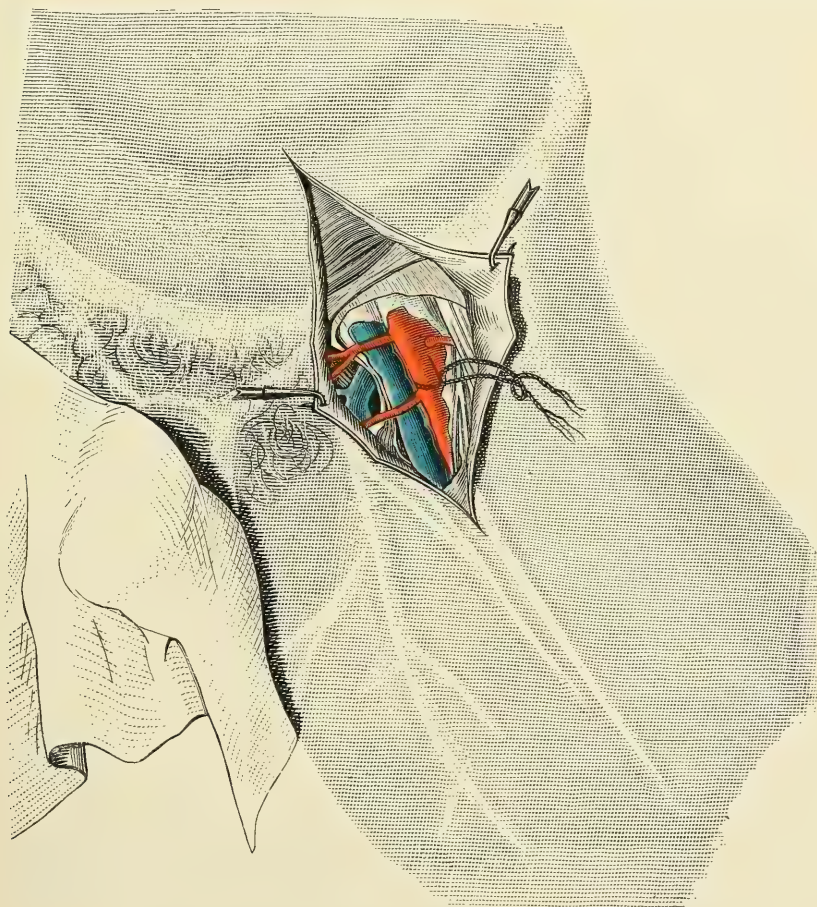


FIG. 302.—Ligation of the superficial femoral in Scarpa's space.

an extent that the femoral vein is deeper and slightly behind the artery. The long saphenous nerve lies upon the sheath of the artery, in its middle third, and occasionally sends a branch through *Hunter's* canal. The *sartorius* muscle covers the femoral artery in all of its course except the first four inches, where it is superficial.

Operation.—A line from a point half way between the symphysis pubis and the anterior superior spine of the ilium to the internal condyle

of the femur will run over and parallel with the femoral. It may be secured in any part of its course.

In Scarpa's Space.—The point of election for tying the superficial femoral is from four to five inches below Poupart's ligament. With this as the center, make an incision three inches long on the line already indicated. Beneath the skin and fascia some superficial and unimportant vessels may be divided; the fibers of the sartorius will be seen in the lower portion of the wound, and should be drawn downward with a retractor. The saphenous nerve will next be seen on the outer side of the common sheath of the vessels. The sheath should next be incised, and the artery carefully isolated by inserting a dull director beneath and around it from the inner side. The ligature is passed the same way.

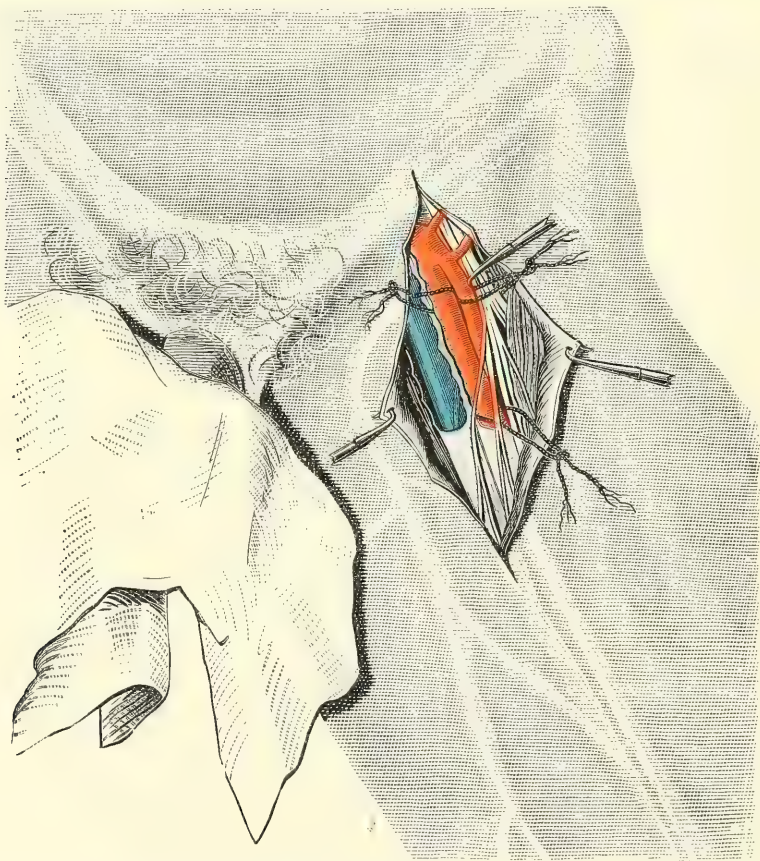


FIG. 303.—Ligation of the deep and superficial femoral near the bifurcation of the common femoral, and in the apex of Scarpa's triangle.

In this same plane an incision may be made to expose the artery lower down, where it is completely hidden by the sartorius. This muscle may be drawn to the side most convenient to the operator (Figs. 302, 303).

In Hunter's Canal.—Find the junction of the middle and lower thirds of the thigh. In the femoral line, with this point as the center, make an incision, about four inches in length, directly down to the sheath of the

sartorius, which is incised and the muscle displaced outward. Immediately upon opening the posterior layer of the sheath of the muscle, the oblique aponeurotic fibers which pass from the adductor magnus to the vastus internus—forming the anterior wall of Hunter's canal—are seen. These may be divided on a director, or the sheath opened half an inch above this point. The saphenous nerve is on the sheath, and the vein is behind and to the outer side (Fig. 304).

The Common Femoral above the Profunda.—Make an incision in the femoral line, from three fourths of an inch above Poupart's ligament downward for three inches and a half. Do not divide the ligament, but approach the artery one half inch below. The superficial epigastric vein and artery may be wounded. Divide the fascia lata, and pass the ligature from within out. (Dissection shown in Figs. 302, 303.)

The Profunda Femoris.—Make an incision in the femoral line, three inches and a half long, the center opposite a point one inch and a half to two inches below Poupart's ligament. As above, approach the common trunk and search along its outer border for the origin of the profunda* (Fig. 303). Pass the ligature from within out, one inch from its origin. Avoid the branches of the anterior crural nerve.

In wounds of the posterior femoral region it may be necessary to tie this vessel as well as for aneurism. Ligation of the *common femoral* is rarely called for, and should only be done in extreme cases. In modern surgical practice, deligation of the superficial femoral is comparatively free from danger.

Ligation of the Popliteal—Operation.—Place the patient on his belly, with the popliteal space looking upward. Make an incision, four inches long, beginning two inches and a half above the level of the joint, at the outer edge of the semi-membranosus tendon, and extending down through the middle of the space. Dividing the dense, deep fascia, the areolar tissue which sur-

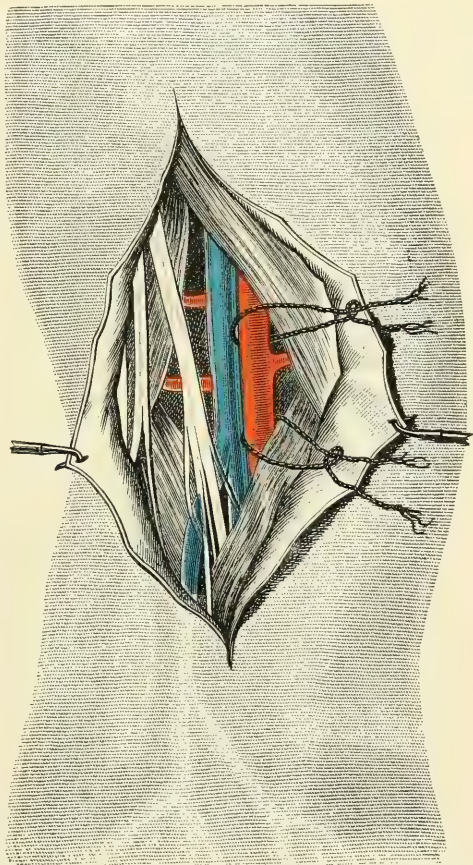


FIG. 304.—Ligation of the popliteal artery. Relations of contents in the left lower extremity.

* In a large majority of subjects I have found this branch given off one inch and a half below the ligament.

rounds the vessels and nerves of the space will be seen, and at the same time, and superficially, the popliteal nerve. Draw this and the vein which is immediately below outward, and the artery will be seen deeply situated, and in the upper part of the space internal to the vein. Lower down the relations change, the nerve crossing superficial to the vein, and this overlying the artery (Fig. 304).

Ligation of the Posterior Tibial Artery at the Middle of the Leg.—Make an incision, half an inch from and parallel with the inner margin of the tibia, three inches and a half long. Avoid the internal saphenous vein.

After passing the deep fascia, look for the lower tibial fibers of the soleus, which pass obliquely from this border of the tibia backward and slightly downward. Divide these on a director, and with the finger separate the sural from the flexor muscles. Retracting the edges of the wound, the artery will be seen, with a vein on either side and the posterior tibial nerve lying just behind. The vessels are held down by the common sheath of the deep muscles (Fig. 305).

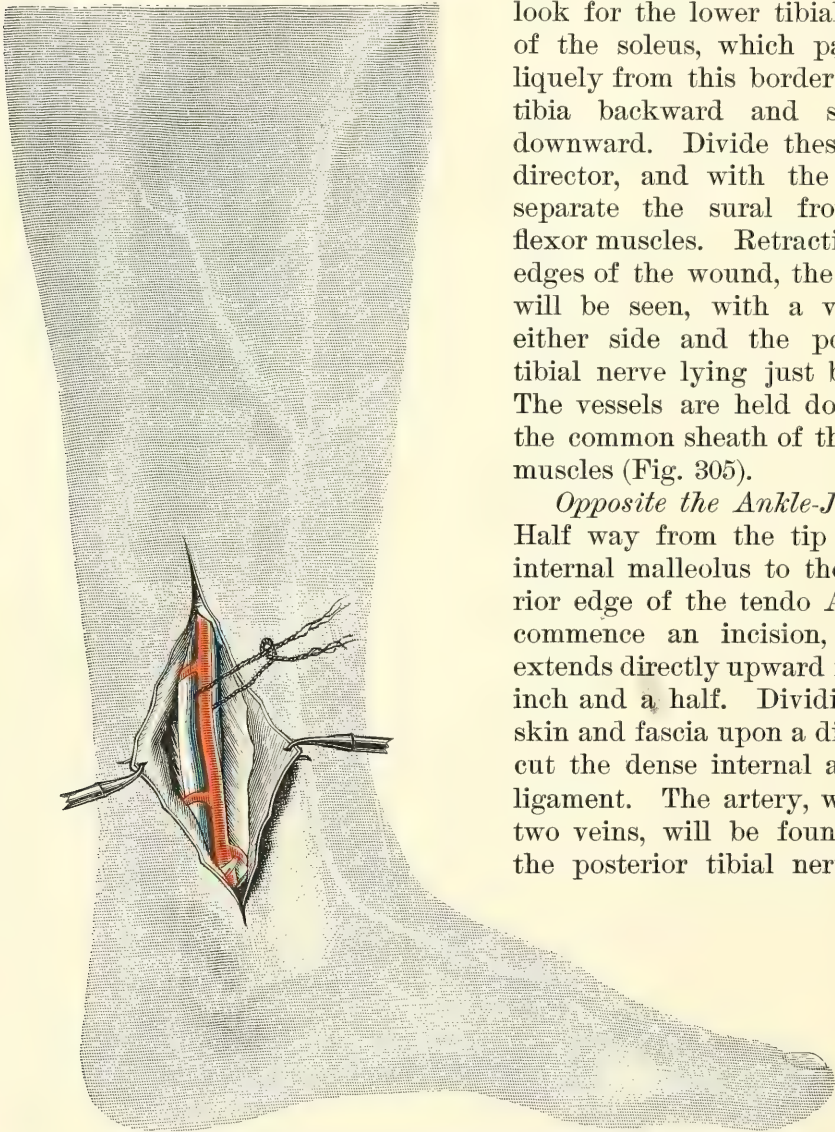


FIG. 305.—Ligation of the posterior tibial above the malleolus.

tendon of the flexor longus pollicis behind, and the flexor longus digitorum and tibialis posticus in front. As the artery curves around the mal-

leolus it will be found one third the distance from the tip of the malleolus to the convexity of the heel.

The Anterior Tibial at the Middle of the Leg.

—A line from a point half way between the anterior tuberosity of the tibia and the head of the fibula to a like point between the two malleoli, in front of the ankle, will indicate the position of this artery. At the middle of the leg make a four-inch incision in this line, dividing everything down to the dense fascia immediately over the muscles. Split this on a director and dissect it up carefully, searching for the interspace between the tibialis anticus internally and the extensor proprius pollicis externally. Finding this, discard the knife, and with the finger separate the muscles, and the artery, veins, and nerve will be found deep down upon the interosseous membrane, the nerve being external and slightly in front, and the veins wound about the artery. In order to relax the muscles and admit the light, flex the tarsus on the leg (Fig. 306).

At the Lower Portion.—One inch above the tip of the internal

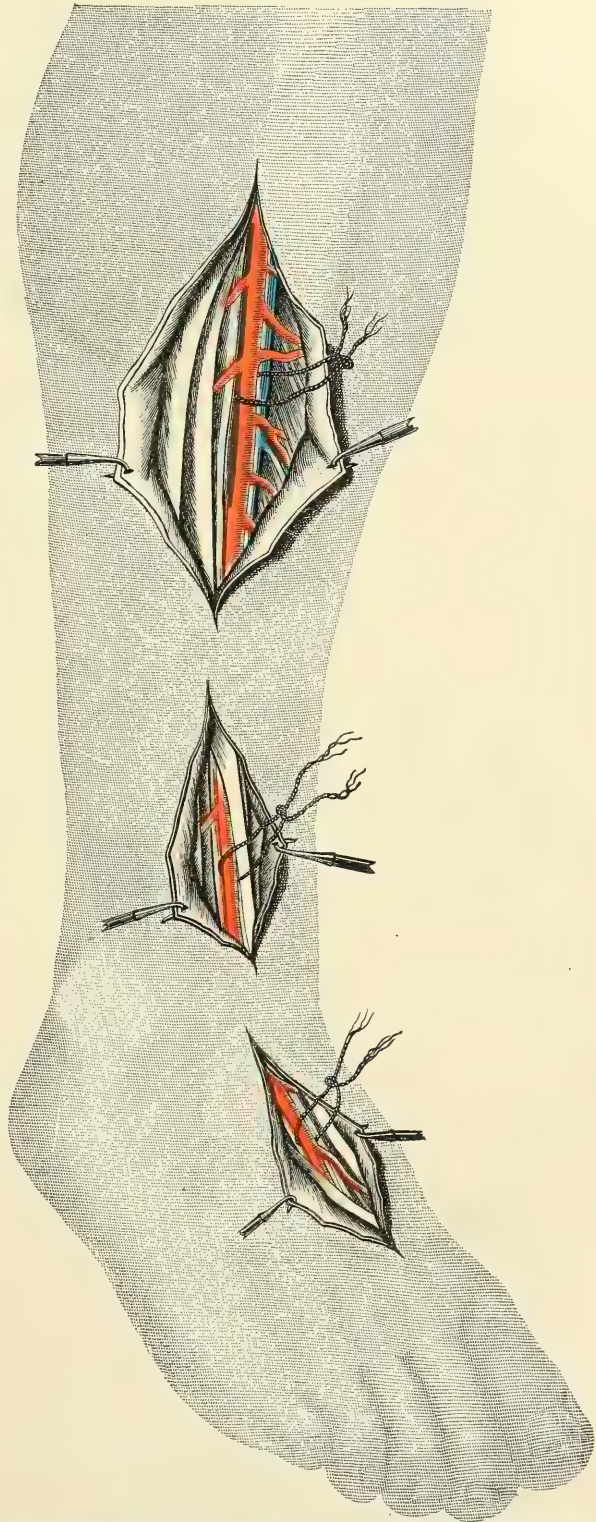

FIG. 306.—Ligation of the anterior tibial in the middle and lower third of the leg, and of the tarsalis pedis artery.

malleolus begin an incision, and carry it two inches upward, in the tibial line above given. This incision is along the fibular border of the extensor pollicis, between which and the tendon of the extensor communis digitorum the artery will be found, with the nerve on the fibular side, and its companion veins on either side.

The Dorsalis Pedis.—One fourth of an inch to the fibular side of and parallel with the tendon of the extensor pollicis make an incision, one inch long, over the tarsus. The artery and veins will be seen on a plane slightly deeper than the tendon, with the nerve on the tibial side of the vessels. This line is a continuation upward of the first metacarpal interspace (Fig. 306).

CHAPTER XII.

THE SURGICAL DISEASES AND SURGERY OF THE BONES.

Ostitis.—Inflammation in bone may be *acute* or *chronic*, *general* or *circumscribed*, *traumatic* or *idiopathic*. It may involve the periosteum (*periostitis*), the compact and cancellous substance (*ostitis*), and medulla (*endostitis* or *osteo-myelitis*). Endostitis and periostitis may occur independently, yet ostitis, more or less severe, must of necessity be a part of a pronounced inflammation of either the periosteum or the endosteum and medulla.

The termination of inflammation in bone is in *resolution* or local *death*. In resolution the inflammatory embryonic tissue undergoes granular metamorphosis and is absorbed, or it may be in part converted into new bone. If the bone dies, it may be cast off as a *sequestrum*, or remain imprisoned in a shell of new-made osseous tissue, the *involucrum*.

When the inflammatory process is severe, or the arrest of nutrition sudden and complete, *necrosis*, or death in mass, occurs; under other and milder conditions of death in bone, the process of dissolution is known as *caries*.

In *necrosis*, which is aptly compared to *gangrene* of the soft tissues, the cast-off portion retains something of its original form and character; in *caries*, which is the molecular death, or *ulceration* of bone, the cell-elements disappear by granular degeneration, leaving no trace of the original structure.

Pathology.—When a bone is subjected to irritation by a force applied from without, or an interference with its normal process of nutrition from within, the earliest change which occurs is *hyperæmia*, with marked increase in the number of white blood-corpuscles. With the dilatation of the blood-vessels, and escape of the leucocytes into the extra-vascular spaces, cell-activity becomes general. Rapid proliferation occurs in the cells of the periosteum; the medullo-cells and the myeloplaxes, found not only in the central marrow, but around the vessels in the Haversian canals; the connective-tissue cells and the bone-corpuscles. The result of this general proliferation is a mass of protoplasm or embryonic cells analogous to that described in the chapter on Inflammation.

Coincident with the formation of this embryonic tissue, absorption of the surrounding and contiguous osseous lamellæ occurs, giving rise to abnormal, and often multiple and communicating, cavities, known as the

caverns of *Howship*. The cause of this absorption can not, as yet, be satisfactorily explained.

Up to this point in the process of inflammation the progress is practically the same in all forms of ostitis, whether acute or chronic, traumatic or idiopathic.

If the ostitis is mild in character, and the tissues involved are in proper condition to resist disease, a portion of the mass of embryonic cells disappears by absorption, while the remainder becomes converted into new bone, which new formation is compensatory to the loss of tissue in the earlier stages of the inflammation. This result may occur in the periosteum, compact tissue, or endosteum.

In exceptional cases the process of embryonic tissue-formation and absorption of the lamellæ goes on indefinitely until the bone is more or less completely destroyed and replaced by granulation-tissue. This variety is known as rarefying ostitis (*ostitis rarefaciens*).

When, in the process of repair, the new formation of bone-tissue is in excess of the original structure, it is termed productive ostitis (*ostitis osteoplastica*). In some of these new formations or *exostoses* the osseous structure resembles closely the parent bone, while in others the new product is more dense and *eburnated*. To this variety the name of *ostitis sclerosa* has been given.

Productive ostitis and ostitis sclerosa occur usually in the bones of the cranium and in the compact substance of the long bones. In rare instances the medullary cavity is filled with newly formed bone. If the inflammatory process is intense, and the condition of the tissues favorable to its development, not only the compact substance, but the medulla and cancellous tissue becomes rapidly infiltrated with pus, inducing a more or less extensive necrosis. This condition is termed *osteo-myelitis*. Suppuration is especially apt to occur in ostitis affecting the spongy bones, as those of the tarsus and carpus, the terminations of the long bones, and the bodies of the vertebræ, although cases are not infrequently observed in which the embryonic granulation-tissue has filled the space formerly occupied by the spongy substance, and in which no pus is present (*ostitis interna fungosa*). The inflammatory tissue occasionally undergoes caseous degeneration (*ostitis interna caseosa*). It is the opinion of modern pathology that a large proportion of cases of ostitis and osteo-myelitis not of traumatic origin are due to the presence of the *bacillus tuberculosis* (*tubercular ostitis*).

Causes.—Inflammation of the periosteum and the underlying bone may result from direct or indirect violence. A fracture will produce a typical acute ostitis, while the same result may be secondary to an injury of a joint. Traumatic ostitis is almost always acute, while idiopathic inflammation is usually subacute in character. Ostitis and periostitis occur chiefly as expressions of a dyscrasia. They are frequently met with in patients suffering from tuberculosis, scrofula, and syphilis. *Periostitis osteoplastica*, affecting the tibia and bones of the calvarium, resulting in nodes or exostoses, is frequent in this last disease. Tuberculosis in bone usually occurs in the young, and naturally in children of

tubercular parentage. The vertebræ, ribs, and sternum are more apt to be attacked, and next in order are the tibia and femur. In these bones the tuberculous deposit is usually found at or near the epiphysis, the joint becoming affected by direct invasion through the articular surfaces; less frequently the bone is involved by invasion from the joint (tubercular synovitis or arthritis).

In traumatic osteitis it is probable that the initial lesion, in the great majority of instances, is the rupture of a capillary, and hæmorrhage in the cancellous tissue. It has been shown by Cornil and Ranvier that the protection of the capillaries, in bone which is undergoing active development, is so deficient that extravasation occurs with such frequency that the process may be almost considered as physiological. This is especially true of the short, spongy bones, the epiphyseal regions of the long bones, the sternum, and vertebræ. If to this be added the fact that these bones are the most frequent seat of the inflammatory change, and that the period of life in which osteitis usually occurs is the period of greatest nutritive activity, it is not difficult to conceive that an extravasation of blood which would be practically harmless in a vigorous and healthful condition of the bones might induce serious inflammatory changes in tissues already deficient in nutrition.

Symptoms.—*Periostitis*, whether acute or chronic, is usually characterized by pain at the seat of inflammation before any tumefaction is recognized. The severity of the pain is in proportion to the intensity of the morbid process. It is markedly increased on pressure, and is usually more severe at night. The symptoms of pressure upon the end-organs of the sensory nerves are coincident with the remarkably rapid development of the embryonic tissue from proliferation, chiefly of the cells of the periosteum, the new formation lifting the covering from the bone. The disease may be ushered in with or without a chill or rigors. The exacerbations of temperature are, as a rule, not so high in *osteo-periostitis* as in *osteo-myelitis*.

In this latter form of *ostitis* the symptoms are more grave in character. The sense of pain is deep-seated and intense in most instances, with usually high febrile movement. The surrounding soft parts become swollen, red, and œdematous, and, as a rule, septic absorption becomes, in the early history of the case, a prominent and dangerous symptom, terminating not infrequently in pyæmia and death.

Treatment.—The earliest indication in the treatment of acute periostitis is rest in bed, with the part involved in the position of least discomfort. Hot applications, by means of the rubber water-bag, or cloths dipped in hot water and partially wrung out, or the cold ice-bag or cloths, as may seem most agreeable to the patient, will be found of value.

When the inflammatory symptoms are severe, as determined by pain, swelling, and high febrile movement, and especially when the suspicion of pus under the periosteum has been confirmed by exploration with a good-sized hypodermic needle and aspirator, a free incision is demanded. This procedure should not be delayed, for not infrequently irreparable damage may follow the lifting of the periosteum by the inflammatory

process. It is better to err on the safe side, if the diagnosis is in doubt, and make the incision down and through to the bone, an operation which is exceedingly simple when Esmarch's bandage is employed, and practically free from danger.

All such wounds should be filled with sublimate-gauze dressings. When osteitis exists, if the symptoms point to severe or extensive inflammation, the trephine, rongeur, gouge, or chisel should be freely used to effect easy escape to any pus which may be imprisoned in the bony tissues. In osteo-myelitis this method of treatment is imperative. Abscess of bone should be treated upon the principles of immediate operation and free drainage.

When necrosis or caries is evident, the removal of the dead tissue is necessary, since its presence as a foreign body is a constant menace to the contiguous healthy structures. A free incision should be made, down to and along the diseased line, the first and only cut going down to the dead bone, dividing the thickened periosteum with the skin. Then, with the elevator—preferably Sayre's oyster-knife—carefully peel up the periosteum until the healthy bone is reached. If the dead bone can not be lifted out it should be divided with the exsector or the cutting-forceps. For lifting a sequestrum the forceps of Hamilton or other grasping instrument will suffice. In chronic osteitis of the spongy substance Volkmann's spoon-scraper is an excellent instrument.

In no department of surgery is thoroughness more essential than in operations upon carious and necrotic bone, and especially in *osteo-myelitis*. The part involved should be exposed by a very free incision, when this is possible, and all diseased portions removed with the sharp spoon or chisel or gouge. When an extremity is involved, Esmarch's bandage should be used. In applying it, no compression should be exercised over the area of inflammation, for fear of forcing septic products into the vessels. In the tibia, after the periosteum has been lifted and the soft parts held aside, the anterior aspect of the bone should be chiseled off with the curved instrument until the medullary canal as far as diseased has been converted into a trough, the sides and bottom of which should be most thoroughly scraped with a Volkmann's spoon.

In all these cases sublimate irrigation is essential, and in tuberculosis of bone, in order to prevent possible systemic infection, it is imperative. With the tourniquet applied, a 1 to 2,000 solution may be used either continuously or by freely flooding the wound at very frequent intervals. In order to insure the destruction of all germs, the wound may be finally filled and mopped out with a 1 to 500 solution; but this should be immediately diluted by washing out with the weaker solution. When no tourniquet is employed, the solution should not be stronger than 1 to 3,000, usually 1 to 5,000.

When one portion of the canal of the tibia is involved it is imperative to expose the medulla well above and below this point in order to allow of full inspection, and in most cases it will be necessary to *trough* the entire canal to each epiphysis. When the disease extends through the epiphyses the cancellous expansions should be scraped out.

When a bone is thus troughed it should be packed with aseptic gauze and treated by the open method. No sutures are used and no ligatures are required. Hæmorrhage is controlled by compression over the dressing and by elevation of the member. The dressings usually require renewing about once every five or seven days. When sinuses in the soft parts exist they should be thoroughly scraped out or dissected away and carefully asepticated with sublimate solution.

When the lower end and cancellous expansion of the femur is involved and the joint not yet invaded, it should be entered from the lateral aspects (preferably the external), in order to avoid the synovial cavity beneath the quadriceps tendon which extends two inches or more above the articular surface.

The same general rules apply to all the long bones. In the hands and feet the sharp spoon will usually suffice. Multiple drainage-tubes are often essential in these cases.

Osteomalacia—Rachitis.—*Osteomalacia (mollities ossium)* is a disease of adult life, and is especially apt to occur in child-bearing women. The chief pathological change is the disappearance of the earthy constituents from the bones, and their presence in the blood and excretions in abnormal proportion. Softening is often present to such an extent that marked distortions occur from muscular contraction and superincumbent weight. The medulla of the bones is the seat of congestion, often resulting in extravasation of blood. In the later stages the bony lamellæ disappear by absorption, the process commencing from within.

The *treatment* consists in the prevention of fracture and deformity by proper precaution, and the restoration of the osseous system to its normal condition by generous diet, studied hygiene, tonics, and the administration of the hypophosphites of lime and soda, with cod-liver oil and iron.

Rachitis, or "*rickets*," is strictly a disease of childhood and youth. Although it attacks the entire osseous system, its disastrous effects are chiefly observed in the bones of the skull and the long bones of the lower extremities. The bones of the skull become thickened and prominent, the sternum is advanced and angular ("pigeon-breast"), and the bones of the lower extremities are curved antero-posteriorly or laterally. While the diameter of a rachitic bone is usually increased at all points, the enlargement is most marked near the extremities. Rickets is a disease of malnutrition. Its chief pathological feature is the formation of an embryonic tissue, which in normal condition is converted into bone, but in the rachitic diathesis only partially (if at all) undergoes ossification. The cells of the periosteum are unusually active in this proliferation, as are the cartilage bone-making cells; yet this new tissue remains in great part embryonic, without the formation of the osseous lamellæ.

The *treatment* of rickets is, first, to prevent deformity, and, secondly, to relieve the dyscrasia. Rachitic children should be kept in the recumbent posture, or, if allowed to stand or walk, artificial support should be given to the lower extremities and spine. The medical indications are nutritious diet, out-of-door life, and the administration of the hypophos-

phites of lime and soda, with cod-liver oil and tonics. The correction of the deformities which may result from rickets will be considered in the article on Orthopædic Surgery.

FRACTURES.

Fractures.—A fracture is a sudden solution of continuity in bone or cartilage. The term is commonly applied to lesions of bone. A fracture may be partial or complete; transverse, oblique, or longitudinal; single, double, or multiple; simple, comminuted, compound, and complicated. A partial fracture occurs when a bone *breaks* or splinters on one side (its convex surface) and *bends* on the opposite (green-stick fracture). In a complete fracture there is a total solution of continuity. A transverse fracture, or one in which the line of cleavage is, in general, at a right angle with the axis of the bone, is rare as compared with the oblique. A longitudinal fracture is a split in the long axis of a bone. It is frequently caused by penetrating wounds (gunshot), or may result from a fall with great violence upon the hands or feet, when the cleavage commences in the articular surface. In this way the astragalus may be driven between the fragments of a longitudinal fracture of the tibia, or a like accident occur at the knee or wrist.

A single fracture is *one* break in *one* bone; a double fracture is a solution of normal continuity in two bones of one member, as the ulna and radius, the tibia and fibula; multiple fracture is a term applied to two or more separate breaks in one or several bones. When a bone is broken in one direction, and at one point, without injury of any surrounding organ or perforation of the skin, it is termed a *simple* fracture; if there are more than two fragments it is a *comminuted* fracture; if any part of the fractured surface communicates with the atmosphere it is a *compound*; and if it communicates with a joint, or involves in the fracture the wound of any important organ, as a large artery or vein, or, as in fracture of a rib, occasionally the pleura or lung is wounded, it is a *complicated* fracture. An *impacted* fracture is one in which the fragments are splintered and interlocked with more or less complete immobility.

A fracture may be caused by external violence, directly or indirectly applied, or by muscular action, or both factors may unite in the production of the lesion. As an example of direct violence, in the effort to ward off a blow from the head the ulna may be broken by the force of a cane immediately beneath the contusion of the soft parts. A blow on the vertex which fractures the base of the skull, or a fall on the foot which breaks the femur, are common examples of fracture from indirect violence. Contraction of the quadriceps extensor may fracture the patella, or the same lesion may result from a fall on the knee, in which the direct violence and the action of this powerful muscle *unite* to cause the fracture. In addition to these direct agencies, certain conditions of the tissues predispose to fracture. The bones of the aged break more readily and are slower in repair than the young and middle-aged. There is a not infrequent condition of fragility in the bones of the insane which, either alone

or together with excessive and uncontrollable muscular action, renders them liable to break. I have seen one specimen of this nature in which every rib was broken, and some of these in two or more places. As heretofore stated, fracture is common in the disease known as osteomalacia, and may occur, though less likely, in rachitis. Sex, vocation, and manual preference also predispose to fracture. Men suffer much more frequently than women, and any vocation which exposes to violence increases the proportion of fractures. The bones of the right, the preferred side, are more frequently broken than the left.

Symptoms.—The symptoms of fracture are: *Loss of function; absence of normal contour; preternatural mobility; crepitus.* A broken bone which is not impacted no longer acts as a support, or sustains muscular contraction. The natural shape or outline is more or less distorted by displacement and overlapping of the fragments. Careful manipulation will determine the overriding, measurement will show shortening, while comparison with the uninjured side will determine the degree of asymmetry.

Crepitus, which is not always necessary to correct diagnosis, is the sensation imparted to the touch, and occasionally recognized by the ear, when the rough fragments are moved so as to grate upon each other. The diagnosis of an *impacted* fracture is more difficult, since crepitus and mobility are absent. Shortening must of necessity exist, which, with partial loss of function and more or less pain and thickening at the point of fracture, will lead to the recognition of the lesion. A longitudinal fracture or fissure is often with difficulty recognized, and may escape detection.

Process of Repair.—The first and immediate result of a fracture is hæmorrhage, which occurs from the arteries, arterioles, capillaries, venules, and veins of the medulla, compact substance, periosteum, and any surrounding soft parts which may be involved in the injury. As a result of the irritation determined by the accident and hæmorrhage, inflammation is precipitated. Hyperæmia of the bone and contiguous soft tissues ensues. As in *ostitis*, absorption of the bony walls of the Haversian canals occurs with the dilatation of the vessels, and general cell-proliferation follows. In the medullary cavity proper, in the medullary spaces of the Haversian systems, in the periosteum, and the inflamed surrounding tissues, this process is common. As in all inflammatory processes, the leucocytes are present in great numbers. The medullo-cells, myeloplaxes, osteoblasts, periosteal cells, and connective-tissue corpuscles, undergo rapid proliferation, resulting in the formation of a mass of common embryonic cells, which infiltrate the clot between and around the fragments. New-formed capillaries are projected into and through this granulation-tissue in the same manner as in the process of repair in wounds of the soft parts.

If the broken ends do not come in contact with the air—that is, if the fracture is not *compound*—the process of repair in bone after an injury is similar to the physiological process of development of this tissue—namely, the embryonic tissue is developed into cartilage-cells, and these,

undergoing proliferation, develop into a secondary embryonic tissue, which is formed directly into bone. If, however, air is admitted to a wound in bone, the process of ossification in the embryonic tissue is more rapid and direct, since the intermediate stage of cartilage-cell formation does not occur.

A portion of this new-formed tissue, which results from the irritation following a fracture, undergoes a process of calcification by the absorption of inorganic material from the blood, and is then known as *callus*. That portion which lies around and on the outer side is the *ensheathing* callus; between the fragments, the *intermediate*; and within the medullary canal, the *central* or "*pin*" callus.

In an adult or middle-aged person, commencing within the first few hours succeeding a fracture, the embryonic tissue, which is formed in varying quantity, remains soft and yielding until about the tenth day, when the cells begin to be infiltrated with calcareous matter. The process of solidification in the callus is complete at a period varying usually from fifteen to thirty days. It is more rapid in children, and slower in the old.

When complete displacement with overlapping occurs, or when an aponeurosis or tendon, or other dense tissue, separates the broken ends, the process of callus-building is interfered with, and failure of ossification may result. Usually a greater portion of the callus becomes absorbed

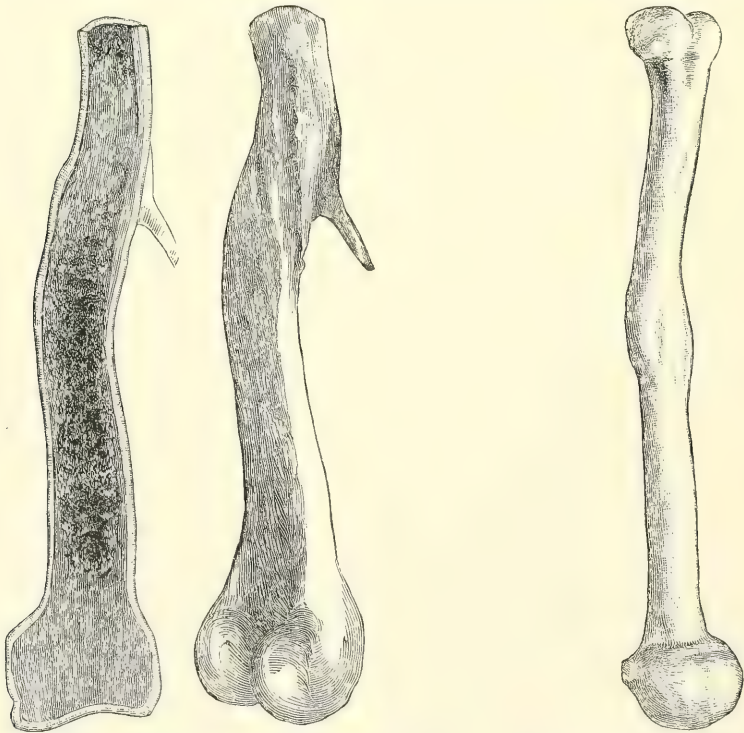


FIG. 307.—Longitudinal section of a fractured femur, showing permanent occlusion of the medullary canal. The stalactite exostosis is well shown in the right-hand figure. (From a specimen of the author's.)

FIG. 308.—Permanent thickening from new-formed bone in a fractured humerus. (From a specimen of the author's in the Wood Museum.)

within from thirty to sixty days after the fracture. This is especially true of the ensheathing layer and the central callus. That portion which intervened between the opposing surfaces becomes organized into permanent bone. The pin callus remains for a while, and may completely occlude the medullary canal, but usually at a later period undergoes absorption. In some cases the medullary canal is not re-established. Fig. 307 shows a section of a broken femur in which, after a considerable lapse of time, the canal was still occluded. The peculiar *stalactite* (exostosis) occurred at the seat of fracture. The permanency of the external callus and its development into exostoses depends chiefly upon the disturbed nutrition of the part (Fig. 308). It has been noticed that when a fracture occurs near the insertion of a group of muscles (as at or near the trochanter), exostosis is the rule, and may be very extensive (Fig. 308 A).

Prognosis and Treatment in General.—The prognosis of a simple fracture in a healthy child or adult is always favorable. The danger is increased with the multiplicity and complications of the accident. A compound fracture is sufficiently grave to demand the greatest attention. Death may result from sepsis or fatty embolism. A longitudinal fracture is a more serious injury, especially grave, as far as the integrity of the member is concerned, when a joint is implicated.

In all forms of fracture the prognosis increases in gravity with each decade beyond the third. When the fracture is complete, and displacement has occurred, exact reposition is impossible, and shortening almost inevitable. The exceptions are extremely rare, especially in the single bones, as the femur, humerus, and clavicle.

The great end to be achieved in the *treatment* of fractures is a reduction of the displacement to as near the normal as possible, and the absolute retention of the parts as replaced. Reduction may usually be accomplished without an anæsthetic, but where the overlapping is considerable, and muscular contraction and rigidity marked, ether narcosis should be secured. The comparative safety of this anæsthetic justifies its general employment in fractures. A compound fracture demands,

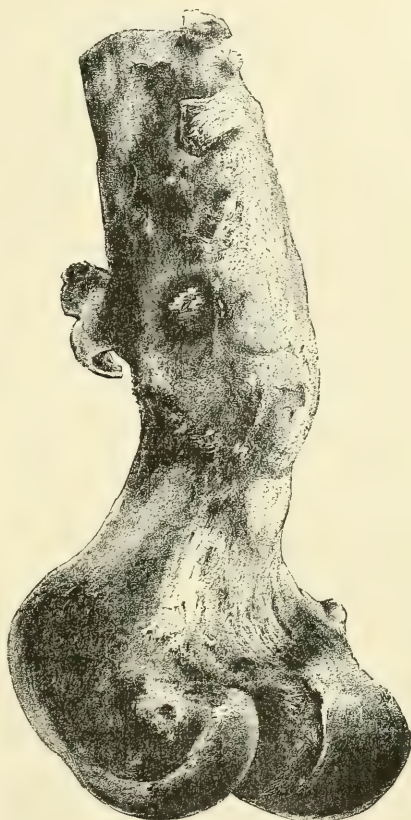

FIG. 308 A.—Case of I. J. Lichtenberg. Showing condition of femur twenty-five years after gunshot-fracture (at "the Wilderness," 1864). At *a*, sequestrum projecting from center of shaft. Two small particles of lead may be seen imbedded at the edge of the opening. Numerous exostoses. Amputation done January 8, 1889.

with fixation, free drainage. The fragments should be reduced, even when it is necessary to remove projecting ends with the forceps or saw to effect this. Once placed in position, they should be kept at rest, with openings and counter-openings. The various methods of treatment will be described with each fracture.

Special Fractures—Cranium.—The bones of the skull may be fractured by *direct* or *indirect* violence. Direct, when the bones give way immediately beneath the point which is struck; indirect, as when, by falling from a height and striking on the feet or buttocks, the base of the skull is fractured by the force transmitted through the vertebral column. A rarer form of indirect fracture of the skull is that known as fracture by *contre-coup*, in which the bones give way at a point opposite to that at which the injury is received.

Fractures of the skull may occur with or without compression of the brain or meninges. The outer table may be depressed by crushing into the diploë without fracture of the inner or vitreous table, and, strange as it may appear, in rare instances the inner table is broken, while the outer plate is not depressed. More frequently both tables are involved. Fractures of the skull may be simple, compound, comminuted, complicated, single, or multiple. They are chiefly divisible into those of the *vertex* and those of the *base*.

Fractures of the base are usually due to *indirect*, those of the vault to *direct*, violence. A blow on the top of the head may produce a fracture only at the base, or at both the apex and base. Usually the break occurs at a point directly in the line of the force which causes the lesion. Aran demonstrated, by dropping cadavers from a height, that when the frontal region received the blow the fracture usually took place in the anterior fossa, the middle parietal and the occipital region giving the key to a fracture respectively in the middle and posterior fossæ. A blow on the chin has been known to produce a fracture by driving the inferior maxilla against the temporal bone. A fall on the buttocks may produce a comminuted fracture, the force being transmitted through the

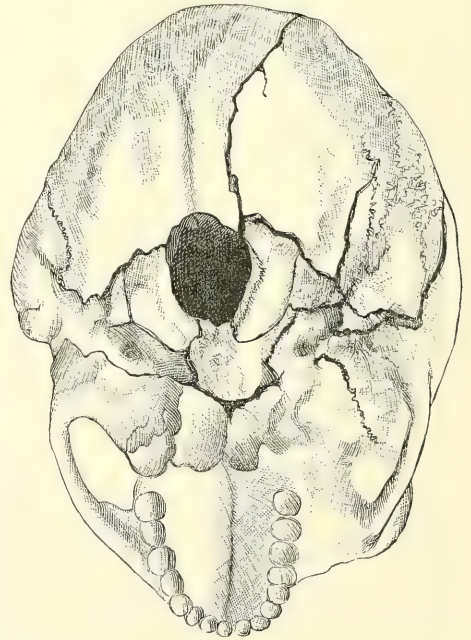


FIG. 309.—Comminuted fracture at the base of the skull, from a fall on the buttocks. (From a specimen of the author's in the Wood Museum.)

vertebral column. Fig. 309 is a copy from a specimen I placed in the Wood Museum of Bellevue Hospital. The patient, a heavy man, a sailor, fell through the hatchway to the hold of the ship, a distance of about twenty feet, striking on the buttocks. Death occurred instantly. The

head was not bruised. The cause of death was a comminuted fracture, extending through the temporal, occipital, and sphenoid bones.

Diagnosis.—The diagnosis of fracture of the vertex may be readily determined when an open wound exists. In many instances a depression may be determined by palpation, even when the scalp is unbroken. Symptoms of compression of the brain are not reliable aids in the diagnosis of fracture in the first few days after an injury, for the reason that any violence sufficient to produce a fracture is also likely to produce symptoms of concussion which might easily be mistaken for compression. The escape of brain-substance or the ventricular fluids is of course an unmistakable sign. At the base, one of the most reliable symptoms of fracture, yet not always a positive indication of this lesion, is hæmorrhage, or the escape of a serous fluid from the ears. This only occurs, however, when the line of fracture passes through the petrous portion of the temporal bone. Swelling of the vault of the pharynx is not without significance when any violence has been suffered which leads to the suspicion of fracture of the skull. If the basilar process of the occipital bone is involved, extravasation will not unlikely be present in this region. Loss of vision or the sense of smell indicate lesion of the anterior fossa. In many instances the diagnosis must rest wholly upon subjective symptoms.

Based upon no objective symptoms, the differentiation between *concussion* and *compression* of the brain is difficult, and often impossible.

In general, it may be said that the symptoms of *compression* are those of paralysis, usually unilateral and more profound than the symptoms of concussion.

In simple *concussion* the patient may be aroused to partial consciousness, the respiratory movements of the muscles of the face will be symmetrical, equality of the pupils is maintained, and vomiting is of frequent occurrence. In *compression*, stupor is apt to be prolonged and profound, the facial muscles are drawn to one side, and the buccinator of the affected side is apt to puff out with the expiratory effort. There may be inequality of the pupils, and vomiting is absent.

In the *treatment* of concussion of the brain the first indication is rest. The recumbent posture, with the head elevated, should be maintained. If there is marked coldness of the skin, and evidence of great prostration or impending collapse, warmth should be applied locally, and stimulants hypodermically. Stimulants must, however, be given with discretion, since the fever of reaction may be increased by their excessive use. After the shock passes off, cold applications to the head are essential.

The *treatment* of fractures at the base is altogether expectant. Surgical interference is rarely if ever called for. In fractures of the vault, with depression, in adults, the trephine should be applied as soon after the injury as is consistent with the patient's safety. If shock is present without serious compression, it will be wise to wait until reaction is established. When, however, dangerous depression exists, immediate operation, even without an anæsthetic, is demanded. When the symptoms of depression are not prominent, an exploratory incision is justifiable in

order to determine with certainty whether there is compression of the brain or meninges. With antiseptic precautions this operation adds little to the gravity of the patient's position.

A *comminuted* fracture in an adult always demands the elevation and removal of the fragments. A linear fracture, with depression, even if this is thought to be confined to the outer plate, also demands the trephine as far as the diploë, and, if the depression involves the inner table, this should also be raised and the fragments removed. A fracture made by a narrow instrument, or other penetrating substance, as a gunshot missile, etc., demands the trephine at the point of entrance. In children, the toleration of the brain to pressure is such as to justify delay in elevation of the fragments unless alarming symptoms supervene.

Localized paralysis, coming on immediately after an injury to the skull, calls for trephining at once. It is always better to operate early than to defer interference until inflammatory symptoms are present. The danger is enhanced by such delay. The disrepute which this operation has fallen into has been chiefly due to too great procrastination in surgical interference.

Operation.—Besides the ordinary cutting and hæmostatic apparatus, a trephine and elevator will be found necessary, while a rongeur and sequestrum-forceps will be of great service. Of the various trephines, the conical instrument of Galt is preferable (Fig. 80).

The scalp, within two or three inches of the wound, should be shaved perfectly clean, and it, together with the hair, washed with 1-to-3,000 sublimate solution. A rubber band or piece of drainage-tube carried around the head, dipping beneath the occiput, and passing above the ears and eyebrows, will control all bleeding from the scalp. Catgut ligatures may be applied later. In cutting down to the bone, any wound which may exist should be utilized, and may be enlarged by a crucial incision, if found necessary. The periosteum should not be lifted.

When the fracture is well exposed, if there is great comminution, and if the fragments are not tightly impacted, they may be lifted by the elevator without trephining. If this instrument is required, advance the central bit about one eighth of an inch beyond the level of the circular teeth, and fasten it firmly here by turning the screw near the center of the shaft. The point of the bit should be applied upon the solid unfractured bone, about one fourth of an inch from the fissure, and the greater part of the button lifted from the uninjured bone. The instrument is now caused repeatedly to rotate for a half circle and back, and sufficient pressure is made to carry the point and teeth into the calvarium. When the teeth have cut a circle about one sixteenth of an inch in depth the instrument should be removed, and the bit slipped up the shaft to its original position. As the operation proceeds, the trephine should be removed every few turns and the ring cleaned out with a tooth-pick. A slight bleeding is apt to occur when the diploë is entered. As soon as the inner table is divided the instrument becomes locked and practically immovable. Wounding the dura mater is scarcely probable if the trephine is held perpendicular to the plane of the bone which is being cut. If the

button does not come up with the instrument, it should be lifted out with the elevator or forceps. The elevator may now be carried carefully under the edge of the depressed bone, and, using the solid surface for a fulcrum, lifted into position, or, if comminuted, removed. It is always important to look for any fragments, however small, which are apt to be broken off from the vitreous table and driven between the *dura mater* and the skull. If the *dura* be torn, the bleeding should be arrested by catgut ligatures, and the wound in this membrane closed by sutures of the same material (Fig. 310).

The wound should be treated under strict antisepsis, and should be kept open with a light dressing of iodoformized and sublimate gauze.

The trephine should not be applied over the track of the longitudinal or lateral sinuses and the middle meningeal artery. Depressed bone may be lifted from these vessels. Hæmorrhage, if it occur, may be controlled by the ligature or by compression.

Nasal Bones.—One or both nasal bones may be fractured and depressed, and in severe injuries the nasal processes of the superior maxilla and the perpendicular plate of the ethmoid are involved.

Hæmorrhage from within the nose is usually severe, and may require the tampon of the anterior and posterior nares. The reposition of the fragments should be effected with great care. A strong, blunt, and narrow instrument passed along the septum nasi until it is in contact with the inner surface of the fragments, together with lateral pressure from without and at the base of the nose, will best reduce the displaced pieces. In order to hold the fragments in position, the method of treatment introduced by Dr. Lewis D. Mason will be found preferable. After reposition, as above described, a steel drill is passed directly across the nose, being entered through the line of fracture or beneath it. Over the ends, which project through the integument on either side of the nose, a strip of pure rubber "is placed, across the bridge of the nose, by puncturing either end on the head and point of the needle, giving the rubber sufficient tension to exert a gentle downward and lateral compression, but not enough to interfere with the circulation or to exert a degree of pressure on the fragments. The point and head of the needle may be protected by small pieces of cork."* The accompanying cut (Fig. 309 A)




FIG. 310.—Fragments removed by the trephine and elevator in a depressed fracture caused by a blow with a hammer. The beveling at the expense of the vitreous table is well shown.

* "Annals of Anatomy and Surgery," vol. ii, pp. 110 and 199.

illustrates the employment of this procedure. This patient received a kick which drove the nasal process of the superior maxilla of the right side and the right nasal bone into the cavity of the nose. The deformity was marked and the voice greatly changed and unusually nasal in tone. The bones could be readily replaced, but would return to their abnormal



FIG. 309 A.—Case of O'Toole.

position as soon as the instrument was withdrawn. Under ether I replaced the fragments, and, while held in proper position, I drove one of my steel fixation-drills from side to side, passing it beneath the loosened pieces. A light loop of iodoform gauze was twisted across the nose and over the ends of the drill. The instrument remained in place ten days, was removed, and a proper cure attained.

The drill may be removed about the sixth to the tenth day. When the blow is received on the side of the nose, the fracture and depression may be unilateral. In such cases, replacement effected after the man-

ner just described will usually suffice, since the fragments are not likely to be displaced when once in position. When the fracture is bilateral, the drill should be entered at the level of solid and unbroken bone, on one side, if possible. When the bones are widely comminuted a second drill may be utilized. In those instances where the perpendicular plates of the ethmoid or vomer are broken, after reposition and fixation with the drills, any lateral deviation of the septum should be corrected. Plugs of gauze may be carried into the nares, if necessary.

At times, and especially in children, when the nasal arch is struck from the front, the fracture occurs at the naso-maxillary suture, and the nasal bones are driven in without comminution. In this variety of depression considerable force is needed to effect reduction. Such is the rapidity with which repair and union occur here, as in all the bones of the face, that, if the effort at reduction is delayed for more than twenty-four or forty-eight hours it will be exceedingly difficult, if not impossible, to accomplish.

Fracture of the *malar* bone occurs rarely, and is the result of violence so great that usually the upper jaw and other bones are broken. Every effort should be made to restore the normal contour to the face by reposition of the fragments, none of which should be removed, since the vitality of the bones of the face is so great that necrosis after injury is exceptional.

When the fracture is compound, and this is usually the case, the fragments may be lifted into place through the wound, by means of the bullet-screw elevator, or other instruments; or, as advised by Hamilton,

the finger or thumb may be passed underneath the lip to the zygomatic arch, which can be utilized as a point for pressure. At times, however, it may be necessary to enter the *antrum maxillare* by trephining or drilling through the anterior wall of the antrum. The point of entrance should be immediately above the first (or anterior molar) tooth, at a distance of from one half to three fourths of an inch below the inferior margin of the orbit.

Fracture of the zygomatic process, either of the malar or temporal bones, may occur singly or as a complication of the fracture just treated. If the force which produces the lesion does not wound the temporal or maxillary arteries, the treatment is simple. If the depression is sufficient to cause deformity, cut down to the arch, insert a hook elevator, and lift the bone into place. It may be necessary to limit mastication by the application of a bandage, as in fracture of the lower jaw.

The *superior maxilla* may alone be broken, although it is usually complicated with fracture of other bones. A blow received at the roots of the teeth may drive the alveolar and palatal arch downward, or, if the direction of the impinging body is from before backward and upward, the antrum may be opened.

The treatment is to cleanse the wound antiseptically and replace all pieces of bone as well as possible.

The following case illustrates in a remarkable degree the vitality and reparative power in the bones of the face: In September, 1884, a robust Irishman, about forty years of age, came into my service at Mount Sinai Hospital. He had just been kicked by an unshod horse. The crescentic wound extended from the center of the forehead down by the nasal process, along the facial groove, and out beyond and below the malar bone. The soft tissues were lacerated, and the bones extensively comminuted. The wound was cleansed of particles of manure, straw, and pieces of hoof. Strict antiseptics were employed, thoroughly cleansing the wound and replacing every piece of bone. The torn edges were pared and closed by silk sutures. Rapid union ensued, without the exfoliation of any portion of the bone.

The great desideratum is the prevention of a scar. Upon the face the greatest care must be taken to avoid deformity. If the soft tissues are torn and contused, the edges of the wound should be smoothly pared and nicely approximated by fine silk sutures.

When the destruction of the bone is so extensive that, even after reposition of the pieces, the fragments will not remain in place, it may be necessary to use the lower jaw as a splint, by fixation of the two rows of teeth, with the head and chin figure-of-8 dressing, as for fracture of the lower jaw. The interposition between the teeth of short strips of gutta-percha, thoroughly softened in warm water, will firmly fix the broken to the unbroken bones, and admit of the introduction of liquid food between the upper and lower incisors.

Fracture of the *inferior maxilla* may occur in rare instances through the *symphysis menti*, but much more frequently external to this and near the opening of the mental foramen. The majority of all fractures

are of the body, and within the first inch and a half leading backward from the symphysis.

Fracture of the *angle* or *ramus* is infrequent, and is usually the result of a blow upon the side of the jaw. The *coronoid process* is rarely if ever broken, except by penetrating bodies. The condyle may be broken through its neck by a fall or blow on the chin, or by force applied laterally at or near the angle.

Diagnosis.—Among the symptoms of this lesion are pain at the point of fracture and loss of function. If the break is complete, the diagnosis is made evident in the displacement which usually occurs, and by the presence of crepitus. This bone may, however, be broken without displacement, and where crepitus is not present. Under such conditions, while a diagnosis may not be positive until the swelling which indicates the formation of callus ensues, the jaw should be kept at rest by one of the methods to be described. When the fracture occurs at or posterior to the mental foramen, the temporary loss of function of the inferior dental nerve, which is not infrequent, points almost unerringly to a recognition of the character of the lesion. When the neck of the condyle is broken, the chief symptom is pain in this region, with partial or complete loss of function. Crepitus is with difficulty elicited by the surgeon, although it may be evident to the patient.

Treatment and Prognosis.—Immediate reposition of the broken and displaced surfaces, and as perfect a degree of rest as possible, are the first and chief indications for treatment. When the presence of a partially displaced tooth offers an obstacle to close adaptation it should be removed. When reduction is effected, one among the following methods may be employed:

A simple and ready method, which may be used until a more secure apparatus is constructed, is found in the four-tailed bandage (Fig. 32). The fragments being carefully adjusted, the bandage is applied as already given on page 20. The figure-of-8 chin and head bandage (Fig. 24) is also an excellent emergency dressing for fracture of the lower jaw. If this is intended to be used permanently, a leather or gutta-percha cup should be constructed, to fit over the chin and well along the body of the jaw. The material should be cut from three to three and a half inches wide and about six to seven inches in length, and split from each end in its long axis to within three fourths of an inch of the center. One strip should be about half an inch narrower than the other. If gutta-percha is used, this should be dipped in warm water for a minute or two, until it becomes softened. It is then laid across the chin, the upper and narrow ends are turned back over and parallel with the body of the jaw, while the lower ends are turned upward and made to cross outside the horizontal ends. The bandage is applied over this cup, which soon hardens into an unyielding dressing. Leather may be prepared in the same way, but requires to be soaked longer than the rubber. Inter-dental splints, made of gutta-percha strips, cut about one inch and a half in length, from one fourth to one half an inch in width, and about one fourth of an inch in thickness, are sometimes employed to fix the molar

teeth immovably, and at the same time to separate the anterior teeth enough to allow of the introduction of liquid food. These strips should also be softened, and, when placed between the teeth, the crowns of the molars are pressed into the rubber by the dressing. When the fracture is through the molar region, the strip on the broken side is placed on either side of the fracture.

The most suitable apparatus is that of Prof. Hamilton, seen in Fig. 311. It consists of a chin-and-head strap, made of strong, soft leather.

This piece, where it passes under the chin, is shaped so that while it may not cause uncomfortable pressure at the base of the tongue, it is wide enough, as it passes up on to the side of the face, to include the angle of the jaw in its support. From this point it is gradually narrowed, until at the temple it is an inch in width, and the same where it is buckled at the fronto-parietal suture. A piece of cloth, fashioned so as to fit like a cup over the chin, is sewed on to this. A second strip is buckled around the head, across the forehead and beneath the occiput, and from this point an antero-posterior strap passes forward to the maxillary piece, to which it is attached at the fronto-parietal junction. By shortening or

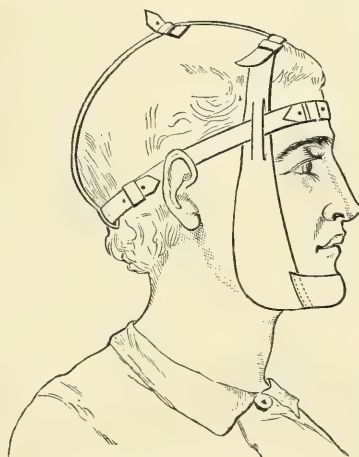

FIG. 311.—(After Hamilton.)

elongating this strap the direction of the pressure on the jaw can be changed, while it prevents the maxillary strip from pulling forward. A piece of soft lint or cotton should be placed under each buckle. If, after the apparatus is applied, the teeth fit so closely together that it is impossible to introduce liquid nourishment, inter-dental splints of gutta-percha should be employed. In some instances it will be necessary to unite the fragments by silver-wire sutures. The sutures usually require to be removed after union is secured.

A patient with a fractured jaw should not be allowed to talk, and, when in bed, should be required to rest in the dorsal decubitus, so as not to press laterally upon the injured bone.

The *prognosis* is usually favorable. Fixation by ossification occurs in from two to five weeks. In some cases later, while in a small number, in which proper treatment has been delayed, or the character of the injury severe, or the condition of repair in the patient unfavorable, union is delayed or fails utterly. In instances of delayed union fixation should be faithfully tried. If this fails, and the function of the jaw is seriously impaired, the point of fracture should be exposed by incision, the broken edges scraped, one or two holes drilled through each fragment, one fourth of an inch from the edges, and fixation secured by means of silver wires.

Fracture of the *cartilages* of the *larynx* is of rare occurrence. Simple fracture heals without retentive apparatus, quiet being the chief indication. The prognosis is grave in proportion to the danger of asphyxia

from inflammatory swelling or emphysema. When the force has been great, and the comminution extensive, death may occur from shock or other complication before asphyxia from occlusion of the trachea supervenes. When this last danger is threatened, tracheotomy should be performed early.

When the *os hyoides* is broken, the fragment, if displaced or driven through the soft tissues, may be brought into position by introducing one finger into the mouth and pressing with the other hand from without. It is scarcely possible to retain the ends in apposition, and fibrous union is apt to occur. The accident is rare, is not dangerous, and the prognosis consequently favorable.

Clavicle.—The clavicle is, next to the radius, more frequently the seat of fracture than any other bone. In children the fracture is rarely complete, and consequently overlapping is not met with, as is the rule in adults. The break occurs, in a large majority of instances, in the middle third, i. e., in that portion of the bone between the attachments of the trapezius and sterno-mastoid muscles. This fracture may be caused by direct violence, or by indirect force, as a fall upon the shoulder or the extended arm.

The character of the displacement is shown in Fig. 312. The inner fragment is held in position by the mastoideus muscle, and is prevented from being carried upward by the costo-clavicular ligament. The weight of the arm and shoulder drags the outer fragment downward, while the contractions of the pectoralis major, latissimus dorsi, and subclavius muscles carry it toward the middle line of the body, beneath the inner fragment. In rare instances the displacement is the reverse.

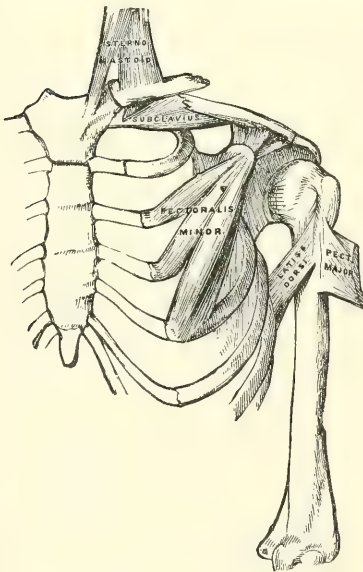


FIG. 312.—(From Gray.)

The diagnosis rests upon loss of function, pain at the seat of lesion, possibly crepitus, loss of symmetry, shortening, and recognition of displacement by palpation.

The *prognosis* is good as to restoration of function, although, in complete fracture, overlapping and a certain amount of permanent deformity and shortening are almost inevitable.

Treatment.—In complete fracture overlapping of the fragments may be corrected, and the ends brought into apposition, by first carrying the arm and shoulder

backward, and then elevating the shoulder. This is the principle involved in Prof. Sayre's excellent method of treating this lesion, which is as follows: Cut two strips of strong adhesive plaster (moleskin is preferable) about three inches wide and several feet in length. Just above the elbow of the arm on the injured side, one strip, with the adhesive surface

nearest the body, is passed around the arm and secured with a safety-pin, so that it will not constrict the member (Fig. 313). The hand is now laid

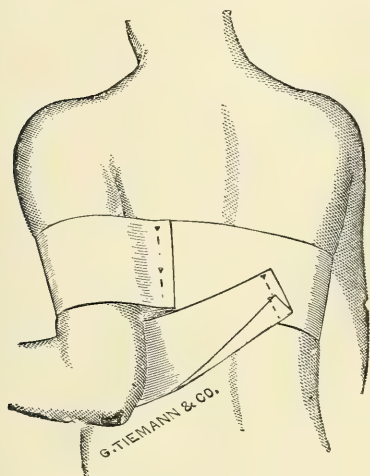


FIG. 313.—The first strip.

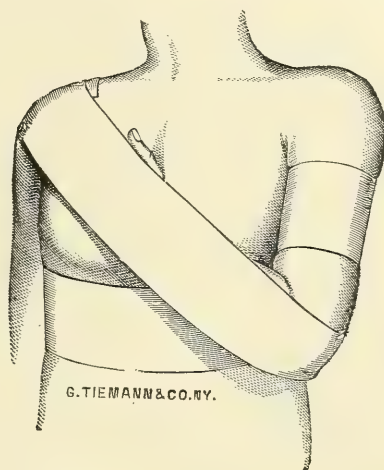


FIG. 314.—Sayre's dressing for fractured clavicle. Front view.

over the middle of the sternum, the shoulder elevated, and the elbow carried well backward by an assistant, while the operator carries the plaster directly around the body by the back, fastening it snugly to the integument. The second strip is split near its middle for about three inches, for the accommodation of the elbow, and is applied along the forearm and over the shoulder of the sound side, and obliquely around the back to the same point (Figs. 314, 315). A wad of absorbent cotton should be placed in the axilla of the affected side, and between the hand and the sternum. The plasters should be stitched or fastened securely with safety-pins.

A convenient and effective ready-method is that of Prof. Moore, of Rochester. A strip of sheeting, eight inches in width and three yards long, is held near its center across the palm of the operator, who, for the left clavicle, grasps the elbow of this side from behind. That end of the strip which is next the patient's body is passed between the arm and chest, then up in front of and over the clavicle of the injured side, obliquely across the back, under the opposite axilla, thence across the right clavicle, and over this to the back.

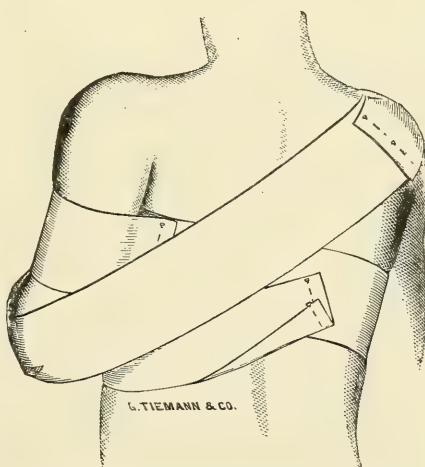


FIG. 315.—Sayre's second strip for fractured clavicle. Back view.

The opposite end is passed to the front of the arm at the elbow, between the first strip and the arm, and is then carried around the back.

An assistant now carries the elbow backward and upward, and, while held in this position, the bandage is tied, sewed, or pinned. A sling to support the forearm is added. This is practically a figure-of-8 bandage around the elbow of the broken side and the shoulder of the sound

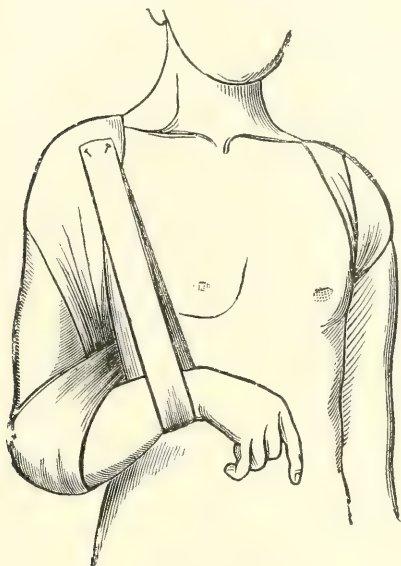


FIG. 316.—Moore's method.

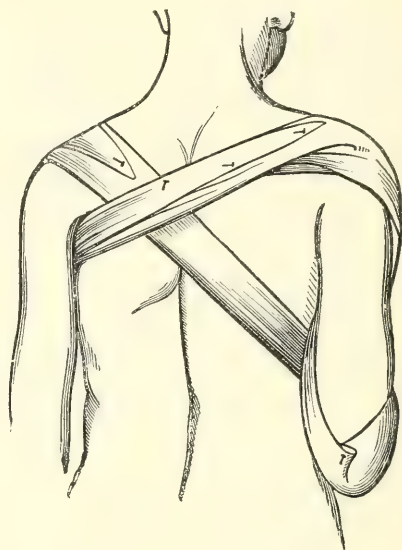


FIG. 317.—Moore's method.

side. The hand is carried across the chest, slightly elevated, and is held in a sling. Safety-pins are inserted at the points of crossing (Figs. 316, 317).

In incomplete fracture, and in children, especially during the summer months, when the plaster tends to produce irritation of the skin, Velpeau's method is preferable. (See page 327.)

Any form of apparatus should be worn at least four weeks.

The *scapula* is almost always broken by direct violence. It is thought to have been fractured in a few instances by muscular action alone.

Acromion Process.—The *acromion process* is usually broken by a fall on the shoulder or a blow received from above. The fracture may occur anterior to, through, or behind the acromio-clavicular articulation. The *diagnosis* is evident from crepitus, preternatural mobility, and depression of the outer end of the clavicle. The treatment is to bend the forearm at a right angle to the arm, and throw a roller under the forearm, at the elbow, and over the clavicle and shoulder of the affected side, fixing the head of the humerus in the upper part of the shoulder-joint and lifting the acromion into its place.

Coracoid Process.—When this process is broken the tendency to displacement is downward, owing to the action of the pectoralis minor, coraco-brachialis, and short head of the biceps. Unless the fracture is anterior to the attachments of the coraco-clavicular ligaments, or unless these have been detached, the displacement can only be limited.

Treatment.—Place the hand of the injured side on the opposite shoulder, and apply Velpeau's bandage as for fracture of the clavicle. The prognosis is good, although fibrous union is the rule.

Fracture of the *glenoid process*—that is, through that portion of the scapula between the glenoid fossa and the anterior portion of the base of the coracoid process—has not yet been noted. Several instances are recorded, however, of fracture which, while anterior to the base of the acromion, included the base of the coracoid process.

Treatment.—Flex the forearm at right angles to the arm, and carry it across the chest, leaving the humerus parallel with the axis of the body. Lift the humerus directly upward against the coraco-acromial ligament, place a pad in the axilla, and carry a roller around and under the forearm, at the elbow, and over the shoulder of the same side. Every other turn should be carried horizontally around the body. By this means the head of the humerus keeps the fragment in position.

Fracture of the spine of the scapula is rare, but below this it is of more frequent occurrence. Velpeau's bandage, or any method which will give the minimum of discomfort and the greatest degree of rest, will be most successful.

Humerus.—Fracture of the *humerus* occurs most frequently in its lower third, while the proportion of fractures in the middle and upper thirds is about equal.

In the upper third this bone may be broken through the anatomical neck; just below this line, through the tuberosities; immediately below the tuberosities (the surgical neck); or through the shaft. It may also be fractured longitudinally, with separation of the tuberosities.

Fracture of the *anatomical neck*, or intra-capsular fracture, is rare. It is caused by a blow or fall directly on the shoulder.

Diagnosis.—There may be crepitus. If the shoulder is fixed and the humerus grasped below and up to the tuberosities, and crepitus is felt by moving the head against the glenoid cavity, the character of the injury is evident. If impaction into the shaft has occurred, crepitus will be absent, but shortening will be ascertained by careful measurement.

Bony union after intra-capsular fracture is rare, unless impaction has occurred. Osteo-arthritis may result, rendering exsection of the joint necessary.

Fracture through the tuberosities occurs also from direct violence. The symptoms closely resemble those of the variety just described. The prognosis is more favorable, since bony union is the rule. Prognosis as to freedom of motion should be guarded, since exostosis may result to such an extent as to interfere with the usefulness of the arm.

Fracture through the surgical neck is of far more frequent occurrence than the intra- or extra-capsular fractures at the anatomical neck. It may result from direct violence, although not infrequently a fall upon the hand or elbow will produce it. The bases of the tuberosities are rarely involved in fracture of the neck in adults—except in the young, when separation at the epiphysis may occur. In the middle-aged and old the point of fracture is usually about one inch below the tuberosities.

Displacement may occur in any direction, although as a rule it is not extreme. The tendency of the lower fragment is to be drawn upward by the deltoid and triceps, inward by the pectoralis major and latissimus dorsi, and upward and inward by the short head of the biceps and the coraco-brachialis (Fig. 318).

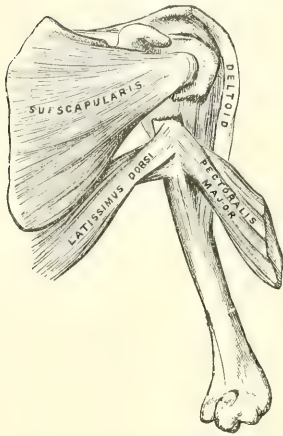


FIG. 318.—Showing the mechanism of displacement in fracture of the surgical neck of the humerus. (After Gray.)

Longitudinal Fracture.—This form of fracture, though rare, occurs from direct injury. The split usually runs through the head of the humerus and along the bicipital groove, resulting in a separation of the greater tuberosity from the shaft. The bone will be found to be flattened and wider than normal, while a deep groove marks the line of cleavage. The prognosis is unfavorable as to restoration of function.

Differential Diagnosis.—In *dislocation* of the shoulder-joint there is always abnormal immobility; the muscles of the shoulder and arm are rigid; a measurement over the acromion and around through the axilla will be at least one

inch greater than on the non-dislocated side; the head of the bone will be felt out of its normal position; if the hand of the affected side is laid upon the opposite shoulder, the elbow can not be made to touch the chest-wall.

In *fracture* without impaction, crepitus and shortening; more or less pain on motion; mobility free; the circumference not increased; the head of the bone in position; with the hand of the affected side upon the opposite shoulder the elbow drops to the chest. With impaction, all of these symptoms except crepitus.

Treatment.—Reduction of displacement is usually effected by extension from the flexed forearm, the shoulder being fixed by traction in the opposite arm, or by a sheet carried around the body, just under the axilla. In the first manœuvre it is usually best to hold the arm at right angles to the body, and, continuing the extension, to bring it down parallel with the chest, in which position it is to be fixed. To this is added direct manipulation of the fragments. The choice of dressings may be made between plaster of Paris and a cup-shaped splint of gutta-percha, sole-leather, or book-binder's board. Properly adjusted, either of these materials will suffice. The gypsum dressing has the advantage of more certain and permanent fixation of the parts. It is, however, not so comfortable as the shoulder-cap splint.

It should not be forgotten that there is an element of danger in applying a fixed dressing (gypsum, glass, or starch) to a recent fracture. Should swelling occur, constriction and gangrene may ensue. It is always safer to wait until swelling has subsided, using the cup-shaped shoulder-splint temporarily. If deemed necessary to apply the gypsum dressing at once, directions should be given to open it enough to relieve tension whenever the pressure is painful or constriction is evident.

If a shoulder-cap is to be applied, a pattern is first made by cutting

a piece of paper to fit over the shoulder and down the arm. It should be large enough to spread over a part of the scapular and pectoral region, and to embrace two thirds of the circumference of the arm. The paste-board, gutta-percha, or leather is cut to correspond to this, and is immersed in hot water until it is soft and pliable, when it is lined with a thin layer of absorbent cotton and molded over the arm and shoulder, where it is secured by a roller, applied as above. The inner side of the arm is protected by cotton or cloth. The forearm and hand should be bandaged, and held in front of the ensiform cartilage by means of a sling. If the dressing becomes loose, an additional roller should be applied. Any dressing for this fracture should be worn continuously for at least four weeks. In order to prevent contraction of the biceps, it will be advisable to fully extend the forearm every two or three days.

Fractures of the shaft of the humerus, although chiefly caused by direct violence, are not infrequently the result of a fall on the hand or elbow, and may, in rare instances, be caused by muscular action alone. The displacement, which is usually not marked, will in great part be determined by the direction of the line of fracture. If the break is above the insertion of the deltoid, while the lower fragment is drawn upward by the deltoid and the long muscles extending from the scapula to the elbow, the upper fragment is apt to be drawn toward the thorax by the pectoralis major and minor and latissimus dorsi muscles (Fig. 318). If the break is below the deltoid tubercle, the displacement and overlapping will, in general, follow the obliquity of the fracture. The lower fragment is apt to be drawn behind the upper longer piece.

The *treatment* is practically the same as that just given. If the cup-shaped splint is used it should be made longer, and an extra short, narrow, internal splint may be added (Fig. 319). The plaster-of-Paris dressing is very satisfactory in this region of the arm.

Fracture at the condyloid extremity of the humerus may be divided into: 1, transverse fracture above the condyles, caused by violence applied to the elbow; 2, epiphyseal separation (on a plane lower than the above); 3, transverse fracture, with a longitudinal split into the joint (inter-condyloid); 4, fracture of the external condyle; 5, of the internal condyle; 6, of the external epicondyle; 7, the internal epicondyle.

In transverse fracture above the condyles the obliquity is usually from behind forward and downward (Fig. 320), the inferior short fragment being carried up behind the longer. When the lower fragment is split into the joint, the displacement is the same.




FIG. 319.—Apparatus for fracture of the humerus at any point above the condyles. (After Hamilton.)

In epiphyseal separation the displacement is not great, unless the capsule is badly torn, as a result of extreme violence.

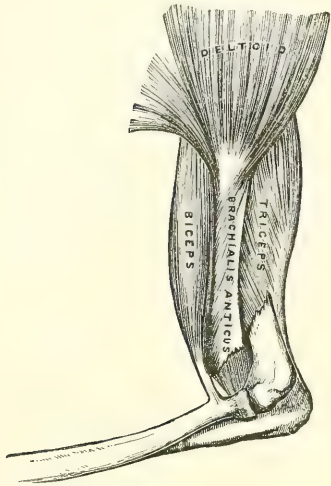


FIG. 320.—Showing mechanism of displacement in fracture above the condyles. (After Gray.)

The *treatment* of these three forms of fracture is the same. Reduction by extension and the long L-shaped cup-splint of Hamilton should be preferred (Fig. 319). This splint is made of gutta-percha (leather or good card-board will suffice if the rubber can not be obtained). It should go from the shoulder to the wrist, and the measurements should be taken on the unbroken arm. The apparatus should be padded with a layer of absorbent cotton. Instead of holding the forearm at a right angle to the arm, as represented in the cut, it is best to carry it about half way between this position and full extension, in order to carry the olecranon process into the fossa, which, if allowed to fill with callus, will prevent full extension of the forearm. The prognosis is more favorable in the first variety, since the joint may not be

involved in the injury. Destruction of the joint, requiring excision, may occur in epiphyseal separation. When the fracture is comminuted, and into the joint, ankylosis, more or less complete, may result.

In all fractures about the elbow it is important to remove the splints at the end of the third week, steady the fragments above and below the line of fracture as well as possible, and make limited motion at the elbow-joint. The splints are again adjusted, and at the end of another week this manœuvre is repeated, with an increased degree of motion. After this, every two or three days, until the greatest possible freedom of movement is secured. An anæsthetic is advisable, to insure thoroughness. My preference is for nitrous-oxide gas, the effects of which are only momentary.

The *internal condyle* is broken much more frequently than the external. It is more prominent, and, in the act of falling backward, the arms are thrown out from the body in such a manner that the inner condyle first receives the force of the fall. The fracture may be confined to the tip (extra-capsular), or it may include a portion of the internal epicondyle, and lead into the joint through the trochlear surface.

Fracture of the *external condyle* is of rare occurrence. The line of cleavage usually commences about the middle of the external condyloid ridge, and runs obliquely to the articular surface, in the groove between the radial eminence and the trochlear surface, or through the center of this surface. The diagnosis is determined by the crepitus, degree of mobility of the fragment, and by the partial loss of function of the extensor or flexor muscles (as the outer or internal condyle is affected).

Treatment.—In fracture of the inner condyle, whether complete or incomplete, flex the forearm on the arm to an angle slightly less than 45°,

and pronate the forearm until the back of the hand is uppermost. This position most fully relaxes the flexors and the pronator radii teres. Use the same splint as just described. Place a compress of cotton or lint in front of the condyle, in order to increase the pressure backward.

For the external condyle, bend the forearm as before, and place the hand palm upward. In all these lesions plaster-of-Paris or liquid-glass dressings may be used, although a well-made gutta-percha, shellac, leather, or pasteboard shoulder, arm, and forearm splint is preferable.

Separation of the epicondyles is of rare occurrence, and demands no especial mention. The indications for treatment are similar, and the prognosis more favorable than for fracture of the condyles.

Forearm—Ulna.—Fracture of the *olecranon process* usually occurs as a result of a fall on the elbow, when the forearm is in strong flexion. It is occasionally caused by contraction of the triceps. The line of fracture is most frequently at the epiphyseal junction. The displacement is upward, in the line of the triceps (Fig. 321).

The diagnosis may be determined by loss of function, crepitus, which may be obtained when the forearm is fully extended, or by appreciation of the separation of the two fragments.

Treatment.—Extend the forearm to the fullest degree consistent with comfort. Make a soft-board splint, two or three inches wide, and long enough to extend from within two inches of the carpus to the same distance from the axilla. Cut a deep notch on either side, three inches below the level of the line of fracture.

Pad the splint with batting, making it twice as thick in the bend of the elbow as elsewhere,

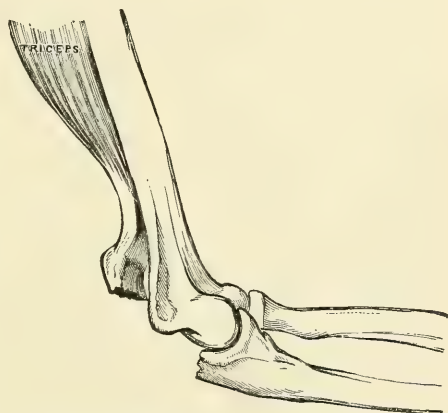


FIG. 321.—Displacement of the upper fragment in fracture of the olecranon. (After Gray.)



FIG. 322.—Hamilton's olecranon splint. (After Hamilton.)

Pad the splint with batting, making it twice as thick in the bend of the elbow as elsewhere,

and wrap it with a roller. Lay the splint on the anterior surface of the arm and forearm, and secure it near the ends by several turns of the roller. Next, take a flannel bandage (on account of its elasticity), and, commencing below, cover the forearm and splint by circular turns until the notch is reached, at which moment the roller is carried well above the upper fragment, around the posterior

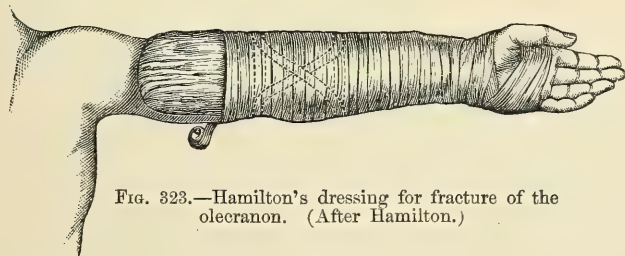


FIG. 323.—Hamilton's dressing for fracture of the olecranon. (After Hamilton.)

account of its elasticity), and, commencing below, cover the forearm and splint by circular turns until the notch is reached, at which moment the roller is carried well above the upper fragment, around the posterior

aspect of the arm, and down again, to be secured in the notch on the opposite side of the splint. This oblique turn is repeated until the fragments are in apposition, when the whole is secured by as many circular turns as are needed (Fig. 323). Within a week the fracture should be inspected, by removing a portion of the dressing, and additional turns applied if any separation has occurred. After four or five weeks the splint should be removed, and careful passive motion made, while the fragments are supported by the operator. The union is apt to be ligamentous.

Fracture of the coronoid process is exceedingly rare. The diagnosis is difficult—often impossible. If the lesion is strongly suspected, secure quiet by applying a splint in extreme flexion.

Fracture of the ulna, in its shaft, occurs in the effort to ward off a blow, or as a result of a fall directly upon the bone.

The diagnosis is usually not difficult, even when displacement is slight. In suspected fracture of one of the bones of the forearm, if compression be made by grasping both bones at a point remote from the suspected break, and pain or abnormal mobility be caused at that point, the diagnosis of fracture is fairly clear. If crepitus is obtained, all doubt is dissipated.

Displacement of the upper fragment is always slight. The lower may be drawn toward the radius by the pronator quadratus. The obliquity of the cleavage, and the direction of the force which produced the lesion, will almost always determine the displacement.

Radius.—Fracture of the radius above the bicipital tuberosity is one of the rarest forms of injury, and, when present, is with great difficulty recognized. The cause is direct violence. Displacement of the upper fragment will be slight, unless the fracture is complicated with a dislocation at the radio-humeral joint. The action of the biceps will tend to draw the lower fragment forward. The best position for treatment is to flex the forearm on the arm, with the palm turned upward, and to apply an anterior splint, wider than the arm, and provided with an interosseous pad. If the displacement forward is extreme, a compress may be employed.

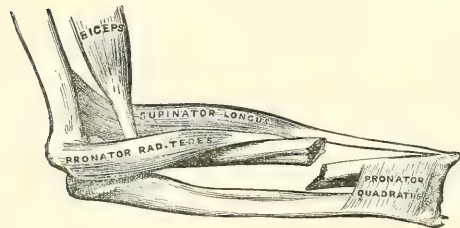


FIG. 324.—Displacement of the fragments in fracture of the radius in its lower third. (After Gray.)

Fracture of the radius between the bicipital tuberosity and the insertion of the pronator radii teres is also usually from a direct blow, although it may result from a fall on the hand, or from muscular action.* While the obliquity of the line of fracture will in great part

determine the displacement, the tendency is for the lower fragment to be carried toward the ulna by the conjoined action of the pronator quadratus and pronator radii teres muscles, while the upper fragment is

* Packard, in Ashhurst's "Encyclopædia," vol. iv. William Wood & Co., New York.

rotated outward by the biceps. When the bone is broken below this point the lower fragment tends toward the ulna. The upper may be held out by the biceps, or carried toward the ulna if the pronator radii teres is contracted (Fig. 324).

Treatment.—The position which renders the approximation of the fragments most easy is that of supination; but in this position the two bones are almost in apposition, and the danger of osseous union between them, with loss of lateral motion, is increased. For this reason it is safer to fix the limb half way between supination and pronation (with the thumb pointing upward). (The application of the splint is the same as for fracture of both bones.)

Fracture at the Carpal End of the Radius.—Fracture through the cancellous expansion of the lower end of the radius is the most frequent of all fractures; that of the clavicle next in order. The line of fracture is in general transverse, and within one inch of the articular surface, being usually nearer the anterior margin of the articular surface, and running obliquely upward, on to the dorsal aspect of the bone, at a distance varying from one fourth to one inch above the posterior lip. In very exceptional instances the posterior lip or rim is split off, the line of fracture leading from the articular surface upward, on to the dorsal aspect of the bone (Barton's fracture). The styloid process is also occasionally broken off, or, when the violence of the fall is great, the bone may be split in its long axis by the first impact of the carpus, and afterward transversely fractured by the forced extension and strain on the anterior ligaments.

Though a fall on the back of the hand has been known to produce a transverse fracture of the cancellous expansion of the carpal end of the radius in a few instances, in the vast majority of cases the force is first received upon the palmar aspects of the fingers and the palm, with the hand in forced extension.

The mechanism of this lesion is this: In the act of falling, the hand is thrown out, and the force of the fall is received first upon the palm, and chiefly upon the anterior extremity of the metacarpus, whence it is transmitted backward to the carpus, and to the anterior radio-carpal

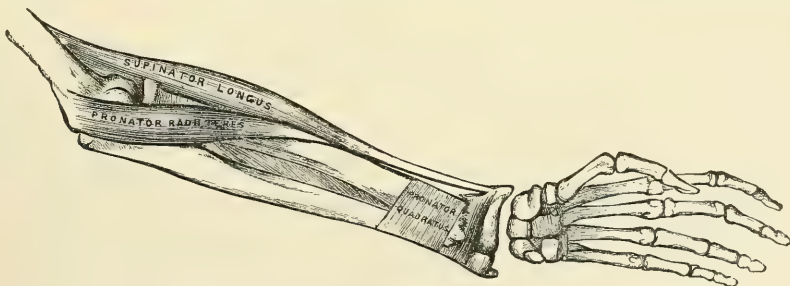


Fig. 325.—Displacement of fragments in Colles's fracture. (After Gray.)

ligaments. As the extension is continued, the strain on this ligament is increased, until the bone begins to yield on its anterior aspect, close to and parallel with the radial attachment of the ligament, and, as the force

is continued, the line of fracture travels upward and backward. The same force which produced the fracture by forced extension and impact of the body will, if continued, produce the usual displacement, causing the lower fragment to ride backward upon the upper, and frequently causing impaction of the compact posterior rim of the upper, into the spongy substance of the lower fragment (Fig. 325).

The *diagnosis* of Colles's fracture is not difficult. The "silver-fork" deformity, the history of the accident, and pain at the seat of the lesion, point to the character of the fracture. When backward displacement occurs it will be recognized by palpation. Crepitus may or may not be elicited. The hand is directed to the radial side, and the styloid process of the ulna is unusually prominent.

Treatment.—When, after careful examination, there is found any degree of displacement of the lower fragment, upward and backward upon the upper, proceed as follows :

With the back of the patient's hand turned upward, the operator with one hand grasps the forearm in such a way that, while the radius is firmly held, the thumb is immediately above the line of fracture. With the other, the hand of the patient is grasped so that his (the surgeon's) thumb (or index-finger, if preferred) presses firmly upon the back of the lower fragment. The hand is now carried strongly back toward the dorsal aspect of the radius (forced and extreme extension), and while in this position the lower fragment becomes unlocked, and may be pushed into place by the thumb, while at the same time the hand, under strong extension, is carried into the straight position. If this manœuvre fails it should be repeated, *and under ether if there is great pain or muscular resistance*. Too much stress can not be laid upon this. The cause of so much deformity after this accident is in many cases due to imperfect reposition. If no displacement exists, extension or the employment of any force is contra-indicated. In aged patients, who have considerable impaction, it is not advisable to break up the impaction, but deformity and impaired usefulness should be prognosticated. In cases with little or no displacement and deformity all extension or manipulation should be abstained from.

In many instances, however, deformity will inevitably remain. The shortening which may result from the accident, or, in the young, the injury to the epiphysis, which may retard the growth of the bone in its long axis, causes a deflection of the hand to the radial side, and an abnormal projection of the styloid process of the ulna. When, as in some exceptional instances, the radio-ulnar ligaments are torn, and, as described by Prof. Moore, of Rochester, the tendon of the extensor carpi ulnaris is displaced, the tendency to deformity is even greater. When proper reduction is obtained, any dressing which keeps the parts at rest will secure a good result.

Within the last few years a large number of cases of Colles's fracture have been treated after the method described by Prof. Lewis E. Pilcher. This dressing has been slightly modified since it was first made public. The results have been very satisfactory. It is as follows :

Roll two pieces of a bandage, two inches and a half wide, into a compress about as thick as the little finger. After the reduction, place one along the inner aspect of the ulna, extending from the anterior margin of the carpus upward, the other exactly parallel with this, along the outer border of the radius, over its styloid process. While these are

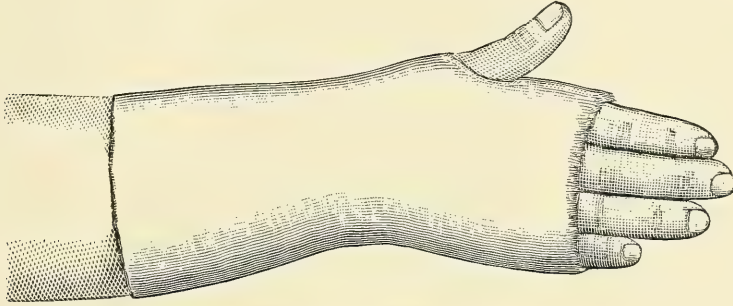


FIG. 326.—Plaster-of-Paris dressing for Colles's fracture.

held firmly in position, secure them by strips of adhesive plaster, one inch in width, wound securely around the wrist and arm, from the lower end of the carpus to the end of the compresses. The hand and arm are carried in a sling. The dressing may be changed in two or three weeks. Gentle and careful motion of the fingers should be made daily, but it is advisable not to move the wrist until about the end of the second week. The dressing should be worn about four weeks.

Another method is to envelop the forearm and hand, as far as the metacarpo-phalangeal articulation, in a plaster-of-Paris dressing. In this treatment, after reposition of the fragments, the hand should be given a considerable declination to the ulnar side. If it is desired to examine the condition of the fracture, the plaster may be cut on the ulnar and radial sides, and reapplied as a modified Bavarian splint (Fig. 326).

Prof. Hamilton's method is as follows: A wooden splint, made from a box-top or shingle, is shaped to extend from a half inch in front of the elbow-joint to the metacarpo-phalangeal articulation. Its breadth is equal to that of the arm at its widest part. This splint is thrust into a muslin sack (the seam of which is kept away from the arm), and is stuffed moderately full of cotton, wool, or hair. The packing should be




FIG. 327.—(After Hamilton.)

a little thicker in the hollow of the palm and just above the lower end of the upper fragment. A straight dorsal splint may also be employed. It is stuffed in the same manner as the other, leaving the packing a little

thicker just over the carpus. After the fragments are reduced, the splints are applied, and held in place by bandages, as shown in Fig. 327.

Fracture of the styloid process, and longitudinal fracture, should be treated by the modified Pileher dressing.

In fractures of both bones of the forearm proceed as follows: Prepare two splints of thin board, one, the posterior, to extend from within one inch of the olecranon to the ends of the fingers; the anterior to extend from the elbow to the carpus; both wider than the forearm at every point. Pad these with some soft material, considerably thicker in the center than elsewhere, to serve as an interosseous pad. Wrap each splint with a bandage to hold the padding in place. An assistant grasps the patient's hand and arm above the elbow, and, with the forearm at a right angle to the humerus, held in a position half way between supination and pronation, makes steady extension, while the operator makes a careful reposition of the fragments. Apply the splints so that the interosseous pads will push the muscles down and between the radius and ulna. Then fasten them by a bandage made tight enough to prevent slipping. If, in the course of a few days, the dressing becomes loosened, it can be tightened by applying an additional roller. The forearm is carried in a sling. The treatment should be continued for about four weeks, when passive motion at the elbow, and supination and pronation, should be made, and the dressing readjusted for another week. This simple dressing is sufficient for all fractures of one or both bones of the forearm (excepting Colles's or Barton's).

Compound fractures of the bones of the forearm require fixation by this method, and the security of open wounds, free drainage, and strict antisepsis.

Carpus—Metacarpus—Phalanges.—Fractures of the carpus occur from great and direct violence, being almost invariably compound. The treatment should be fixation, rest, and drainage under antiseptic precautions.

The metacarpal bones may be broken by direct violence or by blows or falls on their distal ends. This fracture is not uncommon with boxers. I had under observation three brothers, professional pugilists, each of whom had a metacarpal fracture, and one of whom had also a fracture of the radius, all received while sparring. In the young, in rare instances, separation may occur at the epiphyses, which are at the phalangeal extremities of the metacarpal bones of the fingers, and at the carpal extremity for that of the thumb. The fracture of a metacarpal bone, broken by indirect violence, is usually situated in its middle. The accident is recognized by pain, displacement, or crepitus. The treatment is reduction by extension and counter-extension, with direct manipulation and the application of an anterior splint, padded and arched so as to fill the concavity of the palmar aspect of the bone, and to extend to the end of the finger. A posterior splint is also applied, both fastened by a roller. The danger is from fixation of the extensor tendon as a result of inflammation. Passive motion of the finger every day will prevent this result.

Fractures of the Phalanges.—In the treatment of fractures of these bones the same principles are involved as for the metacarpus. The chief precaution is to prevent stiffening of the finger from adhesion of the tendons to their sheaths. Passive motion should be made as early as the sixth day.

The Sternum—Ribs—Vertebrae.—The *sternum* may be broken by direct or indirect violence. In recent cases reposition may be effected by pressure, or by lifting with an elevator. In the treatment of these cases the most perfect quiet should be enforced. Necrosis occasionally follows this accident, necessitating operative interference.

Fracture of the *ribs* or of their *cartilages* may result from (1) indirect violence, as a blow upon the sternum; (2) from a direct injury; or (3) from muscular contraction.

The longer ribs are most liable to fracture. When the force is applied to the sternum, the break most frequently occurs at or just anterior to the middle of the bone.

The displacement is usually slight. Hæmorrhage from division of the intercostal vessels is one of the immediate dangers, while localized inflammation of the parietal pleura is inevitable. The diagnosis will depend upon pain, elicited by pressure on the bone, at a point remote from the fracture, and occasionally by a peculiar click or crepitus felt by the hand applied over the lesion during a full respiratory act. The respiratory movement is less free upon the affected side.

Treatment.—Fixation of the chest-wall, as far as is possible, is the indication in treatment. To this end, the affected side should be shaved, and adhesive strips, cut one inch and a half in width and long enough to reach from the sternum to the vertebral spines, are tightly applied, extending far enough above and below the broken rib to cover the three or four adjacent bones. The strips should overlap about one half of their width.

The body of a *vertebra* may be broken by indirect violence, as a fall from a height, the patient striking on the head, feet, or buttocks, or the bone may be crushed by extreme anterior flexion (occasionally due to muscular action), or by direct injury, with or without penetration. The character of the injury, pain, and symptoms of pressure upon the cord or nerves will lead to a correct diagnosis.

The treatment is quiet in bed, with extension and counter-extension in the earlier stages, and later, the plaster jacket, with jury-mast head-extension for all lesions above the tenth dorsal vertebra. Below this point the jacket, from the pelvis to the axilla, will suffice.

In the case of the patient from whom the accompanying cut (Fig. 328) was taken there was a fracture at the dorso-lumbar junction, which involved the eleventh and twelfth dorsal, and first lumbar vertebrae. There was a sharp knuckle at the last dorsal and first lumbar spines. He was injured by an elevator descending upon him and violently flexing the spine. Paraplegia resulted, with incontinence of fæces and urine. I treated him by extension and the plaster-of-Paris jacket. The symptoms of paralysis gradually disappeared, and now, ten

years after the accident, he walks well, and does not suffer from incontinence.

Fracture of the *articular processes* is of less frequent occurrence.

This accident results from extreme extension (dorsal), or may occur from direct or indirect violence.

When the *spinous processes* are broken, the lesion may occur near the extremity, but more frequently the laminated expansion is the seat of fracture.

The indications in all forms of injury to the vertebral column are to relieve pressure upon the cord and nerves, and insure all possible fixation. While, from the anatomical construction of the spinal column, extension is limited and difficult of accomplishment, yet it may be obtained in a sufficient degree to relieve the injured structures from the greater part of the superincumbent weight. When the bodies are injured, dorsal extension throws, in part, the weight from the spongy bodies on to the compact processes. When the

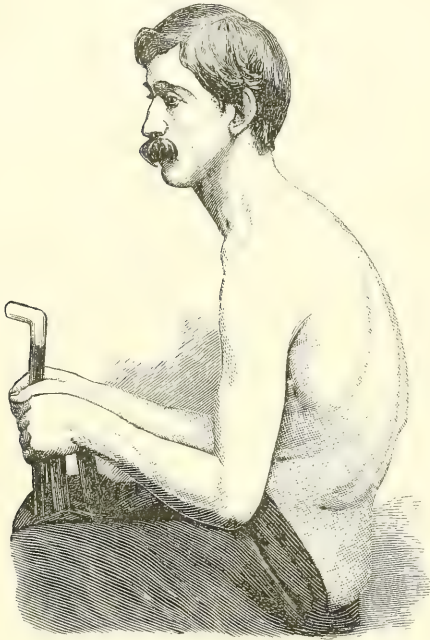


FIG. 328.—Fracture of the vertebrae.

plaster jacket can not be worn, Taylor's or Shafer's brace may be employed with advantage.

Fractures of the *sacrum* are rare, and, when occurring, are due to direct violence by penetrating bodies, or to falls from such heights that other and serious complications render the prognosis grave.

No treatment except enforced quiet is called for primarily. When ostitis and necrosis occur as a result of comminution, operative interference may be required.

Fracture of the *coccyx*, with displacement forward, is not uncommon. The accident occurs from a fall or blow directly upon the tip of the spine. The symptoms are those of pressure upon the rectum, causing difficult defecation, proctitis, and at times fissure or ulcer. Pain is always present, and is due to inflammation as well as pressure upon the fifth sacral and coccygeal nerves (*coccydynia*). The only treatment is removal of this bone, which is almost always followed by relief.

The incision is made over the bone, in the posterior median line, the muscular attachment being divided close to the bone. Care must be taken to avoid wounding the posterior plexus of veins, or the rectum.

The wound may be sewed in its upper portion, leaving the lower end open for drainage.

Os Innominatum.—Though rarely fractured as compared with other portions of the skeleton, the ilium, ischium, or pubes may be broken

singly, or all may be involved in a common lesion at the acetabulum. The force causing the fracture may be directly applied, or, less frequently, by an indirect blow, as a fall on the foot or great trochanter, in which the head of the femur may be driven into the acetabulum with such violence as to cause fracture.

When the fracture is confined to the iliac crest the diagnosis will be determined by preternatural mobility, crepitus, and pain, in conjunction with the history of the case. When the bones of the deeper basin are broken, exploration by the rectum or vagina will be necessary.

The treatment demands reposition and rest. When the acetabulum is involved, extension to the foot and leg (Buck's method), with the foot of the bed elevated, should be practiced. When possible, the bed should be so arranged that defecation may be accomplished without lifting the pelvis. A modification of Crosby's fracture-bed would answer this purpose well. Fixation of one or both thighs, including the pelvis and lower portion of the abdomen and spine, could be well effected by surrounding these parts with a plaster-of-Paris dressing. The prognosis will depend, in great part, upon the extent of the injury sustained by the pelvic viscera.

Fractures of the *femur* may be best studied in three groups, viz.: (1) of the upper extremity (including the neck and trochanter); (2) of the shaft; (3) of the lower or condyloid extremity.

Fracture of the *neck* of the *femur* may take place wholly within, partly within and partly without, or wholly outside of the capsule. This accident rarely occurs in the young and middle-aged. It is a lesion of old age, and women suffer more than men. The anatomical cause is chiefly a condition of senile rarefaction, which begins usually about the fiftieth year.* It has been demonstrated that the change in the relation of the axis of the neck to that of the shaft in the aged is not enough to account for the greater prevalence of this accident in the old, nor is there a marked diminution of the animal constituents of bone at this time of life. The change is one of senile atrophy.

Fracture of the neck of the femur is usually caused by force transmitted from below upward, and along the shaft of the femur. In many instances the accident is trivial. The specimen shown in Figs. 329 and 330 was taken from a patient who broke her femur while in the act of kneeling in church.† It has been known to occur even while turning over in bed. The line of fracture may be at any part of the neck, and in exceptional cases is through the epiphysis. When the fracture is near the trochanteric line, or when these tuberosities are involved, it is usually the result of direct violence—that is, a fall or blow upon the hip.

The *diagnosis* of fracture of the neck of the femur may be determined by a study of the history and the symptoms. If, after a fall upon the

* Prof. L. A. Stimson, "Treatise on Fractures." Henry C. Lea's Son & Co.

† This patient was treated by Dr. Selden, of Norfolk, Va., and, from the history of the case, together with the appearance of the specimen, I consider it an intracapsular fracture, with osseous union. Prof. F. H. Hamilton, to whom I showed the specimen, considered it rather a condition of senile atrophy.

foot or knee, or directly upon the trochanter, there results *pain* in the hip, *eversion* of the foot, *loss of function* in the member, *shortening*,

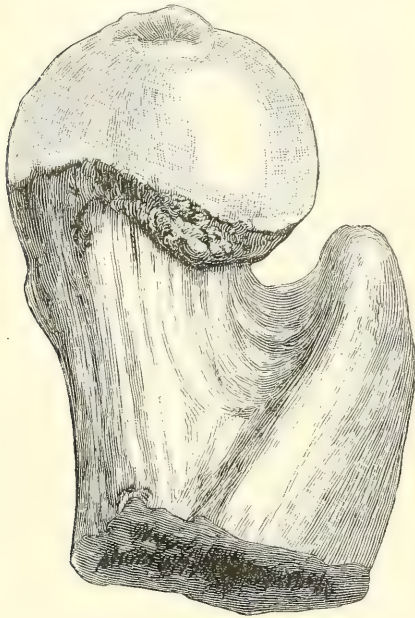


FIG. 329.

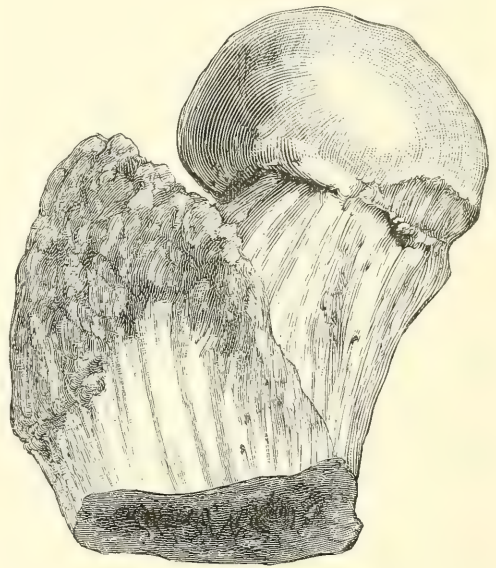

FIG. 330.

and *crepitus*, fracture at the neck is probable. These symptoms are, however, not always present. Pain is the most constant, eversion is the

rule, inversion the exception, in about the proportion of eight to one. The turning outward of the leg and foot is probably due to gravity, and when inversion occurs it is due to a peculiarity in the locking or overlapping of the fragments. Loss of function is not always entire, for in some instances—and very probably in impacted fractures—the patient has been known to walk a considerable distance upon the limb after the fracture. This is, however, a rare occurrence.

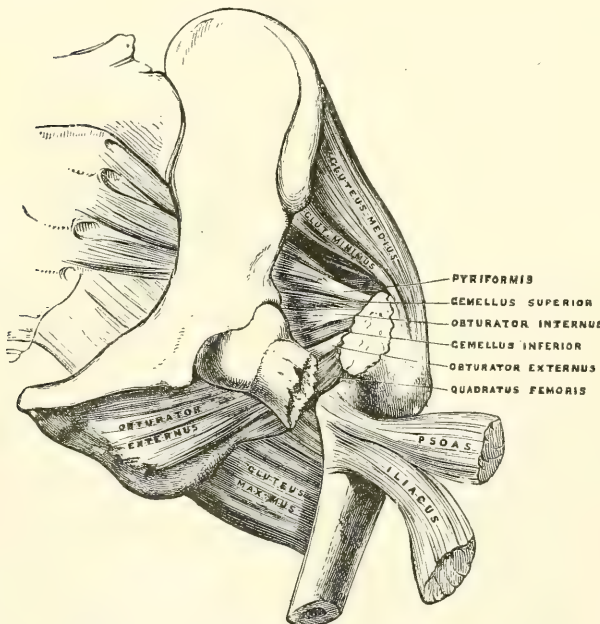


FIG. 331.—Showing the displacement of the fragments in fracture of the neck of the femur. (After Gray.)

Shortening is deter-

mined by comparative measurement of the two sides, from the anterior superior spine of the ilium to the inner malleolus. The internal malleoli should be made to touch, and should be directly in a line with the symphysis pubis, umbilicus, and interclavicular notch. The end of the tape should be held on the thumb-nail, and pressed well into the notch, just under the anterior superior spine. It is then carried along the inner side of the thigh, knee, and leg, to the under edge of the inner malleolus. The degree of shortening will vary from one fourth of an inch up to two or more inches. The occasional normal inequality in the length of the two lower extremities should not be lost sight of. This varies from one eighth to, in some instances, as much as one inch and over. To determine that the shortening is between the trochanter and the acetabulum, apply *Nélaton's* test; a line drawn from the tuberosity of the ischium to the anterior superior spine of the ilium passes over the upper surface of the great trochanter. The distance the tip of the trochanter may be above this line will give the degree of shortening. Bryant's test is, with the patient resting upon the back, the legs parallel and extended, to drop a line from the anterior superior spine and to measure the distance between this line, at its nearest point to the trochanter and this tuberosity. If the fracture is above the trochanter the tuberosity will be found nearer the line than on the sound side.

Crepitus can not always be obtained. In the cases of impaction it is not possible without the employment of force sufficient to unlock the fragments, and in many cases of fracture above the trochanteric line, without impaction, crepitus is not felt. Any unnecessary manipulation of the hip is contrary to the best rules of practice, and an effort to elicit crepitus should, therefore, not be made.

It is difficult, and at times impossible, to determine at what particular portion of the neck the fracture has occurred. Practically it makes little difference, as the treatment is the same.

Treatment.—Rest in the dorsal decubitus, with fixation of the pelvis and the affected limb, are the immediate indications. To secure fixation, extension in a limited degree is desirable. To obtain this, place the patient upon a hard mattress. If the bed is too soft and yielding, place wide boards underneath the top mattress in order to hold it smooth and firm. Elevate the foot of the bedstead from six to ten inches, by placing the legs at this end upon blocks of wood or bricks. Cut two strips of strong adhesive plaster (Maw's moleskin is preferable) about two inches wide and long enough to extend from the hip to beyond the sole. Lay one of these upon the inner and outer surface of the

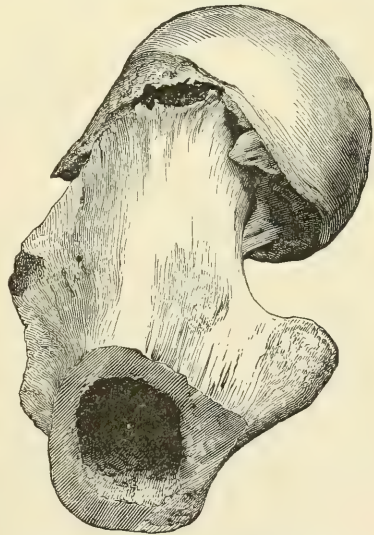


FIG. 332.—Fracture of the neck of the femur, with impaction. (Bigelow.)

thigh and leg, exactly opposite each other, and hold them in place by a well-adjusted roller. The strips can be more nicely applied if they are partially divided with the scissors, in a direction upward and inward, at intervals of about two inches. When within four inches of the ankle the bandage is interposed between the strips and the integument. In order to prevent pressure upon the malleoli, a stick about six inches in length is placed between the ends of the adhesive strips, and the extension-weight is attached to this.

A piece of board provided with a pulley is next fastened to the foot of the bed, so that the tip of the pulley will be on a level with the malleoli. The weight will vary from two or three up to eighteen pounds. A pound for every year of life up to eighteen is the rule; but this is too much for fracture above the trochanter. About ten pounds is sufficient for all ordinary cases. Shot in a bag, or smoothing-irons, are usually employed for the extension-weight, which is tied to the string (Fig. 333). The pa-

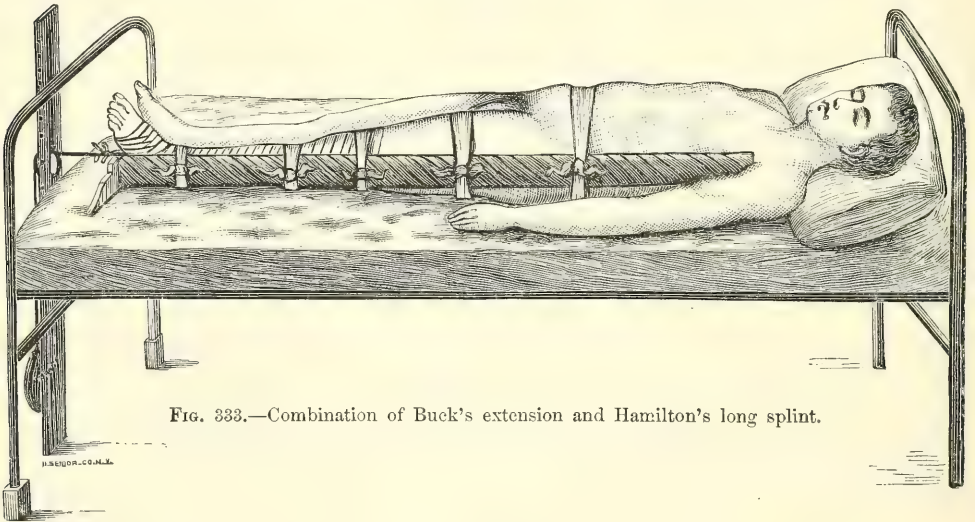


FIG. 333.—Combination of Buck's extension and Hamilton's long splint.

tient's body serves as the counter-extending force, the gravitation toward the head of the bed being about counteracted by the weight attached to the foot. Additional benefit and comfort may be obtained by laying small, long bags, filled with sand, on either side of the thigh and leg. When the limb tends too strongly to outward rotation (or inversion) this may be corrected by the sand-bags, or by Prof. Hamilton's long splint, which is shown in Fig. 333, and which is tied by strips of bandage from the axilla to the ankle. The foregoing is practically Buck's extension, to which may be added Hamilton's long splint.

In some instances it may be found advantageous to use Volkmann's sliding foot-piece, seen in Fig. 334. This consists of a posterior splint for the leg, to which is attached a foot-piece having the angle shown in the cut. This splint should be perforated for the heel, and rest upon two cross-bars of wood, which in turn slide up and down on a rectangular frame. Upon the upper edge of these parallel bars a tongue is cut, and

a corresponding notch or groove in the cross-bars. This apparatus is complicated and will rarely be needed. Buck's extension, with Hamilton's long splint, or preferably the sand-bags, will meet almost every requirement, and give the greatest satisfaction.

In order to prevent the bed-clothing from coming in contact with the fractured limb, wire screens (Figs. 335, 336) may be employed. In some instances plaster of Paris may be used; but this method of treating fractures above the trochanter is now rarely employed.

The most easily managed and simply constructed apparatus for making the necessary extension and counter-extension, in applying the fixed dressing for fractures of the lower extremity, is made as follows:

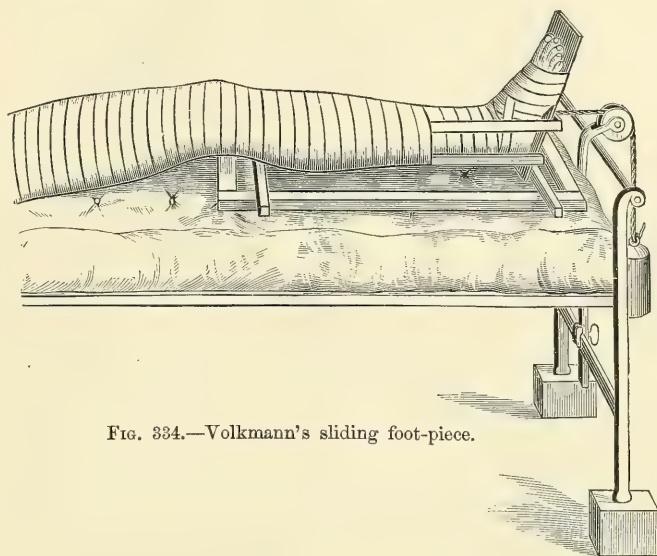


FIG. 334.—Volkman's sliding foot-piece.

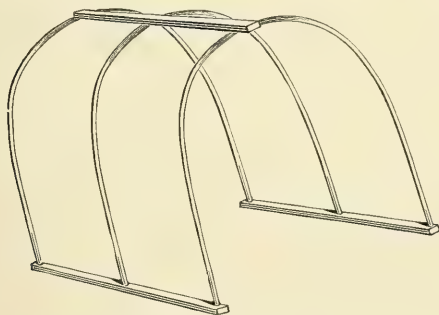


FIG. 335.—(After Esmarch.)



FIG. 336.—(After Esmarch.)

Into each end of a table, about five feet long, two holes are bored, and into these two perpendicular pieces are fitted, two feet long and about two inches in diameter, while a strong horizontal bar connects the two upper ends. One of these uprights is smoothed, rounded, and padded, to prevent injury to the perinæum.

The foot of the injured side being nicely bandaged, the patient is placed upon the table, astride the padded upright (Fig. 337), with the perinæum against it, and is suspended by a strap passed over the horizontal bar and underneath the sacrum, being elevated from the table sufficiently to allow free manipulation of the bandages under the back. The head and shoulders are supported upon pillows, the foot

of the uninjured limb rests upon a stool, a clove-hitch or double loop is thrown around the ankle, and to this a block and pulley is attached, the opposite end of which is fastened to the wall.

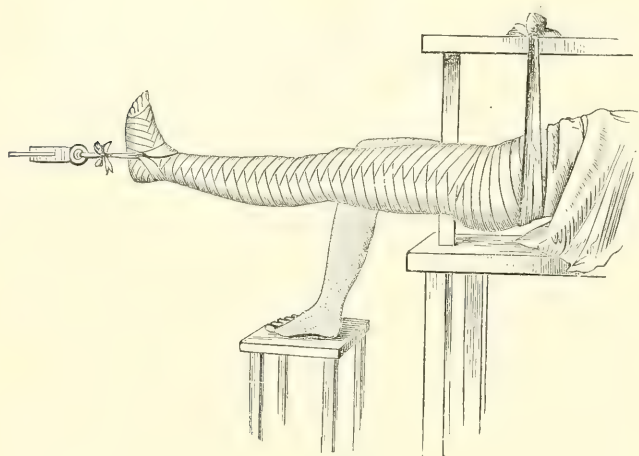


FIG. 327.

Extension is then applied until, by measurement from the anterior superior spinous process of the ilium to the lowest point of the inner malleolus, the two legs are found to be of the same length. The pelvis, thigh, and leg are then covered with a dry roller, or a trousers' leg, or piece of soft blanket, and the plaster rollers applied. Accessory splints of zinc, cop-

per, tin, or hoop-iron may be worked in with the plaster bandages if desired.

The *prognosis* in this class of cases should always be guarded. Useful limbs result in a large majority of cases, but the function of the hip is not often fully restored.

Fracture of the Trochanter.—Separation of the great trochanter is a rare accident. The cause is direct violence. A diagnosis must rest upon independent mobility of the tuberosity, with crepitus. The treatment should be fixation, firm compression by bandages, and rest.

Fracture through the Trochanters.—Fracture through the trochanters is also comparatively of rare occurrence. The diagnosis may be determined by shortening, crepitus, pain, and loss of symmetry and function. A strong diagnostic feature is, that a portion of the trochanter may remain attached to the neck.*

The *treatment* does not differ from that just given. The *prognosis* is more favorable as to restoration of function. Occasionally enormous exostosis occurs after fracture at this locality.

Fractures of the Shaft.—The shaft of the femur is usually broken by direct violence, or indirectly by a force transmitted from below upward. In exceptional instances the fracture is caused by muscular contraction alone. The line of fracture is generally oblique, and the displacement is determined chiefly by the direction of this line. In complete fracture overlapping is the rule. When the break is in the upper portion the lower fragment is drawn up by the long muscles extending from the pelvis to the neighborhood of the knee-joint, and, as shown in Fig. 338,

* Prof. L. A. Stimson, *op. cit.*

the upper fragment is usually rotated outward by the external rotators, and tilted up and to the front by the psoas and iliacus. When the fracture is near the knee-joint the lower fragment is tilted backward by the action of the gastrocnemius, popliteus, and plantaris muscles. The upper fragment is acted upon in a milder degree by the same muscles that caused its displacement in the higher fracture (Fig. 339).

Fractures at the condyles may include, transverse fracture near the epiphyseal line, or through the epiphysis proper; transverse fracture, with a split into the intercondyloid notch; or one or the other condyles may alone be broken off.

The *diagnosis* of fracture of the shaft of the femur is not difficult, as a rule. Preternatural mobility, crepitus, pain, and shortening will usually determine the character of the injury. When the joint is involved, in addition to the usual symptoms of fracture the knee becomes much swollen.

Treatment.—In the treatment of all fractures between the trochanters and the knee-joint the choice rests between the method by Buck's extension and the plaster-of-Paris dressing. In general the first method is preferable. Unless the fracture is too low down, the traction of the adhesive strips should be upon the condyles as well as upon the leg below. Even when it is determined to employ the gypsum fixed dressing, it is wise to defer its application until after all danger of swelling is past, usually after from four to eight days. When the fracture is below the middle of the thigh the plaster-of-Paris dressing may be applied without anæsthesia. The bandages need not extend higher than the level of the perinæum. After a few days the patient may move about on crutches. In the higher fractures the same principles are involved as in fractures of the neck. When the knee-joint is involved, passive motion should be commenced on the third week, and continued at intervals thereafter. Whatever method is employed, immobilization at the seat of fracture should be maintained for five or six weeks.

In fracture of the femur in children the plaster-of-Paris dressing is to be preferred. The reposition of the fragments should be made under anæsthesia, and the parts immediately immobilized. This class of patients are not easily controlled and kept quiet by the use of the ordi-



FIG. 338.—Displacement of fragments in fracture of the thigh in the upper third. (After Gray.)

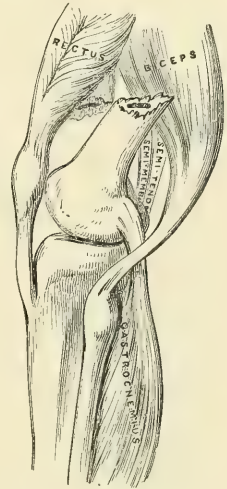


FIG. 339.—Displacement of fragments in fracture of the thigh in the lower third. (After Gray.)

nary apparatus.* In one instance of fracture at the trochanters in a child just delivered, I placed the extremity in the position assumed *in utero*, the thigh flexed on the abdomen, the leg flexed on the thigh, enveloped the parts with flannel bandages, and applied plaster-of-Paris rollers from the ankle to the axillæ. The dressing was removed on the twenty-first day, and the cure was perfect. There is no shortening or impairment of function, and the child walks and runs with perfect motion.

Patella.—Fracture of the patella may be caused by violent contraction of the quadriceps extensor muscle, or by a blow or fall upon this bone, or both of these factors may combine to cause this lesion. The line of cleavage is usually transverse, and in the majority of instances just below the middle of the patella. It may be broken in an oblique or longitudinal direction, or in several directions at once—“*stellate fracture.*”

When muscular contraction is the chief or sole factor in this break, the line of cleavage is usually transverse. Longitudinal and stellate fractures are the result of direct violence. Fracture of the patella is usually complete, the separation of the fragments varying from a small fraction of an inch up to two or more inches. The separation is generally more marked on the internal than the external border. In rare instances incomplete fracture may occur, the cartilage not giving way. Such cases are scarcely recognizable without exploration, the few recorded being seen post-mortem. Fracture of the patella is more frequent in men than in women, and occurs mostly in the decades from the twentieth to the fortieth years.

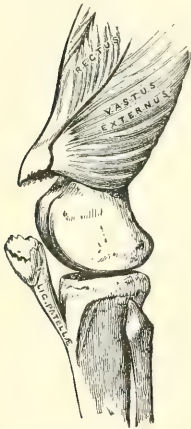

FIG. 340.—Displacement of fragments in fracture of the patella. (After Gray.)

The *diagnosis* may be made from loss of function, pain at the seat of injury, and separation of the fragments. Inability to extend the leg, or marked impairment of function, is always present. The limb may, however, be used to support the body if it is allowed to fall into the straight position. One of my patients, with a separation of three fourths of an inch, walked, unaided, a quarter of a mile immediately after the accident. Hæmorrhage between the fragments occurs in all cases, and therefore communicates with the synovial membranes, which are interposed between the posterior surface of the patella and the general cavity of the joint, and, in cases where the separation is well marked (from half to one inch and over), it is more than probable that the reflection of the synovial lining, from the lower anterior portion of the joint below the patella upward and forward to the front of the intercondyloid notch, is torn, and that whatever of extravasation occurs is into the general cavity of the joint. This occurred in the only knee I have opened, immediately after this fracture. More or less effusion into the joint follows in the majority of cases. In longitudinal and stellate fractures the separation is usually slight.

* In one instance, in the case of a child three and a half years old, with a fracture at the middle of the thigh, chloroform narcosis was obtained during natural sleep, the child not becoming conscious while passing under the influence of the anæsthetic.

Treatment.—A patient with a broken knee-pan should be immediately put to bed, in the dorsal decubitus, the affected limb kept straight, and the foot and leg elevated on pillows. In case of swelling and inflammation at the knee, cold cloths or the ice-bag should be applied. The mechanical treatment should commence at once.

A posterior splint is made to extend from near the heel to the gluteal fold. Shellac-board is best suited for this purpose, but sole-leather, gutta-percha, or a piece of plank will suffice, if these lighter articles can not be obtained. If either of the first three articles is employed, the piece should be cut wide enough to envelop from one half to two thirds of the circumference of the limb. Three inches above and below the center of the knee-joint a tongue, one inch wide and two inches long, should be cut, and turned out so that the attached end is nearest the joint. The splint is dipped in warm water until soft enough to be molded to the part, when it is lined with a sheet of absorbent cotton and applied on the posterior aspect of the limb. The cotton or padding material should be considerably thicker opposite the popliteal space, in order to prevent complete extension of the leg. Secure the upper and lower ends by turns of the roller thrown around the thigh and leg, and next begin the oblique or approximating turns by carrying a flannel bandage around the leg, so that it catches behind the lower tongue, whence it is carried obliquely upward above the upper fragment, across the quadriceps, and back to the starting-point. This is continued until the upper fragment is brought into apposition with the lower. For

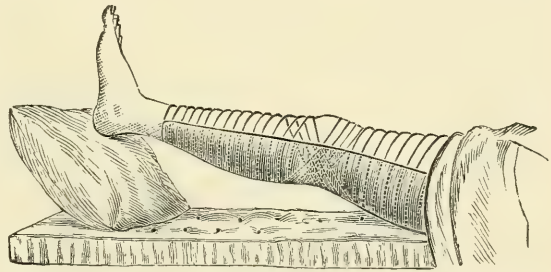


FIG. 341.—Hamilton's apparatus for fracture of the patella. (Hamilton.)

the lower fragment the bandage is made to catch behind the upper tongue upon the splint. When the fragments are approximated the entire limb is invested by the roller.

After the dressing is applied the same position is maintained for two weeks. The portion of the bandage immediately over the fracture should be opened on the fifth or sixth day, and a careful inspection made, in order to determine whether the roller has slipped and re-separation occurred. If the bandage is at all loose it should be tightened, but never drawn so tightly that it produces any discomfort.

This inspection should be repeated every five or six days, but the splint is never taken off until the fourth week, when passive motion at the knee-joint should be made. In doing this the surgeon should grasp the patella between the thumbs and fingers, in order to hold the fragments firmly in contact, and while thus held should have an assistant move the leg back and forth, not flexing it for the first time more than 15° or 20°. This should be repeated each week until the ninth week, and twice a week after this for the next two or three months. After the first

two weeks the patient may be allowed to sit up in bed, or to be moved upon a sofa or chair about the room. After four weeks he may be permitted to move about on crutches. Except when passive motion is being made, the splint should be worn night and day for the first ten weeks after the injury. After this it may be removed after retiring for the night and adjusted before rising, the posterior splint gradually shortened, and a figure-of-eight bandage about the knee should be worn for six months, to prevent a re-separation. After this a strong leather flexion-check should be worn for the next twelve months. After eighteen months of careful watching, such a ligamentous union will not give way, except under conditions which would break the bone. In two cases which came under my observation (the patients both males, one forty and the other about fifty-five years old) the ligamentous union was so strong that, several years after the first accident, they suffered a second injury, and the upper fragment parted transversely, the ligament holding intact. The foregoing method, which is practically that of Prof. Hamilton, is by far the most preferable treatment for this injury.

Many innovations have been made in the treatment of this fracture, some of which are unnecessary, others unjustifiable. Among the former may be mentioned *aspiration* of the effusion into the joint and between the fragments. This should only be done when the capsule is distended in an extraordinary degree. The most unjustifiable method of treatment ever introduced in this fracture is that of opening into the joint and wiring the fragments together. Unjustifiable because, first of all, it is dangerous; secondly, it is unnecessary. A careful observance of the rule of practice just laid down will secure a ligamentous union, with a restoration of the function of the extremity, equally as good in many cases as that enjoyed before the injury, and in the vast majority of cases equal to all the ordinary requirements of the limb, and this is accomplished without the slightest risk to the patient's life, and with no disturbance of his comfort beyond confinement to bed for two weeks, to the room for four weeks, and to his crutches and cane for about six months.

On the other hand, by wiring, although an osseous union may be obtained, the restoration of function is not more complete, the confinement in bed is longer, and the danger to life and the integrity of the part sufficiently great to deter the surgeon from employing this method of practice.

In September, 1881, induced by the reported successes after this operation, I wired a fractured patella on the twentieth day after the accident, in the case of a woman twenty years old. The strictest antiseptic precautions were employed, and free drainage was secured. Osteoarthritis with destruction of the joint resulted, and the patient barely escaped with her life, the limb having been amputated in the lower third of the thigh.* Another patient, in the hands of a New York surgeon,

* For a full report of this case, and a synopsis of other cases, see the author's paper in the "Medical Record," vol. xxi, 1882.

died as a result of this operation. If the full histories of all these cases were written I think few surgeons would have the temerity to repeat the procedure.

The employment of Malgaigne's hooks gives more pain and annoyance, and does not secure a result at all superior to the conservative method just given.

The plaster-of-Paris method is employed by some operators; but it is not to be preferred to the method of Hamilton. In this procedure the fragments are approximated by adhesive strips. One piece is cut in the shape shown in Fig. 342, the broad part of which is applied just above the upper margin of the upper fragment, and fastened here by a roller. The entire limb is now covered by a bandage which leaves exposed the two narrow strips of the adhesive plaster. Over this the plaster bandages are applied, strong traction being made upon the adhesive strips in order to hold the fragments approximated until the gypsum hardens. The limb should be enveloped from the ankle to the perinæum.

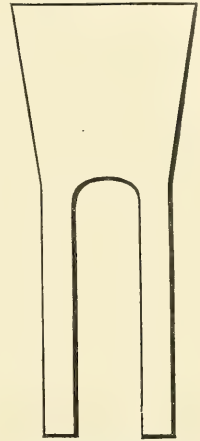


FIG. 342.—Gauntlet of adhesive plaster for exerting traction on the upper fragment of a fractured patella.

In old fractures, with wide separation of the fragments and permanent loss of function of the extensor muscles, the best prosthetic apparatus is a strong leather shield worn around the knee. This prevents too much flexion, and partly stiffens the joint.

Many cases of wide separation, however, retain the function of the limb in a remarkable degree. In a case occurring in my practice,

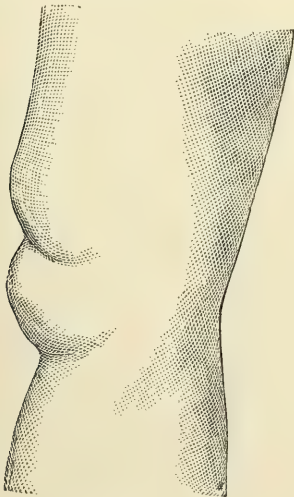


FIG. 343.

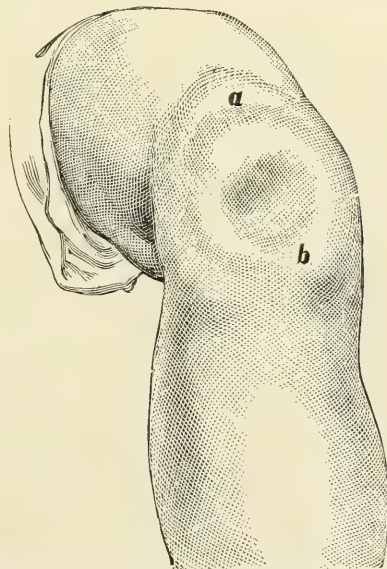


FIG. 344.—Wide separation of fragments (from *a* to *b*), with perfect function of limb.

from which the two accompanying cuts were taken, there is a separation of more than three inches with the leg flexed (Fig. 343), and nearly one inch

and a half in extension (Fig. 344); yet this patient has perfect use of the limb. No approximation of the fragments was ever attempted in this patient. He was kept in bed, with the leg elevated, for six weeks, and an ordinary roller applied after this, without any effort at bringing the fragments together.

Longitudinal fractures of the patella should be treated by fixation of the muscles of the thigh and leg, and lateral approximation of the fragments by flannel bandages, well applied over a thin layer of absorbent cotton.

Stellate fractures, in which the air is not admitted to the joint, should be treated by Hamilton's method.

In *compound* fractures of the patella in which the joint is laid open, the cavity of the joint should be carefully drained and strict antiseptics employed. If the fragments are widely separated, and can not be kept in approximation, strong catgut or fine wire sutures may be employed to hold them in position. Such instances will rarely occur.

Leg.—Fracture of one or both bones of the leg occurs next in frequency to that of the radius and ulna. The upper end of the tibia is usually broken by direct violence, although a fall from a height upon the foot may produce a longitudinal or oblique fracture communicating with the joint. The separation sometimes takes place through the epiphysis. The most common point of fracture is the junction of the middle and lower third. The fibula may be broken at the same level, or at a point removed from the line of fracture in the tibia, or this last bone alone may be broken.

Near the ankle-joint fracture of one or both bones is not uncommon. While a complete double fracture below the junction of the middle and lower third is rare, a partial fracture of the tibia (malleolus) and a complete break of the fibula is comparatively frequent. In this (Pott's) fracture (called also railroad or street-car fracture, since it is often caused by jumping from a car in motion) the foot is powerfully everted, the inner malleolus bent forcibly inward, and the strain falls upon the internal lateral ligament of the ankle-joint, the internal malleolus, the external malleolus, and outer tip of the articular surface of the tibia. As the force is continued, either the internal lateral ligament or the inner malleolus must yield, and, as usual in this test between ligament and bone, the latter yields. As a rule, the osseous rim is torn off with the ligament, or the entire malleolus is wrenched off at a higher point. The pressure upon the inner aspect of the external malleolus forces this outward, and the fibula above is bent inward and usually breaks at between two and three inches above the tip of the malleolus. If great force is exercised in the production of this fracture, the inferior tibio-fibular ligament may be torn away, or, more likely, the outer lip of the articular surface of the tibia broken off. In exceptional instances, inversion of the foot will produce fracture of the inner malleolus by direct pressure of the astragalus, and of the external malleolus or fibula by traction on the external lateral ligament.

In fracture of the tibia alone the displacement will be determined by

the direction of the line of fracture. Marked overlapping or displacement is prevented by the unbroken fibula. In the upper portion, with a transverse fracture, the deformity is slight. At the lower and middle third the obliquity is usually considerable, and from below upward and backward (Fig. 345). The upper fragment is tilted forward by the action of the quadriceps extensor, and partly by the pressure of the upper end of the lower fragment, which is thrown in the same direction by the contraction of the sural muscles and the consequent lifting of the heel. The

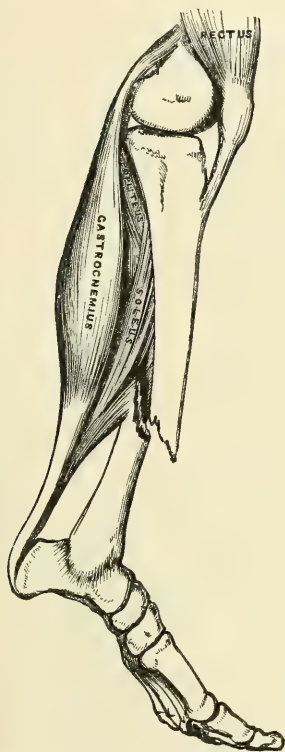

FIG. 345.—Displacement of fragments in fracture of the tibia, near the junction of the lower and middle third. (After Gray.)

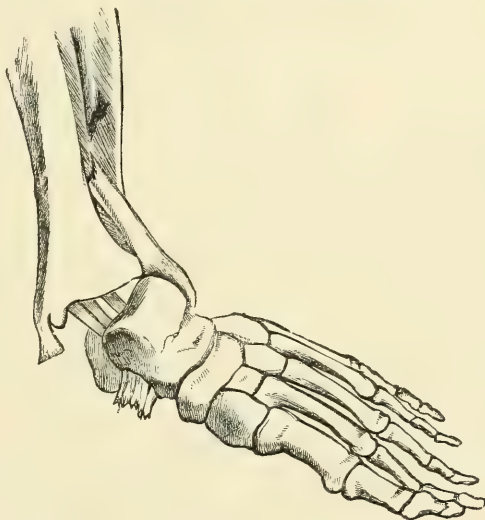


FIG. 346.—Displacement of the fragments in Pott's fracture. (After Gray.)

deformity in Pott's fracture is shown in Fig. 346. In complete fracture of both bones of the leg, overlapping and displacement are the rule.

Diagnosis.—Fracture of the fibula alone may exist without detection, although a careful examination, with direct pressure, will usually elicit crepitus or reveal the point of fracture by abnormal mobility and pain. Fracture of the tibia is easily made out by palpation along the spine, crepitus, loss of symmetry, and pain. These symptoms, together with the history of the accident, will leave little room for doubt in any case. Pott's fracture is recognized by the peculiar eversion of the foot, the abnormal prominence of the internal malleolus, pain, and loss of function. Crepitation of the fragments of the malleoli may be elicited, and preternatural mobility in the fibula, at a point two or three inches above the tip of the outer malleolus. In inversion with fracture the outer malleolus is prominent. Fracture of both bones is easily made out by the deformity, abnormal mobility, and crepitation.

Treatment.—In most cases of fracture of one or both bones of the leg it is the best practice to reduce the displacement by extension and coun-

ter-extension, and to fix the part in the position of least discomfort for from four to six days, or until all danger of swelling is past. After this time no method is so satisfactory as the plaster-of-Paris dressing.

To meet the first indication the fracture-box (Fig. 347) is a most useful apparatus. It consists of a bottom, a foot-piece, and two movable

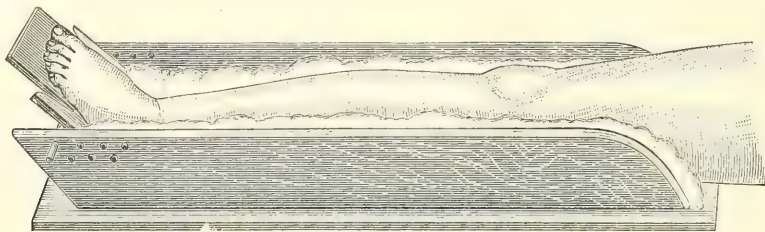


FIG. 347.—Fracture-box.

side-pieces. This may be placed upon a pillow or box to give it a slight elevation, or the apparatus may be modified after Petit's box (Fig. 348), since the position of positive flexion is usually more comfortable than full extension.

If any extension is needed it may be secured by a bandage around the ankle and foot, which is also passed through the holes in the foot-piece. In fixing the leg in this fracture-box the sides are turned down, a thick

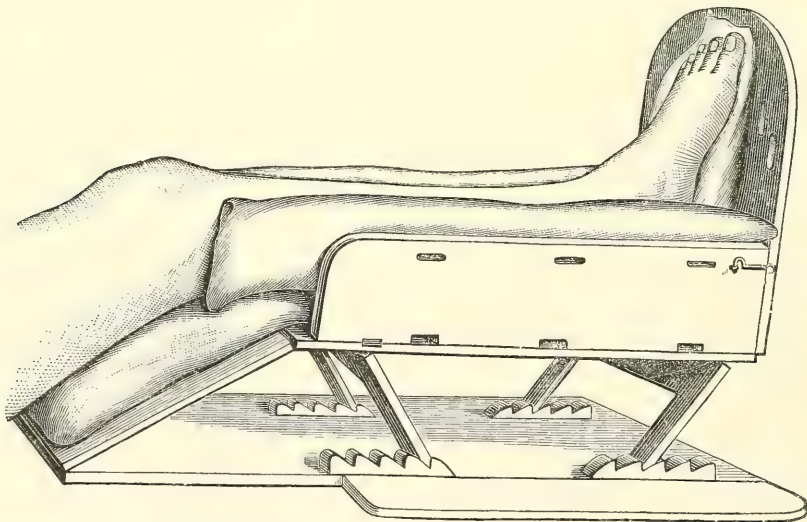


FIG. 348.—Petit's fracture-box. (After Stimson.)

layer of cotton or some soft material arranged for the leg to rest upon, and shaped to fit the natural contour of the calf. The sides are also packed, turned into position, and fastened. As soon as the first swelling subsides, or as soon as it is evident that no marked swelling will occur, the plaster of Paris should be applied. This dressing should extend at least half way up the thigh, in all cases, in order to fix the knee-joint. It is applicable to all fractures of one or both bones, from the knee down to and including the malleoli. Extension can usually be made from the

neel and ankle by an assistant. A dry muslin or flannel roller is first applied, and the plaster bandages laid on over this. A thin layer of absorbent cotton is at times placed between the first dry roller and the leg (Fig. 349). If swelling should occur, the plaster cast should be split down the middle line, in front and behind, and replaced, but not so tightly. When such a dressing requires frequent removal it is best to line the cut

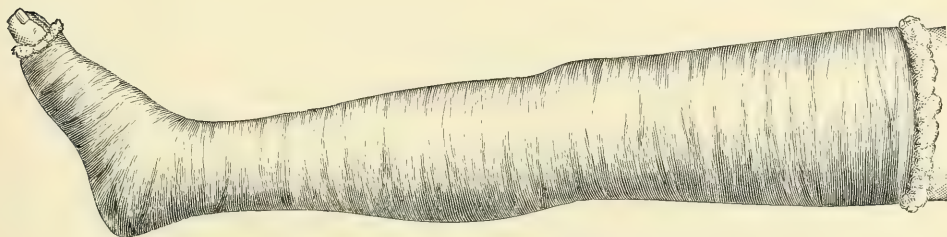

FIG. 349.—Plaster-of-Paris dressing in fracture of leg.

edges of the cast with adhesive strips, and to make hinges along the posterior seam out of the same material. At the end of four weeks all splints should be removed, passive motion made at the knee and ankle, and the apparatus reapplied and worn for at least two weeks more. Passive motion should be repeated each week.

In applying the plaster in *Pott's* fracture the eversion needs to be overcome and the straight position maintained while the gypsum is hardening. To accomplish this a piece of adhesive plaster about two inches wide is laid along the fibula side of the leg, as high as the upper two thirds, extending down over the external malleolus, and across the sole of the foot to the inner side. A muslin roller is next passed around the ankle over the inner malleolus. These tuberosities should be protected by bits of absorbent cotton. An assistant steadies the ankle by traction on the roller, while the foot is brought into straight position by traction on the adhesive strip. The plaster is now applied, and the foot held in position of slight over-correction until the cast hardens.

When plaster of Paris can not be had, starch is next in order, or splints of felt, leather, book-binder's board, metal, or wood may be employed.

Compound fractures of the leg are treated by immediate reduction of the deformity, by free drainage, and strict antiseptic precautions. For perfect fixation, and at the same time leaving the wound open for irrigation and inspection, the interrupted or the fenestrated plaster-of-Paris dressing is the most generally useful. If the injury is slight and limited, the fenestrated dressing is preferable. Extension is made from the foot, and, after reposition and drainage are secured, the plaster bandages are applied. As soon as the dressing sets, windows large enough to permit of free inspection are cut immediately over the wound and at the points of exit of the drainage-tubes below. A wire loop, worked into the plaster or tied around the leg after hardening has taken place, will serve as a medium for suspending the limb at any required height (Fig. 350).

The interrupted plaster dressing is more difficult of application. The entire leg and foot, and half way up the thigh, are covered with a dry flannel or muslin roller, which passes over the wound, retaining the sublimate and iodoform gauze in place. A strong piece of bar-iron, or two

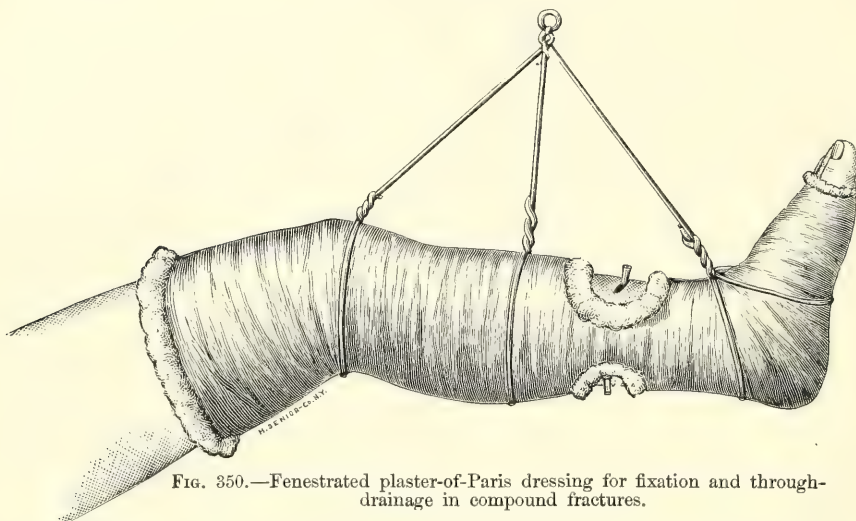


FIG. 350.—Fenestrated plaster-of-Paris dressing for fixation and through-drainage in compound fractures.

or three thicknesses of hoop-iron, or a twist of from four to six ordinary telegraph-wires, is now shaped to follow the outline of the foot and leg up to within three inches of the wound and exits of the drainage-tubes, at which point it is bent up for several inches, and passes over the wound much like the handle of a valise (see Fig. 351). As soon as a point three inches above the wound is reached it is again made to conform to the



FIG. 351.

shape of the leg and thigh. A separate straight piece of iron, or, if needed, two pieces, about sixteen inches in length, are also prepared. A layer of absorbent cotton is placed around the leg and thigh before the first bandage is applied, and over this the plaster rollers are carried, above and below the fracture, to within three inches of the wound. After several layers of bandage (generally three thicknesses) have been applied, this much is allowed to harden, and upon this the long iron splint is laid, in front, and the short pieces posteriorly and laterally (out of the way of the drainage-tubes), and are fixed by additional turns of the plaster bandages and by plaster mortar worked in with the hands. That portion of the bar which is shaped like the handle of a valise should be stiffened by winding around it several thicknesses of the plaster rollers, and adding a sufficient quantity of plaster mortar. Suspension is made from the ends and center of the wire.

The fracture-box may be employed when plaster can not be obtained.

Foot.—The bones of the tarsus may be broken by direct or indirect violence.

The diagnosis is not always easily made. The best method of treatment is fixation with a plaster-of-Paris dressing, after all danger of swelling has passed. When the os calcis is broken, and the tuberosity drawn up by the sural muscles, the leg should be flexed well upon the thigh, and the tarsus extended in order to relax this group of muscles.

Fracture of the metatarsal bones and phalanges should be treated in the same manner as the corresponding bones of the upper extremity.

Ununited Fractures—Fibrous Union.—In a certain proportion of cases union between the ends of broken bones is delayed beyond the time usually required for ossification, and may remain permanently ununited.

The *causes* of ununited fracture are: (1) Failure to secure immobility; (2) presence of muscle, tendon, nerve, or other substance between the fragments; (3) violent and prolonged inflammation of the broken bones and the surrounding soft parts; (4) any intercurrent disease which interferes with nutrition; (5) a too great separation of the fragments. If the ends of broken bones are not kept in contact, and at the same time immovable, fibrous union may result, for by motion the provisional callus is injured, and may disappear by absorption as a result of continued irritation. If the fragments overlap, so that no portion of the broken surface of one side is in contact with that of the opposite end, no matter how well adapted the dressing may be, muscular contraction may retard or prevent union.

The intervention of any of the soft tissues, or any foreign substance, may prevent the formation of callus, and lead to fibrous union.

Ostitis after fracture may lead to destruction of the fragments, and of the shafts of bone, to such an extent that union can not occur. Instances are on record where, resulting from fracture, rarefying ostitis has destroyed the entire bone.

Any general condition of impaired nutrition increases the liability to fibrous union. Rickets, osteomalacia, syphilis, scrofula, tuberculosis, or any acute febrile disease supervening upon fracture, tends to interfere with or to delay bony union after fracture.

When by any reason the broken surfaces are separated, osseous union will probably not occur. This accident and result are exemplified in fracture of the patella, where fibrous or ligamentous union is the great rule.

The *diagnosis* of fibrous union is determined from continued pre-natural mobility at the seat of fracture after two months have elapsed. Crepitus is not to be depended upon, as the ends of the fragments may be rounded off by absorption, and covered over with inflammatory newly formed material, or at times with cartilage.

Treatment.—The immediate indication is to correct any constitutional condition which may be present, and to increase general nutrition. Syphilis, or any recognized dyscrasia, must be specially treated. In the

administration of tonics, cod-liver oil, with the hypophosphites of lime and soda, should play an important part.

It is of importance to fix the broken part immovably by the plaster-of-Paris or other solid dressing. This should be removed after four weeks, in order to allow passive motion of any articulation near the seat of fracture, and necessarily included in the dressing. After the first movement of the joint the dressing should be reapplied and the passive motion repeated each week. Great care should be observed to prevent motion at the seat of fracture. If, after the lapse of from ten to fourteen weeks, there are no indications of union, a mild inflammation should be induced in the tissues immediately about the fracture. This may be accomplished by forcibly rubbing the ends of the bones together (after an anæsthetic has been administered), and then investing the member with the gypsum dressing. In obstinate cases more radical measures may need to be adopted. A favorite practice is to cut down upon the fracture, dissect away any new-formed tissue, and saw off the ends of the bones, back far enough to reach healthy and well-nourished bone.

It may sometimes suffice to cause inflammation and stimulate bone-formation by puncturing the skin with an awl or drill, and with the point of this instrument scraping the ends of the fragments.

If these measures fail, the bones should be freshened and brought together by silver-wire sutures, as advised in fracture of the jaw, or by transfixion with movable steel drills, in the same manner as given in excision of the knee-joint.

CHAPTER XIII.

SURGERY OF THE ARTICULATIONS.

Dislocations.—A dislocation is the displacement of the articular surface of one bone from its normal relation with another. Dislocations are *traumatic*, *pathological*, and *congenital*. They are also *partial* or *complete*, *simple*, *complicated*, and *compound*.

Traumatic dislocations are sudden, and result from violence; *pathological* when, from disease of the joint, the bones and ligaments are more or less destroyed; *congenital* when, from failure of development, the normal contiguity of the articular surfaces can not be maintained. A dislocation is said to be *partial* when any portion of the articular surfaces are still in contact; *complete* when one articular end overlaps the other; *simple* when there is no other lesion than displacement and injury of the capsule; *complicated* when there exists with the dislocation a fracture into the joint; *compound* when, by reason of a wound, the air is in contact with the dislocated surfaces. Again, a dislocation may be *recent* or *ancient*, the limit of the former variety being from a few hours to two or three weeks. A *primitive* luxation is one in which the dislocated surfaces retain the same position as at the time of the accident, *secondary* when another position is assumed.

In a dislocation the capsule may be ruptured, or simply stretched without a solution of its continuity. When great violence is employed in producing it, the muscles, tendons, nerves, vessels, fascia, and skin about the joint may be more or less involved. The changes which follow are practically those of acute synovitis, arthritis, or peri-arthritis.

Dislocations occur chiefly in adult life, and are most frequent in those joints which enjoy the greatest freedom of motion, and, at the same time, are subjected to the heaviest strains. The condition of the individual, the tonicity of the muscles, and the strength of the ligaments, have a great deal to do with the frequency of dislocations. All things being equal, patients with poorly developed muscles and relaxed ligaments are more prone to these lesions than the well developed and vigorous.

The diagnosis of a dislocation rests chiefly upon *abnormal immobility* and *asymmetry*. Pain is usually present.

Special Dislocations—Inferior Maxilla.—Displacement of the condyles of the lower jaw, from its articulation with the temporal bone, may occur on one or both sides; usually it is bilateral. The condyles slip

forward and are engaged partly beneath the zygoma, in front of the *eminentia articularis*, and partly between the zygoma and the temporal fossa. Muscular action alone may produce this luxation, or it may be caused by external violence.

The *symptoms* are great pain, difficult deglutition, and indistinct articulation (especially of the labial sounds). The lower teeth are unusually advanced, the mouth is widely opened, and the saliva trickles over the lips.

In unilateral luxation the chin points toward the sound side, and the teeth are less widely separated.

In the diagnosis the chief point of differentiation is fracture at or near the condyle. In fracture the condyle may possibly be recognized in its normal position by palpation; immobility is not marked; the mouth is not opened; crepitus may be obtained.

Reduction.—In bilateral displacement, wrap the thumbs with several layers of bandage or cloth, to protect them from being bitten when reduction is accomplished. Place one thumb along the inferior molars of each side, and the fingers beneath the body of the jaw; press downward and backward with the thumbs, while the fingers lift the chin upward.

Or place a thick roll of leather, piece of wood, or firm cork, between the upper and lower posterior molars of each side, and upon these, as a fulcrum, lift the chin upward, and at the same time push backward in the direction of the socket.

If both of these methods fail, they should be repeated under ether. It may sometimes be advisable to attempt the reduction of one side by either of the above methods, and retain it in position while reducing the other.

After reduction is completed put on a head and chin figure-of-8 bandage, and allow it to remain for a week (Fig. 24), or apply Hamilton's head-stall for fracture of the lower jaw (Fig. 311). In several instances, where the dislocation has become permanent, the symptoms have gradually subsided, and a fair degree of motion and usefulness acquired through the false joint.

Clavicle.—The sternal end may be displaced *forward* on the manubrium, *upward* above the sternum, *backward* behind the manubrium. The last two varieties are rare. The cause of the first form is usually force applied to the shoulder with the arm thrown backward. In the case of a boy fifteen years old, treated by myself, the displacement was caused by a comrade catching him by both shoulders, placing his knee in the middle of the back, between the shoulder-blades, and violently pulling the shoulders back.

The diagnosis is not difficult, the reduction easy, but the maintenance of the bone in position difficult. A compress, covered with adhesive plaster to prevent slipping, placed upon the bone after reduction, and firmly held in place by a roller, is a proper method of treatment. The arm should be fixed with Sayre's apparatus for fractured clavicle, in order to prevent a repetition of the luxation.

The outer end of the clavicle may be displaced above or below the acromion process, and above or in front of the coracoid process. Displacements under the acromion and in front of the coracoid are very rare.

The *symptoms* are very distinct, and the reduction not surrounded with great difficulty. When replaced, however, the bone is with difficulty maintained in position. By drawing firmly outward upon the shoulder of the affected side, and pressing the clavicle downward into position, reduction will be successfully accomplished. Place a firm compress over the end of the bone, bend the forearm at right angles to the arm, and carry one or two strong strips of adhesive plaster over the compress, behind the shoulder, along the arm to the olecranon, and again by the front over the compress. Re-enforce this by a bandage, and place the arm in a sling. If luxation recurs, tighten the adhesive strips, and place the arm in a Velpeau's bandage. To apply this bandage, place the hand of the affected side almost upon the opposite shoulder, fixing a wad of cotton beneath each axilla. Lay the end of a roller on the shoulder-blade of the sound side, and carry the bandage over the acromial end of the clavicle of the injured side, and the front of the arm for a short distance, passing obliquely to the under surface at the elbow, and around beneath the well axilla to the point of starting. Repeat this to secure the roller, and then carry the bandage horizontally around the chest and over the tip of the elbow. The oblique and horizontal turns are alternated until the shoulder and arm are completely enveloped (Fig. 352).

Humerus, at the Shoulder.—Dislocation at the shoulder-joint is by far the most frequent. It may take place in three directions—*backward*, under the spine of the scapula (*subacromial* and *subspinous*); *downward*, below the glenoid cavity (*subglenoid*); and *forward*, beneath the coracoid or clavicle (*subcoracoid* or *subclavicular*).

The first variety is of rare occurrence. The subacromial dislocation is only a partial displacement, and becomes complete when the head of the bone passes well beneath the spine of the scapula (Fig. 357). The subglenoid is more frequent, but not so common as the subcoracoid. Displacement forward under the clavicle is rare. On account of the coracoacromial ligament, and the additional protection afforded to the joint above by the acromion process, dislocation directly upward can scarcely occur.

Subcoracoid and Subclavicular Dislocation.—In the more frequent variety of luxation—the subcoracoid—the capsule is ruptured along the

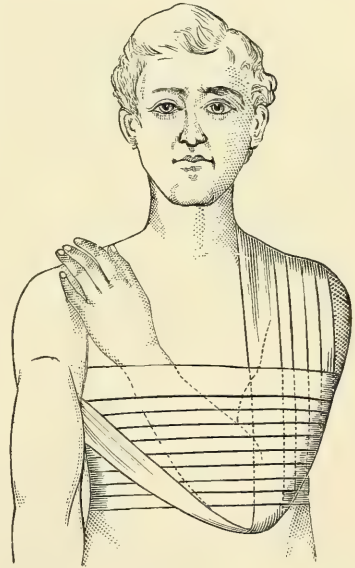

FIG. 352.—Velpeau's bandage. (After Stimson.)

lower and inner portion, extending to the insertion of the subscapularis muscle. It is caused by violence applied directly to the shoulder from without inward and forward, or to the elbow or hand when the extremity is extended. The head of the humerus rests upon and in front of the inner rim of the glenoid cavity and just underneath and in contact with the coracoid process (Fig. 359). The acromion process is unusually prominent, a depression is felt beneath it, while the head of the bone is seen and felt in an abnormal position beneath the coracoid. The humerus stands stiffly away from the chest at an angle varying from twenty to thirty degrees. The circumference of this shoulder, measured over the acromion and through the axilla, is greater by at least one inch than on the opposite side (Callaway). If the hand of the affected side is placed upon the sound shoulder, the elbow can not be carried down to the chest-wall (Dugas).

According to Kocher—whose researches are based on anatomical as well as clinical demonstrations, the obstacle to reduction is tension of the capsule, especially of the coraco-humeral ligament, with consequent closure of the rent through which the head of the humerus has escaped. If this displacement exists, by carrying the humerus directly down until the arm touches the side of the chest-wall, rotating it outward and then carrying the elbow in front of the chest to the middle line, the capsule is relaxed and the rent is opened. It only remains to rotate the humerus slightly toward the body, when the head slips through the opening back into its normal position.

Dr. Charles A. Powers, of New York, has shown that the recumbent posture is preferable to the sitting position which was original with Kocher. The steps of this method are well shown in the accompanying cuts taken from his article.*

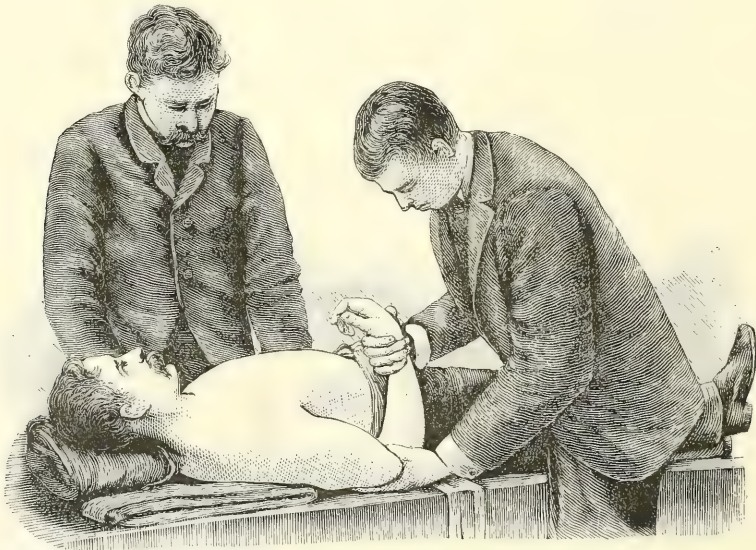


FIG. 353.—First Movement. The elbow is adducted to the body and drawn downward. (The arm and wrist should be firmly grasped, as shown in the figure.) (After Dr. C. A. Powers.)

* "Medical Record," March 30, 1889.

Method.—Place the patient on the back, upon a hard table or the floor, with an assistant holding the shoulder of the sound side firmly down. The operator grasps the member of the injured side at the wrist

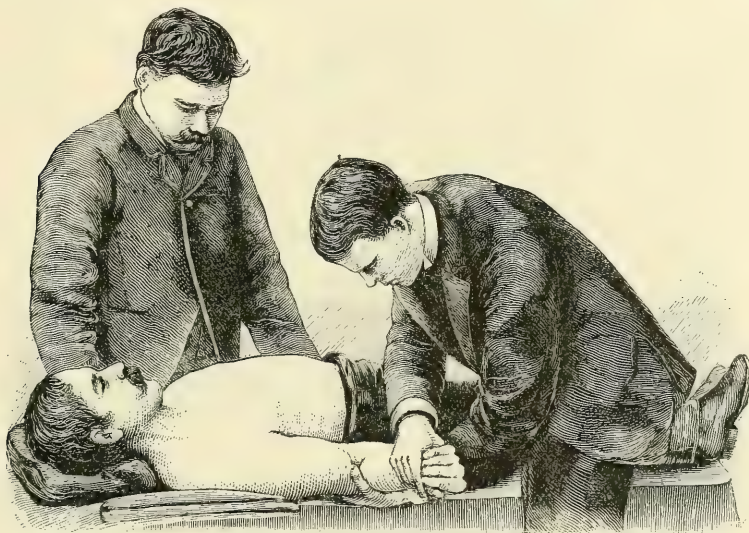

FIG. 354.—Second Movement. The arm is rotated out until firm resistance is met. (Practically until the long axis of the forearm points directly outward.) (After Dr. C. A. Powers.)

and elbow and brings the humerus well against the wall of the chest (Fig. 353). Outward rotation is made until the long axis of the forearm points directly outward (Fig. 354), when the elbow is brought along the front of the chest to the median line (Fig. 355) and the hand of

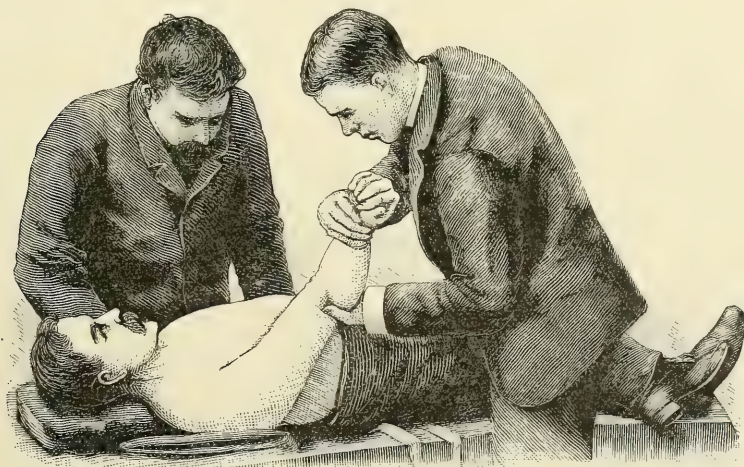


FIG. 355.—Third Movement. With the external rotation of the arm still maintained, the elbow is carried forward and upward on the chest. (After Dr. C. A. Powers.)

the affected side placed on the sound shoulder (Fig. 356). If this fail, repeat the procedure. An anæsthetic is not usually required, but should be given if, after two or three efforts, reduction is not accom-

plished. The method of using the foot in the axilla, as given for subglenoid luxation, may also be tried.

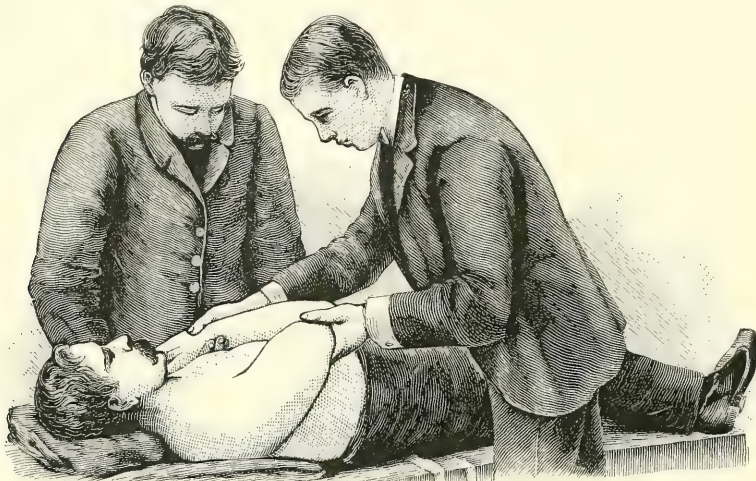


FIG. 356.—Fourth Movement. The hand is placed on the sound shoulder. (After Dr. C. A. Powers.)

The *subclavicular* variety of this forward dislocation is only an exaggeration of the subcoracoid, in which the head of the bone slips underneath and internal to the coracoid, and rests against the serratus magnus and behind the pectoralis minor, below the clavicle (Fig. 360). The causes are the same, and the symptoms differ in little else than the presence of the head of the humerus nearer to the clavicle. The arm stands slightly out from the body, and the elbow is tilted backward. The tension on the posterior scapular muscles is greater, and rupture of their attachments often occurs, while the anterior insertion of the subscapularis may be dissected up. Pressure on the axillary vessels and nerves is more marked in this luxation. Reduction may be effected by the means just described.

Subglenoid Dislocation.—In the subglenoid luxation the capsule is stretched or torn along its lower surface, and the head of the humerus rests upon the margin of the glenoid cavity in a partial dislocation, or, if

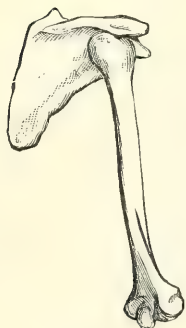

FIG. 357.
Subacromial and subspinous. (Bryant.)

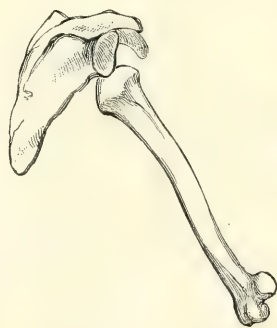

FIG. 358.
Subglenoid. (Bryant.)

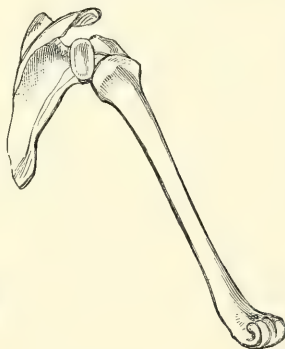


FIG. 359.
Subcoracoid. (Bryant.)

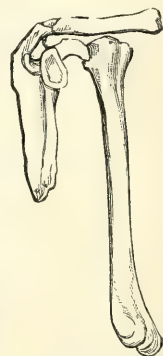

FIG. 360.
Subclavicular. (Bryant.)

the capsule is torn, it (usually) slips in front of the long tendon of the triceps, and is lodged upon the axillary border of the scapula, immediately below the articular surface (Fig. 358). The supra-spinatus muscle is severely stretched, and either suffers rupture of its tendon or substance, or, rather than yield, it may tear off a rim of the upper facet of the greater tuberosity. The long head of the biceps and the coracobrachialis are also subjected to great strain or rupture, while the tension of the deltoid holds the arm in a position with the elbow slightly tilted from the side of the body.

Among the less frequent complications of this lesion may be mentioned pressure upon the circumflex and axillary nerves, and injury or rupture of the great vessels.

The cause of this dislocation is violence applied to the shoulder in a direction from above downward, or indirectly to the hand, forearm, or elbow, with the humerus raised at or beyond an angle of 90° to the axis of the trunk.

The *diagnosis* of a subglenoid luxation will depend upon the following symptoms: The acromion process is unusually prominent, the head of the bone is not in its normal relation to this process, and may be felt low down in the axillary space. There is a depression in the anterior axillary fold in these subjects. The arm is fixed in such a manner that the elbow is directed outward from the side of the body (Fig. 361). As in all the shoulder dislocations, the arm is so held that, if the hand of the injured side be placed on the opposite shoulder, the elbow can not be made to drop down upon the wall of the thorax. This, the test of Dugas, is important in differentiation from fracture in which there is such a considerable degree of motion possible that the arm can be brought well down upon the chest.

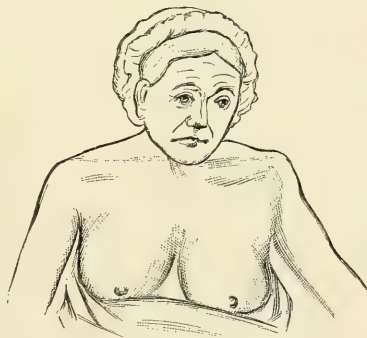

FIG. 361.—Subglenoid. (Bryant.)

There is always preternatural immobility in a dislocation. Another excellent method of differentiation is that of Callaway, based upon the fact that the circumference, measured over the acromial end of the clavicle and the acromion, and through the axilla, is in a dislocation much increased over the normal, or over that present in fracture at the neck. Crepitus, when obtained, will determine a fracture.

Reduction—First Method.—Place the patient upon a table, bed, or upon the floor. For the left shoulder the operator removes the shoe from the left foot and places it in the axilla, against the thorax. He now seizes the arm and forearm of the patient, carries it out at a right angle to the axis of the patient's spine, and makes powerful traction in the direction of the glenoid cavity. While this is being effected the arm is brought inward, parallel with and against the side of the body (Fig. 362). The foot not only serves to effect counter-extension, but is also used as a fulcrum for lifting the head of the bone over the edge of the

glenoid facet into the articular cavity of this process. If this can not be accomplished without ether, after one or two trials the anæsthetic

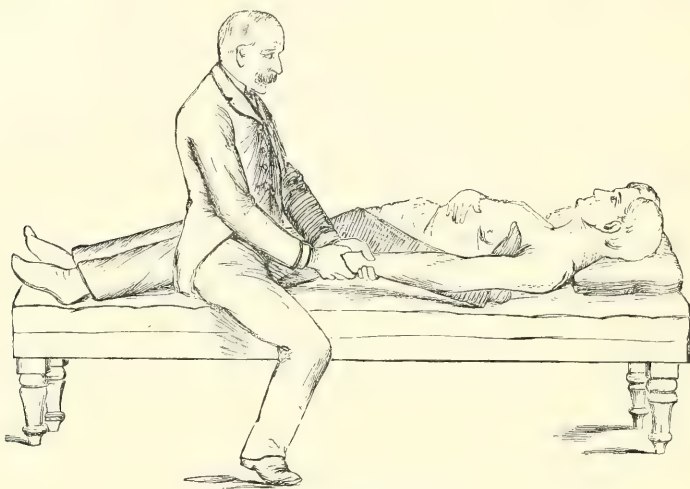


FIG. 362.—(Erichsen.)

should be given. After reduction a shoulder-cap of book-binder's board, leather, or gutta-percha should be applied, and worn for at least one week.

Second Method.—Fix the scapula by placing a folded sheet or long cloth around the body, so that the upper margin of the cloth will touch the axillary folds. The ends are intrusted to an assistant, who, standing on the sound side, makes counter-extension. The surgeon now takes hold of the arm about its middle with one hand, and near the elbow with the other, and carries it slowly and steadily away from the body, and in the direction of

least resistance. When it is at a right angle to the axis of the body, strong traction is made, with slight axial rotation. If the manœuvre is still unsuccessful, carry the arm higher, until extension is made in the line of the axillary border of the scapula (Fig. 363).

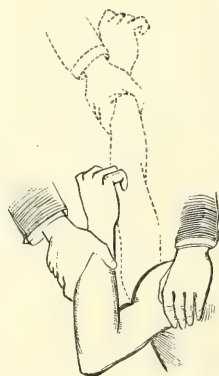


FIG. 363.—(Bryant.)

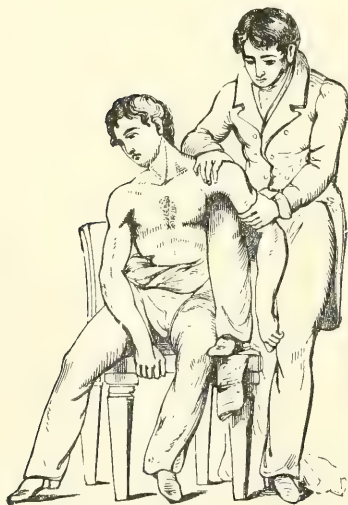

FIG. 363 A.—(After Hamilton.)

Third Method.—Place the patient in a chair, so that, with the foot of the operator on the edge of the seat, his knee will come snugly into the axilla. Place one hand upon the shoulder to steady it, while the other seizes the arm near the elbow. With the knee as a fulcrum, use the hu-

merus as a lever, which, being depressed, carries the head of the bone into position (Fig. 363 A). Extension from the forearm, and counter-extension through the medium of the opposite arm, may also be employed.

The *subacromial* and *subspinous* dislocations are reducible by extension and counter-extension in the line of displacement. Counter-extension may be made by an assistant holding the arm of the sound side, or by the folded sheet (already described) applied just in the axilla. The operator makes extension from the arm and forearm, imparting to the humerus a slight axial rotation.

General Considerations.—Recent dislocations at the shoulder may not always be reduced, and some which are readily replaced are with difficulty held in position. Rupture of any muscle, or group of muscles, renders the luxation subject to recurrence, since there is no antagonism to the remaining muscles. Even when reposition is effected and maintained, the function of the joint may be permanently impaired on account of injury to the surrounding structures. Injury of the circumflex nerve has been followed by atrophy of the deltoid and teres minor, while traumatism of the great cords of the axillary plexus and injury of the vessels have led to impairment or loss of function in the extremity. Ligature of the subclavian artery and amputation have been necessitated after dislocation of the shoulder-joint.

These injuries may occur at the time of the displacement, or they may be produced by a lack of skill or the employment of too great force in the efforts at reduction.

After one or two days from the date of a luxation at the shoulder (as elsewhere) the difficulties of reduction increase, and are in general proportionate to the length of time which has elapsed since the accident. At the expiration of the first week inflammatory adhesions occur, and the cavity of the joint is in part filled with the products of inflammation. In rare cases reduction has been accomplished at the end of three, six, and twelve months.

The propriety of attempting reduction in ancient shoulder luxations will depend upon the individual case. It will frequently occur that, in the new position, attachments are formed, with ligaments, cartilage, and synovial membrane, with fair, yet limited, motion in the false joint, which, together with the free mobility of the scapula upon the thorax, gives a useful degree of motion to the arm. Under such conditions any attempt at reposition is unnecessary.

In well-selected cases, where an ancient dislocation can not be reduced by any other means consistent with safety to the tissues about the joint, and where motion is so limited that the usefulness of the arm is seriously impaired, direct incision, under strict antiseptic precautions, may be employed, and reduction thus effected, with or without excision of the head of the humerus. After the head of the bone is returned to its normal position, drainage should be secured through the rent or incision in the capsule. A *Neuber's* bone-drain, or a soft rubber tube, may be employed, and should be so placed that it will lead downward from the most dependent portion of the capsule.

Dislocations at the Elbow-Joint.—The upper end of the radius may be displaced forward on to the anterior surface of the humerus, near the coronoid fossa, or backward upon the olecranon process. The anterior displacement is met with somewhat more frequently than the posterior.

In the displacement forward the orbicular and a portion of the external lateral and anterior ligaments are ruptured; in the opposite luxation only the first two are lacerated.

The *forward* displacement is caused by direct violence applied to the posterior aspect of the upper end of the radius, or by falling upon the palm of the hand while the forearm is completely extended, the full force of the contraction of the biceps being thus added to the force transmitted along the shaft of the bone.

Symptoms.—Careful palpation will reveal the abnormal presence of the head of the radius near the center of the humerus, while pressure along the outer condyle will demonstrate its absence from its natural position. The forearm is semiflexed and slightly pronated.

Treatment.—Flex the arm and push the head of the bone forcibly downward in the direction of the articulation. When reduction is accomplished, place a compress over the upper end of the bone and the external condyle, and bind it firmly in position. The arm should be snugly bandaged, and carried in a sling for several weeks.

The backward dislocation is recognized by the presence of the head of the bone in an abnormal position near the olecranon, behind the external condyle.

Treatment.—While an assistant makes strong extension and counter-extension from the hand and arm, the operator makes direct pressure upon the head of the bone, forcing it in the direction of the articulation. As the displacement is being corrected the assistant should carry the forearm in a position of supination. The after-treatment consists of a compress and bandage, worn for several weeks.

The *prognosis* of this injury is generally not favorable, since it is very apt to recur after reduction, and may become permanent. A fair degree of usefulness is maintained, however, in many cases of chronic luxation of this end of the radius.

Complete forward dislocation of the ulna alone, at the elbow, can not occur without fracture of the radius or extensive laceration of the radio-ulnar ligaments.

Subluxation of the Head of the Radius.—This lesion is met with usually in children from nine years old and under, and is much more common than complete dislocation at this joint. It is caused by sudden traction on the hand or forearm in lifting a child by a single arm or in saving it in the act of falling.

The symptoms are loss of function, the arm often hanging as if it could not be moved. Motion at the wrist may be, however, free. Pressure over the head of the radius causes sharp pain. Passive flexion at the elbow is permitted to about 60°, when resistance may be met with. Complete extension is also painful. With the forearm flexed at right

angles to the arm, pronation is possible, but is slightly resisted, while supination causes great pain. If, however, this movement is carried to the extreme, a distinct click may be heard and felt at the head of the radius, with which the pain suddenly ceases and free motion is re-established (W. W. Van Arsdale).^{*} Reposition is thus effected. With the patient sitting or standing in front of the operator, he grasps the arm just above the elbow with one hand, while with the other the forearm is seized near the wrist. The forearm is now flexed to an angle of ninety degrees with the arm, and steadily rotated into a position of extreme supination. As above stated, the reduction is accompanied by a perceptible slip or click. A splint should be applied to hold the arm quiet in the right-angle position for four or five days.

The pathological conditions of this lesion are not thoroughly understood. Since it is caused by pulling upon the radius, the cup-shaped articular facet of the head of this bone is evidently abnormally separated from the humerus. One theory is that the soft parts are interposed either by muscular action or by atmospheric pressure, while another holds that the edge of the head of the radius is slightly locked on the humerus, a complete dislocation being prevented by the integrity of the capsule.

Dislocation of *both radius and ulna* at the elbow may take place in all directions.

The dislocation backward may be produced by falling upon the hand with the forearm almost extended; by a blow upon the anterior aspect of the forearm, near the elbow, a blow upon the posterior surface of the humerus, in its lower portion, or force applied at the same time, in opposite directions, upon these surfaces. The coronoid process will be found lodged in the olecranon fossa, the upper end of the radius resting on the posterior aspect of the external condyle.

The anterior ligament and the anterior fasciculi of the external and internal lateral ligaments are torn loose, and in extreme cases the orbicular ligament may give way, although the yielding of the external ligament usually saves the circular ligament from being torn. The tendon of the brachialis anticus is stretched or is broken loose from the coronoid process. Pressure upon the brachial artery may be so great that pulsation at the wrist is diminished or absent, while in extreme cases the median, ulnar, or musculo-spiral nerves may be injured.

The usual position of the forearm is one of almost complete extension, with pronation. Measurement from the inner condyle to the styloid process of the ulna will demonstrate shortening. Muscular rigidity is marked, and motion of the displaced bones difficult and painful. From these symptoms the diagnosis can be readily made. If swelling has ensued, and the tumefaction is great, it is not always easy or possible to recognize the character of the injury. Under such conditions it is wise to reduce the swelling by rest and local application for a few days, until the exact character of the luxation may be determined.

^{*} "Annals of Surgery," June, 1889.

Treatment—Reduction—Method of Astley Cooper.—With the patient seated in a chair, the operator places his foot on the seat so that the anterior aspect of the patient's forearm will be brought in contact with the anterior surface of the surgeon's knee. The forearm should now be grasped near the wrist and forced flexion made, using the knee as a fulcrum, and at the same time as a point of resistance to the extension made by pulling upon the forearm (Fig. 364).

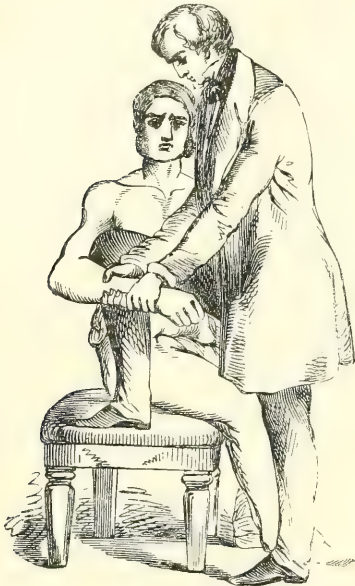


FIG. 364.—(Erichsen.)

Flexion unlocks the coronoid process from the olecranon fossa, and extension carries both bones forward into position. Unless the operator is positive that perfect reduction has been accomplished, the joint should be freely flexed and extended to test its working capacity. Care must be taken to hold the muscles in check while this manipulation is going on, for fear the bones may again slip out of place. Bandage the arm and forearm, and apply a splint, which should be worn for a week or two. When an anæsthetic is used the

recumbent posture should be maintained. The bare foot may be utilized instead of the knee.

A cloth or sheet folded around the arm, just above the elbow, may be used for counter-extension.

Liston advised strong extension from the forearm, and counter-extension from the shoulder, with the arm and forearm held straight.

Dislocation of the radius and ulna *forward*, without fracture of the olecranon, is of rare occurrence, and is always the result of great violence. Rupture of the posterior and lateral ligaments occurs, and the triceps tendon is torn or greatly stretched, while the brachialis anticus and biceps are relaxed. The posterior portion of the olecranon rests upon the anterior articular aspect of the humerus, or may slip into the coronoid fossa. The forearm is bent at an angle varying from 90° to 120° to the anterior surface of the humerus, and is well supinated. Motion is painful and limited. The character of the injury may be determined by the absence of the olecranon projection, the smooth, broad, posterior surface of the lower end of the humerus being readily appreciated.

Treatment.—An anæsthetic is usually required. With the forearm held at about a right angle to the arm, make extension from the wrist, and counter-extension from the lower anterior surface of the humerus, in order to disengage the olecranon process from the coronoid fossa, and, when this is effected, make direct pressure downward upon the anterior aspect of the forearm, near the elbow. After the bones slip seemingly into position, careful examination should be made to see that the radius is in its proper relation to the external condyle, for the ridge between the

two sigmoid cavities of the ulna may lodge in the groove between the trochlear surface and the articular surface for the head of the radius.

In the *outward lateral* dislocation the luxation is usually partial. The cause is direct violence applied to the inner aspect of the forearm, near the joint, or to the outer aspect of the humerus, low down, or to force applied simultaneously, in opposite directions, upon these two surfaces.

The *diagnosis* will rest chiefly upon the increased prominence of the inner condyle, and the difficulty of recognizing the outer condyle by palpation. The angle at the elbow is about 120° , motion is wanting, and the hand is pronated. Reduction is best effected by strong extension from the forearm, counter-extension from the humerus, and direct lateral pressure in the direction of the displacement.

Inward dislocation is always incomplete (Hamilton). The causes are direct violence in the opposite direction to that given for the luxation outward. The internal condyle will be less prominent, the external more prominent, the olecranon will be seen crowded over to the inner aspect of the joint, while the head of the radius rests near the middle of the articular surface of the humerus. The position of the forearm is that of flexion. Reduction is difficult, and should be effected in ether narcosis. Extension and counter-extension should be made in the flexed position, and the arm gradually brought out straight, while at the same time direct pressure is made, in proper and opposite directions, upon the humerus and forearm, near the joint.

Dislocation of both bones backward is the most frequent form of displacement at the elbow. Incomplete external and incomplete internal luxation are next in order of frequency, while the forward dislocation is most infrequent.

In the posterior variety the direction of the force may be such that a deviation to one or the other side may occur. The treatment is practically the same. Direct lateral pressure in the line of the normal position of the bone may be required in addition to the mechanism of reduction above given. Partial ankylosis is not infrequent after these lesions. Passive motion should be begun within two weeks after the injury, and repeated daily if no acute inflammation is produced.

Wrist-Joint.—Dislocations at the carpo-radial joint are very rare. Only a few instances of complete *backward* or *forward* luxation of the carpus are on record. Lateral dislocations are considered impossible without fracture of the styloid process of the radius or ulna. The two principal displacements occur with about equal frequency. In the *backward* variety the anterior aspect of the carpus rests upon the dorsal rim of the cancellous expansion of the radius, the reverse being true in the dislocation *forward*. The anterior and posterior ligaments are partially or completely ruptured, and the annular ligament, which binds the tendons down, may be torn and the tendons displaced.

The *cause* of the *backward* displacement is a fall on the back of the hand, or a blow upon the dorsum of the radius, just above the wrist, while the hand is in extreme flexion. Violence of a similar

character, applied in the opposite direction, will produce the *forward* luxation.

The *diagnosis* must be made between Colles's fracture and dislocation. In *dislocation* the deformity from the over-riding carpus is much greater than after fracture. In Colles's fracture the swelling on the dorsum of the wrist is smooth and rounded. When impaction has not occurred crepitus may be obtained.

Reduction is effected by extension and counter-extension from the forearm and hand, to which direct pressure in the line of displacement should be added.

Dislocation of the *metacarpal* bones, at their carpal extremities, is rare. Luxation of the metacarpal bone of the thumb is most frequently met with. The carpal end of this bone may be displaced partially or completely, in a *forward* or *backward* direction. When the end of the bone rests upon the dorsum of the trapezium it can be easily recognized.

Extension and counter-extension, with direct pressure, is usually sufficient to accomplish reposition. A clove-hitch or snare may be thrown around the thumb to insure extension. Reduction is at times difficult, and the history of this accident is not without a record of failure both as to replacement and retention when replaced.

In the displacement forward, on account of the thickness of the soft parts, the end of the bone can not be easily recognized. An unusual depression may be observed on the radial and dorsal aspects of the wrist, just in front of the os trapezium.

Strong extension with counter-extension is necessary, and to this should be added direct pressure, applied near the end of the displaced bone.

Luxation of the remaining metacarpal bones occurs rarely, and, when met with, the displacement is usually partial, and toward the dorsum of the carpus.

The *phalanges* may be dislocated either *backward* or *forward* at the metacarpal articulations, or at the interphalangeal joints. The character

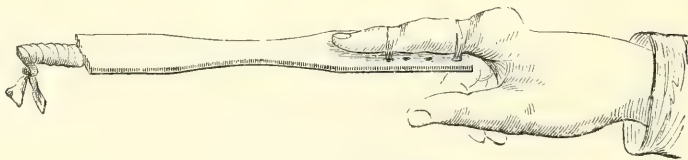


FIG. 365.—(After Hamilton.)

of the lesion is easily recognized, and the reduction, as a rule, is not difficult. Extension with a clove-hitch, or with the apparatus shown in Fig. 365, will effect reduction. In some instances operative interference is demanded when reposition by extension and pressure can not be effected. Careful asepsis should be observed. On opening into the joint, the resisting ligaments should be snipped with a sharp bistoury, when the displacement may be easily corrected.

Hip-Joint.—While the head of the femur may be displaced from the cotyloid cavity in any direction, it is customary to consider *four* distinct

luxations: (1) *Upon the dorsum ilii*; (2) *into the ischiatic notch*; (3) *into the obturator foramen*; (4) *upon the os pubis*. Practically these lesions occur in each of the quadrants of a circle, the center of which is the center of the acetabulum.

As shown in Fig. 366, about 50 per cent of all luxations at the hip occur in the iliac quadrant, 30 per cent in the ischiatic, 11 per cent in the obturator, and 7 per cent in the pubic. Two per cent occur beyond these regions. Cases are on record where the head of the bone was lodged on the tuber ischii, in the perinæum, and just beneath the anterior-superior spine of the ilium.

The capsule is usually torn at its inferior and posterior surface. It may be a slit or tear in the long axis of the ligament, or frequently a broad rupture occurs along the edge of the cotyloid cavity. The ligamentum teres (when present) is always torn. The ilio-femoral (or Y) ligament is very rarely completely ruptured. The injury to the muscles and surrounding structures is always

severe, and varies in proportion to the degree of violence which caused the luxation, together with the particular direction of the displacement.

In the displacement upon the *dorsum ilii* the glutei muscles may be lacerated, bruised, or lifted from the ilium by the head of the bone, but not by tension on their tendons, for, with the exception of the lower fibers of the maximus, their axes are slightly shortened in the new position. The obturator internus, externus, gemelli, and quadratus femoris are greatly stretched, or torn entirely loose. The pyriformis is not so apt to suffer. The pectineus, iliacus, and psoas are carried upward and outward. When the head of the bone is projected into the *ischiatic notch*, the conditions as to the muscles are practically unchanged. The sciatic nerve and vessels are pressed upon and may be contused or lacerated. In the displacement upon the pubes the psoas and iliacus may be injured, while the femoral vessels and anterior crural nerve are more or less pressed upon. When the head of the bone is lodged in the *obturator foramen*, the obturator externus muscle and the obturator vessels and nerves are more or less contused, while the glutei and the remaining external rotators are put upon the stretch.

Causes.—Dislocations at the hip may be congenital, pathological, or traumatic in cause.

Congenital luxations, rare in occurrence, are the result of interference

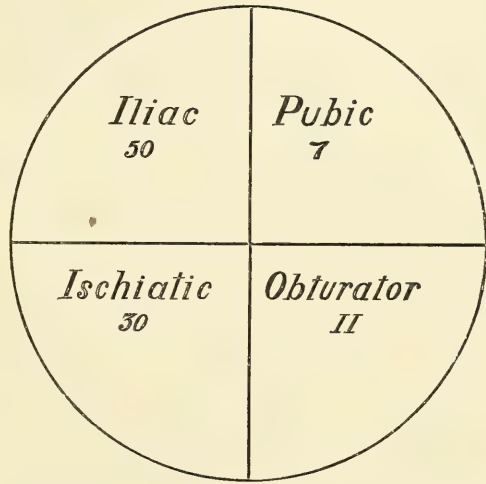


FIG. 366.—Showing the proportion of displacement in the four quadrants of a circle about the acetabulum.

with normal development. Failure to complete the process of ossification in the three bones which compose the acetabulum leaves a soft and fibro-cartilaginous cup or sac, through which, when the weight of the body is sufficient, the head of the femur is more or less completely displaced into the pelvic cavity. Absence of the ligamentum teres is not alone sufficient to account for displacement when the bones, capsule, and muscles are normal, for it is not infrequently absent in cases which have never suffered a luxation. Moreover, the majority of cases in which this ligament has been ruptured by one luxation do not suffer a second displacement. An abnormally long, loose, or relaxed capsule will lead to sub-luxation or displacement without rupture of the capsule. Failure of development from the cervical epiphysis is another cause of congenital dislocation at the hip.

Pathological dislocations are caused by chronic arthritis. The bones are more or less destroyed, and the capsule breaks down, permitting dislocation of the head of the bone as a result of muscular action or slight violence.

Traumatic luxations are direct or indirect. The most frequent cause is a fall from a height or from a carriage in motion, the person striking upon the foot or knee, with the thigh carried in such a direction that its axis is at a considerable angle to that of the spinal column.

Anatomically considered, the most favorable position for the two posterior, and by far the most frequent displacements, is when the thigh is flexed at about an angle of 90° to the axis of the body. If the thigh be adducted, the tendency is to rupture the capsule on its posterior-inferior surface, with escape of the head on to the *dorsum ilii*, or into the *ischiatric notch*. When in a position of abduction, the rupture is likely to occur on the lower anterior aspect of the capsule.

A fall directly upon the trochanter, with the thigh in adduction or abduction, with extreme outward or inward rotation, is apt to produce rupture of the capsule and luxation.

Symptoms.—In dislocation upon the *dorsum ilii*, with the patient standing erect upon the uninjured extremity, the trochanter of the displaced femur will be nearer the anterior-superior spine of the ilium than that of the opposite side; the thigh is slightly flexed upon the abdomen, adducted, and rotated inward. The head of the bone may be appreciated




FIG. 367.—Position of extremity in dislocation of the head of the femur upon the *dorsum ilii*. (After Hamilton.)

in the new position. The shortening is from one to two inches, and in the vast majority of cases the great toe of the injured side is directed to or rests upon the instep of the opposite foot, while the knee of the luxated side is in front of, and slightly above, its fellow (Fig. 367). Muscular rigidity and fixation are extreme. In very exceptional cases there is eversion of the foot, with slight abduction, which Prof. Bigelow holds to be due to extensive and unusual laceration of the ilio-femoral ligament.

When the head of the bone is lodged in the *ischiatric notch*, the general characters of the deformity are the same, yet not so well marked. The degrees of flexion and adduction are less extreme, the trochanter is less prominent, and there is not so much shortening.

In the *thyroid* displacement the

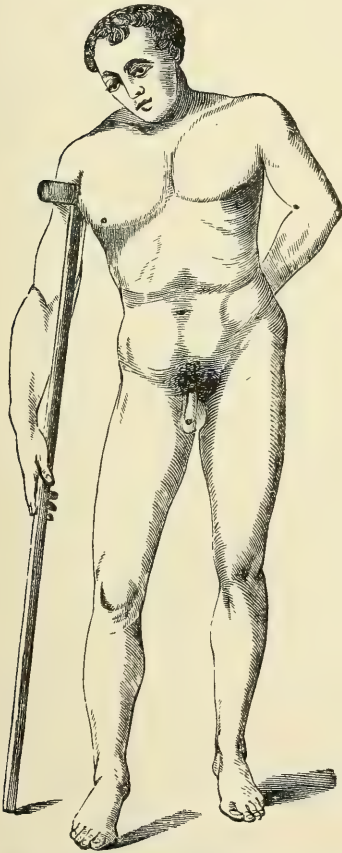


FIG. 368.—Position of extremity in dislocation of the head of the femur into the thyroid foramen. (After Hamilton.)

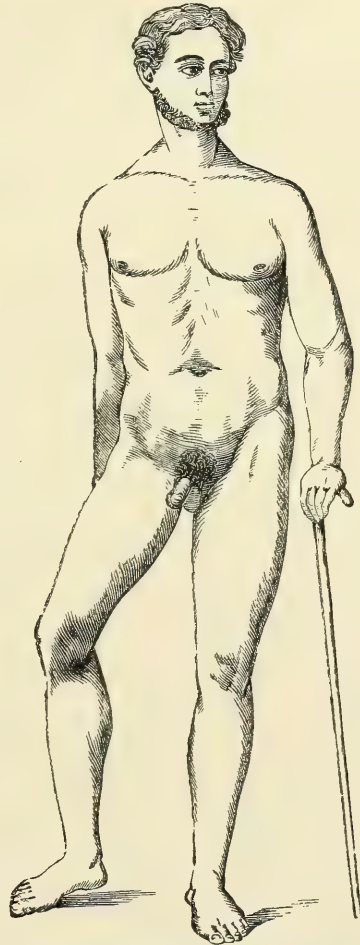


FIG. 369.—Position of extremity in dislocation of the head of the femur upon the pubes. (After Hamilton.)

extremity is increased in length, and the thigh is abducted and slightly flexed upon the abdomen. The toes may be turned slightly in or out, although they usually point to the front. The hip is less prominent than normal. The head of the femur may at times be recognized in the new position, although, on account of the tense condition of the adductor muscles, this is in some instances impossible (Fig. 368).

When the dislocation occurs *on the pubes* there is abduction, slight flexion, and slight outward rotation. The foot is carried away from that of the sound side, and the toes are pointed outward. The chief diagnostic feature of this displacement is the presence of the head of the bone at Poupart's ligament (Fig. 369).

The differential diagnosis is between muscular spasm or rigidity and fracture.

Spasm or rigidity of the muscles about the hip may occur as a result of an acute or subacute inflammatory process in the joint, or in the periarticular tissues, or in certain cases of ostitis of the lumbar vertebræ, sacrum, or ilium, in the neighborhood of the psoas and iliacus muscles. This condition of partial immobility may be differentiated from that of dislocation by the absence of the *shortening*, which is present in the displacement on the dorsum ilii and into the ischiatic notch, the *lengthening* in the thyroid luxation, while the head of the bone on the pubes will determine the character of this lesion. The absence of the characteristic deformity of each of these forms of dislocation will determine the diagnosis of muscular spasm or rigidity. The symptoms of fracture near the hip have been given. *Shortening*, *preternatural mobility*, and *crepitus* are to be chiefly relied upon in differentiation.

Reduction—Dislocation on the Dorsum Ilii—Bigelow's Method.—In complete ether narcosis, place the patient upon a strong, low table, or upon the floor, in the dorsal decubitus. Grasp the leg of the dislocated side, just above the ankle, with one hand, and near the knee with the

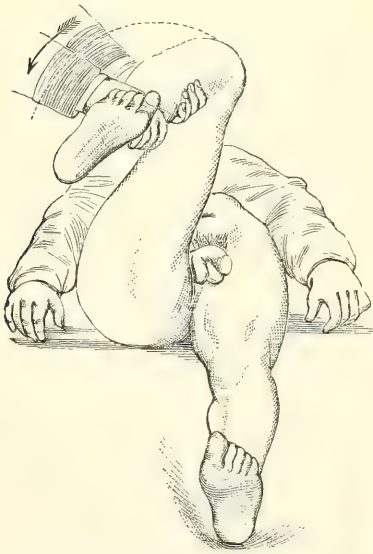


FIG. 370.—Reduction of dislocation on the dorsum ilii by manipulation. (After Bigelow.)

other, flex the leg on the thigh, and the thigh on the abdomen, to nearly an angle of 90° with the surface of the floor, adduct the thigh until the knee of this side is carried to about the middle of the sound thigh, and then cause the knee to describe a circle *outward* and *downward* until the leg is brought to the floor in its normal position (Fig. 370). If the luxation is not reduced the manœuvre should be carefully repeated. This method of reduction by manipulation is based upon the resistance to reduction which is made by the ilio-femoral ligament (when this is not torn).

The normal position of this ligament is shown in Fig. 371, and its relaxation by flexing the dislocated thigh upon the abdomen is shown in Fig. 372; and it is readily seen that if, with the thigh in this position, abduction, with outward rotation, is practiced, the head of the bone will be lifted over the margin of the acetabulum and carried in the direction of the socket.

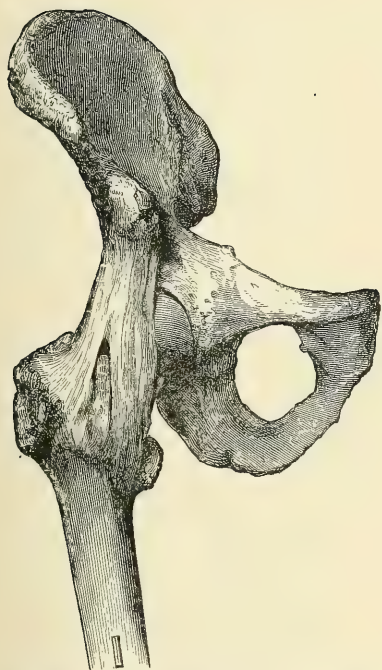


FIG. 371.—The ilio-femoral or Y ligament. (Bigelow.)

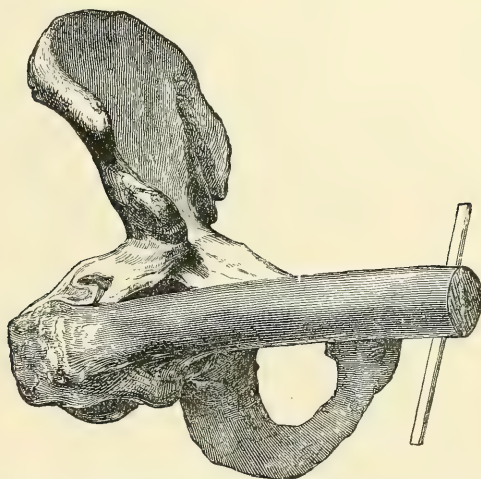


FIG. 372.—Relaxation of the ilio-femoral ligament by flexion and adduction of thigh. (Bigelow.)

Crosby's Method.*—Place the patient on the floor, in the dorsal decubitus. Flex both legs on the thigh, and the thighs on the abdomen, and, with the arms locked underneath the knees, raise the patient from the

floor so that the body will rest only on the neck and shoulders. If, after suspension lasting two or three minutes, reduction is not accomplished, the patient should be swayed from side to side, thus adding alternately slight abduction and adduction to the extension. While the displacement may be overcome without anæsthesia, it is much more easily and surely effected with it.

The same result may be accomplished by employing vertical extension in the manner recommended by Bigelow and shown in Fig. 373.

Hamilton's Method.—The patient is in the dorsal decubitus, and the limb is grasped as in Bigelow's method. "Flexing the leg on the thigh, the knee is to be carefully lifted toward the face of the patient, until it meets with some resistance; it must then be

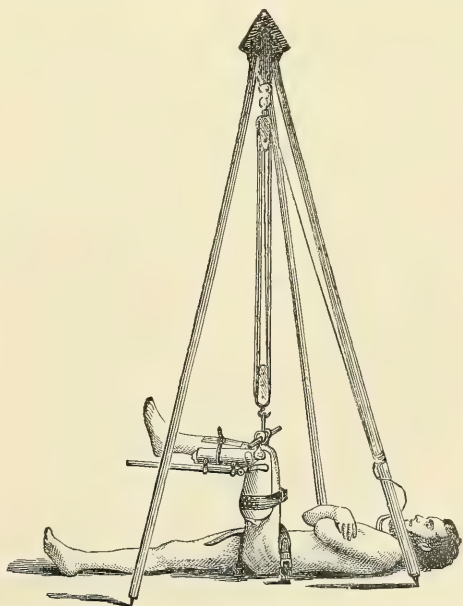


FIG. 373.—Reduction of dislocation on the dorsum ilii by vertical extension. (Bigelow.)

* This method was introduced by the late Prof. A. B. Crosby.

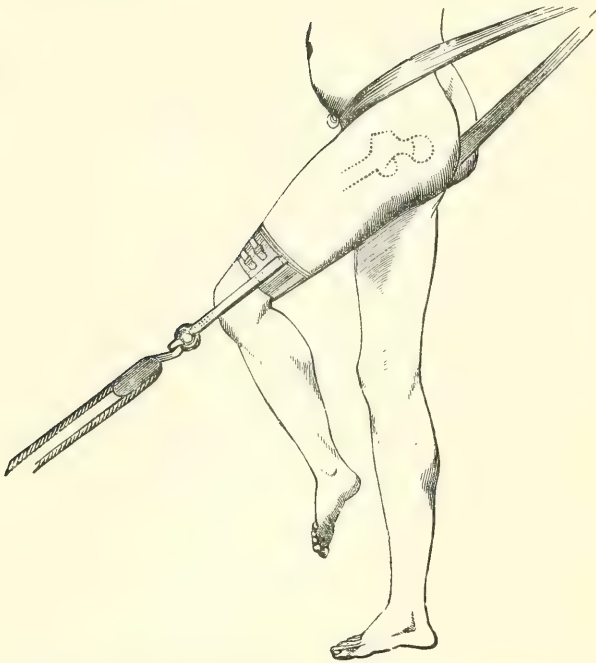


FIG. 374.—Cooper's method of extension and counter-extension in reduction of dislocation into the ischiatic notch. (Hamilton.)

the head of the femur reaches the margin of the acetabulum, it may be deflected below the rent in the capsule, and lodge in the thyroid foramen.

If extension and counter-extension after the older method (Astley Cooper's) be necessitated, the pelvis should be fixed by a sheet folded and passed through the perineum and over the groin, and extension made from above the knee, with the thigh flexed almost to an angle of 90° with the abdomen, and adducted until the knee is carried in front of the opposite thigh (Fig. 374).

Reduction of Dislocations in the Thyroid Foramen—Method of Bigelow.—Place the patient upon the floor, in the dorsal decubitus, flex the leg on the thigh, and the thigh on the abdomen, making, at the same time, slight abduction. Then rotate the femur inward, adduct, and carry the knee to the floor.

The older method involved extension in a lateral direction, by means of a sheet folded and

moved outward and slightly rotated in the same direction, until resistance is again encountered, when it must be brought downward again to the bed."

The older method of violent extension, by means of blocks and pulleys, should not be employed, unless all other means have failed.

Reduction of Dislocations into the Ischiatic Notch.—In this luxation the mechanism of reduction is practically the same as for the preceding displacement. One point must be guarded against—the danger that, when

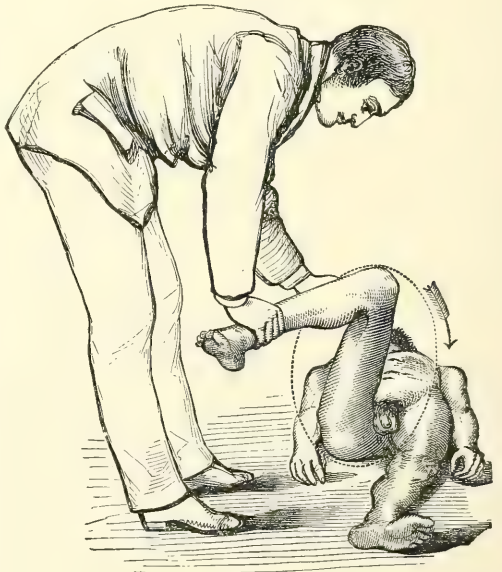

FIG. 375.—Reduction of dislocation into the thyroid foramen. (Bigelow.)

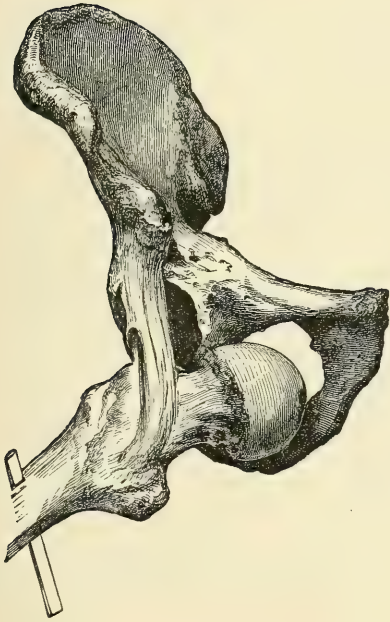


FIG. 376.—Showing the relation of the ilio-femoral ligament in dislocation of the head of the femur into the thyroid foramen. (Bigelow.)

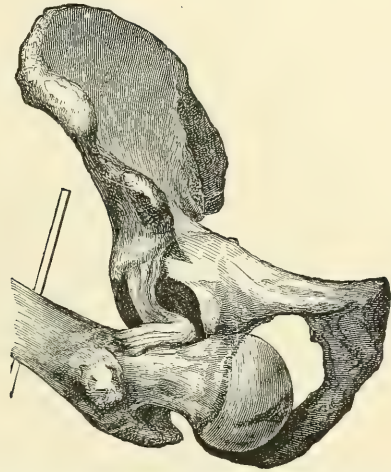


FIG. 377.—Showing how flexion of the thigh on the abdomen relaxes the ilio-femoral ligament in dislocation into the thyroid foramen. (Bigelow.)

passed around the inner surface of the thigh, while the pelvis was fixed by a sheet passed around this part of the body, and upon which traction was employed in an opposite direction (Fig. 378). If

pulleys can not be had, the sheet which is carried around the thigh should be tied into a loop and laid over the shoulder of the operator.

Reduction of Dislocations upon the Pubes—Hamilton's Method.—

When the head of the bone is lodged well over the pelvic rim the thigh should be abducted and rotated outward, in order that the head may be thus lifted over the pubes, and then flexed upon the body, adducted, and brought down. Rotation outward should cease as soon as the head of the bone has risen above the pubes. When the head has not passed above the rim of the pubes, outward rotation is not called for.

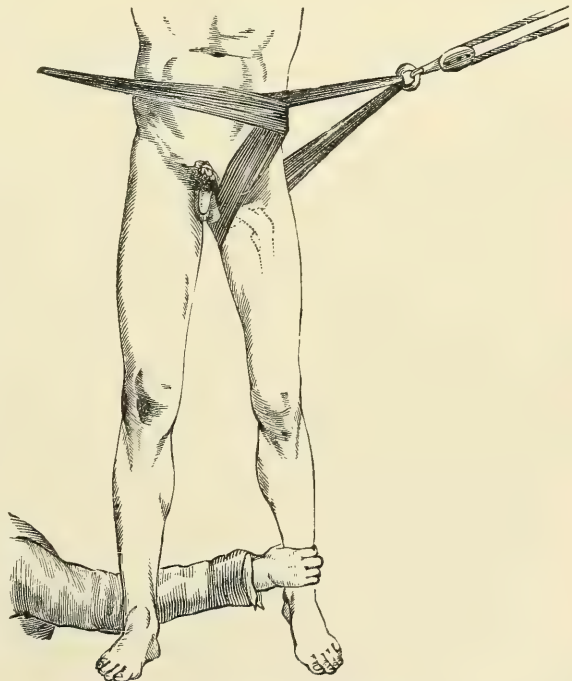


FIG. 378.—Cooper's method of reducing dislocation into the thyroid foramen. (Hamilton.)

If in this manœuvre the bone slips into the thyroid foramen, the manipulation given for this luxation should be practiced.

By Extension and Counter-Extension—Hamilton's Method.—Place the patient upon the edge of a bed or table, so that the injured limb may

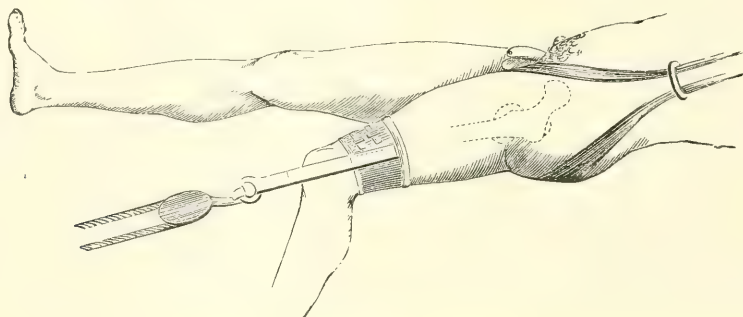


FIG. 379.—Reduction of dislocation upon the pubes by extension and counter-extension. (Hamilton.)

fall slightly over the edge. Extension is made from the thigh, and counter-extension from the perinæum and groin, in the direction indicated in Fig. 379.

The *after-treatment* of hip-luxation involves fixation of the muscles about the joint for from two to six weeks. A gutta-percha, heavy pasteboard, or leather splint, molded to the side of the pelvis, thigh, and down to the ankle, applied upon a thin layer of absorbent cotton, and held in place by a leg-, thigh-, and spica-bandage, should be employed.

The *prognosis* as to rapid restoration of function is not always favorable. The injury to the capsule, and more especially to the muscles around the joint, may lead to an impairment of the hip, more or less permanent. In permanent luxations, in some instances, a fair degree of mobility may be developed. Reduction has been successfully performed as late as four and six months after the injury.

The treatment of *congenital* dislocations of the hip, and of *pathological* luxations, will be given later.

Dislocations at the Knee—The Tibia from the Femur.—Displacement of the femoral end of the tibia may occur as a result of *congenital malformation, disease, or accident.*

Congenital luxation is rare, and is usually partial. As a rule, the tibia is displaced forward, although the opposite condition may prevail. Absence of the patella has been observed in several of these cases.

Pathological dislocations will be given under the head of diseases of this joint.

Traumatic luxation at the knee is comparatively rare. The tibia may be completely or partially displaced, and in any direction. Partial dislocation is the rule. Complete luxation is apt to be complicated with a wound. A compound dislocation usually occurs forward or backward. The *cause* is direct violence. A blow upon the anterior aspect of the tibia, near the joint, or the posterior-inferior portion of the femur, may

cause a *backward* displacement of the tibia, while violence from opposite directions may produce a *forward* dislocation. The same force applied laterally may also produce the *lateral* displacements. A favorable condi-




FIG. 379 A.—The author's case of backward dislocation of the tibia at the knee, caused by stepping into a hole while in the act of running. (From a drawing by Dr. Mewborn, fifteen years after the accident.)



FIG. 379 B.—The same, after exsection.

tion for luxation is the application of violence when the leg is in extreme flexion. A sudden twisting or wrenching of the femur upon the tibia when the foot is so caught that rotation on the heel is impossible, is favorable to rupture of the ligaments, and lateral or oblique incomplete luxation.

The *symptoms* of dislocation at the knee are usually clear. In the *backward* variety the antero-posterior diameter of the knee is increased, the tibia projects into the popliteal space, and the condyles of the femur are unusually prominent. In the *forward* variety the antero-posterior measurements are also increased, the anterior edges of the tibia are easily detected in the advanced position of this bone, while the condyles of the femur are unusually prominent posteriorly. The tibia may be rotated upon its axis. In the *lateral* displacements the condyle of the femur is recognized as projecting on one side, while the flat end of the tibia is felt on the opposite side. The transverse diameter of the joint is increased in proportion to the degree of displacement, which is, however, rarely complete.

Treatment.—Reduction is readily effected by extension and counter-extension, with direct pressure and counter-pressure in the proper direc-

tions. Once reduced, fixation should be secured by Buck's extension, with sand-bags applied to the limb, or an investing splint should be employed.

The *prognosis* after this injury is unfavorable. The function of the joint is rarely fully restored. The question of *amputation* after dislocations of the knee, where there is extensive injury of the surrounding structures, is one of great importance. Shock is more profound in this luxation than in dislocation at any other joint. A primary amputation will rarely be justified except after laceration of the popliteal vessels. All antiseptic measures should be employed, and amputation only advised after every effort consistent with the safety of the patient's life has been made. Exsection is preferable, and offers not only a greater degree of safety but a more useful result.

Dislocation of the Patella.—This bone may be displaced by muscular action, without the aid of external violence, or by an injury alone. When the ligamentum patellæ is ruptured, it is carried *upward* for a varying distance by the contraction of the quadriceps. It can only be displaced *downward* by a blow received upon its upper margin sufficient to tear it loose from its muscular attachments. Dislocation *outward* is the more frequent variety, and occurs as a result of muscular contraction and from violence. Displacement *inward* is the result of a blow received upon the outer margin of the bone. In the *lateral* dislocations, in rare instances, the patella is turned obliquely on its edge, or it may possibly be completely inverted.

The *symptoms* of these various luxations are unmistakable, and the reduction, by relaxing the quadriceps and pressure, not difficult.

The after-treatment is directed to the prevention of recurrence.

Dislocations at the Ankle-Joint.—Dislocations at the tibio-tarsal articulation may occur in four directions, viz., *forward, backward, inward, and outward.* In the last two forms fracture of one or the other malleolus is apt to occur.

Dislocation of the tibia *inward* is caused by a fall upon the foot at a time when it is turned outward, the body-weight being brought to bear upon the inner aspect of the heel and great toe. This form of sprain is frequently caused by leaping from a wagon or car in motion. It may also result from a heavy blow upon the fibular side of the leg, near the ankle, when the foot is solidly fixed against the ground. The displacement is usually partial. A complete luxation is apt to be compound.

The *symptoms* of *inward* dislocation are the great prominence of the inner malleolus and the peculiar twist of the foot, so that the inner side of the heel and the great toe rest on the floor while the sole looks obliquely outward and upward. The only displacement it may be mistaken for is that of the astragalus from the os calcis.

The *treatment* is to bring the foot into the normal position by pressure and counter-pressure, and fix it with a splint and bandage. On account of the great swelling which is likely to occur, an immovable dressing should not be applied until the acute symptoms of inflammation have subsided.

The *symptoms* of *outward* displacement are the reverse of the inward, and can without difficulty be recognized. Displacement of the tendons

of the long and short peronei muscles, from their sheaths behind the external malleolus, is likely to occur in this accident. After reduction at the joint these should be pushed into place, and an effort (rarely successful) made to hold them in position by a compress and bandage, applied before the splint for the luxation is adjusted.

Forward dislocation may occur as the result of a blow upon the back of the leg, near the ankle, while the foot is firmly placed upon the ground; by falling forward with great violence, when the momentum of the body is suddenly arrested by the foot striking against the ground; or by falling backward, with the foot so fixed that great and unusual extension of the tarsus takes place.

The *symptoms* are unnatural prominence of the heel, shortening of the distance between the toes and the front of the tibia, on the displaced side.

Reduction.—Place a clove-hitch around the heel and instep for extension, and make counter-extension from the thigh. Flex the leg so as to relax the sural muscles, and make forcible extension from the foot. As soon as the extension is well begun the operator places his foot against the front of the patient's tibia, just above the ankle, and pulls forward on the foot, at the same time flexing it on the tibia.

Backward displacement is caused by violence applied in a direction opposite to that which produces the *forward* luxation, and the *symptoms* are exactly the reverse.

The *treatment* demands reduction by extension and counter-extension, and direct pressure.

Dislocations at the ankle are often complicated with fracture, or may be compound. In any form of injury an effort should be made to save the foot and joint. The ankle is exceedingly tolerant of surgical interference, and, with strict cleanliness and antisepsis, amputation on account of complicated or compound dislocation will be rarely necessary.

The fibula may be displaced from its articulation with the tibia at its upper or lower end. At the upper end it is usually luxated forward, as a result of direct violence from behind, although it is possible to have the reverse occur. The bone will be felt in the abnormal and anterior position, and may be pushed directly back into place. In the backward displacement the biceps muscle may produce the luxation, or it may be from violence applied from the front. Strong and continued pressure must be employed to retain the bone in position until adhesions occur. During the treatment the leg should be flexed on the thigh in order to relax the biceps.

At the lower end dislocation of the fibula alone, without the tibia, is exceedingly rare. Anatomically, it may occur in both directions. Reduction may be effected by direct pressure. The fibula may be displaced outward from the tibia by the astragalus being driven upward between these bones.

Dislocations of the Bones of the Tarsus.—The *astragalus* may be partially or completely dislocated forward, backward, outward, or inward. The luxation is usually incomplete. On account of the great violence necessary to its production it not infrequently is compound, or

complicated with a fracture. Violence of the same character as that which produces displacement of the tibia will cause dislocation of the astragalus.

Treatment.—Luxation of the astragalus is a serious accident. The efforts at reduction do not always succeed, and, even when reduction is effected, the injury to the joint may be such that loss of function results. Direct pressure and counter-pressure, while the patient is profoundly anaesthetized, offer the best means of successful reduction. Displacements of the metatarsal bones and phalanges of the toes are treated in the same general way as described for similar lesions of the hand.

The Vertebrae.—Dislocation may occur at any articular surface of the vertebral column. The accident is always serious, the gravity being proportionate to the degree of displacement and the injury to the cord and nerves.

Luxations are more common in the *cervical* region. One or both articular processes may be displaced forward or backward upon the vertebra below. In the *unilateral* displacement the fibro-cartilage between the bodies is only slightly involved, and, while there is pressure upon the nerves passing out of the intervertebral foramen, there is no pressure upon the cord. In the *bilateral* form the cartilage is torn, the body more or less involved in the luxation, and the cord compressed.

The *causes* are muscular contraction, or violent twisting of the neck by accident.

The *symptoms* of unilateral displacement are pain—which may be referred to the distribution of the nerves passing through the intervertebral foramen involved—at the seat of luxation and rotation of the head, in a forward dislocation, so that the chin points to the side opposite to that upon which the injury exists. When the luxation is backward, the face is turned toward the seat of injury.

In the case of a young lady which came under my observation, the right articular process of the fourth cervical vertebra was displaced forward by sudden and violent muscular contraction. Pain was acute at the seat of luxation, and numbness down the right arm indicated compression of some of the filaments forming the brachial plexus. Reduction was effected as follows: The patient being seated in a chair, the shoulders were held immovable and the head further rotated to the left; then strong extension was made by lifting the patient from under the chin and occiput, at the same time carrying the head back to the right. Relief was immediate and permanent.

In bilateral luxation careful extension and direct pressure and counter-pressure should be practiced.

Dislocation of the condyles of the occipital bone from the atlas is probably always fatal. Luxation at the atlo-axoid joint, with fracture of the odontoid, is also fatal.

Ribs.—The ribs may be displaced from their vertebral articulations. The cause is direct violence, and the displacement usually forward. The true ribs may be dislocated at the junction of these organs with their cartilages, near the sternum. The treatment for these luxations is the same as for fracture.

DISEASES OF THE JOINTS IN GENERAL.

The simplest form of inflammation in a joint is that of the synovial membrane with which it is lined, or *synovitis*. A similar condition of the sheaths of the tendons of certain muscles is known as *theclitis*.

When the ligaments of a joint become involved in the inflammatory process the condition is known as *syn-desmitis*; when all the structures of the articulation—as bone, cartilage, ligaments, synovial membranes, etc.—are involved, it is an *arthritis*, or, as it is sometimes called, *osteo-arthritis*.

Synovitis may be acute or chronic, traumatic or idiopathic, circumscribed or general. It may precede or follow a *syn-desmitis*. If the process of inflammation in the lining membrane is not very mild, lasting only a few hours, it must of necessity involve the ligaments upon which its basement-substance rests. On the other hand, a peri-arthritis which invades the ligamentous structures of a joint will also produce a synovitis.

The process of inflammation in acute synovitis is primarily confined to the joint capsule, since the lining membrane is not reflected on to the articular cartilaginous surfaces. Hyperæmia and dilatation of the capillaries in the basement membrane occurs, followed by escape of leucocytes into the inter-capillary spaces and into the capsule, proliferation of the normal epithelia, and general effusion into the cavity of the joint.

The synovial fluid is increased in quantity, richer in cell-elements than normal, and may be discolored by the escape of red blood-corpuscles or free hæmatin. The result of this process is distention of the capsule and communicating bursæ, infiltration of the basement membrane with embryonic cells, which are the common product of all the proliferating cell-elements in the tissues involved.

Synovitis may terminate in various ways. If the process is acute yet mild, and all the conditions of the individual tissues favorable to rapid repair, resolution may occur without invasion of the ligaments, cartilages, or bones. The escaped corpuscular elements undergo fatty metamorphosis, together with those of the embryonic tissue, and these elements, with the excessive fluid in the capsule, are absorbed. The functions of the joint are soon restored.

Under less favorable conditions the acute process may pass into a sub-acute and chronic synovitis; the embryonic granulation-tissue remains, the normal epithelial lining disappears, giving way to a dirty fungus-like granulation-tissue, which thickens the entire capsule and projects on all sides into the cavity of the joint. The ligaments may soften and ultimately break down, the cartilages become eroded, or a periostitis and ostitis may be precipitated by invasion of the bone, from the point of junction between the synovial membrane and the osseous tissue—a true *arthritis*.

The *causes* of synovitis are predisposing and direct. It may be said that any *dyserasia* (which in itself indicates a low order of tissue-nutrition) encourages the development of a synovitis, and, once inaugurated, feebly resists its progress. Tuberculosis, syphilis, gout, rheumatism, the

eruptive fevers, traumatic septicæmia, and gonorrhœa may be mentioned as the chief predisposing conditions, while excessive use, a blow or a sprain, or exposure to cold, are common exciting causes of synovitis.

The chief *symptoms* are pain and swelling. Under direct pressure or motion the former is increased. Both are due to hyperæmia and the distention of the capsule from the effusion. Local elevation of temperature is present.

The *treatment* is local and constitutional. Rest, in the position of greatest comfort, is essential. Mild extension, to a degree to insure fixation, affords marked relief in most cases. Cold, applied by means of the ice-bag, is invaluable. Heat may be used, as hot cloths, the hot-water bag, or immersion in hot water, if cold is distasteful to the patient. Extreme pain, with marked distention, should be immediately relieved by aspiration. Among the many useful local medical remedies are lead-and-opium wash, vinegar, solution of the subacetate of lead, and various liniments. Compression by means of absorbent cotton and a flannel bandage is useful after the acute symptoms have subsided.

The constitutional treatment looks to the correction of any existing disease, the administration of well-selected articles of food, and tonics.

When *synovitis* becomes a chronic affection, aspiration and irrigation of the capsule and joint are the most effectual methods of treatment. The manner of operating is as follows: Shave the joint to be operated upon thoroughly, and wash it with ether and with 1-to-3000 sublimate solution, and apply a disinfected rubber or flannel bandage around the part, leaving a small space exposed at the point where the needle is to be inserted. Wash out the instrument and needle with 5-per-cent carbolic-acid solution. Exhaust the aspirator, push the needle into the joint without wounding the cartilage, and turn on the stop-cock which leads into the vacuum. When the flow ceases, close the cock, empty the cylinder and fill it with 1-to-10000 corrosive-sublimate solution, and force this into the capsule, to its full distention; then exhaust it, place on an antiseptic dressing, and compress and lock the joint with plaster of Paris, liquid-glass, or some fixed apparatus or splint. This operation may be repeated as often as needed, always guarding against the admission of air to the capsule, which may usually be prevented by keeping the cylinder of the aspirator higher than the needle. The air will rise and remain in the upper chamber of the instrument. The joint should be kept quiet for about six weeks, and the dressing then removed to allow careful passive motion. If the fluid has re-accumulated, repeat the operation.

Not infrequently a synovitis passes uninterruptedly on into an *arthritis*, in the manner already described. In the majority of instances, however, the destructive lesions of the joints, which obstinately resist all ordinary methods of treatment, commence in the cancellous tissue of the bone in the immediate vicinity of the epiphyses; in other words, destructive *arthritis* is secondary to *ostitis*, and this inflammation of bone is almost always the result of a dyscrasia and an accident of nutrition.

The opinion which has prevailed—namely, that almost all lesions of

the joints were caused by a traumatism—has been proved by the accumulated experience of many accurate and conscientious surgeons to be unscientific and without foundation in fact.

The pathology of *ostitis* has been dwelt upon on a previous page. That form of inflammation of bone which leads into *arthritis* begins in an interference with the normal nutrition of the growing bones. As stated, the primary lesion is capillary rupture or tuberculous deposits in the cancellous expansions, near the articular surfaces. It is known that in growing bones rupture of a vessel, with extravasation of blood, is very common, even in healthy children. It must be still more frequent in those children suffering from any dyscrasia which not only renders the capillary walls less strong, but lessens the reparative power of the tissues involved in the area of extravasation.

Tuberculous Arthritis.—By far the more frequent form of subacute and chronic arthritis which comes under the surgeon's observation is tubercular in character. Tuberculous arthritis may originate in the deposit of the *bacilli of tuberculosis* directly in the synovial membrane or articular structures proper or indirectly by invasion from foci of this disease in or near the epiphyses contiguous to the joint. Though not uncommon in adult and older life, it is much more frequent in children. The symptoms of tuberculous joint disease vary in some respects owing to the direct or indirect involvement of the cavity. There is also a marked difference between traumatic arthritis and this specific form of infection.

Acute arthritis is always a painful affection, and is almost always traumatic in origin. In tuberculous arthritis pain is rarely acute, often absent or at least denied by the patient, and most frequently present, but intermittent and mild in character.

When the tuberculous deposit is primarily met with in the capsule, the interference with the function of the joint is not material until the disease has so far progressed that disintegration is occurring. The joint is usually swollen or distended, the accumulation of fluid at times being so grave as to require aspiration, but not infrequently disappearing rapidly without surgical interference to refill seemingly without periodicity and without an exciting cause.

When tubercular ostitis precedes the arthritis, pain of a mild character is more apt to be a fixture. In all of these cases, however, the dyscrasia may be recognized either from a study of the patient or of the family history.

The treatment of these cases, both constitutional and local, will be taken up with the special management of the various joints.

DISEASES OF SPECIAL JOINTS.

Of the Hip.—Arthritis of the hip, hip-joint disease (*morbus coxæ*, or *morbus coxarius*), is a frequent and formidable affection, and one which, in many instances, will baffle the best medical and surgical care through months and years of suffering, ending in destruction of the joint, and frequently in death. It is a disease of childhood, occurring chiefly in

the period of rapid growth. It rarely occurs after the twelfth year. It may occur at any time prior to this age, the majority of cases being between the ages of three and six years.

The pathology of *morbus coxæ* will vary with the peculiar character of the lesion. The morbid changes which occur in that variety which is most frequently met with are those of tubercular *ostitis*, primarily, followed by destructive *arthritis*. The initial lesion occurs as an interference with, or arrest of, nutrition, near the diaphyso-epiphyseal cartilage (Fig. 380, *a*), due to a deposit of tuberculous material at this location. It may begin on the diaphyseal or epiphyseal side. According to Prof. Gibney,* the initial lesion appears in several centers of ossification about the same time. It is an *ostitis rarefaciens*. The cancellous cavities become filled with embryonic cells, absorption of the lamellæ occurs, the inflammatory new products may undergo a slow process of fatty metamorphosis, may become caseous, or the process may terminate in pus-formation.

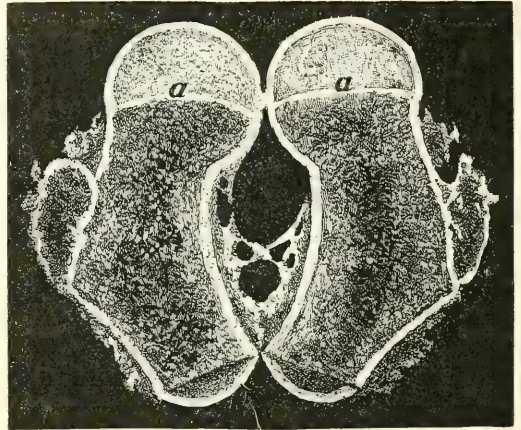


FIG. 380.—Section of normal femur of a boy eight years old. (After Gibney.)

The development of the bone is arrested, the *ostitis*, commencing in the deeper portions, travels in all directions, destruction of the diaphyso-epiphyseal cartilage occurs, with separation of the epiphyses (*diastasis*). While these changes are going on, the lining membrane of the capsule becomes involved, the process being one of *chronic synovitis*, which, as has been stated, terminates inevitably in inflammatory changes in the tissue proper of the capsule. The joint becomes filled with the products of inflammation, the capsule, over-distended and weakened, ruptures either spontaneously or as a result of motion, and dislocation may occur. With separation of the epiphysis and destruction of the neck of the femur shortening ensues.

While those just described are the usual morbid changes in hip-disease, in other cases the pathology is different.

Morbus coxæ may begin as a simple idiopathic or traumatic *synovitis*, the destruction of the bone being secondary and commencing from the articular surface, progressing inward. It may commence as a result of injury to, or arrest of nutrition in, the digital fossa of the acetabulum, and the destruction of the ligamentum teres. Again, the initial *ostitis* may be situated in the bones which form the cotyloid cavity. Lastly, hip-joint disease may, in rarer instances, result from a peri-articular inflammation, first a *syndesmitis*, secondly a *synovitis*, lastly *arthritis*.

Causes.—The causes of hip-disease are chiefly predisposing. Any

* "The Hip and its Diseases," Bermingham & Co., New York, 1884.

dyscrasia which impairs nutrition in general, tends to destructive osteitis in children, and consequently to the resulting arthritis. Traumatism may, and undoubtedly does, precipitate the inflammatory process in many cases, yet the ordinary violence to which this joint is subjected will rarely induce *coxitis*, except in children affected with some constitutional disease. Excessive use or a blow may produce synovitis, but, in a healthy patient, rapid recovery is almost certain. If diastasis occurs as a result of accident, *ostitis* ensues, and destruction of the joint is apt to follow; yet this is an exceedingly rare injury. Rupture of the ligamentum teres, which must occur in a traumatic luxation, rarely leads to destructive arthritis in an otherwise healthy individual.

The *symptoms* of hip-disease are divisible into *two stages*. The *first stage* embraces all the phenomena of inflammation, up to a positive and appreciable destruction of the structures which enter into the formation of this joint. The *second stage* embraces the phenomena of destruction, namely, shortening of the neck, diastasis, rupture of the ligamentum teres and capsular ligament, and luxation.

Among the earlier signs of this disease is pain, referred directly to the hip, or it may be to the hip- and knee-joint, of the affected side, and in some instances the pain is felt wholly in the knee of the same side. This symptom is most exaggerated at night and in the early morning hours, and after the child begins to move about may disappear. The distribution of the obturator nerve to both articulations will account for the reflex sensibility in the knee. In a certain number of cases the patients will deny all sense of pain, and even under pressure may not exhibit signs of suffering. In children this effort at concealment (not uncommon) is incited by the fear of being subjected to surgical treatment. If, however, a careful examination is made, rigidity of the muscles about the hip will be evident. In standing erect, the weight of the body will be brought upon the sound extremity, the gluteal fold on the affected side is partially obliterated (Fig. 381), and in walking there is almost always

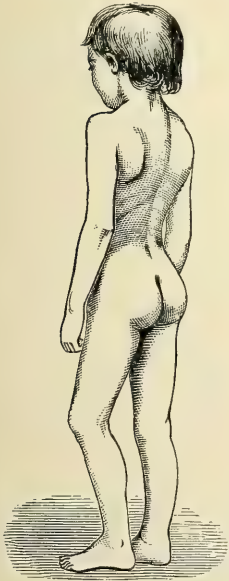


Fig. 381.—(After Sayre.)

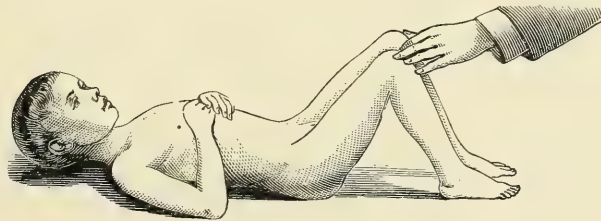


Fig. 382.—(After Sayre.)

a perceptible limp. The iliacus, psoas, and adductor muscles are usually in an abnormal state of tension; hence the initial flexion of the thigh, and outward rotation or eversion of the foot.

Rigidity of the psoas and iliacus muscles—one of the more positive early symptoms of hip-disease—may be demonstrated in the following

manner: If the patient be stripped and laid flat on the back, on a hard, level surface, and both legs drawn up (Fig. 382), it will be seen that the sacrum, spines of the vertebræ, the scapulæ, and occiput rest in contact with the table. If the

sound leg be now extended and the popliteal space brought well down against the surface of the table, the lumbar spine is only very slightly, if

at all, lifted from the table (Fig. 383). If there be rigidity of the muscles named, as a result of hip-disease, on the suspected side, when the effort is made to bring this leg into a position parallel with the sound

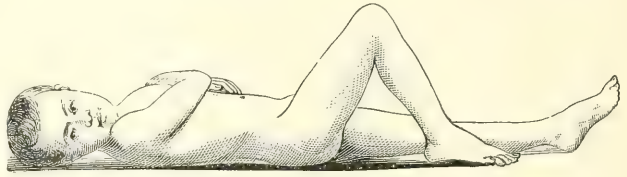


FIG. 383.—(After Sayre.)

one, it will be seen that extension of the thigh is limited, and that the motion of the hip-joint is transferred to the lumbar vertebræ, so that when the popliteal space touch-

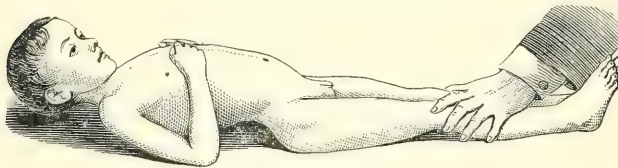


FIG. 384.—(After Sayre.)

es the table the lumbar spines are lifted from one to three inches from its surface (Fig. 384).

The duration of the first stage varies from two or three months to as much as one year, and in exceptional cases longer.

In the *second stage* the thigh is further flexed on the abdomen, adduction is more pronounced, and shortening is present in a degree varying with the extent of destructive ostitis in the acetabulum, or head and neck of the femur, and to the character of the luxation. In the usual position of the foot of the affected side, in this stage, the great toe or inner surface of the tarsus rests upon the dorsum of the well foot, or on the spine of the tibia. The shortening—which may be determined by measuring from the anterior-superior spine of the ilium to the inner malleolus—will vary from half an inch to several inches. Nélaton's or Callaway's test—already given in the article on fractures of the femur—will demonstrate that the shortening has occurred above the trochanter.

Suppuration occurs, the capsule gives way, and sooner or later, if surgical interference is delayed, sinuses open through the skin, about the trochanter, or in the groin. Perforation of the acetabulum takes place in a certain proportion of cases.

Diagnosis.—Disease of the hip-joint may be differentiated from bur-sitis, peri-articular inflammation, rheumatism, neuralgia, sacro-iliac disease, or ostitis of the trochanter or ilium. It is also important to determine whether the initial lesion is a *synovitis* or an *ostitis*.

Synovitis may be caused by excessive use of the joint, by strain or concussion, by sudden exposure to cold, or it may result as a symptom of gout or rheumatism. It is a painful affection from its incipiency, and

the pain increases with the march of the effusion into the joint and the distention of the capsule. Motion increases the pain, which is usually so severe that all movement of the joint is firmly resisted. The cause may usually be traced to an injury. Synovitis due to gout or rheumatism occurs usually in adults; coxitis is practically a disease of childhood.

When *ostitis* is the initial lesion, the approach of the disease is insidious and much less painful. When present, the pain in *ostitis* of the head and neck of the femur is deep-seated and dull, and motion is comparatively free. Rotation and pressure of the head upon the capsule and in the acetabulum do not produce the sharp sense of pain felt in synovitis. *Ostitis* is the rule in children, synovitis in adults.

Bursitis about the hip is rare. The sac between the capsule and the conjoined tendon of the psoas and iliacus muscles, and those situated between the tendons of the gluteus maximus, medius and minimus and the great trochanter, and that between the quadratus femoris and the lesser trochanter, may one or all be involved. Inflammation in one or more of these bursæ may be recognized by the limited extent, as well as the acuteness of the pain elicited by direct digital pressure immediately over the known position of the sac. Pain in the knee is not present in bursitis at the hip. Rigidity is not general in the muscles about the joint.

Peri-articular inflammation is a painful affection, causing marked lameness from the start; it is accompanied by local swelling and tenderness if superficial, and by exacerbations of temperature, all of which will render it easy of recognition.

Muscular rheumatism is rarely confined to the muscles of the hip. It is an expression of a constitutional condition which can not but be elicited by a careful history and study of the case. The pain is more severe and more early recognized than in coxitis. The painful territory may be outlined by fixation of the joint and digital pressure upon the muscles involved.

Neuralgia occurs very rarely in children, in the period when hip-disease is most likely to appear. The exacerbations of pain are more sudden in development and acute in character, and occur with greater frequency and regularity than in hip-disease. Motion is tolerated better in neuralgia than in coxitis. The symptoms of *ostitis* which lead to arthritis, if carefully studied, will show a wide difference from neuralgia about the hip.

In *arthritis* or *ostitis* at the sacro-iliac junction pain is caused by forcibly pressing the ilium against the sacrum. The same symptoms may be elicited by direct pressure posteriorly over the sacro-iliac articulation. Motion at the hip is only slightly if at all embarrassed.

Prognosis.—In hip-joint disease commencing—as is the rule—in *ostitis* or *epiphysitis*, the prognosis is bad as regards restoration of function. Partial or complete ankylosis, with a variable degree of shortening, will result, in the vast majority of cases, no matter how skillfully treated. The proportion of fatal cases can scarcely be de-

terminated. It is safe to say that at least twelve per cent of all cases in which the lesion begins as an ostitis end in death in from one to six years.

In traumatic synovitis of the hip the prognosis is favorable. A restoration of function is the rule.

Treatment.—The treatment of hip-disease may be divided into *mechanical, operative, and constitutional.*

In the early stage of coxitis *rest* to the inflamed articulation, in the position of least discomfort, is essential. Fixation of the muscles which act upon and about this joint can be best secured by extension from the lower part of the thigh and the leg or foot, and counter-extension from the perinæum. To accomplish extension satisfactorily the limb should be brought into the straight position—that is, about parallel with the axis of the body.

If a child with hip-disease be seen very early in the history of this affection, flexion of the thigh upon the abdomen will not have occurred to any extent, but, in cases where the inflammatory process has gone on for some time, the iliacus and psoas and adductor muscles will have become rigid and shortened to such an extent that the thigh can not be immediately brought out straight.

In the former class of cases the apparatus about to be described can be at once adjusted; in the latter, extension in the recumbent posture is necessary until the shortening in the ilio-psoas muscles is overcome.

In fact, since in all cases some time must elapse between the discovery of the lesion and the preparation of the mechanical apparatus, it is a wise practice to put the patient to bed at once, and apply the extension as follows: Cut two strips of mole-skin plaster, from one inch and a half to two inches wide, and long enough to extend from six inches above the trochanter to below the sole of the foot. Adjust one to the outer and one to the inner aspect of the thigh, allowing the upper end, which is to be doubled back upon itself and woven in with the roller, to extend four or five inches above the level of the trochanters. Mold them carefully to the contour of the limb, bringing the strips exactly over the inner and outer condyles of the femur, and hold them by a well-adjusted bandage, beginning from above. In order to prevent the plaster from wrinkling, it is necessary to clip it, at intervals of an inch or two, with the scissors, obliquely upward from each edge. The strips should be made to adhere to the skin to within six inches of the malleoli, not so much that traction below the knee is necessary, but because the complete extension of the leg on the thigh enforces more perfect quiet. The bandage is commenced just at the level of the great trochanter, and that portion of the strips which extends above this is to be turned down and worked in with the roller.

That part of the plaster which is exposed near the foot should be doubled by laying a second strip of equal width on this, the adhesive surfaces coming together. In this way it is not only strengthened, but is prevented from sticking to the dressing.

The extension-weight—varying from two to seven or eight pounds—is applied as in Buck's apparatus (page 304). The dorsal decubitus should be maintained, for, if the sitting posture is assumed, the iliacus and psoas muscles are not materially affected by the extension. To secure this result the long splint of Hamilton should be applied from the axilla along the thigh and leg, and firmly secured by a bandage carried around the chest, pelvis, and thigh.

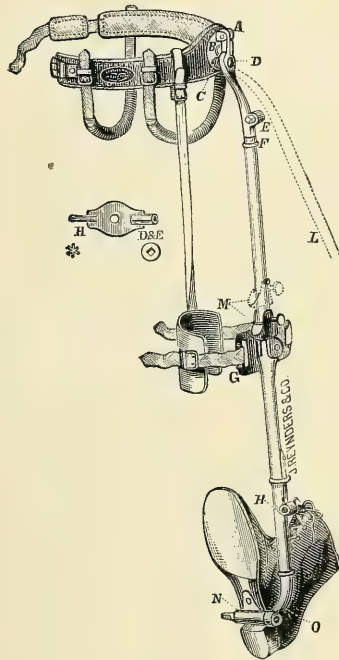


FIG. 385.

As soon as the thigh is fully extended the following mechanism should be adjusted. It consists of a long Sayre splint (Fig. 385) and the high shoe and crutches of Hutchison. The splint is composed of a long, hollow steel shaft, attached above to a pelvic belt by a joint capable of motion in every direction. To the belt two perineal bands are attached. Opposite the knee a strap and pad are fixed, which serve to steady the leg at this joint. Fitting snugly within this hollow shaft is a bar of steel which may be slid up or down by a ratchet and key, and locked in any position. The lower end of this rod is turned at an angle of 90° to the shaft, and fitted with a spring-catch into a socket on the sole of the shoe. In applying

the instrument shorten the shaft as much as possible, fasten the belt around the pelvis just above the trochanters, and then the perineal bands, one on either side. The shoe is put on, the spring-catch fixed in the socket at the sole, and the knee-pad buckled. The shaft of the instrument is now lengthened by the key until a fair and comfortable degree of extension is secured. The shoe upon the foot of the sound side should be raised from one inch to one inch and a half, and the patient made to move about on crutches. Upon retiring for the night the extension employed at first should be resumed. This, the combination method, is shown in Fig. 386. The effectiveness of this plan of treatment has been satisfactorily demonstrated in a number of instances. The advantages are: 1. The patient is able to move about and obtain the benefit of out-of-door life, while the hip is held in extension and practically immovable. 2. The high shoe and crutches hold the lame foot and leg suspended. 3. In case of a fall, the splint prevents concussion in



FIG. 386.—The author's combination method.

the joint. 4. The night-extension prevents spasmodic contraction of the muscles and pain from unguarded movements during sleep.

The length of time for which this treatment should be continued will be determined by the result achieved. It is often a necessity for one, two, or three years, and sometimes even longer, and should be worn for several months after all active symptoms of coxitis have disappeared.

The constitutional treatment of this disease is of great importance. Carefully selected diet, out-of-door life, cod-liver oil and the hypophosphites of lime and soda, and tonics, are indicated.

If the long splint can not be obtained, the high shoe and crutches should be used while the patient is out of bed, and the extension employed while lying down.

In the *second* stage of hip-disease operative interference may be demanded: (1) To relieve pain on account of suppuration and the retention of pus, or to prevent sepsis from insufficient drainage; (2) to arrest osteitis in the head and neck of the femur, and in the acetabulum.

When pain is so severe that fixation with extension will not afford relief, it is safe to conclude that distention of the capsule exists, or that in the structures which form the joint, or are immediately around it, suppuration has occurred to such a degree that free puncture or incision is necessary. For this purpose the aspirator may be employed, or the bistoury.

Although the propriety of opening the joint freely and removing all diseased bone—exsection of the hip-joint—when positive symptoms of destructive osteitis are present, is questioned by some surgeons, the weight of opinion is on the side of operative interference.

Admitting that probably a majority of all cases in which destruction of bone occurs recover, with more or less complete ankylosis, without exsection and without operative interference of any kind, the drainage through the sinuses which lead out through the skin being sufficient; and that the operation is not without danger to life; and when not fatal is not successful in all cases, the osteitis continuing or recurring after exsection—the argument in favor of operation is not answered.

Exsection of the hip-joint is not a dangerous operation when done in the earlier stages of destructive osteo-arthritis, before the patient's vitality is impaired by continued suppuration, septic absorption, and amyloid changes in the viscera. Moreover, in the cases which recover without surgical interference the dead bone and products of inflammation must be carried away through tortuous channels, in which absorption is more apt to occur than when direct drainage is established. The operation removes at once all diseased tissue and leaves a free and open wound for drainage.

After exsection the wound should be packed with sublimate gauze and treated by the open method—not even partially closed by sutures. The gauze may be changed every few days, the wound irrigated with

1-to-3000 sublimate solution, and again filled. Extension by the weight and pulley, in the dorsal decubitus, is necessary for from three to six weeks after the operation, unless the child is strapped in the wire breeches recommended by Prof. Sayre (Fig. 387) immediately after the exsection. The chief recommendation of this apparatus is that it allows the patient to be carried out of doors, or about the house, with perfect freedom from motion or pain. The chief objection is its costliness, which puts it out of the reach of many patients. The extension in bed is very satisfactory in its results, and, with attention to ventilation and the amusement and entertainment of the little patient, the confinement need not be a formidable objection.

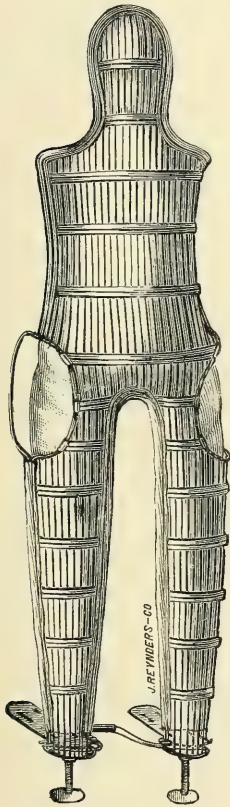


FIG. 387.—(After Sayre.)

When the wire apparatus is used the following directions should be carried out: Pad the instrument well, so that too great pressure at any one point may not occur. Place the patient in it so that the anus will project well over the crotch of the breeches. It is well to insert a piece of protective under the sacrum and buttocks to prevent soiling. Fasten the well leg and the body to the instrument by rollers. Lay the extremity of the affected side in its splint, and screw the foot-piece up until it touches the sole. Apply two strips of adhesive plaster in the same manner as heretofore given, attach these to the foot-piece, and make the necessary extension by turning the screw in the proper direction (Fig. 388). Passive motion to the ankle and knee should be made at the end of two or three weeks, and repeated weekly. After from four to six weeks, no matter whether the wire apparatus is used or extension in bed employed, the long splint, high shoe and crutches should be adjusted, and the case treated as given for the first stage.

Within the last few years the operation of drilling into the neck and head of the femur, in certain cases where the initial lesion is an osteitis, has been advocated and performed in a number of instances by Mr. Macnamara.* The results so far have been of a nature to encourage a repetition of this procedure. The object of the operation is to give escape to, and secure drainage of, the products of the inflammatory pro-

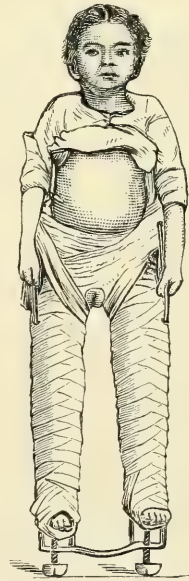


FIG. 388.—(After Sayre.)

* "Gibney on the Hip." Birmingham & Co., New York, 1884.

cess, at or near the epiphysis, and thus prevent disintegration of the bone and invasion of the joint. To be beneficial it must be done early in the process.

The operation is neither dangerous nor difficult. A longitudinal incision, from two to three inches in extent, is made along the middle of the trochanter, down to the bone. The wound should be deep enough to permit the fingers to locate the neck of the femur, on its upper and lateral surfaces, so that the drill may be directed along its center. The chief danger to be avoided is entering the cavity of the joint by carrying the drill too far. In the single case in which I performed this operation, in a boy about eight years old, a button of bone was removed by the trephine from the compact substance of the femur, just below the trochanter. A drill, about three sixteenths of an inch in diameter, was then carried up through the neck, a distance of one inch and a quarter. The direction of the neck was readily made out by keeping the index-finger applied to the upper surface of the neck and capsule. After the operation a rubber tube was inserted, and through this drainage maintained until all discharge ceased.

Knee-Joint.—Acute synovitis of the knee is frequently of traumatic origin, resulting from the excessive strain to which this joint is subjected, and also on account of its exposed position. It may occur in the history of gout, rheumatism, gonorrhœa, and other diseases.

The chief *symptoms* are pain and swelling. Pain may be elicited by motion, or by direct pressure at any part of the joint, but it is, as a rule, emphasized over the coronoid ligaments, along the articular margin of the tibia, on either side of the *ligamentum patellæ*.

The *treatment* consists of *rest* and *fixation*. As a rule, the most agreeable position is that of slight flexion, with the limb elevated and the leg resting over a pillow. Fixation may be best secured by extension from adhesive strips, reaching from just below the knee to beyond the sole. The strips are applied in the same manner as above given. The weight will vary from three to fifteen pounds, according to the age of the patient. Cold, applied by means of the ice-bag, is a most useful remedy during the acute stage of inflammation. When pain is very severe, and when the capsule is greatly distended, aspiration is indicated. This should be done with all antiseptic precautions, and with great care in preventing the entrance of air. The proper instrument is shown at page 65. The needle may be introduced on either side of the patella, at the point of greatest distention, or where fluctuation is most marked. The diagnosis may be made positive by the exploring hypodermic needle and small aspirator (page 63). Or, when the tumefaction is evident above the patella, the needle may be carried from above downward, behind this bone. After the excess of fluid is withdrawn a fair degree of compression should be exercised by enveloping the joint with borated cotton, held firmly down by a roller. Passive motion of the joint may be omitted for as long as four weeks, but should be made weekly after this.

When an acute synovitis of the knee becomes rapidly suppurative, with the symptoms of sepsis, which are common to this form of disease,

evacuation of the pus and irrigation of the joint are indicated. The same instrument is to be employed, and, after the fluid is withdrawn, the capsule is distended with 1-to-40 carbolic-acid or 1-to-10000 sublimate solution, and again emptied. This operation should be repeated until the liquid comes out clear. Compression should be applied in the same manner as before given. The same treatment applies in chronic and repeated effusion of non-purulent fluid in the joints (see pages 352, 353).

If the joint refills with pus, and the symptoms of sepsis are not relieved by aspiration and irrigation, it should be opened and free drainage established. It is safer to make one incision on either side of the patella, directly into the capsule, introduce the closed dressing-forceps and bore through the ligament, making a counter-opening on the lower lateral aspects of the joint. It is only necessary to incise the skin where it is pushed out and made tense by the point of the forceps. The hole may be enlarged by separating the blades of the instrument. A drainage-tube should be caught in the grasp of the forceps before it is withdrawn, and pulled through the joint as the instrument is removed. The irrigation may be constant or interrupted, according to the severity of the symptoms. A method of continuous irrigation is shown on page 119.

The danger of ankylosis after acute synovitis of the knee-joint, lasting not longer than from one to six weeks, is slight. It is always great after *suppurative* synovitis and arthritis, and in *osteo-arthritis* is almost inevitable.

Destructive *osteo-arthritis* of the knee-joint may commence as a synovitis, either traumatic or idiopathic, or it may begin as an ostitis, in or near the epiphysis of the tibia or femur, the joint being secondarily involved. The latter is by far the more frequent source of chronic knee-joint disease.

Symptoms.—Pain is not, as a rule, a prominent symptom of ostitis near the knee, and, when the joint has become involved and the cartilages eroded, in many instances the degree of pain felt is far from being proportionate to the gravity and extent of the destructive process. In exceptional cases pain may be excessive, and may be felt in the hip as well as the knee, or may be referred entirely to the acetabulum. As the disease progresses the swelling increases, and is due not only to effusion into the capsule, but also to thickening of the ligaments, and, to a certain extent, to changes in the ends of one or both bones which enter into the formation of this articulation. Later the ligaments give way, and dislocation of the tibia backward, with slight outward rotation, occurs (subluxation). In the earlier stages of the ostitis certain constitutional symptoms appear, and remain throughout the course of the disease. Septic fever is present in a varying degree, and with it impairment of function in the digestive apparatus.

Treatment.—Whenever destructive ostitis, with arthritis, at the knee exists, the loss of function of the joint is almost inevitable. In fact, an effort to preserve motion in such a joint is of doubtful propriety, since the disease is apt to be exaggerated if complete fixation is not secured and maintained. If an opening is not made into the capsule it ultimately

ruptures, and a sinus gives exit to the products of inflammation. Operative interference is usually indicated as soon as erosion of the articular surfaces can be made out, or as soon as the symptoms point to the communication of a focus of osteitis with the cavity of the joint. The recognized methods of procedure may be given as follows: (1) Fixation of the joint without drainage; (2) fixation with drainage; (3) opening into the joint, with removal of the diseased tissues—exsection or gouging.

The first method is of the most conservative character, and is only justifiable in the milder class of cases, where pain is not severe, and where sepsis is practically absent. If the leg can be brought into the straight position it should be enveloped in a plaster-of-Paris cast, and allowed to remain motionless for six or twelve weeks, if no urgent symptoms appear. The dressing should then be removed for inspection, and reapplied. This may be continued until a cure results, with ankylosis.

If, on account of subluxation, the straight position can not be secured, extension in two directions (Fig. 389) should be practiced until the sub-

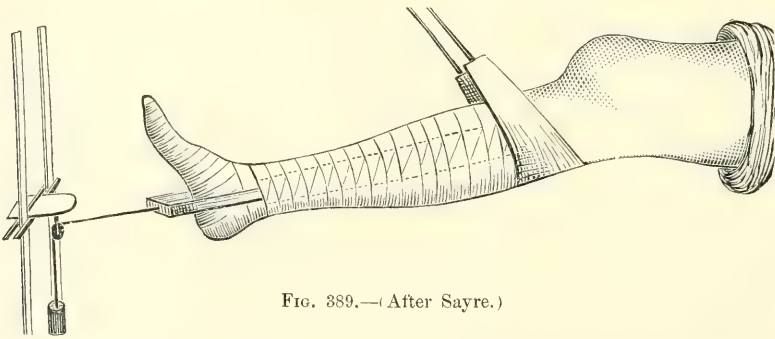


FIG. 389.—(After Sayre.)

luxation is reduced, or until it is demonstrated that this can not be done without operation.

When the condition of the joint demands drainage the same method of fixation may be practiced, adding only one or more windows for outlets to the drainage-tubes.

Operative invasion of the joint may consist either of removal of the ends of the bones by the saw or gouge. The former is the preferable operation, and is now no longer the formidable and complicated method of a few years back. Carefully and properly performed, it is, in my opinion, to be ranked with the conservative operations at the knee, and is entitled to a consideration in the earliest stages of osteoarthritis.

Diseases of the Ankle-Joint.—The pathology, causes, and symptoms of disease at the ankle do not differ from those at the articulation just considered.

Synovitis is oftener traumatic than idiopathic. The exposed position of this articulation, which is called upon not only to sustain the entire body-weight, but is also frequently subjected to great lateral strain, renders it exceedingly liable to injury.

The symptoms of acute traumatic synovitis at the ankle are usually not obscure. Swelling, pain, and heat, following prolonged or violent exertion, a twist, sprain, or other injury, bear strong evidence of inflammation within the joint.

The injury most difficult to differentiate from intra-articular synovitis, and one which frequently complicates synovitis here, is inflammation of the sheaths of the tendons which play around the joint. The evidence of *theclitis* is pain in the track of the tendon, either elicited by direct pressure or by placing the foot slowly in a position which will cause the greatest tension of the tendons, and then requiring the patient to move the foot in various directions which are resisted by the operator. To test the peronei muscles, carry the foot well inward, hold it firmly, and ask the patient to turn the foot out. *Theclitis* in the track of these tendons will arrest the effort at abduction and outward rotation. The reverse of this manœuvre will serve to demonstrate a similar condition in the flexors and internal rotators.

Idiopathic synovitis of the ankle-joint is less painful and comes on slowly. Synovitis from exposure to cold, gout, or rheumatism is frequently symmetrical, attacking either both ankles at the same time, or first one and then the other. Traumatic synovitis, on the other hand, is almost always unilateral.

The *prognosis* of simple synovitis of the ankle, when proper, vigorous, and prompt treatment is instituted, is in general favorable. If left alone it frequently ends in ankylosis or destructive osteo-arthritis.

Treatment.—Acute synovitis, whether of traumatic or idiopathic origin, demands rest, with an elevated position of the foot. Simple cases will require no more than this, with hot or cold applications, or lead-and-opium wash, applied by soft cloths laid loosely around the ankle, or blotting-paper kept wet with vinegar. The employment of compression will depend upon the sense of relief it may give the patient. Absorbent cotton or soft sponges may be used, applied carefully with a flannel or muslin roller.

Aspiration of the joint to relieve extreme tension from effusion applies here as in other articulations. The needle should be entered in front, between the anterior margin of the external malleolus and the contiguous surface of the tibia, away from the vessels and nerves which are opposite the middle of the joint.

In subacute or chronic synovitis, compression is always indicated, and will often cause absorption of the excessive effusion in the joint. It is especially demanded after aspiration, to give support to the parts, and to prevent a further effusion.

Extension is indicated when its employment gives relief from pain, which rest and fixation without extension do not afford. Fixation with liquid glass or plaster of Paris secures rest to the joint in most cases, and permits of locomotion on crutches.

Arthritis of the ankle is often due to *ostitis* of the tibia or the astragalus.

The *symptoms* are those of *ostitis*, elsewhere given, and the *diagnosis*

and *prognosis* do not differ materially from similar lesions in other articulations.

When osteo-arthritis is evident, operative interference is indicated, for the reasons that (1) early incision, by giving discharge to the contents of the capsule, retards or arrests the destructive process; (2) the common experience of surgeons is that the invasion of this joint is practically without danger to the patient's life.

Complete exsection of the articular ends of the tibia and fibula, and of the upper half of the astragalus, is rarely called for. An incision upon the side which, from the symptoms present, will give the best access to the diseased bone, and the free use of Volkmann's spoon or the scalloped gouge (page 38) in removing the dead tissues, will usually suffice. A counter-opening should be made, so that thorough drainage by means of the rubber tube may be maintained. The foot should be kept at rest, and the patient directed to go on crutches until several months after the discharge has ceased, and the sinus closed. The operation of gouging is more successful in osteo-arthritis at the ankle than in any other articulation. Complete exsection is only admissible when the destruction is very extensive.

Synovitis and osteo-arthritis of the articulations of the tarsus and metatarsus are treated upon the same general principles as just given for the ankle.

The Shoulder-Joint.—Synovitis of the shoulder is usually general; in rare instances it may be local. It may affect the general synovial surface of the capsule, be reflected into the synovial sheath of the long head of the biceps, the bursa under the tendon of the subscapularis, or that beneath the infra-spinatus, or in rare instances, especially in the earlier stages, one or more of these bursæ may be inflamed, while the joint is not invaded. The bursa between the deltoid and the capsule may also be the seat of bursitis, although this sac does not communicate with the joint. The diagnosis of inflammation in one or more of the bursæ about the shoulder may be determined as follows: 1. Direct digital pressure upon any single bursa will indicate the sensibility of the part. 2. Extend the forearm fully, grasp the hand and elbow of the patient, and, while the head of the humerus is pulled away from the glenoid cavity, direct the patient to make strong flexion, which the operator firmly resists. If inflammation of the sheath of the long head of the biceps exists, pain will be experienced in the anterior and outer portion of the joint as this tendon is made tense. 3. When the bursa under the infra-spinatus is inflamed, if the arm is rotated inward, and held in this position, pain will be felt when the tendon of this muscle is made to press strongly on the bursa, in any effort at outward rotation.

An opposite manœuvre will serve as a test for the bursa beneath the tendon of the subscapularis. In *general synovitis* each of these movements will be productive of pain, and the differentiation is chiefly between neuralgia and muscular rheumatism. In *neuralgia* the pain is of the peculiar neuralgic type. It is rarely constant, the exacerbation appearing at intervals of comparative regularity, and extending in the recog-

nized course of the nerves. Motion is not painful in the degree which characterizes either synovitis or rheumatism, and, if persisted in, the sense of pain may entirely disappear. Pressure upon the nerves, which lead to and beyond the articulation, will at times cause pain similar to those felt in neuralgia of the joint. Swelling is not a feature of a neurosis. In rheumatism of the muscles about the joint the pain is superficial, and may be elicited by digital pressure upon the substance of the muscles. In rheumatism redness is more apt to be present, and the area of swelling extends farther than in synovitis.

The treatment of synovitis is the same at all joints. Artificial extension is rarely needed, since the weight of the extremity is sufficient.

Aspiration is a safe and efficient means of relief from pain, and is indicated when there is marked capsular tension. The needle should be entered through the center of the joint in front. Fixation of the joint by a shoulder-cap of felt, card-board, or leather, should be secured immediately after aspiration (page 297). When ready for application, lay upon the surface of the board which is to be nearest the skin a layer of absorbent cotton, which shall be wide enough to extend entirely around the arm and over the shoulder, place it in position, and secure snugly by a figure-of-8 bandage around the arm and shoulder (see Fig. 17).

Acute suppurative synovitis demands an immediate evacuation of the purulent contents of the capsule by means of the aspirator, and, if the joint refills rapidly, and the pain and temperature continue or are exaggerated, it should be opened and thoroughly cleansed and drained. The incision is the same as for excision of the head of the humerus, namely, from the anterior internal tip of the acromion, parallel with the fibers of the deltoid along the anterior margin of the great external tuberosity. The capsule is opened external to the long head of the biceps, and, while traction is firmly made upon the edges, the cavity may be thoroughly explored and cleansed. It is of vital importance that in this, as in every cavity which is the seat of purulent inflammation, drainage should, when possible, be established from that portion of the wound which is most dependent. As the patient rests in bed the posterior and outer part of the capsule is lowest. A dull-pointed dressing-forceps should be carried into the capsule through the anterior incision and bored through the inferior posterior wall and all the tissues to the skin, and when this is pushed ahead of the instrument an incision should be made to allow the escape of the instrument. The wound is stretched by opening the jaws of the instrument, and a rubber tube pulled into place as the instrument is withdrawn. In *osteo-arthritis* of the shoulder-joint exsection is demanded.

The Elbow-Joint.—Synovitis of this articulation need not be separately considered. The same general principles of diagnosis and treatment apply here as in other joints. Destructive osteo-arthritis demands gouging or exsection. The operation will be given hereafter.

The Wrist-Joint.—Inflammation of the synovial membranes of the wrist or in the immediate neighborhood of this joint is of frequent occur-

rence. It is usually traumatic in origin, occasionally idiopathic. It may attack the synovial sac between the ulna and radius; that between the radius and the fibro-cartilage and the first carpal row; the general synovial sac between the first and second rows and the metacarpus; or that between the base of the first metacarpal bone and the trapezium (Fig. 390). Inflammation of the sheaths of the tendons on the dorsum of the carpus or on the palmar surface may also complicate a carpal synovitis, or exist alone. The contiguity of these various structures renders a positive diagnosis of great difficulty. If, when the bones of the forearm are grasped near their center and pressed together, sharp pain is elicited at the wrist, synovitis of the radio-carpal sac is indicated. When the swelling is well defined at the edge of the articular end of the radius, extends across the wrist, and is limited to the situation of the first row of the carpus, the radio-carpal sac is probably alone involved. When the several capsules are involved the swelling is general. In *theclitis* the pain is superficial, and usually extends for some distance along the tendons above and below the joint. Contraction of the muscles, the tendons of which are involved, will point to the location of the inflammation. Differentiation of synovitis from Colles's fracture will depend upon a study of the symptoms of this lesion already given. Osteo-arthritis in its earlier stages is comparatively a painless process, and even after the capsule is invaded is rarely as painful as an acute synovitis.

Treatment.—Synovitis of the wrist does not demand separate consideration. Destructive osteo-arthritis requires gouging or exsection. Synovitis of the metacarpal or interphalangeal joints should be treated on general principles of rest and fixation.

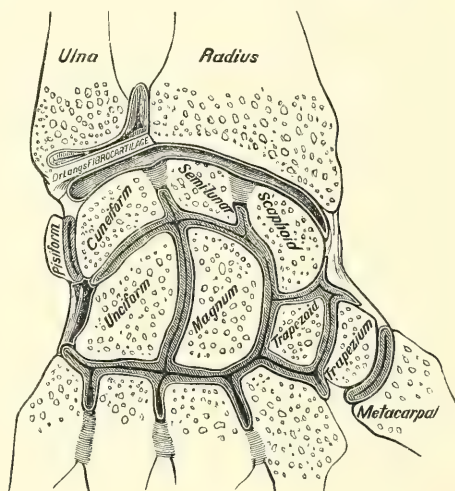


FIG. 390.—(After Gray.)

EXSECTIONS OF THE JOINTS.

The Hip—Sayre's Operation.—Place the patient on the sound side; carry the point of a strong scalpel perpendicularly down to the bone exactly half-way between the anterior-superior spine of the ilium and the tip of the trochanter major;* cut along the neck of the femur, keeping the knife firmly in contact with the bone, carrying the in-

* The extremity should be held parallel with the axis of the spine, with the foot normally rotated outward.

cision midway between the center and posterior aspect of the trochanter, and then curving it slightly forward as it passes about an inch below the tuberosity (Fig. 391). Through this incision, which divides the capsule and thickened periosteum, insert the elevator and lift the periosteal investment from the diseased bone. When the trochanters are involved, the tendons, inserted into these eminences and into the digital

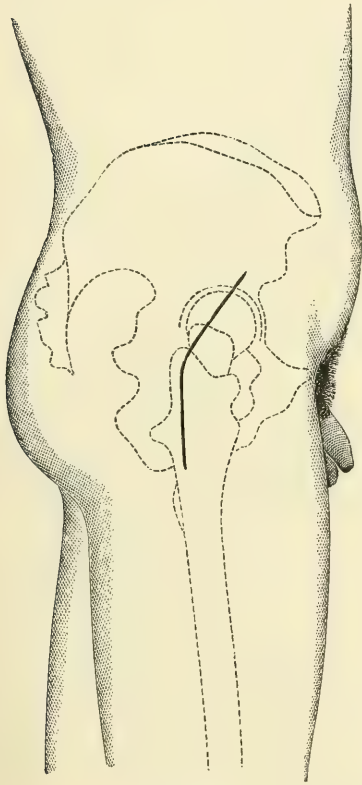


FIG. 391.

fossa just above the great tuberosity, usually require to be detached with the knife, the point of which, in order to avoid wounding any vessels, should be kept in close contact with the bone. As soon as the periosteum is freely raised, the bone should be divided, preferably with the exsector (Fig. 79), and the upper fragment lifted out with the elevator. If the exsector is not used, the chain- or key-hole saw or cutting-forceps may be employed. The sawn surface should be carefully inspected in order to see if the disease extends farther down the bone, necessitating a second division. The acetabulum should next be examined, thoroughly scraped with a Volkmann's spoon, and all dead tissue removed. Hæmorrhage is usually insignificant, and, if occurring, should be arrested as the operation progresses. The wound should be thoroughly irrigated with 1-to-3000 sublimate, all shreds of tissue and particles of bone removed, and the entire cavity filled with sublimate gauze, well packed in, and held in place by a thigh and pelvic spica. The patient should now be put to bed with an extension apparatus applied as given

for the early treatment of hip-disease. Sand-bags may be laid along the leg to hold the foot in the proper degree of outward rotation, or a splint may be used. The long splint from the axilla to the heel is often required to prevent a child from sitting upright in bed. The first dressing is changed usually about one week after the operation, and once or twice a week thereafter. After four or five weeks the *combination method* should be employed, and the case treated as in the first stage. Prof. Sayre prefers, and frequently employs, the wire breeches for the first few weeks after the operation. This instrument can not always be obtained, and the extension in bed has proved perfectly satisfactory.

In a certain proportion of cases the disease is not arrested by the first operation, and a second is required.

The outline of the parts involved in this operation is well shown in Fig. 392.

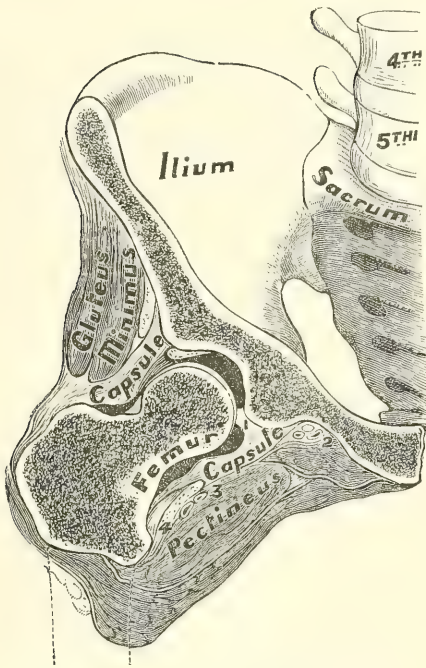


FIG. 392.—1, Ligamentum teres. 2, External obturator muscle and obturator vessels. 3, Circumflex vessels. 4, Conjoined tendon of psoas and iliacus. (After Braune.)

tissues, parallel with the attached edge of the reflected upper flap, lifting everything from the anterior aspect of the femur and its condyles together with the patella, the attached fringes, ligamentum patellæ and coronary ligaments—thus clearing in one mass all the tissues which envelop the anterior three-fourths of the joint.

By sharply bending the knee the crucial ligaments are exposed and divided, the lateral ligaments cut away, and the disarticulation effected. In stripping the attachments of the ligamentum posticum Winslowii from the tibia and femur, the operator should closely hug the bone and thus avoid wounding the vessels. This dissection should extend about three-fourths of an inch below the level of the tibia and one and a half inch above the lowest surface of the condyles. Determining now the amount of bone necessary to be removed, a cloth retractor is applied so as to protect the soft parts from bone detritus or injury,

Operation.—Shave the parts thoroughly, including portions of the thigh and leg, ten inches above and below the articulation and wash with soap and brush, then ether, and lastly 1-1000 sublimate solution. Elevate the foot in order to empty the extremity of blood, and after a minute or two apply the rubber tube tourniquet at the middle of the thigh.

With the leg straightened out, or slightly flexed (Fig. 393), an incision is made across the center of the patella and down on each side until the level of the posterior surface of the tibia is reached. These points must be low in order to secure free drainage. The skin-flaps or cuffs are now dissected and rolled up until the upper one is turned back from two to three inches, the lower about one and a half inch. As the flaps are held well away by assistants, the operator cuts down to the femur through the

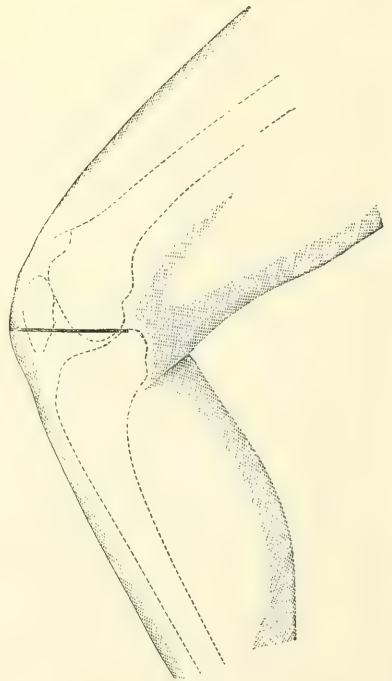


FIG. 393.

and a slice thick enough to freshen the head of the tibia is sawed away, as nearly as possible parallel with the normal plane of the articular sur-

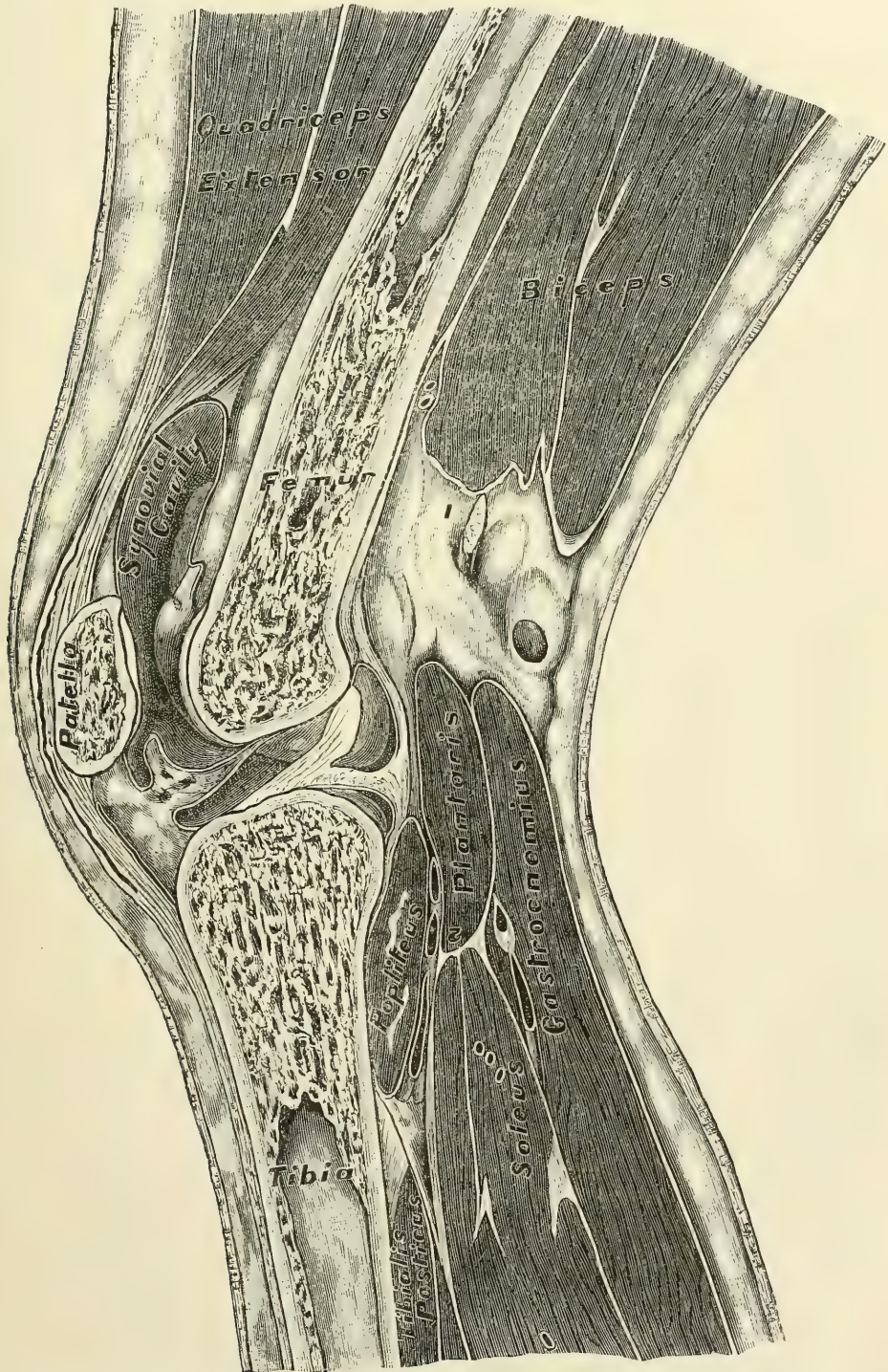


FIG. 394.—Longitudinal section through the knee-joint. 1, Peroneal nerve. 2, Popliteal vessels. (After Braune.)

faces. Should the section expose a focus of disease which dips down into the bone, this should be cleared out with a scoop or Volkmann's spoon, and finally mopped with a strong bichloride solution (1 to 500). It is important, and especially in children and young adults, that the section should not involve the epiphyseal lines.

The section through the end of the femur should now be made (Fig. 394). It follows that if the limb is to be straight in the position of ankylosis, the sawed surfaces of the two bones must be parallel. I have found it of great value to employ this method. By pulling on the foot the limb is fully straightened, and the articular surface of the femur separated from the sawed surface of the tibia. If the operator will now start the saw into the femur, sighting by the flat face of the tibia, the instrument will cut directly parallel with this. If by error the section of the tibia has been slightly oblique, that of the femur will have a like obliquity, and therefore the bones will fit snugly with the extremity straight.

The next step is to dissect away with forceps and curved blunt scissors all the diseased capsule. This should be done thoroughly, and even the bursæ that communicate with the joint should be cleaned out. If care is not taken, a portion of the sac which extends up beneath the quadriceps tendon will not be removed. All bleeding points should be tied with catgut and all hæmorrhage stopped. The bones are now brought in exact apposition, and while so held the steel drills (Fig. 395) are introduced. I usually carry two of these

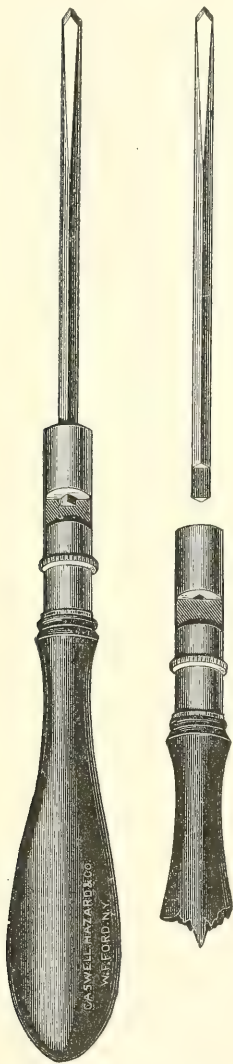


Fig. 396.

Wyeth's drills, with adjustable handle, for fixation of the bones in knee-joint excision.



Fig. 395.

in from below upward, passing them through the skin about two inches below the sawn surface of the tibia and directing them obliquely through the tibia into the femur. When the end of the drill has reached the compact substance of the femur, it is stopped, the handle unshipped, and the drill left in position. Three are used, one on either side from below, and one directly down the median line from above, entering the femur and passing into the tibia (Fig. 397).

As the leg is now held steady the edges of the wound in the skin are sewed together with catgut, and two short bone drains inserted at the inferior angle. I no longer use rubber drains, having had considerable

trouble with the sinuses that persist after their removal. If the absorbable bone drain is not at hand, twists of catgut will suffice. The united lips of the wound are dusted with iodoform, a narrow strip of aseptic protective, split so as to fit over and not obstruct the drainage-tubes, lies over the sutures, and over this a light layer of iodoform gauze and then successive layers of sublimate gauze, until the whole limb from the ankle to the hip is invested to the thickness of about two inches. One thickness of absorbent cotton is now applied, and on the top of this successive layers of veneering or thin wooden splints are applied under firm compression of a roller. Over all, one layer of starched crinoline bandage is placed. This dressing is allowed to remain on for from two to three weeks, and when changed at this time the drills are pulled out.

The roller should be firmly drawn, so that a considerable pressure may be exercised upon the part, to prevent oozing. The elasticity of the cotton distributes the pressure equally, and controls hæmorrhage without causing discomfort. It is the practice of some surgeons not to apply a single ligature in this operation, but to rely wholly upon compression for the control of bleeding.

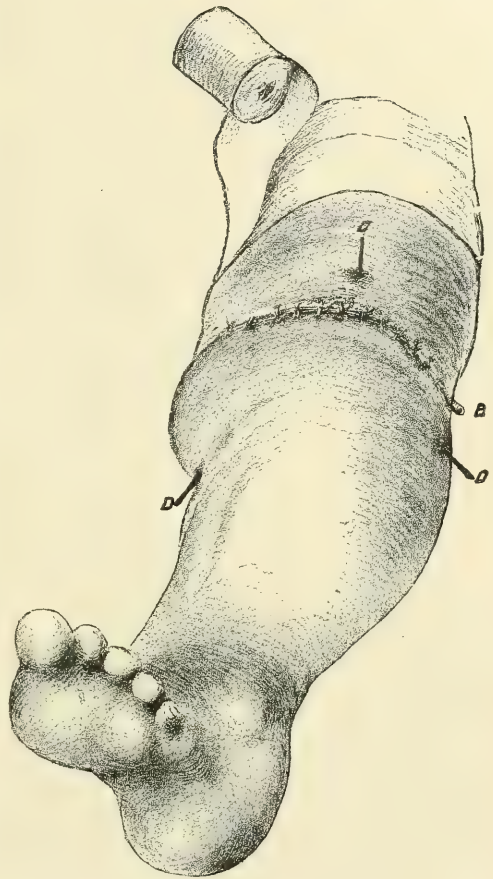


FIG. 397.—Showing fixation of bones by the drills. Wound closed with catgut sutures. *E*, Absorbable bone-drain of one side. *D*, Fixation drills.

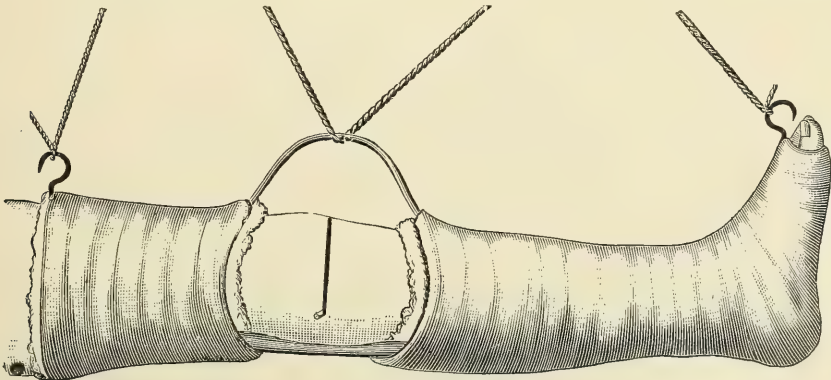


FIG. 397 A.

It is better to search for and tie the larger vessels which may have been divided. As in all the antiseptic operations, the indications for a change of dressing are hæmorrhage, high temperatures, and decomposition of the discharge beyond the zone of asepsis. When the wound is dressed, careful antisepsis should be practiced. Recovery, with ankylosis in the straight position, is the result. No effort at passive motion should be entertained. This operation has met with remarkable success within late years. The drills are preferable to nails in fixation. They are carried into position by steady pressure on the handle, with a slight half rotary movement. When they can not be obtained, the parts may be held in apposition by wiring the bones together and applying an interrupted plaster-of-Paris dressing, as shown in Fig. 397 A.

The Ankle-Joint.—For the complete exsection of the articular ends of the tibia and fibula and the astragalus, proceed as follows: Commence an incision on the internal surface of the tibia, about two inches above

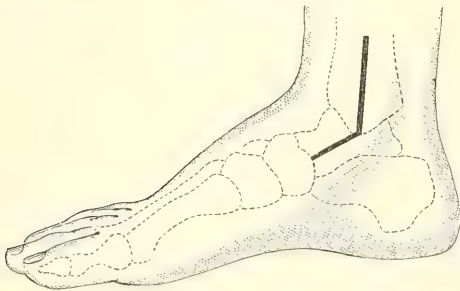


FIG. 398.

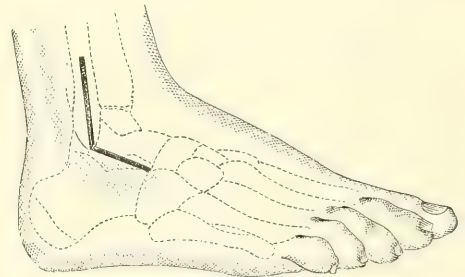


FIG. 399.

the tip of the inner malleolus, and carry it directly down to this point, and thence directly forward, from one inch to one inch and a half along the tarsus, in the direction of the metatarsal bone of the great toe (Fig. 398). A like L-shaped incision is made upon the fibular side of the joint (Fig. 399). These incisions divide all the tissues down to the bone. With

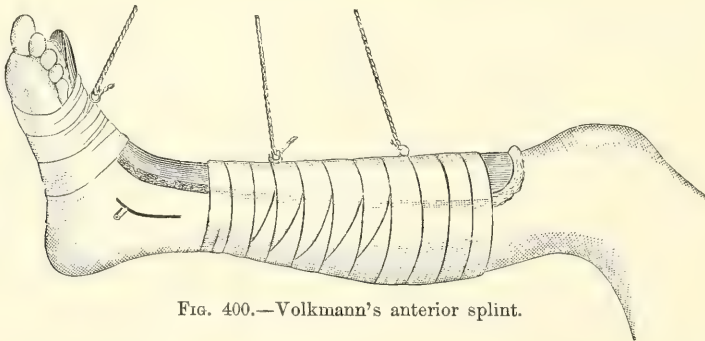


FIG. 400.—Volkmann's anterior splint.

the Sayre elevator lift the periosteum, with its attachments to the superjacent soft tissues undisturbed, from the diseased portions of bone. Expose the outer malleolus and fibula as high as it is deemed necessary to remove this bone, and divide it with the exsector (or chisel). As soon as the piece is removed the joint is thoroughly exposed to view. Now,

further lift the periosteum of the tibia and tarsus, and, by forcibly bending the foot inward, dislocate the tibia and inner malleolus outward, through the wound on the fibular side. The diseased surface may be sawn off with an ordinary saw, or with the exsector. The section through the astragalus may be made with a gouge, chisel, or a key-hole saw.

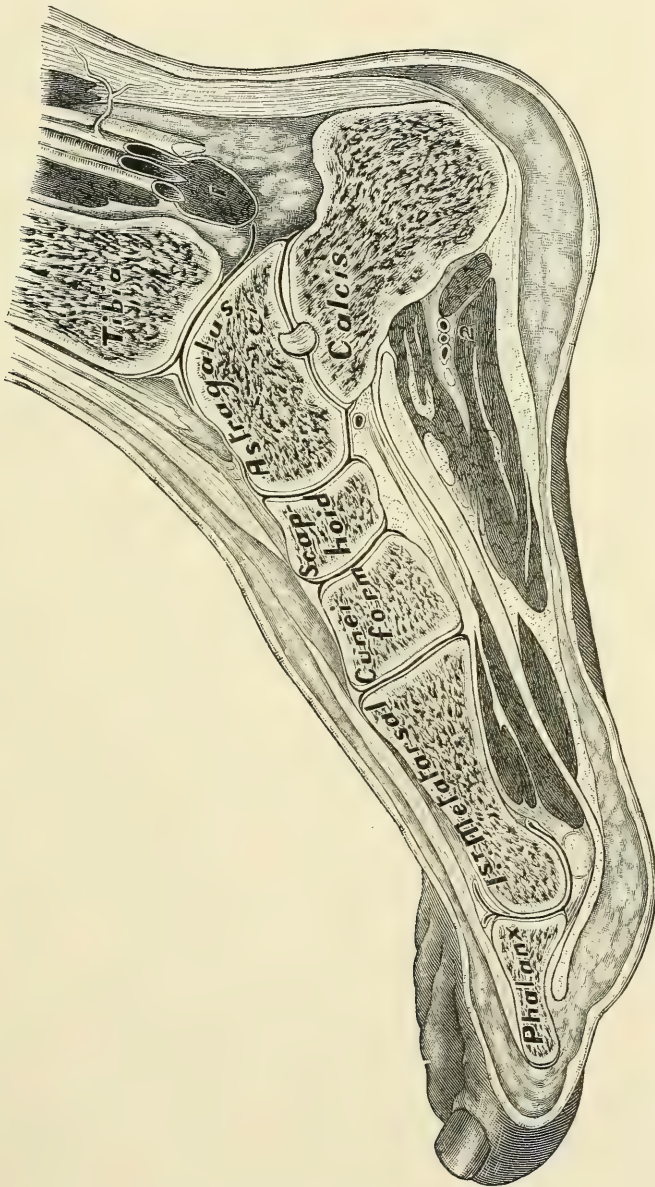


FIG. 401.—Section through the lower portion of the leg and foot, showing the relations of the parts in exsection of the ankle joint. 1, Posterior tibial artery, veins, and nerve. 2, External plantar vessels. (After Braune.)

Usually no vessels of importance are wounded in this dissection, since, by keeping beneath the periosteum, they are lifted with the tissues. The periosteum should not be elevated over the healthy bone. The sawn surfaces are now brought in apposition, so that the foot will be at an angle of 90° with the axis of the leg. Fixation may be secured by trans-

fixion with small steel drills, carried obliquely from above downward, entering on the internal aspect of the tibia and the external surface of the fibula, and passing into the astragalus (in the same manner as at the knee). The wound should be closed with catgut, leaving a small absorbable bone drainage-tube to pass out on each side. An antiseptic dressing is now applied, and the foot and leg placed in a fracture-box and padded to hold it motionless.

If the drills are not employed, the parts should be held in apposition while a plaster-of-Paris dressing is applied, which, being "set," is fenestrated on both sides over the wounds, in the same manner as shown in Fig. 350. Or a Volkmann's splint (Fig. 400) may be applied to the anterior extremity of the foot and leg, and the parts fixed with plaster of Paris, or simple roller. This splint may be made of wood, or sheet- or hoop-iron, properly padded with antiseptic gauze. A useful substitute may be made from several pieces of telegraph-wire.

If the bones are not extensively involved, a single L-shaped incision will suffice to expose the joint, and the dead bone can be removed with the gouge or Volkmann's spoon, and a counter-opening made for drainage. This operation is always to be preferred at the ankle.

When, in an exsection of the ankle, the astragalus is so much involved that its removal is necessary, the upper surface of the *os calcis* should be smoothed off with the chisel or key-hole saw, and brought up in apposition with the plane surface of the bones of the leg. Fig. 402 represents a foot after recovery upon which I did this operation in 1885.

The Shoulder-Joint.—Exsection of the head of the humerus is readily effected by a single straight incision, about five inches in length, made from the acromion process directly down the arm, parallel with and splitting the fibers of the deltoid (Fig. 403). The periosteum should be carefully lifted as far as the osteitis extends, and the soft tissues about the capsule raised with the elevator. The edges of the wound should be held wide apart by blunt retractors, and the tendons of insertion of the supra and infra spinatus, teres minor, and subscapularis di-

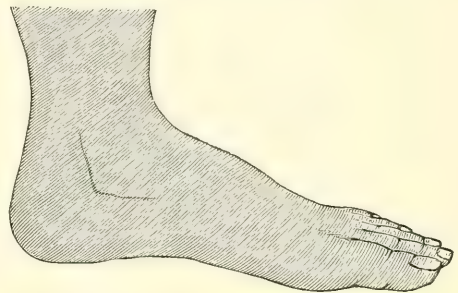

Fig. 402.—The foot after exsection of the astragalus and articular ends of tibia and fibula.

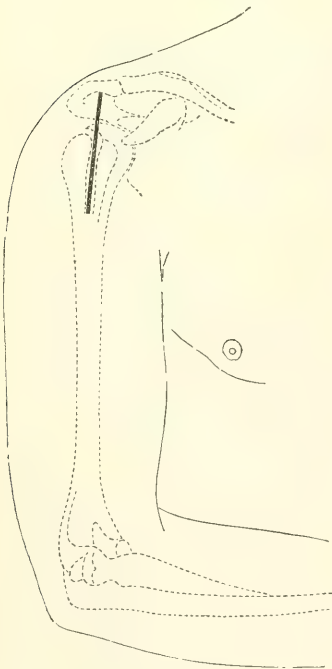


Fig. 403.

vided close to the tuberosities with the curved blunt scissors. The sheath for the long head of the biceps should be laid open, and this tendon held aside. If the exsector is used, the bone should now be divided at the limit of the disease. When the section is completed a strong hook

should be fastened into the end of the upper fragment, in order to lift it and facilitate the separation of the soft tissues on the inner and under surface from the bone and capsule. The capsular ligament should be trimmed from the margins of the glenoid cavity and removed with the head of the humerus. All diseased tissues should be dissected out with the curved scissors, and, if the head of the scapula is involved, all disorganized bone should be scraped away with the spoon

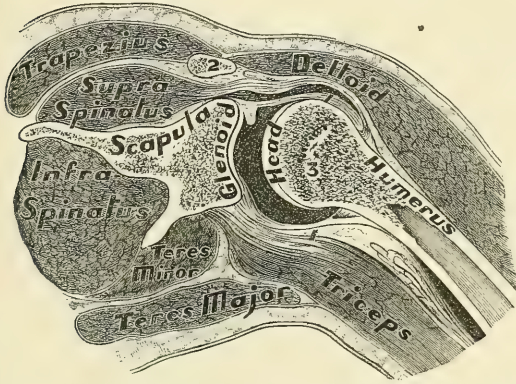


FIG. 404.—Longitudinal section through the shoulder-joint, showing the relations of the bones, ligaments, and muscles immediately about the articulation. 1, The capsular ligament. 2, The acromion. 3, Epiphysis. (After Braune.)

or rongeur. If the exsector can not be had, the capsule should be divided and the head of the bone dislocated upward through the wound. The division is then made with a narrow saw, taking the precaution to protect the soft parts from injury. Upon examining the wound left after this operation, it will be seen that the deepest portion is behind and to the outer side of the end of the shaft. Into this depression carry a closed dressing-forceps, and bore through to the skin, pointing the instrument to the inferior and outer aspect of the arm. Divide the skin over the point of the forceps, dilate the opening by separation of the handles, and draw a drainage-tube from below upward through the hole. A second shorter tube should make its exit through the anterior and lower angle of the wound of incision, and the wound closed throughout with catgut. The forearm should be held in a sling or fastened across the abdomen. The application of Esmarch's bandage, and the rubber tubing in the axilla and over the clavicle and scapula, renders this operation practically bloodless. The rate of mortality is exceedingly low. With careful antisepsis it is practically without danger to life. A second operation for the removal of dead bone is occasionally required.

The Elbow-Joint.—Flex the forearm on the arm and make a straight incision, commencing in the middle of the posterior aspect of the humerus, about one inch above the condyles, and extending over the center of the olec-

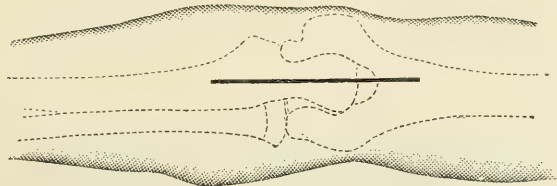


FIG. 405.

ranon process, along the ulnar, for from two to three inches (Fig. 405). The tissues should be carefully lifted from the bone and capsule, and held to either side by blunt retractors. When the trough between the olecranon and internal condyle is approached, extra care should be taken not to wound the ulnar nerve, which passes in this groove. It may be avoided by keeping close to the bones with the knife or elevator. The articular end of the humerus should be exposed, as high as the point of section, by peeling off the soft tissues with the periosteum, after which a retractor is applied and the bone divided at an angle of 90° to the shaft of the humerus. The ends of the ulna and radius may now be readily displaced backward, exposed to the point of section, and divided on a line parallel with that through the humerus. As in all the joint ex-

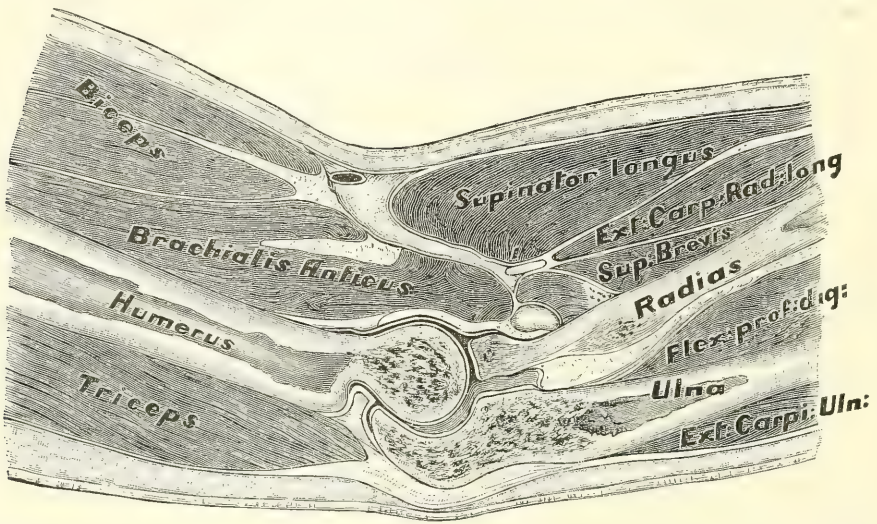


FIG. 406.—Longitudinal section through the elbow-joint. 1, Radial nerve. Superficially on the flexor surface the median basilic vein is seen cut across. (After Braune.)

sections, a careful dissection of all the diseased capsule and soft parts must be made. The wound is drained from the most dependent portion, and closed with catgut sutures. On account of the sinuses which are apt to persist after a rubber drain, it is preferable to employ the absorbable bone drain of Neuber at the elbow. An anterior splint, previously fitted to the arm and forearm, and fashioned so as to hold the forearm half-way between flexion at a right angle and complete extension, is wrapped with gauze and laid on the anterior aspect of the extremity, and fixed by a roller to the arm and forearm, to within a few inches of the incision. A sublimate dressing is next applied to the wound, with cotton and protective, and a bandage over this to effect compression and to hold it in position. When a change of dressing is required, this last bandage only is removed. The rule in this exsection is fibrous ankylosis, with limited motion of the joint and function of the extremity.

Exsection of the elbow is not a dangerous procedure, and, although not usually attended with the success which follows some other opera-

tions (as those upon the shoulder and ankle), it should be preferred to amputation. The anatomical relations at this joint are shown in Fig. 406.

The Wrist-Joint.—The exsection of this joint is attended with considerable difficulty, not only in the performance of the operation, but in

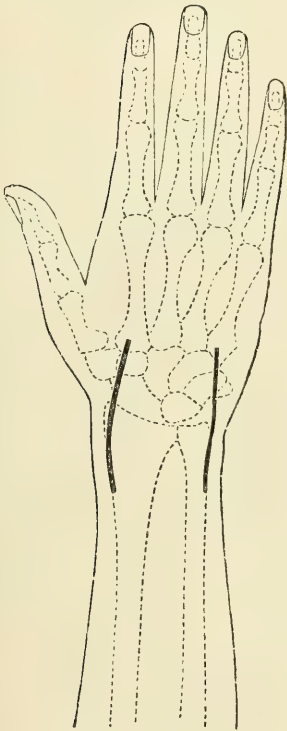


FIG. 407.—Bourgery's operation (modified).

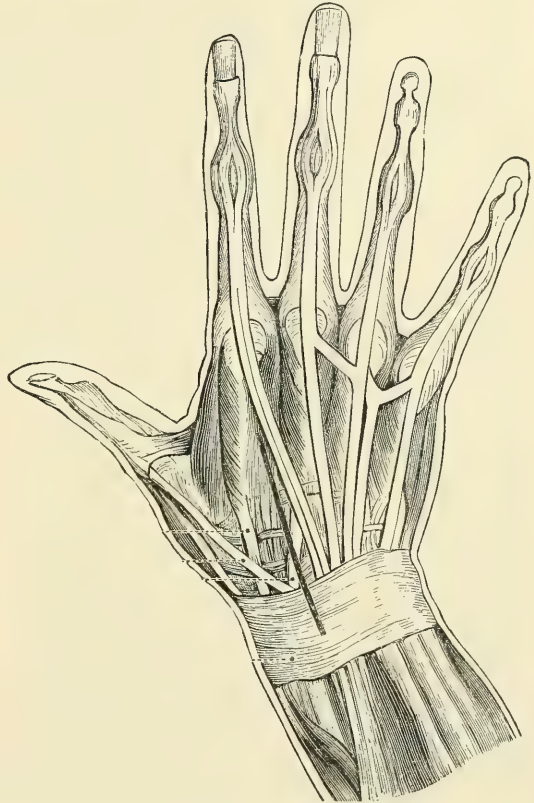


FIG. 408.—Langenbeck's incision. (After Esmarch.)

the after-treatment. Moreover, it is more apt to be followed by failure, resulting in amputation. Of the two procedures—viz., the double lateral and parallel incisions (Fig. 407), and the single longitudinal dorsal incision (Fig. 408)—the latter is preferable when the destructive process is not so extensive, and when the spoon or gouge may be used, while the former will give the freest access to the bones when the saw or exsector is to

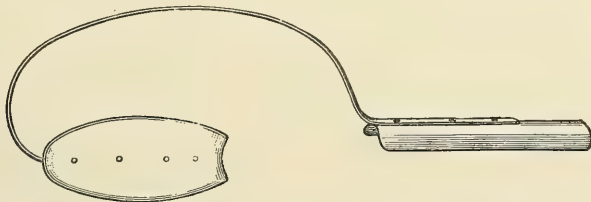


FIG 409.—Esmarch's interrupted splint for exsection of the wrist.

be employed in the removal of a large portion of the bones which enter into the composition of this joint.

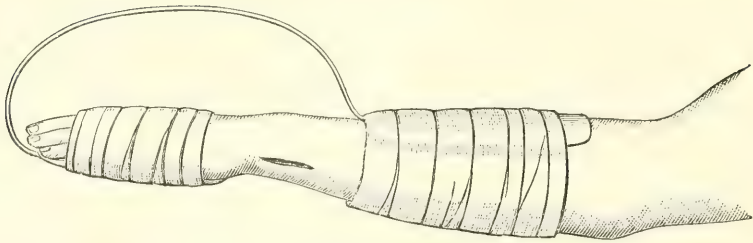


FIG. 410.—The same applied.

In the operation with a single dorsal incision the wrist should be made prominent, by flexing the hand on the forearm, and the integument divided along the tendon of the extensor communis digitorum, which goes to the index-finger, the incision extending from the middle of the metacarpus to one inch and a half above the tip of the styloid processes. The tendon may be retracted to the side most convenient. The posterior segment of the annular ligament is divided, and the tissues lifted from the bones with the elevator. The end of the radius should be removed with the exsector or gouge, when the carpus may be displaced backward through the incision, and removed wholly or in pieces. When the section is completed, the surfaces should be brought in apposition and fixed upon a well-adjusted anterior splint. Or an interrupted dressing may be applied by incasing the forearm in plaster of Paris to within an inch of the incision, and the fingers and hand in the same material, back as far as the anterior limit of the wound. A piece of hoop-iron (or several pieces of telegraph-wire twisted into a single piece) is shaped as shown in Fig. 409, incorporated into the plaster upon the arm, and made to loop over the wrist to the tips of the fingers, where it is turned back underneath the hand, and is fastened to the plaster here by an additional gypsum bandage (Fig. 410).

In the other operation one incision

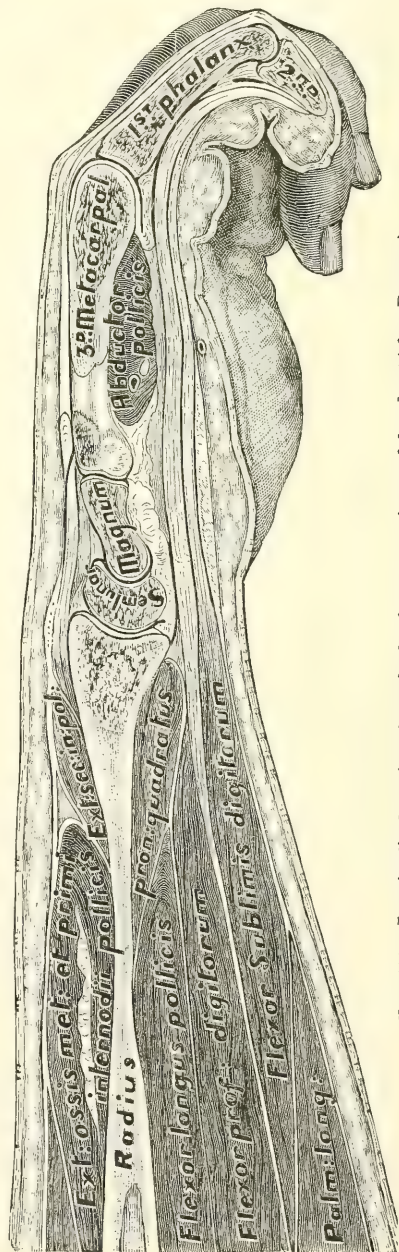


FIG. 411.—Longitudinal section through the forearm, wrist, and hand. (After Braune.)

is made along the outer and dorsal aspect of the metacarpal bone of the little finger, over the styloid of the ulna, and one inch along this bone. The radial incision should commence on the dorsum of the metacarpal bone of the index-finger, pass backward and slightly toward the radial surface of the forearm to a point half an inch above the tip of the styloid process, and thence directly upward along the dorsal aspect of the radius. In extensive operations it may become necessary to divide the tendon of the extensor ossis metacarpi pollicis, which is crossed by the incision. When done, the ends should be reunited by silk sutures when the operation is finished. The tissues are lifted from the bones and capsule as before, and the sections made with the exsector or key-hole saw.

Metacarpo-Phalangeal and Inter-Phalangeal Joints.—Excision of the metacarpo-phalangeal, on the inter-phalangeal articulations, may be done when the destruction of bone is limited. The same general rule, viz., that an excision is preferable to amputation, is applicable both to the hand and foot. At the terminal joints, however, the small size of the last phalanges will rarely permit of any operation except amputation.

CHAPTER XIV.

REGIONAL SURGERY.—THE HEAD.

Tumors of the Scalp.—The most common tumors of the scalp are *cysts*. They are *congenital* and *acquired*.

Congenital cysts are rare as compared with the *acquired*. They are deeply situated, being beneath the skin, and not infrequently below the fascia and muscles. Their contents are chiefly white or yellow fluid, and at times hairs. Each tumor may consist of a single cyst, or there may be several grouped together (multilocular), the mass rarely attaining a size greater than an inch in diameter. If left alone they may ulcerate from pressure or injury, or, in rare instances, may cause atrophy and perforation of the calvaria and dura mater. They should be removed in early childhood. The operation consists in dissecting out the sac, with its contents. As a rule, small wounds of the scalp, situated where a scar will not be apparent, do not need to be stitched. The edges should be approximated and held thus by a dressing of sublimate gauze and a bandage.

Acquired cysts, commonly called “wens,” are of two varieties, one due to retention of sebum in a sebaceous follicle, the duct of which has been obstructed; the other caused by extravasation of blood, where the clot has been absorbed, leaving the serum more or less stained by the decomposition of hæmatin. They are round, smooth tumors, are superficial, and found most frequently upon the upper and posterior portion of the scalp. They are mostly multiple, are unilocular, and contain a granular, cheesy substance. The treatment is removal with the knife. The hair should be shaved from the tumor, and for a slight distance beyond its base. Complete anæsthesia can be obtained by injecting ℥ xv of a 4-per-cent solution of cocaine in the line of incision, and around the base of the tumor. With a sharp bistoury transfix the mass through its base, and lay it open. The integument over the center of the tumor will be found exceedingly thin (not thicker than ordinary writing-paper), and may be easily separated from the thickened sac, which should now be seized with a strong pair of forceps and torn out of its bed. If any strong adhesions are found they should be divided with the blunt scissors.

Sebaceous cysts occasionally become inflamed, the capsule breaks down, the contents escape, and a mass of *granulation-tissue* replaces the original tumor. The new-formed capillaries in this tissue frequently give

way, causing repeated hæmorrhage. They should be scraped out with a sharp spoon, and the sac removed by dissection.

Horns, or dense epithelial outgrowths, are occasionally seen upon the scalp and face. Some of these excrescences attain large size. They should be removed by an elliptical incision around the point of attachment. The incision should remove the entire thickness of the integument.

Lipomata, or *fatty tumors*, are of infrequent occurrence beneath the scalp, and, on account of the dense integument, they grow very slowly, and rarely attain large size. The diagnosis between sebaceous and fatty tumors of this region is not always easy. The treatment is removal by dissection, which is easily effected by lifting the tumor from its capsule with the finger or the blunt scissors. The capsule need not be removed.

Nævi, *port-wine marks*, and other *vascular tumors*, are quite common upon the scalp. They have been treated of in a previous chapter.

Papillomata, or *warts*, occasionally covering a large territory, are found in this region. In one case which came under my care a flat papilloma, two inches in width, extended from the right temple to the middle line of the scalp. They should be clipped closely with the curved scissors, their bases burned with the actual cautery or nitric acid, and the operation repeated until a cure is effected.

Elephantiasis, or general thickening of the scalp from connective-tissue new-formation, is, fortunately, rarely met with. Ligation of the vessels feeding the diseased area will afford temporary relief, and is a justifiable procedure.

Hæmatoma has been considered in the chapter on Wounds of the Scalp.

Abscess of the scalp requires free incision, irrigation, and drainage. Any doubts as to the character of the swelling may be dissipated by exploration with the hypodermic syringe and a good-sized needle.

Pneumatocele, or "*air-tumor*," is occasionally met with beneath the scalp. It results from disease or fracture of some of the bones, permitting communication with the cavities, as the frontal sinus, or the Eustachian tube, etc., and the escape of air beneath the skin. Evacuation of the contents by pressure, with or without puncture, and a compress to prevent recurrence, will produce inflammatory adhesions and cause a cure.

Ostitis, or *periostitis*, is not uncommon in the calvaria. The causes are the same as for ostitis elsewhere. Great care should be observed in the treatment, on account of the proximity of the meninges and brain. Ostitis with exfoliation demands early recognition and immediate operative interference. The rubber tourniquet around the skull will usually serve to control bleeding. A free horseshoe or crucial incision should be made, and all the diseased bone removed with the sharp spoon. When the exfoliation is confined to the outer table of the skull the prognosis is favorable. The wound should be kept open, well drained,

and allowed to heal by granulation. If pus is found beneath the inner table, enough of the bone should be cut away with the rongeur to permit the free escape of all the products of inflammation. The patient should be required to rest in the position which secures most perfect drainage. A loose antiseptic dressing should be applied.

Abscess of the Frontal Sinuses.—Chronic inflammation of these sinuses demands, as a rule, energetic and thorough operative measures. The accumulation of pus may interfere with the integrity of the eye, often breaking out through the orbit. Headache, great discomfort, and frequent and dangerously high temperatures indicate the sepsis which is occurring.

The operation I prefer is the following: Shave the eyebrow of the affected side and make an incision through the line of the brow so that when the hairs grow out the scar will be concealed. The incision should be free, extending across the root of the nose, if necessary. When the bone is exposed, the sinus is entered by chiseling with a small curved-edged instrument through the anterior lamella of the frontal bone at the inner angle of the supra-orbital arch (Fig. 414). A light mallet should be employed and the chisel should be held with the point directed to the nose, so that a slip would not enter either the eye or brain. Continuing into the sinus, an opening large enough to admit the end of the little finger should be made and the walls of the cavity thoroughly scraped with the sharp spoon.

A strong dressing forceps should now be carried into this opening, against the upper turbinated bones, and made, by boring, to crush through into the nasal cavity. A probe is next carried through this hole and brought out at the nostril of the affected side, and by this a strong silk thread is carried through. A good-sized piece of gauze—so twisted that while the end is small as a cord the middle portion is as large as the index-finger—is tied to the string and drawn through the sinus into the nasal cavity and out at the nostril. The entire twist of gauze is now pulled through. This breaks away the turbinated bones, does not cause annoying hæmorrhage, and leaves perfectly free drainage into the nose and mouth. In several cases which have come under my care this method has been attended with gratifying success.

The edges of the wound should be united with fine silk sutures. In cases where the disease is unusually extensive and the discharge profuse, it will be advisable to carry a small soft rubber drainage-tube in through the wound down into the nose, leaving one end projecting through the nostril and the other at the inner angle of the incision above. For one or two weeks after the operation irrigation through the tube with warm boracic acid solution (gr. v- $\bar{3}$ j) should be practiced once a day. When the tube is removed it should be drawn out through the nose. If both sinuses are involved, an incision on one side may succeed in effecting a cure by breaking down the shell of bone which intervenes, and passing beneath the root of the nose into the opposite sinus, which should also be thoroughly scraped with the sharp spoon.

The effort to cure abscess of the frontal sinus by incision and drainage at the angle of the orbit is not only apt to fail, but it endangers the integrity of the eye from the presence of the drainage-tube and the accumulation of inflammatory products.

Osteoma, or *exostosis*, occurs quite frequently upon the bones of the skull. When not due to syphilis they should be removed early, by the gouge or chisel, as there is always danger of pressure upon important organs if allowed to remain. Syphilitic hyperostosis requires the specific treatment given for this dyscrasia.

Encephalocele, or *hernia cerebri*, is a protrusion of the brain-substance through an opening in the calvaria. This condition usually occurs in children suffering from *hydrocephalus*, the protrusion taking place through the abnormally enlarged *fontanelles*. The dura mater surrounds and is carried in front of the mass, lying in contact with the pericranium. When the meninges alone protrude, the tumor is known as a *meningocele*.

Hernia cerebri may occur after perforation of the skull from any cause, as fracture or necrosis. More frequently the mass which protrudes is made up of a granulation-tissue containing no elements from the brain-substance, while at times these masses are composed of both brain- and granulation-tissue (Fig. 412). The character of the tumor will be recognized from its rapid development after perforation of the calvaria.

Treatment.—When the mass is small, and is just beginning to project, compression should be employed to prevent a further protrusion. It is not safe to attempt a reduction of the tumor. The hair should be shaved from the scalp near the opening and disinfection accomplished by sublimate irrigation, and a compress of sublimate gauze and absorbent cotton applied. If the tumor does not rapidly slough away, it should be removed at the level of the scalp with the elastic ligature or the actual cautery.

Sarcoma of the dura mater is a grave condition, fortunately of infrequent occurrence. In the process of development the tumor is apt to cause absorption of the calvaria, and finally perforation. This usually occurs long after symptoms of pressure from within have been developed. If the patient survive the compression of the brain, the tumor ultimately undergoes necrosis and breaks down into a dirty mass, in which the process of ulceration is accompanied by frequent hæmorrhage.

Carcinoma of the meninges may occur as a result of metastasis, although rarely if ever occurring primarily in this situation.

In sarcoma and carcinoma of the dura mater little more can be done than to relieve pain by the employment of narcotics.

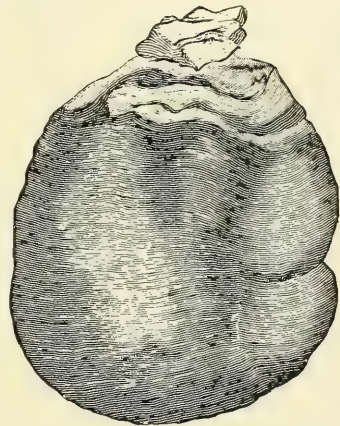


FIG. 412.—Mass composed of brain-substance and granulation-tissue, removed by Dr. E. J. Beall from a boy whose skull had been fractured. Exact size.

Hydrocephalus is primarily a disease of the arachnoid and pia mater. It is a disease of childhood, resulting from inherited tuberculosis. The gross lesion is a transudation of a serous fluid from the pia and arachnoid into the cavities of the ventricles, the arachnoid, and subarachnoid spaces. Distention of the ventricles, compression of the brain-substance, separation of the sutures, enlargement and deformity of the head, projection of the eyeballs, downward squint, and loss of cerebral function, are the symptoms, invariably ending in death.

Treatment.—Tapping will at times relieve the more urgent symptoms of distention and compression. Careful antisepsis should be practiced, and the aspiration made through one of the lateral angles of the anterior fontanella. A small needle should be introduced, and three or four ounces slowly withdrawn, the operation occupying from fifteen to thirty minutes. This treatment is palliative, and is only justifiable in the effort to relieve the suffering of the patient. A cure is impossible.

Wounds of the scalp should be treated as wounds of other parts of the integument. *Incised* wounds should be rendered aseptic, and may be closed by sutures, or the edges brought into apposition by a sublimate-gauze compress and bandage, according to the extent and location of the injury. Sutures are as well tolerated here as elsewhere. When there is no especial desire to avoid a scar, sutures may be omitted, unless the wound is so extensive and gaping that apposition can not be effected by compression. Silk is preferable in stitching wounds of the scalp. The hair should be trimmed for a fourth or half inch from the edges of the wound. When no large vessels have been divided, the introduction of the sutures will suffice to arrest the bleeding. It is a safe precaution to insert a small twist of catgut into one angle of the wound to secure drainage in case of suppuration.

Lacerated wounds of the scalp are at times very extensive and formidable. Several instances are reported of complete avulsion of the female scalp from the entanglement of the hair in machinery. In such cases transplantation of integument becomes necessary, in order to prevent otitis from denudation of the calvaria. Ordinary lacerated wounds should be rendered aseptic, and treated by a compress of sublimate gauze. No sutures should be employed, except when a scar is to be avoided, and then only after the torn and bruised edges have been trimmed off with the scissors.

Contused wounds of the scalp are usually followed by marked swelling, due to extravasation of blood (hæmatoma) beneath the pericranium. The treatment consists in cold applications, by means of the ice-bag or cloths taken from ice-water. If suppuration occurs, incision should be promptly made. A form of serous cyst sometimes results from hæmatoma of the scalp. It should be treated by aspiration, and, if one or two evacuations do not effect a cure, it should be incised, and the cyst-wall dissected out.

Gunshot wounds in this part require no especial consideration.

Punctured wounds of the scalp are not serious, as a rule, when no

poison is introduced through the wound, and when the bones are not penetrated.

Penetrating Wounds of the Skull.—When a foreign body has penetrated the cranial cavity and passed out, and the patient survives the immediate effect of the accident, the wounds of entrance and exit should be cleansed of loose fragments of bone, or any foreign body. To accomplish this it will be not only justifiable, but often imperative, to enlarge both openings, by use of the trephine, and, while employing strict antiseptic precautions, to secure free drainage for the discharge of blood or other fluids from the track of the missile. When severe intra-cranial hæmorrhage occurs, no attempt should be made to arrest it by plugging the wounds through the skull, for fatal compression of the brain might thus result. If the vessels involved can not be reached from the enlarged openings, and secured by hæmostatic forceps or the ligature, the head of the patient should be elevated, in order to diminish the pressure at the bleeding point. This may in part be aided by ligation of the extremities, as heretofore described.

If there is only a single opening, and the body is lodged within the cranium, a careful inspection should be made about the wound of entrance, and, if the presence of the missile can be recognized, it should be at once extracted, even if the application of the trephine is required. If the bullet shall have entered the substance of the brain—which can be determined in part by the careful employment of a light Nélaton's probe, provided with a good-sized porcelain tip, introduced through the wound in the skull, sufficiently enlarged by the trephine—the probabilities are that it has passed through the brain in the line of projection of the missile, and is lodged beneath the skull, at or near a point directly in the line of its projection. This condition was found to exist in the remarkable case operated on by Prof. W. F. Fluhner, in Bellevue Hospital, in 1884. The patient, aged nineteen years, received a pistol-shot wound, entering at the forehead and passing through the brain, in the line shown in Fig. 413. The hole of entrance was enlarged by biting off the edges of the bone with a rongeur. An alarming hæmorrhage from a vessel of the pia mater was controlled by a small artery-clamp, or forceps. The patient's head was placed so that the supposed track to be explored was perpendicular to the surface of the table. A good-sized porcelain-pointed Nélaton's probe was carefully introduced, and allowed almost to find its own way in the track left by the bullet. This instrument passed to a depth of six inches, where, a slight resistance being met with, it was allowed to remain. The direction of the probe indicated the point on the opposite side of the skull, at which the missile had most probably struck. Three fourths of an inch below this line the trephine was applied. Upon removing the disk of bone the dura mater appeared dark from blood



FIG. 413.—Fluhner's case of penetrating pistol-shot wound of the cranium. (After Fluhner.)

effused beneath it. An incision was made through this, and the track of the bullet through the pia mater was discovered. It had struck the inner surface of the calvaria, had rebounded with a downward deflection, and was found about half an inch from the hole made by the trephine. A small rubber drainage-tube was passed entirely through the track made by the bullet, and left projecting at each opening. Irrigation through the tube was not attempted. The wounds were dressed with iodoformized gauze, loosely laid on, and an antiseptic dressing over this. The patient recovered and returned to his occupation, suffering only with a slight impairment of memory and occasional muscular spasm.

The important lesson from this case is, that the careful exploration of the cranial cavity, and of the brain-substance, for the removal of a foreign body, is a rational and justifiable surgical procedure. The careful employment of a light, broad, dull-pointed probe will enable the operator, in a certain proportion of cases, to follow in the track of a foreign body and indicate its place of lodgment.

Not infrequently compression of the brain occurs from hæmorrhage between the skull and the dura mater, or from a collection of pus, exostosis, depression of bone, or tumor within the cranium. Within recent years researches in cerebral anatomy and physiology have enabled scientists to determine, with accuracy sufficient to justify the application of their conclusions to surgical practice, from the disturbance of function in certain portions of the economy, the region of the brain involved in the zone of compression. That portion of this subject which is most

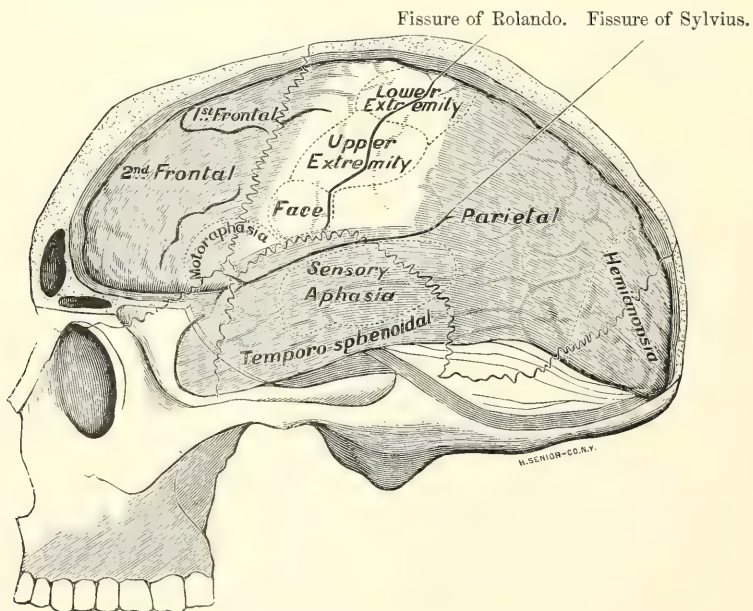


FIG. 414.—(Modified after Champoinnière.)

capable of demonstration, and therefore most practical, relates to the interference with motion in certain muscles, or groups of muscles, which have their "centers of motion" situated contiguous to the fissure of

Rolando, and to certain disturbances of the mind and the senses chiefly located in the cortex of the brain. According to Lucas-Championnière,* who adopts the conclusions of Charcot and Pitres, our knowledge of this subject may be summarized as follows: "In a lesion followed by paralysis of the *lower extremity* the trephine should expose the summit of the *ascending parietal convolution*, on both sides of the upper end of the fissure of Rolando (Fig. 414). Of the *upper extremity*, the middle third of the *ascending frontal convolution*, also on both sides of the center of the fissure; *upper* and *lower* extremities, *both* regions just given; *upper extremity* alone, with *motor aphasia*, *foot of third frontal* and lower third of *ascending frontal convolutions*, in zone marked *motor aphasia* in Fig. 414. *Facial paralysis*, lower third of the *ascending frontal* and foot of *second frontal convolutions*. *Aphasia* alone, foot of *third frontal*."

After a careful analysis of all the cases of cortical lesions of the brain published in America, and a thorough review of the results of foreign investigators, Prof. Starr arrives at the following conclusions: †

"1. Various powers of the mind are to be connected with activity in various regions of the brain, the surface of the organ being the seat of conscious mental action.

"2. The highest qualities of the mind—intellect, judgment, reason, self-control—require for their normal display integrity of the entire brain, but especially of the frontal lobes. A change of disposition and character may be considered as symptomatic of disease of the brain, and, in the absence of other symptoms, of disease of the frontal lobes.

"3. The power of sensory perception is distributed over the various regions of the brain with which the various sensory organs are anatomically connected. In these regions objects are not only first consciously perceived, but are also subsequently recognized; and hence it is in these regions that the memory pictures are stored, by whose aid the act of recognition is accomplished.

"(a) Disturbance of sight, whether in the form of actual blindness, or of failure to recognize or to remember familiar objects, or of hallucinations of vision, may indicate disease in the occipital lobes. An examination of the field of vision will indicate which lobe is affected, since blindness in the right half of both eyes may be due to destruction of the left lobe, and blindness of the left half of both eyes may be due to destruction of the right lobe.

"(b) Disturbance of hearing, either actual deafness in one ear or hallucinations of sound on one side (voices, music, etc.), may indicate disease in the first temporal convolution of the opposite side. Failure to recognize or to remember spoken language is characteristic of disease in the first temporal convolution of the left side in right-handed persons, and of the right side in left-handed persons. Failure to recognize printed or

* "La trepanation guidée par les localisations cerebrales." V. A. Delahaye et Cie., Paris, 1878.

† "Cortical Lesions of the Brain." M. Allen Starr, from "American Journal of the Medical Sciences," July, 1884.

written language has accompanied disease of the angular gyrus at the junction of the temporal and occipital regions of the left side in three foreign and in one American case.

“(c) Disturbance of smell, either as an hallucination or as a loss of power to perceive odors, may possibly indicate disease in the temporo-sphenoidal region on the base of the brain.

“(d) Disturbance of taste can not, as yet, be connected with disease in any region. This is due to lack of care in testing this sense in cases of brain disease.

“(e) Disturbance of general sensation—including the senses of touch, pressure, pain, and temperature, together with the sense of the location of a limb—may occur either in the form of subjective perceptions of such sensations without objective cause, or in the form of impairment of these sensations. In either case it indicates a disease in the central convolutions, and possibly in the adjacent portion of the parietal lobules.

“4. The power of voluntary motion of the muscles of the opposite side of the body is located in the two central convolutions which border the fissure of Rolando. Motions of the face and tongue originate in the lower third of this region; motions of the arm, in the middle third; motions of the leg, in the upper third.

“Spasms in a single group of muscles, or paralysis of a single group of muscles, may indicate disease of its motor area. Extensive spasms or paralysis may indicate a large area of disease in this region; but if more marked in a single group of muscles than in others it may indicate a small focus of disease in the motor area of that group affecting other motor areas indirectly and coincidentally. Paralysis following spasm in one group of muscles is a characteristic symptom of disease in the central region.

“5. Disturbance of the power of speech indicates disease in the convolutions about the fissure of Sylvius, on the left side in right-handed persons, and on the right side in left-handed persons. If the patient can understand a question and can recall the words needed for a reply, but is unable to initiate the necessary motions involved in speaking, the disease is probably in the third frontal convolution, and in the adjacent portion of the anterior central convolution. If the patient can not recognize spoken language, but can repeat words after another, or can use exclamations on being irritated, the disease is probably in the first temporal convolution. If the patient can understand and can talk, but replaces a word desired by one that is unexpected, the disease is probably situated deep within the Sylvian fissure, or in the white substance of the brain, and involves the association fibers which join the convolutions just named.

“In making a diagnosis of cortical disease care must be taken to distinguish between direct and indirect local symptoms; and also to separate clearly lesions of the cortex from those of the various white tracts within the substance of the brain.”

As far as the disturbances of motion are concerned, these points of interest bear such close relation to the fissure of Rolando that it is necessary to determine approximately its location. Championnière's line is as

follows: From the posterior border of the malar process of the frontal bone, at the upper outer angle of the orbit *A* (Fig. 415) draw a line *AB*, directly backward, a distance of two and four fifths inches. From *B* draw a perpendicular line, one inch and one fifth long, to *C*, then from *C*, upward and backward, to *D*, which shall terminate in the sagittal suture, two and one fifth inches directly behind the junction of the coronal and sagittal sutures, *E*. The point of junction of the sagittal and coronal sutures is not always easily recognized in the adult. If, however, the distance from the root of the nose (the naso-frontal suture) to the posterior-inferior border of the occipital protuberance be measured, the point *D* (Fig. 415) will be found to vary from three quarters of an inch to an

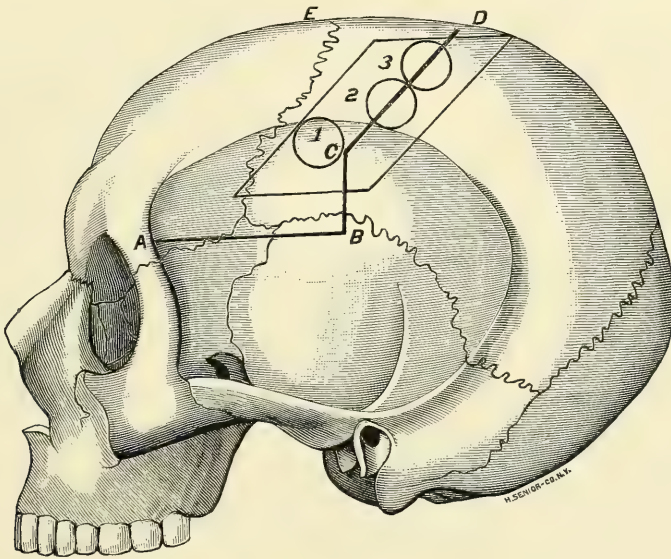


FIG. 415.—(Modified after Championnière.)

inch posterior to the center of this line. The junction of the sagittal and coronal sutures is directly above the external opening of the auditory canal. The researches of Championnière may practically be applied as follows: In complete and persistent hemiplegia, where the history of the case may exclude extravasation in the deeper ganglia, the center or bit of a large-sized trephine should be placed in the middle of this line, at 2 (Fig. 415), on the side opposite to the paralysis. If there is loss of motion or convulsive movements of the lower extremity alone, the trephine should be applied in the upper third of the line, at 3. When the upper extremity alone is involved (the lesion being probably in the middle third of the ascending frontal convolution), the operation should be performed opposite to the middle and in front of this line. When simple aphasia is present, the trephine is to be applied at the lower end, and well in front of this line, 1. If, when the button of bone is removed, the cause of the compression is not revealed, the opening should be enlarged by the rongeur, or by reapplying the trephine.

In elevating a portion of the cranial vault for exploration, or the relief

of compression of the brain, the following rules should be applied: The entire scalp should be closely shaved, thoroughly cleansed, and rendered aseptic. A proper elevation should be given the head, to suit the convenience of the operator and to command the best light. A rubber tube should be carried around the scalp beneath the occiput and just above the ears and eyebrows, thus in part controlling all external bleeding. Having determined upon the point of brain surface to be explored, make this the center of a large horseshoe-shaped incision. If it has been determined to lift the skull *en masse*, the horseshoe flap should not be raised separately, but the bone having been exposed in the line of incision, the soft parts are retracted enough to permit the division of the cranial vault in this line. This may be done with the Hey saw, rongeur, or the burr-saw in use with the dental engine. When this is done, an elevator may be inserted and the entire piece lifted by fracturing the uncut isthmus. The pericranium not having been raised, the bone may be replaced after the operation, without material impairment of its vitality.

The dura mater is next opened by a crescentic or crucial incision and reflected. Any offending mass should be removed. If nothing abnormal appears upon exposure of the cerebral surface, the question of invasion of this body, or of further surface exposure, must be determined by the gravity and prominence of the symptoms and the condition of the patient. Hæmorrhage should be controlled by fine catgut ligatures, and by aseptic water at about 110°. On account of the delicate structure of the several vessels, the ligatures should not be drawn too tight or any lateral traction made, for fear of tearing or cutting through.

The wound in the dura should be closed with catgut sutures. A fine catgut drain may at times be indicated. The bone is next turned back into place and the soft parts sutured. If only a moderate surface is to be exposed, the soft covering should be lifted separately and the large trephine employed. The button of bone removed has been replaced in a number of instances successfully by immersing it as soon as cut out in warm sublimate (105° F.) and placing it again in the hole from which it was taken. It would be dangerous to attempt restoration of the bone when the underlying dura is destroyed or removed. The success achieved in late years in this department of surgery by Horsley,* Keen,† Allis, and others justifies the hope that still greater progress is probable in the near future.‡

* "American Journal of the Medical Sciences," April, 1887.

† See same, October and November, 1888.

‡ This case of recent brain surgery (Prof. W. W. Keen, "American Journal of the Medical Sciences," October, 1888) illustrates so well the value of operative interference that an abstract is appended:

Tumor of Brain-Epilepsy.—A man, aged twenty-six, at the age of three fell and struck his head upon a brick. He remained comatose one hour. At twenty-three years of age he had an attack of severe neuralgic pains. These symptoms increasing, culminated, in February, 1885 (twenty-four years old), in epileptic convulsions, and, in April, paralysis of right face, arm, and leg. Epileptic attacks ceased from November, 1886, to June, 1887. A small scar a quarter of an inch long persisted, located two inches and a quarter to the left of median line and three inches

When laceration of brain has been produced by fragments of bone or other foreign substance, drainage is an essential feature of successful treatment; indeed it is imperative, for drainage is as necessary in the cranial cavity as elsewhere. This point is well illustrated in a brilliant case recently reported by Dr. Oscar H. Allis.* A man received a com-

behind the left external angular process. December 8, 1887, it was tender to pressure. Temperature over the scar, 95.5° F.; corresponding point on opposite side, 94.4°. December 15, 1887, operation under ether and incision through the scar down to the bone; no indication of injury to the bone. A

nick was made in the skull just at the seat of the scar. Large semi-elliptical flap three inches and a half broad; convexity of incision posterior for drainage was cut and turned forward. Trephine an inch and a half in diameter applied so as to include point under the old scar. Dura adherent to the button in the lower half. Hard mass recognized, and a second button removed. Rongeur used, to fully expose the remainder of the tumor. Dura opened. It was adherent to the tumor, and a portion of it was removed with the neoplasia, which was enucleated with the finger.

Bleeding controlled by fine catgut and hot water, 115° to 120° F. The cavity occupied by tumor was one half filled by the resilient brain tissue before operation

was completed. A bundle of horse-hairs for drains was carried across the wound and left projecting at each side. Small rubber tube inserted. Patient recovered, improved in mind and body, although mild convulsive movements occurred at rare intervals.

Keen also proposes the following procedure for the relief of abscess of the lateral ventricles or in hyperdistention by any fluid:

I. Trephine half-way from the external occipital protuberance to the upper end of the fissure of Rolando, half to three quarters of an inch to either side of the middle line. Puncture toward the inner end of the supraorbital ridge of the same side (Fig. 415 c, A). The puncture will pass through the precuneus, and the normal ventricle will be

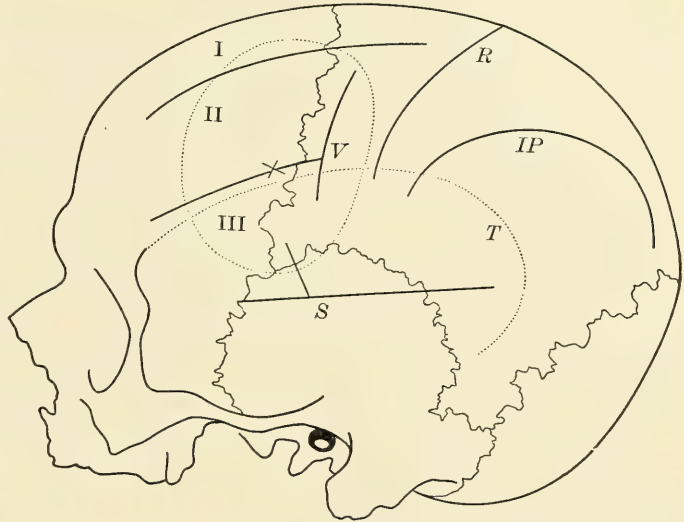


FIG. 415 A.—Diagram of the skull showing the site of the tumor. *S*, Fissure of Sylvius. *R*, Fissure of Rolando. *IP*, Intraparietal sulcus. *V*, Vertical or precentral sulcus. *T*, Temporal ridge. *I*, *II*, *III*, the first, second, and third frontal convolutions. The oval dotted line represents the tumor, the cross (*x*) the site of the scar. (Keen.)

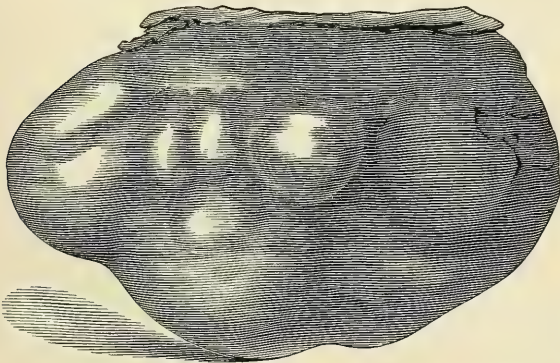


FIG. 415 B.—Appearance of the tumor with dura attached. Natural size. (Keen.)

* "Annals of Surgery," July, 1889.

minuted fracture of the frontal bone, with extensive lacerations of brain tissue. The fragments were removed and the wound cleansed. The

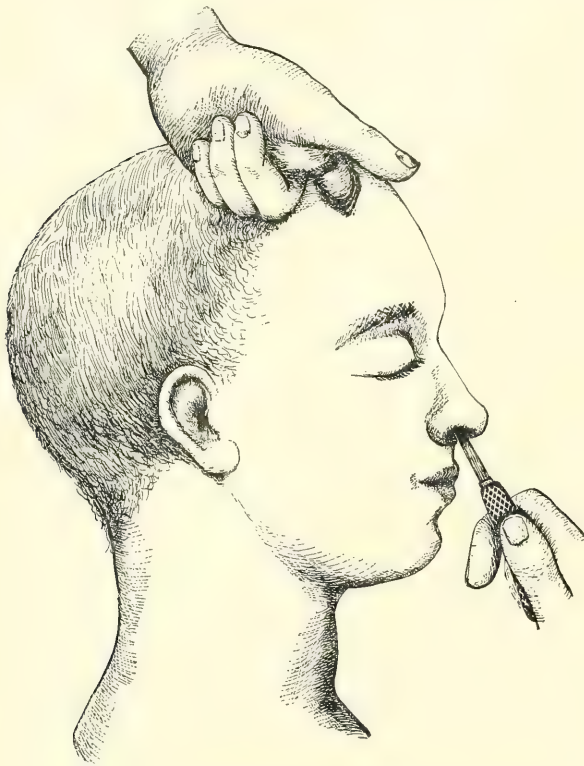


FIG. 415 D.—Drilling through the cribriform plate. (Allis.)

lesion extended along the frontal bone to its horizontal plate, which was also fissured. In order to secure drainage, with the finger of one hand as a guide, the cribriform plate of the ethmoid was bored through by a drill carried up through the nose (Fig. 415 D). A probe armed with a ligature was passed through and a rubber drainage-tube three eighths of an inch in diameter pulled through from above downward, the upper end being left on a level with the cerebral surface of the cribriform plate. A second tube was inserted and allowed to project from the nose and wound in the skull

(Fig. 415 E and Fig. 415 F). An antiseptic dressing was applied, and the patient recovered without an unfavorable symptom.

struck at some point in the posterior horn at from two inches and a quarter to two inches and three quarters from the surface of the scalp.

II. Trephine at one third of the distance from the glabella to the upper end of the fissure of Rolando and half to three quarters of an inch to either side of the middle line. Puncture in the direction of the external occipital protuberance (Fig. 415 c, B). The puncture will traverse the first frontal convolution well in front of the motor zone, and the normal ventricle will be struck in the anterior horn at about two inches to two inches and a quarter from the scalp.

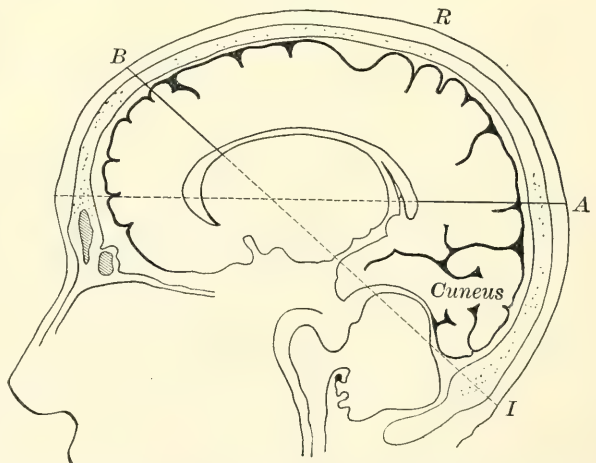


FIG. 415 c.—Antero-posterior section of the head half an inch from the median line. *R*, Fissure of Rolando. *I*, Inion. *A* and *B* (solid), lines of puncture, the dotted lines showing their imaginary continuation to the opposite fixed points. (After Keen.)

In fracture through the middle fossa, where blood or cerebro-spinal fluid escapes through the ears, natural drainage may be secured through the auditory meatus. In all such cases this canal should be cleansed with sublimate solution, and aseptic cotton pads applied to absorb the discharge and prevent septic infection.

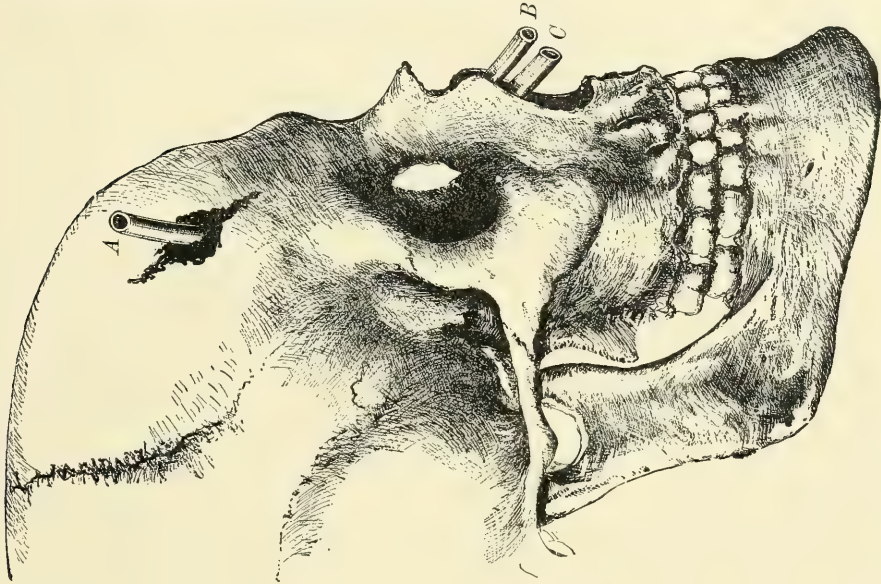


FIG. 415 F.—A, B, Through drain. C, Short tube. (Allis.)

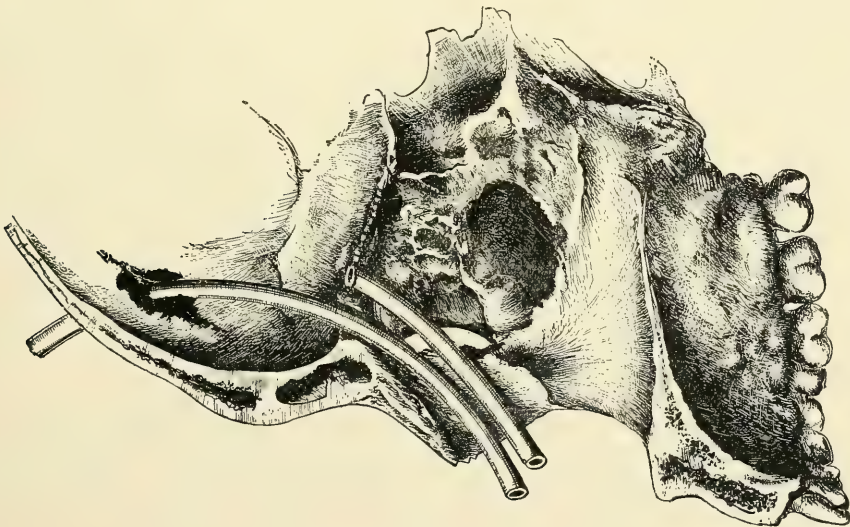


FIG. 415 E.—Drainage-tubes in position. (Allis.)

SURGERY OF THE FACE.

Wounds.—*Incised* wounds of the face usually bleed profusely. The two essential features in treatment are to arrest hæmorrhage and secure repair with the least possible deformity. When the bleeding is only slight, bringing the edges together with fine silk sutures will arrest it. When ligatures are applied, catgut should invariably be employed.

Every wound of the face should be treated with the strictest antisepsis. The approximation of the edges should be accomplished with exactness. The finest black iron-dyed silk is the best material, and the interrupted suture should be preferred. If the character of the hæmorrhage necessitates central deligation, the *external carotid* (not the common trunk) should be tied. This necessity could scarcely arise in an incised wound, unless the internal maxillary or upper part of the external carotid was involved.

Contusions of this region require, as in other parts of the body, local applications, usually of cold water or the ice-bag. Ecchymosis is, as a rule, present, and is persistent in the tissues about the eyes.

Lacerated wounds of the face are serious, on account of the danger of disfigurement after repair. If the procedure does not involve much loss of tissue, the edges may be pared smoothly and united with silk sutures, under careful antisepsis. If there has been extensive contusion, a small catgut-twist drain should be left at each end, to guard against the danger of infiltration of pus in the subcutaneous tissue. In wounds which involve the circular muscles of the eyes and mouth, great care must be taken to guard against contractions and deformities.

Punctured wounds require no special consideration. Deligation of the external carotid may be necessitated to arrest bleeding from deep wounds of the speno-maxillary fossa.

Shot wounds of the face are not, as a rule, dangerous to life, even in military practice. Of 3,312 cases, in which fracture of the bones of the face occurred as a result of shot wounds, as given in the "Medical and Surgical History of the Civil War," by Dr. George A. Otis, only 340 died, while of 4,914 flesh wounds only 58 died. In civil practice the rate of mortality is still lower.

When the missile has penetrated the speno-maxillary fossa, or divided any deep-seated vessels, the necessity of tying the external carotid may arise. A ball or any foreign body lodged in the bones or tissues of the face should be immediately removed, when this can be accomplished without an operation which may incur the danger of deformity. When, however, the missile is deeply lodged, and is of small size, it should not be molested until there is evidence that it will not remain encapsuled and harmless.

Bones or fragments of bone which have been displaced in part, but not entirely stripped of periosteum and vascular attachments, must not be removed, since, if replaced and held in proper position, they usually become reunited to the sound bone

THE EYE.

Wounds of the eyelids and of the circular muscle of the eye scarcely require special consideration. In *incised* or *lacerated* wounds a careful approximation of the edges of such wounds with the finest silk sutures, and the maintenance of the parts in a condition of perfect quiet, are essential. The sublimate and carbolic-acid solutions can not be em-

ployed when the surface of the eye is exposed. A saturated solution (about grs. xv to ʒj of water) of boracic acid is to be preferred for purposes of cleanliness. *Contusions* about the eye should be treated by cold applications, using a very small and light ice-bag, or frequent changes of bits of linen cloth, taken from a block of ice.

New Formations.—*Vascular growths* (nævi or angeiomata), usually of the capillary variety, are not infrequent in the vicinity of the eye. When of small size, not exceeding a half or three fourths of an inch, they may be successfully destroyed by the hypodermic injection of from two to five minims of a 50-per-cent solution of carbolic acid. Great care should be taken not to allow any of the solution to enter the eye.

Removal by free excision is not practicable when the tumor is of large size, and when the palpebral margins are involved, or when their shape and situation are such that deformity is apt to follow the excision. A careful application of the rules of plastic surgery to the region of the eye will often obviate deformity, even after extensive dissections with loss of tissue in the vicinity of this organ. What has been said of the excision of vascular growths applies equally to all forms of neoplasms in this region which—themselves a deformity, or malignant in character—require removal.

When this can be done with safety, it is of the utmost importance that the palpebral margin be left intact for at least one eighth of an inch in width, and as much more as is consistent with the free excision of the tumor. One incision should be parallel with the border. The palpebral

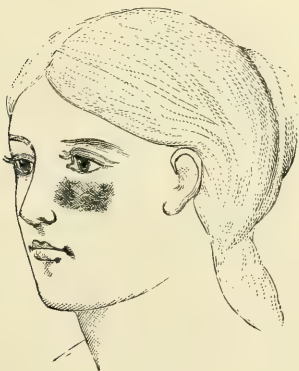

Fig. 416.

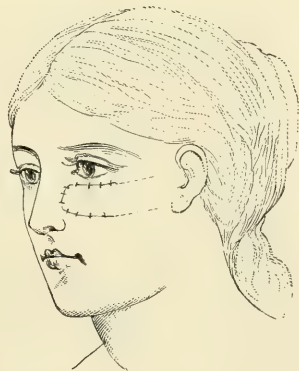

Fig. 416 A.

branch of the ophthalmic artery, which runs parallel with and about this distance from the free margin of the lid, should not be wounded when it is possible to avoid it. When the dissection is completed, a tongue of skin may be slid from the malar region across the wound, provided the space to be filled does not measure more than one inch in its transverse diameter. It is at times advisable to divide the tension by sliding a shorter flap from the direction of the nose. For larger spaces a flap may be turned from the cheek, hand, or arm, as given hereafter. Fig. 416 represents the space left after the removal of a myxo-sarcoma of the face, and Fig. 416 A the method of covering in the deficiency. From

the outer angles parallel incisions were continued through the skin toward the ear, as far as was necessary to secure integument enough to slide across the gap. The

transverse facial artery, which runs about one fourth of an inch below and parallel with the zygoma, should be kept in the flap, which is dissected up until the end nearest the nose can be carried across to the edge of the wound upon the nose and stitched at this point. The lower border is next fastened, and after this the palpebral border is stitched to the upper margin of the tongue of skin with the finest suture material. The sutures may be removed in from four to six days. It is necessary to arrest all bleeding from the bottom of the cavity left after a dissection; that from the edges will be arrested by the sutures. The tension on the



FIG. 416 B.

flap should not be so great that the blood-supply is seriously interfered with. After the first sutures are inserted, it will be well to wait for a few minutes in order to see that the circulation is established. Fig. 416 B and Fig. 416 C are taken from a patient from whom a large naevus was excised, and the wound filled by free dissection and sliding of the integument of the cheek. Little or no eversion or dragging down of the lid will follow in these operations when carefully performed.

Sebaceous tumors (retention-cysts) are occasionally met with on the outer surface of the lids, and in the skin about the orbit. They should be removed by thorough dissection of the sac. When situated



FIG. 416 C.

upon the lids they rest between the integument and the tarsal cartilage. The line of incision should be parallel with the free border of the lid, to avoid dividing the horizontal fibers of the orbicularis muscle.

Hordeolum, or "stye," is a purulent inflammation of the sebaceous gland and hair-follicle at the palpebral margin. It is a *furuncle* of the lid. Warm or emollient applications hasten the suppurative process and soften the epidermal covering. The treatment consists in early evacuation of the contents by pressure after pricking the stye with a delicate sharp lance or needle. Professor David Webster recommends sulphide of calcium, gr. ss., twice each day as a corrective and preventive of hordeolum.

Chalazion.—Obstruction of one or more of the ducts of the Meibomian glands causes a swelling and inflammation of the gland, or tube behind the point of obstruction. These protrusions appear on the conjunctival surface of the tarsal cartilage, and should be treated by puncture through the edge of the lid, with evacuation of their contents by pressure on both surfaces of the lid, directed from the base toward the free border, in the effort to squeeze out the plug and thus restore the normal condition of the excretory duct. Any incision on the under surface of the lids should be made parallel with the ducts of these glands. A rare form of cystic tumor occasionally develops in the substance of the tarsal cartilage. It may be cured by incision and destruction of the sac, or by evacuating the contents and injecting one minim of 50-per-cent carbolic acid into the cyst.

Blepharitis or inflammation of the lids may affect all or a limited portion of these organs. It most frequently involves the ciliary margins, and is known as *blepharitis ciliaris*. In rare instances the cartilages are involved. *Acute blepharitis* demands rest and local antiphlogistic applications. Cloths dipped in warm water are in general more agreeable. In *chronic blepharitis ciliaris* the scaly covering of the inflamed borders of the lids should be removed by the prolonged use of warm boracic-acid water and a mop of soft lint, having first trimmed the lashes closely. When this is done the inflamed surface should be lightly touched with a pencil of lunar caustic. At night the lids should be lubricated with a small quantity of cosmoline.

Blepharospasm, or spasm of the *orbicularis palpebrarum* muscle, results usually from irritation of the conjunctiva or cornea. It may, in rare instances, occur without any inflammatory exciting cause (idiopathic blepharospasm). The treatment is rest and the removal of the cause of the spasm. In rare cases division of the muscle through the outer canthus is demanded to relieve pressure on the conjunctiva, cornea, and globe.

Blepharophimosis, or narrowing of the palpebral opening, is due to contraction of the lids at the outer canthus or angle. It may be relieved by an incision commencing in the outer angle and carried directly out through the entire thickness of the commissure for the required distance, extending the cut in the skin a short distance farther than that

in the conjunctiva. The edges of the skin and mucous membrane are then united by silk sutures, as shown in Fig. 416 D.

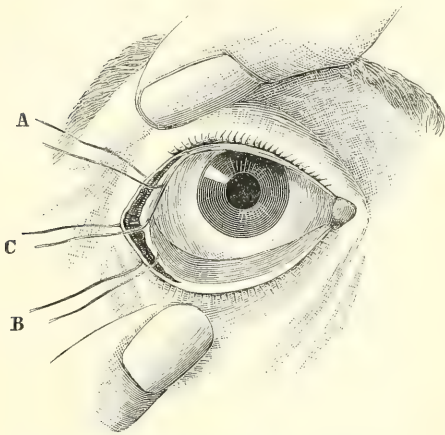


FIG. 416 D.—Incision and sutures in operation for blepharophimosis. (De Wecker.)

Lagophthalmos.—Inability to close the eyelids may be due to protrusion of the globe from tumors of the orbital cavity, or of the globe; it occurs in the disease of which enlargement of the thyroid body and “exophthalmos” are symptoms; in staphyloma and in paralysis of the facial nerve. It is a serious condition, on account of the liability of ulceration of the cornea from prolonged exposure of the anterior surface of the globe. The indications in *treatment* are first *palliative* in keeping the lids closed by bandaging, or uniting the edges by sutures.

When the condition is permanent, the operation of *tarsoraphy* is to be performed as follows: Introduce a horn spatula between the globe and the lids at the outer canthus; make the tissue tense, and with a sharp knife remove the free borders of the upper and lower lid for a distance sufficient to close the eye to the desired extent. The incision should remove the roots of the ciliae. The opposing edges are now united with silk sutures.

Blepharoptosis.—Ptosis, or inability to lift the upper lid, may be due to partial or complete paralysis of the third nerve, or the filament which supplies the levator palpebræ; to adhesions from inflammatory affections of the lid; to the presence of neoplasms or to acquired or congenital weakness of the levator muscle. In ptosis due to paralysis when electricity fails to restore the function of the muscle or nerve, it may be corrected by excising an elliptic-shaped piece of the skin of the upper lid, including the areolar tissue and the fibers of the orbicular muscle. The lower incision should run parallel with the margin of the lid and about one quarter inch above it. The edges of the two incisions should be united with silk sutures.

Symblepharon is a term applied to adhesions of the lids to the ocular conjunctiva. Limited adhesions may be broken up repeatedly until a cure is effected by the extension of an epithelial covering over the granulating surfaces. When the adhesions are extensive, Teale’s operation may be performed.

Supposing the condition shown in Fig. 416 E to exist, the symblepharon is cut through at A, in the line of the corneo-sclerotic junction, and the lid is dissected up to the normal fold of palpebral and ocular conjunctiva (D, Fig. 416 F). Two flaps (B and C, Fig. 416 F) are now dissected up from the conjunctiva, and turned down and stitched in position to cover the raw surface left by the dissection of the adhered lid. The spaces left by lifting the flaps are closed at once

by fine silk sutures (Fig. 416 G). The island of tissue left on the cornea is allowed to disappear by atrophy.

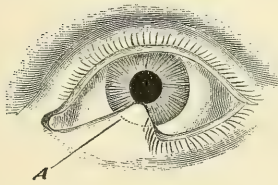


FIG. 416 E.
Symblepharon. A, Incision through the attached conjunctiva at the corneo-sclerotic junction. Teale's operation. (Swanzy.)

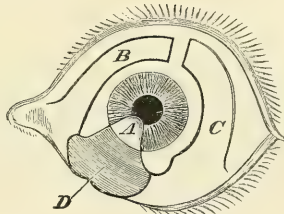


FIG. 416 F.
The same. D, Adherent conjunctiva dissected down. B, C, Incision for flaps to cover this wound. (Swanzy.)

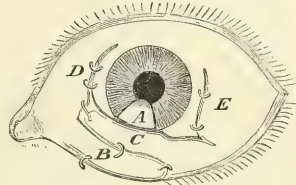


FIG. 416 G.
The same. A, Tip of symblepharon left to disappear by absorption. C, B, Flaps turned and sewed into new position. D, E, Wounds closed by sutures. (Swanzy.)

Ectropion, or eversion of the lid, may be *partial* or *complete*, and is due first to weakness of the orbicularis palpebræ muscle, especially to the palpebral fibers; second to cicatricial contractions due to injury or disease of the soft parts above the eye, or of the bones surrounding the orbital cavity. The lower lid is usually involved.

The *treatment* is operative. In mild cases, those in which no cicatricial adhesions have occurred, the following operation, as given by Swanzy, is advised:

Method of A. Robertson.—Thread a long quarter-curved needle with each end of a small Chinese twisted-silk ligature, about fifteen inches long; with one of these perforate the entire thickness of the lid one line from the ciliary margin and one quarter of an inch to the outer side of the center (*b, a*, Fig. 416 H).

The needle is now passed over the conjunctival surface of the lid, till it meets the fold of conjunctiva reflected from the lid on to the globe through which the needle is thrust—the point being directed slightly forward—and pushed slightly downward under the skin of the cheek until a point is reached from one to one and a quarter inch below the edge of the lid, where it is brought out. The other needle is introduced in a corresponding manner at the same distance from the middle line on the inner side (*a', b', d'*, Fig. 416 H).

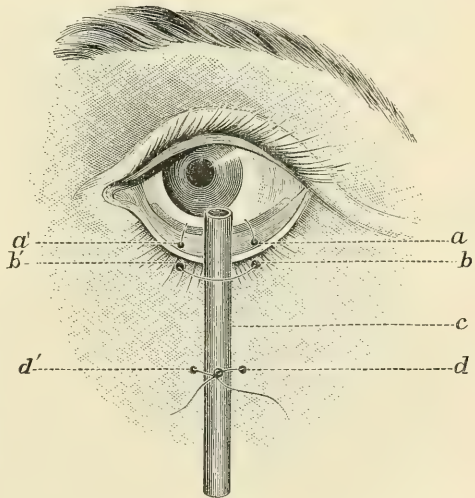


FIG. 416 H.—Robertson's operation for ectropion of the lower lid. (A. Robertson.)

A piece of thin sheet-lead, about one inch long and one quarter inch broad, rounded at its extremities and smooth on all surfaces and edges, bent to fit the curvature of the eyeball, is now slipped under the loops of the ligature that

pass over the conjunctival surface of the lid; at the same time a short piece of small rubber drainage-tube is passed beneath the loop on the cutaneous surface just below the ciliary margin. Now, as the ends are

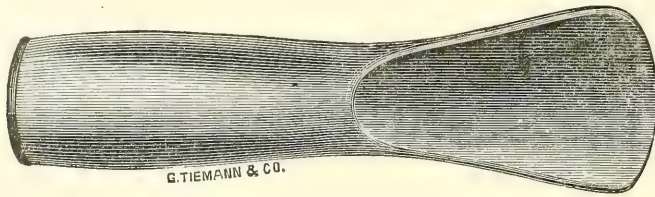


FIG. 416 l.—Jaeger's plate lid-holder.

drawn gradually tight, the edge of the lid is made to revolve inward over the upper edge of the piece of lead, while the tarsal cartilage is molded to the curve of the lead, and the lid assumes its normal position. The threads are tied below over the rubber tube, *d, d*. The sutures and lead are removed from the fourth to the sixth day.

In mild ectropion, due to limited cicatricial adhesions, Wharton Jones's V Y operation may be adopted.

As shown in Fig. 416 j, a V-shaped incision is made so as to include the scar, the flap dissected up, and the underlying cicatricial adhesions cut out. The lid is lifted into its normal position, stitched to its upper fellow, if necessary, to hold it in place, and the edges of the wound sutured from below upward, leaving a Y-shaped scar (Fig. 416 k).

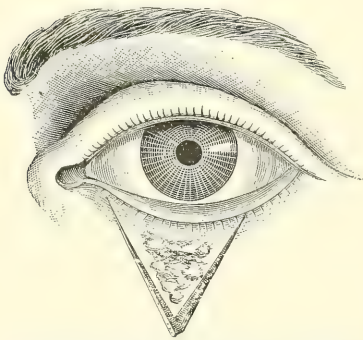


FIG. 416 j.—Wharton Jones's operation for ectropion of the lower lid. (De Wecker.)

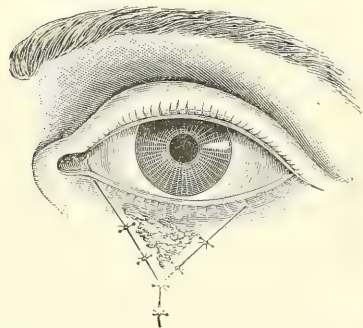


FIG. 416 k.—The same, after the flap is dissected up and the sutures tied. (De Wecker.)



FIG. 416 l.—Complete ectropion of lower lid, due to cicatricial contractions after ostitis of the orbital margin.

In more extensive adhesions (Fig. 416 L), in which neither of the foregoing methods will meet the indications, a plastic operation is inevitable. Make one incision, parallel with the free border of the lid,

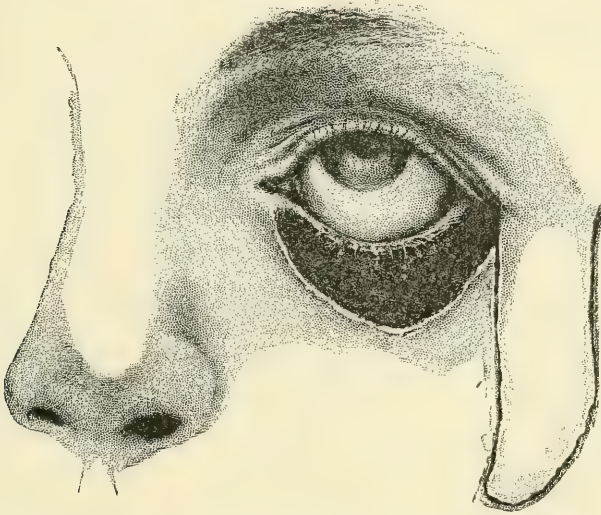


FIG. 416 M.

Showing the cicatricial tissue dissected out, and the flap to be turned from the cheek outlined.

which shall extend beyond the cicatricial tissue to be removed. Dissect out freely all adhesions and cicatricial material, until, when left to itself, the remaining edge of the lower lid rises into its natural posi-

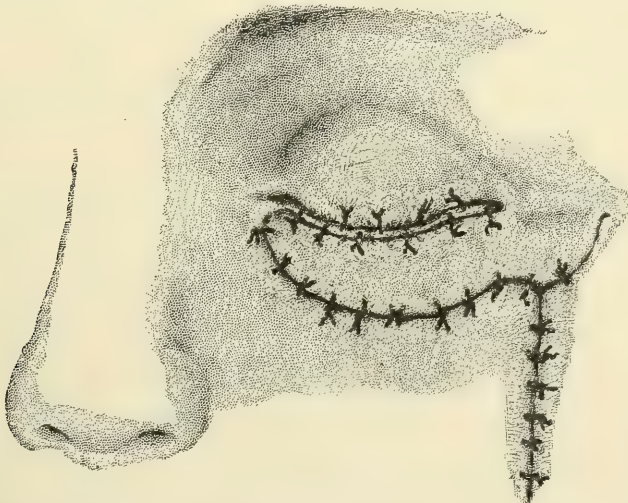


FIG. 416 N.

The flap sutured into position, and the wound formed by its removal closed.
The lids temporarily sutured.

tion. In order to fill the deep oval cavity (Fig. 416 M) left by such dissection, a flap may be turned from the cheek, forehead, or arm. The plan of the flap from the cheek is shown in Fig. 416 N. It should be cut by measurement, so as to fit without tension. As soon as it is

turned across to its new position, the eyelids should be stitched together, and the flap accurately and carefully stitched to the margins of the elliptical wound. Before the lower row of sutures are inserted, the edges of the perpendicular wound from which the flap was removed should be approximated by sutures of fine silk, which material should be used throughout. The stitches are to be removed on the fifth day. If any puffing remains at the seat of the pedicle of the flap, it may be relieved, after a few months, by dissecting out a small elliptical piece and bringing the edges together. As it is often desirable to avoid a scar upon the face, an effort should be made to fill the cavity left by dissecting out cicatricial tissue by turning a flap from the ulnar border of the palm of the hand, which is free from hairs.

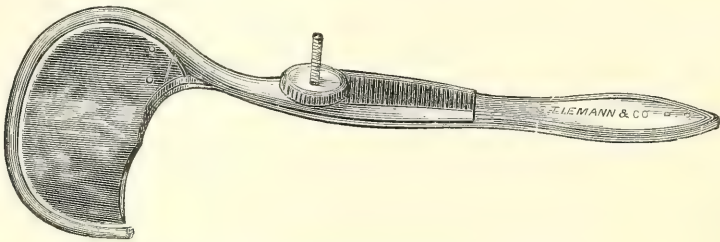


FIG. 416 o.—Knapp's entropion forceps, or clamp.

Entropion, inversion of the lid, usually results from chronic inflammation of the conjunctiva and tarsal cartilage. It is more frequent in the upper lid. In mild cases relief may be obtained by excising an

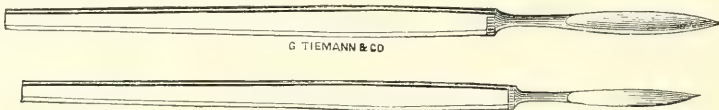


FIG. 416 p.—Lid scalpels.

elliptical strip of the integument of the lid and stitching the edge of the wound together. When, however, the tarsal cartilage is involved, Snellen's method will prove more satisfactory.

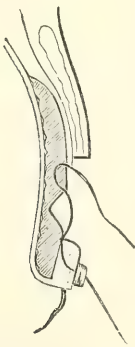

FIG. 416 q.—Perpendicular section showing character of dissection. The muscular strip and a triangular strip of the tarsal cartilage are removed. (De Wecker.)

With Knapp's clamp applied, make an incision through the skin one eighth of an inch from and parallel with the whole length of the margin of the lid. Lift the *skin-flap*, expose the fibers of the orbicularis muscle, and excise a strip of the muscle about one twelfth of an inch wide for the full length of the incision. The tarsal cartilage is now seen, and from it as far as it is exposed a wedge-shaped piece is excised with a sharp knife (Fig. 416 q). The apex of the wedge points toward the conjunctiva, but the section should not extend entirely through the cartilage. Three sutures are now inserted, each entering from without

inward, traversing the skin and muscle (Fig. 416 R) of the strip left at the palpebral margin; then in the same direction it is carried across the wound into the upper bevel of the incision in the cartilage, from which it emerges (without transfixing the integument of the flap), to be again brought out through the tissues it first entered, about one eighth of an inch distant from the point of entrance. Each end of the suture is fastened with a shot, to prevent it cutting through.

Eczema of the eyelids is not of very frequent occurrence. Swanzy recommends the daily removal of the crusts by bathing the parts in a warm solution of bicarbonate of potash, drying, and then

painting with solution of nitrate of silver (gr. xx to water ℥j); after this an ointment of boracic acid (gr. xxx to ℥j) is applied.

Epicanthus.—This term is applied to a congenital defect which consists of a fold of skin stretched across the inner canthus and the caruncula. It may be relieved by excising an elliptical piece of integument in the long axis of the nose just between the eyes. The width of the excised portion must be sufficient to remove the deformity when the edges of the wound are drawn together by sutures.

Restoration of the Eyelids.—In destruction of the lids by accident or disease it becomes necessary to restore the covering to the globe. Flaps may be turned from the neighboring healthy integument or borrowed by a plastic operation from the arm. In many cases much damage may be prevented by applying good-sized and numerous grafts to the exposed surfaces while granulation is going on.

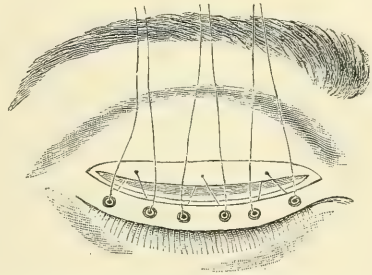


FIG. 416 R.—Front view of the same, with sutures inserted ready to be tied. (De Wecker.)

THE LACHRYMAL GLAND AND DUCTS.

Disease of the *lachrymal gland* is rare. In inflammation of this organ (*dacryoadenitis*) tenderness and swelling may be observed in the upper outer portion of the orbital cavity. In well-marked enlargement from any cause, the eyelid is pushed forward and the globe displaced downward and inward. An abscess here should be opened by puncture through the base of the lid at the most convenient point. When a neoplasm develops in the gland, extirpation should be done by incision in the fold of the upper lid, just beneath the brow.

Epiphora, or continual overflow of tears, is caused by obstruction in the system of canals which normally should conduct the secretion of the lachrymal gland from the margins of the lids into the nasal cavity, or by displacement of the *punctum lachrymale*, so that the tears can not enter the orifice. On account of its position, the lower canaliculus is of much more importance to the drainage of the eye than the upper.

Epiphora due to disturbance of the canaliculus may be present as a symptom of any displacement of the lower lid, from swelling, paraly-

sis, or cicatricial contraction, the direction of the puncture being so changed that neither gravity nor the normal suction-force will carry the secretion into the opening. Occlusion, partial or complete, may occur either from lodgment of foreign substances, products of inflammation, pus, epithelia, etc., and occasionally to calcareous formations (*dacryoliths*).

The most common form of obstruction is, however, met with in the nasal portion of the excretory apparatus. Catarrhal inflammation of the mucous membrane lining the canal or cyst may occlude the duct either by approximation of the walls or by excessive secretion of tenacious mucus. Such condition is met with in patients of all ages, occurring chiefly in the poorly nourished and scrofulous or tuberculous subjects, who suffer from chronic nasal catarrh and ophthalmia, or ostitis of the neighboring bones. As a result of obstruction in the nasal duct, *dacryocystitis*, or inflammation of the lachrymal sac, may ensue with distention, the swelling showing beneath the skin at the inner angle of the eye (*muco-cele*).

The *treatment* of displaced *punctum lachrymale* should be directed to the restoration of the lid to its normal position. In partial obstruction, due to catarrhal conditions, relief may be obtained by slitting the canal with the canaliculus knife or scissors, and frequently repeated irrigations



FIG. 417.—Agnew's canalicula knife.

with the lachrymal syringe. When obstruction occurs, dilatation by means of probes is indicated. Should the stricture be close and resisting, the knife should be carefully introduced and a division effected, the dilatation being continued by inserting the probes at intervals of two to six days. The prognosis in many cases, no matter how faithfully and skillfully treated, is not favorable.

In slitting up the canaliculus the delicate probe-pointed knife or scissors should be introduced at the inferior punctum, and carried toward the canthus for a distance of about one sixth of an inch, the slit extending for this distance. The wound should be kept open by forcibly separating the edges once or twice a day, until the cut surfaces are covered with epithelium and the trough becomes permanent. Some operators in

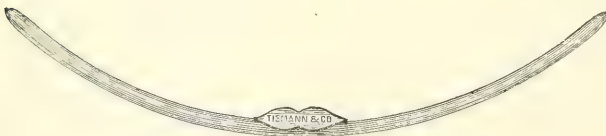

FIG. 417 A.—Theobald's lachrymal probes.

chronic dacryo-cystitis prefer to slit the upper canaliculus and pass the probes by this route. The bulb-pointed dilating-probes should now be careful-

ly introduced, beginning with the smaller sizes (Fig. 417). As soon as the bulb enters the sac, it should be gently and slowly directed along the nasal duct until it is arrested by the floor of the nose. The larger sizes may be introduced as in the treatment of stricture of the

urethra. After full dilatation is secured the channel should be washed out daily, for about ten days, with a 1-per-cent boracic-acid solution. For this purpose Anel's syringe (Fig. 417 B) will be found useful. The probe-pointed nozzle is introduced into the sac and the water forced through until it flows freely into the nose. If the obstruction recurs, the probes should be reintroduced at regular intervals, gradually increasing until a permanent opening is effected.

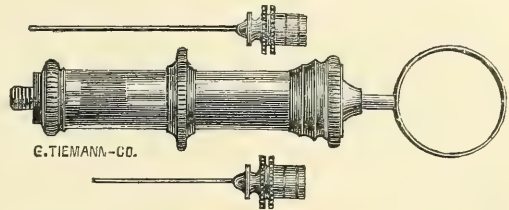


FIG. 417 B.—Anel's syringe.

Trichiasis, or turning in of the eyelashes, occurs with entropion, but may exist independently. Occurring with inversion of the lid, it does not require any other interference than that given for the cure of entropion. When the ciliæ turn in without inversion of the lid, the proper method of treatment is total excision of the hair-follicles. This should be accomplished by two parallel incisions made along the margin of the lid, one on either side of the row of



FIG. 417 c.—Grüening's depilating forceps.

hairs, and extending deep enough to insure the complete removal of the roots of the ciliæ. When only a few hairs are at fault, the follicles may be destroyed by the galvanic needle. When depilation is demanded, the instrument shown in Fig. 417 c will be found of great service. In *distichiasis* there is an extra row of ciliæ; these require removal by the method just given.

THE CONJUNCTIVA AND CORNEA.

Conjunctivitis may be acute or chronic, and circumscribed or diffuse. *Simple conjunctivitis* may result from prolonged strain or over-use of the eyes, from the lodgment of foreign particles, or exposure to strong winds. The hyperæmia may be confined to a limited portion of the mucous membrane, or spread over the entire palpebral and ocular conjunctiva.

The treatment consists in the instillation of two or three drops of cocaine, two to four per cent solution, at intervals of from one to several hours, the removal of any foreign matter, rest by closure of the lids, or the dark room and the application of soft cloths taken from cold boracic-acid solution (grs. x to $\frac{3}{j}$) or from a block of ice.

Follicular conjunctivitis may follow an acute simple inflammation, and is characterized by the development of small red points or elevations scattered over the deeper portions of the palpebral surfaces of the mucous membrane and the contiguous reflection of the ocular conjunctiva. The elevations are swollen and distended lymphatic channels and follicles. The disease is characterized by considerable pain, inability to use the

eyes, and a sensation as if a gritty or sandy substance were present. In *treatment* the condition of the general system should be improved by tonics and nutritious diet; rest to the diseased organs, and the daily application, by means of a camel's-hair brush, into the conjunctival sac of a small mass, about one eighth-inch diameter, sulphate of copper gr. ss. to ij in ℥j vaseline (Swanzy).

Granular Conjunctivitis (Trachoma).—It is not yet positively known whether there is any real pathological difference between follicular and granular disease of the conjunctiva. Some observers hold that the latter is but an exaggerated and chronic form of follicular conjunctivitis. The weight of opinion, however, favors the non-identity of the two diseases. Trachoma is chiefly met with among the lower classes—the poorly fed and overcrowded, who live in damp and unwholesome surroundings. It is held to be contagious at all times, and, in the more violent forms, when a muco-purulent discharge is plentiful, the contagious nature of the affection is evident (Fig. 418).

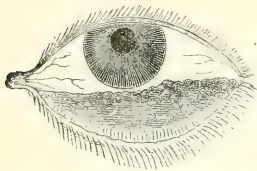


FIG. 418.
Granular lower lid. (Eble.)

In the earlier stages there appear upon the lower lid round, granular elevations, vesicular at times, scattered here and there, or the whole mucous membrane may be thickly studded. As a result of the chronic inflammatory process the lid is at first thickened. As the process is continued, connective tissue is developed with the usual cicatrization and contraction, causing, in obstinate cases, deformities of the lids and great and persistent discomfort.

The treatment includes the measures just given for follicular conjunctivitis. In addition, either the sulphate of copper stick or nitrate of silver in strong solution—grs. x-xx to ℥j—or the *mitigated lunar caustic*. Nettleship advises the following strength: "Nitrate of silver, one part; nitrate of potash, two parts, fused together and run into molds to form short pointed sticks; used for granular lids and purulent ophthalmia." The application should be made every day, or less frequently, as may be demanded. When these measures fail, canthoplasty may be done and the diseased tissue dissected from the lids.

Gonorrhœal Ophthalmia.—Conjunctivitis caused by the introduction of the virus of gonorrhœa into the eye should be treated with great care and persistency from the first symptom of this painful affection. Usually a single organ is attacked. It is important that, while the effort to cure one eye is being made, the other should be protected from the contagion. To effect this, a watch-glass, to the edge of which adhesive plaster is attached, is placed over the sound eye and closely fastened to the skin about the orbit by the plaster, so that it is hermetically sealed. This should not be removed until the other eye is well.

In the local treatment of the affected eye it is required to remove the purulent discharge by frequent irrigation with warm boracic-acid water or by the pellets of lint or absorbent cotton, and to brush over the everted lids once or twice a day, as the attack is light or severe, a solution of nitrate of silver (grs. xx to ℥j). The excess should be immediately

washed off with tepid water. Cold applications are of great importance, and a very efficient method is to apply frequent changes (every one or two minutes) of pieces of lint about two inches square, which are taken directly from a block of ice and laid over the inflamed organ. In this form of conjunctival inflammation, as in others where the injection is marked and the thickening great, and where painful *blepharospasm* occurs, or where a free discharge of purulent matter can not be effected by ordinary means, *canthoplasty* is required. This operation consists in slitting the outer canthus in the direction of the ear, and in this way dividing the fibers of the orbicular muscle.

In gonorrhœal conjunctivitis the impairment of function in the muscle is not intended to be of long duration, and the wound is left open. In some cases of spasm of this muscle, and where a chronic inflammation exists, the mucous membrane is stitched to the skin along the edges of the wound, thus preventing a reunion. Reunion may be effected later by paring the edges and bringing the parts together after the lesion for which the canthoplasty was performed is healed. Cocaine should be used to relieve pain, and all adhesion between the ocular and palpebral mucous surfaces should be broken up as soon as discovered.

Conjunctivitis in the new-born (*ophthalmia neonatorum*) is a form of purulent ophthalmia which usually results from the inoculation of the conjunctiva with septic matter present in the genital passages of the mother. It may come from carelessness on the part of the nurse, herself affected with a leucorrhœa, etc., or from the lodgment of any virus in the eye of the child. The *treatment* is *prophylactic* as well as *curative*.

The eyes of a child born of a mother known to be suffering from a vaginal discharge of a purulent character should, as soon as possible after birth, be washed or mopped out with clean warm water, or



FIG. 418 A.—Drop-glass for the eye.

boracic-acid solution, to be followed with one or two drops of a 2-per cent nitrate-of-silver solution (grs. ijss.— ζ j) once or twice a day, for three or four days.

When the disease is declared, the pus should be gently removed from the eye by pellets of soft lint or absorbent cotton, dipped in warm boracic-acid solution, the lids everted, and nitrate-of-silver solution (grs. v-x to ζ j) applied to the inflamed surfaces by means of a camel's-hair brush. The excess should be immediately washed away by the free use of warm water. This should be repeated every day until the purulent discharge is notably diminished. Boracic-acid water (grs. v— ζ j) should be used several times each day after the application of the nitrate of silver.

Croupous conjunctivitis is a contagious disease met with in children, and characterized by injection of the mucous membrane, swelling of the lids, and the deposit of a film or membrane upon the conjunctiva.

The *treatment* consists chiefly in frequent washing of the eye with warm boracic-acid water in the earlier stages. When suppuration supervenes, the indications are the same as for purulent ophthalmia.

Diphtheritic Conjunctivitis.—In this disease, which is exceedingly contagious, the inflammatory process is rapid and often hopelessly destructive. The lids soon become greatly swollen, and the mucous membranes are glazed over with a tough, closely adherent diphtheritic membrane. The period of infiltration varies from six to ten days, and is followed by the stage of suppuration.

Treatment.—The immediate danger is destruction of the cornea, the circulation being more or less interfered with by the false membrane. Since all pressure should be eliminated, in extreme cases it will be advisable to perform *canthoplasty*. Cold-water dressings should be employed in the early stages. Leeches to the temples are advised. When suppuration ensues, astringents are indicated.

Pterygium is the name given to a vascular network which extends from the ocular conjunctiva on to the cornea. It is usually situated on the inner side, less frequently on the outer portion of the globe. It is commonly triangular in shape, the apex encroaching more or less upon the corneal surface. It is caused by constant irritation from dust or sand, or fine particles of matter floating in the air, and is therefore chiefly met with in sandy, arid regions.

When small and not progressive, it is advisable not to interfere with pterygium. When it is growing steadily, it should be tied off or removed by dissection. For the first method the pterygium is lifted at the margin of the cornea, and a fine silk thread carried beneath it here. A second is carried beneath the base of the mass at the conjunctival fold. The ligatures are tied and cut short. In a few days they come away,

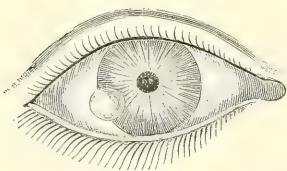


FIG. 418 B.
Pterygium. (Swanzy.)

and the vascular tuft disappears; or a dull instrument, as a strabismus-hook, may be inserted beneath the pterygium, which is gradually detached and divided with the scissors. One or two sutures are inserted to close the wound, where the base of the growth is cut away from the conjunctiva.

Pinguecula.—This is a small, yellow elevation occasionally met with at the inner or outer margin of the cornea (Fig. 418 B). It occurs usually in the aged, and should not be molested unless it seriously interferes with vision or comfort. It is a simple hypertrophy of the tissues of the conjunctiva.

Lupus of the conjunctiva is exceedingly rare, and does not require special consideration.

Epithelioma here does not differ from this affection on other mucous surfaces.

Cystic tumors occur in the conjunctiva in a certain proportion of cases, and demand extirpation.

Polypus develops occasionally on the semilunar fold, or caruncula, and should be clipped off.

Lithiasis, or calcification of the secretion of the Meibomian glands, appears in the shape of little white spots or elevations on the inner surfaces of the lids. As they produce considerable irritation of the conjunctiva and cornea, they should be picked out with a needle-point after anæsthesia with cocaine is secured.

Xerosis is a term applied to a dry condition of the conjunctiva resulting from changes in the structure of this membrane and deficient supply of the secretions which moisten this surface. The indications are to remove, if possible, any chronic inflammatory condition, and keep the eye moist by artificial means.




FIG. 418 c.—Sichel's iris knife.

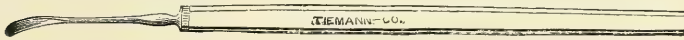


FIG. 418 d.—Daniels's curette.

CORNEA.

Foreign Bodies and Wounds.—Non-penetrating wounds of the cornea should be thoroughly cleansed with warm boracic-acid solution, and the lids closed with a bandage until repair is effected. A penetrating wound should be treated on the same principle as the incision for cataract.

A foreign body lodged upon or buried in the cornea should be at once removed. Anæsthesia with cocaine is essential. Oblique illumination by means of the convex lens is of value in locating the body. A clean needle or knife-point may be used in lifting the foreign substance out.

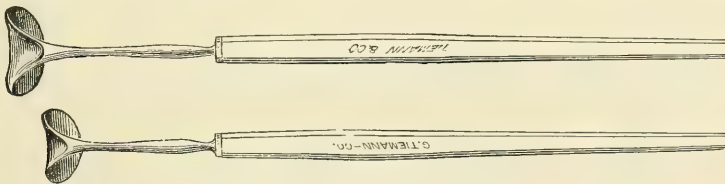


FIG. 418 e.—Demarre's retractors.

Keratitis, or *corneitis*, may originate from injury or disease of the cornea proper or by extension of the inflammatory process from the conjunctiva or sclerotic, iris or choroid. The symptoms are pain variable in character, interference with vision, especially if the infiltration occurs toward the center of the cornea, and the appearance of a cloudy film upon the normally clear and transparent membrane.

Diffuse idiopathic keratitis usually commences at the periphery and travels toward the center. Occurring as a feature of a constitutional dyscrasia (syphilis, tuberculosis, etc.), both eyes are usually, though not simultaneously, involved.

Abscess of the cornea may be recognized by the grayish-yellow color of the pus collection and the greater density of the membrane at this point. In many cases the transudation or escape of the purulent liquid

takes place into the anterior chamber, and may be seen to occupy the lower portion of this space (*hypopyon*).

Treatment.—In *traumatic keratitis* the removal of all irritation, disinfection with warm boracic-acid solution, relief from pain by cocaine locally or morphia internally, and the exclusion of light by the dark room, bandage, or shade, are the indications.

When the disease is *secondary* to inflammation in other parts of the globe or conjunctiva, the treatment should be directed to the original malady as well as to the protection of the cornea.

Diffuse keratitis demands active constitutional treatment to increase nutrition and neutralize the virus of general infection. In *abscess*, tension should be relieved by careful puncture. Penetration of the anterior chamber with the instrument should be avoided, unless the pus here is rapidly increasing; it should then be evacuated.

Pannus is a term applied to a condition of opacity of the cornea due to the formation of a vascular network beneath the epithelial covering of this membrane. It is associated with a conjunctivitis, the vessels really extending from the conjunctiva into the cornea.

If the disease is due to chronic granular lids, entropion, distichiasis, etc., the cause should be at once eliminated. In milder cases of persistent pannus a cure may be effected by excision of a zone of conjunctiva and subconjunctival tissue from around the cornea (Nettleship). In severer cases the local use of jequirity-bean is advised. Prof. David Webster recommends the following:

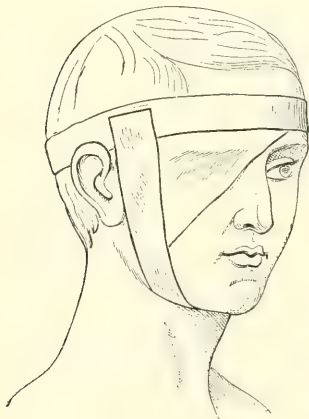


FIG. 419.

One jequirity-bean coarsely powdered is placed in an ounce of water for four hours. The patient is then required to bathe the affected eye very freely with this solution for ten or fifteen minutes, letting some of it get into the eye. One thorough washing will usually produce the characteristic membrane of the conjunctiva. If this does not succeed, the operation should be repeated. Or the bean, very finely pulverized, may be applied to the whole palpebral conjunctiva.

A convenient shade or screen for the eye is shown in Fig. 419.

Ulcus Corneæ.—Ulcers of the cornea may follow injury, or the eruption of herpes or small-pox; they are met with in conditions of general malnutrition (syphilis, tuberculosis, etc.), and may also occur with inflammation of the other structures of the eyeball, or of the lids or conjunctiva.

Herpetic vesicles occur at times upon the cornea, either as *herpes zoster ophthalmicus* or *herpes corneæ febrilis* (Swanzy). They appear as groups of clear vesicles, the superficial covering of the vesicle giving way within a few hours and leaving a shallow ulcer. In *treatment*, herpes, or the resulting ulcer, demands little beyond protection from

light, the removal of all irritation by the bandage, and the prevention of infection by careful aseptic irrigation.

Phlyctenulæ of the Conjunctiva and Cornea.—Phlyctenular ulcers occur almost invariably in strumous subjects, either with or without any direct exciting cause. When first noticed they are usually papules or pustules on the conjunctiva or cornea or both. There is, however, a localized hyperæmia in and near the spots where the elevation occurs which precedes the papule or pustule. Breaking down and discharging their contents, ulcers of variable extent are formed. They frequently develop on the conjunctiva and sclerotic without invading the cornea. Not infrequently, however, the process of ulceration travels on and toward the center of the cornea, leaving behind a trail of enlarged vessels, giving to the whole a comet-like appearance (Fig. 420). Perforation may follow in a certain proportion of cases. These ulcers may occur in all ages, but are chiefly met with after the third year and before the twenty-fifth year of life.

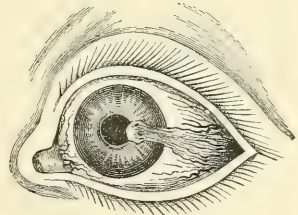


FIG. 420.
Phlyctenula of the conjunctiva
and cornea. (Travers.)

Ulcus Serpens.—The acute serpiginous ulcer is probably due to infection. It commences as a grayish film or spot, breaking down from the center, leaving sharp, precipitous edges (as in phagedenic chancre), “one part of which is more densely opaque than the rest; this infiltrated advancing edge is the distinguishing mark of the ulcer” (Nettleship).

Treatment.—In phlyctenular keratitis and conjunctivitis warm applications of boracic-acid water are useful. Pain should be relieved as heretofore directed. If blepharospasm is present, *canthotomy* may be necessary. The ulcers should be stimulated locally by use of nitrate of silver to those on the conjunctiva, the mitigated stick; while weaker solutions (gr. v-x, ζ j) may be used for the corneal ulcers. In given cases the ulcers may be scraped out or burned with the fine galvano-cautery platinum wire. The prevailing dyscrasia should be corrected by appropriate remedies. The nutrition should be increased, and an out-of-door life advised.

In acute serpiginous ulcer active measures are often imperative, the phagedenic process marching rapidly to perforation and collapse of the globe. Hot boracic-acid water applications at intervals of an hour or two are advised for relief of pain. Cocaine may also be instilled. If the ulcer does not remain stationary, it should be carefully and thoroughly burned with the cautery needle upon the same principle as for chancreoid ulcer of the skin. When the serpiginous ulcer dips down into the deeper corneal tissue and undermines it, it should be laid open by incision in its entire extent.

Staphyloma Corneæ.—Bulging of a portion of the corneal surface may result from intra-ocular tension upon a point weakened by ulceration or cicatrization. *Conical cornea* differs from this in being due to atrophic (not inflammatory) changes in the central portion of the cornea,

this part projecting by reason of intra-ocular tension. When perforation takes place, the aqueous humor escapes and usually carries the iris with it, this latter structure being caught in the opening, where it adheres. This condition is known as *anterior synechia*.

When the staphyloma involves a limited portion of the cornea, iridectomy should be done, making the artificial pupil behind the best remaining surface of the cornea. In complete staphyloma, vision being lost, Critchett's operation is advisable. Five half-curved needles, threaded with fine strong silk, are passed from above downward through the sclerotic, being made to enter and exit half-way between the insertions of the recti muscles and the posterior edge of the staphyloma. When

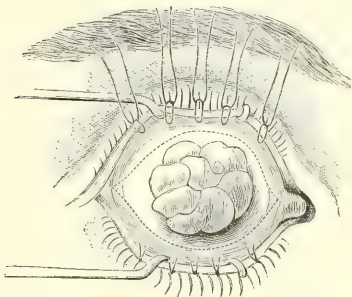


FIG. 421.—Needles introduced in Critchett's operation for staphyloma. (Abadie.)

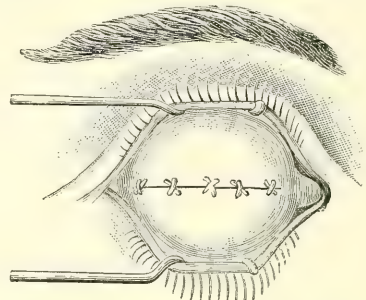


FIG. 421 A.—The same, after the sutures are tied. (Swanzy.)

the point of each needle has emerged about one quarter inch, it is allowed to remain, and the staphyloma is divided by a horizontal incision. The flaps are now snipped off with the scissors about one twelfth inch in front of the needles, this line (see the dotted line, Fig. 421) being through the sound sclerotic. The needles are next drawn through and the sutures tied, as in Fig. 421 A.

In *conical cornea*, if any operative interference is deemed advisable, the conicity should be reduced by inducing cicatrization at and about the apex of the projection.

Von Graefe's Method.—Just to one side of the apex of the cone remove with the knife a small bit of the surface of the cornea without penetrating the anterior chamber. Every third day for about two weeks this wound should be touched with the mitigated pencil of nitrate of silver. Then puncture through this scar every second or third day for one week, evacuating at each puncture the aqueous humor. The wound is now allowed to heal.

Nebula, *macula*, and *leucoma*, are terms used to designate degrees of corneal opacity—the first being so slight as to be scarcely discernible, the second a more serious lesion, while in leucoma the opacity is complete. The grayish ring seen at the corneal margin in many old persons—*arcus senilis*—is due to fatty degeneration of the cells of the cornea, near the sclerotic junction. This condition occasionally exists in the middle-aged and in young children. While not a contra-indication to operative interference, that it suggests faulty nutrition should not be forgotten in prognosis.

SCLEROTIC.

Simple incised wounds of the sclerotic heal readily. Lacerations are more serious by reason of the greater violence accompanying such injuries. No special treatment is demanded beyond rest and cleanliness.

Scleritis.—Inflammation of the sclera is usually circumscribed, and may or not be accompanied by an appreciable thickening of this tunic. As a rule, the affection is not painful, unless it extends so widely that the choroid, cornea, or iris is involved.

Treatment should be directed to the prevailing dyscrasia. It is met with as a late manifestation of syphilis, and is also a symptom of rheumatism. No local medication is advisable, beyond the limited instillation of atropine to prevent iritis. Rest, and light cloths wet in warm boracic-acid solution locally, are advised. A single thorough application of the actual cautery will frequently abort this disease, which under other methods of treatment usually lasts many months.

IRIS.

Iritis is most frequently seen as a late manifestation of syphilis or in chronic rheumatism. It also may occur with inflammation of the cornea or sclera. The symptoms are abnormal immobility, thickening and cloudiness of the organ, irregularity of the pupillary margin, and adhesions to the anterior surface of the capsule of the lens (posterior synechiæ). The injected zone is usually of a pinkish color. Vision is more or less affected; and pain, though not always a symptom, is usually present. In rare cases the pupil is *occluded* by the formation of a membrane from the products of inflammation.

The *treatment* of iritis is local and general. To prevent permanent adhesions and to relieve pain, the instillation of atropine solution—gr. iv to water ℥j—is imperative. From one to two minims should be dropped in the conjunctival sac every hour, in the first few days of the attack. The degree of synechia is evident as soon as the iris is affected by the atropine, and even when the adhesions between the capsule of the lens and the iris are not completely relieved, firmer and more injurious adhesions will be prevented. Bloodletting at the temples, either by scarification and cups, or dry cupping, hot fomentations, etc., are local remedies of value. Rest to the eyes should be complete, and exposure to draughts or extreme changes in temperature are to be avoided. Any constitutional disease should be treated or any diathesis corrected by internal medication. Saline laxatives are indicated, as in other inflammatory affections.

In extreme cases, when all other remedial agents fail, *iridectomy* may be necessitated. This operation will be described hereafter. The permanent changes to which the iris is subject, after iritis, are adhesions (*synechiæ*), atrophy of the curtain at one or many points as the effusion disappears, and changes in color due to absorption of the normal pigment.

CHOROID AND CILIARY BODY.

Choroiditis is occasionally of traumatic origin. The lines of rupture are seen most frequently near the fundus, and in recent injuries may be concealed by extravasation. *Idiopathic choroiditis* occurs often in the tertiary step of syphilis. A less frequent variety is of tuberculous origin.

The diagnosis rests chiefly upon examinations with the ophthalmoscope. Disease is evident from the abnormal paleness due to atrophy and diminution of the blood-supply. It may be general and symmetrical in the two eyes (*syphilis*), or confined to one or more isolated patches (*tuberculosis*). In the syphilitic variety, changes in the retina are more evident. In very old persons an extensive area of atrophy may occasionally be observed, situated, as a rule, at the fundus.

The indications in treatment are to correct the prevailing dyscrasia, by specific remedies and tonics, and to give the eye as complete rest as possible.

Cyclitis occurs rarely except as in conjunction with inflammation of the sclerotic choroid or iris.

Sympathetic ophthalmitis is a term applied to inflammation in one eye, followed by a like disturbance in and threatened destruction of the other. It is very apt to occur, after *traumatic cyclitis*, from a penetrating body. Dislocation of the lens, iritis, or any inflammatory process, without penetration, and the entrance of air or a foreign substance, may also cause this form of ophthalmitis.

The invasion from one eye to the other is now believed to be by means of septic bacteria traveling along the optic nerve and chiasm. When once declared, the remedy of most avail is enucleation of the diseased eye. It is important that this operation be not too long postponed. The chief difficulty to be surmounted is to determine when it is necessary to operate. The following rules may serve as a guide :

When a penetrating septic body has entered the eye and destroyed vision, it would be wise to enucleate even before iritis and cyclitis are established, and if these symptoms of ophthalmitis are present, operation is imperative. Enucleation is indicated in an eye in which a foreign body is lodged with vision not materially impaired when the earliest symptoms of irido-cyclitis supervene.

Idiopathic inflammation of the interior of the globe, which destroys vision, also indicates enucleation.

Operation.—Seize the conjunctiva with a mouse-tooth forceps over the location of the internal rectus, open the sac here, introduce the strabismus-hook and divide the internal muscle at its insertion into the globe. The conjunctiva is opened in the direction of the other recti muscles until all four are divided. The ball is then carried toward the nose and a dull-pointed scissors curved on the flat is carried (concavity to the globe) backward and the nerve divided close to the ball. The attachments of the oblique muscles are next cut through.

An artificial eye should not be worn until the stump is entirely healed, which requires usually from four to five weeks.

Glaucoma.—This disease is almost always met with after the fortieth year, and is more common in the hypermetropic than in the myopic eye.

The prevailing symptom is an *abnormal distention* of the eyeball.

Glaucoma may be acute, subacute, or chronic. In rare instances, it occurs with great rapidity (*g. fulminans*). More frequently it is slower in its progress. The earliest symptom is dimness of vision. Patients usually complain of indistinctness of sight, as if they were looking through frosted glass. These attacks are at first commonly spasmodic, but the interference with vision soon becomes permanent. Halos or rainbows are seen when an artificial light is looked at. The cornea has a dead and glazed appearance, and the iris is not so movable as normal. If the pulp of the finger is pressed upon the eyeball, it is felt to be hard and abnormally inelastic. Pain is not always present. Inflammation may or may not occur. Blindness sooner or later supervenes, unless prevented by treatment. The causes of glaucoma are, as yet, not satisfactorily explained. It is more generally held that obstruction of the efferent lymph-channels, or of the vessels which carry off the intravascular fluids, is the chief cause of this disease.

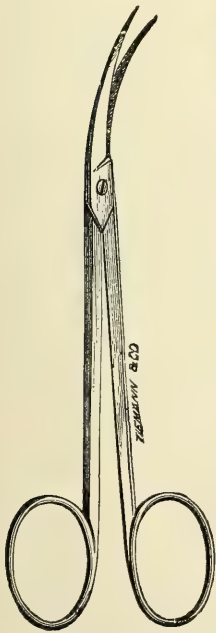


FIG. 422 c.
Curved iris scissors.



FIG. 422.—Jaeger's angular keratome.




FIG. 422 A.—Beers's keratome.

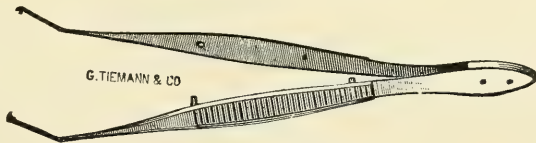


FIG. 422 B.—Iris forceps.

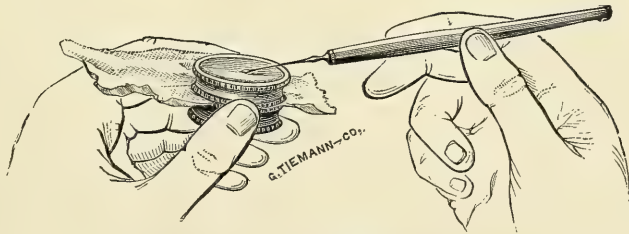


FIG. 422 D.
Drum for trying the edge of eye instruments.

Treatment.—The chief reliance is in *iridectomy*. With the iridectomy knife, enter the anterior chamber by cutting through the sclerotic near the corneal border, exposing the upper margin of the iris for at least one fifth of its circumference. Divide the iris at one end of the incision in a line radiating from its pupillary margin to its ciliary attachment, by traction tear it from the ciliary attachment and divide

with the scissors at the other limit, severing one fifth of the membrane (Fig. 423). No particle of iris should be allowed to be caught and remain in the wound. The after-treatment consists in bandaging the eye, and complete rest.



FIG. 423.—Iridectomy for glaucoma. (De Wecker.)

In mild cases, a smaller section of the iris should be made. The edge may be drawn out with the forceps and a loop of iris clipped off with the scissors.

CRYSTALLINE LENS.

Cataract, or opacity of the lens, although chiefly encountered after the fortieth year of age, may occur at any period of life. It may be divided into—1, *congenital* or *infantile cataract*; 2, *cataract of adult and middle life* (before forty); 3, *senile cataract*.

Cataracts are also classified according to their location in the lens—*nuclear*, or central; *cortical*, or peripheral; and *capsular*.

Nuclear cataract occupies the center of the lens, either permanently, or spreads gradually until the organ is entirely involved. It is at first observed as an opacity or cloudiness immediately behind the pupil, white or amber-brown in color.

Cortical cataract commences near the margin of the lens, behind the iris, and is characterized by grayish-white lines or streaks projected toward the center of the pupil.

In the *capsular* variety the cloudiness or opacity is confined to the anterior shell of the capsule, the substance of the lens not being affected.

Cataracts which are congenital, or only observed in early infancy, are classified as *anterior polar*, or *pyramidal*; *lamellar*, or *zonular*; *central*, *posterior polar*, and *fusiform*. All of these types are comparatively rare.

The *anterior polar* variety is due to the formation of a chalky concretion in the center of the anterior lamellæ of the lens, caused by inflammation and perforating ulcer of the cornea in the early days of life. Operative interference is not called for.

In *lamellar* or *zonular* cataract the opacity is limited to a thin layer of lens-substance, about half way between the nucleus and the anterior and posterior surfaces. The nucleus and peripheral portions are normal. When vision is seriously interfered with by this form of opacity, it may be improved by *iridectomy* or incision through the anterior layer of the capsule (*discission*). In some cases extraction is advisable.

In *central* cataract the deeper fibers of the lens only become opaque. It may be treated in the same way as the zonular opacity. *Posterior polar* cataract is seen deeply behind the center of the lens. Operative treatment is rarely demanded, and when indicated discission is advised.

Fusiform opacity extends from the posterior to the anterior pole. It is very rare.

Cataracts are *primary* when the opacity is developed independent of any other lesion of the eye, and *secondary* when some other lesion exists.

A *traumatic* cataract occurs as a result of rupture of the capsule, with or without perforation, allowing the aqueous humor to invade the crystalline substance. A *Morgagnian* cataract is one in which partial liquefaction of the cortex has taken place, and the nucleus drops to the lowest portion of the capsule. The opacity occurring in *diabetes mellitus* is called *diabetic* cataract.

Cataracts are also termed *senile*, *hard*, and *soft*. Senile cataract occurs, as its name implies, in old persons, usually very late in life, but not unfrequently as young as the fortieth year. This variety, though usually firm or *hard*, is at times soft. Under forty years cataracts are usually *soft*. A cataract is said to be "ripe" when the lens is solidified to such an extent that all of it may be extracted.

Symptoms and Diagnosis.—With senile cataract the earlier symptoms are disturbance of vision. Indistinctness of vision for distant objects is usually first noticed, and, in certain cases, multiple images of one object are observed. If the cataract is *nuclear* or central, vision is improved by shading the eye, thus allowing the pupil to dilate. In *cortical* cataract this is not the case, but by dilatation of the pupil with atropine the presence of the peripheral opacity may be detected. When a cataract is general and ripe, blindness for objects is complete, although light and darkness are appreciable.

Examined in ordinary light a well-marked nuclear cataract may be recognized; but it is by focal illumination and by the ophthalmoscope that a diagnosis is positively made. The pupil should be dilated.

A large nucleus with very fine radiating striæ indicates a hard cataract, while a small nucleus and large striæ suggest a soft opacity. If the cataract be *ripe*, no clear space will be discovered between the nucleus and the iris, and no shadow will be thrown upon the nucleus by the iris. Focal (oblique) illumination—i. e. concentrating by means of a prism the rays of a strong light let fall obliquely upon the cornea—is essential in this examination. By the ophthalmoscope the normal red reflection from the fundus is absent (Swanzy).

As it is important to have a cataract ripe when an operation is undertaken, *Foster* submits the following general guide: Cataracts which are ripe, according to the tests just given, and in which there are *no sectors shining like mother-of-pearl*, are considered ripe for operation. In color they are white, yellow, or gray; also when the lens is wholly occupied with a brownish-yellow nucleus. This may be semi-transparent, and the iris throw a distinct shadow.

Treatment.—When a cataract is not ready for operation, the vision may be improved by glasses, which shade the eyes, allowing the pupil to dilate, and by the instillation of weak atropine solution. These measures apply to opacities at or near the antero-posterior axis of the lens.

Opacities of the lens may be removed by three methods: *Solid extraction*, *absorption after discission*, and *suction*. The first method is applicable to all forms of ripe cataract; the lamellar, central, posterior polar, and fusiform varieties are treated by discission when any operative interference is indicated; soft opacities are removable by suction.

Extraction, except for appearance' sake, is not indicated when only one lens is affected, vision being about perfect in the other, unless the cataract is becoming overripe. It is advisable to remove only one lens at a single operation, even in double ripe cataract.

Operation is not advisable when any serious intra-ocular complication exists, or when insurmountable opacity of the cornea is present. It is always advisable to allay any existing inflammation of the ball or appendages before an operation for cataract. When a cataract is not ripe, its solidification may be hastened by *massage* of the globe—that is, by pressure applied over the ball with the tips of the fingers. The massage should last a few minutes, and be repeated every few days as indicated.

Operation of Extraction.—Two principal methods of extraction are at present employed, viz., (1) *simple extraction* and (2) *extraction after iridectomy*. The former is the ideal operation, and, although at this date not so generally employed, is fast gaining in popularity.

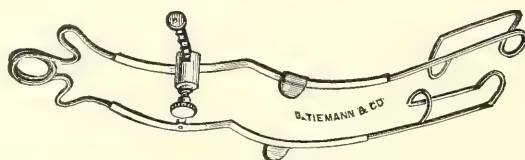


FIG. 424.—Graefe's speculum.

Simple Extraction.—The most careful asepsis is demanded. The eye should be irrigated with warm boracic-acid solution (gr. x-xv to ℥j). The instruments should be thoroughly cleansed by boiling and immersion in alcohol. Anæsthesia is obtained by dropping several minims of 2-per-cent cocaine hydrochlorate into the eye, five minutes, and again three minutes, before the operation. The head should be so held that

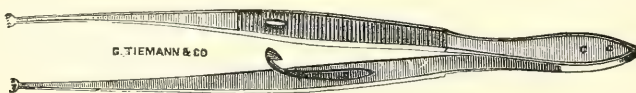


FIG. 424 A.—Graefe's fixation forceps.

the cocaine rests in contact with the upper surface of the cornea through which the incision is made. When ready to operate, the eye and conjunctival sac should be dried with absorbent boracic-acid cotton pellets. The speculum is introduced and secured, and the conjunctiva seized with fixation-forceps just below the center of the lower margin of the cornea. The ball is drawn slightly downward and steadied, while the




FIG. 424 B.—Graefe's linear knife.

knife, cutting edge upward, is entered *through the cornea* just at the corneo-sclerotic junction, carried carefully across in front of the iris, which must not be touched, and out at a point corresponding to that of entrance (Fig. 424 c). By careful to-and-fro movements, the flap

is made by cutting upward through the cornea just anterior to the sclerotic junction. The line between the angles of this flap should cross the cornea a little more than one third the distance from the upper to the lower margin. As this section is being made, and before the aqueous humor escapes, an assistant should slightly lift the speculum, so that no pressure may be made by it upon the ball.

The cystotome is now carried through the wound, kept clear of the iris by the operator, who very cautiously scratches through the anterior capsule, through the whole width of the pupil. Care must be taken not to press so hard against the lens as to dislocate it. As soon as the capsule is opened, gentle pressure in an upward direction should be exercised by means of the spoon against the lower margin of the cornea, or pressure with the finger on the lower lid may suffice to deliver the

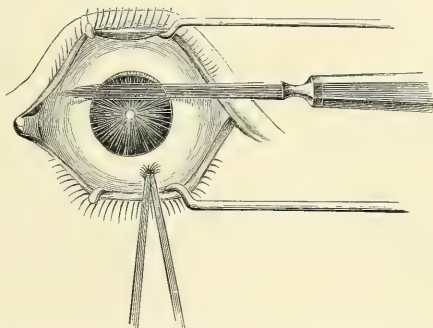


FIG. 424 c.—Introduction of Graefe's knife, showing size of corneal flap in extraction of cataract. (Swanzy.)

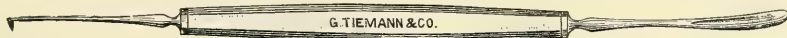


FIG. 424 d.—Cystotome and Daviels's spoon.

lens through the pupil and out through the wound of incision. The pressure should be carefully gauged to effect only the exit of the cataract, and not to rupture the zonula. The wound should now be examined, and no particle of iris, lens, or capsule should be left in the incision. A drop of eserine solution (gr. ij- $\bar{3}$ j) is now instilled into the conjunctival sac in order to contract the pupil. The eye is finally irrigated with the boracic-acid solution and the dressing applied, and both eyes closed by bandaging. The patient is required to remain quiet in a light room for a week. The first change of dressing should be made on the second day, and daily thereafter. Strict asepsis is essential at each change of dressing. The light should be excluded only from the eyes by bandages and shades, and *not* from the room. At the end of a week or ten days a black silk shade may be substituted for the bandages, and in from two to three weeks the patient will need only medium smoke coquilles to protect his eyes from the strong light. He should not be fitted with cataract glasses until all signs of redness and sensitiveness have disappeared.

Extraction with Iridectomy.—The speculum is introduced and secured, and the ball steadied by grasping a fold of the conjunctiva, just below the center of the lower margin of the cornea (Fig. 424 c), with a mouse-tooth fixation-forceps. The ball is drawn slightly downward, and the Von Graefe knife, edge upward, is made to enter the cornea, just at the sclerotic junction, at a point three millimetres (about one eighth of an inch) below the highest margin of the cornea (or about one third of the distance between the upper and lower margins of the cornea). The

point is then made to emerge accurately opposite the entrance, when, by a gentle movement of the knife, the flap is completed by cutting through the cornea, just anterior to its junction with the sclerotic. As this flap is made, a certain proportion of the aqueous humor escapes. The fixation-forceps being, at this stage, transferred to an assistant, the iris-forceps are introduced, and the iris seized at a point corresponding to the center of the incision, and carefully drawn out through the wound. A narrow strip, including the entire depth of the iris, is then excised.

As soon as the iridectomy is completed the operator relieves the assistant of the fixation-forceps, directs that the speculum be lifted, so that no pressure is made on the eyeball, while, with the cystotome carried into the anterior chamber, he freely scratches through the anterior layer of the capsule. Care must be taken not to press so hard against the lens as to dislocate it. It is also important to see that no shred of the capsule is dragged out into the wound in withdrawing this instrument. The globe should now be depressed, either with the forceps or by the patient's volition, and the cataract extracted by gentle pressure with the spoon from the lower margin of the cornea upward. The pressure should be carefully gauged, and the wound examined as above described. Should bleeding occur, this may be checked by a light compress of cold boracic solution. The after-treatment is the same as just given.

If the primary incision should not be large enough to allow the easy escape of the lens, it should be enlarged, preferably with the iris-scissors; it should be free, to begin with. If any fragments of the lens adhere to the capsule or are caught in the wound, they must be worked out by careful manipulation. Should the zonula be ruptured, allowing the vitreous to escape, the lens should be extracted with the scoop. The vitreous should be divided with the scissors at the level of the wound.

Should septic infection occur, suppuration of the wound follows, with usually destruction of the eye. The treatment should be frequent irrigation with boracic-acid solution, and the galvano-cautery wire applied to the margins of the wound. When iritis is precipitated, atropine should be instilled and warm boracic-acid water dressings applied.

Strong convex glasses are necessary after the operation, but the eyes should not be used for reading, etc., for three or four months. Two pairs of glasses should be prescribed—one for reading and another for vision.

Discission.—After dilatation with atropine, ether or chloroform should be administered to prevent any movement which might displace the lens, the speculum introduced, and the field of operation rendered aseptic.




FIG. 425.—Beers's straight needle.

The point of the cataract-needle is made to pass through the cornea near the outer margin, and the point carried to the center of the pupil, where it enters the capsule of the lens (Fig. 425 A). The capsule and the

anterior superficial layers of the lens are torn open by gentle movements of the point of the instrument, which is then withdrawn, being careful not to injure the iris. The pupil should be kept fully dilated, renewing the instillation every few hours, if necessary, for several days. Cold applications and a dark room are the chief indications in the after-treatment. If successful, the lens becomes opaque after a week or more, and gradually disappears by absorption. A second operation may be necessary.

Suction.—Dilate with atropine, administer ether, incise the cornea half-way between its center and margin, perform discission, and introduce the nozzle of the syringe into the lens, when it and the capsule are broken up. The softened lens is sucked into the cylinder by steady and gradual traction on the piston. Strict asepsis is essential. A single introduction of the instrument is advisable. The after-treatment is the same as for discission.

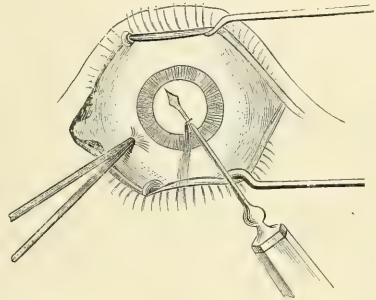


FIG. 425 A.—Introduction of the needle in discission. (Swanzy.)

THE VITREOUS.

Hyalitis, or inflammation of the vitreous, may result from traumatism, with or without the presence of a foreign body, or by the extension of some idiopathic inflammatory process from the choroid, iris, on any portion of the globe. Syphilitic choroiditis is especially apt to produce hyalitis. The immediate symptom is opacity due to extravasation of blood, or the exudation of the products of inflammation. The vitreous breaks down, becoming more fluid than normal (*synchisis*). Flakes or small collections of more solid matter may be seen to change position as the position of the globe is changed. "Spots before the eyes" (*muscæ volitantes*) occur chiefly in myopic subjects, and are due to changes in the vitreous.

The exact condition of the vitreous can usually be made out by careful examination with the ophthalmoscope.

Foreign bodies, when composed of small bits of metal, may be removed by the electro-magnet. Should the wound in the sclerotic be not sufficient, it should be enlarged and the middle of the magnet carried into the vitreous. The metal, if not impacted, adheres to the magnet and is withdrawn. When the foreign body is non-metallic, operative interference is of doubtful propriety unless general inflammation is taking place. Idiopathic hyalitis should be treated by rest to the eye and by special medication.

THE RETINA.

Inflammation of the retina (*retinitis*) may occur independently of lesion of any other portion of the eye, or it may be part of an inflam-

mation of the choroid, ciliary body, iris, vitreous, or by extension from the optic nerve. It is not uncommon in syphilis, and follows thrombosis and embolism of the vessels. It is met with in nephritis and in severe cerebral hyperæmia.

Detachment of the retina from the choroid may be due to extravasation of blood or transudation of serum.

All these conditions may be determined by a careful analysis of the symptoms present and by ophthalmoscopic examination. The indications in treatment are chiefly to correct the general condition of disease on which the retinitis depends. When of traumatic origin, the chief reliance is upon complete rest and warm fomentations. In certain morbid conditions of the external portions of the retina, objects appear unusually small (*micropsia*). The opposite of this condition is known as *megalopsia*.

Night-blindness (*hemeralopia*) is usually only a symptom of *retinitis pigmentosa*, but sometimes occurs in other diseases of the retina and optic nerve.

Day-blindness (*nyctalopia*) is generally due to exposure to strong light, as the glare of the ocean in the tropics, and may occur in persons of faulty nutrition.

Optic Neuritis.—The optic nerve is at times the seat of neuritis which may originate here, or descend from the brain along the nerve; it may be secondary to retinitis, or become involved by contact with morbid changes occurring in the lymph spaces and other tissues contiguous to it. The subjective symptoms are varying degrees of interference with vision. *Amblyopia* (dimness of sight), or *amaurosis* (complete blindness), may be present. These symptoms may be present without perceptible change in the appearance of the retina or optic papilla. When the lesion is beyond the disk, atrophic or other changes of the papilla may be recognized by the ophthalmoscope.

In some instances the obliteration of the retinal image is confined to a portion of the field of vision, usually one half (*hemianopsia*). If one eye only is involved, the lesion is peripheral and limited to the nerve or retina of the affected eye. If binocular, the lesion is in or posterior to the optic chiasm. The inner half of one and the outer half of the other eye are usually obscured.

Color-Blindness.—There is a congenital defect of the retina in which the individual is incapable of recognizing certain colors, as *red*, *green*, and *blue*; a little more than three per cent of males are so affected. Of thirteen hundred and eighty-three men in the employment of the Pennsylvania Railroad Company examined by Dr. William Thomson, fifty-five were absolutely color-blind. It is less common in women. The usual method of testing is that with Professor Holmgren's colored woolen threads. If the patient is wholly color-blind, he will be unable to differentiate between the principal colors. Partial color-blindness may be detected by a careful test with the woolen threads, requiring the suspected person to match to the leading colors those which to him appear of the same or nearly the same shades.

STRABISMUS.

Strabismus, or "squint," may be *convergent* or *divergent*. The former is by far the more frequent variety, and is usually observed in young children. It results from a loss of the normal equilibrium in the muscles of the eye, and when first noticed is often intermittent, appearing in one eye and then the other (*alternating*). As a result of prolonged and repeated efforts at *accommodation* (contraction of the ciliary muscle causing relaxation of the zonula, with consequent increase in the antero-posterior diameter of the lens), the internal rectus becomes permanently shortened.

The degree of convergence may be determined by the strabismometer (Fig. 426).

Let the patient fix his vision on a distant point directly in front of him; place the center of the instrument directly beneath the center of the pupil, and measure the distance from this point to the inner angle of the eye. The same measurement on the affected side will determine the degree of convergence on that side.

Treatment.—Tenotomy is indicated in convergent strabismus for the relief of deformity, as well as for the correction of vision. The prospect of a perfect result is better in recent cases than in those of long standing, in which the external rectus has been overstretched and permanently weakened. In children, about the seventh year is the best period for

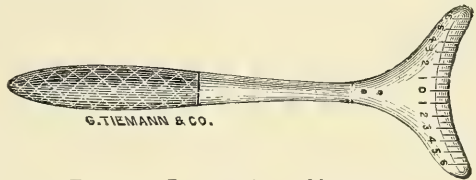


FIG. 426.—Lawrence's strabismometer.



FIG. 426 A.—Graefe's strabismus hook.

operation. Tenotomy of the internal rectus is thus done: The conjunctiva is first anæsthetized with cocaine solution, and two to four minims may be injected into and beneath the conjunctiva, immediately about the insertion of the muscle. The speculum is introduced, and the conjunctiva, just on the inner side of the eye, picked up with the forceps and divided with the scissors. The strabismus-hook (Fig. 426 A) is next carried into this opening and guided beneath and behind the tendon of the rectus internus, which is pulled forward and divided at its insertion into the sclerotic. The hook should be again introduced, to make sure that a thorough division is effected. A pad of cotton dipped in boracic-acid solution, held in

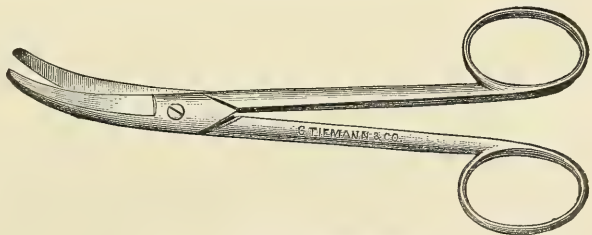


FIG. 426 B.—Strabismus scissors.

place by a dry cotton compress and bandage, should be worn for one or two days. When strabismus makes its appearance in adult life, it is usually due to paralysis, partial or complete, of one or more of the orbital muscles. The lesion producing paralysis may be situated in the brain or in the orbit. Disease of the bones about the foramina of exit of the nerves which supply these muscles, the presence of syphilitic gummata, or any neoplasm, will produce, by pressure on the nerves or muscles, a more or less complete paralysis. Rheumatism is occasionally a cause of strabismus.

In the *treatment* of strabismus due to paralysis, operative interference is not indicated until all other remedial agents have been exhausted in vain. When operation is demanded, not only should division of the contracted muscle be effected as just described, but the weaker muscle may be shortened by *advancing its insertion*.

Take, for example, the external rectus. Perform tenotomy as heretofore described. A small curved needle is threaded with fine silk and

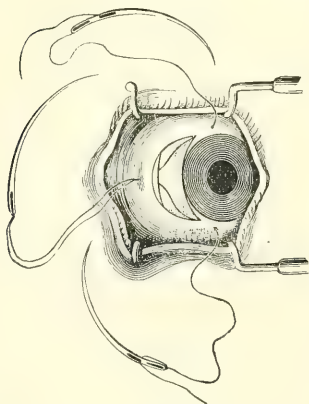


FIG. 426 c.—Advancement of the rectus. (De Wecker.)

carried from the ocular side out through the divided muscle and the conjunctiva. Each end of this double suture is now threaded to a curved needle and passed beneath and through the conjunctiva, coming out near the margin of the cornea and about one eighth of an inch from the vertical meridian of the eye above and below (Fig. 426 c). The needles are cut away, and the two ends of the lower threads tied together, at the same time that an assistant ties the upper ends. These sutures are allowed to remain about forty-eight hours. The amount of shortening in the muscle advanced can be increased by carrying the first needle farther back through the muscle.

In order to get the best possible result, the shortening should be slightly more than appears necessary at the time of operation.

REFRACTION.—THE OPHTHALMOSCOPE.*

By the *refraction* of the eye we mean its power, when in a state of rest, of bringing parallel rays of light to a focus. In normal refraction, or *emmetropia*, the focus for parallel rays is upon the retina (Fig. 427). When the focus for parallel rays is not on the retina, there is said to be an error of refraction. The term *ametropia* includes all the errors of refraction. The principal forms of ametropia are: 1, *myopia*; 2, *hypermetropia*. All the other forms of ametropia are included under the head of *astigmatism*, in which the refraction differs, in degree or kind, in opposite meridians of the same eye.

* The author desires to acknowledge his indebtedness to his friend, Prof. David Webster, M. D., by whom this article on Refraction was written.

The difference in refraction of eyes is due to their difference in shape. While the emmetropic eye is nearly spherical, the myopic eye




FIG. 427.—Showing concentration of rays of light (a, b, c) on the retina (d) in normal refraction. (Swanzy.)

is egg-shaped—too long in its antero-posterior diameter; and the hypermetropic eye turnip-shaped—too short in its antero-posterior diameter. Thus, while the principal focus of the emmetropic eye is upon the retina,



FIG. 427 A.—Showing rays converging to focus (at a) behind the retina (b, c). The hypermetropic eye. (Swanzy.)

that of the hypermetropic eye is behind the retina (Fig. 427 A), and that of the myopic eye in front of it (Fig. 427 B).




FIG. 427 B.—Showing concentration at (f) of rays of light (a, b) in front of retina (c, d) in myopia. (Swanzy.)

Astigmatism is usually due to asymmetry, or irregularity of surface, of the cornea, probably sometimes to a like condition of the lens. The varieties of astigmatism are six in number: 1, *simple myopic*; 2, *compound myopic*; 3, *simple hypermetropic*; 4, *compound hypermetropic*; 5, *mixed*; and, 6, *irregular astigmatism*.

In simple myopic and simple hypermetropic astigmatism, the principal focus of one meridian of the cornea is upon the retina, while the principal focus of the opposite meridian is anterior to the retina or behind it, accordingly as the astigmatism is myopic or hypermetropic.

In compound myopic astigmatism all the meridians of the eye are

myopic, but one of them more so than any of the others, and the meridian at right angles to it less so than any of the others.

In compound hypermetropic astigmatism all the meridians of the eye are hypermetropic ; but one of them more so than any of the others, and the meridian at right angles to it less so than any of the others. In mixed astigmatism one meridian of the eye is myopic, while the opposite meridian is hypermetropic. In irregular astigmatism different parts of the same meridian possess different degrees of refraction. Hence this form of astigmatism is the only error of refraction, which can not be corrected by glasses. It is, in every sense of the word, irremediable.

It is obvious that persons with emmetropic eyes, and with unimpaired accommodation and well-balanced ocular muscles, do not need spectacles. Persons with any of the different forms of ametropia are liable to become the subjects of asthenopia from eye-strain. Such persons complain of inability to use their eyes, pain in their eyes and temples, headache, nausea, and various nervous disorders.

Hypermetropia is congenital, as a rule, and is said to be due to an arrest of development of the globe in its antero-posterior axis. It is sometimes the result of changes in the refractive media, as in the hardening of the crystalline lens that occurs in old age, or the removal of the lens by operations for cataract.

Parallel rays of light passing through the hypermetropic pupil do not meet on the retina, but converge toward a point behind it. Objects are, therefore, seen under circles of diffusion ; and such eyes, in order to see distinctly, contract their ciliary muscles sufficiently to so increase the convexity of the crystalline lens that the focus will be brought forward upon the retina. This act is involuntary, and produces more or less strain upon the eyes. For such persons the *strongest convex* spherical glasses should be selected with which they can distinctly see objects distant twenty feet or more. If the asthenopic symptoms only accompany or follow the use of the eyes for reading and other near work, it may be sufficient to wear the glasses only for the near. But when the asthenopic symptoms are constant, and are only aggravated by near work, the glasses should be worn constantly.

In selecting glasses for the relief of asthenopia, no matter what the error of refraction, it is always well to examine the eyes with the pupil dilated. While sulphate of atropia is the most reliable mydriatic, if used in solution sufficiently strong to paralyze the accommodation, it incapacitates the eyes for near vision for at least ten days.

When the object is to ascertain the true refraction with as little inconvenience to the patient as possible, it is sufficient for all practical purposes to drop into the eyes a few minims of a 3-per-cent solution of homatropine hydrobromate at intervals of fifteen minutes, until seven or eight instillations have been made, and to test the refraction ten or fifteen minutes after the last instillation. If the homatropine produces redness of the eyes, as is often the case, this may be relieved by a single instillation of a 4-per-cent solution of cocaine hydrochlorate, which, at the same time, increases the effect of the homatropine in paralyzing the

ciliary muscle. The effect of these mydriatics passes off inside of twenty-four hours. In cases where it is desirable that the patient should have the benefit of a prolonged rest of his accommodation, regardless of inconvenience, it is better to use the sulphate of atropia (a 1-per-cent solution).

In some cases of asthenopia from hypermetropia, glasses correcting the total error of refraction are worn with comfort from the start. In the majority of cases, however, when the accommodation reasserts itself, such glasses make the eyes practically myopic, and the indistinctness of vision thus produced so annoys the patient that he rejects them. It is safer, therefore, to wait until the hypermetrope has recovered from the effects of the mydriatic, and then to order the strongest convex glasses that he can wear with comfort. When his eyes have become accustomed to these, they should be exchanged for stronger ones, and these changes should be repeated at intervals of two or three months until the total hypermetropia is corrected. After that it is probable that the patient will need no further change of glasses, and that the relief of his asthenopia will be permanent.

Myopia may be apparent or real. Apparent myopia is due to spasm of the ciliary muscle, and may be diagnosticated from true myopia by ascertaining the true refraction under the effects of atropine. Spasm of the ciliary muscle is usually the result of over-use of the eyes. Such patients should be kept under atropine for several weeks, wearing medium smoked coquille glasses to protect the retina from excessive light. When the spasm of the ciliary muscle fails to reassert itself after the use of the mydriatic is stopped, convex glasses, correcting the hypermetropia, which almost always exists in such cases, should be substituted for the coquilles, and the patient should be cautioned not to resume the excessive near use of his eyes. True myopia is the result of the lengthening of the antero-posterior diameter of the eyeball, and is rarely congenital. There often exists a hereditary tendency to myopia; and it is a matter of common observation, that where the father or mother is myopic the children are apt to develop the same condition during school-life. Myopia is frequently developed in children; however, where there is no traceable hereditary tendency. It almost invariably first shows itself during early school-life, and the first intimation of it is that the child fails to see the letters and figures on the blackboard across the school-room. It is encouraged by the use of the eyes by insufficient light in a vitiated atmosphere, and in a stooping position, during the period when the eyes are undergoing rapid development along with the other organs of the body. It is of the greatest importance that it should be arrested as soon as possible; for highly myopic eyes are nearly always diseased eyes, and are in great danger of developing staphyloma posticum, retinal and choroidal changes, floating bodies in the vitreous, and detachment of the retina. Myopic patients should be fitted with glasses at as early a period as possible, the weakest concave glasses being selected for them, with which they can see distant objects distinctly. They should wear such glasses constantly; by so doing, arrest of de-

velopment of the ciliary muscle will be avoided, as will also excessive strain upon the interni. Attention to their general health should not be neglected, and the amount of use of their eyes for near work should be limited. Their eyes should be tested at least once in six months, and a careful record kept of the results of such testings, for it is only in this way that we can tell whether the myopia is stationary or progressive, and, if the latter, whether rapidly so or not. If the myopia is increasing rapidly, near work should be entirely stopped, and the patient should be put upon atropine and colored glasses, and turned out into the open air. Myopia usually ceases to be progressive somewhere between the ages of twenty and thirty. Aside from all consideration of the health of the eyes, myopes should wear the correcting glasses for educational reasons.




FIG. 428.—Nachet's trial-set.

Astigmatism, especially when only slight and correctable by an unequal contraction of the ciliary muscle, is a prolific source of asthenopia. When it exists in the higher degrees, the patient makes no attempt to correct it; sees indistinctly at all distances, and is comparatively free from asthenopic symptoms. The slighter degrees, then, should be corrected with glasses for the relief of asthenopia; the higher degrees for the purpose of procuring distinct vision. Of course, in fitting patients with glasses for the correction of astigmatism, convex and concave cylindrical lenses are necessary. For simple hypermetropic astigmatism that convex cylindrical glass should be selected which brings the focus of

the hypermetropic meridian forward upon the retina, and thus makes distinct vision possible without an effort of accommodation. For simple myopic astigmatism the concave cylindrical glass should be selected which throws the focus of the myopic meridian back upon the retina, and thus renders the eye practically emmetropic. For compound hypermetropic astigmatism a convex spherical with a convex cylindrical glass is necessary; while in compound myopic astigmatism the error of refraction is corrected by the combination of a concave spherical and a concave cylindrical glass. Mixed astigmatism is corrected by a convex cylindrical and a concave cylindrical combined, and with their axes at right angles to one another.

In prescribing glasses for astigmatism the greatest care should be taken to adjust the axes properly. The cylindrical trial-glasses should always be placed before the eyes in trial-frames made for the purpose, and the direction of the axes read in degrees from the frames. Ophthalmologists use Snellen's test-types in examining for errors of refraction, and the cases of trial-glasses made by Nacet (Fig. 428) are as good as any.

TESTING FOR GLASSES.

For determining errors of refraction and fitting patients with spectacles, the surgeon should provide himself with Snellen's and Jaeger's test-types and with a case of trial-glasses, including spherical and cylindrical glasses, convex and concave, trial-frames with the degrees of a semicircle marked upon them, etc. The patient should be placed at a distance of twenty feet from Snellen's test-type, with the light shining upon the test-type and not upon the face of the patient. Each eye should be tested separately, the other being kept open and covered with a screen.

Snellen's test-type is so constructed that the letters in each line subtend an angle of five minutes at the distance marked in feet above the line. The line marked 100 should therefore be read at one hundred feet; that marked 20, at twenty feet, etc. Vision is recorded *fractionally*, the distance from the test-type being set down as the *numerator*, while the number of the line read is set down as the *denominator*. Thus, if a person with his right eye reads Snellen No. 70 at twenty feet, the vision would be recorded thus: R. V. = $\frac{20}{70}$. If with his left eye he reads Snellen No. 20 at twenty feet, it is recorded L. V. = $\frac{20}{20}$. The vision of the right eye would be two sevenths of the normal, while that of the left eye would be one, or normal. If a patient reads $\frac{20}{20}$ with each eye, we know that his vision is perfect in both eyes, but still he may be *hypermetropic*, and straining his accommodation in order to see distinctly. We should always test such a patient with convex spherical glasses. If the weakest glass blurs his vision, he has no manifest hypermetropia. The vision and refraction of such a patient should be recorded thus:

R. V. = $\frac{20}{20}$; E. L. V. = $\frac{20}{20}$; E. (emmetropic).

If the patient can read Snellen No. 20 at twenty feet through a convex spherical glass, the *strongest* one through which he can read it represents his manifest hypermetropia. Thus—

R. V. = $\frac{2}{0}$; Hm. 1.75 D. L. V. = $\frac{2}{0}$; Hm. 1.50 D.

would mean that the patient had perfect vision without a glass, or with any convex spherical glass from the weakest up to + 1.75 D., right eye, and + 1.50 D., left eye; but that stronger glasses than those indicated would blur his vision. Those glasses should, therefore, be prescribed. If the patient sees less than $\frac{2}{0}$, we may suspect myopia or astigmatism. For instance, the formula—

R. V. = $\frac{2}{0}$; $\frac{2}{0}$ with - 4 D. L. V. = $\frac{2}{0}$; $\frac{2}{0}$ with - 3 D.

means that, without glasses, the patient sees $\frac{2}{0}$ with his right eye, and $\frac{2}{0}$ with his left eye, and that - 4 dioptries is the *weakest* concave glass with which he can read $\frac{2}{0}$ with his right eye, and - 3 dioptries the weakest with which he can read $\frac{2}{0}$ with his left eye.*

Again, the patient may be astigmatic. Suppose we find—

† R. V. = $\frac{2}{0}$; $\frac{2}{0}$ with + 1.25 D. c. ax. 90°.

L. V. = $\frac{2}{0}$; $\frac{2}{0}$ with + 1 D. s. \ominus + 1.50 D. c. ax. 90°.

We have here simple hypermetropic astigmatism in the right eye, and compound hypermetropic astigmatism in the left. In the right eye, the vision is brought up to $\frac{2}{0}$ by a convex cylindrical, one and a quarter dioptries, axis 90°; while in the left the combination of a convex spherical and a convex cylindrical is required.

In another case—

R. V. = $\frac{1.7}{0}$; $\frac{2}{0}$ with - 3.25 D. c. ax. 180°.

L. V. = $\frac{3}{0}$; $\frac{2}{0}$ with - 3.75 D. s. \ominus - 2 D. c. ax. 180°.

Here we have simple myopic astigmatism in the right, and compound myopic astigmatism in the left. In mixed astigmatism the refraction may be corrected and the vision brought up to the normal by either of three different combinations of lenses. Thus—

R. V. = $\frac{2}{0}$; $\frac{2}{0}$ with + 1 D. c. ax. 90° \ominus - 1 D. c. ax. 180°.

L. V. = $\frac{2}{0}$; $\frac{2}{0}$ with + 2 D. c. ax. 90° \ominus - 2 D. c. ax. 180°.

The equivalent glasses would be—

R. + 1 D. s. \ominus - 2 D. c. ax. 180°.

L. + 2 D. s. \ominus - 4 D. c. ax. 180°. Or,

R. - 1 D. s. \ominus + 2 D. c. ax. 90°.

L. - 2 D. s. \ominus + 4 D. c. ax. 90°.

In fitting patients with cylindric glasses the direction of the axes is read from the degrees marked on the trial-frames toward which the axes point in giving the best vision.

Presbyopia, or old sight, is an impairment of the accommodation due to the gradual hardening of the crystalline lens, the result of age. Persons who are emmetropic, or slightly hypermetropic, usually need glasses for near purposes when from forty to forty-five years of age. The higher degrees of hypermetropia necessitate the use of glasses for reading much earlier. In the lower degrees of myopia the use of glasses

* In the dioptric scale of numbering spectacle-lenses the unit is a weak lens of 100 centimetres focal length, or D. (one dioptré). A lens with focal length of 50 cm. = (2 D.), etc.

† This reads: Right vision equal $\frac{2}{0}$; $\frac{2}{0}$ with convex 1.25 Dioptries, cylindric, axis 90°. Left vision equal $\frac{2}{0}$; $\frac{2}{0}$ with (+) convex 1 D. spherical, (\ominus) combined with convex 1.50 D. cylindric, axis 90°.

for reading may be deferred considerably longer, while in the higher degrees they may never be needed at all. Presbyopes, no matter what their refraction, should be suited with the glasses, generally convex, with which we find experimentally they can read most comfortably. Generally the weaker convex glasses are selected in the early stages of presbyopia, and these are exchanged for stronger ones as the patient advances in life.

Heterophoria.—Insufficiency of the extrinsic ocular muscles—latent or dynamic squint.

When the extrinsic ocular muscles are not well balanced, as when the interni are relatively stronger than the externi, or one of the inferior recti weaker than its fellow of the opposite side, there is a tendency of one eye to deviate in the direction of the relatively stronger muscle. If the eye should actually deviate, *diplopia* (double vision) would result, and would be productive of great annoyance. Therefore, single, binocular vision is always maintained as long as possible, and in order to its maintenance, an extra innervation has to be supplied to the weaker muscle. This constant strain causes asthenopia, headache, nervousness, etc. In some cases the strain can be removed by the use of prisms worn with their bases toward the weaker muscles, alone, or combined with the lenses which correct any existing error of refraction. But in many cases it becomes necessary to restore equilibrium of the muscles by a tenotomy of the stronger or a tendon resection of the weaker muscle.

The different kinds of correctable heterophoria (tendency to deviation of the visual lines) are: 1. Hyperphoria (a tendency upward of one eye). 2. Exophoria (a tendency outward). 3. Esophoria (a tendency inward).

In order to ascertain with accuracy the kind and amount of heterophoria, the surgeon should provide himself with a phorometer (an instrument of precision invented by Dr. George T. Stevens, of New York), and a set of square prisms, of one degree and upward.

The patient is seated facing a lighted candle, which is situated on a level with his eyes, and twenty feet, or more, distant. The horizontal bar of the phorometer is placed in front of his eyes and a few inches away from them. In a slot in this horizontal bar is placed a frame containing two prisms of 4° to 8° each, bases toward the nose, and on looking at the candle through these prisms, the images are thrown to the nasal side of the macula, and the patient has homonymous diplopia. If both inferior recti are of equal strength, and likewise both superior recti, neither eye will deviate upward, and the two candles will appear in a horizontal line, or on a level. But if one eye deviates upward, the image will be thrown upon the supero-nasal quadrant of the retina of that eye, and will be seen on a lower level than that seen with the other eye. The prism placed before the eye that sees the lower candle, base down, which brings the candles on a level, measures the amount of hyperphoria.

Having tested for hyperphoria, the horizontal prisms should be removed and replaced by a prism base down in front of one eye. This will produce vertical diplopia by throwing the image of the candle-flame

on the retina below the macula, so that it will be projected above. If the two flames are seen in a vertical line, there is no insufficiency of the interni or externi. But if the images are homonymous, there is insufficiency of the externi; and the prism, base out, that makes them vertical, measures the esophoria.

If the images are crossed, there is insufficiency of the interni; and the prism, base in, that makes them vertical, measures the exophoria. In making these tests, the horizontal bar of the phorometer must be carefully adjusted by means of the attached screw or ratchet and spirit-level.

In order to arrive at a more positive idea as to the relative strength of the ocular muscles, it is necessary to measure (1) the abduction, (2) the adduction, and (3) the sursumduction.

The abduction is measured by the strongest prism that can be overcome by the externi—that is, the strongest prism, base in, through which the patient can see singly at twenty feet or more. In like manner, the strongest prisms, base out, through which the patient has binocular single vision, measure the adduction; and the strongest prism, base down, over one eye, through which the patient sees singly, measures the sursumduction.

In hyperphoria of 1° or more, the superior rectus of the hyperphoric eye may be divided; in esophoria of 2° or more, the internus may be cut; and in exophoria of 2° or more, the externus may be snipped. But if the surgeon would avoid an over-correction, thus leaving the eyes in a worse condition than before, he must follow the method advocated by Stevens:

1. Make a small opening in the conjunctiva over the tendon to be cut.
2. Seize the center of the tendon with delicate but strong forceps, made for the purpose, and button-hole it with delicate probe-pointed scissors.

3. Introduce one blade of the same scissors between the tendon and the sclera and the other blade between the tendon and the conjunctiva, and cut transversely to one border of the tendon, and then, reversing the scissors, cut transversely to the other border of the tendon.

4. The eyes should now be tested with prisms, and if the heterophoria is not nearly corrected, the scissors may be again introduced and the loosening up of the insertion be carried a little further. Thus by cutting cautiously, a little at a time, and then testing with candle and prisms to ascertain how much effect has been obtained, it is not difficult for the dexterous operator to correct the deviation with considerable accuracy. No surgeon should undertake these operations with the ordinary clumsy instruments in vogue. The necessary instruments particularly adapted to the purpose, and to tendon-resection, are made by Messrs. Tiemann & Co., of New York. Tendon-resection is practiced in cases where the heterophoria is too great to be corrected by a graduated tenotomy of the stronger muscle without limiting the excursion of the eye in that direction. In such cases it is better to partly correct the deviation by tenotomy and to correct what remains by tendon-resection of the weaker mus-

cle. In performing this operation, by Stevens's method, the tendon is divided as in graduated tenotomy. A delicate hook is then slipped beneath and caught into the under surface of the divided tendon which is now drawn out of the conjunctival aperture and caught some lines from its extremity with delicate fixation forceps. A small, very sharp, curved needle, armed with a fine silk thread, is now passed through the muscle from without inward, as far back as the operator thinks necessary, and then the portion of the muscle anterior to the needle is excised with scissors. The needle is then carried through the stump of the insertion of the muscle, including the capsule of Tenon and overlying conjunctiva, and the thread drawn through and loosely tied.

The patient should now be placed in the position for testing with prisms, and the knot drawn just tight enough to correct, or slightly over-correct, the deviation. In both these operations the lids may be held open by a speculum, an elevator, or the fingers of an assistant. The stitch may be removed at the end of three or four days. No after-treatment is required, as there is rarely any inflammatory reaction.

OPHTHALMOSCOPY.

The general practitioner should familiarize himself with the use of the ophthalmoscope sufficiently to be able to diagnosticate gross lesions of the globe situated posterior to the crystalline lens. He should provide himself with an ophthalmoscope with tilting mirror and convex and concave lenses ranging from one to twenty dioptries. With this it would not be amiss for him to examine the eyes of all his patients, so far as his time would allow. He should dilate the pupils with a solution of homatropine or cocaine, two per cent in either case, in order to facilitate the examination. The patient should be seated in a darkened room, with a German student's lamp placed on a level with the eye to be examined, a little behind and to one side, so that the light will fall on the temple or nose but not on the eye. The observer then rests the ophthalmoscope against the inner angle of his orbit and throws the light into the eye with the mirror, at the same time looking into the pupil through the aperture in the mirror. He thus gazes at the papillary area while the patient looks up, down, right, and left. If the reflex from the pupil is, in all positions of the eye, of a uniform clear pinkish or reddish color, it is to be inferred that there are no gross lesions of the refractive media. If the red reflex from the fundus is interrupted by dark spots, there are opaci-




FIG. 429.
Loring's Student's Ophthalmoscope.

ties of the media, and the surgeon must proceed to locate them. If they move while the eye is fixed, they are floating bodies in the vitreous. If they move with the eye and stop when the eye stops, they are opacities either of the cornea or of the crystalline lens. If of the cornea, they will be seen by oblique illumination. This is also true of opacities situated on the anterior capsule and in the front portions of the crystalline lens. If in the posterior portions of the lens, they will appear to move in an opposite direction to the eye. Opacities in the periphery of the lens are seen only when the eye is so turned that the observer looks through the pupil very obliquely. For more minute examination of any opacity already discovered, the observer should turn on over the aperture of his ophthalmoscope a + 10. D., and approach the eye to within its focal distance, about four inches. In this way he will obtain a greatly magnified view. In high degrees of myopia and hypermetropia pigment patches in the fundus may be mistaken by the novice for opacities of the media. These are excluded by seeing them in their true position while examining the fundus.

There are two methods of examining the fundus: 1, The indirect; 2, the direct.

In examining the eye by the indirect method, the observer interposes a two-inch or two-and-a-half-inch lens, between his ophthalmoscope and the patient's eye, at about its focal distance from the eye, his own eye being twelve to fifteen inches away. In this manner he gets an inverted image of the fundus, magnified some three or four diameters. By directing the patient to look successively in different directions, he thus easily scans the whole fundus.

In using the direct method, the observer approaches his eye with the ophthalmoscope as close as possible to the eye he is examining, often touching the brow or nose of the patient with his instrument. In this way he sees only a small portion of the fundus at a time, but that is in its true position and is magnified some seventeen diameters, more or less. The examined eye being myopic, he must turn on the *weakest* concave lens with which he can see the fundus distinctly; and this, while it enables him to see the fundus clearly, at the same time measures the amount of myopia. If the patient is hypermetropic in a moderate degree, the fundus will be well seen without any lens; but if the observer would estimate the amount of hypermetropia, he must turn on the strongest convex lens through which he can see the fundus distinctly. In astigmatism only one meridian of the fundus is seen distinctly at a time, the opposite meridian being seen through a stronger or weaker lens. If the observer has an error of refraction, he must take it into account in estimating refraction with the ophthalmoscope. Some of the grosser lesions to be looked for by the surgeon are:

1. *Optic Neuritis*.—Here the ophthalmoscopic appearances vary. In the milder cases only the nasal, or upper, or lower, border of the disk is obscured by swelling, while in the severer cases the whole papilla is greatly swollen and its outline entirely obliterated. The retinal vessels are tortuous, while the veins are enlarged and the arteries are either of

normal size or diminished. There may or not be ecchymoses upon the disk or in the retina. Rarely the central vision and visual field are perfect. In most cases, however, both are impaired, and often vision is reduced to perception of light. In optic neuritis or "choked disk" of both eyes intracranial tumors should always be suspected. Optic neuritis may, however, depend on a variety of causes, such as kidney disease, lead-poisoning, meningitis, syphilis, etc.

2. *Atrophy of the Optic Nerve* is recognized by the paleness of the optic disk and the smallness of the retinal blood-vessels. It may be consecutive to optic neuritis, or it may be ushered in as "primary" atrophy. Therefore the conditions which produce optic neuritis should be sought in cases of atrophy. It frequently occurs in poisoning by tobacco and alcohol, and is often a symptom of progressive locomotor ataxia. It is found in advanced stages of retinitis pigmentosa.

3. *Retinitis* is distinguished by bright or whitish patches in the retina. When these arrange themselves about the macula lutea in a stellate form, the cause is generally found to be kidney disease. They are often accompanied by retinal hæmorrhages. Diabetes and syphilis are among the other causes of retinitis.

4. *Choroiditis* is known by white patches in the fundus, generally bordered irregularly with black pigment, and with the retinal vessels passing over them. The cause is often obscured. It is sometimes due to syphilis.

5. *Glaucoma simplex* is always characterized by excavation, or cupping of the optic disk. The retinal vessels appear to end abruptly at the discal border. The bottom of the excavation can be seen through a sufficiently strong concave lens. Around the disk is a ring of choroidal atrophy exposing the white sclera. There is often pulsation of the retinal arteries. Central vision is usually impaired, and the visual field limited, especially on the nasal side.

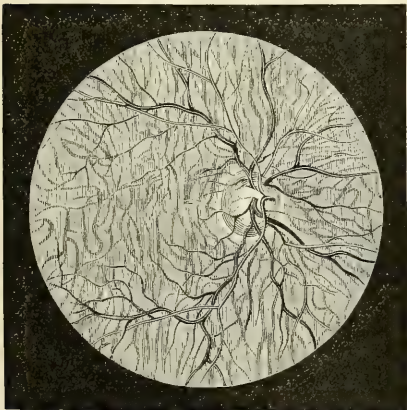


FIG. 429 A.—Ophthalmoscopic appearance of healthy fundus in a person of very fair complexion. Scleral ring well marked. Left eye, inverted image. (Wecker and Jaeger.)

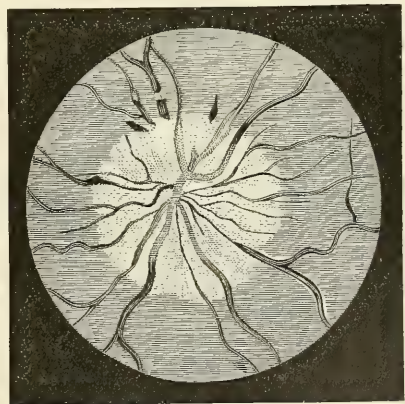


FIG. 429 B.—Ophthalmoscopic appearance of severe recent papillitis. Several elongated patches of blood near border of the central inflammatory area. (After Hughlings Jackson and Nettleship.)

SURGERY OF THE EAR.

Neoplasms of the auricle require extirpation as in other portions of the body. *Angeiomata* of small size may be cured, without excision, by injecting the tumor with a few minims of 50-per-cent carbolic-acid solution. *Cartilaginous* growths are occasionally met with about the ear. Their usual location is just in front of the tragus. I removed two in front of one ear and one from the opposite side in a patient twenty-two years of age. Similar tumors were present in the person of his father and another member of the family.

Wounds of the auricle should be treated with the view of preventing any distortion of this organ.

Lacerations of the lobule from the violent removal of an ear-ring may be corrected by paring the edges and uniting them by fine silk sutures. The hypodermic use of cocaine will secure perfect anæsthesia in all ordinary operations upon the auricle.

Drooping of the ears to a degree amounting to deformity should be treated in children by strapping the auricles close to the skull, by means of an elastic band around the forehead and occiput.

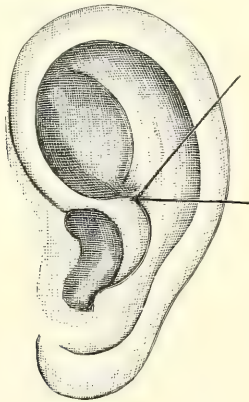


FIG. 430.—(After Reeves.)

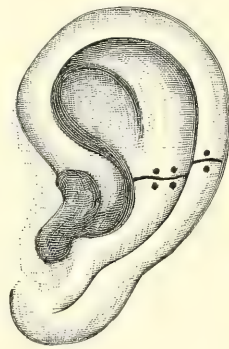


FIG. 431.—(After Reeves.)

Adhesions of the auricles to the scalp should be dissected loose, the organs crowded forward, and, if necessary, skin should be transplanted to fill in the gap and prevent a recurrence of the deformity. Hypertrophy of the auricle should be corrected by excision of a triangular piece, after the method of Martino, shown in Figs. 430 and 431.



FIG. 432.—Sexton's hard-rubber double probe.

Auditory Canal.—Foreign bodies in the auditory canal may be recognized by inspection or with the light gutta-percha probe (Fig. 432), and should be removed by the careful employment of the angular forceps

(Fig. 433), or, if firmly impacted, the ring curette (Fig. 434) may be required. For locating and seizing the body the head-mirror should be employed to concentrate the light in the canal. The solid-silver specu-

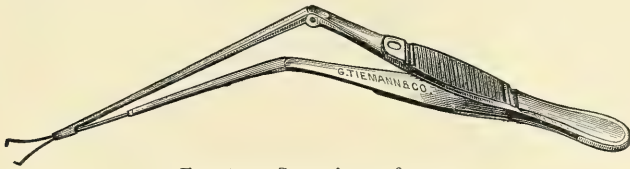


FIG. 433.—Sexton's ear-forceps.

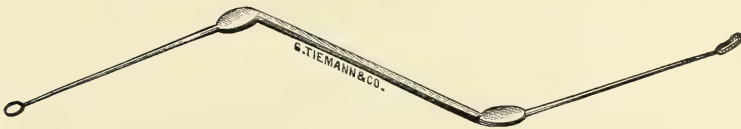

FIG. 434.—Sexton's double ear-hook, to extract foreign bodies.

lum of Wilde, always required in examinations of the deeper portions of the canal and of the membrana tympani, may also be of assistance in locating the foreign body, although this can usually be done, if the light is properly directed, by pulling upon the auricle so as to straighten the canal.

Impactions of cerumen should be removed by irrigation with warm water. The stream should be delicate, and should be directed to one side of the obstruction in order to melt away a portion sufficient to allow the force of the injection to operate upon the mass from behind. The curette or scoop may also be advantageously employed in removing impactions of cerumen.

Furuncles of the auditory canal are quite frequently met with. Their presence is marked by acute pain, located in a circumscribed area, and by redness and swelling.

The treatment consists in alleviating pain by the use of anodynes if necessary, and by softening the skin over the inflammatory process by the use of emollients. Cotton lubricated with vaseline should be introduced. As soon as the formation of pus is evident, it should be evacuated by puncture or incision.

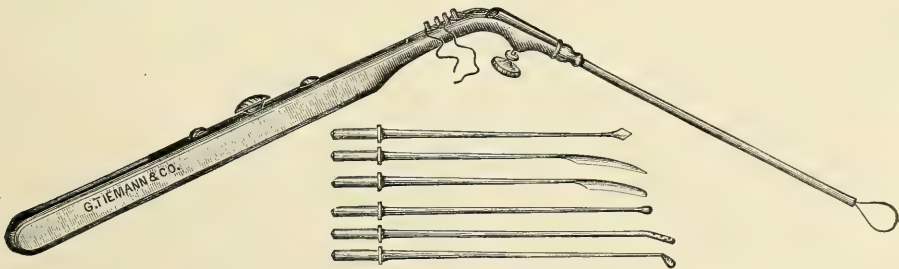


FIG. 435.—Sexton's snare.

Neoplasms of the auditory canal demand removal by the snare (Fig. 435), forceps, or by excision. Polypus of this tube may be single or

multiple, and, when of sufficient size to fill the canal and become constricted, may break down and cause a fœtid discharge.

Occasionally the auditory canal is occupied by a parasite known as *aspergillus*, the spores of which are developed with great rapidity, filling up the canal and causing inflammation, obstruction, and more or less interference with hearing. Finely powdered boracic acid should be blown deeply into the canal at repeated intervals until the fungus is destroyed.

Middle Ear—Membrana Tympani.—The drum of the ear may become involved by extension of an inflammation from the auditory canal, or it may be secondary to an *otitis media*, or it may in rare instances be inflamed without either of the foregoing complications.

Inflammation of the middle ear is in most cases preceded by pharyngitis, and is thus affected by invasion through the Eustachian tube. It may be produced by traumatism, or the initial lesion may be situated within the cavity of the tympanum, or in the mastoid cells, which communicate with the cavity. Otitis media is not uncommon in children as a sequel of *scarlatina* or *rubeola*.

The earliest symptom of this affection is pain of a severe character, accompanied by partial arrest of hearing. Fever is present, and may be preceded by a chill or rigors. When suppuration occurs, and the mastoid cells are involved, the pain is intensified and the febrile movement at times very high. In a case of this character which I saw, and in which the operation of puncture and trephining the mastoid process had been delayed, fatal pyæmia occurred. In specimens of blood taken from this patient just before death, the red blood-disks were seen to be filled with bacteria. Percussion with the finger-tip over the mastoid region exaggerates the sense of pain. Upon examination with the otoscope and head-light, the drum of the ear will be seen to be more opaque than normal, its vascularity increased and bulging toward the meatus if there is pus in the middle ear.

The *treatment* of *otitis media* should be directed to the arrest of the inflammatory process by warm fomentations, by the application of leeches to the temples and mastoid region. Quinia, iron, stimulants, and well-selected diet are indicated in the effort to improve the general condition of the patient. It is of great moment that the tension of the tympanum and of the mastoid cells should be relieved early in the progress of the disease, and, even when there is a doubt as to the presence of pus, explorative puncture of the *membrana tympani* should be

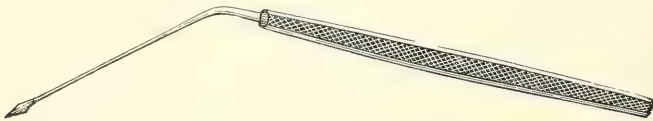


FIG. 436.—Poltzer's tympanum-perforator, angular.

made. The operation is without danger, is not difficult of accomplishment, and, even when suppuration has not occurred, will often give great and immediate relief. A proper instrument for this procedure is

shown in Fig. 436. The silver speculum and reflected light should be employed so as to bring the membrane into plain view, and, while the head of the patient is held motionless, the point of the perforator is carried against the drum on its posterior inferior quadrant, and barely pushed through. The puncture should not be more than one eighth of an inch in length. If there shall have been an effusion of serum, or if pus is present upon the withdrawal of the instrument, a small quantity of fluid will escape through the puncture. If necessary to the establishment of free drainage, the opening may be enlarged.

When *otitis media* is complicated with inflammation and suppuration of the mastoid cells, and when the communication with the tympanum is not sufficient to give ready discharge to the products of inflammation into the middle ear, and thence out through the puncture in the *membrana tympani*, the cells should be opened and drainage secured at once by removing the outer shell of the mastoid process. In children this procedure is not always necessary on account of the very thin shell of bone which incloses the cavity of the mastoid antrum, and which readily gives way and allows egress to the pus formed within. In drilling or trephining the mastoid cells, proceed as follows :

The skin over and near the mastoid process should be shaved and cleansed, and a free incision made in a vertical direction, the center of the cut being opposite the center of the auditory meatus and one fourth of an inch from the posterior wall of the bony canal. If any difficulty is experienced in lifting and reflecting the integument, a short transverse cut should be made backward from the middle of the perpendicular incision. The periosteum should be scratched off at the point where the bone is to be perforated, unless necrosis has already occurred and only a thin shell of bone remains. In this condition the shell should be lifted off and the cells cleaned out. When the bone has a healthy appearance on the exterior it should be cut through with a trephine, gouge, chisel, or drill. The trephine employed should not be more than a quarter of an inch in diameter, and the center of the hole made (no matter what instrument is employed) should not be farther than a quarter of an inch posterior to the wall of the auditory canal on account of the proximity of the lateral sinus and the veins of the diploë which empty into it. After the instrument has traveled about an eighth of an inch into the bone it should be removed and the circular track inspected. The entrance to the cells will be indicated by a slight hæmorrhage, and, if abscess is present, by a few drops of pus. As soon as the bleeding is seen the button of bone should be lifted by the elevator and the remaining cancellous tissue scooped out with the iron spoon or the scalloped gouge. The abscess should be irrigated with a 1-to-3000 sublimate solution, and the wound dressed with a loose sublimate gauze dressing. If the trephine is not used, the scalloped gouge (Fig. 69), the bone-drill (Fig. 72), the scoop (Fig. 68), or the chisel and mallet may be substituted. If (as has occurred in several instances) marked bleeding occurs—probably from wounding some large vein near its entrance into the sinus—it may be arrested by packing with sublimate gauze and

the drainage established a few hours later, when the hæmorrhage has ceased, by substituting a loose dressing.

THE NOSE.

Acquired Lesions.—*Fracture* of the bones of the nose has been already considered.

Epistaxis, or hæmorrhage from the nose, is often severe enough to demand surgical interference. The bleeding may at times be arrested by diminishing the blood-pressure in the vessels of the nose by *ligation of the extremities*. This consists in applying an elastic bandage (or an ordinary roller, if the rubber can not be obtained) around the thighs and arms close to the trunk, and making the pressure strong enough to arrest, in great part, the return of blood through the veins without arresting the circulation in the arteries. When the hæmorrhage ceases the ligatures should be gradually loosened, so that the volume of blood which has been confined in the extremities may not be too suddenly returned to the heart. *Plugging* or *tamponing the nares*, if properly done, will succeed if all other methods fail. First, determine accurately the nostril in which the bleeding is occurring. Take a piece of fine sponge at least an inch in diameter when dry (and it should be introduced without being moistened, so that when in position in the posterior nares it will expand as the blood moistens it), and tie around its center three strong silk threads. A soft catheter or bougie is now introduced into the nostril from the front, keeping the point of the instrument well on the floor of the nose. As soon as the end is seen or felt behind the soft palate, it is drawn out at the mouth by the forceps or fingers. Two of the three threads are attached to the point of the instrument, which is then pulled back through the nostril. When the threads come out of the nose in front they are seized by the fingers of one hand while the sponge is carefully guided into position *behind* the soft palate with the other. Once well in the posterior naris it is held in position and made to exert the necessary compression by tying the two anterior strings over a softened sponge packed into the nostril in front. The third thread is brought out of the mouth, and is to be used in dislodging the tampon when the hæmorrhage has ceased. Lint, soft rags, or cotton may be used for plugs when a sponge can not be obtained. A long probe or a loop of soft wire may be used instead of the bougie. The application of a 4-to-8 per cent solution of cocaine hydrochlorate to the mucous membrane of the nose may prove useful as a hæmostatic, since Bosworth has demonstrated that it causes marked diminution in the caliber of the vessels of the lining membrane.

Foreign Bodies.—Buttons, seeds, and other substances are often lodged in the cavity of the nose. The usual seat of lodgment is in the anterior part of the inferior meatus, or between the lower turbinated bone and the septum, and occasionally they are pushed beyond this into the middle meatus. When allowed to remain, inflammation of the lining membrane always ensues, and otitis is not infrequent.

The diagnosis depends upon physical exploration by means of the head-mirror, a strong light, and the metal probe. The presence of a body lodged in the nasal cavity may be at times indicated by the change of the voice from its natural to a nasal tone. Removal is urgent, and may be effected by inspiration through the mouth and forced expiration through the nose, with the mouth and nostril of the unaffected side closed. In adults the act of sneezing will sometimes succeed in dislodging the substance. A strong, slender forceps, bent at an angle so that the hand of the operator will not shut out the light, is the most suitable instrument to be employed in its removal. When the body is lodged well back it may be pushed through into the pharynx and ejected from there.

Rhinolites, or *nasal calculi*, are occasionally found in these cavities. It is probable that they come from the lachrymal apparatus, since they are found in the immediate neighborhood of the entrance of the nasal duct. Moreover, *dachryolites*, or lachrymal concretions, are not very infrequent in the lachrymo-nasal apparatus. These bodies should be removed with the forceps as soon as discovered.

Neoplasms.—The most frequent variety of tumor within the nasal cavity is the *myxoma*, or so-called *gelatinous polypus*. Next in order of frequency is the *fibroma*, or *fibrous polypus*. Both of these belong microscopically to the connective-tissue tumors, the myxomata being allied to the embryonic, the fibromata to the more developed connective-tissue tumors. *Papillomata*, or *warts*, are not infrequently seen at the edges of the mucous membrane of the nostrils. Lastly, there may be a general *hypertrophy* of the mucous membrane of the nose, causing a tumefaction of the turbinated tufts, and partial, or may be complete, occlusion of the nares.

Gelatinous nasal polypi are usually pear-shaped, the bulk of the tumor tending toward the floor of the nose. The pedicle is attached to one of the thick velvety tufts, most frequently in the upper or middle meatus. There may be a single tumor, although the rule is for them to be multiple. They are of light grayish color, and are covered by a mucous exudation.

The *symptoms* are chiefly those due to pressure and obstruction of the nares. Changes in the voice are not marked until the presence of the tumor has been suspected from pressure and irritation. This irritation gives rise to an excessive secretion and discharge from the nose, and occasionally to prolonged and violent fits of sneezing.

The *diagnosis* may be rendered positive by physical exploration. The shrinkage of the turbinated tufts, following the local use of cocaine hydrochlorate, renders inspection more easy.

Treatment.—The only rational method of treatment is removal and destruction of the pedicle and contiguous mucous membrane. Avulsion may be effected by seizing the growth with a long, delicate polypus-forceps, and twisting the tumor around until the pedicle is wrung off, then applying pure nitric acid or the galvano-cautery to the stump. The *wire écraseur* or *snare* of Jarvis is greatly to be preferred (Fig. 437).

After the wire-loop has been passed around the tumor, and slipped up to the pedicle, it should be slowly tightened, since by this method the danger of hæmorrhage which always follows the use of the forceps is avoided. From one to two hours may be consumed in the division of the growth, the screw being turned from time to time. Nitric acid or the cautery should be applied to the stump in all cases, since without this recurrence is almost certain:

Fibromata, or *fibrous polypi*, are much less frequent than the *myxomata*. As a rule they are deeper situated. They require the same treatment as above given. Occasionally large tumors of the nasal cavities require for their complete removal section of the nasal and superior maxillary bones. In this procedure the skin and periosteum should be left intact, and osteoplasty performed in order to prevent necrosis.

Papillomata, or *warts*, which occur at the junction of the mucous membrane of the nares with the integument, should be clipped off with curved scissors and their bases burned with pure nitric acid.

Hypertrophy of the turbinated tufts may exist to such an extent as to demand interference. Such enlargement should be treated exactly as one would treat true polypus.

Fissures of the nares may be relieved by the repeated local use of the lunar-caustic pencil.

Ozæna.—*Ozæna* is the name given to a chronic inflammation of one or more of the nasal cavities, or the sinuses communicating with them. It may be confined to a process of ulceration of the soft tissues alone, but not infrequently there is an otitis. Syphilitic *ozæna* is probably the most common form. It frequently occurs with other dyscrasiæ. It is accompanied by a fetid odor and a muco-purulent discharge, partially liquid and partially solid. Atrophy, or destruction of the turbinated tufts, is not infrequent, so that there is abnormal space within the nares.

The *treatment* is local and general. The removal of diseased or dead bone is imperative, and irrigation with the weaker sublimate or boracic-acid solutions should be regularly made.

Dobbell's solution will be found of use: Carbolic acid, gr. x; biborate and bicarbonate of soda, each, ℥j; glycerin, ʒx; to this add water to make ʒx. This should be used five or six times a day as a douche. The general condition of the patient should be improved by the administration of well-selected tonics and food, and by out-of-door life.

Superficial epithelioma, situated upon the nose or face, should be destroyed by the application of Marsden's paste. It is made of arsenious acid and powdered gum acacia, equal parts, with enough water to make a fairly soft paste. It may be left on from twelve to twenty-four hours—



FIG. 437.—Jarvis's snare.

as long as the patient can endure the pain. Poultices are applied afterward. If the first application is not sufficient, it should be repeated. The loss of substance caused by the destructive action of the paste may be repaired by a plastic operation; but this should not be done until cicatrization has occurred.

The *frontal sinus* may be involved in some of the diseases which affect the nose. New growths, abscess, or ostitis may demand the application of the trephine in the removal of a neoplasm or dead bone, or the evacuation of pus.

Deviation of the nose from the median line may be congenital or acquired. The septum alone may project to one side, or the entire organ be displaced laterally or upward. When the distortion is due to malformation of the bones, these must be forced into position, with or without fracture.

Deviation of the septum to such an extent that deformity is produced or one nostril closed often requires correction.

The method of Prof. John B. Roberts has yielded good results.

Make a long incision at the most prominent portion of the deviation, and supplement this by chopping the septum full of incisions with the stellate punch. If there is an angular deviation close to the palatal process of the superior maxillary bone, make an incision from front to back at the most prominent part, and do not chop the upper portion with the stellate punch. If the deviation is a curved one, split the

cartilage along the most prominent portion and then chop the rest of the septum until it has lost its resiliency. Afterward




FIG. 437 A.—Roberts's nasal pin.

cut away with the chisel or saw any horizontal bony edge that may remain at the bottom. If some small triangular pieces are removed by the interlacing of the incisions made with the forceps, it makes no difference, since the openings left are very small and will soon become closed. To hold the septum in place, use steel pins (Fig. 437 A), either those with spherical heads of glass, or the flat-headed pins which were devised some years ago. When the head of the pin is to be within the nostril, those with the glass heads are better; when the head is to lie against the exterior of the nose, the flat heads are preferable.

After having divided the septum (*a*, Fig. 437 B), as above described, introduce a pin (*b*) into the more open nostril and thrust its point through the anterior part of that portion of the divided septum. Displace this part into the desired position, thrust the point of the pin onward and bury its point deep in the tissues at the back part of the nasal chamber

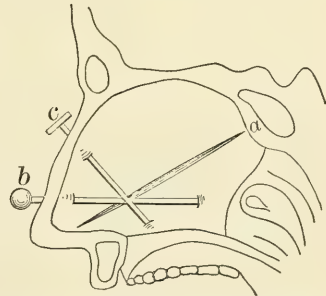


FIG. 437 B.—Roberts's method of holding the septum in correct position by means of pins. The upper part of the septum, immediately above the oblique incision, projected too far this way (i. e., toward the reader). It is now pressed the other way (i. e., from the reader), and is held there by the pins. *a*, Incision through the septum. *b*, *c*, Pins in position.

which was formerly occluded. This holds the septum firmly in its new location. The head of this pin will be just inside of the anterior naris which was not obstructed, and will lie against the columella. It should be allowed to remain about one week, for if left a longer time its head will probably cause ulceration of the columella, and may become deeply buried in the tissues of the columella. Its work is usually accomplished within a week. It is often well to introduce a second pin (c, Fig. 437 B), from the external surface of the front of the nose just below the nasal bones, which aids in keeping the septal cartilage pinned into proper place. If this pin has a flat head, it may be covered with a small square of court-plaster. The patient can then go about the streets without attracting attention.

In many instances hypertrophy of the turbinated bones, or permanent thickening of the vascular membrane covering them, obstructs the nose to such an extent that the passage of air by these channels is difficult or impossible, or deviation of the septum may result. Under such conditions, removal of the turbinated bones and tufts is indicated. The inferior tuft is commonly implicated. A sufficient degree of anæsthesia may usually be obtained by the careful application of cocaine hydrochlorate—4-per-cent solution—brought directly in contact with the mucous surfaces to be incised by means of pellets of cotton, attached to delicate probangs. A small quantity may be employed through the nostril by means of the atomizer. When the anæsthesia is effected, the turbinated bone may be sawed through at its attachment to the superior maxilla. Should hæmorrhage be troublesome, it may be arrested by plugging the nostril.

Hypertrophy of the nose, due to increased vascularity, may be corrected by repeated incisions across the track of the enlarged vessels, by galvano-puncture, or by causing their obliteration by injections of 50-per-cent carbolic-acid solution, as for *nævus*.

PLASTIC SURGERY OF THE NOSE.

Loss of substance may occur from the accidental or surgical ablation of all or a portion of this organ, or from its destruction by disease. The diseases which most frequently produce loss of substance are *syphilis* and *lupus*. Carcinoma, sarcoma, elephantiasis, or any neoplasm, may involve the nose and cause loss of tissue in their removal, but lupus locates itself by preference here, while one of the most common lesions of tertiary syphilis is necrosis of the cartilages and bones of the nose, resulting in great disfigurement. Occasionally sloughing occurs, from the presence of a phagedenic syphilide during the second stage of this disease. This accident occurred in the patient from which Fig. 447 was taken.

Rhinoplasty may be partial or complete. Complete rhinoplasty is performed when the skin, cartilages, and bone of the nose have been carried away. In such cases nothing remains but an irregular sunken pit, leading almost directly into the pharynx.

The successful and satisfactory restoration of this organ is not often achieved. It would be well, in all cases of complete loss of the nose, to try some form of prothetic apparatus before resorting to a plastic operation.

The operation consists (1) in paring the margins of the opening and the integument immediately around the opening, in apposition to which the transplanted flap is to be brought; (2) in the transportation of a properly shaped piece of skin, with its underlying tissues, from its normal to the new position.

The flap may be taken entirely from the forehead, or one half from each cheek, or from the arm. One of the most frequent causes of failure in this operation is the caving in of the ridge of the new nose, and, in order to better support this part, the end of one of the fingers may be utilized, as follows:

First Method—Complete Rhinoplasty from the Forehead and Finger.—Remove the nail and matrix of one finger of the left hand, split and dissect up the integument on the palmar surface of this finger, as far back as the last interphalangeal articulation, and sew this to the already freshened edges of the nasal opening. The arm, hand, and head should now be immovably fixed in a plaster-of-Paris dressing, in which position it remains for about four weeks. When the circulation is freely established between the vessels of the face and the transplanted finger, the latter should be amputated at the first or second interphalangeal articulations, as may be necessary to have it of sufficient length to support the covering of integument. After several weeks' delay, to assure the permanent vitality of the transplanted phalanx, a flap may be turned from the forehead to the nose, as follows:

Cut a piece of chamois-skin, or soft, thin leather, of the shape represented in Fig. 438. Adjust this to the line of the nasal cavity, to see if it is large enough and of proper shape. Bear in mind the following points: 1. The flap once dissected up tends to contract. It should therefore be slightly larger than a pattern which fits exactly. 2. The isthmus (*d*, Fig. 438) must not be too narrow, for fear that the vitality of the flap may be insufficient. It should always be cut so as to include the angular artery. 3. The distance from the isthmus (*d*) to (*e e*), where the lower edge of the new nose is to be, should be considerably less than the distance from *d* to *a c*, in order to prevent tension of the flap and interference with the circulation through the pedicle, *d*. Lay the pattern on

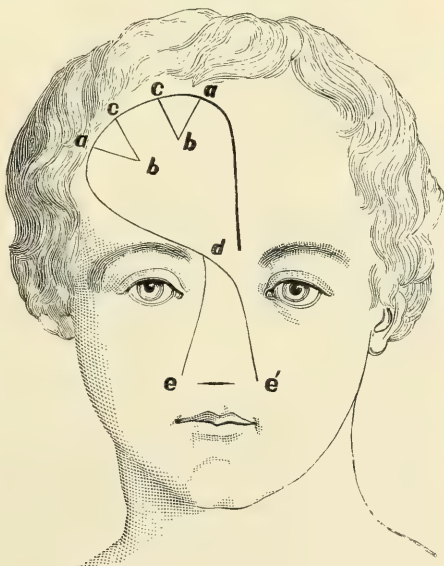


FIG. 438.—(After Linhart.)

the forehead and outline the flap by making punctures at intervals of every fourth of an inch along its edges. The incision, made through all the tissues down to the periosteum, should begin at *d* and be carried to *a c c a*, and then down to a point near the eyebrow, at *d*, in the line of the freshened margin of the nasal cavity. The smaller incisions in the flap *a b* or *c b* are made to provide for the septum and alæ of the new nose. If the finger has been grafted for the support of the flap, the incisions of Labat, *c b*, *c b*, will suffice; if not, those of Linhart, *a b*, *a b*, will give a doubly folded septum, and one less likely to fall or cave in. The flap is now dissected up from the periosteum as far as the pedicle, when it is turned down and sewed into position with fine silk sutures. The secondary flap for the septum is first doubled on itself, and then bent in at a right angle to the axis of the nose, and stitched down, as shown in Fig. 439, to the center of the lowest portion of the nose, just above the middle of the upper lip, while the alæ are also folded in and sewed, as represented in the same cut. The operation is completed

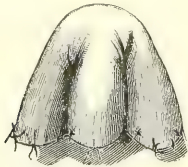


FIG. 439.—(After Linhart.)

when the entire flap has been accurately stitched to the freshened edges of the cavity, as shown in Fig. 440. Pieces of rubber tubing may be inserted in the nostrils to hold the alæ in position. The upper part of the wound on the forehead is drawn as near together as can be done, with silk or silver-wire sutures, and a sublimate or iodoform gauze dressing is applied. No pressure must be exercised upon the pedicle, or flap, which should be loosely enveloped in the dressing. In about two weeks the circulation will have been sufficiently established between the flap and the edges of the cavity to permit the section of the pedicle, the stump of which is used in filling up the gap upon the forehead. In returning the pedicle to its original position, it is advisable to scrape out the granulation-tissue in the bottom of the wound, so that the returned portion will sink to the proper level.

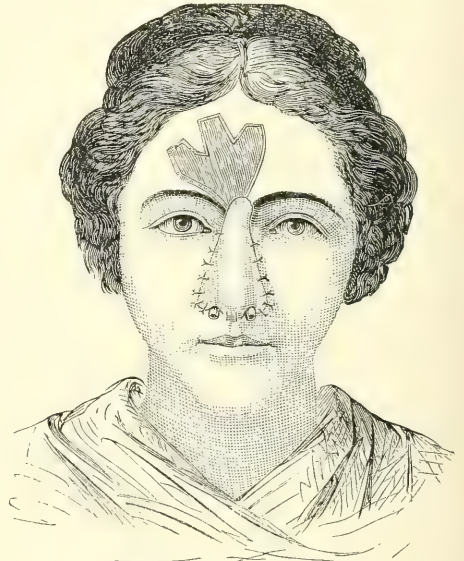

FIG. 440.—(After Malgaigne.)

Among other methods of performing complete rhinoplasty is that of Dieffenbach, as shown in Fig. 441, or that of Koenig, Fig. 442, in which the pedicle is somewhat wider than in the other flaps. The flap of Langenbeck is shown in Fig. 443. These various operations of transplanting the flap from the forehead are modifications of the Hindoc

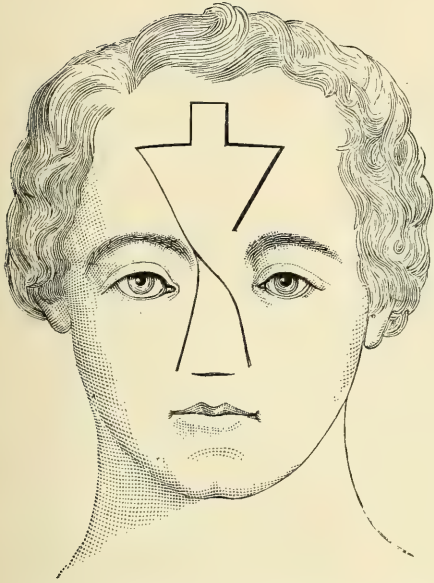


FIG. 441.—Dieffenbach's method. (After Linhart.)

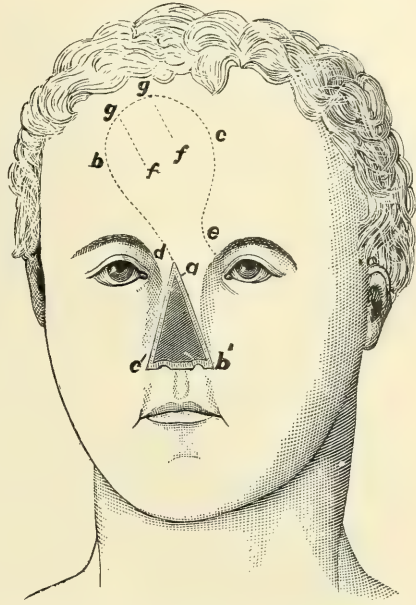


FIG. 442.—Koenig's method. (After Koenig.)

method. Fig. 444 represents a rhinoplasty done by a Hindoo surgeon in 1793.

Second Method—Complete Rhinoplasty from the Arm.—Freshen the margins of the nasal cavity as before.

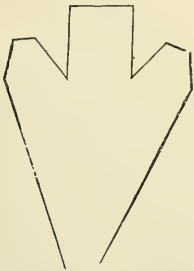

FIG. 443.—Langenbeck's incision. (After Koenig.)




FIG. 444.—(After Szymanowsky.)

Transplant a portion of the finger as before described, if the septum nasi has completely disappeared. Place the palm of the hand on the top of the head, Fig. 445, so that the anterior surface of the humeral region will be in close proximity to the face. Calculate the length and breadth of the flap required to be raised from the arm, and outline it with ink. Fit a strong wire cuirass or the *upper half* of Bauer's wire breeches comfortably and securely, so that the head and neck may be held immovable. Or apply a plaster-of-Paris jacket, which shall cover the head. Mold a strip of one-quarter-inch-thick gutta-percha to the arm and forearm, or, if this material can not be obtained, sole leather or shellac may be sub-

stituted, so that with the hand on the occiput and the interparietal suture, the strip may be fitted to the antero-lateral aspect of the corset and along the arm, forearm, and hand, as in Fig. 445. Next dissect the integument from the deltoid region down toward the elbow, making it

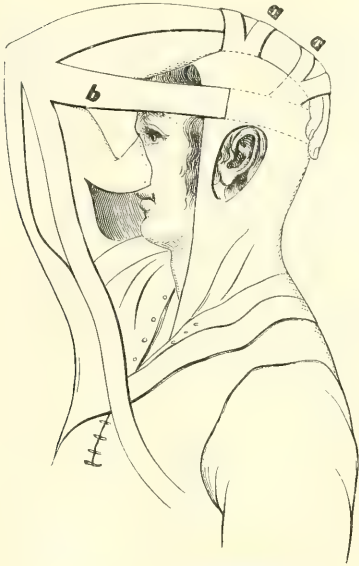

FIG. 445.—(After Linhart.)

it extra long and wide, and lifting everything down to the deep fascia. When the hæmorrhage has ceased, dress the wound in the arm with sublimate gauze, apply the gutta-percha mold, fix it upon the corset with a tight roller, fasten it and the underlying hand to the skull-piece or helmet (*a a*, Fig. 445) and accessory, supporting strips of strong adhesive plaster, as at *b*. Lastly, stitch the edges of the flap to the freshened margins of the nasal rim. The circulation between the face and skin of the arm should be sufficiently established from the tenth to the fourteenth day to permit section of the flap.

Since the skin of the arm is very thin, and after transplantation is apt to shrink away, it is a wise precaution to dissect up the flap from the shoulder and arm, making it longer than may at first appear

necessary—and to do this eight or ten days before the arm is fastened in the immovable apparatus. The flap in this way shrinks, and is covered with granulations, in which condition union with the integument of the face is accelerated and assured.

When the vascular connection is safely established, the pedicle is cut, the arm released, and the flap shaped and stitched in position, as in the preceding operation.

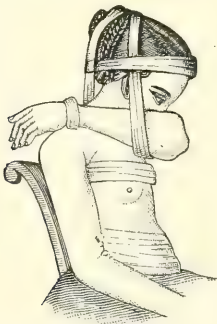


FIG. 446.—(After Szymanowsky.)



FIG. 447.

Wutzer took the integument from the forearm; Fabrizzi from near the elbow (Fig. 446).

Partial Rhinoplasty.—

When there is only a partial loss of substance the operation is less difficult, and the prospect of success greater. When one ala is involved, as shown in one of my cases (Fig. 447), the flap may be made from the cheek (Fig. 448). In this patient I trimmed the cicatricial edges of the scar and turned a flap, as indicated by the dotted lines, and stitched it to the nose. The wound in the face was partially closed by sutures. The pedicle was divided on the fourteenth day and turned back into the wound, the granulations having been previously scraped out. Or the flap may be borrowed from the side of the cheek, leaving the pedicle above, as in Fig. 450.

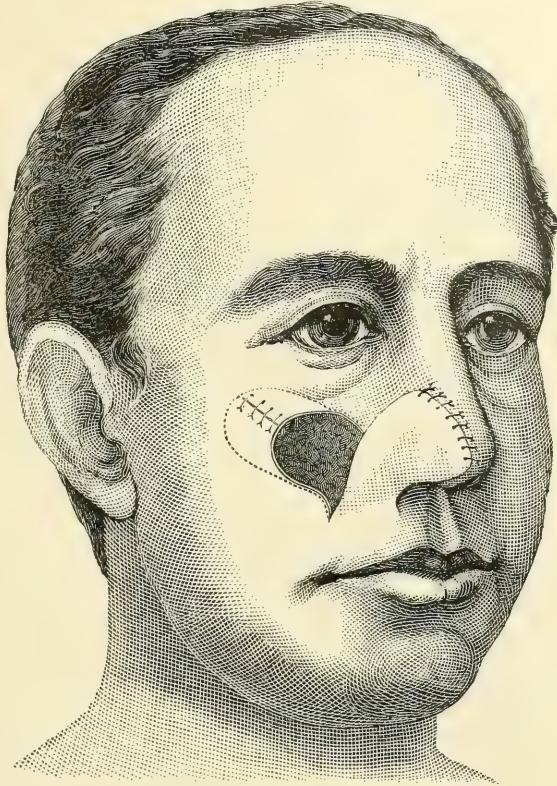


FIG. 448.

When the tip of the nose is eroded, the method indicated in Fig. 451 should be adopted. The broad end of the flap is split; the center strip (*a*) is for the septum, while those at *b b* are to complete the eroded alæ.



FIG. 449.—Transplanted portion in the new position after division and return of the pedicle.

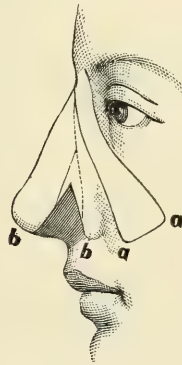


FIG. 450.—(After Linhart.)

When in the removal of small neoplasms the ala nasi is perforated, the wound may

be closed by sutures, or the gap may be filled by a small graft of skin lifted entirely from the arm or abdomen, and transplanted upon the nose.

Operations of minor importance are at times performed to correct lesser deformities.

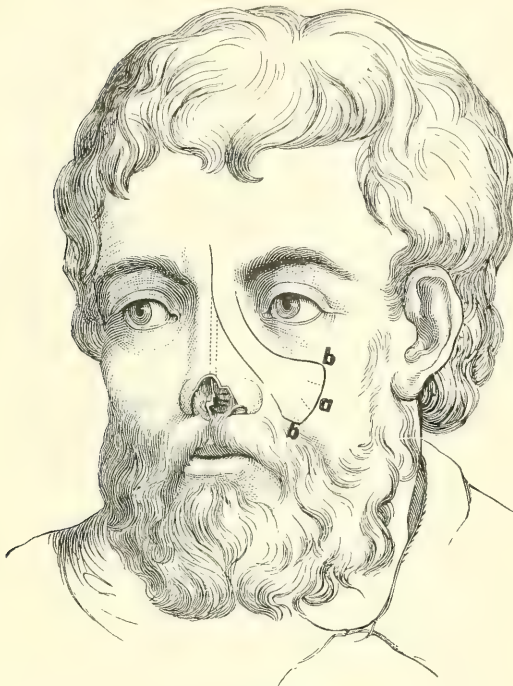

FIG. 451.—(After Linhart.)

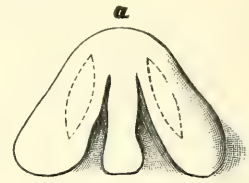


FIG. 452.—(After Linhart.)

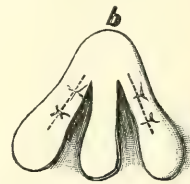


FIG. 453.—(After Linhart.)

When the *alæ* are too thick, elliptical pieces may be excised and the edges closed, as in Figs. 452 and 453. If the tip of the nose is too pointed and upturned, it may in part

be corrected by excising a triangular piece from the septum and closing the gap with sutures.

Congenital Lesions of the Nose.—Occasionally the lateral halves of the nose fail to unite, resulting in the deformity known as bifid nose. There may be *partial* or *complete absence* of this organ, or when present the nares may be occluded, or it may be complicated with the extreme cases of hare-lip. The operative procedure for the relief of this last deformity will be given in connection with congenital cleft of the lip. Occlusion of the nares may be relieved by cutting through the membrane in the direction of the normal opening. For the correction of forked-nose, or the absence of this organ, no fixed rule of practice can be laid down.

THE LIPS AND CHEEKS.

Wounds.—Accidental *wounds* of the lips are usually incised or lacerated. If badly torn, the ragged edges should be smoothly trimmed, washed with sublimate solution, and secured with interrupted silk sutures. When the wound is through the entire thickness of the lip, the sutures should include the mucous membrane. A very fine suture or pin should be used in the vermilion border to insure absolute approxi-

mation here. Adhesive strips are not reliable. In children one or two pin-sutures should be preferred, as they best resist the constant strain to which sutures of the parts are subjected in the act of crying.

Diseases of the Lips.—Among the diseases which involve the lips and the contiguous structures are *epithelioma*, *lupus*, *papilloma*, *naevus*, *cysts*, *lipoma*, *adenoma*, *phlegmon*, *ulcers*, and *general hypertrophy* and *fissures*.

Epithelioma.—One of the most frequent causes of removal of portions of the lips is the presence of *epithelioma*. It is a disease of middle and old age, involves usually the lower lip, and occurs in the great majority of instances in males. Epithelioma may attack the lip without any appreciable cause, but in most cases the appearance of the neoplasm is preceded by prolonged irritation at the place involved. A jagged or projecting tooth, the habitual use of a pipe-stem or cigar, are frequent causes of this disease. It will also result from the irritation caused by chronic fissure or ulcer of the lip.

Symptoms.—It begins as a small ulcer with rather abrupt margins, in the bottom of which is a dirty granulation-tissue partially hidden by thin pus. In its earlier stages it is not readily distinguished from the benign ulcer which is found upon the lip. The preceding history of a prolonged irritation should always suggest epithelioma, especially if it occurs after the age of thirty, and upon the lower lip. Ulcer is apt to occur in one of the scrofulous or tubercular diathesis. If grave doubt exists as to its malignant nature, the application of the solid stick of nitrate of silver should be made. An ordinary ulcer will heal rapidly under this stimulus, while the epithelioma is not affected. Labial chancre may be differentiated by the indurated base, which is characteristic of this lesion. Adenitis in the line of lymphatics along the lower jaw comes on in the earlier stages of syphilis, while in epithelioma the sore may exist for months without perceptible enlargement of the lymphatic glands. In syphilis the appearance of the eruption, together with the history of the case, will lead to correct differentiation.

Epithelioma of the lip is a dangerous affection. Left alone, it destroys life within a period varying from one to four years. It spreads at times with rapidity, eating away the tissues in all directions. It may confine itself to the soft parts, or attack the maxillary and nasal bones. Engorgement of the submental, sublingual, submaxillary, and cervical glands is almost inevitable if the disease is not extirpated in the first few months of its history. The glandular enlargement is at first not always due to metastasis, but may result from simple adenitis following the inflammatory process in the margins of the ulcer.

Treatment.—The early excision of the diseased tissue is imperative. The knife should always be preferred to the use of corrosive substances. The incision should be wide of the diseased area—at least half an inch from the infiltrated margin. If the disease has existed long enough to have caused lymphatic enlargement, the infiltrated glands must also be extirpated.

The *prognosis* as to a permanent cure is always doubtful, although

when the operation is performed early in the history of the disease a cure may be effected. In many cases where recurrence after operation is probable, life may be prolonged and rendered more endurable by excision of the ulcer. After a primary excision the patient should be kept under close observation, and, upon the reappearance of the neoplasm in the scar or lymphatics, a second operation should be performed. In 1884 I removed a large number of infiltrated glands from the neck of a man about fifty years old, who had had an epithelioma of the lip excised twelve years previous to that date. Five years after the first operation a gland at the lower edge of the jaw became enlarged and was extirpated. Six years later the glands beneath the jaw began to swell, and a year later, when I saw him, metastasis had seemingly occurred in all the lymphatics as far down as the lower third of the neck on one side. The infiltration was so extensive and deep that it took two operations, each lasting about three hours, to effect the removal. The examination of the glands demonstrated the malignant character of the disease. At this date, two years from the last operation, the patient is living and healthy.

Lupus.—Lupus erythematosus and vulgaris usually attack the tissues of the nose, cheeks, and lips, at times producing extensive loss of substance. The erythematous variety is first seen as small red papules, projecting slightly above the epidermis, and covered with scales. It is a disease of the sebaceous glands and ducts, causing chronic inflammation of the skin and atrophy of all the elements of the cutis. Its progress is slow, and the prognosis is usually favorable when the disease is confined to a limited area. It does not affect the general health of the patient, and often heals spontaneously, leaving a flat, smooth scar. When disseminated it is more dangerous, not infrequently ending in fatal complications. The *treatment* requires generous diet, tonics, and out-of-door life. Among the local agents recommended in lupus erythematosus is green soap, which should be spread on lint and pressed closely upon the affected part, or rubbed in with the finger every day. Prof. A. R. Robinson, in addition to the above, also recommends a 10-per-cent solution of oleate of mercury brushed over the diseased surface.

If the disease does not yield to these milder measures, the sharp spoon should be employed and the broken-down tissue thoroughly scooped out. Emollients, cold applications, or poultices may be used afterward, according to the requirements of the case.

Lupus vulgaris is a more formidable affection. In its earlier stages it consists of a number of soft red dots in the deeper layers of the integument, which gradually appear as papules upon the surface. The characteristic lesion is the infiltration of the skin with an abundant small cell new-growth. It is believed to be a tuberculosis of the skin. The integument breaks down and is cast off as a slough. The new-formed cells also undergo granular metamorphosis, and disappear with the other destroyed tissues. The only disease likely to be mistaken for common lupus in the adult is epithelioma. Lupus begins usually in childhood, while epithelioma is exceedingly rare before the age of thirty.

The ulcer of lupus is not so painful as that of epithelioma, nor its edges so hard and elevated. The *treatment* of this affection is often unavailing. The constitutional treatment is the same as for lupus erythematosus. Locally, a 10-per-cent ointment of pyrogallic acid, spread upon linen and closely laid upon the diseased surface, is a useful remedy. It should be applied twice daily for several days, and then poultices or ointments used until the slough is removed. In certain cases it is advisable to scrape the ulcer well with the sharp spoon, and then apply the pyrogallic acid for one or two days.

Nævus.—As has been stated in the article on diseases of the vascular system, arterial, capillary, and cutaneous vascular tumors are occasionally located upon the lips and cheeks, and require removal by the knife, ligature, or injection. Their excision often causes extensive loss of tissue. When situated in the free border of the lips or nares, the 50-per-cent carbolic-acid injection should be tried before excision is practiced.

Moles are less formidable, and rarely require an extensive reparative operation after excision.

Papilloma, lipoma, adenoma, and fibroma do not, as a rule, require extensive incisions and loss of tissue in their removal.

Cystic tumors of the lip are not infrequent, occurring as spherical swellings beneath the mucous membrane. They are caused by obstruction of the duct of a labial follicle, and contain a thick, ropy fluid. The treatment involves a careful and thorough excision of the sac.

Fissures, or "*chaps*" of the lip may occur independently of any constitutional disease. They may be cured by a local astringent, as alum, or caustic, as nitrate of silver, applied once a day for two or three days. When these more simple remedies are without avail, excision should be practiced. When fissure of the lip is allowed to remain, and the general condition of the patient is bad, necrosis of the mucous membrane immediately contiguous ensues, causing a grayish-red ulcer. The treatment consists in the local use of astringents and the improvement of the patient's nutrition.

Phlegmon of the lip is rare. It is a painful and dangerous affection. The pathology of carbuncle has been given. The proper treatment is early and free incision through the skin, deep fascia, and muscles, and frequent irrigation with strong sublimate solution.

Hypertrophy of the lip is occasionally met with. It may be confined to the mucous and submucous tissues, or the entire thickness of the lip may be involved. It occurs usually in the upper lip, but may be seen occasionally in the lower lip. When extensive enough to require operative interference, the proper method is to dissect out in the long axis of the lip a portion of the tissue between the skin and mucous membrane, and approximate the edges of the wound with silk sutures.

Hair on the Lips of Women.—Permanent epilation may be effected by introducing into the follicle of each hair the point of a fine platinum needle, which is afterward heated by the galvanic current. The employment of cocaine renders this operation painless.

Reparative Surgery of the Lips.—A plastic operation may be demanded in acquired or congenital lack of tissue in the upper lip. In the lower lip congenital deformity is exceedingly rare.

Hare-Lip.—*Hare-lip* is a congenital defect caused by an arrest of development in the tissues which form



FIG. 454.

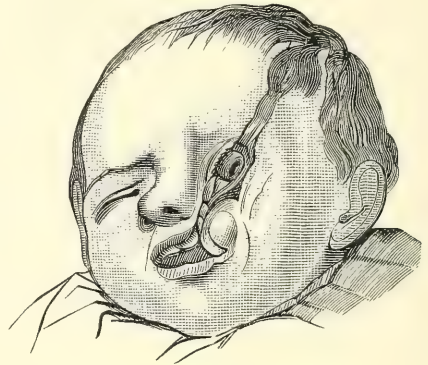

FIG. 455.

the upper lip. Instead of uniting in the median line, a fissure exists which may include either the soft

structures of the face or palate, or the bones of the palate as well. In rare instances the cleavage passes up into the eye and cranium (Figs. 454, 455). The fissure is usually unilateral, and may be so small that it is scarcely noticed, as in Fig. 456, or it may extend half way to or completely into the nasal cavity (Figs. 457, 458, 459). One side of the lip is much thicker than the other. In *double hare-lip* the fissures are about the same distance from the median line. Both may extend into the nose, or one (and rarely both) may be partial. The portion intervening may be

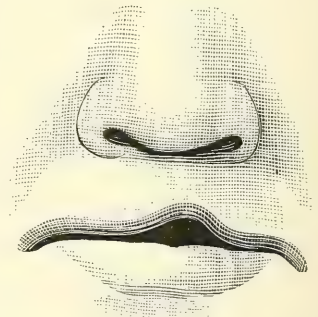


FIG. 456.

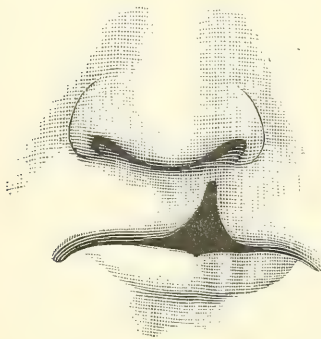

FIG. 457.

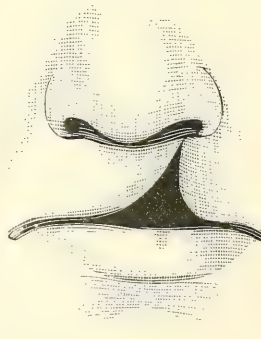

FIG. 458.

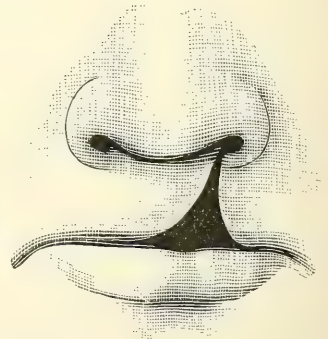


FIG. 459.

composed of a portion of the lip and gum, with one or more rudimentary teeth, at a varying angle of projection. The central piece occasionally is attached to the nose. In incomplete single hare-lip the nostril is not flattened and deformed, as is the case when the fissure extends through the pre-maxillary bone and the palate and alveolar processes of the superior maxilla (Fig. 460). The location of this fissure is most frequently between

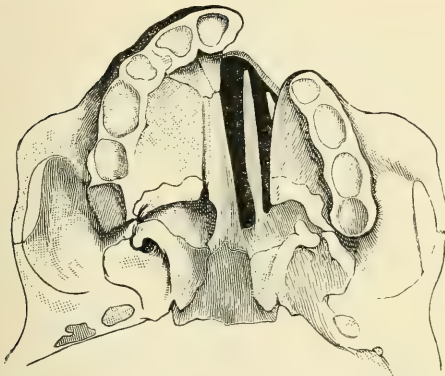


FIG. 460.—(After Koenig.)

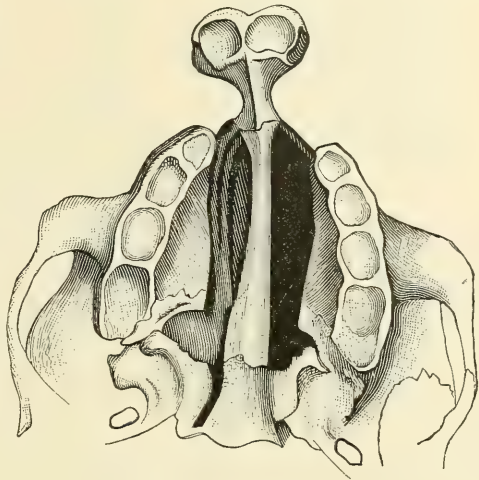


FIG. 461.—(After Koenig.)

the first and second incisor teeth, and through the inter-maxillary bone, and not, as frequently given by some writers, between the second incisor and canine teeth, extending backward through the pre-maxillary suture.

In *double hare-lip* the cleft in the palate is usually double, while the center-piece may be attached to the vomer (Fig. 461), or the pre-maxillary portion may be united to one side of the superior maxilla (Fig. 460). In rare instances the fissure passes obliquely upward and outward, involving the eyelid, orbit, and cranium, producing frightful deformity, as shown in Fig. 455.

Treatment.—The only relief from this deformity is in a plastic operation. It should be done early, and, when possible, within the first few months of life. Hearty and well-nourished infants, with simple unilateral hare-lip, should be operated upon at birth. If they are feeble, an effort at forced nutrition should be made, and the operation postponed until the patient is brought into proper condition. Double or single hare-lip, with cleft palate, should be operated upon early, since by drawing the lip together the tension on the superior maxillary bones facilitates closure of the interosseous cleft.

The methods of operating are numerous. The essential features of every operation are, to trim the edges of the fissure in such shape that, when they are approximated, the gap will be closed and no depression left in the vermilion border of the lip.

Single Incomplete Hare-Lip—First Method.—Having estimated the extent of surface required to fill up the deficiency, with a long, sharp

knife prick the integument of the lip at *a*, *b*, *c*, *d*, and *e* (Fig. 462), as guides to the deep incision. Then the operator, standing in the position which best suits his convenience, seizes the lip between his thumb and

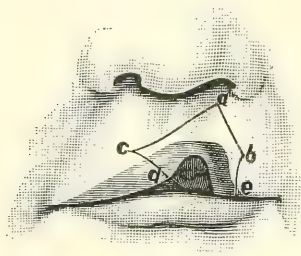


FIG. 462.—(After Linhart.)

finger, so as to control hæmorrhage, and, while the opposite side is held by an assistant, transfixes it at *a*, cuts from *a* to *c*, by smooth, short strokes of the knife, removes and reinserts the blade at *d*, and cuts into the angle at *c*. This manœuvre is repeated in the line *a*, *b*, *e*. With a strong, blunt pair of scissors the soft tissues are freely lifted from the bone, until the edges of the wound can be approximated without any degree of tension. If, as frequently occurs, one side is so much thicker than the other that difficulty is experienced in keeping the approximated edges on the same plane, a part of the under surface of the thicker side should be clipped off with the scissors. Strong silver hare-lip pins (from two to four in number, owing to the length of the incision) are then inserted, being made to enter about one fourth of an inch from the cut edge, passing through the entire thickness of the lip, and out at a corresponding point on the opposite side. A figure-of-8 silk thread is wound about these, and one or two silk sutures are inserted, to secure a perfect approximation at all points. The pins should be about one fourth of an inch from each other, and the lowest should be about this distance from the vermilion border. The last suture should pass through the vermilion border (Fig. 463).

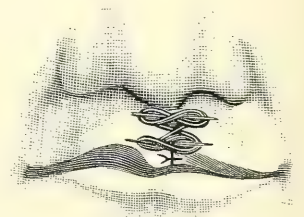


FIG. 463.—(After Linhart.)

In adults a light loose dressing of sublimate gauze will suffice in the after-treatment. In children it is always wise to support the sutures by narrow strips of adhesive plaster, carried from the angle of the jaw across the wound to the opposite side of the face.

The pins and sutures are removed between the third and fifth days. No rule can be laid down, but the removal should be made as soon as union has taken place. For the few days immediately following the operation the muscles of the face should be kept as quiet as possible. Silk sutures may be employed if the pins are not at hand. When the fissure is wider, the angles *b* and *c* should be made deeper, as shown in Fig. 464. When approximation is completed, *c* and *b* unite, while the points *d* and *e* project below the level of the normal lip. Any redundancy of tissue or overlapping should be allowed to remain until all shrinkage has occurred, when the excess may be trimmed off at the level of the lip.

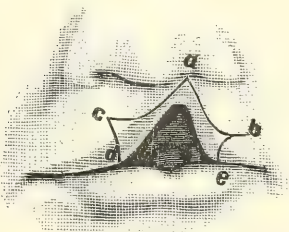


FIG. 464.

Second Method—Operation of Malgaigne.—With a sharp bistoury pare the edges of the fissure, by cutting a strip on each side, from the apex down to about one eighth of an inch from the free border of the lip.




FIG. 465.—(After Malgaigne.)

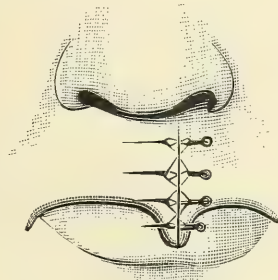


FIG. 466.—(After Malgaigne.)

The strips are turned down, as shown in Fig. 465, and, after the lip on each side is dissected up from the bone, the edges are approximated and united, as shown in Fig. 466. The projecting portion is treated as in the preceding operation.

Third Method—Operation of Langenbeck.—Upon one side of the fissure, as at *b* (Fig. 467), remove a narrow strip from the apex out through

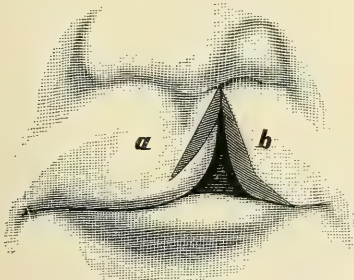


FIG. 467.—(After Linhart, Langenbeck.)

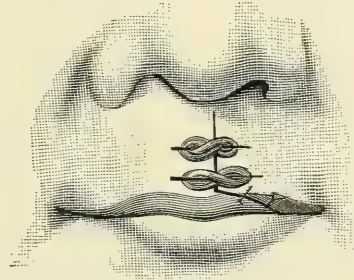


FIG. 468.—(After Linhart.)

the vermilion border. On the opposite side, *a*, the incision extends only to within one eighth to one fourth of an inch of the free border. After the lip is freed from all attachments, the edges are approximated and fastened, as shown in Fig. 468.

Fourth Method—Operation of Nélaton.—Make an incision parallel

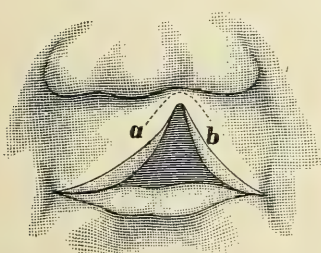


FIG. 469.—(After Nélaton, Koenig.)

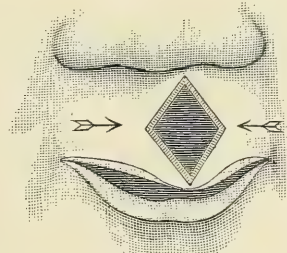


FIG. 470.—(After Koenig.)

with the upper half of the fissure, on either side, the incision arching over the apex, as shown in Fig. 469, *a b*. When completed and turned down, a diamond-shaped or elliptical opening is formed (Fig. 470). The pins should be introduced from near the lateral angles.

Fifth Method—Operation of Graefe.—Make a horseshoe-shaped incision along the apex of the fissure, as at *a* (Fig. 471), and remove the

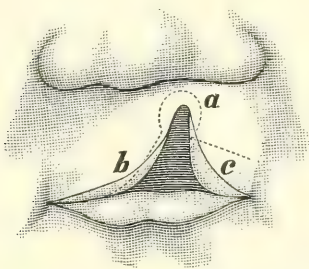


FIG. 471.—(After Koenig, Graefe.)

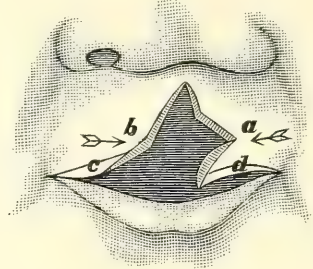


FIG. 472.

included tissue together with a narrow strip along the edge of the fissure on one side, as at *b*, through the free border of the lip. Upon the opposite side, and near the middle of the fissure, an incision through the thickness of the lip is made in a direction outward and slightly downward, as at *c*. In approximating the edges (see Fig. 472), the receding angle at *a* is united to *b* on the opposite side, and the tip of the free border, *d*, is stitched to *c*.

The modification of this procedure by Koenig is preferable in cases where the gap has unusual width at the vermilion border. The horseshoe incision at *a* is the same as in the preceding operation, but there

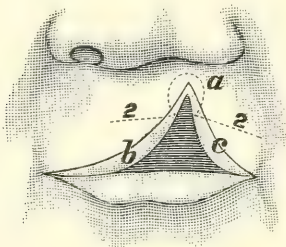


FIG. 473.—(After Koenig.)

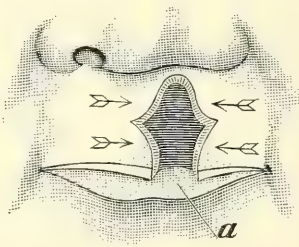


FIG. 474.—(After Koenig.)

are two lateral horizontal incisions, *z-z* (Fig. 473). The wound has the shape shown in Fig. 474, and in approximating the edges the apices of the two flaps, *b c* (Fig. 473), are brought together at the level of *a* (Fig. 474).

Complete Single Hare-Lip—First Method—Colles's Operation.—In certain cases where the fissure is of great width, and extends through the floor of the nose, important modifications of the foregoing procedures are at times necessary. The operation is one of considerable difficulty, not only as to the closure of the fissure, but on account of the flattening of the wing of the nose on the affected side.

In the milder cases the procedure of Colles may be undertaken. Upon one side of the fissure (usually the most perpendicular surface is selected) make an incision parallel with and about one eighth of an inch from its free border, *a c* (Fig. 475). This incision terminates short of the wing of the nose and the vermillion border, and is bisected a little nearer its upper than its lower end, *b*. The opposite surface is freshened by an incision in the line *d e f* (Fig. 475), this strip being entirely removed. When the soft parts are thoroughly dissected up, the edges are approximated, so that the flap *b c* is turned down, and its end is stitched to the line *e f*. The flap *b a* is turned up, its freshened surface being stitched to the upper part of the line *e d*, while its upper edge looks into the cavity of the nostril.

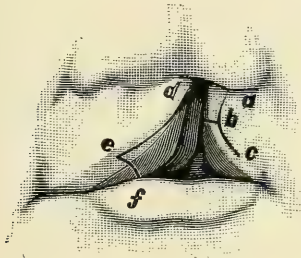


FIG. 475.—(After Linhart, Colles.)

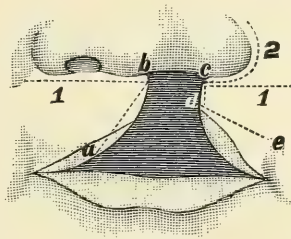


FIG. 476.—(Modified from Koenig.)

Second Method.—In the severer forms of complete unilateral hare-lip, proceed as follows: Freshen the edge of one side of the fissure on the line indicated by *ba* (Fig. 476), and upon the opposite side, as at *cd*, from *d* making a division of the lip outward and downward, *de*, in the direction of the corner of the mouth, and as far as may be necessary. Dissect up the tissues freely from the bones, and make a horizontal incision on either side, as shown at *b 1*, *c 1* (Fig. 476). The length of these incisions will depend upon the degree of tension required to bring the flaps into apposition. When the wing of the nose is greatly flattened the deformity may be in good part relieved by carrying a curved incision, *c 2*, around the ala nasi, and dissecting loose the attachment from the maxillary bone.

Double Hare-Lip.—The method of operation for double hare-lip will depend upon the size and position of the middle piece, and the width

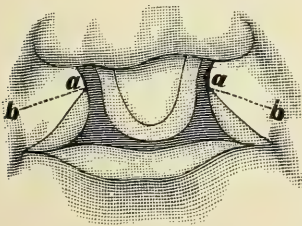


FIG. 477.—(After Koenig.)

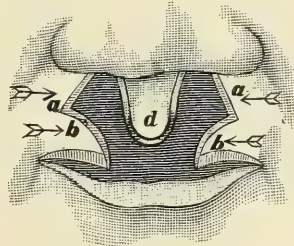


FIG. 478.—(After Koenig.)

and depth of the lateral fissures. If the central piece is so prominent that it will exercise too great tension upon the lip when the sutures are

inserted, the bony projection should be seized with a strong forceps and forced back into a safer position, or broken off with a chisel. The edges of the central tip must be trimmed or freshened. The length of the incision, *a b* (Fig. 477), and the extent of the dissection of the lip from the jaw, will depend upon the space to be covered in. The margin from *a* to the root of the nose is not freshened, since it forms the floor of the nostril when the operation is completed. The condition of the parts when ready for the sutures (pins are not used where a central piece is preserved) is shown in Fig. 478. The points *b b* meet in the median line of the lip, while *a a* are sewed to the central piece.

Cheiloplasty—Upper Lip.—In addition to congenital deficiency of the lips, not infrequently as a result of accident or disease, or the removal of abnormal growths or cicatrices, the surgeon is called upon to relieve the deformity and inconvenience resulting from this loss of tissue.

In the upper lip, when the loss of substance is not extensive, as in Fig. 479, the unsightly appearance may be remedied by making two incisions, curved as represented by the lines *a d*, *a d*, from the side of each

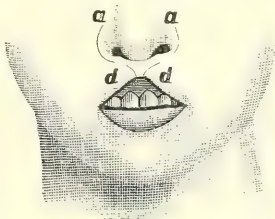


FIG. 479.—(After Roser.)

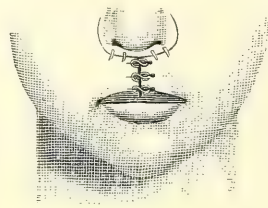


FIG. 480.—(After Roser.)

ala nasi downward and inward to the apex of the fissure. The soft tissues should be dissected up and brought into position by sutures applied as in Fig. 480. If after the dissection the tension is still so great that the parts do not come well into position, a horizontal incision should be made on either side, beginning near the root of the nose, and carried directly

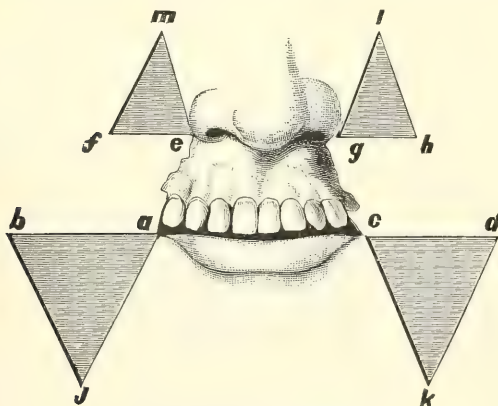


FIG. 481.—(After Linhart.)

outward, or slightly outward, and downward, as the shape of the flap may require. Where there is greater loss of substance, Burrows's method is advisable (Fig. 481). Make a horizontal incision on each side, commencing in the angle of the mouth, and going entirely through the lip, *a b*, *c d*, and unite these at *k* and *j*. Dissect out the triangular piece *j a b*, *k c d*. Make now two other horizontal incisions, which run into the nasal cavity *g h*

and *f e*, and dissect out two smaller triangles, *f e m* and *g h l*. The proximal edges of the quadrilateral flaps *g h c d* and *e f a b* should now

be freshened and freely lifted by dissection, and the sutures introduced. It will be observed that as the edges are approximated, the lines *dk*, *bj*, *mf*, and *lh*, will be united with *ck*, *aj*, *me*, and *lg*.

A third method, which is useful in certain cases, is as follows: After the disease is removed, an incision, *ca* (Fig. 482), is carried from the alæ of the nose upward and outward. The length of this cut and its obliquity depend upon the distance to be filled between the normal line of the lip and the nose. A second incision, *ab*, is now carried deeply downward and outward, making a quadrilateral flap, which hinges at *bd*, and is dissected up, and the edges, *ca*, are brought in apposition and secured in the median line.

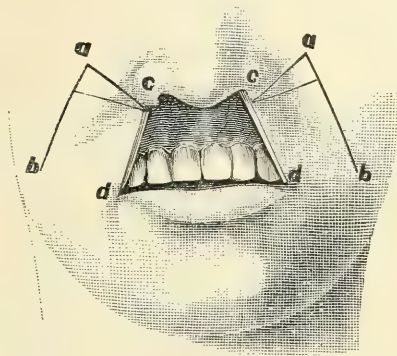


FIG. 482.—(After Linhart.)

Lower Lip.—When the loss of tissue has left a cavity triangular in shape, as in Fig. 483, that one of the following methods may be selected which in the judgment of the operator is best adapted to the case:

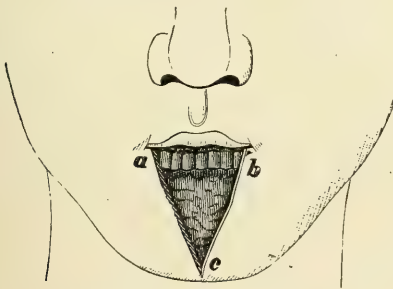


FIG. 483.—(After Szymanowsky.)

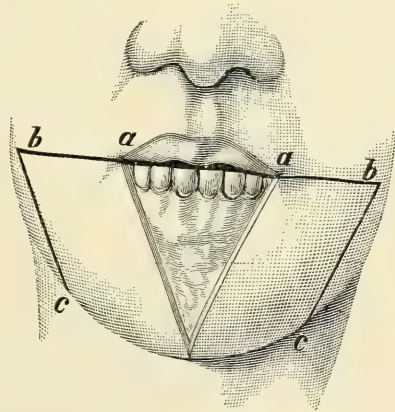


FIG. 484.—(After Linhart.)

1. A horizontal cut, *ab* (Fig. 484), is made outward from the angle of the lip, and a second one, *bc*, parallel with the freshened edge of the fissure. Both flaps are now loosened and slid toward the median line, and united by pins or sutures. Along the free border of the new lip stitch the mucous membrane to the skin with fine silk sutures. The gap left on either side is also wholly or partially closed by sutures.

2. For the same defect make a semi-circular incision outward and downward from each angle of the mouth, *cgd* and *afe* (Fig. 485). Dissect this flap up freely and slide toward the middle line. The pin-sutures are inserted as in Fig. 486, taking

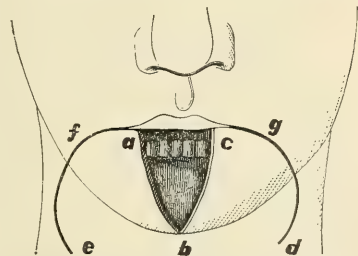


FIG. 485.—(After Szymanowsky.)

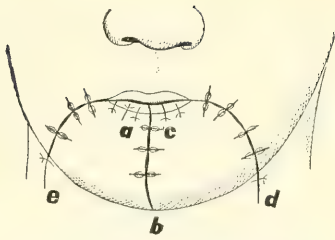


FIG. 486.—(After Szymanowsky.)

the precaution to sew the mucous membrane to the integument along the edge of the newly made lip.

3. If the fissure is less extensive, make a horizontal incision from each angle of the mouth through the entire thickness of the lip for a sufficient distance (Fig. 487), *ae*, *cd*, dissect up the triangular flaps, and adjust with pin-sutures, as shown in Fig. 488.

4. When the apex of the triangular defect does not dip down too far from the teeth, the unilateral sliding operation of Blasius may be prac-

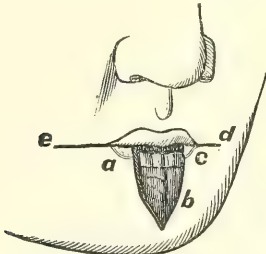


FIG. 487.—(After Szymanowsky.)

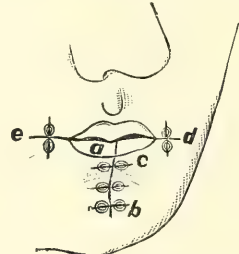


FIG. 488.—(After Szymanowsky.)

ticed. From the apex of the angle, *c* (Fig. 489), make a deep cut, *ced*, downward and outward over the side of the chin, in the main a continuation of the line of the defect, *bfc*.

The flap, *aced*, is dissected up and slid so that *c* is attached to *b* (Fig. 490).

5. When the defect extends in the shape of an isosceles triangle with the apex low down upon the chin, the method of Burrows (Fig. 491) is ap-

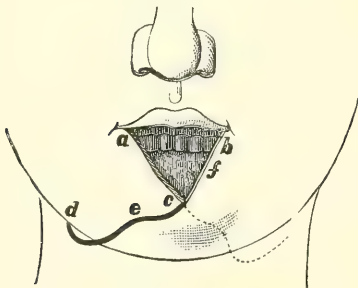


FIG. 489.—(After Szymanowsky.)

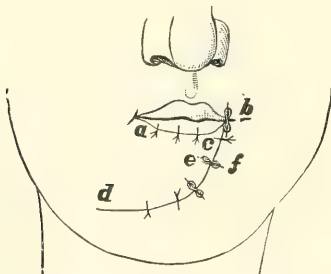


FIG. 490.—(After Szymanowsky.)

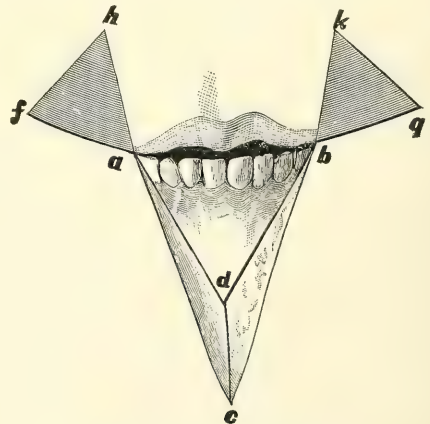


FIG. 491.—(After Linhart.)

plicable. Two triangular pieces, *afh*, *b g k*, are removed from the tissues just above the angles of the mouth. The edges of the fissure are

freshened, the flaps, *f a d g b d*, dissected loose, and the lines, *a c*, *b c*, approximated by sutures.

6. When the defect is long and rectangular, as shown in Fig. 492, the procedure of Von Bruns may be successfully employed. The diseased tissue being removed, the quadrilateral flaps, *a b c d* (Fig. 493), are dis-

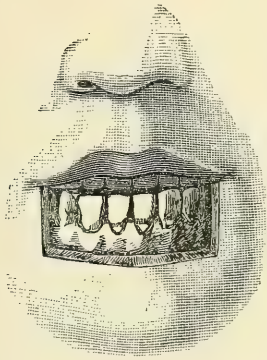


FIG. 492.—(After Linhart.)

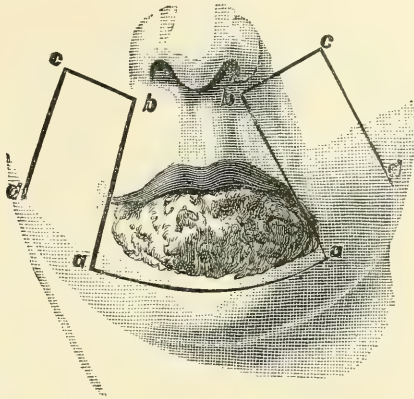


FIG. 493.—(After Linhart.)

sected out and brought down, uniting *c b* in the median line and *a b* on either side to the line *a a*. The defect left on both sides of the outer aspect of the upper lip may be wholly or in great part closed by sutures. The outer incision should not be carried far enough back to wound the duct of Steno.

7. Or the flaps may be turned from below, as advised by Sedillot (Fig. 494). The inferior oblique lines are carried to the middle line and stitched to each other. The defect is closed by sutures (Fig. 495).

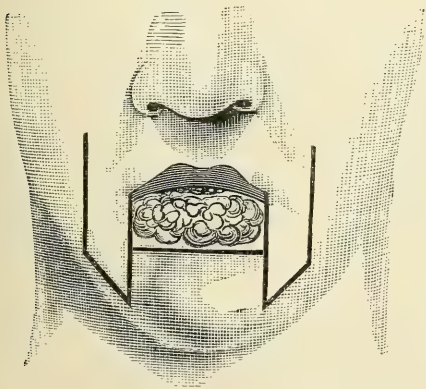


FIG. 494.—(After Malgaigne.)

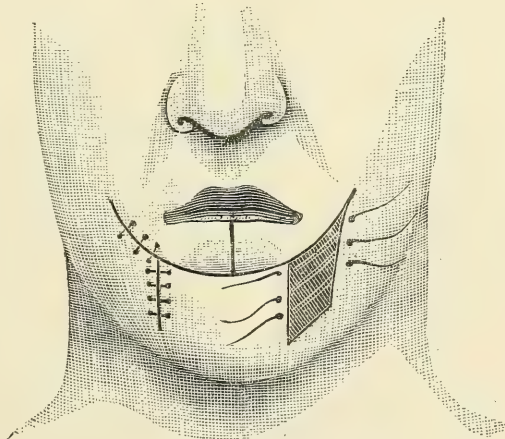


FIG. 495.—(After Malgaigne.)

Cheeks.—When the loss of substance is not extensive, the edges may be dissected up to a limited extent, pared, and brought directly together by sutures. If this can not be accomplished, incisions shaped as shown

in Fig. 496 (Mütter's method), *a b*, *a e*, may be made, the flaps lifted, and brought together by sutures. The gaps left above and below may be also closed at once.

Sliding a flap from the neck is shown in Fig. 497, where the flap, *b a d*, is brought up to fill the oval space left by removal of the diseased

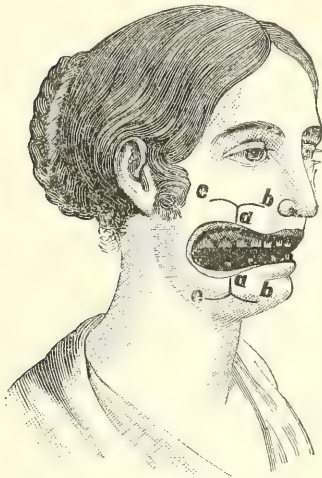


FIG. 496.—(After Roser.)

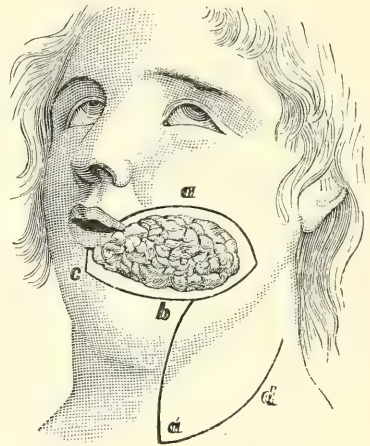


FIG. 497.—(After Malgaigne.)

tissue, *b c a*. The pedicle is divided as soon as union has occurred, and the stump returned, as in *rhinoplasty*.

In *contraction* of the mouth the orifice may be enlarged by incising the angles in a horizontal direction, finishing the operation by stitching the skin and mucous membrane together. Or an elastic ligature may be introduced through the cheek at the required distance from the angle, brought out at the corner of the mouth, and tied. During the slow process of cutting through, the track of the wound becomes covered with epithelia, and reunion is prevented.

In the selection of any of the plastic methods heretofore given, the surgeon must be guided by the requirements of each case. It is a wise precaution to make a guarded prognosis, for, no matter how successful from the surgical standpoint, the operations do not, in the majority of instances, secure the expected improvement in the personal appearance of the patient.

PAROTID GLAND AND DUCT.

Salivary fistula may be confined to the main parotid duct in any part of its course, or to the primary ducts within the substance of the gland.

It may result from a wound or any inflammatory and necrotic process due to obstruction from salivary calculi or other disease of the parotid and buccal regions. Exploration of the duct with a delicate blunt probe is accomplished thus: Find the outlet at the papilla on the mucous membrane of the buccal cavity near the junction of the second bicuspid

and first molar teeth of the upper jaw. Introduce the probe, carrying it at first slightly outward. When it is arrested by the natural curve of the duct, pull the corner of the mouth and the cheek directly outward, thus straightening the tube. The general direction is backward, toward the auditory meatus.

The diagnosis of salivary fistula or of obstructed duct may be determined as follows: By means of absorbent cotton or lint remove all moisture from the mucous surface where the papilla is situated, and place some sapid or acid substance on the tongue. If there is no obstruction, the flow of saliva is immediately perceived. In case of fistula the secretion will flow out through it. Calculi of Steno's duct, or of any of the salivary ducts, should be removed by dilatation, if this is possible, and if not, by incision.

In the treatment of salivary fistula the object aimed at is to stop the flow of saliva on the outside and turn it into the mouth. Arm a probe with a silk seton and carry it through the fistula into the buccal cavity, bring the thread out through the mouth, and tie the two ends together. In about ten days the flow into the mouth will be fully established, when the seton should be removed and the outer opening closed by a compress until cicatrization occurs. It may, at times, be necessary to freshen the edges and bring them together with a suture.

Riberi operated successfully by cutting through the integument down upon the duct behind the opening, passing a ligature around it, and carrying this and the end of the duct into the buccal cavity where it was left open. The wound in the integument was immediately sutured.

In a case recently treated by the author, the following method was successful in restoring the integrity of the flow of saliva into the mouth: A boy twelve years old had scarlatina at seven, which was followed by obstruction of the left duct of Steno. A fistulous opening occurred spontaneously behind the ear. Cutting down through the cheek in the anatomical line of the duct, this was discovered to be obliterated for the last half-inch of its course. It was divided just posterior to the limit of occlusion, and an incision opposite this point made directly through into the buccal cavity. Two fine silk threads were inserted in the wall of the duct at the end, and these sutures were stitched to the mucous membrane of the cheek at the edges of the incision just made. The wound in the integument of the face was closed, excepting the anterior angle, where a small rubber tube was inserted. This tube projected into the cavity of the mouth by the side of the new opening for the duct. This was done to form a fistula in case the wound in the mucous membrane should close and obstruct the duct. A compress was placed and worn on the fistulous opening behind the ear. The tube was removed in five weeks, and the external outlet closed by silk sutures. At this time, also, the old fistulous opening was closed. The saliva up to this time flowed about equally out of the hole behind the ear and the opening in front. After this it came only through the end of the duct in the mouth.

Fistula of the primary ducts within the substance of the gland may require the forced atrophy or ablation of this organ. An effort at occlusion should be made by direct pressure upon the abnormal opening, or by careful dissection in the line of the fistula, when this can be safely done. When, however, the fistulous tract is deeply situated, it will be found almost impossible to effect a cure without serious risk of interfering with the integrity of the seventh nerve, the motor filaments of which are in intimate relation with this gland. Removal of the parotid gland, for any cause, becomes a serious operation, since it necessarily implies paralysis, more or less complete, of the muscles of the face; when it is entertained, the patient should be thoroughly acquainted with the prospect of paralysis which will follow. In non-malignant cases the greatest care should be exercised in avoiding division of the filaments of the facial nerve. Even in the arrest of hæmorrhage, as the operation proceeds, the application of the forceps should be carefully made, so that the branches of the nerve may not be injured or included in the ligature. When the seat of malignant disease, a thorough ablation is essential, and the nerve is necessarily sacrificed.

Tumors of the Parotid.—About 30 per cent of all neoplasms of this organ are enchondromata, 25 carcinomata, while the remaining 45 per cent are about equally divided between sarcomata, fibromata, myxomata, and cystomata. Simple hypertrophy is rare, although hyperplasia of the gland-tissue occurs in a varying degree in the progress of most of the neoplasms which attack this organ.

Tumor of the parotid is rare prior to the thirtieth year of life, being met with chiefly between the thirtieth and fiftieth years. As to the period when the various forms appear, it may be said that carcinoma occurs generally after the fiftieth year, while enchondroma, sarcoma, myxoma, and fibroma develop in the earlier decades. Sarcoma is apt to develop in childhood or early adult life.

Diagnosis.—All forms of tumor of the parotid, as a rule, develop slowly. In the earlier stages of their development they are movable within the limited area of mobility of the gland. This is true of both the benign and malignant growths. Later, even the benign neoplasms may become fastened between the temporal bone and fascia and the ramus of the jaw, but not to the overlying integument. The malignant growths are more rapid in development, and earlier in their history are bound down to the surrounding tissues, may become adherent to the integument, and produce great pain and disturbance by reason of pressure upon the nerves and vessels with which the gland is in close relation.

The cartilage tumors are nodular, hard, and slightly elastic to direct pressure. Cancer is also nodular at times, but not so hard as enchondroma. Cancer comes, as a rule, after the forty-fifth to fiftieth year, and the other neoplasms before this period. The lymphatic glands are involved in cancer, and rarely enlarged in any other form of neoplasm. Sarcoma occurs earliest of all. Cysts are elastic, may present fluctuation, while the exact character of this variety may be determined by

exploration with the aspirator. If of great importance in determining the plan of treatment to be pursued, a section of the diseased organ sufficiently large for microscopic examination should be removed; in this way a positive diagnosis is assured.

Removal of the parotid gland is one of the most difficult operations in surgery. In many cases of tumor of this organ in which the neoplasm is developed at the expense of the under portion of the gland, the internal jugular vein, internal carotid artery, and the important nerves and ganglia situated here become so involved that complete extirpation is impossible during life. This condition was found to exist in a case in which I removed all of the organ anterior to the deep vessels. Having at first tied the external carotid artery, the dissection was comparatively bloodless. When the tumor is of small size, it may be entirely removed. Section of the various divisions of the facial nerve or of the main trunk is almost inevitable. In a patient in whom both parotids were removed by the author for large carcinomata, with an interval of about six weeks, both external carotids were tied. The facial paralysis was at first complete, but after two years there was marked improvement in motion of the face-muscles. Recurrence took place after three years on both sides, and further operation was not advised. If the external carotid is first secured, it may be avoided by a careful dissection, provided that the tumor is of moderate size.

Operation.—Make a crucial incision over the mass, the perpendicular cut being in the line of the external carotid artery. Turn the flaps back from the anterior aspect of the tumor, and approach its deeper portions from below in the line of the vessels. As soon as the external carotid can be exposed, it should be secured with a catgut ligature. All bleeding should be arrested as the operation proceeds. In lifting the under surface of the tumor from its bed, the operator should keep close to the mass, using a dull instrument for fear of wounding the internal jugular vein and other important vessels or nerves. The blunt scissors curved on the flat, the handle of the scalpel, or the thumb and fingernail may be utilized for this purpose. The facial nerve and its branches which run through the neoplasm should be saved, if possible. As before stated, if the tumor is extensive, this is scarcely possible on account of the great length of time it would require. If, in the course of the operation, it is discovered that the neoplasm dips down beneath the jaw and styloid process, and surrounds the vessels and nerves, its complete extirpation is impossible. As much of the mass as can be lifted should now be transfixed near the middle with a double elastic ligature, tied, and the part external to the ligature cut away.

The *prognosis* in cancer and sarcoma of the parotid is always grave, even after removal. The anatomical relations of this organ are such that a wide and complete extirpation, such as is readily made in tumors of the breast, is impossible. The question will naturally arise, Under what conditions should the operation be advised and undertaken? In malignant disease the propriety of extirpation is very questionable, and should only be undertaken after a clear explanation of the dangers of

the operation and the probabilities of recurrence. In benign tumors which show a tendency to increase, operation may be advised, especially if the tumor is still of small size. It is always important to attempt the removal of the neoplasm early in its history. Facial paralysis generally follows the operation, and is more or less permanent.

PAROTITIS—"MUMPS."

Inflammation of the parotid gland occurs chiefly in children, but is occasionally met with in adults. In males it is, at times, accompanied by orchitis, and in females the mammary glands and ovaries are affected. The symptoms are pain and swelling of the gland, difficult deglutition, and slight febrile movement. The prognosis is favorable, the disease yielding to warm applications, quiet, and the judicious employment of laxatives. In rare instances atrophy of the testicle has been known to follow the inflammation of this organ, occurring as a complication of "*mumps*."

Abscess may occur after an acute inflammation of the parotid from traumatism, or as a complication of the eruptive or continued fevers. Under these last conditions the prognosis is always grave. The presence of pus is recognized by the intense character of the pain experienced, the febrile movement, the doughy condition of the skin and areolar tissue in front of the organ, and by aspiration. The abscess should be evacuated by aspiration, puncture, or incision.

SUBMAXILLARY GLAND.

This organ may become inflamed and suppurate, or be the seat of neoplasms, yet not so frequently brought to the attention of the surgeon as the parotid. Its removal is a simple procedure, and may be accomplished by a crescentic incision commencing at the angle of the jaw, dipping three quarters of an inch toward the hyoid bone, and ending one and a half inches in front of the angle at the lower border of the jaw. The flap of skin should be raised with the platysma muscle as far as the jaw, and the deep cervical fascia divided. The gland rests beneath and internal to the bone and upon the mylohyoid and hyoglossus muscles. The submaxillary branch of the facial artery will be divided.

THE JAWS.

Superior Maxilla.—Periostitis, ostitis, and abscess of the upper jaw may be caused by caries of the teeth, disease of the upper jaw within the antrum, or pathological changes within the bone proper. Ostitis of the maxilla is more apt to occur in children, and especially in those of a strumous diathesis. Phosphorus-poisoning and the syphilitic dyscrasia lead also to inflammation and caries of this bone.

The *symptoms* of ostitis and abscess here do not differ from those

already given in the general chapter on bone diseases. Pain is, perhaps, more acute in otitis within the distribution of the trifacial nerve. It is elicited by direct pressure, and, when the process is associated with a carious tooth or its roots, the exact location may be determined by striking the tooth sharply with a metallic substance.

The *treatment* is to relieve the tension by puncture or incision, or by extraction of one or more teeth in case they are connected with the diseased surface. The removal of dead bone is demanded, although it is wise not to operate too early. When exfoliation has occurred, the operation is much simplified. If free drainage is secured by early incision, the arrest of the spread of the disease is practically insured. *Chronic alveolar abscess* is often cured by extraction of an offending tooth. When this fails, the diseased surface should be exposed by incision, and a thorough removal accomplished. When possible, all sequestra should be removed from within the oval cavity in order to avoid a scar upon the face.

Syphilitic otitis, and that variety which occurs from absorption of the fumes of phosphorus, require specific constitutional treatment as well as operative interference.

Abscess of the antrum of Highmore may occur as the result of an inflammatory process in the mucous membrane lining this cavity, or in connection with otitis of the upper jaw, or from the presence of foreign bodies or neoplasms within its cavity. The chief symptom is pain, referred to the region of the antrum. The febrile movement of acute abscess is usually present. The pus may force its way through the opening into the meatus, or cause necrosis in the bone and discharge in any direction.

Treatment.—*Free drainage* must be established in all cases. The extraction of the first or second molar and the application of a drill to enlarge the opening may suffice. If necessary, a portion of the alveolar process should be gnawed away with the forceps. In extreme cases an incision should be made through the skin just above the situation of the first molar tooth, and a thorough opening made with a trephine or gouge. It is important to explore the cavity with the finger in order to determine the presence of dead bone or any offending substance. Free drainage must be maintained until recovery is secured. In a case which came under my observation, I found the cause of an abscess of thirteen years' duration to be a supernumerary molar tooth which was lying loose in the antrum.

The same operation will be most essential in those cases of *hydrops antri*, or retention of fluid, and in the cure of *cysts* of this cavity.

Among the many other diseases to which the antrum is subject are myxoma, fibroma, papilloma, sarcoma, carcinoma, and various hyperostoses. The differentiation of these growths is extremely difficult, and, when doubt exists as to the character of the neoplasm, an exploratory operation for the purpose of positive diagnosis should be made. This is done by applying the trephine as just given.

Non-malignant new formations may be removed by an osteoplastic

operation, while malignant growths often require the sacrifice of the entire upper jaw.

Osteoplastic Operation for Removal of Benign Tumor from the Antrum of Highmore—Langenbeck's Procedure.—From the junction of the wing of the nose with the lip an incision is carried outward parallel with the level of the teeth, and is made to divide the soft parts to the bone as far as the center of the malar prominence, where it is curved upward and inward, ending a quarter of an inch below the outer angle of the orbit. This is joined by a second incision, which is commenced about a quarter of an inch below the level of the orbit at the suture between the nasal bone and the nasal process of the superior maxilla, and is carried outward parallel with the lower margin of the orbital cavity.

The tissues must not be lifted from the periosteum within this curved incision. The hæmorrhage, which is always sharp, being arrested, with a blunt instrument carefully lift the eye from the floor of the orbital cavity until the finger can be carried into the anterior portion of the speno-maxillary fissure. With this as a guide, insert a small, strong key-hole saw into the fissure and divide the malar bone outward in the line of the incision (see Fig. 498). In moving the saw, keep the blade perpendicular, and limit the motion so that the point may not penetrate the temporal fossa and wound the vessels. Next insert the saw in the lower horizontal incision and divide the superior maxilla into the cavity of the antrum and nose. In sawing on this line, keep the mouth open and the finger inserted behind the palate to

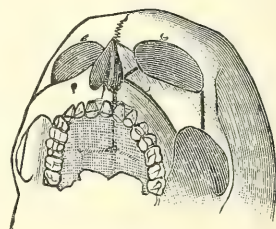


FIG. 498.

prevent the point of the instrument from penetrating too far back. The nasal process of the superior maxilla is now divided with a chisel at a point half way between the inferior orbital foramen and the inner angle of the orbit. The cutting-edge of the chisel should be directed slightly outward for fear of injuring the lachrymo-nasal duct. The lines of section in the bones are shown in Fig. 498. The point of exit of the infra-orbital nerve should be found and this branch of the trifacial divided at the foramen. An elevator is now placed in the fissure made by the saw through the malar bone and the mass dislocated inward, hinging on the undivided soft tissues. This force fractures the floor of the orbit and opens widely the antrum of Highmore. When the operation is finished, the bone is neatly replaced and the edges of the wound accurately adjusted. Drainage may be secured through the wound, or a hole may be drilled through the edge of the alveolus. This same operation is advisable in section of the second branch of the fifth nerve and extirpation of Meckel's ganglion. When the ganglion is the objective point, it may be found by following the superior maxillary branch of the fifth nerve along the floor of the orbit to the location of the ganglion on the anterior surface of the pterygoid process of the sphenoid bone. The posterior shell of the antrum must be broken through in order to enter the fossa.

OPERATION FOR REMOVAL OF THE UPPER JAW.

A quarter of an inch below the inner canthus of the eye commence an incision and carry it downward along the naso-maxillary groove, curving in the contour of the ala nasi, then horizontally beneath the ala to the median line of the lip, where it turns directly downward, dividing the lip in the median fissure. From the point of beginning carry a second incision one fourth of an inch below and parallel with the inferior margin of the orbit out to the prominence of the malar bone (Fig. 499). Dissect up the soft tissues of the cheek, and turn the flap downward and outward. If the disease is so extensive that the incision does not expose the parts sufficiently, a horizontal cut may be made outward from the angle of the mouth.



FIG. 499.—(After Roser.)

The bone may be divided by the saw inserted in the spheno-maxillary fissure, as in the preceding operation, cutting through the nasal process with a chisel. Extract an incisor tooth, and with large, strong bone-cutting forceps divide the alveolus and the palate-process by inserting one blade in the nose and the other in the mouth. These sections being accomplished, avulsion is made by means of elevator and forceps. The operation is completed by the closure

of the wounds with fine silk sutures. If, in section of the palate, the Paquelin cautery is used, hæmorrhage will be less annoying.

Preliminary tracheotomy and plugging the pharynx and larynx with sponges in order to prevent hæmorrhage into the trachea is rarely, if ever, required. If such precaution is considered necessary, an ordinary trachea-tube will suffice.*

For simple osteoma, or for necrosis of the upper jaw, this bone may be removed without incision in the cheek. In one case I removed the left superior maxilla, except the orbital plate entering from within the mouth. In necrosis, when the sub-periosteal operation is permissible, the procedure is devoid of great difficulty.

Neurectomy.—Exsection of a portion of the second division of the fifth nerve may be made at three points—at its exit from the infra-orbital canal, within the canal, or at the foramen rotundum. In this last operation the spheno-maxillary ganglion is also extirpated. If the cause of the neuralgia is peripheral, make an incision about one inch long, parallel with and half an inch below the lower margin of the orbital cavity.

* Trendelenburg's trachea-tube and tampon is such a complicated apparatus that, when possible, it should be dispensed with. It is more to be commended in laryngectomy than in any other operation about the mouth or pharynx. The mechanism of this tube, and the method of using it, are given on page 505.

The center of this cut should be over the infra-orbital foramen, which is just half way between the outer and inner angle of the orbit. The nerve may be excised here or stretched by pulling on the central end. It may be reached at a point considerably behind this by trephining the antrum. Make a curved incision, beginning about half an inch below the inner canthus, passing downward to the level of the end of the nose, thence upward to a point about half an inch below the outer canthus. Dissect this flap upward, apply the trephine so that its upper edge will cut just below the foramen and enter the antrum. The nerve runs directly backward, and may be followed by keeping it as a guide and breaking off the lower shell of the canal as far back as the posterior wall of the antrum, where it is divided.

The operation for the removal of Meckel's ganglion has already been given.

THE LOWER JAW.

Ostitis of the inferior maxilla is of frequent occurrence.

Various forms of fibroma, fibro-myxoma, encysted fibroma, enchondroma, and, in rare instances, angioma, have been observed in this bone, but of new formations sarcoma is most frequent. Cystic formations resulting from failure of normal development of the teeth are not uncommon.

Ostitis occurs most frequently in children. It may be an expression of a dyscrasia, or an accident of nutrition, or be secondary to disease of the teeth, or the inhalation of the fumes of phosphorus. While this process may be located at any portion of the jaw, the neighborhood of the angle seems to be most frequently affected.

The *symptoms* are pain, followed by swelling of the jaw and contiguous soft tissues, ending in abscess, which, if left alone, eventually opens and discharges.

Treatment.—As soon as the character of the disease is evident, an incision or puncture should be made through the overlying tissues and periosteum, in order to give free exit to pus and loose particles of bone. The operation for removal of the dead bone may be delayed for several weeks until exfoliation has taken place. Incision should always be made below the line of the jaw if this is feasible, so that the resulting scar will be less apparent. Usually by following the track of the abscess it will lead directly to the dead bone surrounded by an *involucrum*. This often requires to be chiseled or forced open to allow the extraction of the *sequestrum*, which may be readily removed with ordinary bone- or dressing-forceps. The cavity should be well scraped with a Volkmann's spoon, a drainage-tube left in, and the edges of the wound adjusted with silk sutures. The deformity due to the rich deposit of callus disappears with the absorption of this material. When all or any portion of the entire thickness of the jaw requires removal for *ostitis*, the sub-periosteal operation is imperative, since by this means alone is it possible to have a reproduction of the bone. The method of procedure, when the

bone is the seat of a neoplasm, depends upon the character of the new formation. If there is any doubt as to the benign character of the tumor, a piece should be removed and examined microscopically before operation.

In sarcoma, cancer, and enchondroma of the jaw, the sub-periosteal operation can not be performed, since the sound tissues must be included in the ablation, in order to secure immunity from recurrence. Enchondroma, though not intrinsically malignant, tends to recur if not freely excised.

Operation.—When it is safe and possible, the diseased portion of the lower jaw should be removed without breaking the continuity of the bone. If a portion of the entire thickness of the organ is removed, the tendency to displacement is inward, thereby interfering with mastication. The entire thickness of the jaw should be included in exsection for malignant neoplasm.

Partial resection of the upper or alveolar portion of the body of the lower jaw in front may be accomplished, in mild cases, from within the buccal cavity. When the disease is extensive, proceed as follows: At a distance from the alveolar margin sufficient to permit the exposure of all diseased bone make an incision parallel with the margin of the lip, and also parallel with the inferior border of the jaw. This incision should extend in depth to the bone and in length beyond the area of disease. The bone is next divided by the chisel and mallet, the key-hole saw, or removed in small pieces by the rongeur, in the line indicated in Fig. 500. The operation is concluded by bringing the flap back into place with silk sutures.

When the disease is more general, necessitating a removal of the

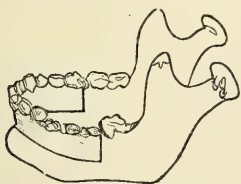


FIG. 500.—Line of section in removing the alveolus of the lower jaw. (After Roser.)

entire thickness of the bone, a more extensive incision is required. The lip is divided in the median line down to the under surface of the chin, and thence along the lower border of the jaw (Fig. 501).

When the ramus and articular process require removal, the line of incision may be carried to the angle and up the ramus. In disarticulation, while the incision through the skin can be safely carried as high as the zygoma, the incision down to the bone should not extend farther than on a level with the tip of

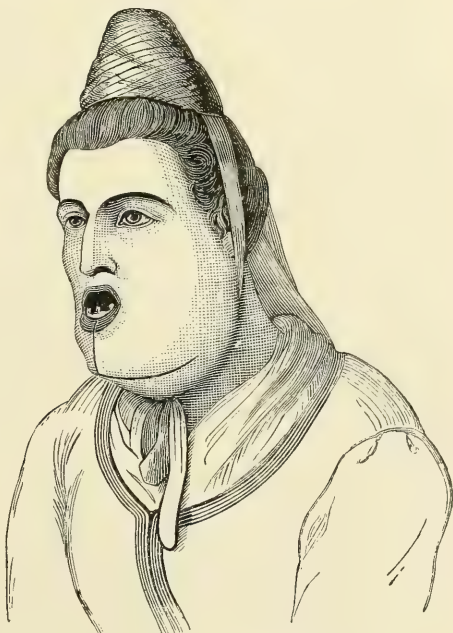


FIG. 501.—(After Roser.)

the mastoid process, for fear of dividing the facial nerve. From this point the coracoid process and the articulation may be reached by working up close to the surface of the bone, beneath the periosteum (if the disease is not malignant). The inferior dental artery should be secured when divided, and the other branches of the internal maxillary avoided. The external carotid is left behind the ramus. In the act of disarticulation it must be remembered that the internal carotid artery and internal jugular vein enter the cranium just behind the vaginal process of the temporal bone, which forms the posterior wall of the articulation. As this process is only about one eighth of an inch thick, the walls of the vein and artery are in dangerous proximity to the attachment of the capsule. The anterior and outer wall of the capsule should be first separated, and then, while strong outward traction is made on the ramus, the inner wall of the capsule should be divided as close to the neck of the bone as possible. If ablation of the entire bone is demanded, this operation is repeated for the opposite side. It must not be forgotten that when the attachments of the hyoid muscles to the jaw are severed, the action of the remaining muscles, together with gravity, aid in carrying the base of the tongue backward upon the glottis, producing dangerous if not fatal asphyxia. The precaution of passing a thread through the tip of the tongue should not be overlooked.

Resection of the inferior dental nerve may be performed at the mental foramen, or at the commencement of the dental canal at the angle of the jaw.

The *mental foramen* is situated about half way between the inferior border of the bone and the alveolar border or necks of the teeth. A line let fall perpendicularly from the interspace between the two bicuspid teeth of the lower jaw will pass over the opening. A curved or crucial incision will expose the nerve at this point.

The foramen of entrance of the inferior dental nerve is very near the center of the quadrilateral formed by the anterior and posterior margins of the ramus, the lower horizontal border of the angle, and an imaginary horizontal line on a level with the lowest portion of the sigmoid notch.

An incision about two inches long and slightly curved is made so that its middle will be about the center of the parallelogram above described. The trephine should be applied over the center of the quadrilateral. The best indication of having reached the nerve is the bleeding through the track of the trephine when it passes into the cancellous tissue of the jaw. This comes from the wounded inferior dental vessels. An elevator placed in the cut will now lift the button of bone, and the nerve is exposed. The entire portion in the limit of the trephine should be excised. Temporary relief is almost invariably secured, although a recurrence of pain is not uncommon after several months.

Anchylosis.—Motion of the jaw may be limited or entirely prevented by muscular rigidity, cicatricial contractions, or true anchylosis at the temporo-maxillary articulation.

The area of motion in partial anchylosis may be increased by forcible separation of the lower from the upper jaw by the apparatus shown in

Fig. 37. This should be repeated at frequent intervals, gradually increasing the pressure. In severe cases a false joint may be successfully established by section of the bone anterior to the point of fixation, usually at or above the angle. Care must be taken to make frequent passive motion in order to prevent union of the divided ends.

THE TEETH.

Extraction.—Dental forceps should be of different patterns, the jaws bent at various angles to the shaft, and the handles large enough to be grasped firmly and securely by the operator.

The gum immediately around the neck of the tooth should be freely incised with a lancet, since if this precaution is not taken it may

be unnecessarily torn away with the tooth. The injection of cocaine around the tooth will render the cutting painless. The jaws of the forceps are applied on either side of the neck, and forced down toward the root until they grasp the tooth firmly at the margin of its alveolar insertion. The

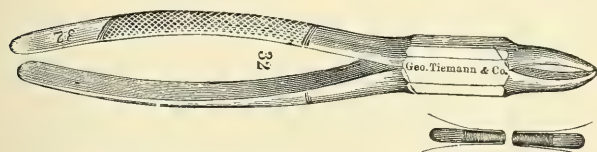


FIG. 502.—Incisor, straight root.




FIG. 503.—Incisor, half-curved root.

direction of traction is determined by the normal direction of the axis of the tooth. In extracting the incisors and canine teeth, the forceps represented in Figs. 502 and 503 are applied as described above, and, when firmly fixed, a slight forward and backward movement, with limited rotation, will loosen the root, while traction should at the same time be made in a direction upward and slightly forward for the lower jaw, and downward for the teeth of the upper row. For the bicuspid and molars, the instruments shown in Figs. 504, 505, and 506 are preferable.

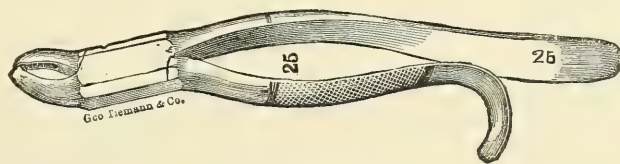


FIG. 504.—Wolverton's upper bicuspid.

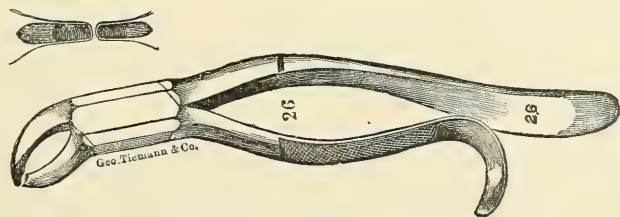


FIG. 505.—Wolverton's lower bicuspid.

The bicuspid and molars may be loosened by lateral motion or rock-

ing. The direction of traction is slightly inward for the lower teeth, and slightly outward for those of the upper jaw.

Fracture of a root or shelving of the alveolus will occur at times in the most skillful hands, and abscess and necrosis may ensue. Fragments of the teeth should be gouged out by using an elevator. Hæmorrhage, usually insignificant, may at times be dangerous, death having occurred from this cause in one or more instances. Cold

or heat, or packing the cavity with a compress of cotton or lint, will effect its arrest. In extreme cases the compress may be saturated with Monsel's solution, or alum, or any astringent, and left in for forty-eight hours. Anæsthetics may be employed with great safety in dental surgery. Nitrous oxide is of every-day use, and ether is both safe and effective. Chloroform is not to be employed unless, after full information, the patient relieves the operator of all responsibility. When ether or chloroform are administered, the patient should be placed in the recumbent posture.

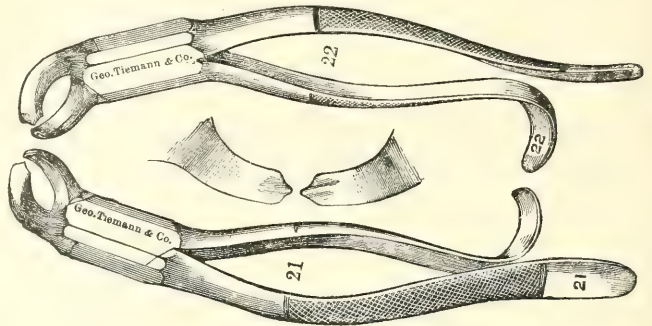


FIG. 506.—Harris's lower molars, for the two sides.

THE PALATE.

Uvula.—On account of elongation or hypertrophy of this portion of the soft palate, its excision is at times required. It may be accomplished by taking hold of the tip with a mouse-tooth forceps, and with a long curved scissors removing as much as required. Complete local anæsthesia may be obtained by mopping the uvula with a small quantity of a 4-per-cent solution of cocaine hydrochlorate at intervals of three minutes for fifteen minutes before the operation.

Tumors of the palate, abscess, necrosis, and ulceration are not infrequent, and demand the same treatment as in other portions of the body.

Cleft palate may be confined to the soft palate; it may include with this a portion or all of the hard palate and alveolus, or it may be confined to the hard palate alone. It is usually congenital, although it may be acquired, as in the perforations which ensue as a result of syphilitic ulceration and necrosis.

The cleft in the hard palate is most often single, the vomer being attached to one side of the palate-process of the superior maxilla (Fig. 460). Occasionally it is double, there being a central piece—the vomer—which runs forward and is attached to the pre-maxillary bone (Fig. 461).

Treatment.—When a hare-lip exists as a complication of cleft palate, the operation on the lip should first be made in order to enable the child

to swallow sufficient nourishment, and to gain the additional advantage of pressure of the united lip, which aids in approximation of the edges of the cleft in the hard palate.

The most suitable age for operating is within the first three years of life, if the infant is sufficiently strong and well nourished to endure so formidable a procedure. One of the most discouraging features of this operation, if postponed until later, is that, owing to the shortening and failure of development in the palate muscles, it is practically impossible to acquire a natural articulation, even after the fissure has been successfully closed.

When the cleft is general—that is, entirely through the soft and hard palate—it is advisable to close the soft portion first and finish the remainder in one or more sittings, as may be found necessary. In children, chloroform should be used; in adults, a sufficient degree of local anæsthesia may be obtained by the employment of hydrochlorate of cocaine to enable the operation to be done with the very valuable aid of the patient.

In a case operated upon by myself, the parts to be incised were brushed over with a 4-per-cent solution of cocaine at intervals of two or three minutes for half an hour preceding, and about every five minutes during, the operation. The anæsthesia was perfectly satisfactory, and complete union resulted after the first operation.

Operation of Staphylorrhaphy.—The first object in this operation is to keep the mouth of the patient widely opened. For this purpose Goodwillie's gag is the best of all instruments (Figs. 35 and 36). The

tongue may be depressed with a spatula if necessary. If an anæsthetic is employed, the condition of narcosis should not be profound, for, if laryngeal sensibility is completely lost, blood or mucus may pass into the larynx and trachea instead of being swallowed. The patient's head being firmly held by an assistant, the soft palate is seized by a mouse-tooth fixation-forceps, and with a blunt-pointed, long narrow knife (Fig. 56) a strip, about one eighth to one sixteenth of an inch wide, is removed from the edges of the fissure, in its entire length

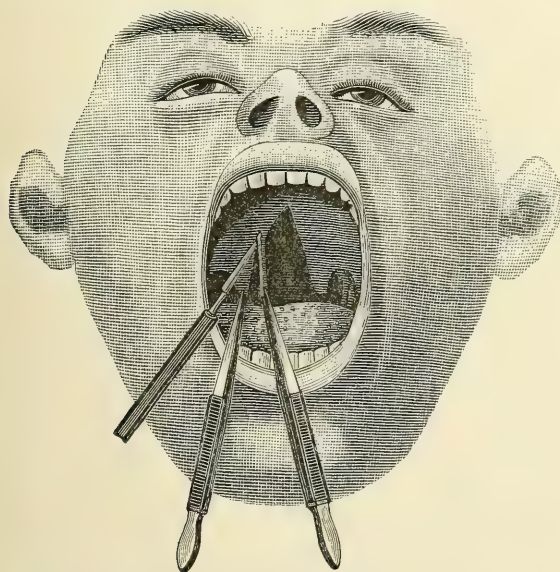


FIG. 507.—Freshening the margin of the cleft in the operation of staphylorrhaphy. (After Malgaigne.)

(Fig. 507). In order to steady the palate, a silk thread may be inserted on either angle, or a second forceps applied, although this is not always

necessary. The entire margin of the cleft must be carefully freshened, for if any point is left uncut union will fail. The bleeding is next arrested by small sponges, on staffs (Fig. 83), dipped in ice-water and squeezed dry.

In uniting the freshened edges, Dr. Goodwillie's hollow needle (Fig.

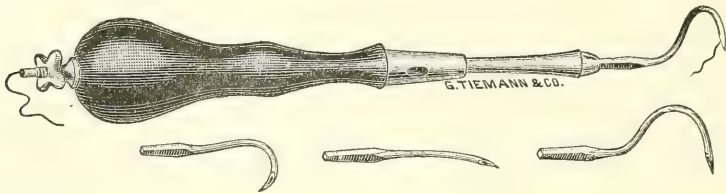


FIG. 508.—Goodwillie's hollow needle for silk-worm gut suture in the closure of cleft palate.

508) is the best instrument, while the silk-worm gut suture leaves nothing to be desired in this operation.

To the shaft adjust one of the needles which, from its shape, is best adapted to the peculiar form of the fissure to be closed, and push one of the silk-worm bristles through from the butt to the point until it projects, and then draw it back one eighth of an inch within the eye of the needle. Seize the edge of the flap with the forceps, and at a point between one eighth and one fourth of an inch from the freshened margin of the fissure insert the needle from before backward, through the side corresponding to the operator's right hand (left side of the patient), and then through the opposite side, at a like point from behind forward. In order to facilitate the passage of the needle, the flap must be held steadily with the forceps. As soon as the needle has transfixed the second flap and the eye is visible, the operator pushes on the bristle at the butt of the needle-holder, causing the other end to come out of the eye of the needle, when it is seized with the forceps and drawn forward. Holding this end firmly, the needle is withdrawn, leaving the suture in position. The ends of this are now fastened together with a perforated shot, and held aside until all are inserted. The sutures should be about one fourth of an inch apart. When the last one is inserted, the operator ties one after another from above downward. The first knot is single, and this is run down tight and repeated with two additional knots to secure it. The ends are then cut off, one fourth of an inch from the knot. This material ties easily, does not slip or break, is not absorbable, and holds its place until removed.

After the sutures are tied it will be observed that (as a result of the fissure, the levator palati and palato-pharyngeus muscles being shortened) there is now marked tension of the soft palate, which, if not relieved, will pull upon the sutures and cause separation of the edges of the wound. To obviate this, a sharp knife (Fig. 55) is thrust through the palate, about the center of the posterior margin of the horizontal plate of the palate-bone of that side, and an incision made, in a direction downward and outward, to within from one fourth to one half of an inch from the free border of the palate, near the hamular process, as in

Fig. 509. This incision divides the levator palati of either side. The anterior and posterior pillars of the fauces should also be snipped with dull-pointed scissors. All of these wounds close later by granulation. It is important to keep the muscles of this region at rest for a week after the operation.

When the cleft extends into the hard palate, as shown in Fig. 510, the fissure may be closed by sliding the membrane lining the vault of the palate.

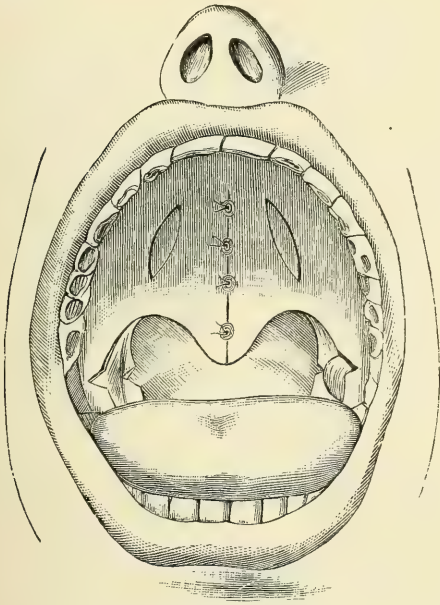


FIG. 509.—(After Agnew.)

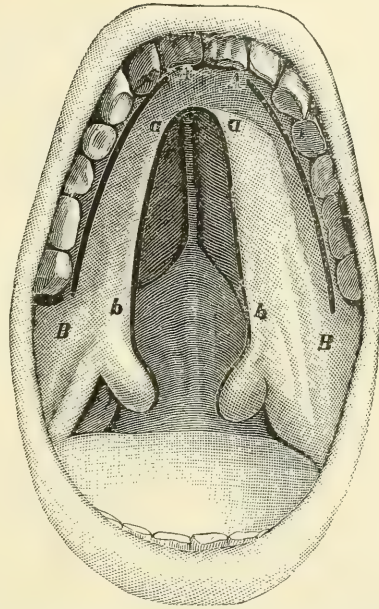


FIG. 510.—Incisions in sliding the periosteum for closure of the bony cleft. (Modified from Koenig.)

The edges of the fissured soft palate are freshened, as in the preceding operation. Along the edges of the bony fissure an incision (*a b*, Fig. 510) is made, with a knife shaped like a gum-lancet (Fig. 57), and, by the aid of curved elevators (Fig. 71), the membrane lining the bony palate is carefully lifted with the periosteum. Another incision is now made on either side of the fissure, close to and parallel with the junction of the alveolus with the palate processes, *A B*, through which the elevator is again introduced, and the periosteum lifted until the whole flap included between *B A* and the edges of the fissure *a b* is detached. If severe hæmorrhage follows the incision, the wound should be temporarily packed with lint, or pressure with the finger may arrest the bleeding.

The flaps are now ready for sliding, and the sutures are introduced along the freshened edges, as in the preceding operation.

When the cleft extends still farther forward through the alveolus, and the fissure is wide, it will become necessary to carry the palate processes toward the median line by an osteoplastic operation. In this procedure no effort is made at lifting the periosteum, and it is better to attempt the approximation of only one portion of the cleft at a sitting. In order to secure all the nutrition possible, the soft palate should be

first united. The anterior or posterior portion of the bony fissure may be closed at the next operation, as follows: Freshen the edges of the soft parts along the fissure. Drill two holes through the bony palate of either side, one fourth of an inch distant from the edges to be approximated, and insert two strong silver wires, as shown in Fig. 511. On either side, close to and parallel with the alveolus, make two incisions through to the bone, as at *A B* (Fig. 510), and drill with an awl a series of holes in the track of these incisions. A few strokes of a small chisel will now break the palate processes in the line of the holes, when, by twisting the wires, the loosened plates will be approximated in the median line. After union has occurred in this portion of the cleft, the operation may be completed in the anterior portion, by drilling the palate and alveolus, and breaking this last through from the front with a chisel, approximating the sides as above.

Perforations of the palate are treated practically in the same way as congenital cleft, by freshening the edges, and, if necessary, sliding the periosteum, as above given.

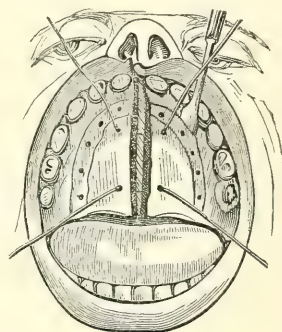


FIG. 511.—(After Agnew.)

THE TONGUE AND BUCCAL CAVITY.

Wounds of the tongue bleed profusely, especially if the larger vessels along its under surface are divided. The arrest of hæmorrhage is easily and safely accomplished by introducing the index-finger well back over the dorsum to the root of the tongue, and bringing the organ well forward and forcibly compressing it against the symphysis menti. The tip of the organ should be turned upward, and the forceps applied at the bleeding points. In the substance of the tongue the vessels are also readily secured in the same manner. Should any difficulty arise, a silk thread may be carried around the bleeding vessel by means of a curved needle, or it may be transfixed with a tenaculum and the thread tied around the hook.

Glossitis—Hemiglossitis.—Inflammation of the tongue may result from the same causes and assume all the phases of inflammation common to the soft tissues in other portions of the body. It may be acute or chronic, ending in ulceration or hypertrophy. The process may begin superficially, as after the ingestion of some irritating substance, or it may commence in the deeper portions of the organ as a diffuse phlegmonous process. In some instances only one lateral half of the organ is involved.

Treatment.—Inflammation of the tongue from any cause should be closely watched, on account of the danger of asphyxia from rapid enlargement of this organ. In this emergency tracheotomy should be performed. If abscess forms, incision or puncture is demanded. Scarifi-

eration may be required in rapid enlargement of this organ from engorgement of the vessels.

Hypertrophy of the tongue is both congenital and acquired. It may exist in adult life, although it is in general a condition of childhood. The enlargement is due to hypertrophy of the lymphatic plexuses of this organ and to a general hyperplasia of the connective-tissue elements. The muscular substance undergoes granular metamorphosis. The cause of this disease is not understood. The organ may become so large that it protrudes from the mouth, pushes the teeth out of their normal position, and interferes with deglutition and respiration to such an extent that its partial or complete removal becomes necessary. Cystic tumors of the tongue may be mistaken for hypertrophy. A diagnosis may be made by exploration with a good-sized aspirator-needle.

In mild cases deligation of the lingual artery of one or both sides may be done, and this may be followed by excision of a portion of the organ. The tip may be amputated, or a triangular section may be removed from the central portion, the sides being brought together by sutures.

Atrophy is a rare disease, and is due to diminution of the blood-supply, or to lesions of the trophic nerves of this organ.

Cystic tumors of the tongue may be caused by closure of the outlet to any portion of the follicular apparatus (retention-cysts), or less frequently by the lodgment in this organ of a parasite, the *cysticercus*.

The *diagnosis* is made positive by exploration. The *treatment* required is excision of the sac with the scissors, or the less bloody operation of opening it with the Paquelin cautery, burning the lining membrane thoroughly, and packing the cavity with iodoformized gauze. The precaution should be taken to make the packing from one piece of gauze, and of securing it by a thread attached outside, in order to prevent its accidental escape backward.

Angioma of the tongue is rare. When present, the treatment is removal by the ligature, or by injection with 50-per-cent carbolic-acid solution.

Abscess of the tongue should be treated by aspiration, and hyperdistention of the sac with 1-to-3000 sublimate solution. If this does not succeed, an incision should be made and drainage secured.

Ulcers of the tongue appear as a symptom of various conditions. They occur in syphilis with great frequency. They may occur as a result of general catarrh of the pharynx and mouth, or as a result of any violence. If an ulcer exists as an expression of a dyscrasia, the treatment must be chiefly constitutional. The local treatment consists in cleanliness and the application of nitrate of silver, or other stimulating remedies.

The tongue is at times the seat of *papilloma*, *lipoma*, *fibroma*, *sarcoma*, and one or two instances of *enchondroma* in this organ are reported. *Epithelioma* is not infrequent, and is the most important of the neoplasms of this organ, not only on account of its greater frequency, but also on account of its grave character and the necessity of arriving

at an early diagnosis of the disease. The late manifestations of syphilis (ulcers, gumma, fissures), ulcers of tuberculosis, and some specific ulcers, and papilloma, may be mistaken for this neoplasm.

If a patient has a syphilitic history, gumma or specific ulcer will naturally be suspected. If large doses of potassium iodide be administered for two or three weeks, the specific ulcer will respond to this remedy. If no impression is made upon it, it should be treated as malignant. As regards all other suspicious sores of this organ, it will be the wiser practice to treat them also as malignant growths, for it is a well-recognized fact that papillomatous, tuberculous, and simple ulcers of the tongue (as elsewhere), chronic in character, are capable of transformation into epithelioma. If these sores are removed early in their history, no mutilation is required, the operation is without danger, only a small portion of the organ need be sacrificed, and the focus of disease is removed before its malignant nature is declared or metastasis occurs. If an epitheliomatous ulcer exists, its character may be determined by microscopical examination, as given by Butlin.* If the scraping from a tuberculous, syphilitic, or simple ulcer is placed in a drop of water on a slide, pus- and blood-corpuscles, particles of food, bacteria, and a few normal or almost normal epithelial cells, are observed. If the scraping from an epitheliomatous ulcer be examined, in addition to the above will be seen a great number of abnormal epithelia, varying in size and shape, some flattened scales, others round or oval, others elongated, with caudate prolongations. The cells are generally granular, and possess from two to three or more nuclei, much larger than the normal nuclei of these cells. In some instances the "swallow's-nest" arrangement may be observed.

If no ulcer is present, a section for microscopical examination may be removed from the indurated mass.

Operation.—The method of procedure must be determined by the extent of the organ to be removed. If the induration is confined to the tip, and does not extend more than one inch behind this point, the line of section should be at or near the center of the tongue. It should always be well away from the disease. An inch from the nearest induration will be safer than to allow the line of section to approach the neoplasm in order to save more of the tongue. When the lateral aspect of the anterior half is involved, the line of section need not pass at right angles to the axis of the organ, but may curve around parallel with the limit of induration at a sufficient distance from it. In this way the anterior portion of the opposite half may be, in part, preserved. If the floor of the mouth is infiltrated, it should be dissected from its attachments to the jaw, and the diseased part removed with the tongue. If the disease extends to the middle of the tongue, and involves its entire width, the organ should be removed at its base, and the floor of the mouth thoroughly cleared of all suspicious tissue. The lymphatics in the middle line below the symphysis menti, in the submaxillary region

* "Diseases of the Tongue," Lea Brothers & Co., Philadelphia, 1885.

and down the neck, should be examined and removed if metastasis has occurred.

When the floor of the mouth, together with the anterior two thirds of the organ, are involved, and metastasis is evident in the deeper lymphatics, the propriety of surgical interference is questionable. A cure is not probable, and the operation formidable and dangerous. The removal of the ulcerating portion may be done as a palliative measure.

Without regard to the manner in which the operation is to be performed, the ether should be administered at first through the mouth, and, after the narcosis is complete, when it becomes necessary to work within this cavity, the anaesthesia should be carefully continued by the rectum. It is essential for the teeth to be held widely separated by the gag (Fig. 36), and the lips held out of the way by flat, blunt retractors.

In mild cases, where the disease is situated near the tip of the organ, and where the floor of the mouth is not involved, the operation may be done with the galvano-cautery loop, as follows: The tongue should be drawn well out of the mouth and transfixed from its under surface with a strong needle (armed with a heavy silk thread) at a point in the healthy tissue where the section is to be made. One end of the wire of a galvano-cautery battery is fastened to the thread, drawn through the tongue, attached to the *écraseur* apparatus, and the loop tightened so as to grasp the organ in the direction it is desired to make the section. When it is not divided entirely across, the antero-posterior section is first made. The wire is now slowly heated to a red color, and the loop is very slowly tightened and drawn through the organ. If it is made to cut through quickly, the vessels may not be occluded. The transverse section is next made in the same way, and, if any attachments to the floor of the mouth remain, these may also be divided by throwing the loop around them.

If the cautery battery is not at hand, the Paquelin thermo-cautery may be employed.

If neither of these more modern instruments are to be had, the *écraseur* will suffice. It is not only efficient, but is less apt to get out of order than the other apparatus. When the lingual arteries have not been tied, hæmorrhage is apt to occur after section with either of these instruments. It may be arrested and controlled as directed in wounds of this organ.

When a more extensive operation is required, the following method will be advisable:

A careful examination of the lymphatic glands of the submaxillary and cervical regions should be made, and if any induration is discovered they should be removed as the first step in the operation. If the disease has existed for several months, in all probability metastasis has occurred, even when the enlargement of the glands can not be detected by palpation. This condition is especially apt to exist in the glands corresponding to that side of the tongue upon which the disease originated. It is, therefore, a wise precaution to tie the lingual artery of that side, since this not only lessens the danger of hæmorrhage in the removal of

the tongue, but exposes the glands of the submaxillary and upper cervical triangles, and facilitates their removal if involved. The operation of tying this artery has been given on page 246. It can readily be secured opposite the central tendon of the digastric muscle, at which point it is almost always situated half way between the insertion of this tendon and the hypoglossal nerve, which is from a quarter to a half inch above. In two instances I have divided the posterior belly of this muscle in order to expose the vessel thoroughly. When this is accomplished, the wound should be irrigated with sublimate (1 to 3000), a drainage-tube inserted, and the sutures applied.

The ether should at this stage of the operation be transferred to the rectum, the gag inserted, and the lips retracted.

It is important, in dissecting out the floor of the mouth and the tongue, to be able to control all hæmorrhage and at the same time to fix the tongue. This may be accomplished in a most satisfactory manner, and may be considered as the second step in this operation. An incision about an inch long is made in the median line, commencing at the hyoid bone and extending toward the symphysis. By this incision the integument and deep fascia are divided. A long steel needle, with the eye at the point (Peaslee's instrument will suffice), armed with a strong silk thread, is introduced through the wound, and, while the tongue is drawn well forward, the point of the needle is pushed along the inner surface of the lower jaw into the mouth by the side of the tongue at its base. One end of the thread is pulled out through the mouth, the needle withdrawn, and the end of the thread projecting from the mouth is again carried through the eye of the needle. This is now introduced by the side of the base of the tongue exactly opposite the point at which it entered, and is brought out at the wound below the chin. A strong wire is fastened to one end of the thread and is pulled into the mouth and around the base of the tongue by withdrawing the silk. The wire should now be fastened to an *écraseur* and tightened just enough to control the bleeding. In this manner all the vessels going to the tongue and the floor of the mouth are surrounded and controlled.

The third stage of the procedure is the removal of the tongue and the tissues which form the floor of the mouth. In doing this the Paquelin cautery-knife will be found exceedingly useful. If it is not at hand, the scissors or knife may be used. A strong silk thread should be passed through the sound tissues of the tongue near the end and intrusted to an assistant. It is to be used in lifting the organ as the dissection proceeds. The attachment along the lower jaw should first be divided and the tissues dissected up until the tongue can be lifted freely to a point at least one inch behind the induration. The *écraseur*-loop should now be placed around the organ and the division made at the desired point. If at this time the wire loop which is around the base of the tongue is fairly tight, no bleeding will occur after the amputation. If gradually loosened, the bleeding points on the stump can be readily seized with the long-nosed narrow forceps and tied with silk ligatures. In the after-treatment no dressing is applied to the wound in the mouth.

I am not aware that this method of controlling hæmorrhage in this operation has been performed by any other surgeon.

When the inferior maxilla is involved, it should be excised beyond the limit of the disease.

If, for any reason, more space is required in the ablation of this organ than can be obtained through the natural orifice, one of the following procedures may be adopted:

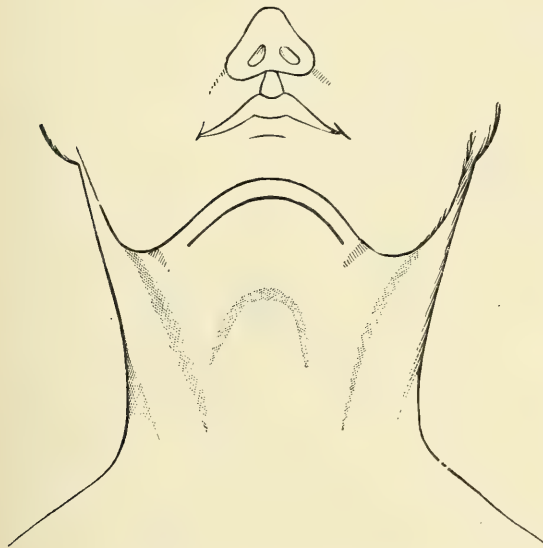

FIG. 512.—Billroth's incision. (After Butlin.)

rior maxilla below the symphysis (Fig. 512), dividing all the tissues on this line until the floor of the mouth is opened.

3. *Kocher* has lately devised an operation the incision in which is shown by the line *b d e c* (Fig. 513). A preliminary tracheotomy is done, and the pharynx stuffed with a carbolized sponge to which a string is attached. The excision extends along the anterior border of the sterno-mastoid muscle, from the level of the lobule of the ear to the level of the hyoid bone, along this bone to near the median line, and thence to the symphysis menti. The skin and platysma are turned up on the jaw, the lingual and facial arteries and veins are tied as they are encountered, all enlarged glands are extirpated, the muscles and floor of the mouth separated along the attachments to the lower jaw to any required extent. If the entire tongue is to be removed,

1. *Gant's* incision through the cheek, from the angle of the mouth in the direction of the lobe of the ear as far as required (Fig. 513, *a*). This incision gives a full view of the lateral aspect of the tongue, and may be made upon both sides when the disease is bilateral and extends beyond the middle of the organ. The edges of the wound are afterward brought together by hare-lip pins or silk sutures.

2. *Billroth* employs a curved incision made parallel with the arch of the infe-

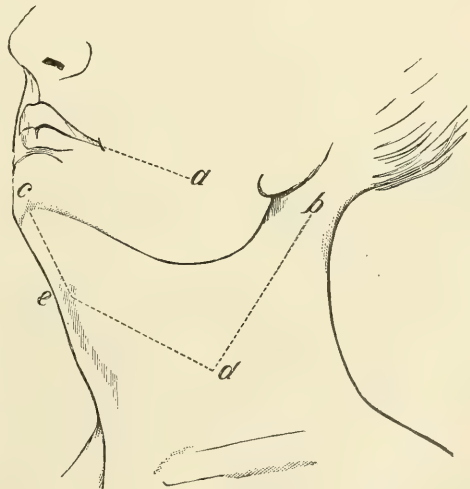


FIG. 513.—Incision of Gant and Kocher. (After Butlin.)

the opposite lingual is also tied. Through this opening the tongue is drawn out, dissected from its anterior and lateral attachments, surrounded with the cautery-loop and divided, or cut off with the *écraseur* or scissors.

In the after-treatment the trachea-tube is left in place, and the pharynx, mouth, and wound filled with sponges dipped in a 5-per-cent carbolic-acid solution, the excess of the acid being washed off with water before the sponges are applied. The wound is dressed twice a day, and liquid nourishment given at each change of the dressing.

The operation of Kocher is objectionable on account of the extent of the dissection, the danger of submitting such a large wound to the probability of septic infection from the mouth, and the complication of tracheotomy. The free inspection of the tissues of the neck which it permits, and the command of the base of the tongue which it allows, are in its favor.

The operations in which the organ is removed through the mouth are simpler, and require much less time in execution. If the author's method of controlling hæmorrhage is adopted, the procedure is practically bloodless, and a preliminary tracheotomy is unnecessary. The conditions which call for the operations of Gant, Billroth, or Kocher rarely exist.

The after-treatment consists in rinsing the mouth at frequent intervals with a warm solution of permanganate of potassa (gr. ss. to $\frac{3}{j}$), anodynes to relieve pain, and generous liquid diet.

Ranula.—This name is applied to certain tumors, cystic in character, which are situated immediately beneath the anterior and lateral portions of the tongue. Ranula is usually acquired, although it may be congenital. The tumor is almost always single; occasionally there is one on either side of the organ. Commencing as a result of obstruction to the outlet of one of the subdivisions of the sublingual gland (rarely as a result of occlusion to one of the terminal ducts), it may grow, when left undisturbed, to great size, crowding the tongue out of its position, rising above the level of the teeth, and protruding through the muscles of the chin until it appears beneath the skin above the hyoid bone.

The only method of treatment is to evacuate the contents and cause an obliteration of the sac by inflammatory adhesion. The Paquelin cautery is the best instrument to employ in their removal. Etherize the patient, introduce the gag, lift the tongue upward with the forceps, protect the lips and teeth by means of flat retractors, seize the wall of the cyst with a mouse-tooth forceps, and with the platinum-knife at a red heat dissect away the anterior wall. After the fluid escapes, dilate the cavity, and make a thorough digital exploration of the sac. The cautery-knife should now be carried slowly back to the deepest portions, searing all sides of the cyst-wall. The wound should be well packed with a single piece of iodoformized gauze. The after-treatment consists in changing the packing every twenty-four to forty-eight hours, and at each dressing irrigating the cavity with 1-to-2000 sublimate solution.

If the Paquelin thermo-cautery is not convenient, seize the cyst-wall with the forceps and dissect it out with curved, blunt scissors. Pack the wound firmly with iodoformized gauze, as above. Hæmorrhage may be controlled as directed in wounds of the tongue.

In a ranula of small size, cocaine may be injected, the anterior wall cut away with the scissors, and a pellet of cotton moistened with pure carbolic acid left in the cavity to destroy the lining membrane. With the first dressing a tuft of gauze should be packed in, and this should be renewed on alternate days until the wound closes.

Tongue-Tie.—When the frænum extends an unusual distance toward the tip of the tongue, or is so narrow that it checks the free movements of this organ, it should be divided in the following manner: Seize the tip of the tongue with a dry towel, carry it upward so as to put the bridle on the stretch, and, with a curved scissors, divide the frænum from one eighth to one quarter of an inch nearer to the floor of the mouth than to the surface of the tongue. This precaution is necessary to avoid wounding the ranine vessels. The gag may be used if required.

A *congenital* defect, very rarely observed, is the adhesion of the tongue to the floor of the mouth. The adhesions should be broken up at birth, and the operation repeated daily until free mobility is secured.

Equally rare is the bifid or snake-tongue, which results from arrest of development or failure of union of the two halves from which this organ is formed. The edges should be pared, and the two halves united in the median line by sutures.

Tonsils.—*Acute tonsillitis* is of very frequent occurrence, causing, in a varying degree, pain, difficulty of deglutition, and interference with phonation, deglutition, and respiration.

The *pathology* of this affection consists in dilatation of the blood- and lymph-vessels, emigration of leucocytes, and proliferation of the connective tissue and other cell-elements of the tonsil. The gland rapidly enlarges, producing great tension of the pillars of the fauces, and projects toward the median line, at times filling the pharynx and crowding the velum upward and backward.

Acute tonsillitis may end in resolution, the gland rapidly diminishing to its normal size, or in ulceration or suppuration (abscess), or the acute process may subside into a chronic form of inflammation, which induces permanent hypertrophy of the organ.

The local *treatment* of acute tonsillitis consists in the application of hot water as a gargle, and scarification of these organs when the tension is sufficient to produce great pain. The internal administration of aconite tincture and quinine is highly recommended.

Abscess of the tonsil should be opened as soon as its presence is detected. The discharge of pus always brings great relief. If the symptoms lead to the suspicion of pus, exploration with the hypodermic aspirator-needle should be made to determine the diagnosis. The internal carotid artery and jugular vein are well back from the tonsil, on a level with the posterior wall of the pharynx.

The object in operating early is to prevent œdema of the glottis, which may occur when the abscess is large or situated behind the body of the tonsil. A more remote danger is rupture of the abscess during sleep, and escape of the contents into the larynx.

Chronic hypertrophy of the tonsils should be treated by partial ex-

cision, repeated as often as may be deemed necessary. The presence of these enlarged organs forces the patient to breathe through the mouth, a habit which often induces a catarrhal condition of the mucous membrane lining the respiratory tract. The follicles of the tonsil discharge a dirty, cheesy secretion, which at times becomes retained in the gland and undergoes calcification. Calculi one fourth of an inch in diameter have been removed from this organ.

Tonsillotomy.—Excision of the tonsils is an operation practically free from danger. In children who can not control themselves, chloroform should be used, the gag introduced, and the tongue depressed by an assistant. The operator seizes the exposed portion of the organ with a long mouse-tooth forceps or a tenaculum, pulls it slightly toward the median line, and with a long-handled pair of scissors, curved on the flat, clips off from one third to one half the tonsil. A sponge, fixed in a holder, dipped in ice-water and pressed on to the bleeding surface, will arrest the hæmorrhage.

In adults local anæsthesia may be insured by cocaine hydrochlorate, and the operation performed as above, with much greater facility, since the intelligent co-operation of the patient is of great value. If the long scissors can not be had, a long, curved, probe-pointed bis-

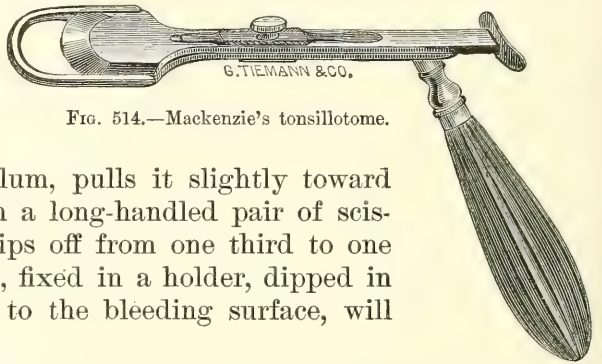


FIG. 514.—Mackenzie's tonsillotome.

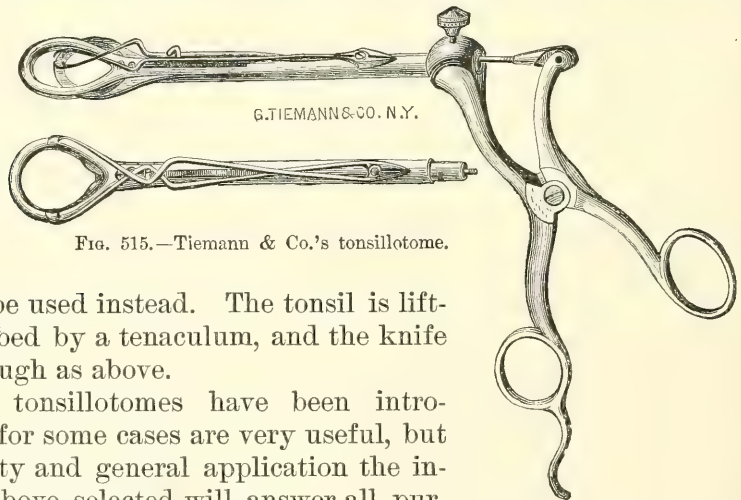


FIG. 515.—Tiemann & Co.'s tonsillotome.

toury may be used instead. The tonsil is lifted from its bed by a tenaculum, and the knife carried through as above.

Various tonsillotomes have been introduced, and for some cases are very useful, but for simplicity and general application the instruments above selected will answer all purposes. Among the best of the tonsillotomes is that of Mackenzie (Fig. 514), and Tiemann's instrument (Fig. 515).

The tonsil is also occasionally the seat of malignant neoplasms, as sarcoma and carcinoma, while cystic tumors, fibroma, and lymphoma are among the benign new formations which attack this gland. They require early and thorough excision in all cases.

CHAPTER XV.

THE NECK.

Wounds.—Wounds of the neck may prove rapidly fatal from hæmorrhage inducing syncope ; from hæmorrhage into the trachea, causing fatal asphyxia ; from the entrance of air into the veins ; or from injury to the cord, at or near the medulla. Death from sepsis may occur as a more or less remote sequence of a wound in this region.

Treatment.—The immediate indications are to arrest hæmorrhage at once, and prevent asphyxia, either by obstruction of the trachea or the admission of air into the veins. Hæmorrhage should be controlled by pressure directly in the wound, until the injured vessels can be secured by the ligature. The entrance of air into the veins must be carefully prevented, by constant pressure on the cardiac side of the lesion, until the forceps have been successfully applied at the bleeding point.

When the wound is *incised* or *lacerated*, and is above the hyoid bone and has severed the hyoid muscles, in addition to the prevention of hæmorrhage into the larynx the tongue must be drawn forward, for when these muscles are divided it falls back upon the glottis, and may occlude the larynx. If the trachea is opened, the edges of the wound should be held apart with tenacula, the head dropped over the end of a table (Fig. 44), any clots removed, and artificial respiration practiced by Sylvester's method (page 31). In the closure of all wounds of the neck the antiseptic precautions should be taken, and drainage secured. When the pneumogastric, hypoglossal, or other important nerves have been divided, the ends should be brought together by a delicate silk suture. It is also advisable to unite the ends of divided muscles by sutures. An incised wound of the œsophagus should be closed immediately. Lacerated wounds of this tube should be allowed to close by granulation. Difficulty in deglutition follows severe wounds of the throat, not infrequently necessitating the introduction of liquid food through the œsophageal tube, or feeding by the rectum.

Punctured wounds of the neck should be dressed antiseptically, and compression employed to arrest hæmorrhage. If this does not succeed, the ligature should be applied.

Gunshot wounds should be treated in practically the same manner. Missiles of small caliber deeply lodged should be left alone, since they usually become encapsuled and remain harmless. When superficial and readily detected, they should be extracted by the forceps. In the effort to locate a bullet it is always important to place the parts in about the

same position as at the time when the missile penetrated. If this is not done, the muscles and fascia become displaced, and the track of the wound obstructed. Gunshot wounds traversing the outer lateral and superficial posterior regions of the neck are not, as a rule, dangerous. If the vertebral column is involved, the prognosis becomes grave. A missile traversing the tissues of the neck laterally, and in front of the vertebral column, is apt to inflict fatal injury.

Abscess.—Abscess of the neck occurs most frequently in children, and may follow an injury, or result from an idiopathic inflammation of the tissues of this region. It occurs very frequently as a result of adenitis, or periadenitis, tonsillitis, and in caries of the upper cervical vertebræ, or base of the skull (retro-pharyngeal abscess). It may also follow the lodgment of a foreign body in the œsophagus. Collections of pus in the upper cervical regions, and in the superficial portions of the root of the neck, tend to become encapsuled, or may open ultimately through the integument. Retro-pharyngeal abscess, if left alone, not infrequently travels downward along the deep fascia of the neck, and may open into the mediastinum.

The *diagnosis* of abscess in the neck, from the various tumors which are found in this region, depends upon the febrile movement present in abscess, the acute and persistent character of the pain, and fluctuation. The value of exploration, with an aspirator-needle large enough to carry pus, should not be lost sight of in the effort to arrive at a positive diagnosis.

The *treatment* is evacuation, either by the method of aspiration and hyper-distention already given, or by puncture or incision, and free drainage. When the abscess is situated in a portion of the neck rich in vessels, it should be opened by cutting carefully down upon it, so that any hæmorrhage encountered may be immediately and readily controlled. If a puncture is determined upon, the knife should be introduced in the part farthest from the vessels, and along the aspirator- or exploring-needle as a guide. As soon as the sac is entered by the instrument it is withdrawn and a dull-pointed dressing-forceps, tightly closed, is carried into the abscess, when, by forcible separation of the jaws, the puncture is enlarged.

The finger may now be introduced, or, if this can not be done, the forceps will indicate the size and most dependent portion of the sac. If the first opening has not been made at the lowest part of the abscess, or is not so situated that thorough drainage is secured, it should be enlarged so as to extend this far, or a counter-opening made by boring through with the forceps until the skin is distended over the point of the instrument, when it can be safely incised. Drainage should be maintained, and the cavity irrigated with 1-to-3000 sublimate solution.

The *diagnosis* of retro-pharyngeal abscess depends upon the following symptoms: Pain, a feeling of soreness and stiffness in the neck, swelling, with protrusion of the posterior wall of the pharynx if the disease is high up, interference with deglutition and respiration. In the earlier stages all of these symptoms will not be present, but as soon as this dangerous condition is suspected an effort should be made to locate the abscess by palpation and aspiration.

In evacuating the pus an incision should be made in the pharynx, as near the median line as possible. When a large quantity of fluid is present the head should be inclined downward as the incision is made, so that the contents of the abscess may not gravitate into the larynx. This danger may be obviated by partially emptying the sac by the aspirator before the incision is made. When the sac extends low down the neck it should be entered and drained from below. Deep retro-pharyngeal abscess may be reached, as a rule, by the incision and dissection laid down in the operation of *œsophagotomy*.

Phlegmon of the neck demands free incision in all cases, when such incision does not encroach upon the important organs of this region.

Tumors of the Neck—Solid and Cystic—Lymphoma.—Pathological changes in the lymphatics of the neck account for the large majority of swellings in this region. Lymphoma of the neck may be solid or cystic, benign or malignant.

Tumors of the cervical glands may comprise simple lymphoma, the result of hypertrophy and hyperplasia; tubercular lymphoma, lymphosarcoma and lymphangiectasis.

Lymphoma occurs most frequently in the submaxillary and upper carotid triangle, and next in order of frequency along the line of the great vessels beneath the mastoideus, and lastly in the subclavian region. In some instances these tumors attain enormous proportions, filling in the neck to the level of the lower jaw and clavicle, and, if not removed, produce death by pressure upon the respiratory apparatus or the œsophagus.

Fatty tumors are apt to occur upon the posterior aspect of the neck, and occasionally in the clavicular region. They are comparatively rare in the anterior and upper triangles.

Cystic Tumors.—Cysts of the neck are congenital and acquired.

Congenital cysts are rare. The form most frequently observed is that already mentioned as a dilatation and hypertrophy of the lymphatic vessels (lymphangiectasis). They are usually multilocular, and may extend deeply and, at times, assume enormous proportions.

Acquired cysts are seen chiefly along the line of the mastoid muscles, having a tendency to occur in the neighborhood of the parotid gland, less frequently in the subclavian triangle.

Cysts resulting from extravasations of blood may also occur here, and occasionally distention of the bursæ in the thyro-hyoid region produces cystic tumors. They require thorough and careful dissection to secure the removal of the entire cyst-wall.

Thyroid Body.—Hypertrophy or hyperplasia of this organ may be partial or complete. All, or a part, of one lateral lobe is usually affected; less frequently the isthmus is alone involved. The offshoots of this body which are met with at times near the hyoid bone, near the inner edge of the sterno-mastoid muscle, and occasionally dipping down behind the œsophagus, may also become enlarged. *Goitre*, or *bronchocele*, is usually endemic, and attacks females more often than males. No climate or condition of living affords a positive immunity from this disease, although in certain localities, as in the valleys of Switzerland, it is

frequently met with. The cause of goitre is unknown. It is prone to occur in those whose surroundings are damp and unwholesome and among the poorly fed. The influence of heredity is recognized in the occurrence of this disease in the children of patients affected with bronchocele.

A goitre may be *solid* or *cystic*. In solid goitre the enlargement may be caused by a general hypertrophy of the normal elements which compose this body, or some of these elements may undergo proliferation and increase at the expense of the others. When the tumor is hard and tense, it is called *fibrous* goitre, and in this form the chief pathological change is an increase in the connective-tissue elements of the stroma.

In *cystic* goitre the tumor is caused by the accumulation of a dark-brown fluid within the substance of the organ. There may be one or more separate collections of fluid, although a multilocular arrangement is most common.

The *diagnosis* of goitre is not difficult. The presence of a tumor in the region of the thyroid body, usually unilateral, occasionally bilateral, moving with the trachea in the act of deglutition, capable of very perceptible enlargement during coughing or any prolonged and violent expiratory effort, are symptoms which point quite clearly to bronchocele. As to determining the character of the tumor, one must depend upon palpation in great part, and also upon exploration with the aspirator. Fibrous goitre is dense, hard, very slightly elastic, often presenting irregularities in surface. Cystic bronchocele is round, smooth, elastic, movable, and, even when the capsule is greatly distended, fluctuation is perceptible. The use of the exploring-needle, and the withdrawal of a portion of the fluid contents for microscopical examination, is important in diagnosis.

The fluid from a cystic goitre varies in color from amber to dark brown and almost black. Under the microscope crystals of cholesterin, crenated red blood-corpuscles, large compound granular cells, leucocytes, etc., are seen. The characteristic contents of *hydatid cysts* are easily recognized and excluded. Fibro-cystic, or mixed goitres, possess some of the characteristics of both the foregoing varieties. The feeling of solidity is not so great as in the fibrous, and is less elastic and with a less appreciable sense of fluctuation than in cystic bronchocele.

Sarcoma and *carcinoma* of this organ are hard, solid tumors of rapid development, steadily increasing in size, and in their growth binding the invaded organ to the integument, muscles, and fascia of the neck. *Abscess* would have a previous history of inflammation, pain, and febrile movement. *Aneurism* of the carotid appears usually to the outer side of the thyroid region, and presents the symptoms of expansion with the heart's systole, the aneurismal thrill and murmur, all of which symptoms disappear after pressure upon the artery on the cardiac side of the tumor.

The diagnosis of other cervical tumors may be considered here. Tubercular lymphomata are recognized by their anatomical locations, by their slow process of development, together with the personal and family history of the individual.

In many instances these tumors of the glands remain quiet for a period, and, responding to some irritation, an adenitis and periadenitis are developed, which rapidly lead to the formation of abscess. They are found most frequently along the lower border of the inferior maxilla in the lower parotid region, along the under surface and posterior border of the sterno-mastoid muscle, and in the subclavian triangle.

Metastatic lymphoma, secondary to epithelioma or other malignant disease of the face, will be recognized by the history of the case. Lymphosarcoma of the neck is, in its earlier stages of development, with difficulty differentiated from simple adenoma. It grows, however, with much greater rapidity, and, by its tendency to become fixed to the surrounding tissues, suggests its malignant nature. It is most usually located about the center of the neck and beneath the sterno-mastoid muscle.

Treatment.—Cystic goitre does not yield to constitutional measures. Solid tumors should be treated by the administration of full doses of potassium iodide. If marked diminution in the size of the tumor does not follow within the first few weeks of this treatment it should be discontinued.

Bronchocele, either solid or cystic, which is small in size and not perceptibly increasing, does not demand surgical interference. Such tumors should be kept under observation, and if at any time there is a marked increase in size operative interference is called for, before the mass has assumed such proportions that its removal involves considerable danger to life. According to Kocher, another contra-indication to surgical interference is the presence of a goitre involving the entire organ, since—although the operation may be recovered from—death results in from one to two years, from the development of a strumous condition not unlike that known as myxœdema. Physiological experiments have shown that a like condition results from the total extirpation of the thyroid body in animals. Under no circumstances, therefore, is a complete removal of this body justifiable. One side and the isthmus may be removed, and in extreme cases both lobes may be extirpated, provided the isthmus is left undisturbed.

Another contra-indication is calcareous degeneration of a considerable portion of the mass, causing a condition of friability in the vessels which renders their deligation unsafe.

Operation—Cystic Goitre.—Make a perpendicular incision, about three inches in length, over the center of the tumor. Divide the integument, fascia, and intervening muscles down to the sac. Upon approaching this, the dissection should be carried on between two anatomical forceps, lifting only a thin bit of tissue at each grasp of the instruments, and looking closely for any vessels which may run upon or through the anterior wall of the tumor. When the wall is reached it should be divided in the same manner, and, upon the escape of the contents through the opening, this should be enlarged by introducing the dressing-forceps and dilating. The opening in the wall should be about one inch long. A continuous catgut suture should be carried through the integument, stitching this to the edges of the sac. The cyst should now be well irri-

gated with 1-to-5000 sublimate solution, and rubber drainage-tubes introduced, one into the deepest and another in the upper portion of the sac. A loose sublimate dressing should be applied. The indications for changing the dressing are hæmorrhage, rise in temperature above 103° after the second day, and for purposes of cleanliness. In two of my cases in which larger cysts were evacuated there was considerable febrile movement for the first week after the operation. As the cyst becomes filled with granulation-tissue, the tubes should be gradually shortened.

In the removal of a solid unilateral goitre, a crucial incision is preferable. This should be very free, in order to give a full view of the wound. The dissection should expose the entire anterior surface of the mass before attempting to get beneath it at any point. Care must be taken not to tear or incise the substance of the tumor, since it bleeds profusely, and is often so friable that it will not hold a ligature. The object of the operator should be to get into the capsule of the tumor. Working with the dry dissector between this and the surface of the neoplasm much bleeding may be avoided. Whenever a vessel is seen in the track of the dissection, it should be seized in two places with the forceps (the narrow-jawed instrument, Fig. 82, is preferable), divided between them, and each end tied with stout catgut.

In lifting the tumor the operator should work along the outer side, and pass under the mass from this aspect. In this way the superior and inferior thyroid vessels may be ligatured in the earlier stages of the operation, and the chief source of bleeding controlled. The presence of the recurrent laryngeal nerves, as they pass upward on either side, in the space between the trachea and œsophagus, should not be forgotten. It is not always possible to avoid them, but by keeping close to the capsule of the tumor the least risk will be incurred. The veins passing into the mass are at times of great size, and the walls of those in the tumor are in some cases very friable, causing much annoyance and delay, in repeatedly breaking down under the ligature and recurring hæmorrhage. In one of my cases the internal jugular vein was involved in the mass to such an extent that it was necessary to tie this vessel above and below, and divide it. When all of the tumor is free, except the isthmus, this should be surrounded with a small elastic ligature, and divided. The edges of the wound are now closed with catgut, the drainage-tube and rubber ligature brought out at the most dependent portion of the incision, and a sublimate dressing applied. The ligature comes away by drawing upon it about the eighth day.

The *prognosis* from this operation is favorable in the large majority of cases. It only becomes grave in the larger tumors, and the chief element of gravity here is the exhausted condition of the patient, resulting from pressure of the mass. It must, however, be classed among the more formidable operations, although modern surgery has greatly reduced the death-rate.

In the removal of double goitres, if the two tumors are of large size, the two operations may be done with an interval of two or three weeks, should

the first operation be unavoidably prolonged. In the double simultaneous operation, the better incision is that of Kocher, whose magnificent achievements in thyroidectomy leave him unquestionably the first of surgeons in this field. It is Y-shaped, the oblique prongs running from below the ear on either side and uniting at the most convenient point near the pomum Adami in the middle line. Thence a single median incision extends down to and somewhat beyond the sternal notch. Reflecting the flaps, the masses are well exposed. The intra-capsular dissection should now be continued as just described.

Hydatid cysts are in very rare instances met with in this organ. They should be treated by incision and drainage, as laid down in the management of cystic goitre. When the tumor is of small size (two inches or less in diameter), aspiration and hyperdistention with 1-to-5000 sublimate solution, or 1-to-40 carbolic acid, may be tried. The fluid should be at once withdrawn and compression maintained for several days.

In *carcinoma* and *sarcoma* of this body, complete thyroidectomy is demanded, when the neoplasm is limited to a portion of the gland. When both sides are invaded, or when the entire lobe on either side is occupied with the new growth, operation is of doubtful propriety, not only on account of the immediate danger attending such an extensive dissection, but by reason of the fatal termination within one or two years of those cases in which both lobes and the isthmus have been extirpated. When the tissues immediately surrounding the tumor are invaded, surgical interference is not indicated.

Exophthalmic Goitre—Basedow's or Graves's Disease.—In this disease the thyroid body is increased in size, chiefly due to the dilatation of the arteries and veins in its substance. There is a varying degree of hyperplasia of the glandular substance and the connective-tissue stroma. This condition is accompanied by violent chronic palpitation of the heart and protrusion of the eyeballs. The cause of this disease is not known. It is generally considered to be a nervous disorder. It is met with in women about twice as often as in men. After death the heart is found to be hypertrophied and dilated. The size of the thyroid tumor is greatly diminished after death, and the exophthalmos disappears. This form of goitre is not amenable to surgical treatment, and is mentioned here as an aid to the more accurate diagnosis of these forms of bronchocele which may be relieved by operative interference.

In the medical treatment of exophthalmic goitre the galvanic current directed to the sympathetic ganglia of the neck is highly recommended. The direct current is employed, one electrode being placed over the spines of the cervical vertebræ, while the other is passed over the enlarged thyroid from the sternum to the lower jaw.* This treatment should be supplemented by tonics, out-of-door life, attention to increased nutrition of the tissues, and abstention from all violent exercise or excitement.

* Dr. Doughty, of Augusta, Ga., has met with gratifying results in this method of treatment.

THE LARYNX AND TRACHEA.

The operations upon these organs in the neck are *thyrotomy*, *laryngotomy*, *laryngo-tracheotomy*, *tracheotomy*, and *exsection* of the larynx.

Thyrotomy is indicated in the removal of neoplasms or foreign bodies from the larynx, which can not be reached through the mouth by the aid of the laryngoscope and forceps or snare. The patient should be placed upon the table, with the head well depressed. Make a perpendicular incision from near the center of the hyoid bone, exactly in the median line of the pomum Adami, as far down as the cricoid cartilage. The bleeding is thoroughly arrested, and the two wings of the thyroid cartilage divided exactly in the angle of union. This should be done with great care, in order to avoid wounding the vocal bands, which are attached on either side of the median line, in front. If at this stage of the operation a tenaculum is inserted, on either side, the alæ may be drawn apart, freely exposing the interior of the larynx. In closing the wound the cartilages are not included in the sutures, it being sufficient to bring the edges of the skin together.

In *laryngotomy* the opening is made through the crico-thyroid membrane. It is indicated in œdema of the glottis, obstruction of the larynx by new growths, foreign bodies, and exceptionally in rapid inflammatory swelling of the tonsils or pharynx, with occlusion of the larynx.

When the emergency demands it, rapid laryngotomy may be performed as follows: Make a single incision from the notch in the upper margin of the thyroid cartilage, in the median line, to the lower edge of the cricoid ring, then turn the knife-edge upward and thrust the point through the crico-thyroid membrane. A hook should now be quickly inserted on either side, and the edges of the wound separated. Traction not only opens the wound in the membrane to admit the air more freely, but it also arrests the bleeding. When tenacula can not be had, a fair substitute may be extemporized from wire, or the ordinary metal hair-pin. The opening in the membrane may be enlarged by a transverse incision when necessary.

When expedition is not urgent, the bleeding from the wound in the integument should be arrested before the opening into the larynx is made.

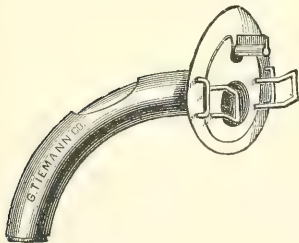


FIG. 516.—Double trachea-tube, silver, plain.

If it is necessary to keep the wound open, a silver trachea-canula (Fig. 516) should be inserted. This instrument is secured by a tape tied around the neck. When it becomes obstructed, the inner canula should be withdrawn, cleansed, and reinserted, and, if necessary, the larger tube remaining in the larynx should be brushed out with a small brush or mop. When this instrument is worn it should be carefully

watched, as long as any danger of its becoming obstructed exists. It may be worn indefinitely in cases of permanent laryngeal stenosis.

Laryngotomy without a Tube.—When a canula is not at hand, a needle, armed with fine, strong silk, should be passed, on either side, through the integument and cricoid membrane, brought out through the opening in the larynx, and the suture tied. It is best to employ two sutures in each side of the wound. These may be tied behind the neck, or attached to bits of adhesive plaster and fastened to the integument, so as to keep the wound open. A strip of plaster should be laid on each side of the wound, to prevent the thread from cutting into the integument.

Laryngo-tracheotomy (an operation rarely performed) consists in extending the incision of laryngotomy through the cricoid cartilage, and the upper one or two rings of the trachea.

Tracheotomy is more frequently done than either of the operations just given. The trachea may be opened (1) above the isthmus of the thyroid body, the upper three or four rings being divided; (2) the isthmus may be tied with a double ligature, divided, and the trachea opened beneath it; (3) the opening into the tube may be altogether below the isthmus.

It will rarely be found necessary to divide the isthmus. The operation above the isthmus is simpler, and should be preferred in all cases where the obstruction is in the larynx. For the removal of a foreign body lodged in the bifurcation of the trachea, or in either bronchus, the lower procedure should be adopted. This operation should also be preferred in diphtheritic croup when all other measures have failed. The results achieved with the laryngeal tube of Dr. O'Dwyer, of New York, justifies a faithful trial with this instrument before resorting to the formidable operation of tracheotomy in diphtheritic croup.

Dr. O'Dwyer's directions are as follows: The tubes are of various sizes, and are constructed on a scale (Fig. 517) somewhat like the urethral sounds. No. 1 is intended for a child eighteen months old, or less; No. 2, between eighteen months and three years; No. 3, for the fourth year; No. 4, for the fifth year, and so on.

When the proper tube is selected for the case to be operated on, a fine silk thread is passed through the small hole near its anterior angle, and left long enough to hang out of the mouth, its object being to remove the tube should it be found to have passed into the œsophagus instead of the larynx. The obturator is then screwed tightly to the introducing instrument, to prevent the possibility of its rotating while being inserted, and passed into the tube.

The child is held upright on the nurse's lap, with its arms secured by the sides or behind the back. An assistant holds the head, which he inclines backward at the proper time, while the operator, seated in front, inserts the gag (Fig. 518) well back between the teeth, in the left angle of the mouth, and opens it as widely as possible, without using undue force. He then inserts the index-finger of the left hand, which serves to




Fig. 517.
Scale.

elevate the epiglottis and guide the tube into the larynx. The handle of the introducing instrument (Fig. 519), held close to the patient's chest

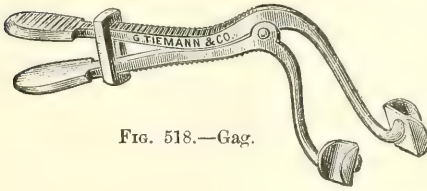

FIG. 518.—Gag.

in the beginning of the operation, is rapidly elevated as the glottis is approached, and the tube pushed downward without using much force. It is then detached, and the obturator quickly removed. The joint in the shank of the obturator is for the purpose of facilitating this part of the

operation. Lest the tube should also be withdrawn, it is necessary to keep the finger in contact with it.

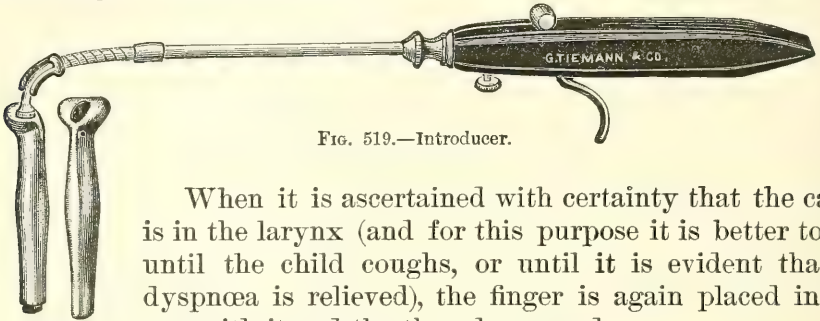


FIG. 519.—Introducer.

When it is ascertained with certainty that the canula is in the larynx (and for this purpose it is better to wait until the child coughs, or until it is evident that the dyspnœa is relieved), the finger is again placed in contact with it and the thread removed.

It is important that the attempt at introduction be made quickly, as respiration is practically suspended from the time that the finger enters the larynx until the obturator is removed. It is, therefore, under the circumstances much safer to make several abortive attempts than one prolonged effort, even if successful.

The removal of the canula is a more difficult operation than its introduction, owing to the fact that the aperture of the tube into which the

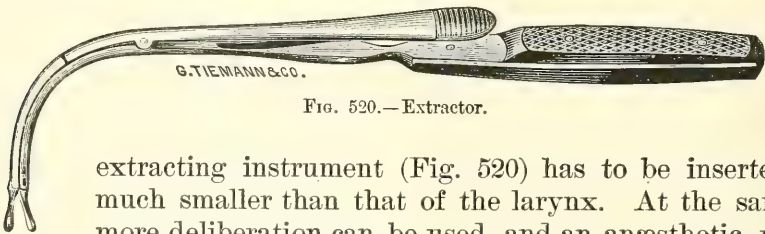


FIG. 520.—Extractor.

extracting instrument (Fig. 520) has to be inserted is so much smaller than that of the larynx. At the same time more deliberation can be used, and an anæsthetic, which is never necessary for the introduction, can be given if required.

There is no danger whatever of these tubes slipping through into the trachea, even if used on older children than those for which they are intended.

Some practice on the cadaver is a very necessary preliminary to using them on the living subject. It is well also to bear in mind that it is much more difficult to reach the larynx in the dead than in the living.

High Operation.—Place the patient on the back, in such a position that the head falls well over the end of the table. If an anæsthetic is

not given, one assistant should hold the extremities immovable, while a second steadies the head. The operator should stand to the patient's right, facing the light. It is important that the head be held so that the nose and symphysis menti will be directly in line with the inter-clavicular notch and umbilicus, for if this precaution is not taken the trachea may be displaced, an accident which might lead to great annoyance, especially in children, in whom this tube is always very small. The incision should be exactly in the median line, commencing at the center of the thyroid cartilage and extending downward one inch and a half, or more if necessary. The edges of the wound should be separated by retractors, and the incision continued down to the tube. All bleeding should be arrested by the forceps and ligature before the trachea is opened, for fear of suffocation from the entrance of blood.

In some subjects it will be found that the isthmus of the thyroid body is situated so high that an opening sufficiently long can not be made without displacing it downward. This may be done by dividing with the curved scissors the muscular and ligamentous bands which are attached to the isthmus below, and the hyoid bone and thyroid cartilage above. This section should be made on either side of the incision, opposite the first ring of the trachea. After all bleeding has ceased, the knife should be carried into the trachea with the edge directed upward, and the two or three upper rings divided.

Low Operation.—The incision through the integument extends from the cricoid cartilage to the level of the inter-clavicular notch. Separate the sterno-thyroid muscles in the median line, and carry the dissection carefully down to the trachea, avoiding the isthmus of the thyroid body and the inferior thyroid vein, a branch of which is in front of this tube. The anterior jugular vein occasionally is in the median line. Any of these vessels coming within the line of incision should be secured with a double ligature before being divided. The trachea will be found deeply situated, and should be incised through four or five rings, in the same manner as advised in the preceding operation. If a trachea-tube is not at hand, the operation may be completed, as advised in laryngotomy, without a tube.

FOREIGN BODIES IN THE LARYNX, TRACHEA, AND BRONCHI.

Foreign bodies in the respiratory tract are, in almost all instances, introduced by way of the larynx, into which they may fall by gravity or be drawn in by the suction-force of the inspiratory effort. Occasionally they enter directly from without, as in stab- or gunshot wounds, or may make their way in from the œsophagus by perforation or from the rupture of an aneurism or abscess. Pieces of coin, buttons, teeth, seeds, threads, pins, blow-gun darts, shot, particles of food, etc., are among the most frequent substances lodged in the air-passages. A foreign body may lodge just behind the epiglottis, across the rima glottidis, in the ventricle between the true and false bands, between the vocal cords, or, passing these, it may descend into the trachea or bronchus. If it be a

solid and smooth body, it will pass into the bronchus and continue to descend until the smaller diameter of the tube arrests its progress. Any substance with projecting, sharp edges, or long and pointed, as a pin or fish-bone, may become lodged across the windpipe at any point.

The symptoms of foreign body in the air-passages are immediate and remote. Strangulation, cough, and cyanosis immediately after the escape of any substance backward from the mouth or nose, or matter which has been regurgitated from the stomach, always suggest the entrance of foreign matter into the larynx or trachea. In some cases death ensues almost instantly from asphyxia. In others the symptoms of strangulation last for a few moments and then disappear, leading the patient or attendant to believe that the foreign body has been coughed out or swallowed. The momentary cyanosis and strangulation are caused by spasm of the laryngeal muscles, induced by direct irritation from the foreign body. As soon as these relax a forcible inspiratory effort may carry the substance downward to the trachea or bronchus, or the expiratory cough may have discharged it into the mouth. In any event, the symptoms of asphyxia disappear unless the offending substance is so large that, even when sucked into the trachea, it completely occludes this tube. The remote symptoms of foreign bodies in the air-passages are chiefly inflammatory. Traumatic trachitis, bronchitis, pneumonia, gangrene, and abscess may ensue. Abscess and gangrene are rare. Bronchitis is inevitable, and localized or lobar pneumonia is not infrequent.

The *diagnosis* may be determined by inspection, palpation (either direct or intermediate), and by auscultation, together with a due regard for the sensations experienced by the patient. Inspection is only possible with the laryngoscope. Direct palpation is only possible when the substance is lodged in the larynx, since the tip of the finger can not be carried beyond this point.

Auscultation is of great aid to diagnosis, especially when the body has passed deep into the respiratory tract. Diminution or absence of the normal vesicular murmur over one entire lung indicates the partial or complete occlusion of one primary bronchus by the foreign body. If this interference is limited to only a portion of the lung, the indication is that the body has passed into one of the subdivisions of the bronchus.

The compensatory increase of the normal vesicular respiration in the opposite lung will be proportioned to the interference with the function of the affected side. When a narrow body becomes lodged in the trachea or bronchus, its presence is indicated by a sibilant or hissing sound, heard with greatest intensity over the point of lodgment, and carried upward and downward with the expiratory or inspiratory movement.

The presence of pain persisting in a given locality points to the seat of lodgment of the foreign substance. Persistent spasm of the larynx until tolerance is acquired suggests lodgment in the ventricle of this organ.

Treatment.—The immediate indication is the prevention of fatal asphyxia, and this may require rapid laryngotomy or tracheotomy, and, in exceptional instances, the resuscitation of the patient by the method

of Sylvester (page 31). As soon as this danger is obviated, the removal of the foreign body may be undertaken. It is well to remember that in a few instances symptoms of asphyxia have been produced from the epiglottis having been drawn into the rima glottidis by a powerful inspiratory effort.

When fatal asphyxia is not threatened, no immediate operation is indicated. The patient should be turned head downward and violently shaken, and at the same time made to cough or sneeze. If the substance is smooth or heavy, it may be dislodged and expelled in this manner.

If this procedure is unsuccessful, the question of operative interference should be considered. If the body can be located in the larynx, it can readily be removed by the operation of thyrotomy if the patient is a child, or by laryngotomy and the introduction of the little finger into the organ through the wound in the adult, pushing the offending substance upward into the pharynx. Either of these procedures is practically free from danger. When the foreign body has passed into the trachea or bronchi, the necessity for operative interference will depend upon its size, shape, and location. If it is small, and produces no marked disturbance of respiration, and is deeply lodged, no effort should be made to remove it, for the following reasons: When small, it is not apt to inflict serious damage; the tracheotomy and the introduction of instruments into the respiratory tract are dangerous operations; lastly, the uncertainty of finding or dislodging a small body should be taken into consideration.

When, however, the character of the foreign body is such that its presence is a source of great danger to the patient, and it can not be removed without operation, surgical interference is demanded. The position for the patient is the same as for tracheotomy, and this operation should be done as low down as possible. When the trachea is opened, the little finger should be carried downward to the bifurcation in the hope of locating the body, and, if discovered, it should be grasped with a pair of forceps and removed. If it is not encountered below, the upper portion of the tube should be examined in the same way. If it can not be reached by the finger, the angular alligator-forceps (Fig. 521) should be carried into the bronchial tubes, carefully regarding any arrest in the progress of the instrument.

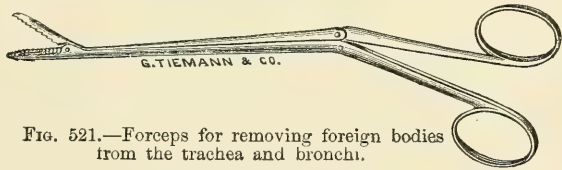


FIG. 521.—Forceps for removing foreign bodies from the trachea and bronchi.

A solid or large body may be felt and seized without great difficulty. A small, light substance may be touched without any sense of resistance to the hand of the operator. If it can not be recognized, the point of the instrument should be carried into the bronchus in which the body is located, the jaws separated, and, while open, carried about half an inch further in, and then closed and withdrawn in order to see if the object has been grasped. This manœuvre is repeated several times until the

whole length of the bronchus has been searched. If the foreign body is not found, it will be judicious to search in the opposite bronchus, for it is possible for it to have been dislodged in the course of the exploration, and carried by the respiratory effort into the trachea and down into the other tube. If proper forceps can not be obtained, a loop of silver wire may be used.

The exploration of the trachea should be done with great care not to inflict unnecessary violence upon the mucous membrane. The search should not be prolonged more than from thirty minutes to one hour.

If the body is removed, the wound may be left to heal by granulation, simply closing it with adhesive strips, or, if the patient has borne the anæsthetic well, it will be better to stitch the trachea with catgut, and the edges of the wound separately with the same substance. If the object is not found, the tracheal wound should be kept open by inserting a large trachea-tube, or by sewing the tracheal rings to the edges of the divided integument and keeping the wound open by tying the strings behind the neck.

Figs. 522 and 523 exactly represent an air-gun dart which was lodged



FIG. 522.—Dart, as it came from the bronchus.

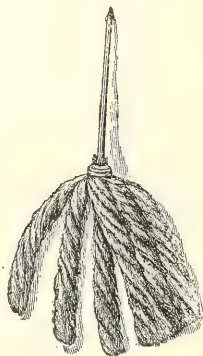


FIG. 523.—The same, before it entered.

in the right bronchus of a boy twelve years old, who came under my care in 1884.* In the act of filling his lungs to project the dart from the gun it was carried into the trachea. Spasm of the laryngeal muscles followed for a few moments, with marked cyanosis. After this there were no symptoms of disturbance beyond a slight cough. I performed tracheotomy at the lowest point possible, dislodged the body by forceps carried into the bronchus, when it was ejected during a violent paroxysm of coughing. The wound was left to close by granulation.

Laryngectomy, or exsection of the larynx, although a formidable operation, is, under certain conditions, justifiable. It may be partial or complete. According to Cohen's excellent article,† complete laryngectomy has been performed ninety-one times. The gravity of the procedure may be estimated from the fact that over one third of all the cases died within eight days of the operation.

The conditions which justify the operation are, the invasion of this organ by malignant neoplasm, and, in rare instances, destructive chondritis, with infiltration and threatened occlusion of the respiratory tract. If, after a careful study of the case, the surgeon is convinced that there is a fair probability of relief from pain and prolongation of life by the removal of the diseased structures, greater than he would be likely to

* "New York Medical Journal," November, 1884, p. 487.

† Ashhurst's "Encyclopædia of Surgery," vol. v. William Wood & Co., New York.

obtain by the palliative operation of tracheotomy, he is justified in advising the operation. When the tissues about the larynx are widely infiltrated with the malignant neoplasm, the operation is not justifiable.

It is performed as follows: The patient is anæsthetized with ether, by the mouth, and, when once fully anæsthetized, the narcosis should be continued by the rectum. The first step is to reach the trachea at a point sufficiently low to be well out of the diseased zone. An incision is made as in tracheotomy, and a Trendelenburg's tube (Fig. 524) is introduced. The end of this

tube, which is carried into the trachea, is surrounded by a rubber balloon, which, after its introduction, is inflated, thus completely tamponing the trachea and preventing the es-

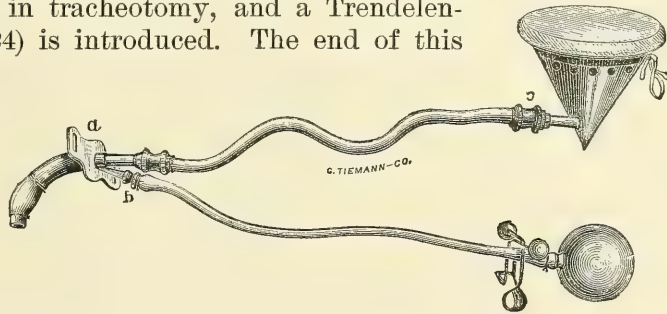


FIG. 524.—Trendelenburg's trachea-tampon, with inhaling-apparatus attached.

cape of blood into the bronchi. The attachment for inhalation of ether may be used if needed. The organ is best exposed by a crucial incision, and all bleeding should be arrested as the operation proceeds. It is best to seize all vessels between two forceps, divide and tie them as directed in the operation for the removal of goitre.

A trachea-tube should be inserted after the exsection is completed. Alimentation is carried on through an œsophageal tube, or by introduction into the rectum.

Partial laryngectomy is performed in the same general way as the preceding operation.

Neoplasms of the Larynx and Trachea.—Almost every form of new growth has been removed from the larynx. No portion of the organ is exempt. The symptoms are referable to the location of the neoplasm and to its size, and in a certain sense to its shape. Those situated upon the vocal bands are first noticed, on account of interference with the voice. A neoplasm may develop in the ventricle, and not be noticed until it encroaches upon the cords. Dyspnœa occurs earlier when the tumor is situated upon the rima glottidis.

Cough is not a prominent symptom, for the reason that the slow and progressive development of the neoplasm gradually accustoms the larynx to its presence. Spasmodic cough does, however, occur in pedunculated growths, which are moved to and fro as the air rushes in and out of the larynx.

The *diagnosis* may be made from the symptoms detailed, but chiefly by palpation and the laryngoscope. The location is simple, but the differentiation as to the character of the growth is at times difficult. *Papillomata* are most frequently met with, and papilloma in the larynx possesses the same general properties observed in these growths in more exposed quarters. They are most commonly found upon the vocal

bands. The tumor may appear in the mirror as a single wart-like fungus, or pinkish-gray tuft upon the cords or laryngeal wall, or there may be several which fill a great part of the opening. The fibroid laryngeal polypi (*fibromata*) are chiefly pyriform, pedunculated, and smooth, in location and color resembling the papillomata.

Enchondromata of the larynx, less frequently observed than the two preceding neoplasms, are developed from the cartilage proper of the larynx. They are usually seen in the vicinity of the crico-arytenoid articulation. *Cystic* tumors are rare. Occlusion of the duct of the *sacculus laryngis* will lead to the appearance of a tumor in the ventricle, between the true and false bands. Other cysts may result from simple follicular occlusion. *Telangiectasis*, or *angioma*, is a still rarer form of laryngeal tumor. *Carcinoma (epithelioma)* is, unfortunately, not a rare disease of this organ. *Sarcoma* is very rarely met with. *Epithelioma* of the larynx, in common with all malignant (as well as benign) neoplasms, occurs chiefly at the upper portions of the organ.

The treatment of all forms of benign tumors of the larynx is their removal with the knife, scissors, the snare, or caustics. Removal of malignant growths, to an extent sufficient to prevent recurrence, without a total or partial laryngectomy, is rarely possible. Benign growths, especially the smaller new formations, may be removed best by chromic-acid crystals directly applied, at frequent sittings. A small pellet of cotton is attached to the end of the applicator, and a particle of chromic acid, of convenient size, is picked up on this and carried down to the tumor. The crystals adhere to the lint until they come in contact with a moist surface. In carrying the instrument through the mouth, care must be taken to avoid touching the mucous surfaces. Epithelioma, in its early stages of development, may be successfully destroyed by this escharotic. The operator should take advantage of the anæsthetic properties of cocaine to render the pharynx and larynx tolerant of manipulation. Nitrate of silver may also be used, but is inferior to chromic acid.

Avulsion, or tearing away the neoplasm, is a useful and frequently-employed method. For this purpose various forms of forceps have been used. Pedunculated tumors may be snared and cut away with the wire loop of Jarvis. Fibromata often adhere so tenaciously that they can not be torn away without damage to the larynx. Care should be taken to regulate the force so that injury to the vocal bands or the smaller cartilages may be avoided.

The operation of *thyrotomy*—heretofore described—gives the best command of the cavity of this organ, and allows the more thorough and safe removal of the neoplasm.

Neoplasms similar in character to those found in the larynx may occur in the trachea and bronchi. The location of the new growth may be determined from the physical signs.

The treatment is strictly surgical, and involves physical exploration of the respiratory tract, with avulsion or excision of the growth, or the introduction of the trachea-tube to prevent asphyxia.

PHARYNX AND ŒSOPHAGUS.

Pharynx.—Neoplasms of the walls of this cavity are comparatively rare. They occur usually in the vault, and are attached to the mucous membrane, or periosteum, beneath the basilar process. The treatment consists in removal by the snare or by the galvano-cautery. When a tumor of any considerable size is to be removed by the knife, it may be necessary to perform tracheotomy, insert a tube, and tampon the pharynx as a preliminary measure. In some instances deligation of both external carotid arteries is advisable. In one instance I was compelled to do this to avert almost fatal hæmorrhage from a very vascular tumor of this region. In this case the tumor was exceedingly well exposed by splitting the soft palate in the median line, and, with a keyhole-saw, I then made parallel sections through the bony palate, one quarter of an inch on either side of the median line, for a depth of three quarters of an inch. The portion between these lines, together with the contiguous portion of the vomer to which the neoplasm was attached, was excised.

Foreign bodies are not infrequently lodged in this organ. They may be discovered by inspection with the pharyngoscope, or felt with the index-finger. Retropharyngeal abscess follows in a certain proportion of cases in which the foreign body is not removed soon after its introduction.

The *treatment* is removal by the aid of the mirror and the curved forceps.

ŒSOPHAGUS.

Rupture of the œsophagus, though several instances are recorded, is exceedingly rare. The accident occurs in forced efforts at deglutition after great distention of the stomach by over eating and drinking. The *symptoms* are intense pain in the region of the rupture—which is usually in the long axis of the tube and near the diaphragm—followed by rapid and fatal collapse. Vomiting does not occur, although the contents of the stomach may be emptied, in part, into the mediastinum. Surgical interference is not justifiable.

Foreign Bodies.—The lodgment of bodies in the œsophagus, resulting in partial or complete occlusion, is of frequent occurrence. The *symptoms* depend in great part upon the character of the foreign substance. A sharp and narrow body—as a bone, pin, needle, or splinter of wood—will produce pain at the seat of lodgment, but will allow the passage of liquid and semi-solid ingesta. Soft, compressible particles of large size may completely occlude the tube, and cause pressure upon the trachea sufficient to induce marked asphyxia. The diagnosis must, in part, be based upon these symptoms and the history of the accident. Pressure over the seat of lodgment of a sharp substance will exaggerate the sense of pain, while the inability to swallow liquids will indicate the complete occlusion of the tube. The introduction of the elastic œsophageal sound (Fig. 525) will demonstrate the presence of any occluding body.

In order to introduce this instrument, lubricate it with the white of an egg, and cause the patient to throw the head back so as to bring the axis

of the mouth and pharynx in line with that of the œsophagus. Insert the bougie so that the point will glide over the root of the tongue and strike the posterior wall of the pharynx behind the larynx. The tongue should not be drawn out of the mouth. Spasm of the glottis will prevent the instrument passing into the larynx, while, if kept in the median line and pushed carefully down, it will pass into the œsophagus.




FIG. 525.—œsophageal sound and bulbs.

The location of the foreign body will be indicated by stoppage of the sound. The *prognosis* is favorable when the occlusion is not complete. If the distention is great enough to interfere with respiration, the gravity of the accident is increased. Inflammation, abscess, and perforation of the œsophagus may occur if the obstruction is not removed within the first few days.

Treatment.—When a foreign body is lodged in the œsophagus, and does not completely occlude its caliber, it may usually be dislodged by producing emesis. If there is complete obstruction, the act of vomiting should not be excited, nor is the employment of a sound or bougie to push the object into the stomach permissible.

When the substance lodged does not occlude the œsophagus, and emesis has failed to dislodge it, the umbrella-probang (Fig. 526) should be introduced. This instrument is lubricated, closed, and passed into the œsophagus until the bristles are well beyond the point of lodgment, when they, by pressure upon the whalebone handle, are projected, completely




FIG. 526.—Bristle probang, for removing foreign bodies.

filling the tube, and the probang withdrawn. If the introduction of this instrument is difficult or painful, an æsthetic should be administered.

In case of complete obstruction, where the danger of inanition is threatened, or where pressure upon the trachea must be relieved, *œsophagotomy* should be performed.

The incision should be made about five inches in extent, along the anterior border of the left sterno-mastoid muscle. If the occlusion is high up, the center of this cut should be opposite the point of obstruction. If it is below the sternal level, the tube should be opened as low down as possible. If necessary, the sternal origin of the mastoideus may be divided. The carotid artery and jugular vein are left to the outer side. The thyroid body should be drawn outward or lifted upward. The omo-hyoid, thyro-hyoid, and sterno-hyoid muscles should be held to the inner side. A sound should now be introduced into the œsophagus, in order to serve as a guide to the operator. The opening should be

made on the lateral and posterior aspect in order to avoid the recurrent laryngeal nerve. With the finger introduced into the wound, the foreign body may be felt and removed by the alligator-forceps. It is usual to leave the wound open. For the first three or four days after the operation the patient must be fed by a tube introduced through the mouth and beyond the wound.

Stricture.—Stricture of the œsophagus may be spasmodic or organic. The irritation caused by an organic stricture may not only exaggerate the degree of constriction by exciting spasm of the muscular fibers of this tube in the immediate vicinity of the stricture, but also at points remote from the seat of the organic lesion.

Organic stricture is comparatively rare. It may result from inflammation of the œsophagus caused by the ingestion of scalding water, strong acids or alkalis, the lodgment of foreign bodies, by wounds of the neck, the presence of a neoplasm, an aneurism, or by the local expression of some general dyscrasia, as in syphilis.

The *diagnosis* is determined by interference with deglutition and by physical exploration with the bulbous bougies.

The *prognosis* is unfavorable, although a fatal termination may not be reached for a considerable period.

The *treatment* consists in dilating the stricture by means of elastic bougies, introduced at intervals of two or three days. These instruments should be softened by being placed in warm water for a few minutes before they are used. The mechanism of introduction is the same as for the bulbous bougies just described. An extra long whale-bone bougie, after the pattern of Bank's dilating urethral filiform bougie, will prove of service in strictures of such small caliber that the ordinary œsophageal bougie can not be introduced.

Internal œsophagotomy is a justifiable procedure in cases of organic stricture which will not yield to careful and persistent efforts at dilatation. In its performance, the œsophagotome of Prof. Sands (Fig. 527)

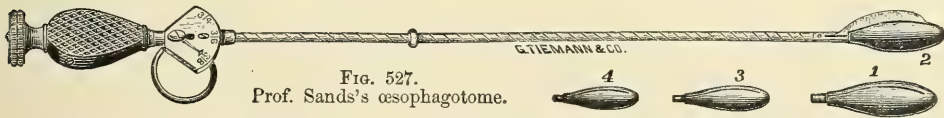


FIG. 527.
Prof. Sands's œsophagotome.

should be preferred. As described by this surgeon,* the shank of the instrument, which is fifteen inches and a half in length and four millimetres in diameter, is a flexible tube, made of narrow, spiral steel plate, secured within by two pieces of fine wire, in order to prevent stretching or separation of the spiral coil. The instrument is provided with a variable number of steel bulbs, each bulb being furnished with a corresponding knife-blade. The bulb is firmly fastened by a screw to the distal end of the shank, and the knife is attached to an inner flexible steel rod, manipulated by a thumb-screw at the proximal end of the instrument. By turning this screw, the knife is drawn out from its concealed position within the bulb, the back of the blade sliding over a firm inclined plane.

* "New York Medical Journal," February, 1884.

An index on a dial-plate indicates the amount of projection of the blade, the maximum being two millimetres and a half. A small sliding ring on the spiral tube is used to indicate the distance of the stricture from the incisor teeth. The bulb being conical, the operator can readily perceive when it comes in contact with the stricture, before he projects the blade. In operating, a bulb must be employed which exactly fits the stricture; the depth of the incision will then just equal the distance to which the blade is projected by the action of the screw in the handle. The bulb is introduced beyond the stricture, and the instrument withdrawn until the shoulder of the bulb indicates that it is in contact with the inferior or gastric border of the stricture. It is then turned so that the knife is posterior, the screw in the handle which projects the blade is turned to the required extent, and the constricting band divided by pulling the instrument outward until resistance ceases. The blade is then concealed and the œsophagotome withdrawn. The dilating bougies may be introduced at once, or this may be postponed for twenty-four hours. The danger to be guarded against is an incision through the wall of the œsophagus. With the instrument of Prof. Sands this is scarcely possible, especially when the smaller bulbs are used, since the greatest projection of the blade is only a little more than one twelfth of an inch.

When the occlusion is so complete that the œsophagotome can not be employed, or if for any reason this method of procedure is contra-indicated and inanition is threatened, the operation of gastrostomy is imperative. It is not only to be commended in permanent occlusion of the œsophagus from stricture, a diverticulum, or neoplasm, but in those cases in which extensive inflammation has resulted from the ingestion of corrosive substances. In this last condition the operation is intended to keep the organ at rest during the process of repair, in which nothing but water is passed through the œsophagus.

Operation.—Beginning near the xiphoid appendix, an incision four inches in length is made, parallel with and from one half to one inch distant from the costal cartilages of the left side. Strict antisepsis should be employed, and all bleeding thoroughly stopped before the parietal layer of the peritonæum is divided. When this is done the index-finger should be introduced and the stomach sought for. If the obstruction to the œsophagus is of long standing, the organ will be found contracted and much smaller than normal. When the anterior wall is made out, it should be seized with a forceps or tenaculum, drawn up to the wound in the abdomen, and held in this position by an assistant. The wound in the abdominal wall should now be closed from each end, leaving an opening from one and a half to two inches in length. The sutures should be of silk, and should pass through the integument and the parietal reflection of the peritonæum wherever the serous membrane has been divided.

The anterior wall of the stomach is now secured to the margins of the wound in the following manner: Fine sutures of iron-dyed silk are carried at intervals of from one eighth to one quarter of an inch through the integument at a like distance from the edge of the incision, passing through the parietal peritonæum and into the wall of the stomach, be-

tween the muscular and peritoneal layers of this organ. The needle should run beneath the peritoneal layer of the stomach for about one eighth of an inch. These sutures are carried entirely around the elliptical opening, in this way uniting the peritoneal layer of the stomach with that of the abdominal wall and the integument. A separate row of sutures stitching the edges of the parietal peritonæum to that covering the stomach is preferred by some operators. It is best not to open into the stomach until after the expiration of from thirty-six to forty-eight hours, by which time union will have occurred between the contiguous layers of peritonæum, and the danger of infiltration into the cavity of the abdomen avoided. If the necessity for nourishment is extreme, and rectal alimentation can not be relied upon to sustain the patient, a quantity of milk or liquid food may be injected by means of a medium-sized aspirator-needle passed through the anterior wall of the stomach. When the incision is made it should be from three quarters to an inch in length. An hour-glass-shaped hard rubber nipple, with a lumen of at least one third of an inch, should be inserted. A cork fitted to this will prevent regurgitation ; or a rubber tube may be substituted.

Liquid or semi-solid articles of food may be introduced directly into the stomach, or, as practiced in the remarkable case of Dr. L. L. Staton, of North Carolina, the food may be masticated and thus submitted to the action of the saliva, and may then be forced from the mouth into the stomach through a tube.

New Formations.—*Epithelioma* is the most common neoplasm met with in the œsophagus. *Colloid* and *medullary* cancer and *sarcoma* are rare in this organ. Cancer occurs usually between the thirty-fifth and sixty-fifth year of life. The favorite location is near the diaphragm. The symptoms of malignant growth are chiefly those due to obstruction and the development of the cancerous cachexia.

Non-malignant neoplasms are slower in development, and, beyond the dysphagia they may produce, do not affect the general condition of the patient.

Treatment.—Malignant new growths of the œsophagus always justify a grave prognosis, especially so when situated in the lower portions of this organ. Beyond palliative treatment by dilatation with bougies, or gastrostomy after deglutition is seriously impaired or impossible, nothing can be done. Non-malignant neoplasms are also not amenable to surgical interference when situated below the level of the upper border of the sternum. When the upper portion of the œsophagus is involved, operation is indicated, not only to relieve dysphagia, but in the effort to remove the disease.

Œsophagectomy, or exsection of a portion of this organ, may occasionally be justified in the removal of a malignant growth of limited extent and situated in the upper portion of the tube. The probability that, before the character of the neoplasm is discovered, infiltration of the neighboring tissues will have occurred, almost precludes a favorable result, and is therefore a strong argument against the propriety of the operation.

Diverticula, or pouches communicating with the cavity of the œsophagus, are occasionally met with. They may be congenital, but are more frequently acquired. They communicate with the œsophagus usually on its posterior wall. Cervical œsophageal diverticula open into the main tube at the junction of the œsophagus with the pharynx, whence the pouch may extend between the vertebral column and the œsophagus as far down as the bifurcation of the trachea. Thoracic œsophageal diverticula occur most frequently opposite the origin of the bronchi.

The *causes* of these abnormal pouches are various. As stated, they may be the result of a failure in normal development. A stricture of the œsophagus may lead to a dilatation and pouching of this organ in that portion immediately above the seat of constriction. Degeneration of the muscular fibers of the tube in a limited area may lead to a hernia of the mucous membrane, in which, by the impaction of ingested matter, a diverticulum is formed. Ulceration of the lining membrane at any point, and from any cause, may lead to the development of a sac or pouch by the infiltration of ingesta behind the mucous membrane.*

The diagnosis of these diverticula is made with great difficulty, and little hope of relief is offered, even when the character of the lesion is recognized.

The presence of the tumor is indicated by dysphagia, and this symptom may vary in severity with the act of deglutition which carries food into the pouch. Dyspnœa may be present as the result of pressure upon the trachea and bronchi, and phonation may be interfered with if the pneumogastric or recurrent laryngeal nerves are involved.

The *treatment* is chiefly palliative, and consists in the use of liquid diet.

Fistula of the œsophagus may occur as a result of a penetrating wound, or from an abscess or ulceration which destroys a portion of the œsophageal wall. A few instances of supposed congenital fistula have been reported.

The *diagnosis* will depend upon the passage of ingested matter through the outer opening, or the successful introduction of a probe from without.

The *treatment* is surgical, and on the same principle as applied to all fistulous tracks; they should be laid open by incision, packed to arrest bleeding, and afterward allowed to close by granulation. Or, as in the recent procedure for the relief of fistula in ano, the lining membrane of the fistula may be dissected away and the wound closed throughout with catgut sutures.

* Rokitansky has advanced the theory that thoracic diverticula result from atrophy of the bronchial lymphatic glands, which are situated on the anterior and lateral aspects of the œsophagus.

CHAPTER XVI.

THORAX.

Mammary Gland—Congenital Defects.—One or both of these organs may be absent; one may develop fully while the other remains in its primitive condition; there may be three, four, or five, the supernumerary glands being placed upon the back, abdomen, axilla, or thigh. The nipple may be absent or retracted, and may be bifid or multiple, as many as a half-dozen occurring within the limit of the areola.

The author presented to the New York Surgical Society a case in which a supernumerary gland was situated in the axilla. The development of this organ simultaneously with the normal breasts produced great pain by pressure upon the branches of the axillary plexus. Relief followed extirpation of the abnormal gland.

Inflammation of the nipple is usually traumatic, occurring at the early period of lactation, and being caused by pressure from the gums of the infant. It may also be involved in the extension of a mammitis along the galactiferous ducts.

The first indication in treatment is to give the organ rest. A rubber shield may be used to prevent injury while nursing, or the child kept away from the breast, the distention of the gland being relieved by artificial means. Poultices of flax-seed or other emollients should be applied during the acute inflammatory process.

Abscess of the nipple and the contiguous skin and subcutaneous tissue is an occasional sequence of inflammation of the nipple.

The treatment is evacuation of the pus by one or more incisions made in the axis of the efferent ducts.

Eczema, or *fissure* of the nipple, is of frequent occurrence during lactation. It is always annoying, and at times causes severe pain. Every source of irritation should be removed. If the integument is inflamed, poultices should be applied, and, after the acute inflammation subsides, the closure of the fissures may be hastened by the local use of glycerite of tannin or other astringent. Chronic inflammatory processes of the nipple which are intractable, resisting all constitutional and local remedies, demand free incision and ablation of the diseased area.

Epithelioma is the most frequent form of malignant neoplasm of the nipple. The treatment is free excision.

Papilloma, *fibroma*, *angioma*, *cysts*, etc., may occur in this organ, and should be removed by the knife as soon as discovered.

Mastitis.—Inflammation of the breast may be acute or chronic, traumatic or idiopathic. A single lobule or subdivision of the gland or the entire organ may be involved. In the more severe forms of inflammation the process may extend along the ducts to the nipple and backward into the submammary tissues.

Traumatic mastitis is usually circumscribed, the integument and subcutaneous areolar tissue being also involved. The deeper tissues escape unless great and unusual violence has been inflicted.

Idiopathic mastitis is almost always connected with lactation, occurring usually during the first few weeks after parturition. In rare cases it occurs at intervals in non-pregnant females, the symptoms of this disorder being associated periodically with the menstrual function. Mastitis is also a symptom of *parotitis* or “*mumps*.”

The milder forms which occur during lactation are little more than exaggerations of the normal functions of this organ, while the more typical pathological process, commencing in the hyperæmia of the secretory apparatus, is exaggerated by obstruction to the escape of the milk through the galactiferous ducts. This obstruction may occur at any portion of the efferent ducts, although the occlusion is usually situated in or near the nipple. Distention of the duct and its subdivisions leading back to the *acini* follows, and inflammation ensues in the entire limit of obstruction.

Symptoms.—The first indications of inflammation of the mammary gland are pain and localized induration. The pain is constant, and usually severe in character, and may extend along the ribs to the axilla. The induration is usually well defined, and may consist of one or more nodules. Injection of the skin is marked over the area of induration. The temperature is elevated one or two degrees, the pulse increased in frequency, and a well-pronounced chill or a series of rigors is apt to be a feature of the earlier stages of this disease.

Treatment.—As soon as inflammation is threatened the breast should be supported by a bandage, or long, soft towel, or handkerchief thrown around the neck and shoulder and beneath the gland, holding it in the position of least discomfort. In the stage of hyperæmia the application of a light ice-bag, with limited compression of the organ, is advisable. The nipple should be kept moistened with a tuft of cotton saturated with vaseline or oil, which is placed in position before the ice-bag is applied. Careful attention should be given to the frequent evacuation of the milk. When the nipple is inflamed, artificial means should be employed to empty the breast. If the inflammatory process does not yield to this treatment after the first few days, it should be abandoned and warm poultices applied. It is important to recognize the earliest collection of pus, and to relieve it by aspiration or incision. Indeed, when the induration is localized and well marked, it is good practice to explore under cocaine with the large hypodermic needle to determine the presence of suppuration. If no pus be found, the puncture does no harm, and of itself often affords relief from tension.

When *abscess* exists the pus should be freely evacuated by aspira-

tion or incision. If the collection is deep-seated, requiring an incision through a considerable area of gland-tissue, aspiration may be tried and repeated for two or three times. By the relief of tension, resolution may be induced. When fluctuation is evident, and only the integument intervening, incision is preferable. This may be done without pain, and offers the speediest and surest means of cure. The incision should be parallel with the direction of the galactiferous ducts. When the cavity is opened, the nozzle of the irrigator should be introduced and the abscess thoroughly washed out with 1-to-3000 sublimate solution. Drainage should be secured, and a loose dressing applied. The point of incision should be made in the lower portion of the sac, so that drainage may be free. At times it may be necessary to make a counter-opening. Less frequently abscess may form in front of the glandular tissue beneath the integument or between the capsule of the gland and the thorax. Ostitis or periostitis of the ribs may be the cause of deep-seated submammary abscess.

Hypertrophy of the mammary gland is a normal process, usually occurring at puberty and during pregnancy and lactation. In rare instances there is an extensive hyperplasia of the connective-tissue elements of this organ, resulting in great enlargement. The *diagnosis* may be based upon the hard character of the mass, there being none of the softness and elasticity which belong to the normal breast. The hyperplasia is general, involving the entire framework of the organ, which will render it easy of differentiation from any form of neoplasm, for these grow from recognized centers of induration. The diagnosis meets with confirmation if the enlargement takes place after puberty, and in a non-pregnant woman.

In the *treatment* of this condition the hyperplasia may be arrested in the earlier stages by well-adjusted and prolonged compression. This may be effected by a thick layer of absorbent cotton laid over the breast and held firmly down upon it by a roller, applied as directed on pages 17 and 18. In advanced cases, a free excision of the organ is demanded.

Tumors of the Breast.—New formations in the mammary gland are among the more frequent surgical diseases. The microscopical characters of tumors are elsewhere described. Unfortunately, they are more frequently *malignant* than *benign*. Although tumors of the breast occur chiefly in females, they are not uncommon in males. Among the non-malignant tumors are *adenoma*, *myxoma*, *fibroma*, and *enchondroma*. Various forms of cysts are also met with, while syphilitic gumma and tubercular deposits may occur in this organ. Carcinoma (scirrhous, encephaloid, colloid, and epithelioma) and sarcoma are the malignant neoplasms which are found in the breast.

Adenoma of the mammary gland is rare. The pathological change, a hyperplasia of the glandular tissue proper, is usually circumscribed. The tumor is of small size, freely movable with the breast, and does not form adhesions with the capsule, integument, or submammary fascia. There is no inflammatory process connected with its development, no

enlargement of the axillary glands, no dilatation of the veins of this region, and little or no pain. It is found in nursing women as a rule, but may occur in early puberty and in women who have not borne children. It is not the rule for cystic degeneration to take place in this neoplasm, although such cysts may be met with in rare instances as a result of degeneration of the new-formed cells of the deeper portions of the growth.

Adenoma, of itself a benign neoplasm, is thought by some pathologists to be capable either of developing into carcinoma, or of exciting the carcinomatous change in the organ. Not only in the simple circumscribed form of this neoplasm, but in that variety sometimes called tubular adenoma, in which the hyperplasia of the glandular cells is not confined to the acini and terminal ducts, but extends into and involves the galactiferous ducts as far as the nipple, and which is more generally diffused than in the simpler form above described, it is admitted that the transformation into carcinoma is possible and at times rapid.

Treatment.—The tumor should be excised. When a considerable portion of the gland is involved, the entire organ should be extirpated on account of the tendency to recurrence in this neoplasm. If the tumor is small it may be removed by sacrificing only that part of the gland-tissue immediately around it. Upon the recurrence of the growth, the entire breast should be excised.

Myxoma is very rarely met with in the mammary gland. It may occur as a single nodule and develop slowly from a single center, or it may develop from several centers and rapidly invade the entire organ. It is not adherent to the skin until inflammatory adhesions occur preliminary to ulceration of the mass. Infiltration of the axillary glands occurs only as a result of inflammation. The nipple is not retracted.

The prognosis is favorable if the tumor is discovered early in its development, and if in the excision a sufficient portion of healthy tissue is removed with the neoplasm. The *treatment* is free excision. The entire gland should be sacrificed, and, if the organ is wholly involved, the line of incision should be well out from the limits of the tumor in the healthy tissues.

Fibroma of the mammary gland may occur at any period of life. It is rarer in the aged than in the young, occurring mostly in persons under forty, and occasionally under puberty. This form of connective-tissue hyperplasia may affect the entire organ (as in general hypertrophy, already described) or a circumscribed area. A nodular or circumscribed fibroma is a hard, dense tumor, freely movable with the gland, and may or may not be painful. Shrinkage of the breast occurs at times as a result of the cicatricial contraction of the new-formed tissue, and, when near the nipple, its retraction may resemble that of scirrhus. As a rule, this variety of tumor is of slow development. Not infrequently it undergoes cystic degeneration. The axillary glands are not involved, nor do adhesions occur until after atrophy of the gland with retraction of the new-formed connective tissue. It should be removed by the same wide and free excision as recommended for myxoma.

Enchondroma of the breast is very rare. It is apt to be circum-

scribed. Calcification has been observed in some of the few recorded cases of this neoplasm. Occasionally it is found with carcinoma. Enchondroma of the breast should be freely excised.

Cysts.—Among the forms of cystic tumors found in this gland are galactocele, sanguineous, dermoid, and hydatid cysts, and the forms which occur in the degeneration of adenoma, fibroma, myxoma, and carcinoma.

Galactocele is a cyst caused by obstruction of the ducts which convey the milk toward the nipple. The obstruction is followed by distention of the tubes and *acini*. Examined with the microscope, the contents of these cysts consist of epithelial cells in various stages of granular metamorphosis, and milk-globules.

The diagnosis may be determined by aspiration. The treatment consists in incision and evacuation of the contents with drainage until the cyst may be obliterated by the process of granulation.

Dermoid and *hydatid* cysts are exceedingly rare in this situation. The diagnosis may be determined by aspiration, and the proper treatment is excision. Cysts may occur in the breast from the extravasation of blood after contusions, or from the non-traumatic rupture of blood or lymph vessels. They heal readily after incision and drainage.

Tuberculosis of the breast is rare. The nodules may be disseminated generally through the gland or beneath the capsule, or there may be one or more large collections. They are hard to the touch. The history of the case will aid in determining the character of the lesion. If there is no general dissemination of tubercular matter—that is, if the disease is limited to the mammary gland—this organ should be freely excised.

Sarcoma of the breast attacks usually the young and middle-aged. It is rarely general in its development, but commences as a single nodule, more apt to occupy the upper portion of the organ than the lower, whence it invades the gland and circumjacent structures in every direction. The rapidity with which it grows depends in part upon the microscopical character of the neoplasm, and in part upon the age of the patient. Sarcoma develops more rapidly in the young, and the round-cell sarcoma, which variety is most frequently met with in the breast, is more rapid in its development than the spindle-cell sarcoma. In the earlier stage this tumor, though firm and nodular, is freely movable with the gland. Its growth, however, is often so rapid that the skin and subcutaneous tissues, the submammary fascia, and the muscles of the chest become involved, the breast stands out full and tense, and becomes immovable. The superficial veins are greatly enlarged. As a rule, the lymphatic glands of the axilla are not involved until suppuration of the mass induces axillary adenitis.

Differentiation between round and spindle-cell sarcoma is difficult unless the tumor is examined with the microscope. Practically, the differentiation is not important. The first variety is softer to the touch, more rapid in growth, and is more vascular. It is apt to occur in the younger class of patients.

Both forms of sarcoma tend to the formation of cysts within their structure. As stated, they may be due to fatty degeneration of the em-

bryonic elements of the tumor, or may result from caverns of blood which have become cut off from the general circulation through the tumor.

The diagnosis of sarcoma of the breast depends upon the age of the patient, the rapidity of its growth, and the absence of axillary engorgement. The treatment consists in free excision.

Carcinoma is by far the most common form of neoplasm met with in the breast. The order of prevalence of the four varieties is *scirrhous*, *encephaloid*, *colloid*, and *epithelioma*. Cancer of the mammary gland occurs in rare instances in males. In women it is met with most frequently in the period from the fortieth to the sixtieth years of life. It may occur later than this, and is rarely seen earlier than the age of thirty. Women who have never been pregnant are affected, though probably not so liable as those who have borne children.

Scirrhous of the breast appears usually as a single hard nodule or lump, situated in the substance of the gland, movable within this organ, but firmly imbedded in it; or two or more nodules may appear simultaneously in different parts of the gland, which eventually approach each other so as to form a nodulated mass. The growth of scirrhous is, as a rule, not rapid in the earlier stages of its development, but, after reaching a certain size, it spreads with increasing rapidity. The length of time which may elapse between the commencement of the neoplasm and metastasis in the subpectoral and axillary lymphatics varies in different individuals. It is, however, in general proportionate to the rapidity of the growth of the neoplasm. Pain, which is a symptom of this disease, is lancinating in character rather than dull and continuous. It is usually more severe in tumors which develop rapidly.

Cancer of the breast may assume the form of a single large, rounded, and nodular mass, or nodules of various sizes may develop in the organ or be scattered in knots or groups beneath the integument, in the pectoral muscles, or along the line of lymphatics leading into the axilla. If left unmolested, scirrhous soon invades the tissues around the breast, the muscles of the chest becoming infiltrated, the skin attached to the mass, and the nipple retracted. On account of pressure the circulation in the most remote portions of the invaded gland is interfered with, and ulceration ensues, giving rise to a more or less extensive granulating surface, from which there is a discharge of a serous-like fluid containing blood-corpuscles, embryonic, pus, and cancer cells. In the later stages lymphatic engorgement is more extensive, and the effects of compression upon the thoracic and axillary nerves more evident. Not infrequently the subclavicular, supraclavicular, and cervical lymphatics become engorged. Pressure-symptoms are not alone confined to the nerves, but the interference with the return circulation in the axillary vein may produce general œdema of the extremity.

Encephaloid cancer of the breast differs only in degree from the scirrhous variety. It is softer under pressure, grows with much greater rapidity, ulcerates earlier and more extensively, is more prone to hæmorrhages, and tends to a more rapidly fatal termination. It is more apt to recur after removal.

Epithelioma of the breast is rare. It commences in or near the nipple, and may extend along the epithelial lining of the lactiferous ducts, or spread along the integument of the areola. Although ulceration begins earlier, its progress is slower and less painful than in either of the forms of cancer just given, which attack the deeper structures of the gland. If not extirpated, the entire gland may be infiltrated, metastasis occurs, and death follows from general exhaustion.

Prognosis and Treatment.—The prognosis of cancer of the breast is always grave, the gravity varying with the character of the neoplasm, the general condition of the patient, and the length of time the tumor has existed before excision. Left without surgical interference, a fatal termination is reached usually within from one to two years after the appearance of the disease. Encephaloid is most rapidly fatal, scirrhus next in order, and epithelioma last. Death ensues from exhaustion caused by suppuration, pain, anorexia, and infiltration of the various organs by metastasis. In isolated cases scirrhus of the breast reaches a certain point and remains stationary for a number of years before again enlarging and producing a fatal issue.

With the operation as performed in modern practice, the prognosis is much more favorable. This practice implies early recognition of the presence and character of the neoplasm, immediate and wide extirpation of the invaded organ, and a careful dissection of all metastatic foci in the glands of the axillary plexus. As to the selection of cases in which operation is justifiable, it may be admitted that interference is called for in all cases in which the lymphatic engorgement has not extended beyond the axillary region, and in which the invasion of the pectoral and thoracic muscles is not so deep or extensive that a clean excision is possible without opening into the thorax. Even when metastasis of the cervical lymphatics has occurred, relief will be gained in those instances in which ulceration is taking place; but, in these cases, the palliative operation should not include invasion of the axilla. It is well to bear in mind that a simple non-malignant enlargement of the glands may occur before true metastasis has taken place.

It should be the practice in all cases of cancer of the mammary gland to open into the axilla in order to be sure of the condition of the glands, for these organs may be the seat of cancerous infiltration which can not be recognized without incision.

As to treatment, the following line of practice should be adopted:

A tumor of the breast occurring in either sex after the thirtieth year of life should be excised as soon as discovered. The contraindications to this procedure are: (1) a condition of prostration so extreme that a surgical operation would involve great and unusual risk to life; (2) metastasis to such an extent that complete removal of the neoplasm is impossible.

The incision should be well away from the limit of the tumor in the healthy tissues. When only a small portion of the organ is involved, it is advisable to extirpate the entire gland. When the patient is under thirty years of age, and when the tumor is thought to be benign in char-

acter, the less radical operation of enucleation of the neoplasm may be undertaken. Any new formation so removed should be carefully examined, and, if found to be malignant, a wider incision should be made, either at the first indication of recurrence, or preferably at once.

Operation.—The patient is placed upon the table with the chest slightly elevated, the breast and axilla of the affected side near the edge. The arm, intrusted to an assistant, should be held at a right angle to the body, and the head directed to the opposite side. The integument of the axilla and within the field of operation should be shaved, washed with soap and warm water, afterward with ether, and finally with 1-to-2000 sublimate solution. The diseased organ should be handled as gently as possible. Sublimate towels should be laid over the exposed surface, leaving only the part to be removed in sight.

The operator now carefully outlines the tumor, since it is essential that the incision should be from one to two inches outside of the limit of induration. On this line the skin and subcutaneous tissues should be divided directly down to the muscles. The fascial covering of the thoracic muscles should be dissected up with the gland. If the infiltration has involved the deeper portions of the organ, the pectoral muscles within the line of incision should be dissected out, leaving nothing but the ribs and intercostal muscles. All vessels should be secured and tied with catgut as fast as divided. Oozing may be arrested by pressing sponges or sublimate towels into the wound as the operation proceeds.

The dissection should be made and the mass lifted from the sternum toward the axilla. In this way the larger vessels (the long thoracic artery and branches) are not divided until the incision, which completely severs the tumor, is being made.

All hæmorrhage in the wound being arrested, and this filled with warm sublimate towels to prevent oozing, the dissection should be continued into the axilla. During this, the most difficult part of the operation, the arm should be held immovably at an angle of 90° to the axis of the spine. From the end of the elliptical wound nearest the axilla, an incision is made along and below the border of the pectoralis major muscle, extending as far as the arm. The integument below this incision should be dissected up from the underlying areolar tissue down to the posterior fold of the axilla, blunt retractors placed above and below, and the edges of the wound separated as widely as possible. It is advisable to remove the adipose tissue which fills in this space along with the enlarged glands. The chief danger is the wounding of the axillary vein or one of its branches so close to the main trunk that air may be admitted or the ligature have to be applied to the axillary vein. If the dissection is made with blunt scissors curved on the flat, keeping the convex surface nearest the vein, and, if the vessel is approached from the scapular border, this danger may be avoided. In this region the subscapular vein is easily recognized, and may be followed toward the large trunk. In the lower portion of the axilla the brachial fascia protects the vein. If the enlarged glands extend high up in the axilla, the pectoralis major and minor should be cut across and a clean dissection

made as high as the clavicle if necessary. When a hard gland is found lying directly upon the sheath of the vein, it may be removed by the thumb and finger-nail. When working close to the axillary vein and artery, all hæmorrhage may be avoided by applying forceps on each side of the track of the incision before the scissors are used, and immediately tying the tissues grasped with catgut. Occasionally the vein will be found so studded with metastatic foci that removal without injury to this vessel's wall is impossible. When this condition exists, either the operation will have to be abandoned or the vein and its branches tied above and below the neoplasm, and the intermediate portion excised.

In one of my cases this operation was performed. The axillary vein was tied near the clavicle, and the brachial just below the tendon of the pectoralis major, and double ligatures to all intervening branches. The neoplasm had not recurred two years after the operation. The venous circulation was well established through the cephalic vein. The patient was in excellent health. When the operation is completed, a drainage-hole should be made from the deepest portion of the wound (estimating this from the position the patient is to assume after the operation) by carrying the tip of a closed dressing-forceps through the tissues until the skin along the axillary border of the scapula is lifted by the instrument. This should be incised and the hole enlarged by separating the jaws of the forceps. A good-sized rubber drainage-tube should be pulled through from below as the forceps are withdrawn. As much of the wound is closed by sutures as possible, a final irrigation of 1-to-3000 sublimate is made, a loose dressing placed in the open portion of the wound, and the usual dressing of gauze and borated cotton, and protective placed over all.

When a benign tumor is to be enucleated from the breast, the incision may usually be made along the crescentic fold at the lower border of this organ, the gland turned up, the tumor removed, and the breast restored to its former position. The scar is concealed in the natural fold between the integument of the thorax and the breast.

Abscess of the thoracic walls usually results from ostitis of the clavicle, sternum, ribs, scapulæ, or vertebræ, or enchondritis of the costal cartilages. If not incised, they open spontaneously through the integument and discharge pus and at times particles of bone and other *détritus*. Spontaneous cure may occur, although this is the exception. Sinuses usually result, and continue until the diseased tissues are excised. The most common seat of ostitis is in the sternum and the sternal ends of the ribs. The indications in treatment are to lay the sinuses open, carefully following each to its terminus, scrape the indurated lining membrane away with a scoop, and remove all dead bone by scraping with the Volkman spoon or exsection in mass. Opening into the pleura or mediastinum should be avoided. When the abscess leads behind the sternum, as in a case which came under my care, a segment of this bone should be removed in order to expose and drain the cavity. In exsection of a portion of one or more ribs, the incision should be made along the center of the bone, the periosteum lifted with the ele-

vator (first from the anterior surface and then from behind), and the bone divided with the exsector or cutting-forceps. All of these wounds should be packed with sublimate gauze.



FIG. 528.—Portions of the left clavicle removed on account of ostitis.

Exsection of the clavicle may be demanded in ostitis of this bone. In a case operated upon by myself for necrosis resulting from a dislocation at the sternal end, the incision extended the entire length of the bone, and the excision was subperiosteal throughout. A new and strong clavicle formed, with perfect motion at the sternal and acromial articulations. The shortening was a little less than one inch. Six years after the operation the function of the injured side is perfect (Figs. 528, 529).




FIG. 529.—The author's case, in which a new clavicle was formed after subperiosteal excision.

Empyema.—Pus may collect in the pleural sac as a circumscribed abscess, or exist in the general cavity of the pleura.

The diagnosis may be determined from the elevation of temperature usually present, by dullness on percussion over the fluid, and by aspiration, using the smaller needles. The treatment consists in evacuation of the purulent contents with the aspirator, or by incision. If the symp-

toms of septic absorption are not urgent, aspiration may be tried and repeated at intervals until recovery ensues, or until a failure of this method is demonstrated. The contents of the pleural cavity should not be too rapidly evacuated. Fatal syncope has occurred in several instances during this operation. Incision should be done in all urgent cases, and in those instances in which aspiration fails. The object of this operation is to drain the cavity of the abscess at its most dependent portion. An effort should be made to determine the lowest point by the introduction of the needle in several of the intercostal spaces. The opening should be made about opposite the center of the rib, preferably a little posterior to the middle. The incision should be in the intercostal space, half-way between the ribs. When the costal pleura is divided, it will be indicated by the escape of pus and the entrance of air. Partial

collapse of the lung of the affected side follows. As soon as the incision is completed, the finger of the operator should be introduced in order to determine if the opening is near the bottom of the cavity. If not, it is usually advisable to make a second, or counter opening, on a lower level. A drainage-tube, or preferably two tubes, are carried side by side in at one opening and out at the other, and secured by transfixion with safety-pins. If a single opening is made, the double tube should always be used. The cavity should now be washed out with 1-to-3000 sublimate, and a dressing applied. Later, a stronger solution may be used. I have repeatedly irrigated with 1-to-1000 sublimate, with no poisoning.

If the ribs are so close together that free drainage can not be secured, a portion of one rib should be excised. The opening should be large enough to admit the index-finger. It is usually advisable to do this, since the collapse of the chest-wall which follows is exceedingly apt to occlude partially, if not completely, the opening through the intercostal space. Portions of several ribs should be excised when necessary to thorough drainage.

Ostitis or other diseases of the scapula do not require especial consideration. Removal of any portion or all of this organ may be effected.

WOUNDS OF THE CHEST.

Wounds of the chest are divided into penetrating and non-penetrating. A penetrating wound is one which opens into the pleural cavity or mediastinum. Pneumothorax, with hæmorrhage into the pleural sac, may occur, however, without an external opening, as when, after a contusion of the chest a rib is fractured, causing rupture of the intercostal artery and penetration of the lung.

Contused wounds of the chest may be accompanied by fracture of the ribs, lacerations of the muscles, or followed by pleuritis with or without either of the above complications.

Non-penetrating wounds of the chest, whether incised, lacerated, or punctured, are treated as directed for such lesions in other parts of the body. The same may be said of gunshot-wounds which do not involve the bony framework of the thorax or pass into the cavities.

Penetrating wounds of the thorax are dangerous in proportion to the size of the entering substance, the direction and depth of the track of the wound.

Punctured wounds, not involving the heart and great vessels, are not usually fatal, while death is apt to follow even small lesions of these organs. *Incised* wounds are more dangerous, while *gunshot*-wounds are still graver lesions.

Passing in any direction into or through the mediastinum, a gunshot-wound is apt to inflict fatal violence. In the lungs and pleuræ the prognosis is not so grave, being proportionate to the size of the missile and to the nearness of its approach to the great vessels at the root of the lung.

Again, if a rib is fractured at the point of entrance, the gravity of the prognosis is increased from the lodgment of particles of bone driven into the lung. Wounds produced by missiles of small caliber, not fatal within a few hours, are apt to end in recovery.

Diagnosis.—Penetrating wounds of the chest, involving the lung, are accompanied almost always by bleeding from the mouth, dyspnoea, and by the passage of air in and out through the wound with each respiratory act. The dyspnoea is due to blood in the bronchial tubes and trachea, and often to partial collapse of the lung, which is caused by the entrance of air through the wall of the thorax.

The admission of air to the pleural sac does not, however, always follow a penetrating wound, on account of its small size or the valvular arrangement of the tissues through which it passes.

Shock is usually profound if the lung is wounded. A wound of entrance and exit, with the pleura and lung directly between, indicates lesion of these organs. Occasionally, however, a ball strikes against a rib, is deflected, and sweeps around the chest beneath the skin and makes its exit at a remote point without entering the pleural cavity.

Treatment.—The arrest of hæmorrhage is the immediate indication. This may be hastened by deligation of the extremities, already described on page 74.

Any bleeding from the vessels of the thoracic wall should be arrested by the ligature. Foreign bodies, fragments of bone, etc., near the wound of entrance or exit, should be removed. When hernia of the lung occurs, if seen before strangulation has taken place, it should be irrigated with 1-to-5000 sublimate solution and reduced. If gangrenous, the protruding mass should be tied with the elastic ligature and the dead portion removed.

Uncomplicated wounds of small size should be closed at once by an iodoform and sublimate gauze dressing, well applied. If symptoms of empyema follow, an opening may be made for drainage, provided that the presence of pus is demonstrated by the aspirator.

In complicated wounds, where the opening is large, or where fragments of bone, clothing, or any foreign substance has been driven into the pleura and lung, it should be kept open for drainage and treated by irrigation, as directed for empyema.

In *wounds of the heart* the right auricle and ventricle are most frequently injured. Punctured wounds are less apt to prove fatal than those produced by gun-missiles. Fischer has collected four hundred and fifty-two cases of wounds of the heart, with seventy-two recoveries.*

The *symptoms* of injury to the heart are those of profound shock. The pulse is irregular, and, if there is hæmorrhage into the pericardium and mediastinum, symptoms of pressure on the heart-muscle are soon evident.

The means employed to arrest internal hæmorrhage elsewhere may be used here. Quiet should be enforced.

* "Archiv für klinische Chirurgie," 1868.

CHAPTER XVII.

THE ABDOMEN.

The Stomach.—*Gastrostomy*,* which operation has been described in the article on œsophageal stricture, is required occasionally in the removal of foreign bodies which have been carried into the stomach and can not find an exit through the pylorus or be ejected in the act of vomiting. Although a considerable degree of tolerance may be present, if the size and shape of the foreign body are such that the probability of its removal by natural means is remote, the stomach should be opened.

The method of procedure is the same as that already described. Since the œsophagus is patent, the stomach should be thoroughly washed out with warm water introduced by means of the œsophageal tube and the pump. No solid food should be allowed within twelve hours of the incision into the wall of this organ. This double precaution will prevent the otherwise possible escape of ingested matter into the peritoneal cavity. The stomach should not be opened until it has been securely stitched to the edges of the wound in the abdominal wall, as heretofore directed. The foreign body may be felt with the finger and extracted with a pair of dressing-forceps. The opening should not be closed at once, but allowed to heal by granulation.

Gastrostomy may also be justifiable in certain cases of stricture of the pylorus, in which at least temporary benefit may be obtained, by dilatation of the stricture by the finger introduced through the stomach, or by mechanical means used in the same way. An incision about five inches in length should be made from the apex of the ensiform cartilage downward and to the right, parallel with and about one inch below the curve of the right costal cartilages. On account of the over-distention of the organ, the pylorus may be farther to the right of the linea alba than normal. The incision in the abdominal wall should be free; the stomach drawn into the wound, and a longitudinal incision from one to one and a half inch in extent made on its anterior wall near the pylorus. The finger should be introduced gradually and forcibly into the stricture. If the stenosis is so great that the finger can not be used, the dressing-forceps or any dilating instrument may be substituted. After the dila-

* The operations of gastrostomy and gastrotomy differ only in this, that the former is intended to be more or less permanently used for the introduction of nourishment, while the latter is either closed at once or allowed to close in a short time.

tation is completed the incision in the stomach should be closed by Lembert's suture. If the operation shall have proceeded thus far and the pylorus found to be occluded, or so nearly closed that the passage of ingesta is impossible and its dilatation can not be successfully accomplished, one of two procedures may be adopted: 1, *exsection of the pylorus*; 2, *gastro-enterostomy*.

Exsection of the pylorus (*pylorectomy*) for malignant disease involves almost of necessity a removal of a portion of the lesser end of the stomach (*gastreotomy*) with the diseased portion of the duodenum. Even for inflammatory stricture (contractions after ulcer, etc.) simple pylorectomy is scarcely possible.

The operation is preceded by washing out the stomach with warm water once a day for several days, and a thorough irrigation just before it is incised. A purgative to clear out the intestinal canal is scarcely necessary, since, as a rule, only liquids pass through the stricture. The most careful antiseptic details should be carried out. The center of the incision through the abdominal wall should be immediately over the recognized position of the part to be excised. If a neoplasm is present, it may be readily located by palpation. If no appreciable tumor exists, the pylorus will be found just to the right of the median line about the level of the costal cartilages, curving downward on the right side of the ensiform appendix (Fig. 530); the incision should extend from near the appendix, parallel with and about one inch from the border of the costal cartilages of the right side. It should be about five inches in length.

All hæmorrhage should be arrested before the parietal layer of the peritonæum is incised. When this is done, the finger should be introduced and the pylorus located by following along the anterior smooth surface of the stomach, beneath the overlapping free border of the liver. If it be discovered that the incision is not sufficiently free, a large flat sponge should be placed in the abdomen between the edges of the wound and the viscera, to prevent the escape of blood into the cavity while the opening is being enlarged. The wound should be widely dilated, the liver and gall-bladder held up out of the way (care being taken not to wound this friable and vascular organ), and the parts to be removed brought into view.

Having determined the extent of stomach and duodenum to be removed, these organs should be lifted as far as possible into the wound, and the omental attachments, on both curvatures, divided between two rows of catgut ligatures as far as the line of excision, and no farther. As soon as the peritoneal attachments are divided, a flat sponge, which has been taken from a vessel containing Thiersch's solution warm (boracic acid, grs. iv; salicylic acid, gr. j; water, grs. 500), and squeezed fairly dry, should be placed under the parts to be excised in order to prevent blood or other matter from getting into the peritoneal cavity. The wall of the stomach is next cut through in a transverse direction, and, when a sufficient opening has been made, all fluids or other matter should be removed by small soft sponges attached to holders. Some operators apply a clamp across the stomach just above, and to the duodenum just

below the line of excision. All hæmorrhage should be arrested as the operation proceeds. If a clamp is not employed, a silk loop should be thrown around the duodenum to prevent its slipping downward. When

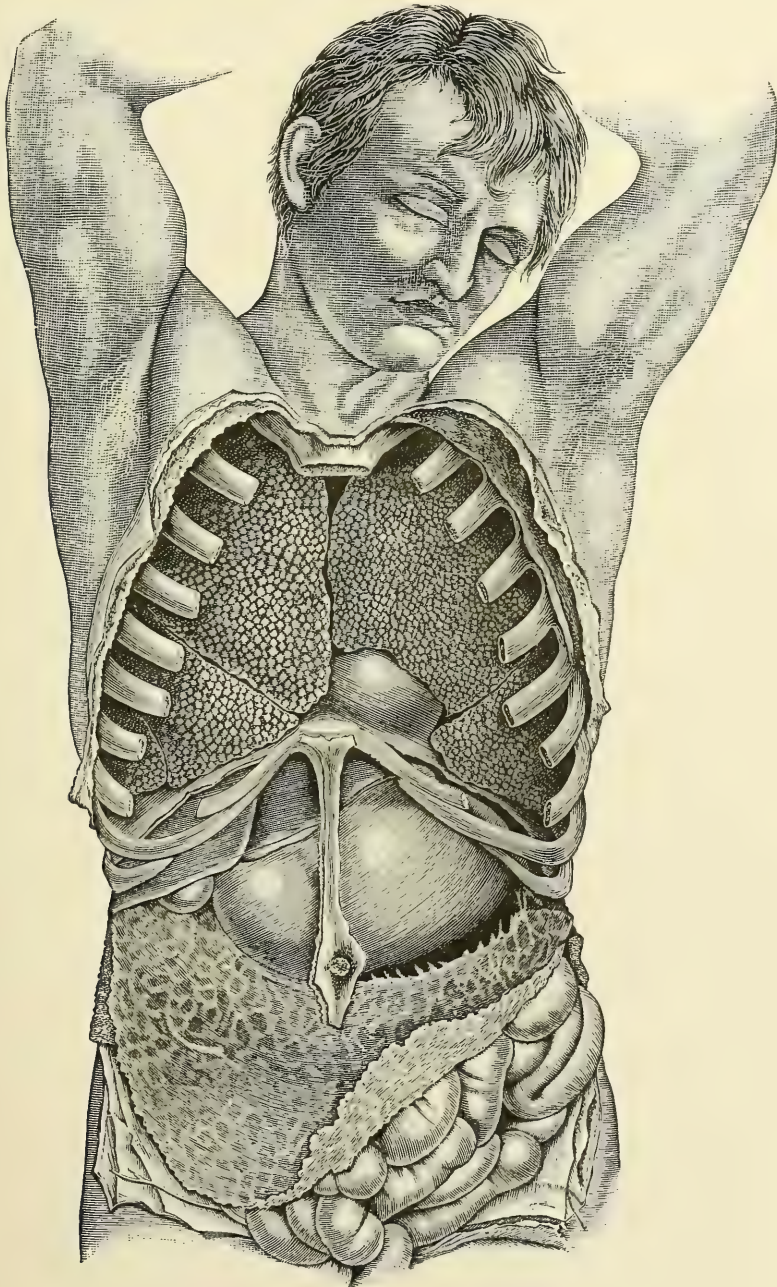


FIG. 530.—(After Maclise.)

the diseased portion is removed, the wound in the stomach should be closed from the lesser curvature downward, until the opening left is of the same size as that in the divided duodenum. The materials to be

used are fine iron-dyed silk, small needles half-curved and perfectly round on section, and the needle-holder.

The method of closure is by the *Czerny-Lembert* suture (Fig. 531). The first row are inserted from the inner side, the needle passing only

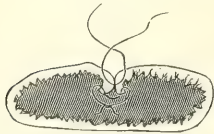


FIG. 531.—The Czerny-Lembert suture. The upper suture is Lembert's, the lower is Czerny's.

through the mucous membrane and submucous tissue, but not including the peritonæum. The posterior half of the wound should be closed first. The outer suture, which is that of Lembert, passes beneath the peritoneal covering, practically running through the muscular layer, but does not pierce the mucous membrane. The needle is introduced on one side three sixteenths of an inch from the cut edge of the viscus, and is made to

emerge one sixteenth of an inch from the margin (passing about one eighth of an inch beneath the peritoneal coat). It is then carried to the opposite side and introduced in the same manner one sixteenth of an inch from the cut edge and brought out one eighth of an inch farther on. This suture should be repeated every eighth of an inch. As fast as introduced the ends should be tied together and intrusted to an assistant. The sutures are not finally tied until all are inserted, and are then secured from above downward.

When the upper portion of the aperture in the stomach is closed, the sutures should be carried from the edges of the remaining aperture across to corresponding points upon the duodenum, and, when the entire circumference is completed, should be tied and cut off close to the knot. After a careful cleaning of the peritoneal cavity, the edges of the peritoneal layer of the abdominal wall are brought together with catgut sutures, while silver wire or strong silk sutures are carried through the integument, muscles, and fascia down to the peritonæum, and the wound closed. The stomach should be kept at rest for the first day or two. An enema of beef-tea and whisky should be given every four or five hours. From two to four ounces of the former to 3j-ij of the latter may be administered at each injection. Crushed ice in moderate quantities may be given in the mouth. After two days, milk and liquid food in small quantities may be given by the mouth, and solid food by the tenth day.

Gastro-enterostomy is an operation in which an opening is established between the stomach and some point along the small intestine, usually the upper portion. On account of the position of the duodenum and its relations to the pancreas and great mesenteric vessels, it can not be utilized. The nearest loop of the jejunum should be selected. In Wölfler's* operation (Fig. 532) the stomach was opened a finger's breadth above the attachment of the gastro-colic omentum to the greater curvature. The incision was in the long axis of the organ, and measured five centimetres (about two inches). A similar incision was made in the nearest loop

* This operation was performed in the case of a patient in whom there was a cancer of the pylorus too large to be excised. The man recovered and was much improved. "Centralblatt für Chirurgie," No. 45, 1881, p. 706.

of small intestine opposite to the mesenteric attachment. The posterior wall of the wound in the intestine was first stitched to the corresponding edge of the incision in the stomach, and the operation completed by uniting the anterior walls. Carbolyzed flat sponges were placed beneath the organs during the operation.

The incision in the abdominal wall in this procedure may be the same as that for exsection of the pylorus, or a free longitudinal incision in the linea alba may be employed.

Exsection of the pylorus is a difficult operation, requiring a most perfect knowledge of the anatomy of the parts involved, and a thorough drilling in the practice of intestinal suture and the management of intra-abdominal wounds. The long duration of the operation, together with the already weak condition of the patient, renders a fatal termination very probable; and if done for malignant disease, and recovery follow, the recurrence of the neoplasm is almost certain. For malignant neoplasm it is scarcely justifiable; for non-malignant stricture limited in extent, its propriety may be entertained.

The operation of Wölfler (*gastro-enterostomy*) is more simple, requires less time in its execution, and offers a better chance of recovery and prolongation of life. With the time saved in this operation (as in other cases of intestinal anastomosis), by the use of Senn's absorbable bone-plates, or Abbe's catgut rings—elsewhere described and shown—the danger of a fatal termination may be lessened. Through the opening thus made the food acted upon by the gastric juice passes into the small intestine and there meets with the bile, pancreatic and intestinal juices.

As far as can be determined by the study of a limited number of cases, dilatation of non-malignant stricture of the pylorus is a justifiable operation. If the stenosis recurs within one or two years, and if the contraction is limited in extent, the surgeon should choose between pylorotomy and gastro-enterostomy. If the cause of the stenosis is cancer, dilatation can only produce a temporary relief. The danger of the operation is practically as great as in gastro-enterostomy, and this last procedure, if successful, offers the best hope of prolonging life and lessening suffering. When, as a result of pyloric stenosis, life is endangered to such an extent that operative interference is determined upon, the abdominal wall should be opened by the curved incision above given, and a careful examination made. If malignant disease is discovered, and if from the size and appearance of the neoplasm infiltration of the neighboring tissues has taken place, or if the neoplasm involves the stomach, necessitating if exsected the removal of a portion of this organ, exsection should be abandoned and *gastro-enterostomy* performed.

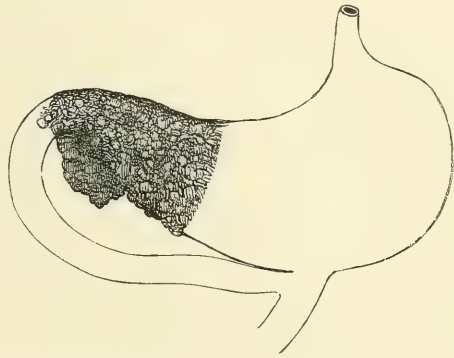

FIG. 532.—Wölfler's operation for gastro-enterostomy.

Duodenum.—Operations upon this organ must be chiefly confined to the upper portion on account of the relations of the bile and pancreatic ducts to the middle portion, and the body of the pancreas and great mesenteric vessels to the lower third.

Duodenostomy has been performed in several instances for the relief of stenosis of the pylorus, but without success. The incision through the abdominal wall is the same as in pylorectomy. The opening should be made in the upper portion of the organ, after adhesions have been secured by stitching the intestine to the edges of the wound in the abdominal wall, as in gastrostomy. Digital or instrumental dilatation of the stricture is done through the fistulous opening. The benefit to be derived from this operation is less than that after gastro-enterostomy or dilatation of the pylorus, and is fully as dangerous.

OBSTRUCTION OF THE ALIMENTARY CANAL BELOW THE PYLORUS.

Partial or complete occlusion of the alimentary canal may occur from a variety of causes, namely: 1, impaction of fecal matter; 2, foreign bodies; 3, intussusception; 4, volvulus; 5, constriction by bands; 6, by adhesions; 7, omental and mesenteric slits; 8, diverticula; 9, neoplasms; 10, stricture; 11, true hernia.

The impaction of ingested matter may occur at any part of the alimentary canal, although this accident occurs in the great majority of cases in the large intestine. The cœcum and ascending colon are the most common seats of fecal impaction, the sigmoid flexure next in order.

The symptoms upon which a diagnosis is made are the presence of a tumor in the line of the colon, which is not painful on pressure, may be molded by firm and prolonged compression, is movable, has formed gradually, and has a history of constipation. In the sigmoid colon and rectum digital exploration will demonstrate the nature of the mass. Vomiting, tenderness, and shock, so common in acute obstruction, are absent, or, if present, only occur in the latter stages and in extreme cases.

The *treatment* consists in the repeated injection of warm water until the bulk of the tumor is softened, when laxatives may be given by the mouth. The method of injection is as follows: Place the patient in the knee-elbow position, or upon the right side with the pelvis elevated. In this position the pressure is in great part taken off the rectum, and a greater degree of tolerance is obtained. If tenesmus results, a full hypodermic injection of morphia should be administered. The fountain-irrigator is the best instrument, and from two to four pints or more may be thrown slowly in at one operation. The water should be allowed to remain in the colon as long as possible. When the impaction is near the anus, it may be removed with the finger or by a spoon.

Foreign Bodies.—Indigestible substances of various kinds, introduced by accident or intentionally, at times pass through the stomach

into the intestinal canal and become lodged. In rarer instances they are introduced through the anus.

Biliary calculi which have passed through the common duct into the duodenum, or causing ulceration of the gall-bladder and duodenal wall, enter the canal in this manner, may also cause intestinal occlusion. Again, obstruction has been caused in a number of instances by *concretions* (enterolithes) composed of magnesia, iron, or any inorganic matter administered for a long period of time. They are met with chiefly in the colon as a solid mass, or are precipitated upon organic and indigestible matter in the canal.

The symptoms vary with the suddenness or completeness of the obstruction, as well as with its location. Sudden occlusion is accompanied by pain of a colicky and violent character, usually referred to the seat of the obstruction. Shock is also present in acute stoppage of the canal. Vomiting is an early and prominent symptom of occlusion of the small intestine, coming on at a much later period, when the colon is involved. On the other hand, constipation is a feature of stoppage in the large intestine, while fecal matter in varying quantity may continue to pass *per anum* for several days after occlusion above the ileo-cæcal valve. In arriving at a diagnosis, palpation and percussion will be of value. The knowledge of the accident when a body has been swallowed will, of course, establish the character of the occlusion. Insane or hysterical individuals often indulge in such practices. Biliary colic not infrequently precedes occlusion from calculi which escape by the common duct, while tenderness in the region of the liver and duodenum must be present in a varying degree in cases of perforation of the duodenal wall by large calculi from the gall-bladder.

Tenderness is also present in cases where delicate sharp objects (pins, needles, etc.) have passed through the walls of the intestine and are wandering in the cavity of the peritonæum or in the pelvis.

The *treatment* which should be instituted in obstruction by foreign bodies will depend in great part upon the symptoms which ensue. If the occlusion is complete and the symptoms are alarming, operative interference should not be delayed. The only doubt which may be thrown upon the propriety of operating is the presence of shock or collapse in an extreme degree. If this condition is present, morphine and whisky hypodermically should be administered in the effort to bring about reaction. If no urgent symptoms follow the presence of a foreign body in the alimentary canal, expectant measures may be employed in the hope that it may pass out by the rectum. When a foreign body has been swallowed and has gone beyond the stomach, and its shape is known to be such that it may cause perforation of the intestinal wall, or that the possibility of its being passed through is remote, it is the wiser policy not to lose valuable time by procrastination, but to operate at once. When introduced through the anus or lodged in the rectum or lower portion of the sigmoid flexure of the colon, they may be removed through the natural opening.

Intussusception, or the telescoping of one part of the intestinal canal into another, may occur at any portion of the bowel (Fig. 533). It is met with in the following order of frequency: at the ileo-colic region, the lower part of the jejunum and ileum, and the colon.

The invagination is usually from above downward; in rare instances from below upward. Very exceptionally both conditions exist in the same subject.* It occurs in males more frequently than in females, and, while it may be met with at any period of life, it is much more common in children than in adults. A large proportion of cases occur in the first six years of life, and of these the first, second, and third years are most prolific.

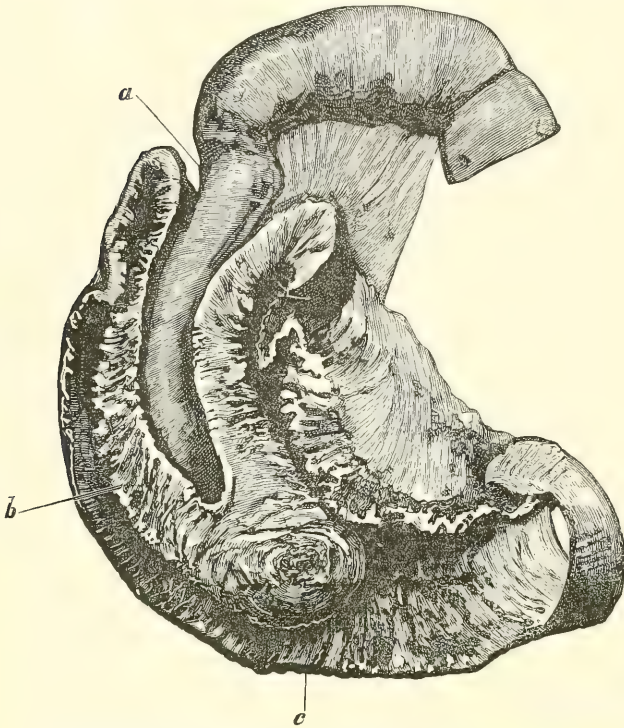


FIG. 533.—Intussusception of the jejunum. *a*, Internal cylinder. *b*, Middle cylinder. *c*, External cylinder. (After Treves.)

Intussusception is usually caused by spasmodic contraction of a limited portion of the circular muscular fibers of the intestinal wall, whereby this portion, becoming smaller and firmer, is either overlapped and included by the part immediately below, or

falls into it. Paralysis of the circular muscle would produce the same condition. It may result from the dragging of a neoplasm developed in the wall of the gut, from the lodgment of a foreign body, or fecal matter.

Invagination may be acute or chronic, may cause complete obstruction at once, or only partially occlude the intestinal canal during its entire existence. The character of the symptoms will in part depend upon the location of the accident.

When the ileum and cæcum are involved, the symptoms of obstruction are more acute. In subacute and chronic cases the colon is usually involved.

The symptoms of intussusception may be those of acute or gradual obstruction, as the invagination is acute, subacute, or chronic.

In general, pain is present, and is continuous or spasmodic, being referred to the region in which the lesion exists. Tenderness is not

* "Intestinal Obstruction," by Frederick Treves. Lea, Sons & Co., Philadelphia, 1884.

present at first, but is developed as the inflammatory changes in the intestine and peritonæum appear. Vomiting occurs early when the obstruction is in the small intestine, and later when the large intestine is involved. Tenesmus exists in a certain proportion of cases, and is especially apt to occur in intussusception in the colon. Fecal matter may pass in complete obstruction above the colon until the contents of the large intestine are evacuated, and may persist throughout the attack when the occlusion of the gut is only partial. Mucus and blood are discharged in those cases in which tenesmus is extreme.

The symptoms of shock and collapse are present early in the history of a majority of all cases. The tumefaction caused by the invagination may be felt through the abdominal wall or *per rectum*. The distention of the abdomen is not great when the lesion is in the jejunum or ileum. It is apt to be present when the colon is affected.

The *prognosis* is always grave. Death occurs in 70 per cent of all cases, being about equal in both sexes (Treves). The only methods of recovery, if left to nature, are accidental reduction, sloughing and elimination of the invaginated gut, or fecal fistula. Accidental reduction can only take place in the milder varieties and in the earlier stages, before adhesions or strangulation have occurred.

Distention of the intestine by gas, or assuming a suitable position, might reduce the invagination. Sloughing occurs in a certain proportion of cases, the dead gut being passed by the rectum. Fecal fistula may form in very exceptional instances.

Treatment.—The conservative treatment consists in the administration of an anodyne to relieve pain and spasm, and the introduction of tepid water in volume into the rectum and colon, with inversion of the patient, or the employment of gas or air in a like manner. If the lesion is recent, and if it is located in the large intestine, this practice should be tried. As it is often impossible, and under all conditions extremely difficult, to overcome the resistance of the ileo-cæcal valve, it is an unjustifiable waste of time to attempt a reduction by these measures in intussusception above the ileo-colic junction.

The objections to this method of treatment may be formulated thus: 1. The administration of opium masks the symptoms by dulling sensibility, and may induce a dangerous if not fatal procrastination of more radical and certain measures. 2. Distention from below by water, gas, or air—within the limit of safety from rupture—fails to reduce an invagination in which strangulation or adhesions have occurred. In all probability only the mildest forms are reducible by this method, even when no adhesions exist. 3. It fails in such a vast majority of cases that it induces a procrastination in surgical interference, and of itself induces a certain amount of shock, which in a measure detracts from the prognosis after abdominal section.

The only means of decreasing the heavy mortality following intussusception is in abdominal section. It is important that the operation be not deferred too long; in fact, not longer than the recognition of the lesion. Within the first twenty-four hours the prognosis will be much

more favorable, and the danger of a fatal termination will be increased with each day thereafter.

In favor of abdominal section it may be said : 1. That a death-rate of 70 per cent in treatment without operation justifies surgical interference. 2. It is now well known that, in a patient not exhausted by asthenia or prolonged suffering, exploration of the abdominal cavity under careful antiseptic precautions is attended with little danger, and, in the earlier hours of intestinal obstruction, it does not add much to the gravity of the prognosis. 3. If recovery by sloughing occurs, stricture of the intestine is always to be considered as a probable sequel. If the invagination is reduced early, or if exsection is practiced, stenosis will rarely occur. 4. In the rare cases of recovery by fecal fistula, operative interference is ultimately demanded.

If the point of obstruction can be definitely located, and is not near the median line, the abdominal incision should be made immediately over the occluded intestine. Under other conditions, the median line near the umbilicus should be selected. The invagination should be overcome, if possible, by gentle traction or massage, leaving the intestine within the abdominal cavity. If necessary, the mass may be drawn out and kept warm with towels. The questions of excision and anastomosis, or artificial anus, must be determined by the conditions present.

Volvulus, or twisting of a loop of intestine, occurs usually in the sigmoid flexure of the colon, although the remaining portions of the colon, or cæcum and small intestine, may be occluded by this accident. The loop may become twisted upon itself at its mesenteric attachment, or one loop may be twisted over a second. The last variety is more apt to occur in the ileum and lower jejunum. The principal cause of volvulus is an abnormally long mesentery, allowing unusual freedom of motion to the loop of intestine which is attached to it. This defect may be congenital or acquired. Constipation and the habitual distention of the sigmoid flexure by fecal matter is probably the most frequent cause of elongation of the meso-colon and increased length of this part of the large intestine. It occurs more frequently in men than in women, and is met with in adults more than in children. When the conditions are favorable, a suitable position or an accident in movement is sufficient to rotate the loop on its axis, causing occlusion by the weight of the loop and mesentery brought to bear upon a limited surface. The symptoms of volvulus are those of acute intestinal obstruction. Pain similar to that of colic is present from the start. Constipation is the rule, and indicates the sigmoid colon as the seat of the lesion. Tenesmus is present in a certain number of cases, and is additional evidence that the colon is involved. Distention of the abdomen to an extreme degree occurs in a large proportion of cases, developing more rapidly in volvulus of the colon. Vomiting is rarely present until late in the history of the case, and, when it appears early, it suggests obstruction in the small intestine. A condition of shock more or less profound supervenes if relief is not obtained. Diminution in the quantity of urine is present in a certain proportion of cases.

The prognosis is fatal probably without exception in every case of

complete volvulus. Strangulation of the loop and enormous distention of the part involved occur.

Treatment.—If the symptoms point to the sigmoid flexure or colon as the seat of the twist, the introduction of warm water into the rectum is indicated. The patient should be placed in the knee-elbow position. The introduction should be made gradually, and may prove successful in recent cases where adhesions have not occurred, or where the distention of the gut is not too great. If this measure is not successful within a few hours, abdominal section should be performed, the hand introduced, and the loop untwisted.

Constriction by Bands.—Bands of cicatricial tissue resulting from peritonitis cause intestinal obstruction in a certain proportion of cases. This accident occurs chiefly in adults, about equally in both sexes, being due to pelvic inflammations in women and to typhlitis and traumatic peritonitis in men (Treves). The bands vary in length, breadth, and points of attachment. The lower jejunum and ileum are involved in almost all cases. The symptoms are in general those of acute obstruction of the small intestine. Pain is violent in the beginning, and in the majority of cases is referred to the part involved. Vomiting is an early and persistent symptom, and, as is common in obstruction above the ileo-cæcal valve, is apt to be stercoraceous. Shock is usually more prominent in this form of occlusion than in those heretofore given. The urine is diminished in quantity. The abdomen is not tympanitic as a rule, although the constricted loop may be greatly distended, and may be recognized as a distinct tumor by palpation or percussion, or by vaginal or rectal exploration.

The diagnosis must be made from the history of a former peritonitis and the presence of the symptoms above given. The prognosis is fatal, and the indication for treatment is early operative interference.

In addition to inflammatory bands, intestinal occlusion is occasionally caused by the pedicle of an ovarian or uterine tumor, or the Fallopian tube may act in the same manner.

Adhesions between contiguous loops of intestine, resulting from peritonitis, may occur in such a manner as to lead to occlusion. The symptoms do not differ materially from those just given, and the treatment is the same.

Strangulation through Slits in the Omentum and Mesentery.—Occasionally a loop of intestine slips through an opening in the omentum or mesentery, becomes imprisoned and strangulated. The rent may be congenital or result from an injury, penetrating or non-penetrating. The small intestine (ileum) is most frequently involved, and the aperture occurs as a rule in the mesentery of the last part of this organ. Strangulation of the colon in this manner is exceedingly uncommon. With the exception of the presence of a tumor, the symptoms are the same as those in hernia of the small intestine with strangulation. Early operative interference offers the only hope of relief.

Constriction by Diverticula.—Pouches or cavities communicating with or attached to the intestines may be true or false—i. e., congenital

or acquired. Meckel's diverticulum, which is attached to the last two or three feet of the ileum, may remain patulous and open at the umbilicus, or more frequently it ends in a blind extremity which may be continued as a cord to the umbilicus. When it exists it represents the vitelline duct of the embryo, in which the normal process of closure and obliteration has not taken place. The vermiform appendix may also be classed with the true diverticula. False diverticula occur in both the small and large intestine, being slightly more common in the colon. Their mode of origin is not as yet satisfactorily explained. They are found to project between the two layers of peritonæum along the mesenteric border of the small intestine, and into the appendices epiploicæ of the colon (Treves). They are herniæ of the mucous membrane projecting through an aperture in the muscular layer.

Constriction and strangulation of a loop of intestine by Meckel's diverticulum are much more apt to occur than by the false pouches. The vermiform appendix in rare instances may become twisted upon its axis and strangulated, or it may cause the constriction of a neighboring loop of the ileum.

There are no symptoms peculiar to obstruction from true or false diverticula, and the nature of the lesion can only be discovered by abdominal section, which is indicated in this form of intestinal occlusion.

Neoplasms.—Various new-formations, both benign and malignant in character, may occur in the intestinal canal and lead to obstruction by projecting into the lumen of the gut, or by pressure from without or by development within the wall proper, producing narrowing or stricture. *Fibroma*, *fibro-myoma*, and *lipoma* are of rare occurrence. *Angioma* is also exceptional in this location. *Adenoma* is a more common form, developing from the glandular apparatus, and more particularly from the follicles of Lieberkühn in the large intestine.

Sarcoma and *carcinoma* are also met with, both as primary and secondary growths. The symptoms of obstruction are, as a rule, gradual in development, and the presence of a tumor may be recognized by palpation with the abdominal muscles in complete relaxation. Cancer is the most common of these new formations, and is apt to be located in the colon or rectum. According to Haussmann and Treves, the variety of cancer met with in the large majority of instances is a *cylindrical epithelioma*, encephaloid and scirrhous being very exceptional. The growth may cause constriction by extending completely around the lumen of the tube, or, by developing on one side, cause stenosis by its bulk and by the contractions which result. The diagnosis of cancer may be made in those cases in which the disease is situated in the rectum or lower portion of the sigmoid flexure by digital examination or by the aid of the speculum. Situated higher up, the presence of a tumor, the age of the patient (over forty as a rule), and the peculiar cachexia, will aid in arriving at a correct diagnosis.

Stricture.—The partial or complete occlusion of an intestine, by cicatricial contractions following inflammation or ulceration of its mucous and submucous or muscular layers, constitutes a true intestinal stricture.

Constriction by peritoneal bands, or the infiltration accompanying cancer, is not considered as stricture proper.

Any disease which produces loss of substance in the inner layers of the wall of the gut may produce stricture. The ulcers of typhoid fever, tuberculosis, dysentery, syphilis, and chronic intestinal catarrh, or those resulting from injury by ingested matter, by traumatism, or the necrosis following strangulated hernia, are the chief lesions which precede true stricture of the intestine. Cicatrization in an ulcer which has its longest axis at a right angle to that of the intestine is more apt to lead to obstruction than one which has its long axis in an opposite direction. Stricture occurs in adults, of forty years or more, oftener than in the young, being rarely met with in children under ten years of age. No portion of the alimentary canal, from the pylorus to the anus, is exempt, yet stricture of the duodenum and upper jejunum is comparatively rare; the ileum, near the cæcum, is more frequently attacked, while the large intestine, and especially the sigmoid flexure and rectum, is the most common seat of this grave and painful affection.

The symptoms of stricture are those of progressive narrowing of the intestine. The intensity of the symptoms will be proportionate to the rapidity with which stenosis results and to the portion of the canal involved. Pain is not marked until the narrowing has arrived at a point where ingested matter passes through with difficulty. It is spasmodic in character, and occurs at varying intervals. Distention of the intestine above the seat of stricture, with consequent hypertrophy of the wall, follows sooner or later in all cases. The continued irritation of the bowel from the pressure of fecal matter induces ulceration of the mucous and submucous tissues at and above the seat of stenosis, and perforation may occur.

Vomiting is an earlier symptom in stricture of the ileum and jejunum than when the colon is involved. There may be diarrhœa or constipation, or these conditions may alternate, and are therefore of no diagnostic value. Tenesmus is rare, and the abdomen is not distended except in case of peritonitis. As far as the previous history may be of value in locating the seat of the lesion, it is known that dysenteric ulcers are usually found in the rectum, sigmoid flexure, and cæcum, and in the order of frequency in which these organs are given: typhoid ulcers (which rarely cause stricture) in the lower ileum and cæcum; those of chronic catarrh in the colon; syphilis (gumma) in the rectum and ileum; and tubercular ulcers in the lower ileum (Treves).

The diagnosis of stricture must be based upon a study of the symptoms above given, except the cases in which the lesion is in the rectum or lower part of the sigmoid flexure, where digital or instrumental exploration may be made.

Treatment.—Stricture of the rectum and lower part of the sigmoid flexure of the colon should be treated by dilatation or division. Above this point the only hope of relief is by exsection of the part involved, or by lateral intestinal anastomosis. On account of the comparative freedom of this last operation it should be preferred. Enterostomy and colos-

tomy are palliative surgical measures, to be instituted when other means are not indicated.

ABDOMINAL SECTION FOR INTESTINAL OCCLUSION.

In all lesions of the small intestines and of the transverse colon in which it becomes necessary to invade the abdominal cavity, the incision should be made in the *linea alba*, between the umbilicus and the *symphysis pubis*, extending it to a higher point if necessary. When the seat of the obstruction can not be determined without exploration, the same incision should be practiced. The cæcum, ascending and descending colon, can be more directly approached from an opening in the lateral aspects of the abdomen immediately over these viscera. The sigmoid flexure and upper portion of the rectum may be well exposed by the median incision when the small intestines and mesentery are lifted to one side. In general, it may be said that the smaller the incision the better, yet the opening should always be sufficient to admit of thorough exploration, and, if necessary, large enough for inspection. The patient should rest upon the back, with the head and shoulders slightly elevated, in order to relax the abdominal muscles. Strict attention should be paid to the antiseptic details already given. An effort should be made to strike the median line so exactly that the incision will pass between the two recti muscles. All bleeding should be arrested before the parietal peritonæum is incised. This should be punctured, and a very dull-pointed, grooved director inserted, and the peritonæum divided on this instrument. The opening should be at least four inches in length. As soon as this is accomplished, the disinfected hand should be introduced and the seat of obstruction sought. The escape of intestines or omentum through the wound should be prevented by holding large flat sponges or aseptic napkins prepared for this purpose over these viscera and pressing them back into the peritoneal cavity. All sponges, towels, etc., brought in contact with the viscera should be disinfected in Thiersch's solution, since the ordinary sublimate solutions are too irritating. If, upon exposing the small intestines, some of the coils are found to be greatly distended while others are collapsed, it is pretty safe to conclude that the obstruction is near at hand, and the collapsed loops should be carefully passed between the fingers up to the obstruction. It is scarcely possible, in the condition in which the viscera will be found, to determine exactly which is the upward or downward direction of the coils, and it may be necessary to begin at the cæcum and work upward.

If the coils which present are so enormously distended that they interfere with the exploration, the gas should be evacuated by multiple puncture with the finest hypodermic needle. The gas escapes through the needle, the hole made by which is so delicate that it is closed by contraction of the muscular fibers of the gut. Should a larger puncture be necessary, it should be closed by Lembert's silk suture.

When, as not infrequently happens, by reason of procrastination in asking for surgical relief, the condition of the patient is so critical that a

prolonged operation is not indicated, it is a practice I have found successful in several instances to seize the first presenting loop of *distended* intestine, stitch it to the abdominal wound, and establish immediately an artificial anus. The alarming symptoms of obstruction thus allayed, the occlusion can be dealt with at a subsequent operation.

If the cæcum is found to be distended, the lesion is evidently in the colon, and this organ should be followed to the obstruction. If biliary calculi, a foreign body, or enteroliths are found, the part involved in the obstruction should, if possible, be brought out at the wound, protected by warm Thiersch towels, the escape of matter into the cavity of the peritonæum prevented by flat sponges or napkins, and the body removed by an incision in the long axis of the gut, and, when possible, opposite the mesenteric attachment. The length of the opening should be sufficient to allow of the removal of the body without bruising or tearing. If the part can not be brought out, it should be laid upon a flat sponge and the peritonæum in this way protected from the escape of fecal contents. This accident may be in great part prevented by compression of the gut above the obstruction. The wound in the intestinal wall is next closed by Lembert's suture.

When intussusception exists, the invaginated portion should be brought into full view, and careful traction employed in the effort at reduction. If this can not be accomplished, or if strangulation and necrosis exist, exsection of the necrosed portion should be made at once, if the condition of the patient is such as to justify a prolonged operation. If not, the dead loop or portion should be brought out at the incision in the abdomen, cut away, and a fecal fistula established. The restoration of the intestinal canal may be accomplished at a subsequent operation. If the operation has not been too long postponed, it will be advisable to proceed with the exsection at once.

Exsection—or, as it is sometimes called, *resection*—of the intestine is a very proper operation, and one which, when performed early enough, with the careful attention to details it requires, will succeed in the majority of cases.

This operation, heretofore so rarely performed with success, is one of such importance that, in describing the technique, the following case is given in detail:

Leah R—, Russian, fifty-six years of age, housewife, was admitted to Mount Sinai Hospital on October 9, 1886, with the following history: For ten years she had had a swelling in the left groin, which would disappear when she was lying down and return when she was standing erect. She had not worn a truss. Two weeks before admission she discovered that the tumor no longer disappeared upon going to bed, but became painful, tender, and more swollen. She had not vomited up to the time of arriving at the hospital, but there had been no evacuation of the bowels for six days prior to her admission.

On admission, a swelling as large as an ordinary fist was found occupying the inner aspect of the left groin and thigh. The skin over the tumor was red in color, tender and doughy to the touch, and fluctuation

was evident. The tissues around were slightly emphysematous. The patient's appetite was gone; she was emaciated, having lain in her present condition ten days in a tenement-house, without proper care. The temperature was normal.

A diagnosis of strangulated femoral hernia was made, ether administered, and the tumor incised. Several ounces of foul pus mixed with intestinal matter were discharged. No trace of a hernial sac or of intestine could be discovered, such was the gangrenous condition of the mass. Upon introducing the little finger into the femoral canal, a slight opening into the intestine could be felt. Into this a closed dressing-forceps was introduced, and the opening dilated by separating the jaws of this instrument. This was intended to secure the freer exit of ingested matter from the upper portion of the occluded gut.

A loose dressing of iodoform gauze was laid over the wound. The patient improved in condition after this operation, under mild stimulation and liquid diet (milk, beef-tea, beef-juice, whisky, sherry, etc.). Only a small quantity of ingested matter escaped when the gauze dressing was changed on every second or third day.

On October 22d, thirteen days after the first operation, with ether narcosis, laparotomy was performed. The patient was placed upon the back, with the pelvis elevated upon a firm cushion. With Volkmann's spoon the granulation tissue was first scraped from the walls of the abscess, the hole into the intestine plugged with a pellet of iodoform gauze, the cavity of the abscess irrigated with 1-to-1000 sublimate, and then tightly packed with iodoform gauze.

The integument about the femoral canal was washed thoroughly with soap and warm water, cleanly shaved, washed with ether, and finally with 1-to-1000 sublimate solution. Towels wrung out of hot sublimate solution (1-to-3000) were laid over that portion of the body near the groin, leaving only a spot exposed measuring six by four inches.

An incision four inches in length was made parallel with the outer border of the rectus muscle, the lower end being over the *femoral ring*. All bleeding was arrested, so that before the peritonæum was opened the wound was absolutely dry. Catgut ligatures were employed. Great care was observed to keep to the inner side of, and away from, the epigastric vessels which were exposed in the dissection. The parietal layer of the peritonæum was picked up with a fine forceps, opened, and further divided upon the finger as a director.

Upon looking into the abdominal cavity, one or two loops of normal small intestine were seen, and, upon displacing these upward, a third loop was seen to be imprisoned in the femoral opening. That part of this loop above the constriction was slightly distended, while the part on the side nearest the rectum was contracted until it was about two thirds of the diameter of the upper segment. The obstruction of the intestinal canal at the ring was complete. A soft, flat sponge taken from a warm Thiersch solution (boric acid, gr. iv.; salicylic acid, gr. j; water, ℥j) was placed beneath the imprisoned loop in such a manner that it held the loose loops of small intestine back, and was ready to

receive any foreign matter which might escape from the gut when it was divided.

Two long-jawed scissors-forceps (used as clamps) were then placed so as to close the loop of gut which was caught in the ring. One of these rested against the inner surface of the ring, and the other only sufficiently removed from this to permit of a division of the intestine between the forceps.

As soon as this was effected, the loose end, with one pair of forceps attached, was brought out through the abdominal wound and placed in a warm Thiersch towel. As the forceps which constricted the ring of gut attached to the femoral canal was removed, a tuft of sponge was tightly packed into this ring to prevent any infection from the abscess with which it communicated.

Of the loop which had been liberated, about ten inches (five above and below the point of occlusion) were drawn out of the abdomen, flat Thiersch sponges carefully placed so as to close the wound and prevent any escape of matter into the peritoneal cavity, and the exposed gut protected by covering with warm towels. A piece of cotton tape one fourth of an inch wide was then tied four inches above and below the limits of the gangrenous opening, so as to completely occlude the lumen of the gut (*d, d*, Fig. 533 A). These tapes had been well soaked in a 1-to-3000

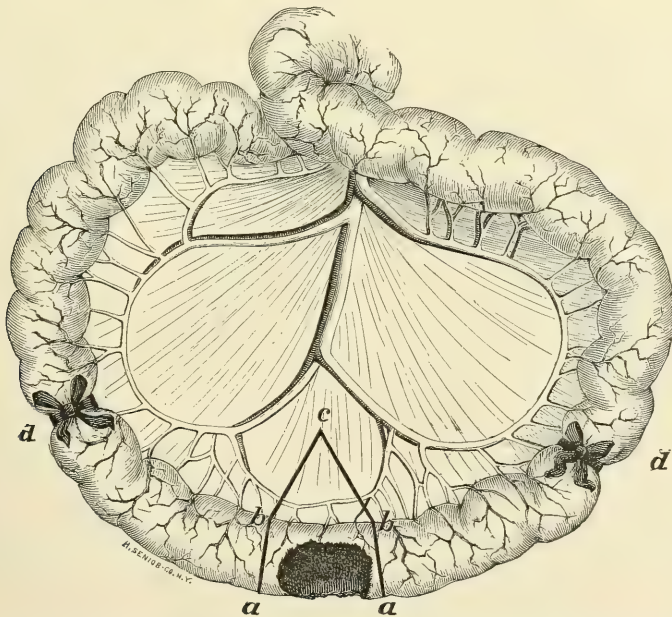


FIG. 533 A.—Loop of small intestines. *a, b*, Lines of section through the gut, removing the gangrenous portion. *b, c*, Same through the mesentery. *a, a*, Gangrenous portion of ileum. *d, d*, Occlusion of the afferent and efferent tubes by tape ligatures.

sublimate solution. When the forceps-clamp was removed, the opening into the intestine was seen to occupy two thirds of the circumference of the canal. The gut was then cut across at a right angle to its axis by a single stroke with the straight scissors (*a, b*, Fig. 533 A). These lines of

section were well out in sound tissue. The piece of intestine removed measured two inches and a half. A triangular piece of the mesentery was also removed (*b, c, b*, Fig. 533 A).

The bleeding from the mesentery was profuse, requiring a dozen catgut ligatures. From the ends of the intestine only a slight oozing occurred. The cavity of the gut from the tapes to the openings was carefully emptied of all matter and washed out with Thiersch's solution. Nothing escaped from the lower end.

The edges of the divided mesentery were first united by eight interrupted catgut sutures about one fourth of an inch distant from each other. When the intestine was reached, the mesenteric attachment of each end was carefully brought into apposition and the work of stitching the ends of the cylinders to each other begun.

In doing this, three forms of suture were employed: 1. A suture through the mucous membrane alone—*Czerny's suture*. 2. That through the peritoneal coat alone—*Lembert's suture*. 3. One which pierces the peritoneal coat and, passing along with the muscular layer, comes out on the free border of the divided gut—the *intermediate suture*.*

In Fig. 533 B, which represents a longitudinal section through the ends to be approximated, is shown at *b* the Czerny suture as it is passed

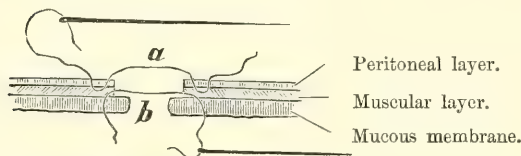


FIG. 533 B.—Schematic. *a*, Lembert's suture. *b*, Czerny's suture.

through the mucous layer of the gut from the inner surface of the canal; while at *a* the method of introducing the Lembert suture through the peritoneal layer is shown.

When a gut is cut across, the longitudinal muscular layer retracts, carrying the peritoneal layer with it, and leaving the thick mucous membrane projecting about one eighth of an inch. The object of the Czerny suture is to bring the mucous membrane and the connective tissue, upon which it rests, together, and thus strengthen the line of union after adhesion occurs. If this is not done, the slight adhesions between the peritoneal surfaces obtained by the Lembert suture might give way under the strain of distention of the intestine by gas or ingested matter. The objection to passing a suture entirely through the wall of the gut, and thus approximating all the coats at once, is the danger that the perforation may be followed by escape of gas or other contents to either side of the line of adhesion between the ends. The inversion of the mucous membrane by Czerny's suture, and of the peritoneal layer by Lembert's suture after the threads are tied, is shown in Fig. 533 c.

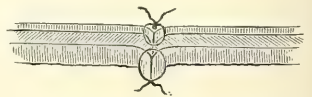

FIG. 533 c.—Schematic. Showing the inversion of the peritoneal layer by tying Lembert's suture, and of the mucous membrane by Czerny's suture.

* Dr. Sutton, of Pittsburg, employed this suture in a case which ended in a good recovery. I saw the line of union in this patient about two years after the operation, through the courtesy of Professor J. B. Hunter, who was performing a second laparotomy.

The mechanism of the intermediate suture is well shown in Fig. 533 D. This suture adds strength to the union by taking in the muscular layer and connective tissue of the mucous membrane, together with the peritoneal covering. Applied after the Czerny suture, there can be no danger of escape of the intestinal contents through the wound.

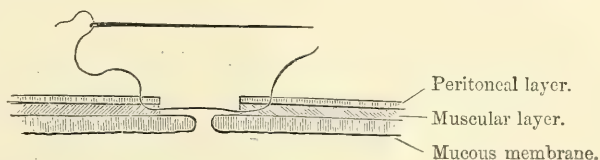


FIG. 533 D.—Schematic. Showing the route of the intermediate sutures.

In suturing the intestine, the very finest black silk, and delicate straight or half-curved needles, should be used. The thread should be made aseptic in sublimate solution (1-to-3000), and it and the needle taken from a 1-to-20 carbolic-acid solution as they are used. In commencing the sutures, first insert one Czerny suture just at the mesenteric or attached border of the intestine, and tie this, the knot, of course, coming within the lumen of the gut. The needle should pass from within through the mucous layer at a distance of about three sixteenths of an inch from the free border (Fig. 533 B), out along the free border of the same end, and, being carried across to the opposite end, should be made to enter below the muscular and mucous layer, and to emerge through the mucous layer three sixteenths of an inch from its cut edge. A Lembert suture should be next inserted just at the edge of the mesenteric attachment, as follows: * The needle is made to enter the peritoneal coat one eighth of an inch from the edge, and, passing between the serous and mucous coats, is again brought through the peritoneal layer about one twenty-fifth of an inch from the edge (Fig. 533 B, a). At a point exactly opposite, the same stitch is passed through the peritoneal layer of that side for the same distance, and this thread is tied. In knotting all of these sutures, it is a wise precaution to use the *double* or *friction* knot for the first tying, for by so doing there is no danger of the suture slipping and the parts separating as the second turn is being made. A second Lembert suture should now be inserted on the other side of the mesenteric attachment, and an *intermediate* suture passed between these, through the substance of the mesentery and down into the strip of intestine which here is uncovered by peritonæum. *Extra care must be taken to see that this part of each end of the cylinder is in perfect coaptation.* The sutures are now inserted for the remainder of the apposing surfaces. The Lembert and intermediate sutures alternate through the entire cir-

* When the peritoneal surfaces of the intestine are held in apposition by this suture, adhesion occurs in a remarkably short time. In January, 1887, I was called in consultation in a case of suspected volvulus. Upon opening the abdomen, it was found impossible to untwist the loop without puncture and evacuation of the contents of the greatly distended gut. The opening, one fourth of an inch long, was closed by four Lembert sutures at 11.30 A. M. Three and one half hours later the patient died. On autopsy, not only had well-marked adhesion taken place, but the silk threads were with difficulty recognized, being hidden beneath the inflammatory exudation.

cumference, and should be one eighth of an inch apart. The mucous or Czerny sutures should be from one fourth to three eighths of an inch apart. The relative proportion of these sutures is shown in Fig. 533 E. It is evident that while the Czerny suture is tied, leaving the knot within

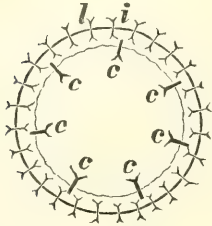


FIG. 533 E.—Schematic. Section of intestine, showing the proportion of each form of suture, and their distance apart. *l*, Lembert. *i*, Intermediate sutures alternating. *c*, Czerny's sutures. (Natural size.)

the cavity of the intestine for the first part of the operation, the last few threads must be tied leaving the knot imbedded between the mucous and muscular layers of the wall. In applying the sutures, the plan followed was—first a Czerny, then a Lembert about over this, next an intermediate, another Lembert, and after this a second Czerny suture, and so on. In other words, it was necessary to insert the mucous suture before the superficial sutures had quite reached that point. All of the threads should be cut off close to the knot.

In this operation I had to leave the space between the sutures on the upper end of the gut a little wider than on the lower, for the diameter of the efferent tube was considerably smaller than that of the afferent portion. The intervening space was a flush one eighth of an inch on one side, and a scant one eighth of an inch on the other. When the sutures were all in, the constricting tapes were removed. The gut immediately filled with gas. To the surprise of all present, the intestine below the line of suture instantly expanded to a size equal to that of the portion

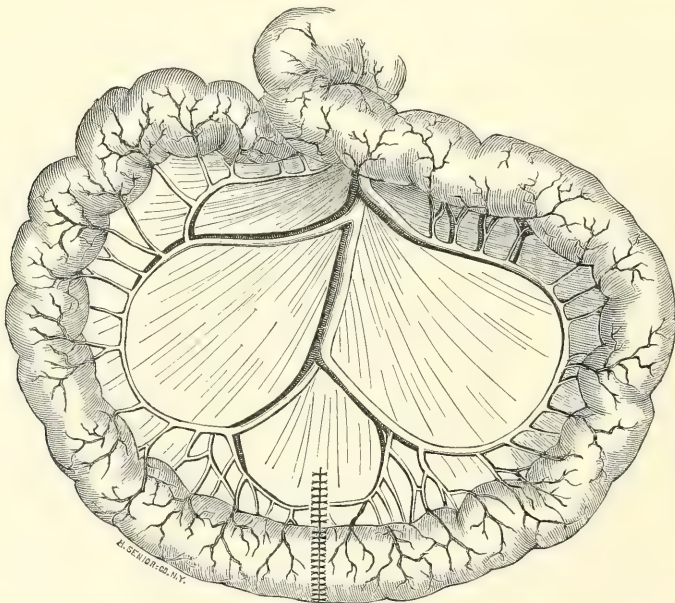


FIG. 533 F.—Showing the line of sutures in the mesentery and around the intestine.

above the line of union. That the wound was tightly closed, was demonstrated by forcing the contents of the intestine from opposite directions toward the sutures. No gas escaped.

The appearance after the tapes were removed is shown in Fig. 533 F. At intervals of about five minutes during the operation, a small quantity of warm Thiersch solution was poured over the exposed intestine. The warm Thiersch towels upon which it rested were changed every ten or fifteen minutes. No fluid was allowed to get into the abdominal cavity. Finally, the intestine was carefully washed with this solution, and returned into the cavity of the peritonæum.

It was now necessary to deal with the ring of intestine which occupied the femoral opening, and which led from the abscess into the abdominal cavity. Two strong silk threads were passed entirely through the opposing walls of this rim of intestine, and tied so as to bring the edges well together. I then passed a silver probe from the hernial abscess cavity up through the femoral canal, and through the ring of adhering intestine between the two silk threads, until the end of the probe projected a half-inch into the cavity of the abdomen. The ends of both threads were tied to the probe, and this withdrawn, bringing the sutures out through the saphenous opening. By making strong and continuous traction on these, the mucous membrane was everted, the peritoneal surfaces brought in contact, and the femoral opening closed. This procedure effected a radical cure of the hernia.

The wound in the parietal layer of peritonæum was closed by catgut sutures. The abdominal incision was closed with silk sutures, which included all the tissues down to (but not touching) the peritonæum. *For the prevention of ventral hernia after laparotomy, it is very important to include the fascia and aponeuroses of the muscles in the sutures.* A Neuber's bone-drain was inserted. The abscess and sinus were packed with iodoformized gauze. The patient rallied well, and was kept quiet with suppositories of opium. She was kept on the back, and was not permitted to move body, legs, or arms for ten days. The diet was milk, beef-tea, and whisky in small quantities.

October 23, 6 A. M., fourteen hours after operation, temperature 99° F. Patient vomited at 4.30 A. M.

October 24.—Pulse, 120; temperature, 99° to 100°.

October 25.—Pulse, 100; temperature, 99.6°. Patient comfortable. Slept well.

October 26.—The pulse and temperature were the same.

October 27.—Pulse, 80 to 100; temperature, 98.4° to 99.6°.

October 28.—Pulse, 100; temperature, 99° to 100°.

October 29.—Pulse, 100 to 106; temperature, 99.2°. Bowels moved; stool normal consistence.

October 30.—Pulse 94 to 100; temperature, 99.2° to 100.2° F. Bowels moved again; stool normal. Opium discontinued.

The subsequent history contains nothing of interest. The patient steadily gained her strength. On November 20th she sat up in bed, and on December 3d was walking about the ward. She is now fully restored and attending to her duties. There is no sign of obstruction or interference with the functions of the alimentary canal, and the hernia is at this date radically cured. The great emaciation of the patient at the time of

operation, and the fact that within half an inch of the opening into the abdomen there was a large abscess cavity, may be mentioned as the two conditions which rendered the prognosis grave.

Exsection of the colon is somewhat more difficult than the operation upon the small intestine, on account of its irregularity in size and the deeper location of all of this organ except the transverse portion. It should be brought into or out of the incision if possible, or, if this can not be done, the opening in the linea alba may be enlarged in the direction best suited to the case. If, after exploration through an incision in the linea alba, the obstruction is found to be in the cæcum, ascending or descending colon, and the part involved is so firmly fixed that it can neither be brought into view through the wound in the median line nor by an additional transverse incision of two or three inches, it will be advisable to close this opening and expose the part by an incision immediately over it.

When, for any of the reasons about to be submitted, lateral anastomosis is determined upon, the method of Senn, as modified by Abbe, will be found superior to the more tedious operation by suture practiced

by Woelfler and others. In its performance the catgut rings of Abbe (Fig. 533 G) are preferable to Senn's absorbable bone-plates. The laborious investigations of Professor Senn, of Wisconsin, in the department of *intestinal surgery* are, it is believed, already yielding gratifying results. The rings are thus prepared :

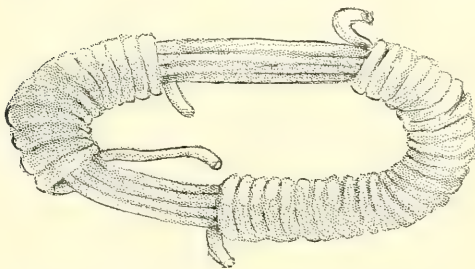


FIG. 533 G.—Showing the construction of Abbe's catgut rings.

“A moderately heavy catgut is chosen ; taken from alcohol or juniper-oil, it is wound loosely on a test-tube and soaked in hot water. It soon kinks up, and were it not on a tube could hardly be unraveled. After a while it is straightened out, allowed to untwist, wound again loosely, and soaked in hot water once more, until it ceases to twist. It is then ready to make up into rings, which will lie perfectly flat. Eight or ten turns over two pins stuck in a cork two inches apart, will make a bundle somewhat smaller than a lead-pencil. These may be tied at four places with fine silk, to secure the strands parallel while being wound round like a cable, with a continuous piece of the same catgut. The end of the piece is secured by threading it into a Hagedorn needle, and transfixing the whole bundle obliquely with it at the place of finishing. Thus there are no knots, and it is difficult to find the point of beginning.

“The ring is now a long oval with an inside diameter of two inches, and in thickness smaller than a pencil. Six strong but small braided silk threads are now fixed to each ring, equidistant, on the face looking toward the other ring which is to be laid against it.

“No knots are used. A needle pierces the ring between the strands, carrying the thread, which is drawn through, all but eight inches, and

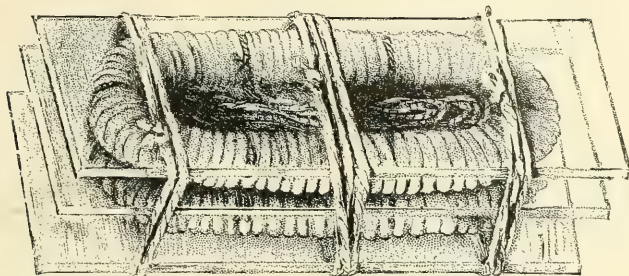


FIG. 533 H.—Method of preserving and flattening the rings.

wound once and a half round, sinking between the encircling catgut, piercing the ring again, and cut off. The rings, which have now been water-soaked, are ready for use if needed for emergency; but, if possi-

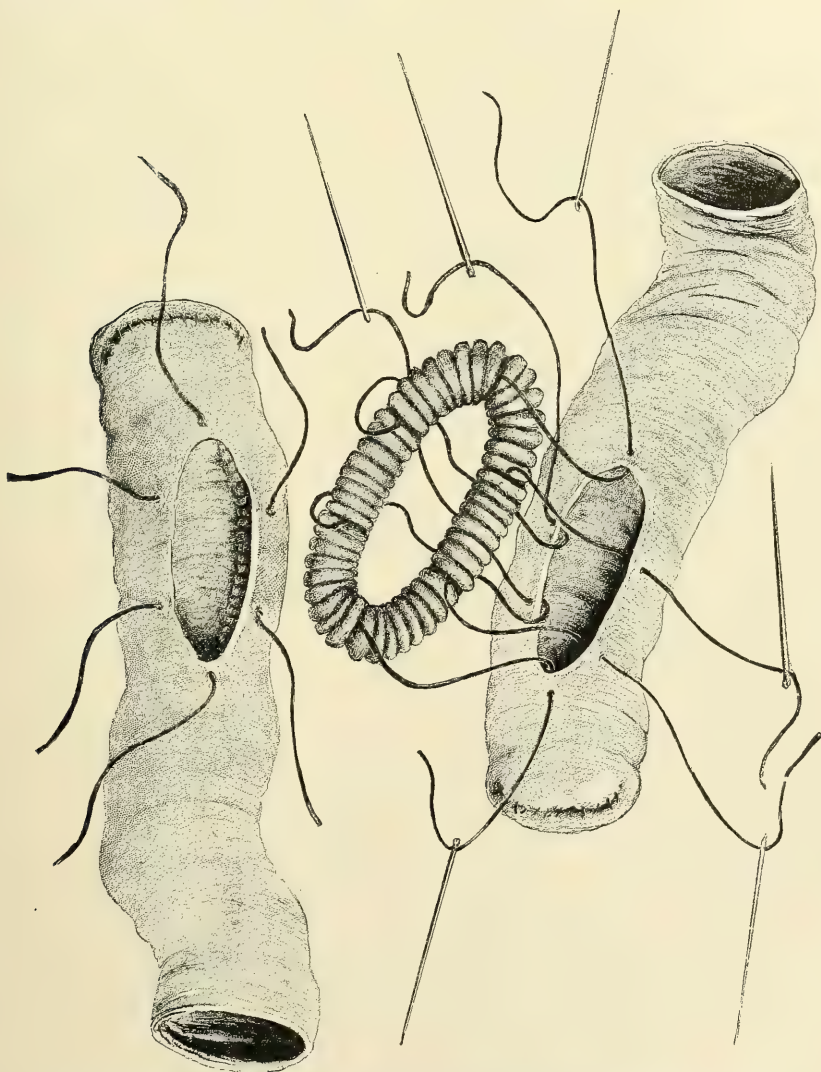


FIG. 533 I.—Showing the method of passing the silk sutures in inserting the rings.
In FIG. 533 J the ring is in position.

ble, they should be kept awhile in alcohol, under pressure between two glass slides (Fig. 533 H), the threads being curled up within the oval, and the sides being pressed as the glasses are tightly tied together. The ring thus becomes a long oval with parallel sides, and soon becomes harder and flattened on its faces. Moreover, it shrinks a trifle in alcohol, to swell again in the intestine and give additional security.

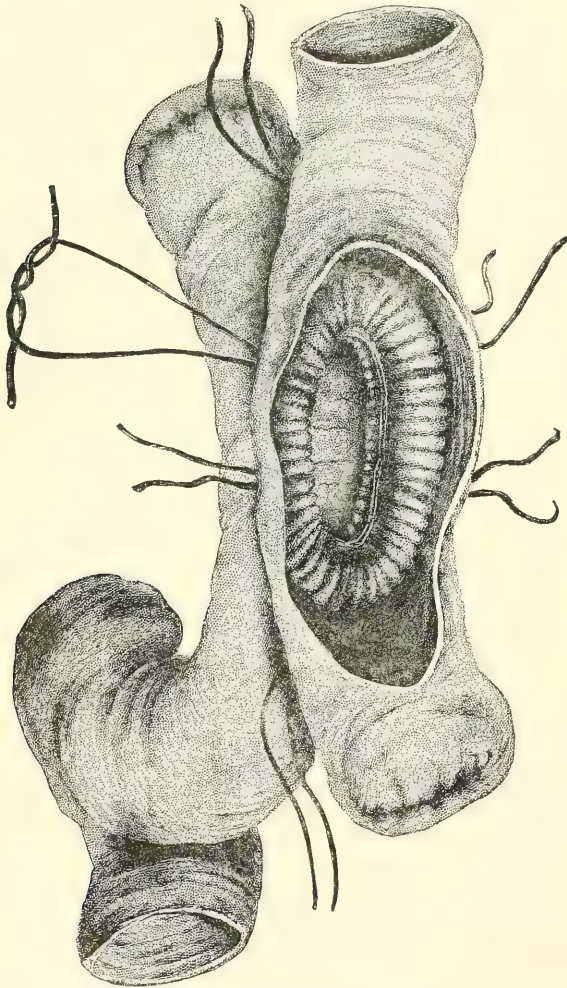


FIG. 533 J.—Lateral anastomosis complete. Intestine fenestrated to show opening from one section of the gut into the other.

delay a long while if he tries to turn in first one and then the other edge, and will also find the mesentery try to turn in after it on the attached side. My rule is to trim back the mesentery at least a half-inch from the end. Then, seizing both lips with toothed forceps, plunge them directly into the lumen. The entire edge usually follows, and one holds them by the left index-finger and thumb while a quick running overhand suture of the slit thus formed is made.*

* "Intestinal Anastomosis," Robert Abbe, M. D. Reprinted from "Transactions of the Philadelphia Medical Society," 1889.

"In using the rings, I find it saves time for each thread to have its own needle. The intestine is pierced from within outward less than a quarter of an inch from its cut edge (Fig. 533 I). The ring should be laid on a damp folded towel with threads in order and needles stuck in the towel, which is held by the assistant close to the bowel, while the operator quickly pulls the threads through and passes the ring into the interior of the bowel. When the threads are tied and cut off, the apposition is perfect, but by a quickly made running suture outside all, a half-inch of peritoneal surface is at once secured beyond the possibility of leakage (Fig. 533 J). More than this is superfluous, for the edges held between the rings act as valves.

"In invaginating the end of the cut intestine after exsection, one will

The application of this method is especially indicated in establishing the integrity of the intestinal canal in malignant disease or other obstruction where excision of the occluded portion is not practicable, as in *gastro-enterostomy* from cancer of the pylorus; or in any condition where a prolonged operation is contra-indicated. If in the further use of the rings they can be employed in direct or *terminal anastomosis*, a great advance will be made, for in lateral anastomosis the pockets necessarily existing are objectionable. The question of time is, however, in a class of cases of such vital importance that this method may be preferred to the more tedious process of direct suture (terminal anastomosis). In anastomosis between the small and the large intestine it should be employed.

Fecal fistula is established by bringing the loop or portion of intestine which is involved in the obstruction into the wound and stitching it to the edges of the incision as directed in gastrostomy. Strangulated and necrotic portions should be cut away.

If the obstruction is due to volvulus, it will be indicated by unusual distention of the twisted loop, which, in case the sigmoid flexure is involved, is enormous. An effort should be made to untwist the gut without puncture; but if this can not be accomplished, the hypodermic needle should be employed as above directed. In case of gangrene or adhesions amounting to stricture at the point of crossing of the two portions of the gut, the operation of exsection or for fecal fistula should be done.

When the constriction is caused by peritoneal bands, these should be divided and the intestine liberated. If a loop of intestine has been caught beneath the pedicle of a tumor (of the ovary, uterus, Fallopian tubes, etc.), the occlusion may be relieved with or without removal of the offending body.

In adhesions of the contiguous peritoneal surfaces of a loop of intestine, or the matting together of several loops in such a manner that obstruction occurs, exsection or the formation of a fecal fistula is indicated. If the adhesions are limited, they may be dissected apart; but this procedure is not unattended with danger from sloughing or a recurrence of the lesion.

Strangulation or constriction of a loop of gut in a slit of the mesentery or omentum should be treated by enlarging the slit, reduction of the loop, and closure of the opening by catgut sutures. If necrosis has resulted, exsection or the formation of a fistula may be done. In limited necrosis the dead portion may be cut away and the hole closed by Lembert's suture, provided that the lumen of the gut is not too greatly occluded by this operation, and always provided that the margins through which the sutures pass are sound.

Intestinal obstruction due to diverticula should be treated by division of the constricting tissues. A false diverticulum can scarcely be removed with safety, but, if necessary, Meckel's diverticulum or the vermiform appendix may be excised. In closing the stump of the appendix, the peritoneal coat should be turned in by Lembert's suture.

The removal of neoplasms may require the exsection of a part of the intestinal canal. In general, the rules above laid down are applicable here. Cylindrical epitheliomata, with no infiltration of the neighboring lymphatics or mesentery, are included among neoplasms which may with propriety be excised. When, however, the extent of the infiltration is such that a complete removal is improbable, the palliative operation of forming a fistula is advisable.

Stricture of the intestine above the rectum may be excised in favorable cases, or life may be prolonged by establishing an artificial opening in the gut above the seat of occlusion. Exsection will afford a more satisfactory result in the majority of instances when undertaken before the patient is exhausted by inanition and prolonged suffering.

When the obstruction is located in the lower portion of the ileum or in the first part of the colon, *ileo-colostomy* may be performed when exsection, in order to be successful, must be an extensive procedure. In this operation the end of the ileum is stitched to the margins of a suitable opening in the colon below the obstruction. It is analogous to gastro-enterostomy.

Hernia.—Literally defined, a hernia is a tumor formed by the escape of the whole or a portion of any viscus from its normal cavity. The term is now by common consent almost wholly restricted to protrusions of intestine or omentum (or both) from the cavity of the abdomen or pelvis. The protrusion may occur through an opening which is congenital or acquired. Complete inguinal hernia following the descent of a testicle, or ventral hernia, due to failure of perfect union in the aponeuroses of the abdominal muscles, are instances of the former; while a protrusion of the intestine after a wound in the abdominal wall is an example of the latter. The hernia may take place into an adjoining cavity, as the thorax (diaphragmatic), or protrude beneath the skin (femoral, umbilical, ventral, etc.).

Herniæ are classified according to their place of escape: inguinal, femoral, umbilical, ventral, diaphragmatic, gluteal, obturator, lumbar, and vaginal. The term ventral is applied to all herniæ occurring at points on the abdominal wall other than those indicated in the classification just given. Of herniæ in general the inguinal variety forms about 80 per cent of all cases; femoral, 10; umbilical, 5; the remaining varieties, 5. Of every five patients affected with hernia four are males.

Inguinal hernia in males occurs more often in the first ten years of life than in any subsequent decade, the period from the twentieth to the fortieth year being next in order of frequency. According to Kingdon, femoral hernia in males of all ages is met with in 4 of every 100 cases; in the first decade, in 1 of every 300; the second, 2 per cent; the third and fourth together, 4½ per cent; the fifth and sixth, 6 per cent; and after this, 8 per cent.

In females, inguinal and femoral herniæ are met with in about equal proportions. The latter variety is rarely met with before puberty, but occurs chiefly during the child-bearing period (Bryant).

The contents of a hernia are inclosed in a *sac* almost always formed

by the peritonæum lining the abdominal cavity. The sac may be carried immediately in front of the escaping intestine or omentum (femoral, umbilical, etc.), or these viscera may descend into a sac already formed by the escape of some other organ (inguinal, scrotal). In the rare cases of hernia of those portions of the large intestine not covered by peritonæum there is no true sac. If the intestine alone enters into the formation of a hernia, it is called *enterocele*; if omentum alone, *epiplocele*; if both are inclosed in the sac, *entero-epiplocele*. The coverings of a hernia outside of the sac will vary with its location, and will be given in the consideration of the different varieties. A hernia is said to be *reducible*, when the contents of the sac can by any means be returned into the cavity of the abdomen; *irreducible*, when adhesions exist to such an extent that this can not be effected; *strangulated*, when the circulation in the tumor is arrested by constriction at any portion (usually at the neck).

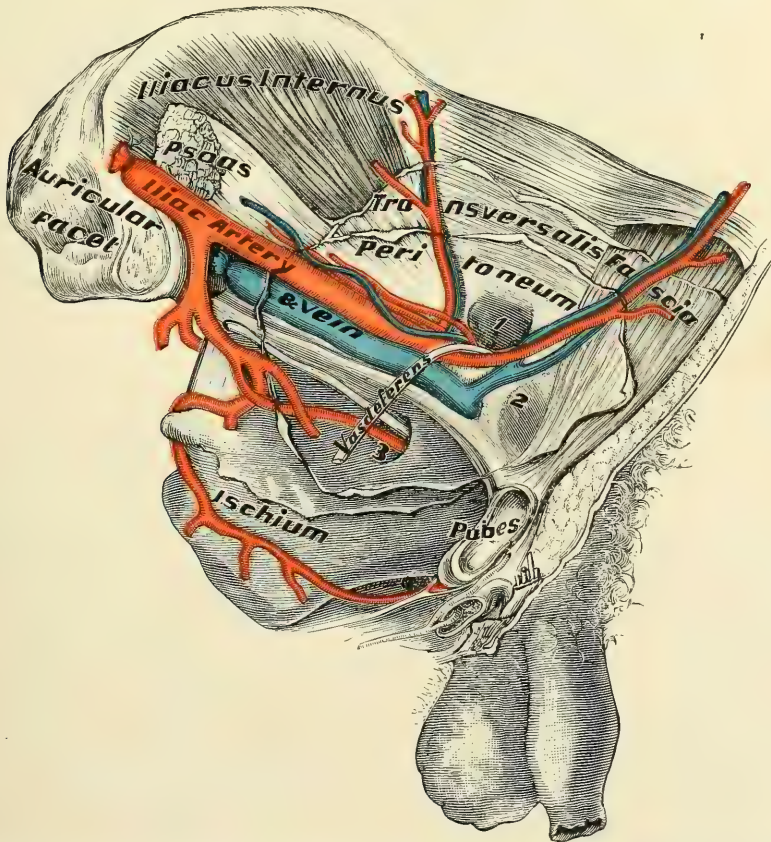


FIG. 534.—The relations of the points of escape of oblique and direct inguinal and obturator herniæ to the important vessels of the pelvis. 1, Internal abdominal ring. 2, Point at which a direct inguinal hernia commences. 3, Obturator canal, artery, and nerve. (Modified from Machse.)

Special Herniæ, Inguinal.—An inguinal hernia may be *direct* or *indirect*, *complete* or *incomplete*, *congenital* or *acquired*.

The *indirect* or “oblique” variety is much more frequently met with. In the male the contents pass into the internal abdominal ring and follow

the spermatic cord along the inguinal canal, at times descending into the *tunica vaginalis testis*. In the female the descent is in the canal of Nuck, following the round ligament into the inguinal canal, and at times as far as the labium. *The epigastric vessels are internal to the neck, and behind the body of an oblique inguinal hernia* (Figs. 534 and 546).

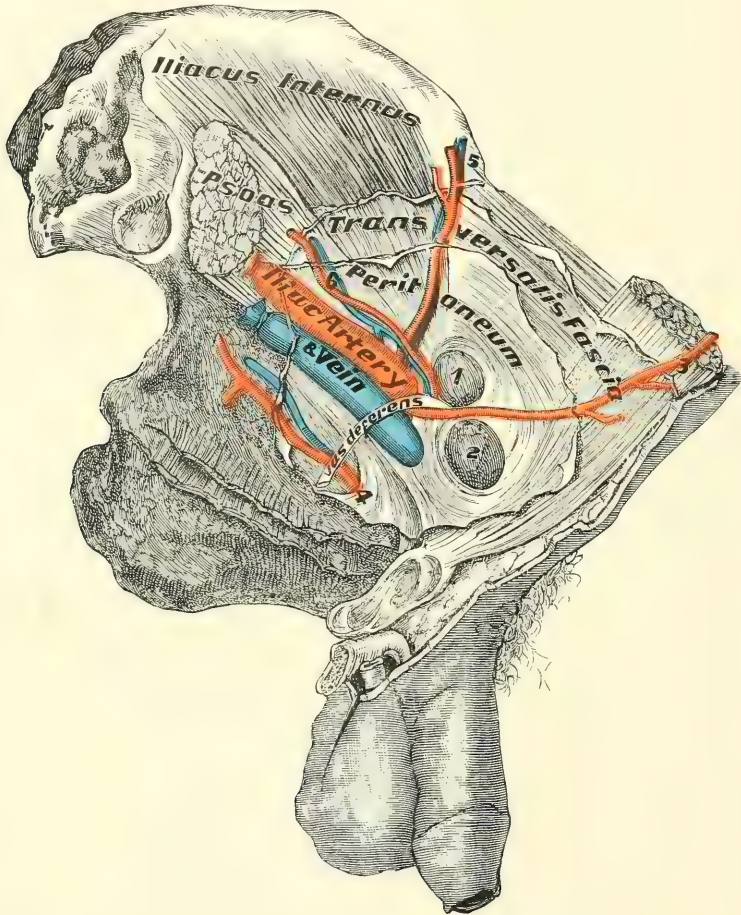


FIG. 535.—Showing, at 1 and 2, openings at which oblique and direct herniæ escape, and their relations to the deep epigastric artery. (Modified from MacLise.)

A *direct* hernia does not enter the internal abdominal ring, but pushes the fascia, which is to the inner side of the epigastric vessels and immediately behind the external ring, directly in front of the tumor and out at the external ring. *The epigastric vessels are external to the neck, and may be displaced slightly in front and to the outer side of a direct inguinal hernia* (Figs. 535 and 545).

An inguinal hernia is said to be *complete* when the contents protrude beyond the external ring; *incomplete*, when the tumor is within this limit.

A complete inguinal hernia in the male may descend into the cavity of the tunica vaginalis testis, the contents resting in contact with the

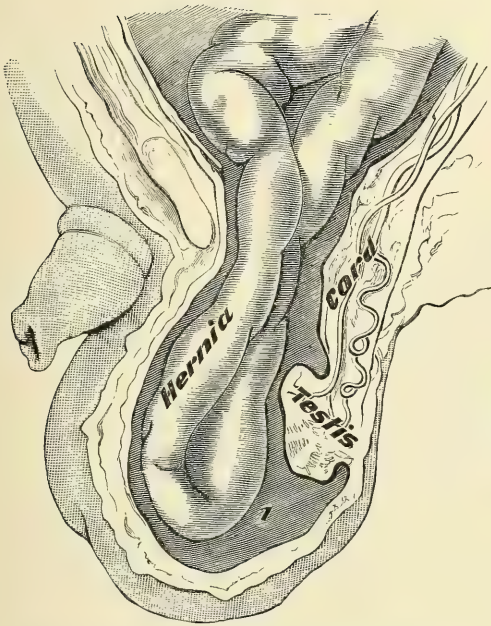


FIG. 536.—Congenital oblique inguinal hernia. Sac formed by the *tunica vaginalis et funiculi*. 1, Cavity of the tunica. (After Maclise.)

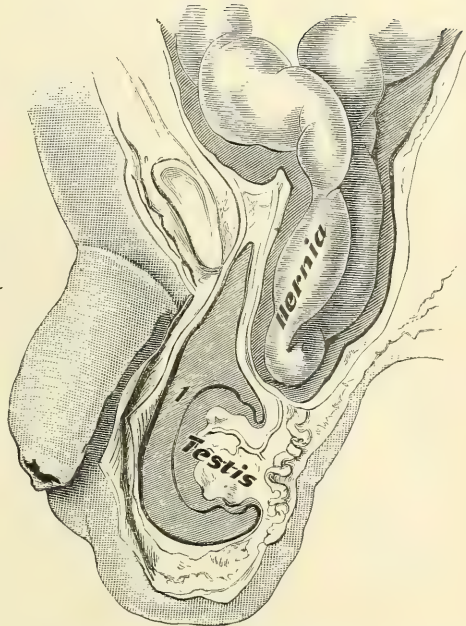


FIG. 537.—Infantile hernia (acquired), the intestine carrying with it a process of peritonæum by the side of the occluded spermatic tube. (After Maclise.)

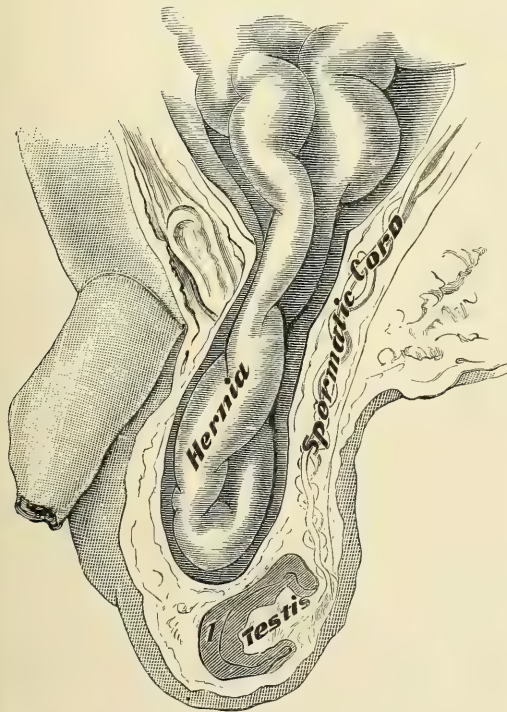


FIG. 538.—Complete inguinal hernia as it occurs in the adult. Not communicating with the cavity of the *tunica vaginalis testis*. (After Maclise.)

testicle (*congenital*) (Fig. 536); or it may be arrested in the tubular sheath which surrounds the spermatic cord (*infantile*), the contents not in contact with, but pressing upon, the testicle (Fig. 537).

Cause.—Inguinal hernia may be *congenital* or *acquired*. A *congenital* hernia exists at birth, and usually descends into the tunica vaginalis testis. It results from the patulous condition of the process of peritonæum, which is carried downward in the descent of the testicle and spermatic cord. *Acquired* hernia is one which comes on after birth. It is caused by the pressure of the intestine or omentum, from gravity and muscular effort combined.

Femoral hernia is always

acquired. The tumor enters the *crural* canal beneath Poupart's ligament, just to the inner side of the iliac and femoral vein (Fig. 539). If it remains in the crural sheath, it is an *incomplete*, but if it protrudes at the saphenous opening, it is a *complete* femoral hernia (Fig. 540).

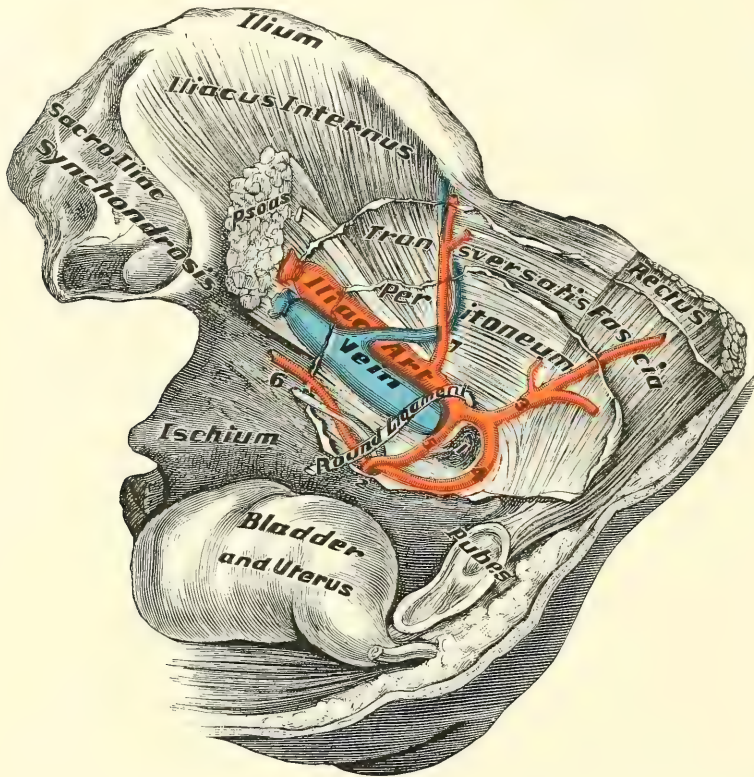


FIG. 539.—Showing the femoral ring and its relations to the iliac vein and the obturator artery when derived from the deep epigastric. 1, Femoral ring. 2, Obturator foramen. 3, Deep epigastric artery. 4, Abnormal origin of the obturator running internal to the neck of a femoral hernia. 5, The same, descending external to the neck of a femoral hernia. 6, Normal obturator artery. 7, Circumflex branch of external iliac. (Modified from MacLise.)

Umbilical hernia is congenital or acquired. It exists not infrequently at birth in both sexes, on account of the patulous condition of the omphalo-mesenteric duct. In this variety the only covering of the tumor is the sheath of the umbilical cord. In the acquired form the intestine escapes either directly through the navel, or more frequently to one side of this contraction. The sac of an acquired umbilical hernia is composed of the parietal layer, of the peritonæum, and the outer covering of integument.

Ventral hernia may also be congenital or acquired. The protrusion may occur at birth, as a result of failure of development in the muscles of the abdomen. It is usually met with along the linea alba above the umbilicus. The acquired form may occur at any point, and results from accidental or surgical wounds of the muscles and fascia. It is quite frequently met with in the wounds of incision in the operation of laparotomy.

Diaphragmatic hernia is usually due to a wound or rupture of the diaphragm. It may result from a congenital defect in this muscle. It generally occurs on the left side, on account of the protection afforded by the liver on the right side.

Gluteal hernia is extremely rare. The escape of the viscus is through the sciatic notch, and it may occur above or below the piriformis muscle.

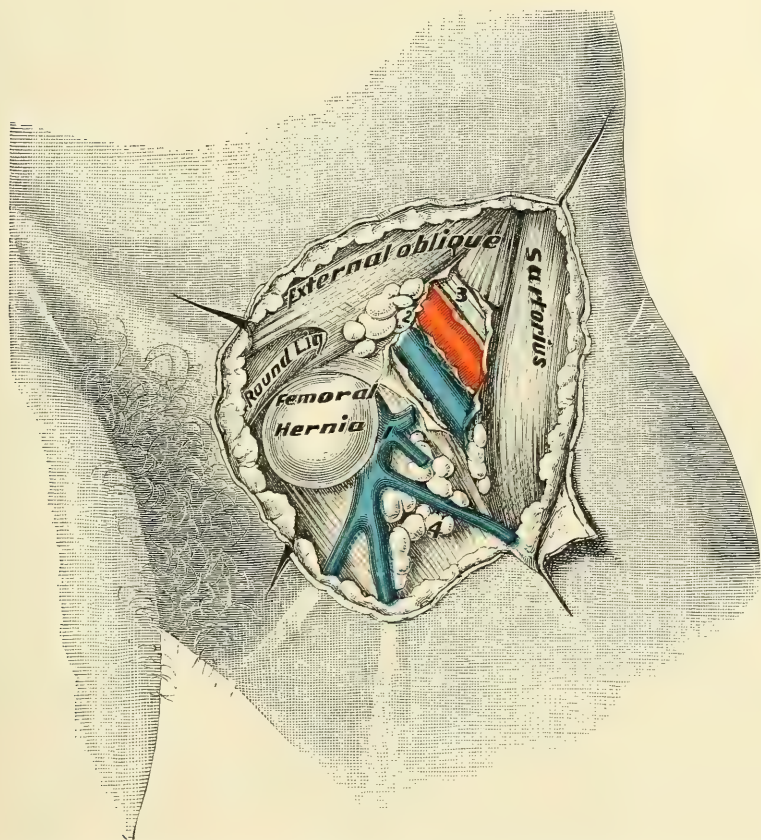


FIG. 540.—Showing the relations of a complete femoral hernia to the important organs of the groin. 1, Saphenous vein passing beneath the falciform process. 2, Femoral vein and artery. 3, Crural nerve. 4, Plexus of femoral lymphatic glands. (Modified from MacLise.)

Obturator hernia takes place in the thyroid foramen, and usually in the upper portion, in the canal which gives exit to the obturator vessels and nerves (Fig. 534). It is more common in women than in men.

Lumbar hernia occurs in the region situated between the twelfth rib and the crest of the ilium.

Hernia into the vagina occurs after partial or complete prolapse of the uterus, or after loss of substance, allowing escape of the intestine.

Symptoms—Inguinal Hernia.—When gradually acquired, the presence of a small swelling or tumor near the center of Poupart's ligament, or a little to the inner side of this point, is usually the first symptom of inguinal hernia. In a certain proportion of cases the appearance of the swelling has been preceded by a feeling of weakness or uneasiness referred to this region, which only disappeared when the recumbent

posture was assumed, or when strong upward pressure was made by the hand.

If suddenly acquired, the presence of the tumor is noticed soon after a violent strain of the abdominal muscles. Pain is almost always present, and the patient is generally aware of the moment the rupture occurred.

The diagnosis of inguinal hernia involves, (1) the differentiation between the direct and indirect form, and (2) between inguinal and femoral herniæ and the various swellings which may occur in this region; varicocele, hydrocele, bubo, incarcerated testicle, new formations, abscess, and aneurism.

A *direct* inguinal hernia is exceptional. The tumor formed by it is apt to be spherical (Fig. 541), is situated nearer the median line, and

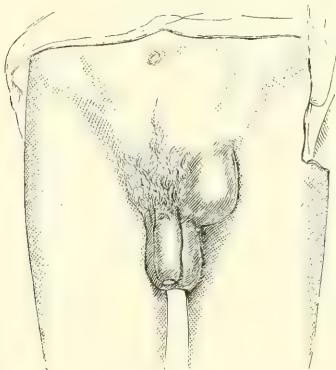


FIG. 541.—Direct inguinal hernia. (After Bryant.)

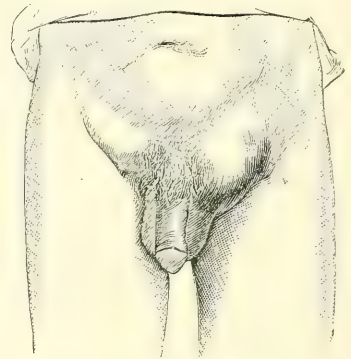


FIG. 542.—Oblique inguinal hernia. (After Bryant.)

the neck will be found to enter the abdominal cavity immediately behind the external ring.

The tumor formed by an oblique inguinal hernia (Fig. 542) is oval or elliptical in the incomplete, and oval or pyriform in the complete variety. The history of the swelling, if gradually developed, will indicate that the tumor commenced at the middle of Poupart's ligament and traveled toward the pubes. In cases of long standing, and when the tumor is of large size, the diagnosis between the direct and indirect form is scarcely possible, from the fact that the inner edge of the internal ring has been dragged down until it occupies a position just behind the external opening.

A femoral hernia (Fig. 543) is situated below Poupart's ligament, and near its attachment to the spine of the pubes, to the inner side of the femoral vessels. In lean subjects the neck of the tumor can be readily traced to the canal at this point. In corpulent persons the diagnosis is more difficult.

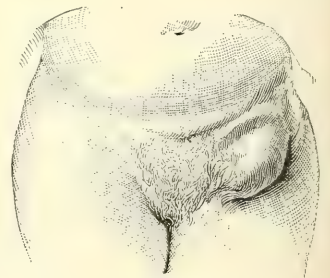

FIG. 543.—Femoral hernia. (After Bryant.)

The swelling of *varicocele* commences in the lower posterior portion of the cord, and increases gradually upward. To the touch the dis-

tended veins feel like worms. The tumor has none of the elasticity of hernia.

In the recumbent posture a varicocele and a non-incarcerated inguinal hernia will both disappear. If after the disappearance firm pressure is made with the fingers, and the patient is directed to resume the upright posture, the varicocele will return, while the hernia can not descend. Coughing does not affect varicocele. The accumulation of fluid in *hydrocele* of the tunica vaginalis is first noticed in the most inferior portion of the scrotum; the swelling is spherical at first, and becomes pyriform after the cord is involved. Hydrocele is translucent, and fluctuation may be detected. *Encysted hydrocele* of the cord near the external ring or within the inguinal canal may make differentiation more difficult. The impulse from coughing is not marked in hydrocele, the sense of weakness is absent, the cyst is small and usually remains so. If, after full consideration, doubt still exists, aspiration with the finest hypodermic needle will clear up the diagnosis.

Bubo.—In *chronic adenitis* the glandular character of the swelling can be made out distinctly.

In *acute adenitis*, although the peri-lymphatic infiltration is so extensive that the glands can not be recognized, the redness of the skin, the great tenderness on pressure, and the superficial character of the pain, with the coexistence of a urethritis or sore upon the penis or scrotum, will serve to establish the character of the lesion.

Incarcerated testicle may be suspected if there is absence of the organ on that side. If the testicle is not extensively atrophied, pressure will give the peculiar and characteristic sense of pain experienced in injury of this organ.

In neoplasms there is a history of progressive development entirely disassociated from that of hernia as heretofore detailed.

Abscess, which not infrequently appears above Poupart's ligament, is accompanied with inflammatory and septic symptoms which do not accompany hernia. Abscess of this region occurs with adenitis, as just stated, and with ostitis of the vertebræ or ilium. The recognition of either of these lesions will lead to the diagnosis of abscess.

In the manipulation of a hernial tumor the sensation imparted to the fingers will vary with the contents of the sac and the condition of the mass. If it contain only omentum, it is doughy to the feel, and will yield dullness on percussion; if the mass is composed of intestine, it is elastic, and more or less tympanitic on percussion. The "colicky" pain felt when the intestine is firmly compressed is of diagnostic value in determining the presence of a hernia.

Whether a hernia is reducible or not, there is always a perceptible impulse imparted to the tumor in coughing or sneezing. In strangulated hernia the diagnosis rests first upon the existence of a tumor, which is present in almost all cases. In very exceptional instances there is no protrusion noticeable. The next symptom is pain at the seat of the hernia. In character it is compared to that of *intestinal colic*, and, when not intensified in the neighborhood of the strangulation, it is usually referred to

the umbilical region. The symptoms of occlusion are more remote, and, while very strong in a diagnostic point of view, are not of such importance practically, because a diagnosis should be made and treatment instituted before the effects of obstruction are made evident. The cessation of fecal discharges may not occur in intestinal obstruction for several days after the occlusion, when the small intestine alone is involved, since the contents of the bowel below the constricted point may be evacuated. The vomiting of recently ingested food or drinks, followed by stercoraceous matter, is the last and strongest evidence of occlusion. Distention of the abdominal walls, with tympanitic resonance, is, when taken in connection with other symptoms, a strong link in the chain of symptoms which make the diagnosis conclusive. Hiccough is present in many cases, but is apt to be one of the later evidences of obstruction. Shock, that condition in which, as a result of an emotion or injury, the functions of the nerve-centers are more or less completely suspended, is present in a varying degree in almost all cases of strangulated hernia. It is evident in the rapid and weak pulse, occasionally missing a beat, or varying in exacerbations of rapidity and slowness; coldness of the skin, with unnatural perspiration; lack of facial mobility, the only expression being that of pain and anxiety.

In omental hernia the pain is not so intense as in intestinal hernia, and the symptoms of occlusion are always absent.

Treatment.—The treatment of inguinal hernia may be considered under the following heads: 1, reducible; 2, irreducible (not strangulated); 3, strangulated.

For a hernia not strangulated, the operative measures are *palliative* and *curative*; in strangulated hernia early operation is always indicated.

A *reducible inguinal* hernia should be returned to the abdominal cavity and retained there by the constant and careful employment of a truss or bandage and compress. In accomplishing the reduction the patient should rest upon the back, with the thighs flexed upon the abdomen and the pelvis elevated. In this position gravity carries the intestine and omentum toward the diaphragm, and this traction from within readily reduces the mass. If this should not succeed, gentle pressure with the hand will suffice. Once reduced, an effort should be made to prevent a recurrence.

For incomplete or slight hernia in patients who are not compelled to do heavy work, the elastic truss is most comfortable and safe. In all other cases the steel-spring truss must be worn. The pad will vary in size as the character of the rupture may require. The hard-rubber or wooden pads are preferable in the great majority of cases. A truss should be applied before leaving the recumbent posture, and should not be removed again until this posture is resumed. When ordering a steel-spring truss the following rule should be observed: Describe fully the character of the hernia. If the case is one of complete oblique inguinal hernia of the left side, take a lead-tape, lay one end directly over the internal ring of this side and carry the tape across the abdomen to the right, just below the anterior superior spine of the right ilium, and

across the gluteal region back to the same point below the left superior spinous process. Press the malleable lead closely to the integument in order to get an exact outline of the surface to which the truss is to be applied, and trace this directly upon a sheet of paper. The instrument-maker in using this tracing can model the spring to fit more comfortably, and after this temper the metal to make the required pressure. When a direct and indirect herniæ exist upon the same side, a single pad properly adjusted will suffice to secure both openings. When there exists a bilateral hernia, a double truss should be worn. A fair temporary truss may be made as follows: A piece of cloth or a tuft of wool, cotton, or oakum is rolled into a compress about half the size of the fist, covered with adhesive plaster (the adhesive surface being external), and is laid immediately over the inguinal canal, after the hernia has been reduced; while the patient is in the recumbent posture a spica bandage is carried around the pelvis and thigh so that the compress is held firmly in position. It is prevented from slipping out of place by the adhesive plaster.

When an inguinal hernia can not be retained by a truss, operative interference is indicated. In cases where the hernia can be retained and yet interferes with the usefulness or comfort of the individual, operation for radical cure is also advisable. In irreducible hernia which interferes with comfort or usefulness, or which is increasing in volume, or in persons going beyond the reach of proper surgical aid, operation for the radical cure should be undertaken. In aged persons operation should be avoided, unless strangulation is occurring.

Of the procedures for the radical cure of inguinal hernia, McBurney's and Macewen's offer the best prospects of success, the former being preferable on account of its greater simplicity of execution. Both operations are yet passing through a period of probation, yet so far they have given results which justify their repetition.

McBurney's Operation.—Under strict antiseptis an incision is made, beginning a little *outside* the situation of the internal ring and extending well down over the tumor in the direction of the cord and deepened until the sac is exposed (Fig. 544). The inter-columnar fascia having been divided, one blade of a blunt scissors is pushed under the edge of the external ring, and the anterior wall is split up to and a little beyond the outer border of the internal ring (Fig. 544 A). The deeper coverings of the sac are dissected off—preferably with the fingers. If, now, the fascia transversalis is partially removed high up in the canal, the cord may be quite easily separated from the sac to a point a little within the abdomen. The entire sac is now dissected up and lifted out (Fig. 544 B). (In many cases of congenital herniæ, this separation can not be effected, and then the sac must be cut away from the cord at each side of the latter. When this is done, the sac requires to be carefully closed by cat-gut sutures.) After thorough irrigation and cleansing the hands, the sac is opened and the intestine reduced. If the sac contains omentum, it may be reduced or tied off, as indicated by its condition, and the stump dropped back. Any adhesions are broken up or ligated and

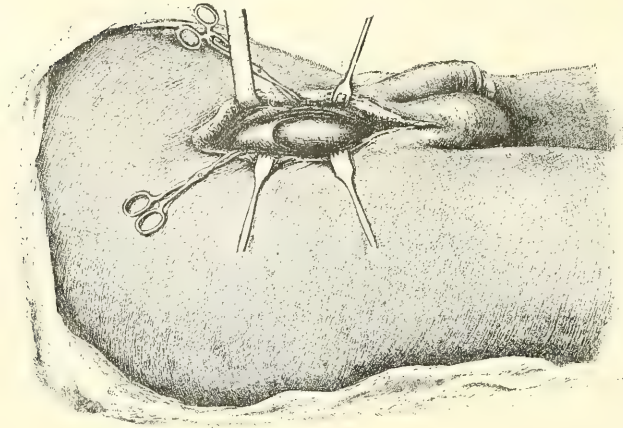


FIG. 544.—The hernial mass exposed by a free incision. The dissection carried down until the arch of the external inguinal opening is seen, with its outer and inner pillar on either side of the hernia. The lower part of the sac is covered by the inter-columnar fascia. (McBurney.)

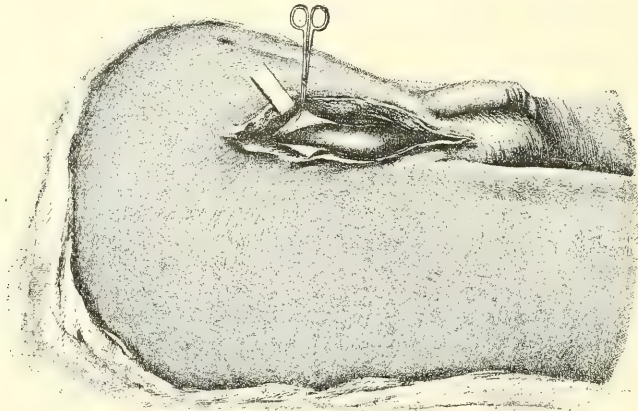


FIG. 544 A.—The external inguinal ring or opening divided and retracted, together with the aponeurosis of the external oblique muscle. (McBurney.)

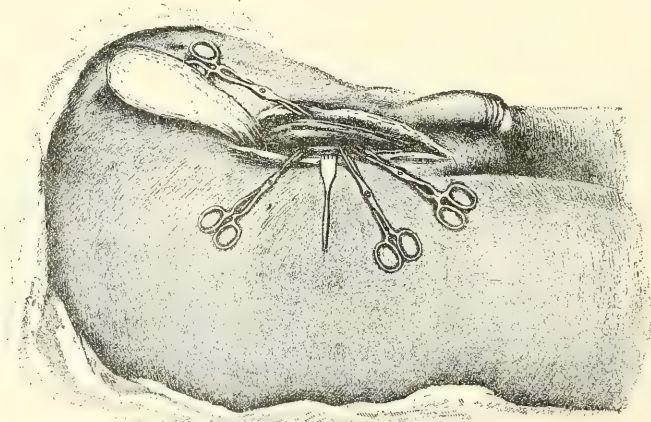


FIG. 544 B.—The sac with hernial contents dissected out, and the neck freed to the level of the parietal layer of the peritoneum and turned up on the abdomen. (McBurney.)

divided. The sac is now held vertically (Fig. 544 c), and the operator inserts one or two fingers through the neck into the peritoneal cavity. This is done to guard against the possible return of a loop of intestine or omentum into the sac during the application of the ligature. While the operator's finger is still in this position, an assistant throws a loop of very strong catgut around the sac, slips it along the neck, gradually tightens and finally ties it over the tip of the finger at the very

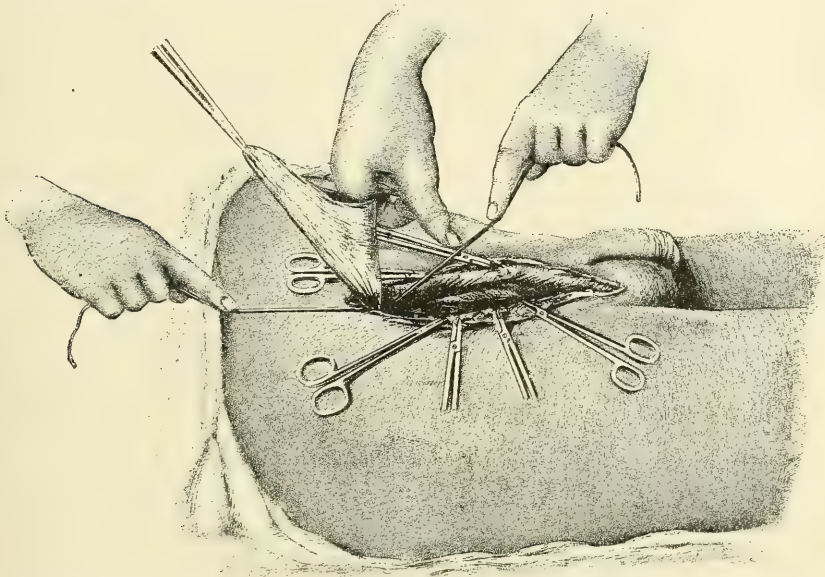


FIG. 544 c.—Sac opened, contents reduced, finger deeply inserted, and the neck of the sac tied off at the level of the internal surface of the abdominal wall. (McBurney.)

deepest portion of the canal (Fig. 544 c). The sac outside this ligature is cut away, leaving enough to securely prevent the ligature from slipping. The ends of the ligature are now cut away. The wound which remains has for its posterior wall the fascia transversalis in its inner part, and the peritonæum in its outer part. The upper or internal wall is formed by the edges of the skin, superficial fascia, external oblique aponeurosis, and conjoined tendon; the lower wall by skin, superficial fascia, and a strip of aponeurosis, including the outer pillar.

In order to prevent too rapid closure of the wound immediately over the internal ring, the skin is tucked under along each edge of the incision, by inserting from four to eight stout silk sutures a half-inch apart, so as to include all the tissues except the peritonæum. They enter about a half-inch from the edge of the wound, and as they are tightened the skin is folded under or inverted (Fig. 544 d).



FIG. 544 d.—Showing the lower portion of the wound closed, and the skin tucked under to maintain the upper portion open. (McBurney.)

Two tension sutures (Fig. 544 E) are next inserted through the skin and superficial fascia, and tied over rolls of iodoform gauze until the edges of the wound are about one fourth of an inch apart. The wound in the scrotum is stitched with catgut and a drain may be inserted at the

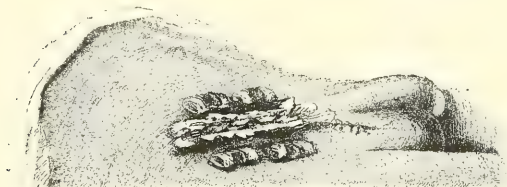

FIG. 544 E.—Supporting sutures. (McBurney.)

lower angle if deemed necessary. The wound is now deeply and tightly packed with iodoform gauze, over this masses of sublimate or carbolic gauze and borated cotton, and over all a spica bandage. A piece of rubber tissue should be placed around the penis and superficial to the dressing, to prevent the possible infection of the wound by the urine. The catheter may be employed for the first few days. In children, it is advisable to envelope the thighs and pelvis in plaster-of-Paris to prevent movements in bed. The dressing should be changed from the sixth to the twelfth day, and every four to six days after this. The silk threads may be removed about the tenth or twelfth day. The dorsal decubitus should be maintained for five or six weeks. A spica may be worn for a week or two after this and then discarded. No truss should be worn after the spica is removed.*

It will be seen that the object of this procedure is, 1, to *tie off the sac at the level* of the parietal peritonæum, thus obliterating any funnel-shaped process which might invite the reformation of a hernia; 2, to compel in the process of repair the formation of a deep cicatrix which will obliterate in great part the old canal, and also strengthen the otherwise over-stretched and weakened structures about the inguinal canal.

In incomplete hernia, where the sac is so short that it can not be tied, it is more than likely a cure would result from the cicatricial contraction secured by the operation. I have not found it necessary to insert the tucking or supporting sutures recommended by McBurney, but keep the wound open by careful packing with the gauze.

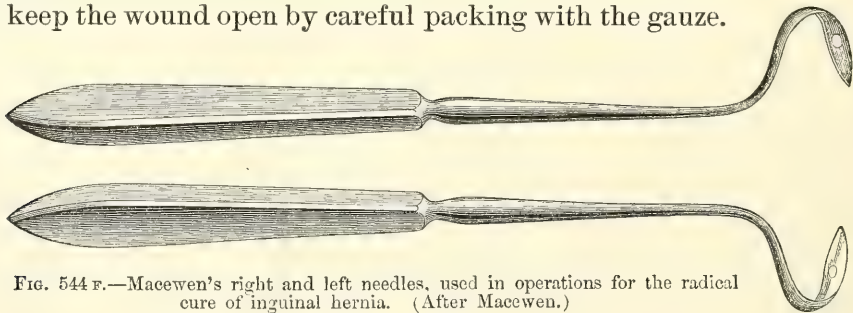


FIG. 544 F.—Macewen's right and left needles, used in operations for the radical cure of inguinal hernia. (After Macewen.)

Macewen's Operation.—This operation is intended for the cure of *oblique* inguinal hernia. The preparation is the same as that just given, and strict asepsis is necessary. Macewen advises the employment of a

* "Medical Record," March, 1889.

right and left needle (Fig. 544 F). The ordinary Hagedorn needle may be substituted. The incision and steps of the operation are practically the same as for McBurney's procedure down to the reduction of the hernia. Macewen advises the reduction of the contents of the sac before the first incision is made; but the separation of the sac from the investing fascia is more easily accomplished when it is distended by the hernia. The external abdominal ring being well exposed, an exploration of the sac is made, and the finger, introduced through the canal, examines the abdominal aspects of the internal ring and ascertains the relative position of the epigastric artery. Now free and elevate the distal extremity of the sac, preserving along with it any adipose tissue that may be adherent to it. When this is done, pull down the sac, and, while maintaining tension upon it, introduce the index-finger into the inguinal canal (outside the sac), and separate the sac from the cord and the parietes of the canal.

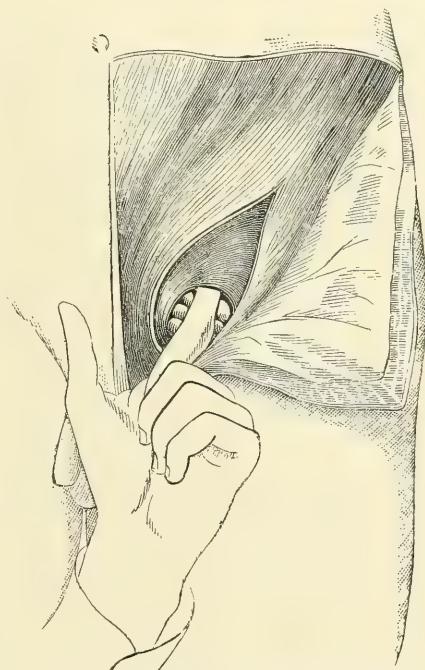


Fig. 544 G.—Separating the peritonæum from the abdominal wall around the neck of the sac. (After Macewen.)

Insert the index-finger outside the sac till it reaches the internal ring; then separate with its tip the peritonæum for about a half inch round the whole abdominal aspects of the circumference of

thering (Fig. 544 G). A large-sized cat-gut suture is now carried through the distal extremity of the sac and passed in and out several times through both walls and finally through the neck of the sac, so that when pulled upon



Fig. 544 H.
Folding the sac.
(After Macewen.)

the sac becomes puckered and folded on itself, as shown in Fig. 544 H. The free end of this suture is now threaded on one of the needles (or an ordinary half-

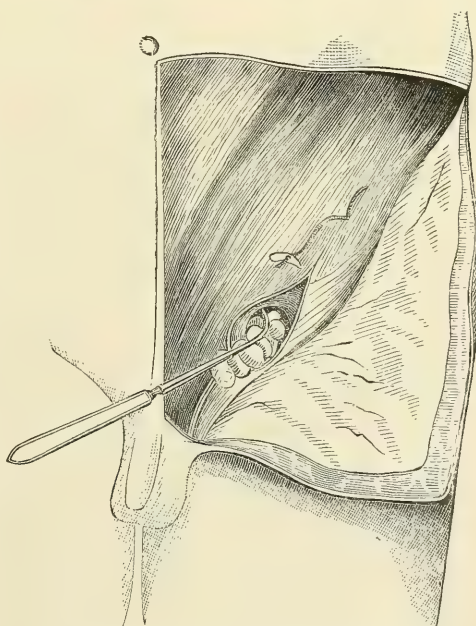


Fig. 544 I.—Carrying the folding suture through the abdominal wall. (After Macewen.)

curved Hagedorn needle may be substituted), which is inserted by the side of the neck of the sac between the parietal reflection of the peritonæum and the muscles, and made to penetrate the anterior abdominal wall about one inch above the internal ring (Fig. 544 i), the wound in

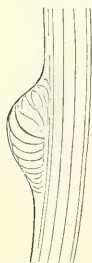


FIG. 544 j.—Showing the sac folded up and covering the abdominal aspect of the internal ring. (After Macewen.)

the skin being pulled upward so as to allow the point of the needle to project through the abdominal muscles without penetrating the skin. Traction upon the suture throws the sac into a series of wrinkles or folds, and pulls it *en masse* into the internal ring, where it projects on the internal aspect of the abdominal wall (Fig. 544 j). An assistant maintains steady traction upon this until the stitches are passed to close the inguinal canal, when its free extremity should be several times passed through the superficial layers of the external oblique muscle in order to secure it; or it may be tied to a piece of decalcified bone drainage-tube.

The method of treating the sac may be modified by carrying the suture after it is inserted into the distal end of the sac directly into the canal and through the abdominal wall. The sac is drawn in but not puckered. Macewen thinks this may suffice in children.

The second step in this operation is the closure of the inguinal canal. The sac being in the position just described, the string firmly held by an assistant, the finger is introduced into the canal and is held between the inner and lower borders of the internal ring, finding the epigastric artery so as to avoid it. The hernia needle, threaded for this part of the

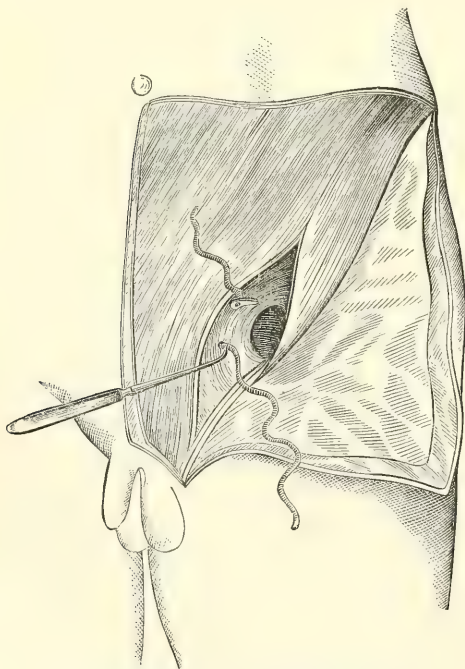


FIG. 544 k.—Inserting the sutures through the conjoint tendon. (After Macewen.)

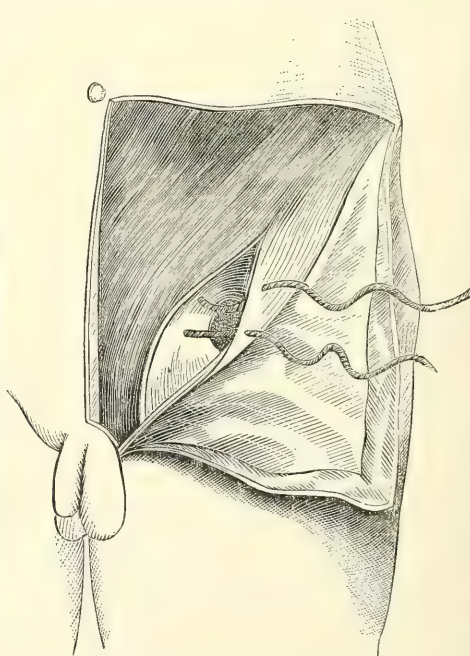


FIG. 544 l.—Sutures ready for tying. (After Macewen.)

operation with a very strong chromic-acid catgut suture, is now introduced and, guided by the index-finger, is made to penetrate the conjoint tendon in two places: first, from without inward near the lower border of the conjoint tendon, and then from within outward as high as possible on the inner aspects of the canal (Fig. 544 K).

The lower end of this loop is again threaded into the proper needle and passed through Poupart's ligament and the aponeurotic structures of the transversalis, internal and external oblique muscles, penetrating those tissues on a level with the lower stitch in the conjoint tendon. The upper end of the suture is also brought through the same structures at its level (Fig. 544 L).

The two free ends are now tied in a reef-knot, which finally closes the canal. The wound is closed with catgut sutures, bone-drain, strict antiseptic dressing, which is left on from fourteen to twenty-one days and reapplied. The patient is not allowed to leave the dorsal decubitus for four to six weeks, nor to work until the eighth week, and not to do any lifting or heavy work for three months.

In *congenital* hernia the sac is first isolated from the canal, opened and cut in two, care being taken to preserve the cord (Fig. 544 M). The lower part is closed to form a *tunica vaginalis*; the upper is pulled down as far as possible, split behind longitudinally so as to allow the cord to escape, and then closed by sutures and treated exactly as for acquired hernia.

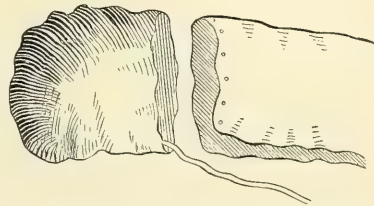


FIG. 544 M.—Manner of treating the sac in congenital inguinal hernia. (After Macewen.)

In competent hands and in well-selected cases in both of these procedures the danger is reduced to the minimum, and the prospects of cure are very good. Both are operations through open wounds. McBurney's method has the greater advantage of simplicity. The chief point in it is to tie the sac off at the level of the abdominal peritonæum. Another advantage of this procedure is the more thorough cicatrization secured, and in this, I believe, the operation depends chiefly for success. It will, in my opinion, be found the superior method for a large proportion of cases. In unusually large herniæ an advantage might be gained by puckering the sac, as advised by Macewen, and treating the wound after McBurney.

Strangulated Inguinal Hernia.—With the first symptom of strangulation the patient should be placed in the dorsal decubitus, with the foot of the bed elevated about twelve inches, the pelvis raised upon a pillow, the legs flexed on the thighs, and the thighs on the abdomen, so that the intestines and omentum will gravitate toward the diaphragm; or the knee-shoulder position may be assumed. Opium narcosis should be secured at once to relieve pain and to relax the muscles of the abdomen. Towels dipped in hot water and partially squeezed should be laid upon the tumor. If within an hour or two the hernia is not reduced, direct and careful pressure with the fingers may be added. The

neck of the tumor should be grasped and steadied between the thumb and fingers of one hand, and the contents pushed gently in the direction of the canal with the other. Taxis should not be continued longer than five or ten minutes at any one effort. It may be repeated at intervals of a half-hour or hour within the first six hours of the history of strangulation. The manipulation of a hernial tumor (taxis) after the first six hours of strangulation is of doubtful propriety, and after twelve hours should not be attempted. It is not only to be condemned for the injury inflicted upon the parts involved by this procedure, but on account of the procrastination in operative interference which it invites. It is true that occasionally reduction is effected after symptoms of strangulation lasting for a longer period than this, but these cases are so extremely rare, and the danger of a fatal termination so much increased by the delay, that it will be wiser to proceed at once to the operation.

In justification of early operation, it may be said that the large majority of cases which end fatally are those in which strangulation has existed for from twelve to twenty-four hours and upward before surgical interference; and that abdominal section in a patient not exhausted by suffering or disease is almost free from danger. The high rate of mortality after kelotomy will only be materially reduced when it is performed not later than twelve hours, and, better still, within the first six hours of strangulation.

Operation.—The pubes, scrotum, and integument near the tumor should be shaved, washed with ether, and finally with 1-to-3000 sublimate solution. The patient, fully anæsthetized, should be placed upon a table nearest the edge most convenient to the operator, with the pelvis slightly elevated. Before proceeding with the operation, a final effort at reduction should be made. An assistant is directed to place the legs of the patient over his shoulders, and to lift him until nothing but the shoulders and occiput rest upon the table. While in this position careful taxis should be made. If, after five minutes, reduction is not effected, the attempt should be abandoned. The parts about the field of operation should be covered with warm sublimate towels (1-to-3000), leaving a space about six by eight inches uncovered.

The incision should be in the long axis of the tumor, and may be made by cutting directly down upon the mass, or by pinching up the skin and fat immediately over the swelling, transfixing it and cutting outward. It should be of good length, with the center a little below the internal ring. All bleeding should be arrested at once with catgut ligatures. The wound should be irrigated with 1-to-5000 sublimate every five or ten minutes.

The first difficult point in the operation is the recognition of the sac. It is safe to cut carefully down until through the puncture of the sac a yellow or brownish-black fluid escapes. It is very exceptional when there is not enough fluid between the hernia and the sac to demonstrate its presence. If adhesions of the sac to its contents have taken place, no fluid would be encountered. Such a complication is rarely met with.

When this fluid begins to escape, a grooved director, with a very dull point, is inserted through the puncture, and the sac further divided until the finger can be admitted, when it is introduced and the sac divided in the entire extent of the tumor. At this stage of the operation the contents of the sac are clearly in view. A thorough irrigation should now be made, and the hands of the operator carefully cleansed. The finger of the left hand is carried toward the constriction, palmar surface upward, and the nail slipped under it. Holding the intestine out

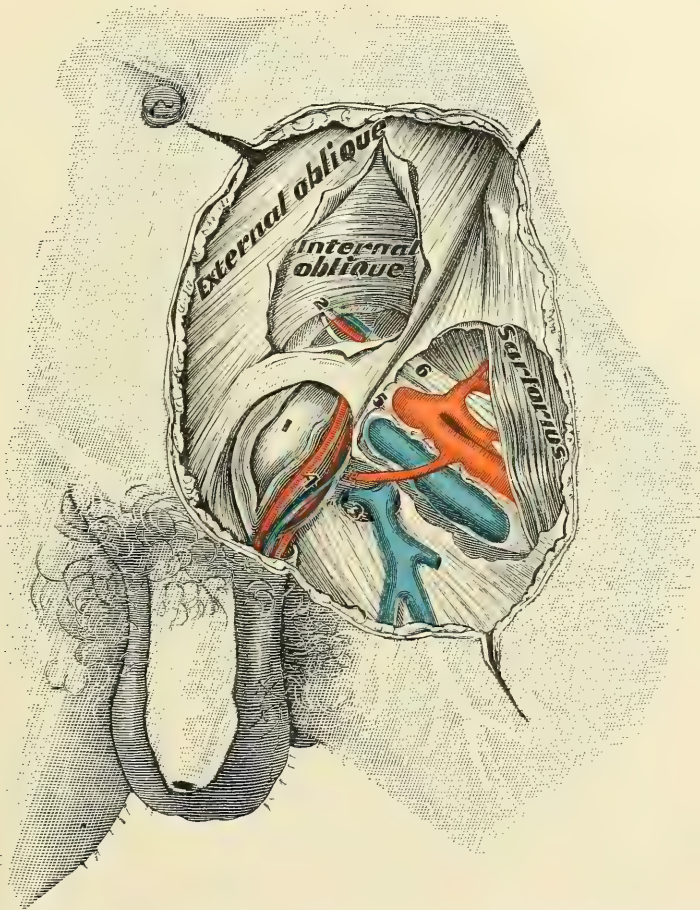


FIG. 545.—Showing the relations of a direct inguinal hernia to the epigastric vessels and the spermatic cord. 1, Hernial tumor. 2, Epigastric vessels in front of and external to the neck of the tumor. 3, Saphenous opening and vein. 4, Spermatic vessels. 5, Femoral vessels. 6, Crural nerve.

of the way, a long, probe-pointed bistoury is carried flatwise along the palmar aspect of the finger until the dulled point passes between the sharp edge of the ring and the nail. The edge is now turned upward against the ring, and pressed against this by the finger upon which it rests. The direction of this cut is upward and very slightly inward in inguinal hernia. It should not extend beyond the eighth of an inch. The finger-nail is usually sufficient to enlarge the opening after the first few fibers are divided.

As soon as the strangulation is relieved, the wound and exposed intestine should be covered in with towels dipped in warm Thiersch solution, and left for from five to fifteen minutes in order to determine whether the circulation can be re-established or not. The color of strangulated intestine varies from pinkish-gray to a black, motley color. The contents of a hernial sac should not be returned into the abdomen unless the color changes to a healthy red after the strangulation is freely relieved. If, after from five to twenty minutes, the circulation is established, reduction should be made. In accomplishing this, posture is

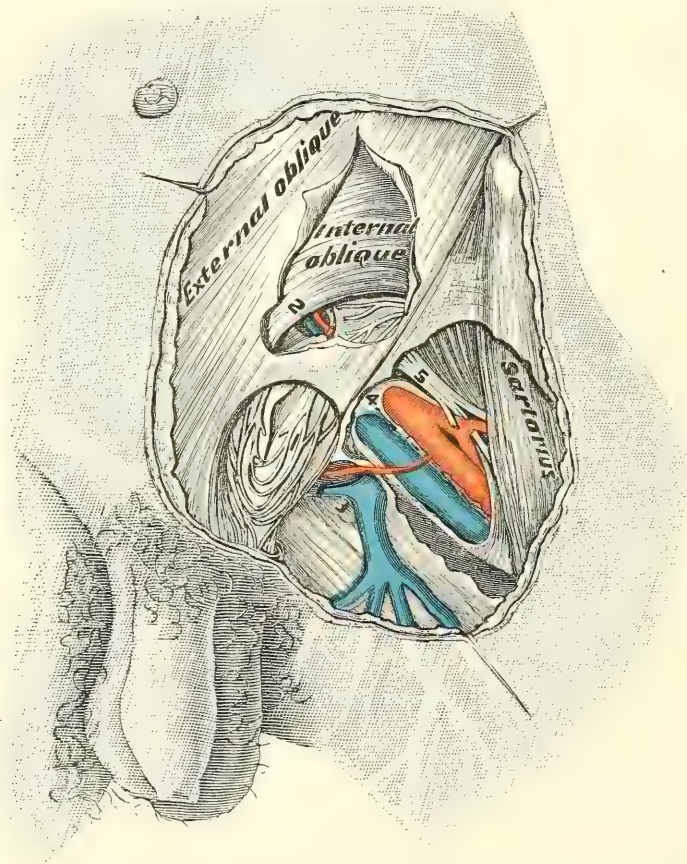


FIG. 546.—Showing the relations of an oblique inguinal hernia. 1, Tumor covered by cremasteric fascia. 2, Epigastric vessels behind and to the inner side of the neck of the tumor. 3, Saphenous vein and opening. 4, Femoral vessels. 5, Crural nerve.

important, and the intestine should be carefully pushed in between the thumb and finger. Once returned, the inner opening should be stopped with the finger or a sponge secured by a string or holder so that blood or the contents of the sac or irrigating fluid may not run into the peritoneal cavity. Sublimate solution should be discontinued after the hernia is reduced and Thiersch's solution used. If omentum is contained in the hernia, it should be transfixed at the neck of the sac with a large double catgut ligature, tied both ways, and the mass beyond the ligature cut

off. The stump should also be returned into the cavity. The details of McBurney's operation should now be carried out, in the hope of effecting a radical cure.

In case the intestinal wall is broken down, or is so nearly necrotic that its return into the cavity of the abdomen is attended with danger of rupture of the gut and escape of its contents, two alternatives present themselves, viz.: to leave the intestine protruding, and establish an artificial anus; or to exsect the dead portion and sew the ends together. If the patient is in good condition, and especially if in the prime of life and usefulness, exsection should be done. If, on the other hand, collapse is imminent, or if there is anything in the condition of the patient to contra-indicate a prolonged operation, the fecal fistula should be established.

Immediate exsection is performed as follows: Release the strangulation as above described, and draw out both ends of the bowel until six or eight inches of sound gut are exposed. Place a clamp or throw a loop of disinfected tape around each end of the intestine near the ring, to prevent the possibility of retraction or escape of the bowel or its contents inward. With sharp scissors divide the intestine squarely across at each end of the limit of necrosis, and cut a triangular piece from the mesentery, the base of which corresponds exactly to the section of intestine removed. Ligate all bleeding points in the mesentery. The operation is completed in the same manner as in exsection of the intestine, given on a preceding page.*

The question of preference between terminal anastomosis and lateral anastomosis by means of the Senn or Abbe rings, as heretofore discussed, may also be applied to this operation. If the operator is expert and safely rapid, or if the patient is in good condition, uniting the ends directly to each other is preferable.

When it is desired to establish an artificial anus, the strangulation should be relieved as already directed, and the bowel incised. As a rule, it is not necessary to stitch the gut to the wound, on account of the adhesions which usually exist.

In the course of a few weeks, after the patient has fully recovered from the effects of the strangulation and the operation, the canal may be restored, by opening the abdomen, exsecting the protruding and attached portion of intestine, and uniting the ends by stitches (p. 539). Or the operation of Dupuytren may be undertaken. It consists in gradually breaking down the promontory formed by the contiguous walls of the incarcerated loop, and, when this is done, allowing the external wound to close by granulation. The instrument used in this operation is, in shape, not unlike a pair of forceps, with flat, roughened jaws, and long handles, which can be locked with a clamp. The jaws are introduced at first for a slight distance only, one going into the ascending and the other into the descending part of the loop of intestine, when they are

* This operation of immediate exsection—i. e., exsection through the hernial opening—has been frequently and successfully performed in late years, notably by Dawbarn, who exsected about twelve inches of the ileum; McCosh also, of New York, and Stewart, of Minneapolis, who operated while House-Surgeon at Mount Sinai Hospital.

closed and clamped in such a manner that the walls of the promontory are held firmly in contact (Fig. 547). The instrument is allowed to remain in position. Adhesion occurs in the contiguous peritoneal coverings of the gut, while that part of the promontory firmly grasped by

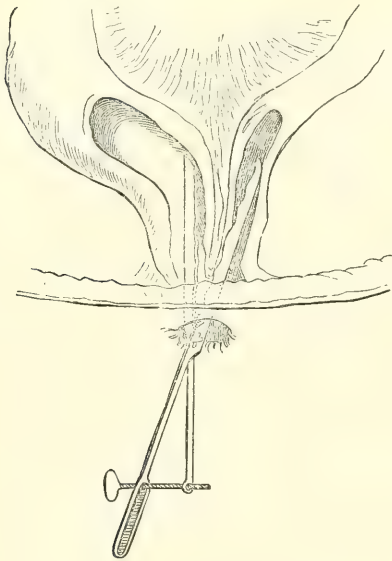


Fig. 547.—Dupuytren's clamp.
(After Gross.)

the instrument is crushed or sloughs away. As soon as the projection is sufficiently broken down, the fistulous opening may be allowed to close.

This procedure has been successful in a number of cases sufficient to justify its employment. If a cure is not effected, or if stricture should result, exsection should be performed.

Inguinal hernia in the *female* has the same relation to the epigastric vessels as in the male subject. In the complete form the contents may descend into the labium. The treatment does not differ materially from that just given. Cysts of the canal of Nuck not infrequently simulate a hernial tumor. Occasionally the ovary descends into the canal.

Femoral Hernia—Treatment.—This form of hernia is more difficult to retain in place with a truss, and is more likely to become incarcerated and strangulated than any other variety. The *prognosis* is, therefore, more unfavorable. The *diagnosis* depends upon the presence of a tumor in the location already given (Fig. 540), the neck of which can be traced to an opening at the inner side of the thigh, just external to the spine of the pubes, and below Poupert's ligament. The impulse in coughing is present, though usually less perceptible than in inguinal hernia. Cysts are less apt to complicate a femoral than an inguinal hernia. Enlargement of the lymphatic glands will not be apt to mislead, since there will have been a history of adenitis, a gradual increase in the size of the glands, which may be recognized as a group. The absence of impulse with the act of coughing will further aid in the exclusion of hernia.

The symptoms of strangulation differ in no essential features from those in inguinal hernia.

Treatment.—A reducible femoral hernia should be retained within the abdomen by a truss, the pad of which presses firmly over the femoral ring, just external to the spine of the pubes. The pad should be small, so that it may not compress the femoral vein, and the spring should be strong, for this form of hernia is not only difficult to retain, but is doubly dangerous when it escapes by the side of the pad.

In reducing femoral hernia, position is invaluable, and taxis may be of aid. The best position without taxis is the knee-shoulder posture, in which the abdominal muscles and fascia lata are relaxed, and the contents

of the abdomen gravitate toward the diaphragm. Or the dorsal decubitus may suffice, with the pelvis elevated, as well as the foot of the bed, and the thighs flexed upon the abdomen. In performing taxis it must be remembered that the bulk of the hernia must pass directly backward to clear the falciform process of the fascia lata, and then upward in the direction of the femoral canal (Fig. 540). Operation for the *radical cure* of femoral hernia may be determined by the rules given for the inguinal variety, and, while the prospects of success may not be so good, the principles of McBurney's procedure may be here applied.

In irreducible (not strangulated) femoral hernia operative interference is more positively indicated, from the fact that strangulation is more apt to occur, and that the employment of a compress to prevent a further descent of the mass is rarely successful.

In *strangulated* femoral hernia operative interference is indicated immediately upon the first symptoms of this condition. So rapid are the changes which occur in the contents of the sac that early operation, always commendable in every form of strangulated hernia, is especially so in the variety under consideration. Taxis should not be performed until the patient is fully anæsthetized. The preparation for the operation is identical with that for inguinal hernia. When narcosis is complete, the patient should be lifted by the legs in such a way that the thighs will be flexed upon the abdomen, and the pelvis raised considerably higher than the thorax. While in this position taxis, in a direction at first slightly backward and then upward, should be practiced. If reduction is not effected in from five to ten minutes, it should be discontinued.

The incision should be vertical in direction, along the middle of the tumor, with its center over the femoral ring. The length will vary with the size of the protrusion, but three or four inches will usually suffice. It should be made by cutting directly down upon the sac, and, when this is reached, the dissection should be continued between two dissecting-forceps. When the sac is opened and the fluid escapes, the index-finger should be introduced and carried upward until the end passes beneath the falciform process, and the nail is under the sharp constricting edge of Gimbernat's ligament. At this stage of the operation the hernia must be kept between the finger and the femoral vein, and the edge of the nail against Gimbernat's ligament, just at its insertion at the os pubis. A long, probe-pointed knife is now carried flatwise along the palmar side of the finger, with the cutting edge directed toward the median line. The constriction is relieved by lifting or scraping the attachment of Gimbernat's ligament from the os pubis, and in doing this the cutting edge of the knife should not be carried beyond this ligament, nor should it have any other direction than inward toward the symphysis. If these precautions are not observed, a dangerous complication may arise in the division of the obturator artery (or vein), in cases in which it is derived from the epigastric branch of the external iliac. In eight fatal cases of this character the patients were females. This abnormal derivation occurs in women in nearly 50 per cent of cases, and in 25 per cent in men, while

the vein is in relation to the femoral ring in a larger proportion of cases.* The manner in which the artery arches over the crural ring is shown in Fig. 539. When the strangulation is released, and the contents of the sac returned into the abdomen, an effort should be made to effect a radical cure as above directed.

Umbilical Hernia.—The diagnosis between this form of hernia and other tumors of the umbilical region will depend chiefly upon the impulse conveyed to the hernia in the act of coughing, or in crying in children. If the hernia is made up of omentum—and this is not uncommon in adults—it will be doughy to the feel and flat or dull on percussion. Intestine will be more or less resonant on percussion. If the mass is reducible in the recumbent posture, and under direct manipulation the diagnosis of hernia is evident. Cyst of the omphalo-mesenteric duct would be translucent, and fluctuation would be present. In congenital hernia the extreme thinness of the covering renders the recognition of the character of the tumor easy.

Treatment.—When an umbilical hernia which is only covered by the thin membrane of the cord exists at birth, it should be returned at once, and the opening closed by carefully adjusted silk sutures, supported by adhesive strips, drawn in dovetail fashion across the abdomen at the weak point. If covered over with integument, it should be reduced, a small, firm compress placed in the opening, and secured in place by a band of adhesive plaster carried around the child's belly. The acquired form is treated in the same general way. It should be reduced by posture, aided by careful taxis if necessary, and a truss worn day and night. In mild cases a light rubber belt will suffice after retiring for the night, but the heavier apparatus should be adjusted before leaving the recumbent posture.

Irreducible hernia, not strangulated, may be held in position by a properly adjusted cup-shaped compress.

The danger of strangulation is always present, and the question of the advisability of operating to relieve the incarceration, and of sewing up the opening, must be determined by the circumstances of each particular case. In the operation for radical cure the sac should be tied off or cut away and the wound closed with strong silk sutures. These sutures should include all the tissues of the abdominal wall, so that when tightened the apposing surfaces of the parietal peritonæum of the two edges will be united.

With the first symptoms of *strangulation* the patient should be etherized, and a final effort at reduction made by careful taxis. If this does not succeed, kelotomy should be at once performed. The incision should be vertical, with its center corresponding to the neck of the hernia. On account of the exceeding thinness of the integument and other coverings, great care should be exercised in cutting down upon the tumor. As soon as the sac is punctured, the dull director is introduced,

* The author's "Essays in Surgical Anatomy and Surgery." William Wood & Co., 1878. "New York Medical Record," October, 1877.

and the sac divided sufficiently to allow the introduction of the finger, upon which the further division of the sac is made. If the finger-nail can now be insinuated between the neck of the hernia and the constricting ring, it should be done, holding the palmar aspect of the finger toward the pubes. The probe-pointed bistoury is now introduced flat-wise, and the constriction divided for not more than a quarter of an inch at first. The direction of this cut should be in the median line, and toward the pubes; or the constriction may be incised on the upper aspect of the neck if more convenient to the operator.

The management of the strangulated bowel or omentum should be the same as advised in inguinal hernia. The sac should be transfixed with a strong double catgut ligature, tied each way, the part beyond the ligatures cut off, and the stump returned within the abdomen. The *radical cure* should be attempted by introducing a flat Thiersch sponge through the opening, which will prevent blood or other matter from entering the peritoneal cavity. The margins of the opening should now be trimmed so as to secure freshened edges for approximation. When all bleeding has ceased, the sponge should be removed, and the fascia, aponeuroses of the muscles, and integument brought together by silk sutures, as above directed.

Ventral hernia is amenable to the same general treatment as the acquired umbilical variety. In operation for the cure of hernia after laparotomy, the parietal peritonæum should be first closed with catgut. In closing the remainder of the wound the sutures should be made to include both layers of the dense sheath of the rectus muscle.

In one of the author's cases the recti muscles, during violent straining at parturition, were split apart from a point three inches below the xiphoid appendix to within an equal distance of the pubes. At least two thirds of the small intestines and a portion of the transverse colon were prolapsed into this enormous hernia. After incision over the entire extent of the tumor, the intestines were reduced, a strip of skin varying in width from one half to two inches was trimmed off from each side on account of redundancy, and the wound closed by large silk sutures, which transfixed the entire thickness of the abdominal wall of each side. A cure was effected.

In *diaphragmatic hernia* the diagnosis must be based upon the symptoms of obstruction. Pleuritis will be present in a varying degree. The only means of arriving at a positive diagnosis is to make the median incision, with manual exploration. The hernia may be reduced by traction, with or without dilatation of the opening in the diaphragm. The prognosis is unfavorable, and the gravity is increased as operative interference is delayed.

The recognition of *gluteal hernia* is also difficult. If with the symptoms of obstruction there is pain in the region of the sciatic notch, or in the distribution of the gluteal or sciatic nerves, which is increased by direct pressure, the presence of gluteal hernia is usually certain. If a tumor is appreciable, it is still more positive.

To locate the notch, place the patient on his belly and hold the leg

perfectly straight, with the toes pointing directly downward. A line, drawn from the posterior superior spine of the ilium to the upper surface of the great trochanter, will cross over the foramen.

The incision should be free, and the fibers of the gluteal muscles separated with the finger. The vessels should be located before the constriction is divided.

Obturator hernia may be present without any appreciable tumor. It may be recognized by digital exploration through the rectum or vagina. Pressure upon the obturator nerve may produce pain in the hip or knee. If the symptoms of obstruction are present, the hand should be introduced through an incision in the linea alba, when, by careful exploration of the pelvis, the character of the lesion can be determined. In the effort at reduction by traction from within, the thigh should be rotated outward to relax the obturator muscle. If necessary, an incision may be made immediately over the foramen, and the constriction divided from below. The point at which the intestine usually escapes is in the adult between two and two and a half inches external to the symphysis pubis, and on a line with the inner border of the femoral or iliac vein. When the fibers of the pectineus muscle are divided, the tumor will be encountered.

Lumbar and vaginal hernia do not demand especial consideration. The diagnosis will depend upon the appearance of the tumor, with the symptoms of strangulation, when the constriction is sufficient. The return of the mass which follows prolapsus of the uterus into the vagina may be effected by direct reposition of the uterus, or by conjoined manipulation with one hand introduced through an opening in the linea alba.

Fecal Fistula.—A fecal fistula may exist between any portion of the intestinal canal and the exterior through the integument; from the intestine into a normal cavity, as the bladder or uterus, and thence to the exterior; into an abnormal cavity, as an abscess, and thence out through one of the hollow organs or directly to the skin; or it may lead into a *cul-de-sac* or blind pocket.

Fecal fistulæ are *congenital* and *acquired*.

Imperforate anus is the most frequent cause of congenital fistula. The pressure of accumulated matter at the extremity of the canal induces inflammation, ulceration, and perforation, with extravasation of the bowel contents. If the congenital obstruction is low down, the opening may occur through the perinæum, bladder, or vagina. If higher up, the fistula may open through the abdominal wall at the umbilicus, or below this point in the linea alba, or posteriorly near the spine. A rare cause of congenital fistula is the presence of the omphalo-mesenteric duct, or Meckel's diverticulum, which, as heretofore stated, opens at the umbilicus.

Acquired fecal fistula may be *surgical* or *accidental*. Colostomy and enterostomy are examples of the former, while the latter result from perforating wounds of the intestinal canal, either from the exterior, as by *gun-shot* or *punctured wounds*, or by the passage of some ingested

sharp or hard body through the intestinal wall; or by perforation of the intestine by an ulcer or abscess, or from gangrene due to strangulation, contusions, etc.

The *diagnosis* of a fecal fistula which communicates directly with the exterior is made evident by the escape of gas and ingested matter. Indirect fistulæ can also be determined by the careful examination of the discharges from the organs through which they pass. In a case reported by Dr. Krackowitz, in the "Transactions of the New York Pathological Society," an ulcer of the appendix vermiformis had opened into the bladder. The diagnosis of entero-vesical fistula was established by the escape of a lumbricoid worm from the urethra. Blind fistulæ can not often be made out until demonstrated by exploration.

In determining what portion of the intestinal canal the fistula opens into one must consider, first, the character of the discharge; second, the distance from the rectum, as determined by injections.

In *congenital fistulæ* opening into the perinæum the inference is natural and generally correct that the lower portion of the large intestine is involved. If bile is freely discharged through a *congenital* or *acquired* fistula, it is safe to conclude that the opening is not very far removed from the duodenum or upper portion of the jejunum. The odor of gas or ingesta escaping from the large intestine is usually more offensive than that from the small bowel.

When caused by a wound, the known direction and character of the penetrating body will aid in arriving at a correct idea of the gut penetrated.

A fistula resulting from perityphlitic abscess occurs almost always in the cœcum, more rarely in the lower portion of the ascending colon or lower ileum. When the colon is involved the location may be determined by slowly injecting milk per rectum, having measured the quantity injected until it begins to flow out at the external opening.

The *prognosis* of fecal fistula depends upon its character. Congenital fistulæ are obstinate under treatment. Acquired fistulæ may be cured in the majority of instances.

Treatment.—Congenital fistulæ, resulting from imperforate anus, can only be healed by the establishment of an opening in the perinæum which shall communicate with the most dependent portion of the blind gut. When this is done, a pad worn over the fistulous opening will lead to its gradual occlusion. When the fistula is the result of a patulous omphalo-mesenteric canal, it may be closed by sutures or by a compress.

Acquired fistulæ not infrequently heal spontaneously. The operation consists in cutting down upon the opening in the gut and laying freely open all sinuses which communicate with the fistulous outlet. As the track of the fistula is often tortuous, it is at times exceedingly difficult to follow it. A repetition of the method employed in the following case will be of service in the more complicated operations:

In 1880 a young man came under my observation on account of a

pistol-shot wound. The ball had entered the abdomen on a level with and about one and a half inch to the inner side of the left anterior superior spine of the ilium. From the direction in which the weapon was aimed, the missile was thought to have passed directly back and lodged in the iliac fossa. There were no immediate symptoms of perforation of the intestine. An abscess formed which discharged from the wound of entrance, and, about six weeks after the receipt of the injury, a fecal fistula was established. The fistulous track was so long and tortuous that it could not be followed. After the anæsthesia was complete, warm milk was thrown into the bowel until it ran out at the opening. The stream of milk was then followed without difficulty, and the opening discovered. All communicating sinuses were laid open and packed with carbolized gauze. The wound closed within a month, and the patient was cured.

It will be advisable, in attempting to close the fistula, for the patient to maintain a position which will prevent the gravitation of ingested matter into the opening.

Closure of the external orifice by means of sutures is not advisable, since it may induce fecal infiltration. A recovery is usually hastened when the margins of the wound in the integument can be stitched to the edges of the opening into the bowel, as directed in enterostomy.

Colostomy.—The establishment of a fecal fistula between the colon and the abdominal wall is usually performed in the cœcum or first few inches of the ascending portion, the lower part of the descending colon, or in the sigmoid flexure.

Colostomy is indicated as a palliative measure in occlusion of the alimentary canal on the anal side of the operation by stricture, neoplasms, volvulus, intussusception, or any lesion for the relief of which *exsection* or lateral anastomosis is not permissible. In chronic *colitis* or *proctitis* it is a curative operation, in giving complete rest to the diseased bowel until recovery ensues.

In selecting the place of operation, the right or left lumbar or the left inguinal region may be chosen, the aim of the surgeon being to get as near the point of occlusion as possible.

When the rectum alone is involved, the left inguinal region should be chosen (Littre), for the sigmoid flexure, the left lumbar region should be selected; if the descending or transverse colon are involved, the right lumbar incision is preferable.

Callisen's Operation—Left Lumbar Colostomy.—Place the patient on the right side, inclined well over upon the abdomen. The objective point is the posterior surface of the descending colon, at a point situated half-way between the crest of the ilium and the last rib, and half-way between the spinous process of the third lumbar vertebra and the anterior superior spine of the ilium. Make an incision about five inches in length, the center of which shall strike this point, commencing about one inch from the vertebral spines. The direction of this incision should be obliquely from above downward and forward—that is, parallel with the lumbar vessels and nerves. Dividing the skin and fascia, the poste-

rior border of the abdominal muscles and the anterior border of the quadratus lumborum muscle will be seen. The posterior wall of the colon—that portion which is not included in the peritonæum—will be found a little posterior to the border of this muscle. A safe guide is to insert the finger along the edge of the quadratus muscle and feel for the kidney. The gut is immediately in front of this organ. It is important to keep well toward the spine in order to avoid opening into the peritonæum. Usually at this juncture, with the wound perfectly dry, the wall of the intestine can be picked up with the finger and lifted toward and into the wound. If it has receded, deep pressure upon the anterior wall of the abdomen will bring it into view. If the cavity of the peritonæum is not opened, it is scarcely possible to get hold of the small intestine. The colon may be recognized by its large size and by its sacculated wall. If there is any doubt as to the large intestine being the one which presents, the expedient of pumping air into the rectum may be resorted to, the immediate distention of the colon proving its close relation to the rectum. As soon as the bowel is brought into the wound, it should be transfixed by two strong silk sutures, introduced about an inch apart, through the integument of one side into the intestine for about one half an inch and out again and up through the margin of the incision in the integument on the opposite side. The colon is now held well up into the wound by traction on the sutures in the hands of an assistant, while the operator makes a longitudinal incision in the wall of the gut superficial to the threads which have transfixed it. When this is done, the center of the ligatures is drawn out by a tenaculum, divided, and the four threads tied securely. From two to four additional sutures may be introduced on each side, to guard against the infiltration of fecal matter. The wound in the integument should now be closed from each end down to or very near the level of the opening in the colon.

If there is much escape of fecal matter immediately following the operation, a dressing need not be applied. The patient should be made to lie upon the back, in which position gravity favors the escape of the bowel contents. At times it is convenient to apply an iodoformized and sublimate gauze dressing, with a bandage around the abdomen. In from three to seven days the stitches can be removed, and, after the wound is healed, a compress and belt should be worn to prevent the escape of fæces until the convenience of the patient is suited.

If in the search for the colon the cavity of the peritonæum is opened, it should be immediately sewed up with continuous catgut sutures.

If, after colostomy, prolapse of the intestine occurs, it may be returned and held in place by a properly adjusted compress of gauze. If the opening contracts to such an extent that the escape of fecal matter is hindered, it should be dilated with the finger or by means of a gum or sponge tent.

Amussat's operation, or *right lumbar colostomy*, is performed in the same manner as the procedure just given, upon the opposite side of the body. Littré's operation is performed by opening into the peritoneal

cavity by an incision in the abdominal wall just internal to the left anterior spine of the ilium over the sigmoid flexure. The small intestines are displaced to the right, while the sigmoid flexure is brought up to the wound and fastened by two rows of sutures. The first, of fine silk, attach the edge of the parietal peritonæum to the peritoneal layer of the gut, while those of the second row pass through the integument and into the lumen of the intestine, as in colostomy. A like operation may be done upon the transverse colon, though not often indicated.

Peritonitis.—In properly selected cases, abdominal section for the relief of peritonitis with effusion has, within late years, become a recognized operation. It is more applicable to cases of local peritonitis, and in chronic inflammation of this membrane, than in acute general peritonitis. The operation is justifiable in the acute inflammation which follows perforation of the alimentary canal, in which closure of the perforation, and a thorough cleansing of the cavity of the peritonæum, are essential. Left without operation, these cases, almost without exception, end fatally; also in chronic local peritonitis, due to any cause in which the symptoms of septic absorption are prominent. The same principle should apply in these cases as in chronic effusions into the pleural cavity.* Mr. Treves, in his excellent monograph, cites a series of cases: one in which Mr. Hancock opened the abdomen for chronic local peritonitis, due to disease of the vermiform appendix; Mr. Tait, in several cases of chronic peritonitis; Dr. Savage, in eight cases of pelvic peritonitis treated by laparotomy; Dr. Playfair, in one case of chronic puerperal peritonitis—all ending in recovery.† When the incision is made, any effused liquid or pus should be removed by means of soft Thiersch sponges on holders, and the cavity of the peritonæum flooded with warm Thiersch solution or 1-to-20000 sublimate solution, or, if neither of these can be had, with clean warm water at a temperature of 100° to 110° F. As soon as it is introduced it should be removed with the sponges, and the irrigation repeated until it comes away clear.

In several instances I have seen the sublimate solution employed in this manner in disinfection of the entire peritoneal cavity with success.

In severe and obstinate cases, drainage should be established in the same manner as described in the after-treatment of certain ovarian tumors.

In the *diagnosis* of peritonitis, pain, though not always present, is in the majority of instances an early and prominent symptom. It is intense in character, almost constant, being first noticed in a given point and extending later with the progress of the inflammation to any portion of the abdominal cavity. Tympanites exists in a varying degree, the patient generally lying upon the back, with the legs drawn up and the thighs flexed upon the abdomen. The abdominal muscles are usually rigid, taking no part in the respiratory act. Constipation is the rule in a large majority of cases. Vomiting is not so common a feature, though often occurring in peritonitis. Difficulty in urinating, or complete retention, occurs in some cases, especially in those in which the inflammatory

* "Intestinal Obstruction." Lea, Sons & Co., Philadelphia, 1884.

† Ibid.

process is marked in the pelvic region. The pulse is increased in frequency. Peritonitis is in almost all instances secondary to a lesion of one or more of the abdominal viscera.

Abscess in the Abdominal Region.—Abscess may occur between the parietal layer of the peritonæum and the muscular walls of the abdomen, within any circumscribed area of the peritoneal cavity, in the loose tissues behind the peritonæum (retro-peritoneal abscess), and in the substance or within the capsules of any of the viscera.

The diagnosis of *extra-peritoneal* abscess will in part depend upon the localized pain or tenderness under pressure, and the induration and œdema which are characteristic of acute inflammation with pus-formation, together with the usual exacerbations of temperature, with or without rigors or a chill. Fluctuation may be appreciable in extra-peritoneal abscess in patients with thin abdominal walls, and, if situated between the muscles or in the subcutaneous tissues, is usually diagnosed without difficulty. The employment of the exploring-needle and aspirator is always invaluable in the recognition of an abscess. The immediate indication in treatment is to cut down upon the tumor, using the needle which has indicated the presence of pus as a guide, until the sac is reached, puncturing this sufficiently to admit the point of the closed dressing-forceps, and enlarging the opening by separating the handles of the instrument. The principles of irrigation and free drainage apply here as to other recent collections of pus.

Intra-peritoneal abscess is usually single, although in exceptional instances there may be two or more different centers of suppuration. The most frequent locations are the iliac regions and the pelvis. Inflammation of the cœcum and vermiform appendix, and the peritonæum immediately about these organs (*typhlitis* and *perityphlitis*), is a not infrequent cause of abscess. All of the lesions considered under the head of intestinal obstruction may induce the formation of pus in the cavity of the peritonæum. Abscess occasionally forms between the upper surface of the liver and spleen and the diaphragm as a result of tearing loose portions of the suspensory ligaments of these organs.

Diagnosis.—Intra-peritoneal abscess must be differentiated from neoplasms, cysts, fecal impaction, with cœcitis or colitis, all tumors resulting from obstruction, hydronephrosis, aneurism, hæmatoma, and abscess within the solid viscera. The characteristic features of neoplasms, fecal impaction, and the various lesions which induce intestinal occlusion, have just been considered. Hydronephrosis develops slowly, and has a history of obstruction of the ureter or urethra which can not be mistaken, while the expansile pulsation and *bruit* of an aneurism render it easy of recognition. Abscess develops quickly, and follows an injury or occurs in the course of some inflammatory process. If, after a blow in the hypochondriac region, or a severe fall, tenderness is developed along the upper surface of the liver or spleen, accompanied by the well-known constitutional symptoms of pus-formation, perihepatic or perisplenic abscess may be suspected. The same symptoms, occurring in the course of typhlitis or perityphlitis, point to suppuration in the region of the

cæcum. In like manner ovaritis, metritis, salpingitis, cystitis, and pelvic cellulitis are conditions which not infrequently induce abscess in the pelvic peritonæum.

Induration and fluctuation are scarcely appreciable in the earlier stages of abscess between the liver or spleen and diaphragm on account of the resistance offered by the ribs. Localized pleuritis and pain in the respiratory act should not be without significance when considered with other symptoms. In perityphlitic abscess induration is felt early in the inflammatory process, tenderness is well marked, while muscular rigidity, especially of the right side of the abdomen, is present. There are dullness on percussion and œdema of the skin. As the inflammatory process extends, the induration becomes more superficial or descends along the iliac fossa. Fluctuation is deep-seated and difficult of recognition until there is either pus in large quantity, or the wall of the abscess has risen in close proximity to the integument. In abscess within the pelvis, exploration by the rectum or vagina will aid in a correct diagnosis.

Treatment.—In perihepatic abscess the pus should be evacuated by means of the aspirator. The needle should be of sufficient caliber to allow the pus to come away freely, and should be introduced in the same opening and to the same depth of the smaller needle which was employed in arriving at a diagnosis. Washing out the cavity of the abscess, when it is of recent formation, is not advisable for fear of over-distention and rupture of the sac. Incision and free drainage may be employed when the abscess is large, the pus superficial, and when adhesions have occurred which will prevent infiltration into the general cavity of the abdomen or pleura.

Perityphlitic abscess demands operative interference as soon as the symptoms point to a collection of pus.

In *appendicitis* with symptoms of perforation operation is urgent and should be undertaken, unless a condition of collapse supervenes so rapidly as to contra-indicate interference. The inflammatory changes in perityphlitis are now understood to proceed in almost all cases from lesions of the appendix vermiformis, the abscess when resulting being primarily *intra-peritoneal*. Appendicitis may be due to the presence of a foreign substance in this organ, or idiopathic ulcer of the wall may lead to peritonitis and perforation, or gangrene may occur, possibly from interference of its proper blood-supply from pressure by surrounding viscera.

The diagnosis is, as a rule, attended with considerable difficulty. While pain varying in severity is usually present, it may be absent until perforation occurs. It is usually acute in character, and by careful and direct pressure with the index-finger alone may be localized about two inches from the right anterior iliac spine, on a line drawn from this point to the umbilicus. Muscular rigidity over the right iliac region may be mistaken for inflammatory induration. High febrile movement points to the formation of pus rather than to spreading peritonitis. The propriety of operation must be determined by a careful study of the individual case, and in no surgical disease is it so difficult to give any positive rule as in the one under consideration.

When the accumulation of pus is evident from recognizable tumefaction, or œdema of the abdominal wall, incision is imperative. In cases of doubt, careful incision adds little to the gravity of the situation and is therefore advisable. Exploration with the aspirator needle is scarcely permissible, unless by incision it is demonstrated that adhesions have occurred. Then its use is indicated in determining the exact location of the pus. If adhesions do not exist, the peritoneal cavity may be opened and the condition of the appendix ascertained by inspection. Great care should be exercised in manipulating the organs involved for fear of breaking down adhesions between contiguous layers of peritonæum and thus spreading the infection. If the appendix is found to be diseased, it may be tied off near the cæcum with a silk ligature and removed. If general peritonitis is threatened, especially if perforation has occurred, a most careful cleansing of the part in the field of operation should be done. It is often safer not to close the wound, but to cut off the danger of infection by surrounding the location of the appendix with a firm wall (packing) of iodoformized gauze, removing this in a few days after firm adhesions have been established. When abscess is present, it should be evacuated and drained. The incision in all cases should be perpendicular and directly over the known location of the cæcum and appendix. Fecal fistula forming in the course of appendicitis or perityphlitis should be treated as advised for other forms of fecal fistulæ.

Retroperitoneal Abscess.—Abscess behind the peritonæum is usually circumscribed, although it may be diffuse. Commencing at any portion of the posterior abdominal wall, pus is apt to dissect up the loose tissues behind the peritonæum, and to travel downward, pointing ultimately in one of the following situations: Above Poupart's ligament, external to its center; beneath this ligament, in Scarpa's space; over the iliac crest; in the gluteal or lumbar region; at the obturator foramen, or less frequently it may empty into the colon, rectum, bladder, uterus, vagina, or pass out through the perinæum. Occasionally the dissection is upward into the pleura, or it may pass across the spine to the opposite side.

Causes.—Ostitis of the vertebræ, ribs, or bones of the pelvis, rupture of the psoas or iliacus muscles; lesions of the kidneys or supra-renal capsules (cysts, neoplasms, calculi, pyelitis, rupture with the extravasation of blood and urine); diseases of the pancreas, liver, spleen, duodenum, colon, and rectum; the pelvic viscera, or tubercular changes in the lymphatics of this region—may cause retroperitoneal abscess.

Diagnosis.—The physical signs of the earlier stages of pus-formation behind the peritonæum are not well marked. With the muscles fully relaxed, deep pressure upon the abdomen from before backward may demonstrate the presence of the swelling. Rigidity of the muscles of the affected side is apt to be present, and in walking there is usually a perceptible limp. When the inflammatory process is situated in the region of the iliacus and psoas muscles, flexion of the thigh on the abdomen, however slight, is apt to occur. The constitutional symptoms of acute abscess will be the chief reliance in arriving at a correct diag-

nosis. The history of an injury, or the presence of a lesion of any of the organs situated in this region, will suggest the probability of abscess.

Extravasation of blood (*hæmatoma*), as far as the swelling is concerned, may simulate abscess, and in one particular may mislead, since the blood dissects up the loose tissues, and the tumor may present at any of the locations named for the pointing of the abscess. The suddenness of the tumefaction in hæmorrhage, the history of an injury (or it may be aneurism), and the absence of septic fever, are sufficient to exclude abscess. Lesions of the kidneys may be recognized by a careful study of the urine. In hydronephrosis the swelling will occur without marked pain or fever, comes on gradually, while a history of obstruction will be given. Tenderness along the spines of the vertebræ suggests abscess. Lastly, the aspirator-needle introduced from behind will determine the character of the swelling.

Treatment.—Incision and free drainage should be the rule of practice in acute retroperitoneal abscess. When the pus is deep-seated, operation should be delayed, provided that the symptoms of septic absorption are not too urgent. The patient should be kept quiet and in bed, and in the dorsal decubitus. The operation and after-treatment are practically the same as in extra-peritoneal abscess.

THE LIVER.

Hepatic Abscess.—A circumscribed collection of pus within the substance of the liver is comparatively rare. Usually single, there may be two or more separate abscesses, which vary in size from a few lines in diameter to enormous cavities holding a gallon or more of pus. They may be deep or superficial, and, while no portion of the liver-substance is exempt, the most frequent location is in the deeper portions of the right lobe.

Causes.—Contusions, lacerations, penetrating wounds, and the lodgment of foreign bodies are among the traumatic causes of suppurative inflammation of the liver. Laceration of the capsule along the attached portion of the suspensory and coronary ligaments not only leads to perihepatic abscess, but may induce suppuration in the deeper portions of this organ. Foreign bodies causing hepatic abscess not only enter through the integument, but ingested substances, as bones, needles, etc., have been known to pass from the alimentary canal into the liver, producing circumscribed inflammation and suppuration. Abscess of the liver may also occur secondary to an inflammatory process in any of the abdominal organs the blood from which is returned by the portal vein. Lastly, it may occur in the course of acute hepatitis, where neither injury or metastasis has occurred. As this disease is almost altogether confined to tropical climates, it will be understood why hepatic abscess is so much more frequent there than in the colder zones.

Symptoms and Diagnosis.—The early recognition of hepatic abscess is exceedingly difficult, especially when the deeper portions of the organ

are involved. Pain is not a prominent symptom, unless there exists a perihepatitis, in which case it is exaggerated. There is a sense of heaviness or fullness about the liver, exacerbations of temperature occur, with general impairment of health. Jaundice is not present unless the bile-duct is compressed by the tumor. Cancer of the liver develops slowly, has a history of progressive emaciation, occurs usually after forty years of age, and is nodular to the feel.

Empyema may be mistaken for abscess of the liver, especially when the accumulation is considerable and the liver is displaced downward. It may be recognized by the interference with the expansion of the lung of the affected side, and by the change in the percussion-sounds with the change in position of the thorax, in which the fluid of empyema is displaced.

Over-distended gall-bladder may be mistaken for abscess; but this error may be eliminated by bearing in mind its location in front and low down, where abscess is exceedingly rare, and also by observing that a distended gall-bladder is appreciably movable independently of the liver.

Hydatid cyst of the liver is not painful, and is not accompanied with exacerbations of temperature, with the exception of the very rare occurrence of inflammation of the cyst, when a differentiation is practically impossible without aspiration and the examination of the fluid.

When the accumulation of pus is considerable, the tumefaction may be recognized by palpation and the diagnosis made positive by the exploring-needle.

The *prognosis* is unfavorable. Left alone, a fatal termination occurs in almost all cases—by rupture into the peritonæum in about 30 per cent, into the lung in 25 per cent, while in a smaller proportion of cases the abscess opens through the integument.

Treatment.—Evacuation is the only rational treatment. In the choice of methods the character of the abscess will determine the employment of the aspirator or drainage by incision.

Aspiration is advisable when the abscess is deeply located, and especially so when strong inflammatory adhesions have not been formed between the wall of the abscess and the abdominal or thoracic parietes. In performing this operation the following plan should be adopted:

The most superficial point of the abscess should be located by careful exploration with the smallest aspirator-needle, and the thickness of the intervening tissue measured. In using the evacuator it is necessary to have a good-sized needle to prevent solid particles or shreds of tissue from the abscess-wall from occluding it; but it is always safer, if firm adhesions have not occurred, to employ the smaller points, since, after the needle is withdrawn, pus is not so apt to escape and find its way into the pleural or peritoneal cavities.

The needle should be introduced in the same opening and to the same depth as the exploring-needle, and the pus slowly withdrawn. It is considered a safer plan not to completely empty the cavity at the first operation. The procedure should be repeated on the second or third

day. A piece of sublimate gauze should be laid over the puncture and held in position by a roller. When, after repeated use of the aspirator, a cure is not effected, and when the tissues between the most superficial portion of the abscess and the integument have been so solidified by adhesions that infiltration of pus can not occur, the abscess should be opened by direct incision, its contents allowed to escape, the sac thoroughly irrigated with 1-to-5000 sublimate, and a drainage-tube inserted. If, after cutting down to the wall of the abscess, it is discovered that adhesions have not occurred, the sac should not be opened. The wound should be packed with sublimate gauze, and, in four or five days after adhesions have been established, it may be incised.

GALL-BLADDER.

Cystotomy of the gall-bladder (*cholocystotomy*) may be indicated in obstruction of the cystic or common duct from any cause, and in the accumulation of concretions (gall-stones) in this organ. The symptoms are pain in the known location of the gall-bladder, at times tumefaction due to its distention, and in a proportion of cases symptoms referable to the retention and absorption of bile. The operation consists in cutting down upon the bladder and securing adhesions to the opening by suture, and then either immediately, or preferably in twenty-four to forty-eight hours after secure adhesions have taken place, opening the sac and removal of the offending substances. The fistula thus established is obliterated by granulation, or, as has been done, extirpation may be performed.

Hydatid Tumors.—Cystic tumors caused by the presence of the *echinococcus hominis*, the larva of the *tænia echinococcus* or tape-worm, occur in the liver more frequently than in all other portions of the body. They vary in size, may be multiple or single, and may be lodged in any portion of the organ. The capsule or periphery of the cyst is firm and dense, and may undergo calcification. Developing in the liver, hydatid cysts may perforate the diaphragm, rupture, and pour their contents into the pleura or lung; or they may extend into the abdominal cavity as far down as the pelvis. In rare instances they open into the stomach, vena cava, duodenum, or colon.

The diagnosis of hydatids of the liver may be made from abscess by recognizing an elastic fluctuating tumor, which is free from tenderness or any of the symptoms of inflammation or septicæmia which are always present in abscess; from cancer of the liver by its fluctuation, cancer being solid, hard, and nodulated. The cachexia of cancer does not occur in hydatids.

In distention of the gall-bladder jaundice is apt to exist, while it is an exceptional complication of hydatid cysts. Aspiration with a delicate needle will be necessary to positive diagnosis. Hydatid cysts contain a watery liquid, nearly clear or of a light straw-color. In some instances fragments of the hooklets and other contents of the cysts may be discovered.

Treatment.—The contents should be drawn off with the aspirator, and the operation repeated if necessary. A single evacuation not infrequently effects a cure.

The needle should be introduced into the most superficial portion of the tumor. As the cyst is being emptied, the abdominal wall immediately around the needle should be pressed toward the tumor, and, when the operation is finished, this should be continued by a compress of sublimate gauze, held snugly in place by a bandage. The object of this is to prevent infiltration of the fluid into the peritoneal cavity. In performing this operation an anæsthetic should not be administered, on account of the danger of rupture of the cyst from vomiting. Cocaine may be employed locally. Complete rest in the recumbent posture should be enforced for at least a week after the aspiration. If at any time suppuration is precipitated, direct incision and free drainage are imperative. If repeated aspirations fail to effect a cure, adhesions being formed as a result of the frequent introduction of the needle, an incision may be made, or the operation of Verneuil performed. This consists in the introduction of a large trocar and canula, evacuating the contents, and inserting for prolonged drainage a large rubber tube through the canula, which is then withdrawn, leaving the tube in position.

THE SPLEEN.

Abscess.—Abscess of this organ is much less frequent than in the liver. It may exist in the substance of the spleen or in the perisplenic tissues.

Abscess of the spleen may be caused by violence, as from a penetrating wound, a contusion with laceration, or a more or less extensive rupture of the capsule and spleen-substance near the attachment of the suspensory ligament.

Idiopathic abscess of this organ may be caused by embolism, or follow in the course of any disease which interferes with its nutrition.

The prognosis of splenic abscess is unfavorable. If left without surgical interference, the contents may escape into the alimentary canal (as the colon or stomach); into the pleural cavity and lung; or, in exceptional instances, open through the integument. Occasionally abscess of the spleen reaches a certain size, remains passive, and becomes a chronic or cold abscess.

Symptoms and Diagnosis.—Traumatic abscess may be suspected when, after an injury, persistent tenderness is felt in the region of this organ, and when to this symptom is added the constitutional disturbance which is a part of the history of acute abscess. In general, the tenderness is more marked in perisplenic abscess than in that which is deep-seated. Swelling, with induration, possibly fluctuation and œdema when the abscess is near the surface, are confirmatory symptoms of suppuration, which may be substantiated by the exploring-needle and aspirator.

In idiopathic abscess the symptoms of suppuration may be masked by the febrile movement in the disease in the course of which it occurs. The treatment is the same as for hepatic abscess.

Cysts.—The diagnosis and treatment of cysts of the spleen do not differ in any essential features from similar lesions in the liver.

Hernia of this organ may occur through a wound in the abdomen, or through an opening resulting from extensive sloughing. If the hernia is recent, and the prolapsed portion is not strangulated, it should be thoroughly cleansed in 1-to-5000 sublimate solution and returned into its normal position. The structure of the spleen is so delicate that it breaks down readily if undue force is employed. If the organ is lacerated, it will be advisable to throw an elastic ligature around it at the level of the skin, apply an antiseptic dressing, and allow the mass to be removed by sloughing or by the scissors, as soon as adhesions have occurred at the opening. When strangulation has taken place, the ligature will not be required.

Complete *splenectomy* may be demanded in displacement of this organ, followed by interference with the function of other viscera, or for the relief of pain caused by the spleen in an abnormal position. It has been performed in several instances on account of the enlargement of this organ in leucocythæmia, but without the success which would encourage a repetition of the operation.

In the extirpation of a wandering spleen, the incision should be by preference in the linea alba, when the tumor is near enough to be reached through an opening here. All adhesions should be divided between double catgut ligatures. The splenic vessels should be tied with a double ligature of strong silk, and divided between the knots.

Pancreas.—Cystic tumors of large size are occasionally met with in this organ, and have been successfully removed by incision in the median line, the operation being practically the same as in ovariectomy.

WOUNDS OF THE ABDOMEN.

Injuries of the abdomen are divided into *penetrating* and *non-penetrating*, and both of these varieties are again divisible into those which involve the viscera and those in which the organs escape.

Non-penetrating Wounds of the Abdominal Walls.—*Contusions* may involve the integument, produce extravasation in the subcutaneous tissues, rupture of the muscles, or displacement or rupture of a viscus and death without any external evidence of injury.

Simple contused wounds of this region demand no especial consideration. If abscess occurs, the same rule of treatment which applies to abscess elsewhere is applicable here. *Rupture* of one or more of the muscles may occur as the result of a blow on a muscle in tension, or by muscular action alone. The rectus abdominalis is most frequently torn. Hernia is apt to follow this injury. The *treatment* consists in perfect rest and well-adjusted pressure to hold the viscera within the cavity of the abdomen until cicatrization can take place. A supporter should be worn for some months after recovery, or permanently if necessary.

Displacement or rupture of an organ (as the kidney, spleen, etc.) may be caused by direct violence or by a severe fall. The diagnosis will, in the first lesion, depend upon the absence of the organ from its normal place, and the recognition of the tumor in the new position. Laceration is followed by hæmorrhage, at times profuse, which is evident from great pallor and a rapid and weak pulse. If the intestine is involved, the escape of gas or fæces is followed usually by profound shock, tympanites, and peritonitis. Emphysematous crackling may be recognized on palpation.

The first indication in treatment of a displaced viscus is to place the patient in such a posture that gravity will aid in the restoration of the organ to its normal position. A compress and bandage may be useful in some instances. In rupture of a solid organ, profound quiet should be maintained. When hæmorrhage is alarming, deligation of the extremities is advisable. Fluid extract of ergot hypodermically may be added. If the symptoms of rupture of the alimentary canal are present, the abdomen should be opened in the median line, the rupture closed, or an artificial anus established, and the peritoneal cavity carefully washed out.

Non-penetrating *incised, punctured, or shot* wounds of this region do not demand especial consideration. The former should be closed, while it is usually safer to treat the punctured and shot wounds by placing a sublimate compress over the opening.

Penetrating Wounds.—Wounds of the abdomen which penetrate without wounding any internal organ should be closed in the same manner as directed for the closure of surgical wounds through the belly. If an internal organ is involved, the abdomen should be opened, the character of the lesion ascertained, and proper surgical treatment instituted. Among the symptoms which aid in arriving at a diagnosis are the following: If the injury is followed by the vomiting of blood, it is fair to conclude that the stomach or duodenum is involved; if blood is passed by the rectum, that the wound is farther along the bowel; or, if hæmaturia exists, that the kidney, ureter, or bladder is injured. If the odor of intestinal gas or fæces is present, the inference is clear that the alimentary canal is opened. Bile, gastric juice, or recently ingested matter seen in the wound or recognized by the sense of smell, indicates the character of the injury and the location of the perforation. The crackling sound peculiar to emphysema, elicited by palpation, indicates the presence of intestinal gas in the loose tissues, beneath the peritonæum (Dennis). Tympanitic resonance over the liver, which has appeared suddenly and which is persistent, is a diagnostic sign of perforation of considerable value. Shock is usually severe, although in some cases it may be slight and of short duration.

In shot-wounds the location of the wound of entrance (and exit, if it exists), together with the known direction of the missile and the force with which it was propelled, will be of aid in determining the character of the lesion within. A bullet passing directly or obliquely into the abdomen, at or below the level of the umbilicus (Fig. 530), can scarcely

miss the intestinal tube, and will be more apt to make a number of holes than a single wound. Above this point the chances of escape are more favorable, yet so fortunate a result is exceptional. The direction and depth of a stab-wound may also be determined by the appearance of the wound and an examination of the instrument with which it was inflicted. The persistence of pain in a given point within the abdomen is a recognized symptom of a penetrating wound.

Many of the foregoing symptoms may not be present within the first few hours after the receipt of a wound which has penetrated the alimentary canal, and, beyond the external wound and a varying degree of shock there may be no symptom of perforation. Temporary contraction of the muscular fibers of the stomach or intestine, or prolapse of the mucous membrane into the wound, may prevent, for a time, the escape of gas or ingested matter, and the appearance of the more pronounced symptoms of perforating wounds of the alimentary canal.

The distention of the alimentary canal by hydrogen gas forced into the rectum, as advised by Senn, in order to determine, by the escape of the gas into the peritoneal cavity and out by the superficial wound, the presence of a penetrating wound of the intestine, is, in my opinion, not advisable. In wounds of small aperture, as is well known, escape of intestinal gas or other contents may not occur. These would be opened by the induction of gas, and extravasation ensue. When doubt exists, abdominal section and direct exploration are preferable.

Treatment.—When there is a wound in the wall of the abdomen, the immediate indication is to determine whether it opens into the cavity. In order to do this, the disinfected finger, or the light and porcelain-tipped Nélaton probe, should be introduced, and, if necessary, the opening should be enlarged. Cocaine anæsthesia may be sufficient for this procedure. If the wound is confined to the abdominal wall, it should be treated in the aseptic method advised for ordinary wounds of the soft tissues. If it extends through the wall, the abdomen should be opened, and the condition of the viscera examined. As to whether the incision should be an enlargement of the accidental wound, or made in the median line, the location and direction of the wound must determine. The section should be, preferably, through the linea alba. If the lesion is not more than six inches from this line, and if the direction of the wound is backward or tending toward the center, the median incision should be chosen. Under other conditions the section may be through the wound of entrance.

In this procedure the details of the antiseptic method should be carried out, as directed in operation for the relief of intestinal obstruction. When the peritoneal cavity is opened, if it contain clotted blood which is known not to have entered from the wound of operation, or ingested matter, or if gas escape through the opening, the penetrating character of the wound is evident. If none of these signs are present, the disinfected hand should be introduced and the internal surface of the wall examined at the supposed point of entrance. In examining the intestinal canal, it is advisable to begin with the loops of small intestine which pre-

sent at the incision. These should be carefully drawn out through the opening, and, as fast as inspected, surrounded with towels moistened in warm Thiersch solution, and supported in the hands of an assistant, who will not allow them to drag heavily upon the exposed mesentery. If an opening be found in the gut, it may be at once closed, or noted and passed over until the entire canal and cavity have been examined. If a cutting or puncturing sharp instrument has inflicted the wound, its edges will be found sufficiently smooth to be sutured at once,

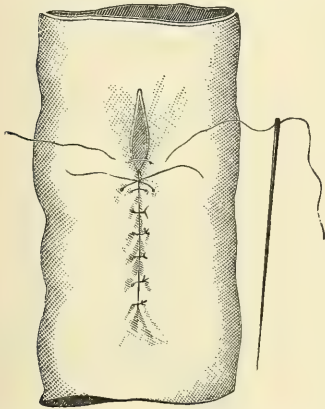


FIG. 548.—Lembert's suture for closing wounds of the intestines. (After Esmarch.)

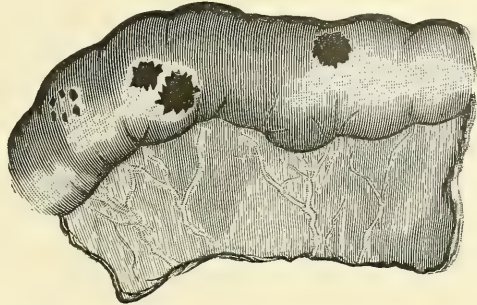


FIG. 549.—Pistol-shot wound of small intestine. (After Bull.)

and should be brought together by Lembert's suture (Fig. 548). If the hole has been made by a bullet, and has rough and torn borders, as in Fig. 549, its edges should be trimmed smooth, with curved scissors, and then closed. When only a narrow strip of tissue separates two openings (Fig. 549), they should be converted into a single elliptical wound, and sutured. The proper distance of the sutures from each other is shown in Fig. 548. While the sutures are being inserted, the intestine should be laid upon towels spread over the abdomen, near the incision. The escape of fecal matter into the cavity of the peritonæum should be prevented by flat sponges placed around the margins of the wound. If the wound in the wall of the gut is so extensive that, in closing it, the lumen of the tube will be seriously constricted, the injured portion should be excised. After all wounds are stitched and hæmorrhage is arrested, the cavity of the peritonæum should be carefully cleansed. This is effected by sponges, attached to holders, carried into all parts of the cavity. When fecal extravasation has occurred, it will be advisable to flood the entire cavity with warm Thiersch's solution, remove it with sponges, and repeat the irrigation until the liquid comes away free from odor or color. A drainage-tube should be employed in this worst class of cases. The Sims tube is to be preferred, and the end of this should be carried down to the most dependent portion of the cavity (usually in the pelvis, in the *cul-de-sac*). The method of employing this excellent instrument is described in the article on *ovarian tumors*.

The intestines should now be returned and the wound closed. Irrigation through the drainage-tube may be made when indicated by the temperature, tympanites, etc.

No especial treatment can be laid down for wounds of the solid viscera or of the great vessels. The arrest of hæmorrhage, the removal of extravasated blood, and the establishment of drainage when needed, are the indications.

The argument in favor of operative interference in penetrating or supposed penetrating wounds of the abdomen may be briefly stated, as follows :

1. The enlargement of a wound sufficiently to demonstrate its opening (or not opening) into the cavity of the peritonæum is a simple procedure, practically without danger.
2. Abdominal section is not a difficult, nor, when skillfully and properly performed, a dangerous operation.
3. A penetrating wound of the abdomen, left without surgical interference, is attended always with great danger.
4. If any vessels of size are divided, hæmorrhage is an immediate danger, and peritonitis a serious and probably fatal complication.
5. If the alimentary canal is opened, death is almost inevitable. The few recorded cases of recovery form such an infinitesimal proportion of the whole, that they should carry no weight against interference.

CHAPTER XVIII.

PELVIC ORGANS.

RECTUM AND ANUS—GENITO-URINARY ORGANS.

Diseases of the Rectum and Anus—Congenital Defects.—Arrest of development in the rectal and anal portions of the alimentary canal, though not so frequent as at the upper or buccal extremity, is unfortunately common enough to justify a consideration of the different kinds of deformity which may here be met with, and the mode of treating them.

Absence of the anus is one of the most frequent congenital lesions of the alimentary outlet. The rectum may be partially developed, and terminate within the pelvis in a blind pouch at a point more or less removed from the normal opening (Fig. 550); there may be a partial de-

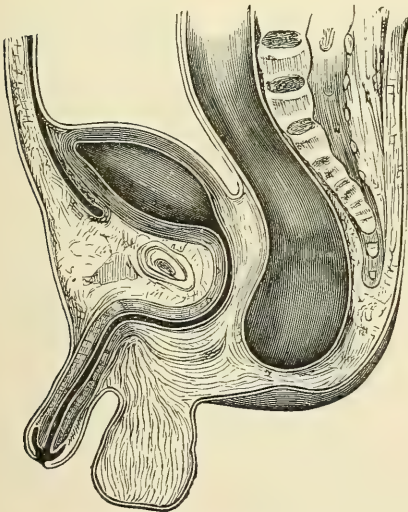


FIG. 550.—Atresia of the anus.
(After Esmarch.)

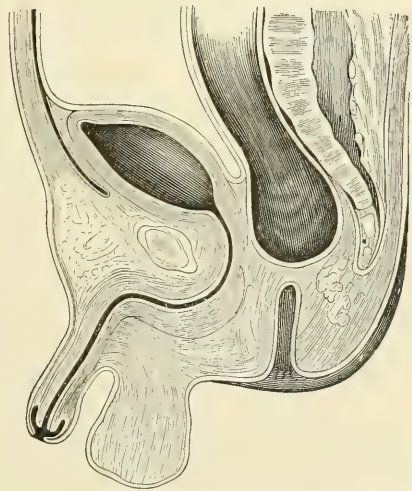


FIG. 551.—Atresia of the rectum, with a rudimentary anus. (After Esmarch.)

velopment of the anus (Fig. 551); or the rectum may be entirely absent (Fig. 552); or it may be present in the pelvis, opening abnormally into the bladder, vagina, uterus, or urethra (Figs. 553 and 554). In the simpler forms of atresia ani only a thin membrane is stretched across the otherwise normal opening. The more complicated varieties are those

in which a greater distance intervenes between the end of the defective intestine and the perinæum.

Diagnosis.—Absence of the anus is easily established by inspection. The more important and difficult point is to determine the distance from

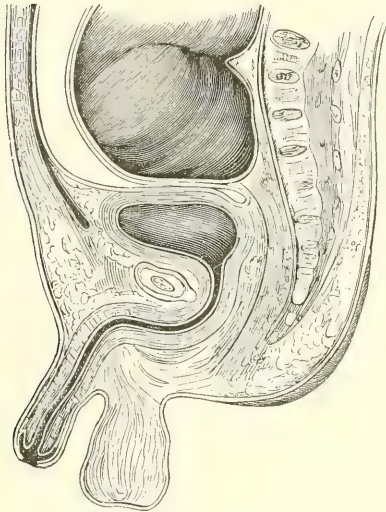


FIG. 552.—Atresia of the anus and rectum. (After Esmarch.)

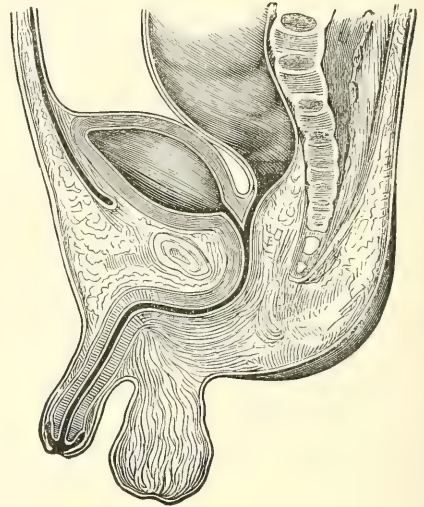


FIG. 553.—Atresia of the anus and lower portion of the rectum; the upper part opening into the urethra. (After Esmarch.)

the perinæum to the end of the pouch. When the intervening tissue is thin, the accumulation of matter within the tube may cause a protrusion in the perinæum which is exaggerated when the infant cries. If the finger be pressed into the perinæum, an impulse somewhat comparable to that felt in the expulsive efforts of a patient with hernia may be appreciated.

Exploration by the vagina, when the capacity of this tube will permit, will aid in diagnosis.

When the intestine opens into another hollow organ, or through the integument in an abnormal position, the only diagnostic sign is the presence of fecal matter in the natural discharge from the organ or at the abnormal opening. In atresia recti in female children, the bowel opens most frequently into the uterus or vagina, and in males into the bladder. At times the communication is established between the bowel and the urethra, or a false opening may occur at any point in the perinæum, and, in rarer cases, in some remote portion of the body.

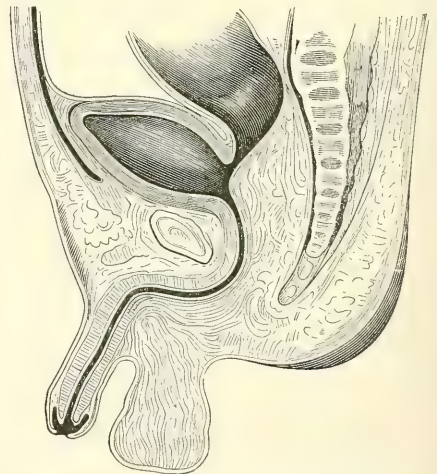


FIG. 554.—The same; the upper portion of the rectum opening into the bladder. (After Esmarch.)

Treatment.—The indications are to establish an opening as near the natural position of the anus as possible. If the blind pouch can be reached by the exploring aspirator, the needle should be left in place as a guide. The operative procedure is to dissect gradually toward the supposed location of the end of the gut, keeping an open and clear wound by using retractors and arresting all hæmorrhage. The incision through the integument should be in the median line, with its center just in front of the tip of the sacrum and coccyx, for, if the *sphincter ani* is present, even in an imperfect condition, it is important to preserve it to aid in the voluntary control of the bowel when the operation is completed. When there exists only a thin septum, this muscle is usually well developed, and the operation is a simple incision and divulsion of the membrane. In more formidable operations, the location of the urethra and bladder, and in females the vagina and uterus, must be kept well in mind, for in infants the pelvic diameters are very small, varying from one to one and a half inch. It is a safe rule to proceed cautiously along the sacral curve. Moreover, it is wiser to dispense with an anæsthetic, since the expulsive efforts in crying may aid in finding the end of the gut.

When it is reached, if it is possible, the end should be loosened, drawn down, and sutured to the integument at the edges of the incision. If this is not done, the opening usually contracts, necessitating repeated dilatation by the use of the finger, tents, or a divulsor. In some instances it has been found necessary to remove the coccyx in order to effect the union of the bowel with the skin.

When, after proceeding as far as the immediate safety of the infant will justify, the bowel can not be discovered, the propriety of colostomy or enterostomy may be entertained. If determined upon, right lumbar colostomy is indicated, on account of the probability of absence or malposition of the descending colon. When the intestine ends directly in the uterus or vagina, and there is no pouching behind these organs toward the perinæum, it is best not to interfere. If, however, the bladder or urethra is involved, an opening should be made or colostomy performed.

In exceptional cases the anus is present in a condition of more or less perfect development, while at the same time the rectum does not communicate with it, but terminates in a blind pouch at a varying distance from the perinæum.

The effort should be made to establish a communication between the two pockets by dissection through the tissues which intervene.

When the opening from the rectum is abnormally small (a congenital stricture), dilatation, incision, or divulsion should be performed.

The unfavorable prognosis in all these cases should not be concealed. Inflammation, visceral complications, dilatation of the bowel above with retained ingesta, insufficient assimilation, pain, etc., render a favorable issue exceedingly improbable.

Pruritus Ani.—Persistent itching about the anus may be caused by a variety of skin-diseases, as eczema, herpes, pityriasis, and erythema,

or by irritation of the end-organs of the sensory nerves from over-distention in the act of defecation. It is also a symptom of hæmorrhoids, fissure of the anus, or may be due to the presence of the thread-worm (*ascaris vermicularis*). The character of the itching is burning, painful, and aggravating, and the desire to scratch is almost irresistible. The successful management of pruritus ani will depend upon the recognition of the disease of which it is a symptom.

Eczema of the perinæum and anus is more apt to occur in a warm temperature, where perspiration is excessive, and in corpulent individuals where considerable friction occurs between the folds of integument of this region. The skin becomes infiltrated and thickened, fissures are formed, and the mucous membrane at the anal opening may become involved.

Treatment.—The part affected should be kept clean and friction prevented as much as possible. In the acute eczema of the anal region a warm bath, without soap, should be taken two or three times a day, the parts thoroughly dried, and sprinkled with powdered starch or lycopodium. If excoriations exist, lead-and-opium wash should be tried. In chronic eczema of the anus, in order to effect a cure, it is often necessary to remove the accumulation of scales by the local use of green soap for a day or two, and then smearing the surface with diachylon-salve.

Herpes may be recognized by the character of the eruption, which is vesicular, the vesicles being grouped in bunches around the anus. Those which rupture and are subjected to irritation present flat and slightly ulcerating excoriations. The treatment consists in thoroughly washing the surface involved with a warm solution of boracic acid, grs. xv— $\bar{3}$ j of water, by means of pellets of absorbent cotton moistened in the solution. This should be followed by applying an astringent ointment, composed as follows: plumbi acetatis, grs. iij; acid. tannic, gr. j; morphiæ sulph., grs. iij; adipis, $\bar{3}$ j.

Erythema is a mild form of inflammation of the integument, occurring here as a result of friction between the folds of skin of the two sides and the irritation from perspiration or other fluids. The warm bath, followed by sprinkling the part affected with starch or lycopodium, will usually effect a cure.

Pityriasis versicolor occasionally exists in the ischio-rectal region. This disease can be recognized by the brownish slate-color of the parts involved. The cause is a vegetable parasite, the spores and mycelia of which may be easily recognized by the microscope. It yields readily to pure sulphurous acid, which may be applied by means of a camel's-hair pencil. Corrosive sublimate (gr. j to water $\bar{3}$ j) may be applied by wrapping the parts with absorbent cotton dipped in this solution.

When pruritus occurs with hæmorrhoids or fissure, the treatment must be directed to these affections. If it is caused by over-distention or irritation of the rectum and anus, the use of enemata and laxatives will arrest the disease. The local application of a 4-per-cent solution of cocaine hydrochlorate will dull the sensibility of the part and temporarily stop the pain and itching.

Ascarides, or "thread-worms," are not an uncommon cause of pruritus ani. They vary in length from a quarter to half an inch, are somewhat lighter in color than the mucous membrane, and are not readily seen unless this membrane is everted and carefully examined. Santonin in full doses should be administered for two or three days, followed by a free purgation. When this is accomplished the bowel should be distended with an enema of lime-water, retained for fifteen minutes, if possible, and repeated. As soon as the last injection is evacuated, a pint of water, in which grs. xx of carbolic acid are thoroughly dissolved, should be thrown into the rectum and retained for about five minutes. The injection of lime-water and carbolic acid in solution should be repeated for several days to insure a thorough destruction of these annoying parasites.

Enemata of the infusion of quassia are also highly recommended in the extermination of the *ascaris vermicularis*.

Foreign Bodies.—Foreign bodies in the rectum are usually introduced through the anus, and not infrequently lodge here, having passed through the alimentary canal. Their presence may be recognized by digital exploration, or, when of small size, the speculum may be employed.

Digital exploration of the rectum may be performed with the minimum of discomfort by curving the thoroughly lubricated finger to conform to the shape of the lower portion of the bowel. The direction from the anus is upward and forward for the first inch and a half, and then upward and slightly backward.

If a speculum is employed, that of Sims (Fig. 555) should be preferred.

A small body may be readily removed by seizing it with a long forceps after dilatation with this instru-

ment. A large substance may require anæsthesia, with forcible division of the sphincter, or a posterior linear rectotomy before it can be removed. When the object is made of glass or any fragile substance, great care should be taken to prevent its breaking.

Fistula in Ano.—A fistula of the anus or rectum may be *complete* or *incomplete*. The last variety is further divided into the *incomplete external* and the *incomplete internal* fistula.

In the complete form the track of the fistula, more or less sinuous, leads from the wall of the rectum or the anal margin out through the integument of the perineal, ischio-rectal, or gluteal regions (Fig. 556). In the incomplete external variety, the track opens through the skin, but does not communicate with the rectum (Fig. 557); while in the incomplete internal fistula the track opens into the bowel only (Fig. 558).

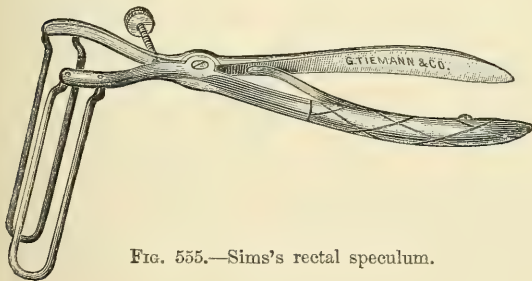


FIG. 555.—Sims's rectal speculum.

The chief causes of peri-rectal abscess are the irritation which follows the lodgment of fecal matter and undigested substances in the rectum; the over-distention of this organ as a result of constipation; the presence of hæmorrhoidal tumors; the introduction of hard bodies, as the nozzle of a syringe, etc., through the anus; and, lastly, direct injury by a blow from without. Abscess in this region occurs by preference in the weak and debilitated, in those suffering from the tubercular diathesis, and is rarely met with before the twenty-fifth year of life.

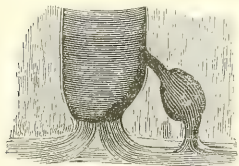


FIG. 556.—Complete fistula in recto.

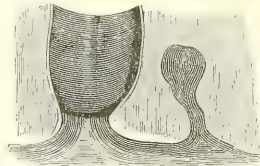


FIG. 557.—Incomplete external fistula.

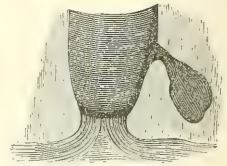


FIG. 558.—Incomplete internal fistula.

Suppuration begins as a rule in the loose areolar tissue around the rectum. Although the inflammation may originate in the mucous membrane and wall of the bowel, perforation of the wall is rare until the process of suppuration is well established in the connective tissues of the ischio-rectal fossa. As the pus accumulates the tissues break down, and the abscess opens into the bowel or through the integument. A complete fistula may be developed from either of the incomplete varieties by partial occlusion of the original opening, thus causing the pus to seek an outlet elsewhere.

Abscess of this region may be superficial or deep. When superficial, it is apt to open through the mucous membrane, just above the junction of the skin and mucous membrane. When the deep variety opens into the rectum, it is usually at a point from three fourths of an inch to two inches from the margin of the anus. A single abscess may have one or more openings into the rectum or through the skin.

The *diagnosis* of fistula in ano is not difficult. It depends upon the history of an abscess followed by a constant or frequently recurring discharge of pus, the pain being severe until the abscess is evacuated, and recurring in a varying degree with the temporary closure of the outlet. An area of induration usually exists, and the opening may be discovered either through the skin or within the anus. If an external opening exists through which gas or fecal matter escapes, a complete fistula is demonstrated. When an external opening is formed, unless the abscess is very recent, there is almost always an internal opening, although it may not be found. The diagnosis may be further made clear by exploration with a probe, an operation which is rendered practically painless by the injection of a 4-per-cent solution of cocaine hydrochlorate into the abscess cavity. If a single injection does not sufficiently dull the sensibility, it should be repeated.

No matter where the external opening is situated, the track will, in the great majority of instances, run just beneath the skin toward the anus. The probe should be allowed almost to find its own way, and,

when well in, the point at which it impinges upon or opens into the bowel can be determined by the finger in the rectum.

The *treatment* should be by free incision. In mild cases local anæsthesia, obtained by cocaine, is sufficient. One or two hypodermic syringes full of a 4-per-cent solution should first be thrown into the cavity of the sinus, and the direction of the opening into the bowel determined by the probe or grooved director. The cocaine should then be injected into the tissues by repeated introductions of the needle in the line of the proposed incision into the bowel. Thirty minims of this solution are usually sufficient in this last procedure, but as many as sixty may be injected if necessary. Of the quantity thrown into the abscess only a small proportion is absorbed, while of that injected into the tissues the larger part escapes with the blood which follows the incision. When the sinus is long and the cavity of the abscess extends more than one inch above the anus, the operation should be performed under ether narcosis.

Operation.—A laxative should be administered the day before the operation, and an enema given two hours before the anæsthetic. The perinæum and region of the anus should be cleanly shaved. The patient should be placed upon the back, with the sacrum resting on the edge of the table, the legs flexed on the thighs, and the thighs on the abdomen, and separated; or upon the side in the Sims position. The probe should be carried into the fistula, the lubricated index-finger of the left hand into the rectum, and the point noted at which the instrument strikes the rectum. The probe is now withdrawn, and the grooved director introduced in the same track. If the opening into the bowel can not be found, the operator should determine by the touch the thinnest point on the intervening wall, and at this location bore through into the rectum, supporting the mucous membrane near the point of the instrument with the finger in the bowel. As soon as the director is felt in the cavity of the gut, the point should be brought out at the anus, the sharp-pointed curved bistoury carried along the groove, and the fistula laid open by dividing the intervening bridge of tissue. If a second sinus exists, it should be incised in the same way. The bleeding is usually insignificant, and may be arrested by pressure, or the ligature. The finger should now be carried into the wound, and, if it is discovered that the abscess extends higher along the wall of the rectum than the point at which the director was carried through, the intervening wall should be divided with the blunt scissors. It is important that the incision in the gut should extend to the depth of the abscess when this point is less than three inches from the anus. A careful search for any pockets or sinuses should be made, and these, if found, should be laid freely open. The fistulous track should now be scraped out with the sharp spoon, and the entire wound packed with sublimate gauze held in place by a compress and T-bandage. This dressing should be allowed to remain in place for two or three days, when, with the first evacuation of the bowels, it is carried away. After this the wound is not repacked, but, for purposes of cleanliness, it may be washed out by allowing the patient

to sit in a basin of warm water once or twice a day, or by irrigation, and an outside dressing applied.

The wound rapidly heals by granulation, and, in the vast majority of cases, a cure is effected by a single operation. Temporary incontinence of fæces results in all cases where both sphincters are divided, but a permanent loss of function is exceptional. It is more apt to occur in females, and for this reason a more guarded prognosis should be made in this class of patients. In the rare instances in which an internal incomplete fistula is present, the cavity of the abscess should be opened by incision through the skin, and the operation completed as just given.

A division of the external sphincter is not necessary in the mildest class of cases, in which the abscess is recent and small, and in which the sinus runs just beneath the skin and opens at the margin of the anus. Under all other conditions it should be partially or completely divided.

The immediate closure of the fistulous track is an operation which has been recently performed in a number of instances. After the fistula is incised, the wall of the abscess is dissected out and the two perfectly healthy surfaces are brought together with sutures.

An older method consists in the introduction of an elastic ligature through the external opening into the bowel and out through the anus, where the ends are tied together. The loop is allowed to cut through slowly, and it may be necessary to tighten it from time to time.

Prophylaxis.—Upon the first appearance of inflammation in the ischio-rectal or perineal region, the integument immediately over the most superficial point of the induration should be incised, and a free puncture made into the inflamed tissues. This should be followed by the application of poultices and complete rest in the recumbent posture. Too great distention of the rectum should be prevented by the administration of laxatives, and an enema of warm water should be given just before the bowel is emptied. By this method the tension is relieved and an outlet given to the products of inflammation before the process extends into the deeper tissues. A cure without further operation will be effected in a fair proportion of cases.

After an abscess is once formed, whether the fistula opens into the rectum or through the integument, or has both outlets, the case demands operative interference. The proportion of cures by the use of injections into the fistula, or the application of stimulating remedies, is so very small and such valuable time is lost, that their employment is unjustifiable. Of the radical operations, preference should always be given to that of free incision. The elastic ligature should only be tried on patients who are unwilling to remain in bed, or to be operated upon with the knife, to whom the merits of the two operations have been explained, and who relieve the surgeon of the probabilities of failure. It is also applicable to those cases in which the fistula enters the rectum so high up that incision is impracticable. A guarded prognosis should be made in this class of patients.

Operation by immediate closure should not be preferred to the open method, for the reasons that the old operation cures almost all cases,

and is easy of execution. The new method is more difficult, and is only applicable to the milder cases. The failure to close even a small part of the wound in the rectal wall would insure failure, while a like result would be apt to follow if the entire wounded surfaces were not in perfect coaptation. This operation would be applicable in those cases where, as a result of incision, there was serious impairment in the function of the *sphincter ani*.

Operative interference is contraindicated in multiple fistulæ in the aged, or in patients in a weak and debilitated condition. When the tubercular diathesis is well marked, an operation should not be done unless great discomfort is caused by the fistula, and, when performed, the prognosis should be guarded.

Fissure.—Fissure of the anus is most frequently met with on the posterior portion of the outlet. It may, however, exist at any part of the anal circumference, or in the rectum above the sphincter. The tear is usually through the mucous membrane, although the muscular fibers may be more or less involved. The chief cause is over-distention of the anus in the evacuation of hardened fæces, together with the presence of sharp substances in the matter discharged. In like manner, foreign bodies introduced into the rectum may produce it. Fissure may result from the inflammation and ulceration of a hæmorrhoid, or from any chronic inflammatory process in the rectum.

The chief symptom is pain of an acute character, exaggerated by an evacuation of the bowel, and continuing some time after the act in a violent spasm of the sphincter muscle. By careful and gentle dilatation of the anus, it may be seen or recognized by the touch as a line of induration running parallel with the axis of the bowel. The employment of cocaine will render the exploration more thorough, and will permit the introduction of the speculum.

Treatment.—The administration of laxatives, and the employment of enemata of warm water and olive-oil, will remove the chief source of irritation, while the stimulating effect of the lunar-caustic pencil applied in the fissure, and repeated every two or three days, will usually effect a cure. Cocaine should be employed to deaden the sensibility before the silver is applied. If a more radical procedure is necessary, it will consist in—1, a partial division of the sphincter in the line of the fissure; or, 2, temporary paralysis of this muscle by divulsion.

As the second operation requires ether narcosis, the partial division should be first employed. In its performance local anæsthesia should be obtained by the application of 4-per-cent cocaine to the inflamed surface, together with the injection of this fluid by introducing the needle just beneath the fissure in its entire extent. The sphincter should now be made tense by separating the sides of the speculum, and an incision made through the depth of the fissure, dividing about half of the thickness of the muscle. In the after-treatment, the bowels should be kept open. Divulsion of the sphincter is performed as follows: The patient, fully anæsthetized, is placed upon the back, with the thighs separated and flexed on the abdomen. The operator, having lubricated both

thumbs, introduces one and then the other to their full length, and stretches the opening directly to the right and left until the palmar aspect of each thumb is in contact with the inner surface of the tuber ischii. A towel, held in place by a roller or T-bandage, should be applied to prevent soiling. The rest obtained by the paralysis of the sphincter allows the fissure to heal. The function of the muscle is restored in from eight to twelve days.

Ulcers.—The traumatic causes of ulcer of the rectum are the same as those given for fissure of the anus. Ulcer may also result from any acute or chronic inflammatory process of the lower bowel. It is a not infrequent sequence of dysentery, and may be met with in that form of proctitis which results from prolonged diarrhoea. Inflammation of a hæmorrhoidal tumor will produce ulcer of the rectum, and the same is true of the gummatous deposits of the late stages of syphilis. A primary chancre or a chancroid may be located at the anal margin, and less frequently in the bowel. These two varieties of ulcer are usually seen in women suffering with pudendal chancre or chancroid, and in males the subjects of pederasty. Tubercular deposits in the rectum may also break down, and thus cause ulceration in the wall of this organ.

The symptoms of ulcer of the rectum vary with the character of the sore and with its location. If the lesion is situated within the grasp of the sphincter muscles, tenesmus is apt to be a marked feature. The ulcer from a traumatism, or following an acute inflammatory process, is more apt to be painful than that which is a part of a subacute or chronic catarrh, or which occurs with tuberculosis or syphilis. A common symptom of all ulcers of this organ is the presence of more or less blood and mucus or pus in the discharges. The diagnosis may be confirmed by inspection with the speculum, and by digital exploration. Tubercular ulcer of the rectum very rarely exists before the symptoms of deposits in the lungs are present. Upon inspection they are recognized by their yellowish color, usually small size, and their dissemination over a considerable area of the mucous membrane. In the more fully developed ulcers the caseous degeneration of the inflammatory products may be observed.

Mr. Allingham describes a rare form of ulcer which he has occasionally observed in the rectum, and which he has named *lupoid*, or *rodent* ulcer, of this organ. Its usual location is near the anus. It tends to spread widely, the floor of the ulcer is red and dry, the margins irregular and precipitous. It is very probably tubercular in character.

Chancroidal ulcer of the rectum may be recognized by the precipitous margins of these sores, and by the rapidity with which they spread. In patients affected with phagedenic ulcers of the genital organs, the inoculation may occur by direct contact of the secretion of the venereal sore, or the virus may be conveyed through the medium of the nails in the act of scratching. Under such conditions the sore usually first appears upon the mucous membrane of the margins of the anus, and extends later into the rectum. The diagnosis must be based upon the

peculiar appearance of the ulcer, together with the probabilities of infection from a contiguous venereal ulcer.

The hard syphilitic or true chancre is rarely observed in this region, and, when met with, is usually confined to the anal margin. It possesses here the same well-recognized features of the specific ulcer of the genital organs, from which source the virus is conveyed usually by the nails, and occasionally by immediate contagion.

Ulcers of the rectum resulting from the breaking down of the gummatous deposits of tertiary syphilis are chiefly seen just along the upper margin of the sphincter muscle. From this point they extend upward, and may involve the entire rectum and invade the colon. These ulcers are usually multiple, varying in size from a small point to a half-inch or more in diameter, and in depth may involve only the mucous membrane, or the muscular and connective-tissue stroma may be destroyed, and in some instances perforation may occur. The process of destruction is greater in the older ulcers, and the various stages may be observed by examining the bowel from below upward. The appearance of the ulcers as above described, together with the history of syphilis, will enable the observer to arrive at a correct diagnosis. Traumatic ulcers, and those resulting from the breaking down of hæmorrhoidal tumors, will be recognized by the appearance of the sore and the history of an accident or hæmorrhoids.

As far as a cure of the ulcer is concerned, a favorable *prognosis* may be made in all ulcers of the rectum except the tubercular. These may be relieved by treatment, but, being expressions of an incurable dyscrasia, permanent relief can not be expected. A more remote, as well as greater evil which often results from ulcer, is stricture of the rectum, and the danger of stricture is usually proportionate to the extent of the destructive process. Phagedenic chancroidal ulcer, and the ulcers of gumma and dysentery, are especially prone to induce stricture.

Treatment.—The common indication in the treatment of all forms of ulcer of the rectum is to keep the bowel in as complete repose as possible. Every effort should be made to keep it clear of fecal matter. This may be accomplished by the repeated employment of enemata, and by the administration of proper articles of diet, all of which should be capable of absorption in the stomach and small intestines. Milk, beef-tea, meat-juice, soft-boiled eggs, wine-jelly, rice, corn-meal mush, etc., will afford variety and sustain the patient's nutrition.

In irrigation of the diseased surface, warm or cold water may be used at the temperature which is most agreeable to the patient. The best apparatus for this purpose is the fountain-syringe. The smallest glass nozzle, thoroughly warmed and oiled, should be employed, and from one to two pints of fluid may be introduced at one injection. A larger quantity may be employed when the colon is involved. If the patient is placed upon the left side, with the buttocks elevated, a greater degree of tolerance will be obtained in the rectum. The fluid should be retained for a few minutes, if possible.

When the ulcer encroaches upon the sphincter muscle, causing painful tenesmus, the hypodermic use of morphia or opium suppositories may be required to relieve the spasm. In obstinate cases divulsion or division of the sphincter may be done as a last resort.

In the treatment of the ulcers which result from dysentery, catarrh of the rectum, an injury, or breaking down of hæmorrhoids, the plan just given should be adopted. It is often advisable to add from grs. v-x of nitrate of silver to the pint of water thrown in, and, if the ulcer can be reached, recovery will be hastened by the local use of the lunar caustic. An excellent remedy for the alleviation of pain and the relief of tenesmus is a suppository composed of gr. ij each of iodoform and cocaine hydrochlorate, introduced from three to five times in twenty-four hours. As already stated, in obstinate and extreme cases, lumbar colotomy may be necessitated.

Chancroidal ulcer of the rectum requires the most energetic treatment. Ether should be administered, the sphincter divulsed, the ulcer exposed by the speculum, its surface scraped with the curette, and a thorough cauterization effected with nitric acid. The cocaine and iodoform suppositories should be employed in the after-treatment.

True syphilitic chancre of the rectum rarely demands local treatment. It yields readily to the constitutional remedies employed in syphilis.

The specific ulcer of the later stages of syphilis requires the constitutional treatment recommended for the late manifestations of this disease, and locally, irrigation and the cocaine and iodoform suppositories.

Tubercular ulcers should be treated chiefly by the administration of cod-liver oil emulsion, the iron tonics, the hypophosphites of lime and soda, and carefully selected diet. Irrigation with warm water will be found useful. When pain and tenesmus exist, relief may be obtained by the means already given.

In rodent, or lupoid ulcer, the Paquelin cautery-knife should be employed, and a thorough excision of the diseased surface effected.

Stricture of the Rectum.—Stricture of the rectum may be congenital or acquired. Partial and complete congenital occlusion of this organ has already been considered. Acquired stricture is usually the result of an inflammatory process in the walls of the rectum, and at times in the tissues which surround this organ (Fig. 559). New formations (cancer, etc.) may also cause a partial or complete occlusion of the rectum, not only by reason of the bulk of the cells proper of the neoplasm, but on account of the inflammatory process which it causes in the connective-tissue elements of the bowel.

The lumen of this portion of the intestine may be partially or completely occluded by pressure of a tumor not connected with the bowel, or by the presence of some displaced organ, as the uterus, bladder, etc. Lastly, spasmodic stricture may occur from contraction of the circular muscular fibers of the rectum.

As stated on a previous page, organic stricture frequently follows ulcer of the rectum, and is especially apt to occur in the process of cic-

trization after dysenteric ulcers and those of the tertiary stage of syphilis. The accidents of parturition not infrequently tend to stricture, and this may account for the greater prevalence of this lesion in females than in males.

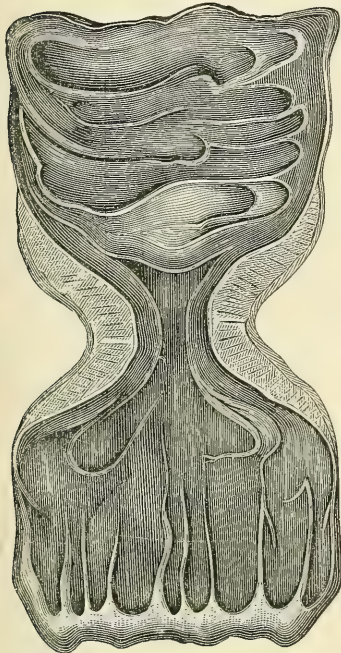


FIG. 559.—Stricture of the rectum from connective-tissue new-formation in the submucous layer. (After Bushe.)

Stricture of the rectum may be *narrow* or *linear*, or *long* and *tortuous*. The usual location is about two inches above the margin of the anus, although any part of the organ may be involved. The earlier symptoms of this lesion are interference with the act of defecation, pain with the passage of fæces, and the presence of blood or mucus in the discharges. In some instances the fæces are tape-like, or are abnormally shaped, although this symptom may not be present when the stricture is high up, since the fecal matter, after it passes through the constriction, may assume the shape of the bowel below. If the constriction is situated within the first four inches of the bowel, its presence and caliber may be determined by digital exploration. When with difficulty reached by the finger, the patient should be directed to strain as if at stool, in order to force the obstruction nearer the anus. Beyond this limit the

bulbous bougies must be relied upon. These instruments are of all sizes, each consisting of an oval bulb of hard rubber, attached to the end of a flexible whalebone staff. In introducing them the patient should rest upon the back while the bougie, warmed and oiled, is guided up the bowel, upon the index-finger of the left hand, which is carried its full length into the rectum (Fig. 560). If resistance is met with, only careful and gentle pressure should be exercised, for undue violence may drive the bulb through the wall of the gut. The inferior limit of the stricture is indicated by the first obstruction encountered. If the bulb can be carried through the constriction, the resistance ceases, but is again experienced when, upon withdrawing it, the shoulder of the instrument catches at the upper limit of the

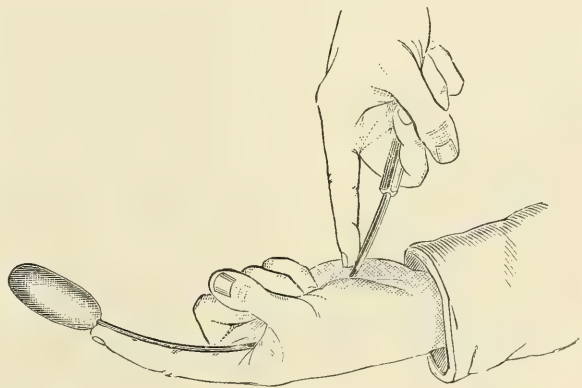


FIG. 560.—Method of introducing the bulbous bougie in exploration of the rectum. (After Bushe.)

bulbous bougies must be relied upon. These instruments are of all sizes, each consisting of an oval bulb of hard rubber, attached to the end of a flexible whalebone staff. In introducing them the patient should rest upon the back while the bougie, warmed and oiled, is guided up the bowel, upon the index-finger of the left hand, which is carried its full length into the rectum (Fig. 560). If resistance is met with, only careful and gentle pressure should be exercised, for undue violence may drive the bulb through the wall of the gut. The inferior limit of the stricture is indicated by the first obstruction encountered. If the bulb can be carried through the constriction, the resistance ceases, but is again experienced when, upon withdrawing it, the shoulder of the instrument catches at the upper limit of the

obstruction. The lower border of the stricture is again indicated when all resistance ceases in withdrawing the bulb.

Treatment.—The surgical treatment of stricture of the rectum may comprise *dilatation* or *division* of the cicatricial tissue or *colotomy*.

The character of the obstruction and its location will determine the means to be employed. When the stricture is linear, and is located near the anus, relief may be obtained by dilatation. For this purpose the finger should be employed, and the operation repeated at necessary intervals until a sufficient opening is secured. If the cicatricial tissue is dense, and does not yield in the effort at dilatation, it should be incised to a slight depth at four or five points of its circumference, and the finger again introduced. The incisions may be made with a probe-pointed bistoury, carried along the finger as a guide, or the anus and bowel may be stretched with the Sims rectal speculum up to the point of obstruction, and the knife introduced without a guide. If this procedure is not successful, the only alternative is *posterior linear rectotomy*. In performing this operation the patient is placed upon the back, with the anus at the edge of the table, and the legs drawn up and separated. The parts below the obstruction are dilated with the speculum. A long, curved, sharp-pointed bistoury is carried through the stricture, keeping the cutting edge toward the posterior median line of the gut. As soon as the point is beyond the obstruction, *but not more than four inches from the anus*, it is carried through the wall of the bowel, which, with the stricture, is completely divided out through the anus. If the first incision does not permit the introduction of the first two fingers side by side, it should be made deeper. Hæmorrhage is readily stopped by packing the wound and bowel with gauze, taking the precaution to insert a stiff rubber tube in the middle of the dressing to allow the escape of gas from the intestine. If any important vessel is divided, it may be secured with the forceps or by transfixion with a tenaculum. The dressing is allowed to remain in place for four or five days, and is not replaced after the bowels are moved unless bleeding should occur. Continence of fæces is restored after from three to six weeks. No matter how thoroughly divided, the tendency is to recurrence,




FIG. 561.—Soft-rubber rectal bougies (twelve sizes).

which necessitates interrupted dilatation at intervals of from three to six weeks during the life of the patient. It is usually not necessary to practice dilatation within the first six or eight weeks after the operation.

When the stricture is situated more than four inches above the anus, rectotomy is not permissible on account of the proximity of the large hæmorrhoidal vessels, the peritonæum, and pelvic fascia. Dilatation with the soft-rubber bougies (Fig. 561) may be tried, and, if this fails, a rectotomy may be done as high as the limit already given, which will allow the introduction of the hand to this point and the finger into the stricture. This may now be nicked with the bistoury, as above described, and digital or instrumental dilatation effected. Rectal bougies before being used should be made thoroughly flexible by immersion in warm water. In their employment only a mild degree of force should be exercised, for fear of perforating the wall of the intestine.

When all other measures fail, *colotomy* is the last resort.

NEOPLASMS OF THE RECTUM AND ANUS.

Carcinoma.—Of the malignant new formations which are found in this organ, *epithelioma* is the most common, *scirrhus* and *encephaloid* cancer being next in order of frequency. The latter is comparatively rare. Cancer of the rectum occurs about equally in the sexes, and almost always in the middle-aged and old, although in exceptional instances it has been observed before the age of twenty-five.

Epithelioma begins in the mucous membrane, scirrhus and encephaloid carcinoma in the submucous tissues.

The former is slower in development and less apt to recur after removal. The most common location of cancer of the lower bowel is at the upper margin of the sphincter muscle.

The *prognosis* is grave, the duration of life varying from one to two or three years, and in exceptional cases longer. Usually the earliest symptom of cancer of the rectum is pain with the act of defecation. If the disease is located at the margin of the anus, it can be recognized before there is any interference with the discharge of fecal matter. Later, hæmorrhage is of frequent occurrence, although, as a rule, it is not profuse in character. After an evacuation of the contents of the bowel, the pain, though less intense, remains for some time. A sense of fullness or "bearing down" is a marked feature of this disease in the majority of cases.

Diagnosis.—If operative interference is to be undertaken, it is important that an early diagnosis be made. Epithelioma, as has been said, begins in the mucous membrane, the cells of the new formation break down early, the ulcer being present in some instances before there is marked induration. On the other hand, induration and thickening are observed early in the history of scirrhus and encephaloid.

Non-malignant stricture of the rectum is always preceded by a history of chronic inflammation. To the touch, the cicatricial character of the tissue may be recognized by its firmness and sharp borders. It is not nodular, like cancer, nor is there a deep and wide infiltration of the surrounding tissues in simple stricture, which condition is common to

scirrhus and encephaloid, and the later stages of epithelioma. In doubtful cases it will be advisable to remove a portion of the mass for microscopical examination.

The *treatment* of cancer of the rectum may be *palliative* or *radical*. The former looks to the prolongation of life and the alleviation of pain by the employment of careful dietetic and medicinal measures. The regular daily introduction of warm water will prevent the lodgment of fecal matter and secure the greatest possible immunity from irritation. The iodoform and cocaine suppositories will be found useful in alleviating pain, and morphia may be employed if all other measures fail. As the disease progresses it will be found necessary to practice dilatation of the stricture at intervals which should be as far removed as possible, or partial or complete division may be required.

The radical treatment consists in the free excision of the neoplasm. The death-rate after this operation is exceedingly heavy, and, when the dissection is extensive and recovery follows, the condition of fecal incontinence is deplorable. Moreover, the tendency to recurrence is so great that this knowledge should deter the surgeon from undertaking the operation in other than the mildest cases. When the disease extends higher than three inches from the anus, it is of doubtful propriety, and in scirrhus and encephaloid cancer, on account of the rapid and wide infiltration which occurs with these neoplasms, the operation does not offer a prospect of relief sufficient to justify the danger which is incurred.

Excision is justifiable and should be done in all cases of epithelioma situated within three inches of the anus which have been discovered before infiltration is deep, or before metastasis has occurred. When undertaken, the dissection should be carried on well away from the disease, in the perfectly healthy tissues. It is performed as follows: The patient should be prepared for the operation by being placed upon liquid diet for one week, and the lower bowel should be thoroughly cleansed by repeated injections of tepid water. A good light should be secured, the patient placed in the lithotomy position, and the parts in the field of operation shaved. The rectum should be well packed with sponges to prevent the escape of fluids or other matter from the bowel into the wound. The number of sponges should be noted, so that the operator may be sure that none are left in after the excision is completed. In order to secure as great a degree of continence after the operation as possible, all or a portion of the external sphincter should be preserved. However, if the disease involves this muscle, it should be removed.

An elliptical incision is first made around the anus along the junction of the skin and mucous membrane (or wider than this if the extent of the disease demands it), and the dissection carried up through the inner fibers of the external sphincter, the posterior insertion of which should be split as far back as the tip of the coccyx, in order to give more room. When the disease is approached, the dissection should be kept well out from the gut in the healthy tissues. Within the first inch of the dissection the bleeding points may be readily secured by the forceps, but,

beyond this limit, the operation will be much more rapidly and satisfactorily performed if the tissues are divided throughout between two forceps and catgut ligatures applied at once. It is best not to encroach upon the vagina or urethra and bladder any more than is essential to the thorough removal of the disease, but to utilize the ischio-rectal fossa in securing room for the deeper dissection. As soon as the lower end of the rectum is freed, the wound should be packed temporarily with gauze, the sponges removed, and the bowel closed by tying a strong silk ligature around it. It is essential to the complete success of the operation that the gut be dissected loose, not only an inch above the upper limit of the disease where it is ultimately to be divided, but to a sufficient extent beyond this point to permit its being drawn down until it can be stitched to the margin of the incision in the integument around the anus. When this is accomplished the gut should be drawn down, a strong silk suture carried through the integument on each side and into the wall of the intestine, just above the line of section, and secured. The gut should now be cut off with the scissors, and other sutures inserted. A drainage-tube should be placed in the ischio-rectal fossa, the end projecting on one side of the anus. A sublimate dressing should be applied, leaving a tube in the bowel for the escape of gas. In the after-treatment opium should be administered to prevent a movement of the bowels for a week or ten days.

Polypus.—Three distinct forms of polypi are found in the rectum, namely—the *villous*, *mucous*, and *fibrous*.

The first of these is the more important, for, while essentially benign in the earlier stages of its development, it not infrequently, as a result of the irritation to which it is subjected, becomes malignant. It is composed of new-formed villi, which resemble the normal villi of the rectum. They are very vascular, and differ from the mucous or fibrous polypus not only in their minute structure, but in gross appearances and the character of their attachment to the mucous membrane. While these latter are pedunculated, often hanging by a narrow stem, the villous growth has a broad attachment frequently as thick as the tumor is long.

The mucous or soft, and the fibrous or hard, polypus of the rectum does not differ in any essential particular from that already described in affections of the nasal cavities. In some instances the deeper portions of the tumor undergo cystic degeneration, forming the so-called *cystic polypus*.

Polypi of the rectum may occur at any period of life, being comparatively frequent in childhood. The most common location of these tumors is on the posterior wall of the bowel, just above the internal sphincter. The pedunculated variety in some instances protrude through the anus, causing violent tenesmus. When not removed these neoplasms may break down, causing ulcer or fissure of the bowel, severe hæmorrhage, or by their weight cause prolapse of the mucous membrane.

The *diagnosis* is readily made by inspection or digital exploration, after the rectum is thoroughly cleansed by an enema. The *treatment* consists in removal of the tumor by the forceps, scissors, or ligature.

Villous polypus may be safely removed by transfixing its base with a double silk ligature, tying these, and allowing the mass to slough away; or, with the sphincter fully dilated, the tumor may be removed by the curette. The hæmorrhage is not severe, and may be arrested by packing with gauze.

The pedunculated tumors may be twisted off with the forceps or clipped closely with the curved scissors. The stump should be touched with lunar caustic or burned with nitric acid or the cautery.

Neuralgia.—Pain, neuralgic in character, is occasionally felt in the rectum or about the anus. In some instances it is caused by displacement of the coccyx, the bone in the abnormal position pressing upon the fifth sacral or coccygeal nerve, or directly against the wall of the bowel. The diagnosis is readily made out by direct examination. The only means of cure is by removal of the displaced bone.

The operation is performed as follows: The patient is placed upon the side, an incision is made in the median line, from the tip of the coccyx to about one inch above the sacro-coccygeal articulation. The tissues are first lifted directly from the dorsal aspect of the bone, and then the anterior surface is exposed by beginning at the tip and keeping close to the smooth face of the coccyx. There is no danger of wounding the bowel if this precaution is taken. When the dissection is completed, the bone should be divided at the sacro-coccygeal junction with the cutting-forceps or chisel.

Idiopathic neuralgia of the rectum and anus may occur as in other portions of the body. Spasm of the sphincter is occasionally due to this cause.

Prolapsus Recti.—Protrusion of the rectum may be *complete* or *incomplete*. In the incomplete variety the lining membrane of the bowel is alone protruded. The everted portion may include a narrow ring of the mucous membrane near the anus, or it may measure an inch or more in width. In the complete prolapsus more or less of the entire thickness of the wall of the rectum is dragged downward and everted. The process commences usually near the anus, and in the complete form the fascia which attaches the rectum to the promontory of the sacrum is elongated, and the peritonæum dragged down toward the anal aperture. In the pocket thus formed a loop of intestine may descend and become strangulated.

Prolapsus recti may occur at any period of life, although usually met with in children. In a varying degree it exists as a complication in all cases of chronic hæmorrhoids. It is chiefly caused by frequent and prolonged straining at stool. A predisposing cause in adults is habitual constipation, with the over-distention of the bowel which is the result of this condition. In children, it is thought that the peculiar shape of the sacrum, the curve of which is much less pronounced than in adults, renders this class of patients more liable to prolapsus. It is probable that indiscretions in diet, the lack of restraint, and the low, squatting posture too often permitted in children in the act of defecation, are more responsible for this accident than the straight position of the bowel.

Diseases of the bladder and prostate, uterus and ovaries, pregnancy, or the presence of a tumor, are also to be considered as exciting causes of this lesion. Finally, the weak and infirm are more liable to be affected than the robust.

When prolapsus occurs it is accompanied with a sense of distention, heaviness, and dragging down, which causes great pain and anxiety to the patient. In recent cases in which there is only an eversion of the mucous membrane, this will be seen projecting beyond the limit of the anus on one or both sides, or in severer cases including its entire circumference. The prolapsed fold or ring is of a reddish-purple color, varying with the degree of strangulation, and is broken at intervals by furrows or depressions which, in the main, seem to radiate from the center of the protrusion. When complicated with hæmorrhoids, these will be easily recognized by their shape and color, giving a swollen and nodulated appearance, which could not exist in simple eversion. In differentiating partial from complete prolapsus, the chief points are the thinness of the prolapsed ring in the partial form, and the radiating direction of the furrows. In complete prolapse the mass is markedly thicker, more strangulated, and the folds of mucous membrane are more nearly circular in arrangement.

Treatment.—In *acute* prolapsus the immediate indication is to relieve the strangulation and restore the prolapsed portion to its normal position. The removal of the cause or causes of the accident is next in importance. The first indication is met by placing the patient upon the left side, with the pelvis well elevated, the shoulders and head depressed, or in the knee-shoulder position, in either of which the return of the bowel is aided by gravity. The fingers of the operator and the protruded mass should now be well lubricated, and steady and gentle pressure exercised upon the tumor in the direction of the normal position of the bowel. In almost all cases this practice will succeed. When, on account of spasm of the sphincter, the strangulation is so great that gangrene is threatened and reduction impossible, an anæsthetic should be administered and forcible dilatation effected by the thumbs of the operator, after which the mass will readily return within the anus. Once reduced, the greatest pains must be observed to prevent the repetition of the accident. Fecal accumulation and straining should be prevented by the injection of cold water when there is a need or desire for an evacuation, and by the use of the bed-pan. In children it is essential that they should not be allowed to squat upon a low vessel, or place themselves in a constrained position at stool. The position assumed should be one where gravitation will not carry the intestines toward the anus. Lying upon the side, with the buttocks slightly projecting over the edge of the bed or table, or defecating in the knee-elbow position, should be insisted upon. Any condition which contributes to the cause of prolapse must be removed or palliated. When, despite all conservative methods, the prolapse becomes chronic, growing progressively worse, operative interference becomes imperative. The preparation of the patient is the same as for other operations about the rectum. After the

narcosis is complete, the patient is placed in the lithotomy position, with the pelvis elevated to such an extent that the intestines will gravitate toward the diaphragm, the mass returned, and a large sponge introduced well up into the bowel. The sphincter ani and rectum should now be widely dilated with the speculum until the walls of the bowel are brought clearly into view. The Paquelin cautery-knife, heated to a light-red color, is carried into the bowel as high as the limit of the prolapsed portion, and drawn straight down the wall of the gut to the margins of the anus, burning its way through the mucous membrane. The depth of the furrow must be determined by the extent of the prolapse. If the entire thickness of the rectal wall is involved, as in complete prolapsus, the wound should extend well into the muscular layer. In partial prolapse it will suffice to go down to the muscle. From four to six incisions should be made at equal distances from each other. Partial divulsion of the sphincter should be made before or after the operation, in order to prevent spasm and to secure rest. A complete recovery will follow in the large majority of cases. If the Paquelin cautery can not be obtained, strong iron wire, or rod-iron, may be used by heating in the ordinary furnace. The after-treatment is to keep the patient quiet with mild opium narcosis, and after five or six days to move the bowels with a cold-water enema, keeping the patient in the recumbent posture. The cure is effected by the formation of inflammatory adhesions between the mucous membrane and muscle, and between the outer wall of the rectum and the peri-rectal connective tissues and fasciæ. The older operation of excising a V-shaped piece of the mucous membrane and afterward uniting the edges by sutures, is bloody and troublesome, and not to be compared to the procedure above given.

In *chronic* prolapsus, the operation is the same, provided that reduction can be effected. The incisions with the cautery-knife must extend deeply, as above indicated. When reduction is impossible, owing to the inflammatory thickening of the protruded mass, there is no alternative but in excision. In this operation the integrity of the sphincter must not be impaired. Preferably, the mass should be cut off with a delicate cautery-knife, keeping just outside the sphincter, which is usually slightly drawn out with the gut. The line of incision should be circular, and, by allowing the knife to burn its way slowly, all danger of hæmorrhage is avoided. The after-treatment is the same as in the preceding operation.

When the cautery-knife is not at hand, a rim of the everted mucous membrane, and a corresponding rim of the integument which has been drawn down with the prolapse, may be cut off with the scissors, and forceps inverted and sutured with catgut, as after Whitehead's operation for hæmorrhoids, given on another page.

Another method is to insert a series of ligatures of strong silk around the prolapsed mass at the level of the anus. These extend through both thicknesses of the gut. When tied tightly, strangulation of the portion beyond the ligatures occurs, and this should be cut off to within a quarter of an inch of the ligatures.

HÆMORRHOIDS.

Hæmorrhoids, or "piles," are vascular tumors or varicosities formed beneath the mucous membrane of the rectum and anus. They are divided anatomically into *external* and *internal* hæmorrhoids. Internal hæmorrhoids are again divided into *venous*, *arterio-venous*, and *capillary* hæmorrhoids.

The veins which are involved in hæmorrhoids belong to two plexuses, between which, ordinarily, there is not a free anastomosis. The inferior or external hæmorrhoidal plexus is situated in the last portion of the rectum, within about one inch of the anus, and the blood from this part returns by way of the middle and inferior hæmorrhoidal veins to the iliacs, and thence by the inferior cava to the heart. The superior or internal plexus occupies the rectum above this point, and from this portion the blood returns by the portal system, passing through the liver.

In their incipiency, *external hæmorrhoids* are simple varicosities of the inferior plexus. Later, as a result of engorgement and repeated inflammation, the walls become thickened from the presence of newly formed connective tissue, which, in the process of contraction peculiar to this product of inflammation, often causes obliteration of the vein within the tumor. The remains of these tumors are seen in almost all cases of chronic external hæmorrhoids, where they appear as tags of thickened skin of variable size and shape, collected around the margin of the anus.

Internal hæmorrhoids of recent development are also varicosities of the internal or portal plexus, but when of long duration the tumors very frequently contain arterioles of considerable size. The mucous membrane of the deeper portions of the rectum is at times studded with small, raspberry-like elevations, which bleed profusely, are found to contain a rich network of capillaries, and for this reason are termed *capillary hæmorrhoids*.

External Hæmorrhoids—Acute and Chronic.—This form of tumor, commonly known as "dry piles," is of frequent occurrence. Few individuals live beyond the age of forty without being affected with this lesion. The chief cause is habitual constipation and the over-distention of the lower portion of the rectum in the act of defecation. Prolonged straining at stool, even without the discharge of fecal matter, will also aid in the development of piles. Gravitation by reason of the erect posture is also entitled to a consideration in the ætiology of hæmorrhoids, since man is the only animal thus affected. Pressure upon the iliac veins or the inferior cava by the gravid uterus, or any form of tumor, will also aid in producing varicosities of the hæmorrhoidal veins as well as in those of the lower extremities.

A patient who is suffering from an acute external hæmorrhoidal tumor will usually give a history of constipation and straining at stool, with an unnatural sense of fullness and heaviness about the anus, and of considerable pain while the evacuation is taking place, for several days before the protrusion is noticed. Immediately after an evacuation

a swelling is noticed just outside of the anus which is painful to the touch, and which can not be pushed into the bowel. Upon inspection, a recent external hæmorrhoidal tumor usually appears tense and glistening on the surface, and red or reddish-blue in color. It is partly within and partly outside of the anus. There may be a single swelling, which is spherical in shape, or it may be crescentic, occupying half of the anal margin. If not observed until after several days have elapsed, and when the tension or partial strangulation has not been relieved, ulceration may have occurred, with inflammation and induration of the tissues near the base of the tumor. In other instances which do not come under the observation of a physician, the patient goes to bed, pushes the tumor within the anus, the symptoms disappear within a day or two, to recur again and again under the same conditions.

Chronic external hæmorrhoids differ from the acute form just described in the following particulars: They are brown or bluish in color, are not tense nor painful, are loose and flabby, and have a thickened, leathery feel when pinched between the fingers.

Treatment.—The treatment may be palliative or curative. If the palliative treatment is determined upon, the immediate indication is to relieve the tension in the tumor by returning it within the anus. The patient should be placed in the left lateral or knee-shoulder position, the protruded portion and fingers of the operator thoroughly lubricated, and reduction effected by well-directed pressure, combined with slight dilatation of the sphincter. If the tumor is so large that it can not be reduced, relief may be obtained by the local application of the ice-bag, or cold water. The majority of cases will be relieved temporarily by this treatment, and a certain proportion may not suffer a relapse, but the rule is for the tumor to recur from time to time until it is cured finally by an operation.

In operating for the cure of external piles, the ligature is rarely demanded. If the masses are extensive, it will be advisable to excise them after the method of Whitehead. If there is a single tumor or one or two small hæmorrhoids which are inflamed, immediate relief may be obtained by incising it. This procedure may be rendered painless by the following method: The smallest hypodermic needle is attached to the syringe, containing about m xv of a 4-per-cent solution of cocaine hydrochlorate. The needle is introduced into one side of the tumor at its base to the depth of about one eighth of an inch, and three or four minims of the solution forced out; a minute later it is carried farther, and the manœuvre repeated until the needle has completely transfixed the mass, and all the fluid injected. Within five minutes the anæsthesia is usually so complete that the tumor can be laid open with the bistoury without pain. The bleeding is insignificant, and is easily arrested by packing a tuft of borated cotton or lint into the wound. No after-treatment is required. The wound heals after five or six days and the pile is cured.

Old external piles may be removed by grasping the tumor with a pair of mouse-tooth forceps and clipping it off near its base with a pair of scissors curved on the flat. Local anæsthesia should also be employed.

Internal Hæmorrhoids.—Constipation, over-distention of the rectum, and prolonged straining at stool must also be considered as among the principal causes of internal as well as external piles. In addition to these, any disease of the liver which causes a retardation of the return of blood through the portal circulation will aid in producing internal hæmorrhoids.

Pressure upon the portal vein, or upon the inferior mesenteric vein, whether due to an overloaded condition of the alimentary canal, or a tumor, will produce the same effect.

Symptoms.—Internal piles, as a rule, cause little or no pain or annoyance until they are sufficiently developed to be caught in the grip of the sphincter, or are protruded through the anus. Previous to their descent, however, a variable amount of bleeding has usually occurred, often enough to attract the attention and excite the alarm of the patient. This is especially true of the arterio-venous and capillary tumor, although the venous tumor not infrequently gives rise to considerable hæmorrhage.

Upon digital examination the presence of the hæmorrhoids may be easily recognized, and ocular demonstration may be made by the careful dilatation of the sphincter with the Sims rectal speculum. If a free enema of warm water be administered, the tumors will usually protrude with the discharge of the water if the patient is placed in the squatting posture, and is directed to make a strong expulsive effort.

Treatment.—Venous and arterio-venous internal hæmorrhoids may be cured by one of three methods—the ligature, by excision, the clamp, and the injection of carbolic acid; the capillary variety by the mild application of the cautery or nitric acid.

Of these methods, the ligature and excision are by far the more satisfactory and thorough operations. The clamp is preferred by some operators, but in the opinion of the author is inferior to either of the above. It requires a special instrument and a cautery apparatus, while the other procedures are done with the ordinary instruments of the general practitioner. Moreover, the danger of hæmorrhage is greater after the clamp. Either of these three methods is preferable to the injection of carbolic acid. The objections to this operation are, that it does not always succeed, it requires a long time—several weeks, and at times months—in effecting a cure, peri-proctitis and abscess of the ischio-rectal fossa may ensue, and hepatic embolism, with abscess, is, however remote, a possibility. Not infrequently ulcer of the bowel results, which of itself requires to be cured. In its favor it may be said that the treatment can be carried on without ether narcosis, in almost all cases without going to bed, and is not, as a rule, accompanied by great pain.

As between the ligature and excision it may be concluded that the former is bloodless, simple in technique, satisfactory in results, and can be done in about one third of the time required for excision. *White-head's* operation, while more bloody, yields a cure equally radical, quicker by from five to ten days, and is somewhat less painful for the first five days after the operation, and is more cleanly. In my opinion,

the ligature will continue to be more generally practiced than all other methods for the radical cure of hæmorrhoids.

Operation by the Ligature.—The preparation of the patient is the same as in other operations about the rectum. When fully anæsthetized, the lithotomy position should be preferred, or, if help is scarce, or the convenience of the operator is better suited, the patient may be placed upon the left side, with the left arm behind the body and the thighs and legs flexed.

The first step is the dilatation of the sphincter, which is accomplished by introducing the thumbs or first and second fingers of each hand and stretching the muscle in all directions, until relaxation is complete. This should not be too rapidly effected, for fear of tearing the fibers. A soft sponge secured by a strong silk thread is carried into the rectum above the piles, in order to prevent the descent of fecal matter; or a Barnes's dilator, as recommended by Dr. Willis P. King, may be introduced and then filled with water. The bowel should then be irrigated with 1-to-5000 sublimate solution.

Seated in front of the patient, the operator—presuming that the tumors are present in the entire anal circumference—introduces one or two fingers of his left hand and by pressure with the palmar surface of the fingers from above downward, brings the mucous membrane, which lines the hæmorrhoidal tumors and these tumors well down to the margin of the anus. In this way he is perfectly able to discover how high up the needle and ligature must be introduced in order to cut off all the varicosities.

With a pair of scissors, or a sharp, small-bladed knife, he now makes an incision at the muco-cutaneous junction, and this incision should extend through the skin and follow somewhat the irregularities of the various tumors.

This done, a large, strong, half-curved needle, armed with a long doubled Chinese twisted-silk ligature, so strong that the operator has essayed in vain to break it, and held by a firm holder, is introduced as follows: For the patient's left side (operator's right) the needle, concavity toward the operator, is introduced into the incision just made and is carried to the depth of about one eighth to one quarter inch—just enough to well engage the point. With the fingers of the left hand dragging down the tumor, and the base of the hæmorrhoid thus well defined, it is evident that, if the needle were plunged directly through to the base of the tumor, it would pass through or so near to the peripheral fibers of the sphincter-ani muscle that, as the ligature was tightened, these would be sacrificed and the integrity of this muscle impaired.

Therefore, as soon as the needle is engaged as just described, enough to clear the sphincter, it is turned completely over, so that the convexity is toward the operator, and is then carried along the inner surface of the sphincter, well away from the mucous membrane, until the point is felt to touch the level of the finger, which all the while has remained fixed at the base of the tumor. It is again turned, concavity to the operator,

which brings the point through the mucous membrane upon the finger located there, which finger now guides the point of the instrument out at the anus. Dividing both threads and liberating the needle, the double ligatures are ready for tying. At this step of the operation two important points are to be considered: 1. That the ligatures be crossed. 2. That not too much tissue be allowed in the grasp of each thread. The threads may be disassociated by traction on the ends, and then interlocked by carrying on one side of the tumor one thread over the other. Not more than three quarters of an inch of the anal circumference should be cut off by one set of double ligatures. Measuring then about one half of this distance on each side of the point traversed by the threads, cut with the scissors directly through the anal margin down to the level of the encircling incision made at the muco-cutaneous junction. When this perpendicular incision passes through a hæmorrhoid, the bleeding should be prevented by applying a forceps before the cut is made. The entire hæmorrhoidal circumference is thus divided into segments of about three quarters of an inch in length each.

The ligatures are now very tightly tied by the reef-knot (Fig. 111), the ends left long and the group of four threads looped together. If the operator is not ambidextrous, the ligatures for the patient's right side (operator's left hand) may be introduced from within out.

Each tumor or section is treated in the same manner, until all are completed, when all the strangulated tissues are cut away with the curved scissors, leaving stump enough to hold the loops securely. The threads are now cut off one inch from the knots, the rectal plug withdrawn, a medium-size rubber tube four inches long is wrapped with iodoformized gauze, lubricated with vaseline and introduced for three inches into the rectum, and a pad of gauze and cotton and T-bandage applied.

It is advisable to give a hypodermic or a suppository of morphia as the operation is being completed, as pain is present in almost all cases.

The dressing may be removed and the bowels moved by enema on the fourth or fifth day. The catheter is frequently required for the first few days after the operation. The ligatures come away about the twelfth day, and the recovery is complete about the third week.

Excision of the Hæmorrhoidal Varicosities, together with a Circle of the Terminal Mucous Membrane of the Rectum—Whitehead's Operation.—The preparation of the patient and position on the table are the same as just given.

The sphincters are thoroughly paralyzed by digital stretching, so that they have no grip, and permit the hæmorrhoids and any prolapse there may be to descend without the slightest impediment.

By the use of scissors and dissecting forceps the mucous membrane is divided at its junction with the skin round the entire circumference of the bowel, every irregularity of the skin being carefully followed.

The external and the commencement of the internal sphincters are then exposed by rapid dissection, and the mucous membrane and attached hæmorrhoids thus separated from the submucous bed on which they rested, are pulled bodily down, any undivided points of resistance

being snipped across, and the hæmorrhoids brought below the margin of the anus.

The mucous membrane above the hæmorrhoids is now divided transversely in successive stages, and the free margin of the severed membrane is attached as soon as divided to the free margin of the skin below by a suitable number of silk sutures. The complete ring of pile-bearing mucous membrane is thus removed.

Whitehead advises that torsion be applied to all bleeding points, as the operation proceeds. The dissection is comparatively dry, if the operator keeps close to the inner surface of the external sphincter, and works with the finger or the dull-pointed scissors.

The silk sutures, inserted as the rim of the mucous membrane is finally snipped off, prevent any great amount of hæmorrhage.

Iodoform may be insufflated upon the raw surfaces, and an ordinary T-bandage dressing applied. The sutures are allowed to come away of their own accord.

The operation with the *clamp* and *cautery* is performed as follows: After stretching the sphincter, the tumor is drawn out and grasped at its base between the jaws of the clamp (Fig. 562), and the blades closed by tightening the screw in the handles until the hæmorrhoid is strangu-




FIG. 562.—Smith's hæmorrhoidal clamp (ivory-plated).

lated. It is advised to grasp the hæmorrhoids in such a manner that the instrument points directly up the bowel. With the scissors the mass is cut away about one fourth of an inch external to the clamp, and the cut surface thoroughly cauterized with the Paquelin or the actual cautery. The ivory plates upon the jaws of the clamp protect the mucous membrane of the bowel from being burned. When this is done, the blades should be slowly separated, and, if any oozing is seen, the bleeding point should be again touched with the cautery. The after-treatment is the same as for the preceding operation.

Injection with Carbolic Acid.—The hæmorrhoid to be operated upon should be exposed with the speculum or drawn well out with the fingers. If it is a long pedunculated tumor, the needle should be introduced from the point to near its base. If it is round or oval in shape, the needle should pass through the longer diameter of the mass near the level of the mucous membrane of the bowel. The mucous membrane and integument should be well covered with vaseline to prevent excoriation from the acid which may leak from the syringe or ooze out of the tumor.

The ordinary hypodermic syringe will answer every purpose if one or

two extra long and fine needles are secured. In Fig. 563 is shown an apparatus especially designed for this operation.

From ten to twenty minims of a 4-per-cent cocaine solution (the quantity being determined by the size of the tumor) are first thrown in, and the instrument unscrewed from the needle, leaving this sticking in the tumor. The carbolic-acid solution is now drawn into the syringe, and this is again screwed on to the needle. After from one to three minutes the anæsthesia will be complete, and the solution should be forced slowly into the tumor, being distributed in the line in which the cocaine was injected. It is advisable to operate upon a single hæmorrhoid at each operation. The strength of the solution and the quantity to be employed will be determined by the size and condition of the tumor. If a

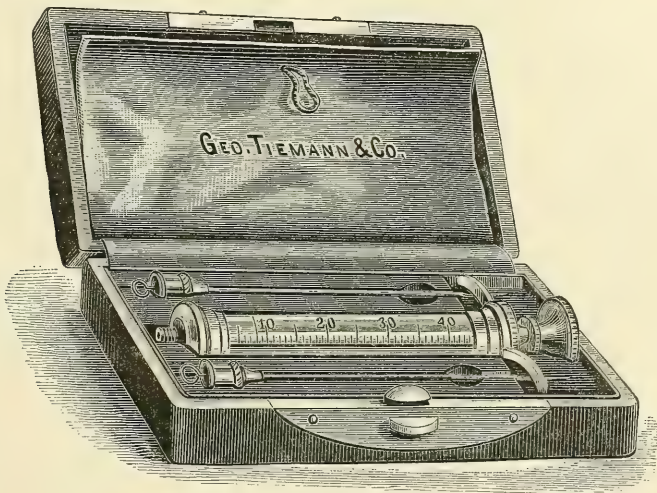


FIG. 563.—Kelsey's hæmorrhoidal syringe.

rapid sloughing of the mass is desired, this result may be secured by using a solution of equal parts glycerin and carbolic acid, and from five to twenty minims should be introduced unless the hæmorrhoid is unusually large. After injecting a solution of this strength the tumor becomes hard, and changes to a blue or bluish-gray color. In from twenty-four to forty-eight hours the mass sloughs away, and by the fourth or fifth day has disappeared, leaving only a small ulcer in the mucous membrane corresponding to the base of the hæmorrhoid. If a 10-per-cent solution is employed, sloughing rarely occurs, and a much greater quantity—from twenty to thirty minims—can be injected. A mild degree of inflammation is established, followed within a few days by a diminution in the size of the tumor, which, in a certain proportion of cases, gradually undergoes atrophy and entirely disappears. The degree of pain following the injection of the stronger solution, after the temporary anæsthesia secured by the cocaine has passed off, varies with different individuals. In some of my cases it was so insignificant that the patients went immediately about their vocations. In others the same solution caused great annoyance and considerable, though never alarming, inflam-

mation. The milder solutions are also painful at times, though in a less degree. In choosing between the weak and strong solutions just given, the operator must be guided chiefly by the time in which it is desired to effect a cure. If expedition is demanded, the strong injections should be employed; if not, the weak solution is preferable to begin with, and, if necessary, this may be increased in strength at a subsequent operation.

In *capillary hæmorrhoids* the chief symptom is hæmorrhage. The bleeding occurs with and after each stool, or may follow violent exercise or straining. If the finger is carried into the bowel, no tumors are felt, and there is usually no tenesmus. If the speculum is employed, the mucous membrane will be seen to be studded with bleeding points or tufts projecting a slight distance from the normal level of the lining membrane of the rectum. They are red, not unlike small raspberries in appearance, and bleed profusely at the slightest provocation. They are really new formations or chronic granulation-tissue, rich in capillary loops.

The *treatment* consists in dilatation of the anus and rectum with the speculum, and in touching the bleeding points with the Paquelin cautery until all bleeding ceases. If the cautery is not at hand, pure nitric acid should be applied.

CHAPTER XIX.

GENITO-URINARY ORGANS.

Kidneys.—Certain diseased conditions of the kidneys, resulting chiefly from traumatism, but in some instances idiopathic in origin, demand a careful consideration, and at times active interference, at the hands of the surgeon.

Wounds.—Solutions of continuity in these organs, either as a result of concussion or from the penetration of a foreign body, are among the most dangerous visceral lesions. Rupture of the kidney occurs not only from violence applied immediately over the anatomical seat of this organ, but indirectly, as from a fall on the head or feet. The conditions which result are practically identical, whether there is a penetrating wound or not. Hæmorrhage is immediate, and is proportionate to the extent of kidney involved and to the vascularity of the part injured. Shock is usually well marked. Vomiting is present, with pallor, cold perspiration, rapid and weak pulse. Pain, if severe, is felt in the region of the organ, and is transmitted in the direction of the ureters, down the leg, and into the testicle of the injured side in the male, which organ is usually drawn up toward the external ring. Extravasation of urine takes place, and, when the capsule is torn, finds its way into the loose areolar tissue of the retroperitoneal space. Hæmorrhage occurs in the same way, as well as into the uriniferous tubules and pelvis of the kidney. The organ may be displaced by concussion, usually traveling downward and toward the median line.

The *symptoms*, although varying with the extent of the lesion, are usually those of profound shock. Pain, not only local, but extending in the direction just described, together with the presence of bloody urine, in a patient who has received a wound in the lumbar region, or a severe concussion, and who has no bladder or urethral disease to account for hæmaturia, are symptoms which point quite clearly to the nature of the injury. Partial suppression of urine is not uncommon. A marked elevation of temperature usually follows the reaction from shock. The febrile movement is chiefly due to the inflammation which follows the escape of urine into the retroperitoneal space. With the advent of pus-formation, local tenderness is increased, the area of inflammation spreads, the more superficial structures become tense, the integument is reddened, and rigors or chills occur, followed by exacerbations of temperature.

The *prognosis* is unfavorable, but must chiefly depend upon the extent of the injury, as determined by the earlier symptoms.

The *treatment* may be *radical* or *conservative*. Immediate operation within the period of shock is scarcely to be thought of. If the symptoms of hæmorrhage are alarming, deligation of the extremities should be practiced, and, if syncope is still threatened, the intra-venous injection of a saline solution should be performed. Direct operative interference, by cutting down upon the wounded organ, will be rarely called for.

With the earliest symptom of abscess an exploratory incision should be made. It is advisable to insert the aspirator-needle at the points of greatest tenderness and induration, and, if pus is discovered, the incision should be made along the needle as a guide. If pus can not be obtained by using the aspirator, the incision is still indicated if the symptoms of sepsis above given are present. The organ may be readily reached by cutting parallel with, and about three inches and a half external to, the spines of the lumbar vertebræ. The kidney is located just in front of the outer border of the quadratus lumborum muscle, its lower extremity reaching down to the level of the umbilicus.

If an abscess is found, it should be irrigated with 1-to-5000-sublimate solution, and free drainage established.

The kidney is often the seat of morbid changes, which occur partly from internal violence and partly from idiopathic causes, which may at times justify the surgical invasion of this organ. Pyelitis, pyonephrosis, calculus, hydronephrosis, and certain new formations, as cysts, carcinoma, sarcoma, rhabdomyoma, adenoma, angioma, tuberculosis, and gumma, are among the chief diseases of a surgical nature.

Pyelitis, or inflammation of the pelvis of the kidney, may be caused by the irritating effects of calculi in the calices or pelvis of this organ, which do not escape readily into and through the ureter; to over-distention, resulting from urethral, vesical, or ureteral obstruction, or by extension of an inflammatory process from below upward (*urethritis*, *cystitis*, *ureteritis*). It is less frequently caused by direct violence from without, or may be part of an idiopathic perinephritis. It is readily understood how a stricture of the urethra, enlarged prostate, or an obstructed ureter would force the urine back upon the kidney, causing, in severe and chronic cases, destruction of this organ, and a pyelitis before this could occur. In like manner, the inflammation in a urethritis or cystitis may travel along the ureter until the pelvis of the kidney is involved.

The *diagnosis* of pyelitis can not be so readily made out by the symptoms referable to the inflammation in the pelvis proper, as by a study of the conditions which precede it. Pain, which is present in this disease, is present in a variety of kidney lesions, and, as in neuralgia of this organ (*nephralgia*), it is met with when no symptoms of inflammation exist. If, after an attack of renal colic, pain of a more constant and less excruciating character is felt, deep in the lumbar region, being on one side only, and on that side upon which the colic occurred, and if pus is present in the urine where no cystitis or urethritis exists, pyelitis should be strongly suspected. Persisting pain in this region, in a patient suffering

from obstruction in the urinary track, beyond the pelvis of the kidney, is also strong evidence in favor of pyelitis, notwithstanding that the pus present is known to come from other sources. Added to the above, the febrile movement, and rigors of the inflammatory process, the frequent micturition, the exaggeration of pain upon pointed and deep pressure, and, in the later stages, the presence of a tumor, caused by the dilated organ, and the diagnosis of pyelitis may be determined.

In cases of pyelitis with complete obstruction, pus is retained, and, together with the urine excreted by the tubules not yet destroyed, distends the pelvis, together with the kidney, causing a hydro-pyo-nephrosis, ultimately opening into the peritonæum, pleura, or retroperitoneal space, or it may open through the integument in the lumbar region, or near Poupart's ligament.

Treatment.—This must be directed to the relief of pain, to the removal of the cause of the disease, and to the maintenance of the patient's powers of resistance by judicious feeding. The relief of pain is obtained by the employment of anodynes and by counter-irritation, as by sinapisms, hot cloths, and cups to the lumbar region. When the disease is obstinate, and the destruction of the kidney is evident, incision should be made, and free drainage secured, or, if the patient's condition will justify a more formidable procedure, the diseased organ should be removed.

Hydronephrosis is both a congenital and an acquired lesion. In the congenital form the arrest of development may be in the ureter or urethra, with partial or complete occlusion of one or the other of these organs. The urine, being unable to escape, accumulates and distends the pelvis and calices, causing destruction of the tubules and Malpighian tufts, and terminating, if the obstruction is sufficiently prolonged, in a cyst, the wall of which is composed of the pelvis and capsule of the kidney. As stated above, obstruction of the urethra usually causes inflammation of the pelvis, the result being not a simple hydronephrosis, but a hydro-pyo-nephrosis. Simple hydronephrosis occurs in rare cases, when the obstruction comes on gradually. In congenital occlusion the distention of the pelvis, the atrophy of the kidney, and the development of a large cyst may occur without inflammation. The character of the obstruction will vary. Calculus in the ureter, or stricture resulting from the inflammation caused by the descent of a stone to the bladder, pressure by a neoplasm or another organ, and all lesions of the bladder and urethra which retard or arrest the flow of urine, may produce this condition. At times the tumor is so small that it may escape observation, or it may almost fill the abdominal cavity.

The *diagnosis* is rarely made unless the cyst is sufficiently large to attract attention. The presence of a fluctuating tumor in the lumbar region will serve to suggest hydronephrosis, and the exploration of the cyst with a very fine needle will exhaust, by aspiration, a fluid which, under the microscope, will demonstrate the exact nature of the tumor. In those cases where the obstruction is not permanent, but recurs at intervals, the disappearance of the swelling, with the discharge of an extraordinary quantity of urine, may be considered almost a positive

symptom of this condition. When the cause is vesical or urethral, both kidneys will be affected. Uræmic symptoms may occur, and are present in the latter stages, when the destruction of the tubules is general. If the obstruction is gradual, the tolerance of uræmia is at times great, and when only a single kidney is affected, especially if the unilateral occlusion is not sudden, the other organ will, in most cases, assume a functional activity sufficient for the work of both kidneys.

Hydronephrosis may be mistaken for hydatid cysts of this organ, for ovarian cysts, cyst of the pancreas and spleen, or for abdominal dropsy. In abdominal dropsy the fluid gravitates to the pelvis and changes with the different positions assumed. Liver-disease almost always precedes ascites. Cysts of the spleen and pancreas are rare, and the early history of their development will point to an origin away from the kidney. In hydatid cysts of the kidney the only positive differentiation is in the recognition of the hydatid vesicles in the urine.

Treatment.—In mild cases, whether the disease is double or single, operative interference is not demanded. In stricture of the urethra or enlarged prostate, the removal of the obstruction is imperative. Symptoms of uræmia call for the warm bath and free perspiration in the effort to eliminate by the skin the necessary quantity of urea. To this, mild purgation may be added. When the cyst is large enough to interfere with the comfort or to threaten the life of the patient, it should be aspirated or cut down upon and drained by incision, or completely removed. In introducing the aspirator-needle, the most prominent part of the protrusion near the last rib should be punctured. If the condition of the patient will permit, preference should be given to incision and free drainage of the cyst. If the cyst-wall has not adhered firmly to the surrounding tissues, the dissection should be carried down to the cyst and the wound packed with sublimate gauze for a day or two until adhesions have taken place, after which the contents may be evacuated.

Renal Calculus.—Stone in the kidney may be formed by an aggregation of urinary crystals in the tubules, calices, or pelvis of this organ. To the composition of these bodies epithelia, mucous and other organic substances contribute. Although chiefly composed of uric acid in various combinations, and oxalic acid in combination with lime, renal calculi may be as variable as those to be considered in connection with diseases of the bladder.

The *symptoms* of stone in the pelvis or the kidney are referable to the degree of inflammation (pyelitis) caused by its presence, and to the interference with the escape of urine into the ureter. The condition of pyelitis is in great part determined by the shape and composition of the calculus.

A mulberry calculus (oxalate of lime) produces here, as in the bladder, a more acute and therefore more perceptible inflammatory process than the smooth uric-acid or phosphatic stones. Stones with smooth surfaces and of slow formation may remain months in the pelvis without causing a disturbance sufficient to attract the attention of the patient

or physician. This is especially true if the body does not drop into the opening of the ureter. Sudden occlusion of this tube produces symptoms of general disturbance. If the stone is small and smooth, it may pass into the outlet and find its way, by gravity and the pressure of urine from behind, into the bladder without attracting the attention of the patient. When a rough stone, or one large enough to distend the tube enters the ureter, symptoms of a more than usually painful nature appear. The pain is usually referred to the neighborhood of the impacted substance; it is violent to a degree rarely experienced in any other affection. It may be spasmodic or constant. In males the testicle of the affected side is drawn up toward the external ring, and not infrequently the pain is felt in this organ, in the scrotum, penis, and down the thigh and leg. Vomiting may be present, and constipation is the rule. Suppression of urine follows in a small proportion of cases, and, on the other hand, in some instances the quantity excreted is greater than normal. In the majority of cases red blood-disks may be found in the urine. The duration of the attack varies from a few hours to days. When the stone escapes into the bladder, the relief is as sudden as the attack. In rare instances it becomes hopelessly impacted.

The *treatment* of renal calculus is practically *palliative*. The diathesis of the individual must be corrected. The diet, mode of life, and surroundings which produce one stone in the kidney will cause the same lesion indefinitely. The character of the urine must be carefully studied and an effort made to dissolve the concretion in the pelvis. The object of this plan is to carry in contact with the stone, through the agency of the blood, certain reagents which are supposed to effect the dissolution of these concretions. The citrate of potash, in doses of from grs. xx-xxx, is a favorite remedy. It is especially commended in the uric-acid calculus, and should be given several times a day, freely diluted with water or flax-seed tea, and continued for several months. In phosphatic calculi the benzoate of ammonia, in doses of grs. v-xx, should be employed. When the persistence of symptoms points to the formation and enlargement of renal calculus, nephrotomy is indicated.

When *renal colic* occurs, the chief indication is to alleviate pain, and for this purpose the hypodermic use of morphia is most efficient. Ether narcosis may also be employed where morphia or opium is contra-indicated. Pain is not only allayed by this means, but the relaxation of the muscular elements of the ureters secured and the passage of the calculus greatly facilitated. In case the calculus becomes permanently lodged in the ureter, the operation of nephrectomy may be necessitated. This procedure will be described hereafter.

Cysts.—In addition to the form of cyst which is caused by obstruction beyond the pelvis of the kidney, there may exist smaller cysts within the substance of this organ resulting from occlusion of one or more of the tubules. These cysts are usually small. When the obstruction occurs near the apex of the pyramid, the entire tubular structure of that pyramid may be destroyed. *Hydatid cysts*, due to the lodgment of the ova of the *tænia echinococcus*, are occasionally met with in the kidney.

The *symptoms* of renal cyst are usually obscure until the tumor becomes large enough to exercise pressure on neighboring viscera or to appear as a swelling in the lumbar region. Fluctuation or aspiration will determine the cystic character of the tumor.

The *treatment* of renal cysts is conservative so long as life is not endangered by the pressure of the tumor. The danger of rupture into the peritonæum is not to be overlooked as a possible and fatal accident.

Opening into the retroperitoneal space is also an exceedingly dangerous complication. It may be put down as a safe rule of practice that when a tumor of the kidney becomes large enough to be appreciated by palpation or inspection, and is proved to be cystic in character, the contents should be evacuated by incision.

Carcinoma may be primary in the kidney or secondary by extension from a contiguous organ, or by metastasis. In primary cancer only one organ is affected. When the disease extends from the bladder it is likely to involve both organs, and the same is true of secondary deposits by metastasis. The adenoid or encephaloid variety is most frequently met with. All ages are liable to this disease. The tumefaction is often very rapid, and may reach enormous proportions, death resulting from asthenia due to the mechanical presence of the mass, as well as to the general dissemination of the disease.

The *diagnosis* of cancer of the kidney will depend upon the appreciation of the tumor and a careful study of the history of the case. The differentiation between the solid and cystic tumors, which has already been given, will eliminate hydatids or obstruction to the outflow of urine and cystic degeneration. The recognition of the cancer must depend upon the presence of the peculiar cachexia. The treatment should be directed to the alleviation of pain. The removal of the organ is scarcely justifiable, since metastasis will in great probability have occurred before the character of the disease can be recognized.

Sarcoma of the kidney is a rare form of disease, and this is especially true of primary sarcoma. The presence of this neoplasm, dangerous in any portion of the economy, is especially so in the kidney, where its deep location renders an early diagnosis almost impossible.

Adenoma, *lymphadenoma*, and *papilloma* may also be found in this organ. Adenoma and papilloma can scarcely be recognized. The same may be said of lymphadenoma, as far as the kidney proper is concerned, for it can scarcely be recognized during life, the diagnosis depending upon the general condition of lymphadenoma and leucæmia. *Angiomata* of the cavernous variety has been noted in the kidney in rare instances. *Rhabdomyoma* of the kidney, an unusual form of neoplasm, which has lately been described, may be also mentioned here. It is supposed to be congenital, and is composed of striped muscle-tissue.

Suppression of Urine.—Not infrequently after a surgical operation, especially upon the rectum and genito-urinary organs, the function of the kidneys is partially or completely suspended. Suppression may also follow an injury to any portion of the body, or any violent emotion. It may occur in patients with healthy kidneys, but is especially apt to be

met with in individuals who suffer from acute or chronic nephritis. It is always fraught with great danger, demanding immediate relief, in the hope either of restoring the function of these organs at once, or of inducing a compensatory elimination of urea and the products of tissue-waste by the skin and mucous surfaces.

The *symptoms* are unnatural dryness and heat of the skin; high febrile movement; quick, distended pulse; at times, headache; pain in the lumbar region; delirium, coma, and convulsions. These graver symptoms are usually observed in the latter stages of complete suppression. If not relieved, the exhalations from the skin and air-passages have the odor of urine. Lastly, though not least in importance in diagnosis, is the absence of urine determined by catheterization.

In all surgical operations the condition of the kidneys can not be too closely studied or too carefully watched. While nephritis, pyelitis, or any kidney lesion should not deter the surgeon from a necessary operation, it should render his prognosis more guarded, and thus relieve him in great part from the responsibility of failure.

The immediate indication in the *treatment* of suppression is chiefly to excite diaphoresis. Opium is a valuable remedy, for it not only relieves pain, which is at times intense, but excites perspiration. The steam-bath is also very useful, and should be given in the recumbent posture. A ready method is to generate the vapor in a tea-kettle and lead the steam under the bedclothes by a piece of tubing. Or hot water may be poured into a large vessel placed under the blanket which is next to the patient.

Next to diaphoresis, mild purgation is advisable, although it should not be carried to the extent of exhaustion. The cautious employment of the muriate of pilocarpin is justifiable in extreme cases. The depressing effect of this drug upon the heart should not be overlooked. The dose should not be more than one twelfth of a grain, hypodermically, and repeated in half an hour if necessary. The hot-bath should be administered at the same time. If there are no symptoms of acute nephritis, and if the kidneys do not resume their function within a few hours, diuretics should be given. A decoction of scoparius, or extract of buchu, will be found useful.

Operation for exploring the Kidney and for its Removal.—When the kidney becomes the seat of any disease which is progressive, and which, in the opinion of the surgeon, will immediately or remotely endanger the life of the patient, operative interference is indicated.

Exploration with the Aspirator-Needle.—In operations upon these organs the following anatomical points should be borne in mind: By reason of the large size of the liver, the right kidney occupies a position about one inch lower than the left; anteriorly it is partially overlapped by this organ; its lower end is a little below the level of the umbilicus; the ascending colon is in front. The left kidney has in front of it the descending colon; the spleen at times may overlap its upper end; its lower end is a little above the level of the umbilicus.

In exploring a diseased kidney percussion will serve to locate the colon so that it may be avoided. If fluctuation is present, the point at

which it is most superficial should be selected for puncture. In general, the organ will be reached most safely three and a half inches from the spines of the vertebræ.

If an exploratory aspiration demonstrates the presence of fluid (other than blood), an incision should follow, for the reason that the escape of liquid into the retroperitoneal space, or into the peritonæum, is a danger to be avoided by incision and drainage through the lumbar region.

Nephrotomy is performed by making an incision from the last rib to near the iliac crest, parallel to and three and a half inches from the vertebral spines. Dividing the integument, fasciæ, and fat, the edge of the quadratus lumborum is sought, and the aponeurotic extension of the transversalis muscle divided, when the finger can be passed into the retroperitoneal space behind the colon and directly upon the kidney. All hæmorrhage should be arrested as it occurs. By drawing the edges of the wound wide apart with flat retractors, the fatty capsule may be separated with the fingers or handle of the scalpel, and the exact condition of the organ determined. If an abscess be discovered, or any lesion demanding incision and drainage, this should be done.

If the pelvis is blocked with stone, or if there is a calculus in the kidney, which may be determined by digital exploration, it should be removed by incision. The operation is known as nephrolithotomy. The incision should be left open and drained. When the kidney has suffered displacement, and is causing distress by dragging upon its vessels, if it is otherwise normal it should be carried as nearly into its former position as possible and its capsule stitched to the edges of the wound through the abdominal walls. Catgut sutures of large size should be used, and these passed well into the fatty capsule which surrounds this organ. The fibrous capsule proper of the kidney should not be perforated by the needle. The patient must be kept in the dorsal decubitus until adhesions have been formed sufficient to hold the organ in place.

Nephrectomy, or removal of the kidney, has been successfully performed so often of late years that its advisability in certain diseases of this organ is unquestioned. Before undertaking this operation the precaution should be observed of determining not only the presence of a second organ, but its condition. A fatal result has followed the removal of a single or "horse-shoe" kidney. It is equally important to determine, if possible, whether the opposite organ is capable of carrying on the necessary excretion of urine. The presence of a second organ may be made out by palpation. That it is performing its function satisfactorily may be determined by a quantitative and qualitative analysis of the urine discharged. The quantity of the fluid and urea eliminated should approximate the normal. If albumen is present, and there is no pus in the urine, the gravity of the prognosis is increased. Any symptoms of uræmia should contraindicate the operation.

The organ is reached by the same incision given for nephrotomy. When necessary to secure the vessels at the hilus, the wound may be enlarged by a limited transverse incision. All bleeding should be arrested as it occurs. When the fatty capsule is reached, it should be

scratched through with the finger-nail, or torn between two forceps. As soon as the hilus is exposed, the vessels should be tied with double-strong silk threads, divided between the ligatures, and the organ removed. When the organ is greatly enlarged, it will be advisable to throw a temporary elastic ligature around the entire pedicle, remove the kidney and then secure the vessels separately. The wound should be irrigated with sublimate solution, drainage-tubes inserted, and an antiseptic dressing applied.

In nephrectomy for displacement of the kidney (*floating kidney*), the operation should be made through the abdominal wall directly over the recognized position of the organ. The intestines should be displaced laterally and the posterior layer of the peritonæum torn open just enough to permit the removal of this mass. When the displaced organ is not diseased, and is near its original position, an effort should be made to secure it in its proper place by stitching the capsule to the lumbar fascia with catgut sutures.

The Ureters.—The diseases which affect the ureters do not demand especial consideration. The inflammatory processes are those which extend downward from the pelvis of the kidney or upward from the bladder. The same may be said of neoplasms. Partial or complete occlusion from pressure within the canal, as from a migrating or impacted calculus, or by pressure from a tumor from without (as by an aneurism or neoplasm), may demand surgical interference.

Bladder.—Among the *congenital* lesions of the bladder to which the attention of the surgeon is called, *exstrophy* is most frequently observed. More rarely there are several sacs, each with a ureter, or there may be a central septum dividing the bladder into two chambers of about equal size, with a ureter emptying into each. The bladder is at times absent, the ureters opening into the alimentary canal, vagina, or perinæum, or into the pelvis, at a point corresponding to the normal position of the bladder.

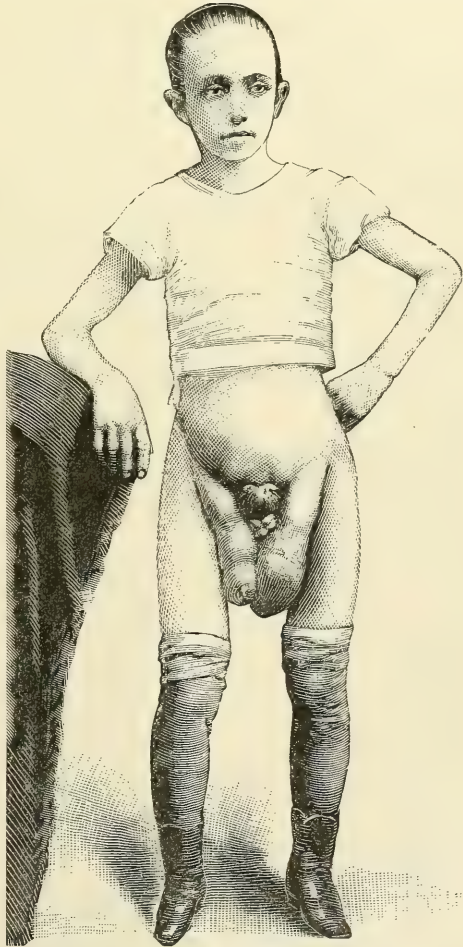


FIG. 564.
Exstrophy of the bladder. So-called hermaphrodite.

Exstrophy, or eversion of the bladder (Fig. 564), is almost always met with in males. It is caused by a failure of development in the anterior pelvic and abdominal regions. The integument, muscles, pubic bones, and anterior part of the bladder-wall are missing. Through this gap the part of the bladder which may be present is protruded, as a mass of variable size (depending upon the extent of the deformity and upon the position of the patient), from one inch up to three or four inches in diameter. In the erect posture it is always largest, being pushed out by the descent of the abdominal viscera, and complicated by hernia of the intestine. The mucous membrane, which covers the mass, is in appearance not unlike a recent non-strangulated *prolapsus ani*. The orifices of the ureters may be found opening at some point on the lower portion of the protrusion, and are often considerably dilated. In all cases of exstrophy the genital apparatus is rudimentary. The penis is wholly or in great part wanting. The urethra may be seen as a simple groove, into which the seminal ducts enter. The scrotum, at times entirely absent, may in other cases be present, lodging the testicles, or it may be blind, with one organ in each sac, or entirely missing, the testes remaining in the abdomen, or lodged in the groin or thigh.

The degree of *exstrophy* varies in proportion to the extent of the malformation. In the more favorable cases the pubic bones are almost united at the symphysis, and the protrusion consequently small.

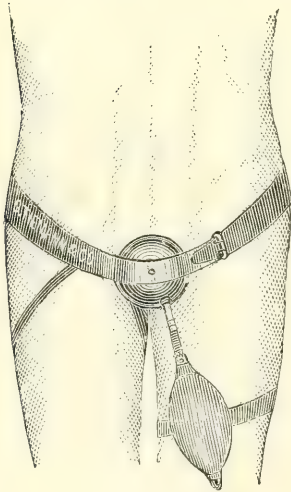


FIG. 564 A.

In females the genital organs are also rudimentary. The clitoris, nymphæ, vagina, and uterus may be absent or displaced, and only partially developed. The general appearances of the tumor are the same in both sexes.

Exstrophy of the bladder, even in a mild form, is a source of great annoyance.

The *treatment* is chiefly palliative, and consists in an apparatus to drain the urine off and prevent excoriations. A suitable instrument is shown in Fig. 564 A. The operative treatment consists in an effort to cover in the protruding mass by integument borrowed from the immediate vicinity of the tumor.

No definite line of procedure can be advised. The skin may be turned from the abdomen, thighs, and perinæum. The operation is not without danger to life, and, when not fatal, frequently fails to benefit the patient. The chief difficulty lies in protecting the flaps from contact with the urine. To obviate this, the procedure of Levis more nearly meets the indications. It consists in establishing a false urethra from that portion of the partly developed bladder near the orifices of the ureters through to the perinæum.

A large and long needle, armed with a good-sized thread or wire, is carried through the wall of the bladder, just at the openings of the ureters, and brought out in the perinæum, about an inch in front of the

anus. The wire is allowed to remain as a seton, and through the fistula thus established the urine begins to flow. The false urethra is enlarged, by gradual dilatation with bougies, until it is of sufficient size to carry off all the urine. When this is accomplished, the second stage of the operation consists in covering the exstrophy with integument turned over from the immediate neighborhood of the deformity. In males, one incision may be carried from near the center of Poupart's ligament, curving downward along the inner side of the thigh, across the scrotum or perinæum, as the case may demand, and terminating at a corresponding point upon the opposite side. This flap is dissected up toward the edges of the exstrophy, leaving a line of attachment sufficient to supply nutrition to it. A second flap is turned down from the abdomen, and the two are sewed together, the raw surfaces being now external, while the epidermis is internal, and in contact with the mucous surface of the deformed bladder. If the penis is sufficiently developed, a hole should be cut in the lower flap and this organ drawn through. The outer raw surface may be left alone to cicatrize, although it should be covered over at a subsequent operation, if there is enough integument left to borrow from. If not, the granulating surface may be covered with grafts.

In females the same method of operation may be used, modifying the flap to suit the deformity, and to preserve as much of the functions of the genital organs as possible.

Hernia Vesicæ, or Cystocele.—Hernia of the bladder is a very rare accident. It is more apt to occur in connection with a perforating wound of the pelvis or supra-pubic region. Idiopathic cystocele occurs chiefly in the aged, and in those who have atony of the walls of this organ from habitual retention of urine, and, at the same time, some form of intestinal hernia. The bladder becomes top-heavy and flabby, and readily prolapses into the patulous inguinal or femoral canal, as the case may be.

The *diagnosis* is evident if the tumor diminishes with the evacuation of the organ by catheterization, and becomes distended by injection through the urethra. If it should become strangulated, aspiration with the finest needle, and microscopic examination of the fluid withdrawn, will confirm the diagnosis of cystocele.

Treatment.—Hernia of the bladder should be reduced by taxis, and prevented from recurrence by a truss. If it should become strangulated, and gangrene occur, an incision should be made, and the wound treated antiseptically. A fistula resulting from this practice will close by granulation, or can be cured by a subsequent operation.

Wounds.—A solution of continuity in the walls of the bladder may be caused by penetration from without, as in the case of a shot- or stab-wound, by rupture from over-distention, by violent concussion, or by direct injury from displaced fragments of bone in fractures of the pelvis. Penetrating wounds of the bladder are rare, not only on account of the protection afforded by the pelvic bones, but because its usual condition is that of only partial distention. This is especially true of wounds received in military practice, since soldiers going into action almost invariably empty this organ.

The *diagnosis* of a penetrating wound of the bladder depends upon the escape of urine through the opening, or the sudden appearance of blood or particles of clothing, or other foreign matter, in the urine. Shock is usually profound. Hæmorrhage is not severe, unless some of the iliac arteries or their larger branches are involved.

The *prognosis* is always grave, though not necessarily fatal. The immediate danger is from hæmorrhage and shock. Peritonitis is inevitable if the wound is above the attachment of this membrane to the bladder. If below this line, the infiltration will lead to pelvic cellulitis.

The indications in *treatment* are to arrest hæmorrhage, and to prevent infiltration and sepsis by free incision and drainage. When the large vessels of the pelvis are wounded, an effort should be made to arrest the bleeding by compression and the ligature.

If extravasation of urine into the cavity of the peritonæum has taken place, the abdomen should be opened and thoroughly irrigated with warm Thiersch's solution. If this is not convenient, warm sublimate solution, 1 to 20000, may be employed, or warm water. The entire cavity should be filled with the fluid, and should afterward be thoroughly dried out with clean, soft sponges. In a case which came under my observation, the bladder was wounded at its summit, and urine escaped freely into the cavity of the peritonæum. The abdomen was flooded with 1-to-20000 sublimate solution, and carefully sponged out. The patient recovered without a symptom of peritonitis. In this case the edges of the incision in the linea alba were held open by retractors, and the warm solution poured in from a pitcher.

If the wound in the bladder is small, and is so situated that its edges can be stitched together, it should be closed at once by fine silk or catgut suture, as directed in supra-pubic cystotomy. Under other conditions the T rubber drainage-tube should be introduced through the wound into the bladder, and the patient placed in the lateral position to facilitate drainage. It is of vital importance that the urine be not allowed to collect and distend the bladder, and thus cause infiltration.

When the opening into the bladder is intra-peritoneal, if the wound can be thoroughly closed by sutures this should be done at once, and, in order to secure the immediate evacuation of all urine, a soft catheter should be fastened in through the urethra, or, better still, through the free wound of a *perineal cystotomy*. If the opening can not be safely closed, the edges of the wound in the bladder should be securely stitched by silk sutures to the margins of the wound in the integument of the abdominal walls, and the thorough emptying of the organ insured as above.

Rupture of the Bladder.—This accident is much more frequent with men than women. When occurring in females it is usually during parturition, or from continuous pressure of this organ by uterine or ovarian tumors. Obstruction of the urethra is the chief cause of idiopathic rupture. In enlarged prostate, or close stricture of long stand-

ing, the bladder becomes gradually accustomed to the presence of an abnormal quantity of urine, its walls become thin and weak under the process of dilatation, until, after a sudden excessive accumulation, rupture occurs. In rare instances the bladder-wall is weakened by ulceration to such an extent that it gives way. Rupture of a diseased or normal bladder may follow a violent concussion, especially if the organ be fully or partially distended, and the blow inflicted over the lower abdominal region. Fracture of the pelvis is not infrequently complicated with this grave accident. Fragments of bone may be driven through the walls of the bladder, or the rupture may occur from compression alone.

The location of the rupture is, fortunately, in the majority of cases, through portions of the organ not covered by peritonæum. The anterior-inferior or sub-pubic portion and the neighborhood of the trigonum vesicæ are most apt to give way.

The *symptoms* of rupture are not always prominent. When violence may be eliminated, there is usually a history of over-distention, a desire to urinate, a feeling as if something had given way, with partial or complete relief from the pressure within the bladder.

When the rupture is extra-peritoneal, the signs of infiltration in the perinæum and perirectal tissues are easily recognized. Direct external palpation, or the introduction of the finger into the rectum, will recognize the doughy condition of the tissues. If the hypodermic needle is introduced, a few drops of bloody urine may be withdrawn. When the rupture is so situated that urine escapes into the peritoneal cavity, the earlier signs are shock, of a severe type, with dullness on percussion in the hypogastric and inguinal regions. In confirming a *diagnosis* based upon any of the foregoing symptoms, an examination of the bladder by the sound or catheter is essential. The passage of this instrument through an opening, so that it may be felt beneath the abdominal walls, is a demonstration of rupture. The passage of a small amount of bloody urine, with or without the catheter, is a suspicious sign, and if this small quantity is passed with each respiratory act the evidence is almost convincing. The

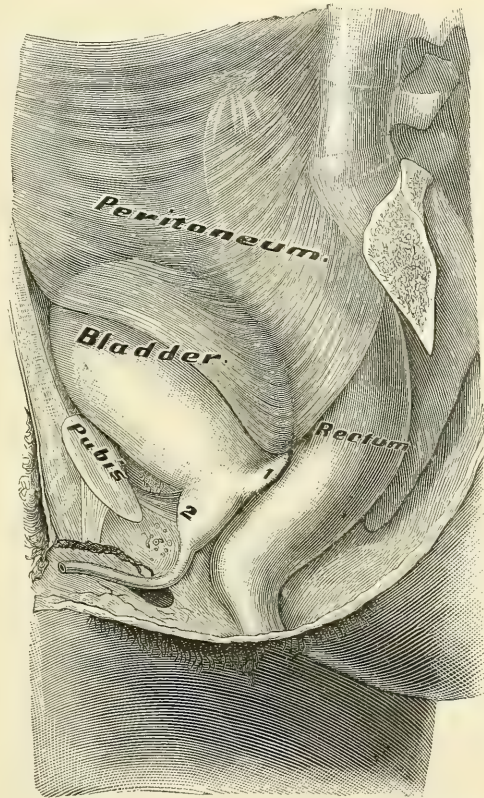


FIG. 565.—The relations of the peritonæum to the bladder when distended. (After Tarnier.) 1, The situation of the trigonum vesicæ. 2, Prostatic urethra.

exploration of the pelvic region with the aspirator-needle will determine the presence of urine in the tissues outside of the bladder.

Treatment.—In extra-peritoneal rupture immediate and free incision should be made into the infiltrated zone, and, while this is being done under ether, the bladder should be incised as in lateral lithotomy, or by the supra-pubic method, as may be indicated. The free escape of urine through this incision arrests infiltration and keeps the bladder in repose, thus facilitating a closure of the rupture.

The treatment of rupture of the bladder into the cavity of the peritonæum has just been given in penetrating wounds of this organ.

The comparatively slight risk involved in an exploratory incision through the linea alba into the cavity of the peritonæum should encourage the surgeon, even in cases in which there may be some doubt as to the correctness of the diagnosis, to perform this operation. The knowledge that death has so far resulted in every case of intra-peritoneal rupture of the bladder in which surgical interference has not been made, adds an additional justification to the exploration of this cavity.

Cystitis.—Inflammation of the bladder is one of the most common surgical diseases. It may be acute or chronic. In the majority of instances only the mucous membrane of the neck and floor of this organ is affected. Less frequently the entire mucous lining is attacked. In extreme cases the inflammation attacks the muscular walls, and spreads to the peritonæum and pelvic fascia. An *acute* cystitis ending in rapid recovery rarely leads to hypertrophy or thickening of the walls of the bladder. In *chronic* cystitis thickening is the rule. Hypertrophy of the bladder may be *true* or *false*. In true hypertrophy the thickening is caused by an increase of the muscular elements of the organ; in false hypertrophy it is due to new-formed connective tissue, which has in great part taken the place of the muscular fibers. When the walls are thickened and the cavity is smaller than normal, the hypertrophy is called *concentric*; when the cavity is increased and the walls thickened, *eccentric*.

Cystitis may be caused by a blow upon the lower portion of the abdomen, or in the perineal or ischio-rectal region, or by the direct contact of an instrument or any liquid or solid substance carried into the cavity of the bladder. Inflammation of this organ always exists with calculus, and almost always with chronic hypertrophy of the prostate. It may become involved by extension of an inflammatory process from the urethra or prostate, from the vagina, the kidneys, or ureters. Certain abnormal conditions of the urine, excessive indulgence in drinking or eating, the pressure of another organ or a neoplasm, or the presence of a new formation or parasites within the cavity or in the walls of this viscus (*Bilharzia hæmatobia*), etc., may also produce cystitis. To these various causes may be added stricture of the urethra or the prolonged retention of urine.

Symptoms and Diagnosis.—Pain, and a desire to urinate frequently, are the earliest signs of acute cystitis. The character of the pain is burning as felt in the bladder and deep urethra, and lancinating as re-

ferred to the meatus. It often increases with the close of the effort at urination, developing into marked tenesmus as the last few drops are forced out. It is exaggerated by direct pressure upon the abdomen, in the perinæum, rectum, or vagina.

The febrile movement varies with the severity of the disease. A well-marked chill or a succession of rigors may occur with the rise in temperature and be present at various times in the progress of the disease. Microscopical examination of the urine will reveal the presence of epithelia and pus-corpuscles in varying quantity. The urine is usually alkaline, and, aside from all diseases of the kidneys, will contain a certain proportion of albumen, which is always found when this fluid is mixed with pus. In severe and unusual cases, shreds of bladder-tissue may be voided with the urine.

Treatment.—Rest in bed, and in that position which gives the fullest sense of comfort to the patient, is essential. When the inflammation is confined to the neck and anterior portion of the floor of the bladder, it is advisable to elevate the foot of the bed from four to six inches, and to place a pillow under the patient's hips. By these means the intestines and other organs are carried by gravity away from the diseased viscus, and at the same time the urine is to some extent distributed over a wider and less inflamed surface.

Morphine is invaluable in the alleviation of pain and the enforcement of quiet. Hot or cold applications—as found most agreeable to the patient—are useful. The free administration of Vichy water, or citrate of potash (grs. x-xx) at frequent intervals, is advisable. The rectum should be thoroughly emptied every day by a cold water enema.

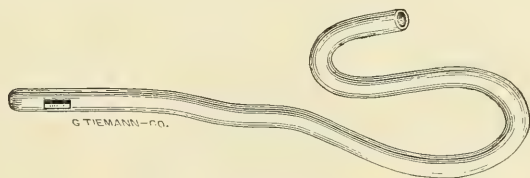


FIG. 566.—Nélaton's catheter.

In chronic cystitis the treatment must be directed to the cause of the disease. Unfortunately, it is too often incurable, and then only palliative measures may be adopted. In paralysis or atony of the muscular walls, or in the enlarged prostate of old men, retention may be relieved




FIG. 567.—Velvet-eyed gum catheters, curved and straight.

by the employment of the soft catheter, and the condition of the organ improved by irrigation. When it is desired simply to empty the blad-

der without washing it out afterward, the soft-rubber catheter of Nélaton (Fig. 566) should be introduced. An instrument of good size—Nos. 12 to 14 U. S. scale—with a perfectly smooth point, should be selected. It should be thoroughly warmed and oiled, and introduced with the patient resting on the back. It should not pass beyond the neck of the bladder. When it is desired to irrigate the bladder, the double-current soft catheter (Fig. 568) should be used. A warm solution of boracic

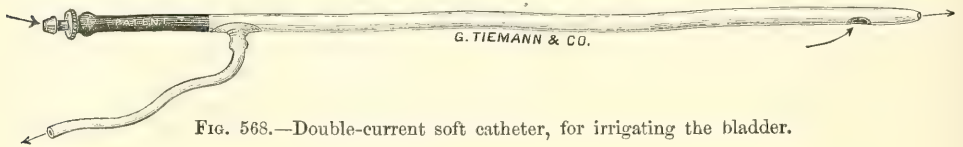


FIG. 568.—Double-current soft catheter, for irrigating the bladder.

acid (grs. $x-3j$ of water) is an excellent remedy. From one to two pints are poured into a fountain-syringe, and a small quantity is allowed to run out at the end of the tube to drive out the air. The catheter is next introduced down to the constrictor urethræ muscle, when the tube from the syringe should be connected with the larger end of the catheter and a small quantity of water allowed to run in until it fills the instrument and flows out at the smaller tube. By this manœuvre the air is completely expelled, and the catheter should immediately be pushed into the bladder. The mechanism of this apparatus is such that it permits a constant and steady current of water to flow in and out of the organ without over-distention. As soon as the fluid comes out perfectly clear, the operation should cease. It may be repeated every day, and oftener when necessary. If the double catheter can not be obtained, an ordinary single instrument will suffice; but the exclusion of air is more difficult. Chronic cystitis due to stone in the bladder, pressure of other organs or a tumor, and stricture of the urethra, etc., will, as a rule, disappear with the cure of these various lesions.

In cases which resist all conservative measures, incision and drainage by the supra-pubic method or through the perinæum, as in the median or lateral operations for stone, will be justifiable. These operations will be given with affections of the prostate.

Paralysis of the bladder may be partial or complete. It may be caused by violence inflicted directly to the organ or in its immediate neighborhood, by pathological changes in its muscular tissue, or by traumatic or idiopathic lesions of the cerebro-spinal axis; or it may occur under the influence of certain emotions in which no lesion is recognizable.

A blow upon the hypogastric region has been known to cause temporary paralysis of the bladder. The unskillful introduction of an instrument, and the prolonged over-distention of the organ which is common in prostatic hypertrophy, will induce the same condition. An operation upon the genito-urinary apparatus is almost always followed by temporary paresis of this organ. Operations upon other portions of the economy under prolonged ether or chloroform narcosis are also frequently followed by loss of function in the bladder. The pressure of

parturition may produce a like result. Severe concussion of the brain or cord, compression of one or both of these ganglia from fracture or displacement of their bony envelopes, hæmorrhage, aneurism or the presence of neoplasms and various pathological changes in the meninges and in the gray and white matter of the cord and brain, will lead to paralysis of the bladder, varying in duration with the severity of the lesion.

In the *treatment* of this affection the first indication is to prevent prolonged distention of the organ by catheterization, which should be repeated at least twice in twenty-four hours. If a catheter can not be introduced, supra-pubic aspiration should be practiced. Cystitis may be avoided if the urine is carefully and regularly drawn off. Attention should next be directed to the removal of the cause of the paralysis.

Retention.—As just stated, paralysis of the muscular walls of the bladder is a cause of retention of urine. Lesions of the sensory nerves of this organ also induce retention, which is proportionate to the loss of sensibility. The chief cause of this condition, however, is some form of obstruction at the neck of the bladder or in the urethra. As will be seen in treating of hypertrophy of the prostate, this is a frequent cause of retention. Organic stricture, spasm of the constrictor urethræ (or “cut-off”) muscle, and mechanical occlusion of the urethra, are also common causes of this affection.

Diagnosis.—Distention of the bladder may be determined by palpation, percussion, and exploration. In this condition it rises well above the level of the symphysis pubis, at times as high as the umbilicus, and causes tension of the recti muscles or protrusion of the abdomen. By direct pressure, the desire on the part of the patient to urinate may usually be increased, and, if the abdominal walls are thin, the spherical character of the organ may be recognized. Upon percussion, dullness is present and fluctuation may be appreciable.

In *suppression* of urine all of these symptoms are absent, the skin is usually hot and dry, the pulse rapid and full, and the temperature is

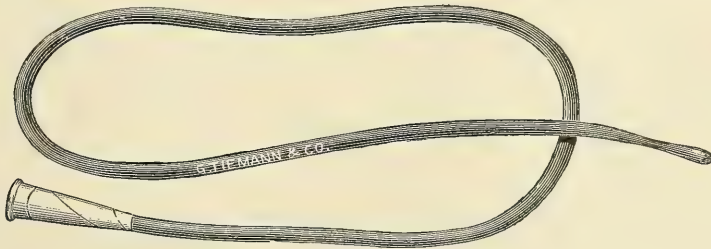


FIG. 569.—Filiform catheter.

several degrees above the normal. The introduction of a catheter or puncture of the bladder with a small-sized aspirator-needle, just at the upper level of the symphysis, will determine the diagnosis.

In *treatment*, the evacuation of the contents of the organ is the immediate indication. The patient should be put to bed and given the

benefit of a full dose of opium. This agent is useful in alleviating pain, in securing relaxation of the muscular elements of the urethra and prostate, and—by producing diaphoresis—in diverting fluids from the kidneys to the excretory apparatus of the skin. A soft-rubber (Nélaton) catheter should be preferred; but, if this can not be introduced, a firmer, olive-pointed instrument (Fig. 571) should be employed. The silk-woven and gummed catheter (Figs. 572 and 573) is also a useful instrument, and if, on account of its elasticity, it can not be introduced, the stylet of Prof. Keyes (Fig. 574) should be inserted into the catheter to give it the required stiffness. The



FIG. 570.—Black French catheter, blunt-pointed.




FIG. 571.—Black French catheter, olive-pointed.



FIG. 572.—Gummed silk-woven catheter.



FIG. 573.—Gummed silk-woven bougie.




FIG. 574.—Dr. Keyes's wire stylet.

metal catheter (Fig. 575), if properly constructed and carefully introduced, can be made to safely overcome any ordinary resistance. It should be of heavy silver, strong, perfectly smooth, and should have a curve corresponding to that of the normal urethra. In size it should correspond to No. 10, 12, or 14, U. S., and the larger sizes should be preferred.

The introduction of a metal catheter or sound through the normal urethra into the bladder is accomplished as follows: The patient is placed upon the back with the lower extremities parallel with the body. If m xx of a 4-per-cent solution of cocaine hydrochlorate are introduced,




FIG. 575.—Strong silver catheter.

the normal sensibility will be lost as far back as the compressor muscle. The catheter is placed in water at a temperature of about 105° to 110° F., and, when warmed through, is lubricated with sweet-oil or vaseline. If the operator is right-handed, it is best to stand on the left side of and facing the patient. The penis is seized with the left hand and held steady while the end of the catheter is carried into the meatus. At this stage of the procedure the shaft of the sound is parallel with Poupart's ligament, and, as soon as the first four inches have

passed into the urethra, while it still descends, the handle is gradually brought toward the median line. The point is now engaged in the bulb, or at the anterior layer of the triangular ligament, and the shaft is about perpendicular to the plane of the abdomen. Without exercising any force to push the instrument in the direction of the bladder, the handle is slowly and steadily carried downward until the shaft is parallel with the anterior surface of the thighs. While this manœuvre is being effected, the point is tilted from the floor of the bulb into the membranous portion which offers the greatest resistance, not only because it is the narrowest part of the canal, but because the compressor-urethræ muscle must be overcome. All the time that the instrument is being pushed toward the bladder the penis should be pulled over the catheter, for in this way the lining membrane is put upon the stretch and the introduction greatly facilitated. When the neck of the bladder is reached, the instrument will usually have penetrated a distance of eight or nine inches. It should be borne in mind that even a silver catheter is capable of doing great damage to the urethra if improper force is employed in its introduction. There is usually no resistance except by the compressor muscle, and this is only spasmodic. If the point of the instrument is kept well against the obstruction by depressing the handle between the

thighs, it will slip by with the first relaxation of this muscle. The methods of introducing an instrument into the bladder in abnormal conditions of the urethra and prostate will be given later.

If it is found impossible to reach the bladder by the urethra, the urine should be evacuated by the aspirator. The apparatus shown in Fig. 576 will give general satisfaction. The needle and entire instrument should be carefully cleansed and disinfected in 1-to-20 carbolic-acid solution, both before and after it is used. The smallest needle will suffice. If its introduction is preceded by a small hypodermic syringe-needle, and $\text{m} \times \text{xx}$ of 4-per-cent cocaine are injected, the operation will be painless. The pubes being shaved and disinfected, and everything in readiness, the needle is filled with the carbolic-acid solution and closed by turning the cock

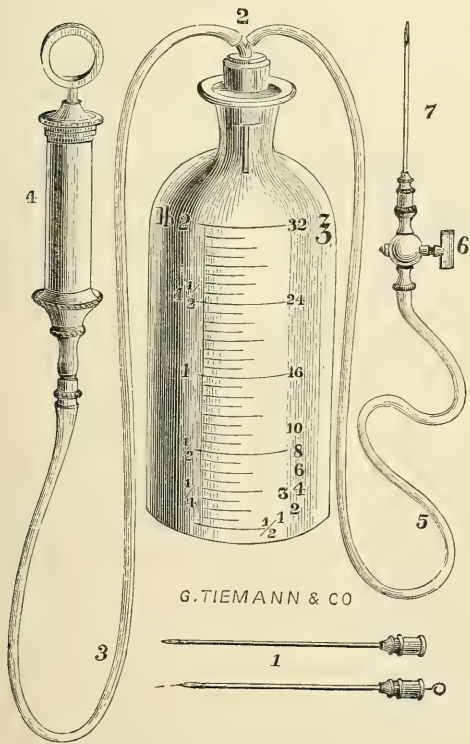


FIG. 576.—Tiemann & Co.'s aspirator.

(6, Fig. 576); the air is exhausted from the receiver (2) by working the pump (4). The patient should be placed in the sitting posture,

and the needle introduced a half-inch above the symphysis and pushed directly backward a distance of two inches. The cock is now opened, and the urine flows into the bottle. If it becomes necessary to empty the receiver, the stop-cock should be turned, to prevent the entrance of air into the bladder.

When the character of the obstruction or disease is such that a permanent urinary fistula is necessary, this may be made through the perinæum or directly from the anterior wall of the rectum into the base of the bladder. Of the two procedures, the former is preferable.

The incision is the same as for lateral lithotomy. To prevent the wound from closing, a soft catheter should be carried through the incision into the bladder and allowed to remain for several weeks. The self-retaining instrument shown in Fig. 577 will give the best satisfaction.



FIG. 577.—Holt's self-retaining catheter.

The fistula will become permanent as soon as its walls are covered with epithelia. Although the annoyance from this condition of incontinence is great, it is preferable to a vesico-rectal fistula, where the irritation of the bowel is the cause of much discomfort and prostration.

The recto-vesical operation is performed in this way: While the bladder is distended, the finger of the left hand is oiled and introduced into the rectum until the tip passes above the prostate. A trocar and canula (Fig. 578) is guided along the finger to a point just beyond the

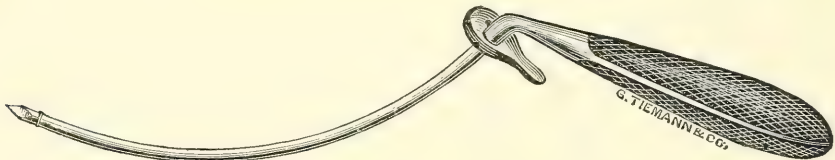


FIG. 578.—Buck's rectum trocar.

prostate, where it is turned directly upward and forced through the floor of the bladder. The trocar is withdrawn and the urine allowed to escape. If this opening is not sufficient to allow of the satisfactory drainage of the bladder, it may be enlarged.

Incontinence of Urine.—Incontinence of urine occurs when the compressor urethrae and the muscular elements of the prostate are paralyzed. It is present in a proportion of cases of prolonged over-distention of the bladder, the pressure from behind overcoming the normal resistance of these muscles. Irritation of the bladder from any cause may produce tenesmus of this organ, and consequent inability to retain the urine. This is especially apt to occur in children during sleep, in the earlier hours of morning, when the bladder is full.

Women are more frequently affected with incontinence than men, which fact is explained not only in the better tone of the muscular system in males, but in the absence of the prostatic muscle in females, which, according to Henle, is of great aid in holding the urethra closed. The general relaxation of the pelvic muscles as a result of parturition may also account for the more frequent occurrence of incontinence of urine in women.

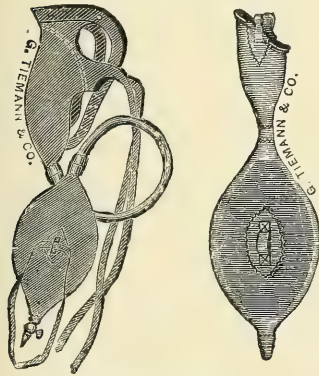


FIG. 579.—Female and male urinals, for incontinence.

The palliative treatment consists in applying a urinal for the reception of the water as it dribbles away (Fig. 579).

Curative measures should be directed to a removal of the cause of incontinence. These will be given with the various lesions of which it is a symptom. In the nocturnal incontinence of children the habit may be corrected by causing the patient to be awakened and the bladder emptied once or twice during the night.

Dr. H. Marion-Sims reported to the New York Obstetrical Society a number of distressing cases of incontinence of urine in adult females. These cases were cured by gradual and frequently repeated distention of the bladder. His method was to introduce, by means of a Davidson syringe through a catheter, cold or tepid water beginning with \bar{z} j, holding this in for some minutes and then allowing it to be evacuated. The next day an ounce and a half was employed, and this was continued until one pint or more was easily contained. In this manner tolerance was established and a cure effected.

NEW FORMATIONS AND TUMORS OF THE BLADDER.

Papillomata, or "villous growths," are among the more frequent neoplasms of this organ. They are located usually upon the floor and lower portions of the lining membrane. There may be one or more. As many as forty of these neoplasms have been removed from a single bladder. Microscopically, they are composed of a series of vascular loops or network, covered with epithelia of the same type as the normal cells of the mucous membrane, only of more luxuriant growth.

The *symptoms* which present themselves in the earlier stages of the development of vesical papilloma are obscure. When a single tumor exists, and is not of rapid growth, the bladder may become tolerant of its presence. Under other conditions, symptoms of irritation, frequent micturition, and tenesmus may be present. If the growth be situated near the outlet of the bladder, it may interfere with the escape of urine. Hæmaturia is of frequent occurrence in connection with this variety of tumor, and is due to rupture of the capillaries from ulceration caused by the action of the urine upon the tufts. An exacerbation of hæmorrhage is apt to follow the introduction of the sound. An examination of the

urine may demonstrate the presence of particles of the papillomatous tissue. If a sound be introduced while the bladder is fairly distended, so as to efface the folds into which the mucous membrane is thrown when the organ is contracted, the presence of the tumor may be recognized by the resistance offered as the convexity of the sound is swept along the floor and sides of the organ.

The employment of the *cystoscope* will be of value in determining the presence and location of a neoplasm or foreign body. In using this instrument, the bladder should be washed out thoroughly and then injected with a warm clear saline solution (about eight ounces).

The *treatment* is to open into the bladder, by the supra-pubic method, and remove the growths with the forceps, or scrape them off with Volkmann's spoon, guided by the finger. A medium-size Spencer Wells fenestrated ovarian sac forceps I have found very useful in twisting off tumors of the bladder. The details of the operation are given with supra-pubic cystotomy for stone.

Fibroma and *myxoma* of the bladder may be considered as next in order of frequency. They belong to the connective-tissue type of new formations, are less vascular, and of slower development, although at times they attain considerable size. The base of the organ is the usual location of the tumor. The symptoms are about the same as those in papilloma, excepting hæmorrhage. The *diagnosis* will depend upon the appreciation of the growth by the sound, or by rectal palpation with the sound in the bladder. If the character of the lesion can not be accurately determined, and the symptoms of irritation are present, a perineal exploratory incision may be made. The treatment consists in the removal of the mass by the operation just given.

Other forms of benign tumors of the bladder are so rare as scarcely to deserve mention. Among the new formations myoma is occasionally found, while of the tumors hydatid cysts are sometimes met with. These formations are amenable to the same rules of treatment as above laid down.

Of the malignant diseases of this organ, *sarcoma* is extremely rare; while of the *carcinomata*, the epithelial variety is by far the most frequent. Scirrhus may, however, originate here. The symptoms differ only in degree in the malignant as compared with the benign tumors just described. The gradual development of the cachexia, which is a part of cancer, may alone lead to a positive diagnosis. Exploration with the sound and rectal examination may determine the suspicious character of the disease by the extent of the infiltration in the tissues around the bladder.

Operative interference is rarely justifiable, for the reason that the disease is almost of necessity so far advanced before it is recognized that a thorough removal is impossible.

The Urine—Quantity.—The average quantity of urine excreted by the kidneys of the normal adult is about fifty-six ounces in twenty-four hours. This quantity varies with the amount of fluids ingested, the ac-

tivity of the sweat-glands, and the elimination of liquids by the alimentary canal.

It is of an amber- or straw-color, which is due to the presence of indican and urobiline. The greater the quantity, as a rule, the lighter the color. It is dark in proportion to the intensity of the destructive changes in tissue, as in prolonged exertion, or during the progress of fevers. Carbohc acid and bile turn the urine brown or greenish-black, and blood (hæmaturia) gives it its characteristic tinge. The normal odor of urine is peculiar to itself. An artificial aroma is easily substituted by the ingestion of certain foods and drinks, as gaultheria, turpentine, asparagus, etc.

Reaction.—Healthy fresh urine is acid in reaction, changing litmus from blue to the faintest red or rose color. Acid urine will at times become alkaline within a few minutes after its discharge. The ingestion of alkaline substances in vegetable foods gives a neutral or alkaline character to the urine passed within a short time after eating. The same is true of the alkaline salts, potash, soda, etc. Urine, alkaline in reaction as it leaves the urethra—the alkalinity not due to food or medication—is an indication of disease of the bladder or pelvis of the kidney.

Specific Gravity.—The specific gravity varies in the normal condition from 1.005 to 1.030. Usually the increase in quantity is accompanied by a smaller proportion of solids and a consequent lower specific gravity. This is not the case in diabetes, where the quantity is abnormally large, while the urinometer may register as high as 1030–1040.

It becomes a matter of great importance to determine through the chemical and microscopical analysis of the urine the condition of the organs which excrete this fluid and those through which it passes in its way to the exterior. Certain conditions of the kidneys, as in Bright's disease, render the prognosis of a surgical procedure more grave, and may justify a modification of the treatment.

Urea.—Urea is the result of destructive tissue metamorphosis. It is increased by the ingestion of nitrogenized food and by excessive muscular exercise. The average daily quantity excreted by the urine is about four hundred and fifty grains, which, with the estimate of the daily urine at fifty-six ounces, is about gr. j of urea to ʒj of the urine.

Any marked diminution of this proportion indicates failure in the elimination of the products of waste in the tissues and the danger of *uræmia*. The simplest quantitative test, and one sufficiently exact for practical purposes, is the following: To make it, it is required to have Labarraque's solution, metallic mercury, a saturated solution of common salt, and a graduated glass tube, with a capacity of several cubic inches, and of a caliber not so large but that the open end can be readily closed by the thumb.

Fill the tube one third full of mercury; on top of this pour ʒss. of urine, fill the balance of the tube with Labarraque's solution poured in quickly, and as quickly close the end of the tube with the thumb. Invert the tube, carry the end well below the surface of the saturated solution of salt, and then remove the thumb, allowing the mercury to escape.

while the salt water rushes in to take its place. Allow the tube to remain in this position about six hours, or until the bubbling entirely ceases. The volume of gas which rises to the top of the tube represents the proportion of urea in the specimen examined. If a half-drachm is used, every cubic inch of displacement of the liquid within the tube is equal to 0.645 of a grain of urea. Multiplying this by the inches or fractions of an inch of gas will give the quantity of urea in ʒss. of urine.

Albumen.—Albumen in the urine of one in health is exceedingly rare. It is said not to indicate disease if present in small quantity soon after the excessive ingestion of albuminous foods.

In isolated cases its presence is ephemeral. In a case presented before the New York Pathological Society, by Prof. Janeway, albuminuria could be produced at will by increased mental activity. In a condition of repose no trace was discoverable.

Albumen is always present in urine which contains pus, independent of any affection of the kidneys.

It may be recognized by the tests with heat and nitric acid. To employ the heat-test, fill a tube half full of urine, to which, if alkaline or faintly acid in reaction, one or two drops of acetic acid should be added. Hold the tube so that the flame of the spirit-lamp will heat the upper inch of urine. If, just before the boiling-point is reached, a cloudy white film pervades the heated mass, the presence of albumen is demonstrated.

The nitric-acid test is not so reliable as the preceding. When albumen is thought to be demonstrated by its use, the heat-test should be applied to confirm it. Into a small test-tube drop from ʒ x-xx of pure nitric acid. Hold the tube slanting and allow the urine from a glass pipette to run gently down the side until it floats upon the acid. Albumen is indicated by a white or cloudy ring formed in the layer of urine immediately in contact with the acid.

Sugar.—The urine of *diabetes mellitus* has a high specific gravity, is passed in great quantity, and has a characteristic sweet odor. This form of sugar may be recognized by *Trommer's test*, in which an oxide of copper is produced by boiling diabetic urine (grape-sugar) with a solution of potash and copper. Fill a test-tube for one inch with the suspected urine, and add one or two drops of a solution of sulphate of copper—just enough to give the whole a pale-blue tint. Add the potash solution in quantity equal to one half the urine. When sugar is present, a pale-blue hydrated oxide of copper will be thrown down and immediately redissolved. If the mixture is now slowly heated to near the boiling-point, a reddish-brown suboxide of copper will be precipitated.

When a quantitative analysis is desired, the fermentation-test will be found simple and sufficiently accurate for practical use. Fill a wide-mouthed bottle with the urine, and register the specific gravity at the time. Place a small piece of yeast in the urine, and set it aside in a warm place for from twelve to eighteen hours until fermentation has occurred, and again take the specific gravity. The difference in degrees of the uri-

nometer, as registered before and after fermentation, will represent the number of grains of sugar in the ounce of urine.

Pus- and Blood-Corpuscles—Epithelia.—Pus-cells in the urine may come from an inflammation in any portion of the urinary tract, from the kidney to the meatus, or from the communication of a sinus or abscess with the urinary apparatus. Urine containing pus may be acid, alkaline, or neutral in reaction. In acid urine the corpuscles are prominent and easily recognized; when the reaction is alkaline, they are usually destroyed, and appear as ropy or gelatinous strings, more resembling mucus than pus. If the urine is examined immediately after being passed, a few corpuscles may be recognized. When allowed to stand for some minutes, the pus-cells collect in the bottom of the vessel. Examined with the microscope, they are seen to be spherical and faintly granular. On account of the absorption of water, they are swollen and less distinct than pus-cells from a recent abscess. The addition of acetic acid renders the nuclei more distinct. The source of pus found in the urine may frequently be determined from the symptoms present, together with the microscopical appearances of the urine. If with the pus-corpuscles flat, large epithelia are abundant, the inflammatory process is in all probability situated in the bladder where these epithelia belong. In females a larger, flat epithelium from the vagina often finds its way into the urine. The cells from the vagina are more often disposed in drifts or groups than the bladder epithelia. Large spherical or polygonal cells may come from the kidney-tubules or the male urethra. They are about twice the size of a pus-corpuscle. Whether they are derived from the kidney or the urethra may in great part be determined by the presence or absence of urethritis. Conical or ham-shaped cells may come from the pelvis of the kidney, prostate, and glandular apparatus of the urethra. They are usually not so abundant as the other varieties.

Hæmaturia.—Blood in the urine may come from traumatic or idiopathic hæmorrhage into the Malpighian tufts or kidney-tubules; from the pelvis or ureters as a result of calculi or ulceration; from the bladder as a result of instrumentation, calculus, wounds, foreign body, neoplasms, ulceration, parasites, or the hæmorrhagic diathesis; from the prostate or accessory organs and the urethra.

The administration of certain remedies may account for the appearance of blood in the urine. Hæmaturia occurs at times as a symptom of malarial fever, and, in women, as a form of vicarious menstruation.

Blood in the urine may be recognized by its characteristic coagula, by the red or reddish-brown color it imparts to this fluid, the presence of the corpuscles under the microscope, or the fibrinous casts of the tubules of the kidney or ureters. In rare instances the blood-disks are entirely destroyed, and the coloring-matter set free. This condition is apt to occur in ammoniacal urine.

When urine containing blood is boiled, a white or cloudy coagulum is formed, its density depending upon the quantity of blood present.

If bloody urine is allowed to stand without being agitated, the corpuscles settle to the bottom of the vessel, and may be recognized by their red or amber color. Under the microscope they may assume different shapes. In *acid* urine the disks retain their bi-concave conformation for a long time. When the hæmorrhage is slight, they float isolated; if profuse, they may be caught in coagula or collect in rouleaux. If the reaction is feebly acid, or where the corpuscles are submitted for a considerable time to the action of the urine, they lose their bi-concave shape, and become distended, swollen, and spherical. They may be recognized from pus-corpuscles by their smaller size, transparency, and in not containing granular bodies. At times they retain their flat shape and appear with serrated edges.

Blood-casts usually come from the kidney-tubules, and are composed of fibrin in which the red disks are entangled in varying proportion. In some, large clusters or groups of blood-corpuscles are seen, with an occasional epithelial cell from the kidney or urinary passages. When the disks have been completely destroyed, as in the decomposition of the coloring-matter in ammoniacal urine, and the organic elements of the blood are not recognizable with the microscope, the spectroscope may be relied upon to demonstrate the presence of the coloring-matter.

In determining the source of blood in hæmaturia the following points should be considered: When the bleeding is urethral, the first discharge of urine is most deeply colored. A clot of blood preceding or accompanying the discharge of urine indicates urethral hæmorrhage. In males, if spermatozoa are entangled in the coagula, the suspicion of hæmorrhage from the *vasa deferentia* or prostatic apparatus is entitled to consideration, although the fact must not be overlooked that these elements may mingle in the urethra with blood from any part of the urinary passages.

When the bleeding is from the pelvis of the kidney, pain and other symptoms of stone or pyelitis will often precede the hæmaturia. Not infrequently, however, the hæmorrhage is, next to the presence of pus in the urine, the first indication of pyelitis.

In hæmorrhage from the bladder there are often symptoms of cystitis which will point directly to this organ as the source of the bleeding. In differentiating the origin of blood from the kidneys, ureters, and the bladder, the method of Thompson and Van Buren may be resorted to with success. Introduce a soft catheter just within the neck of the bladder, draw off the contained urine, and wash out the organ with clean water. If, during the irrigation, the water which flows away contains blood, the hæmorrhage is from the bladder-walls. If it flows away clear, then empty the bladder, place the finger over the end of the catheter, allow it to remain introduced, and wait until a small quantity of urine has accumulated. This is drawn off, and, if it is bloody, and if the clear water now thrown in comes out unstained, the inference is fair that the bleeding is from the ureters or beyond.

Hæmorrhage from the urethra is rare except from violence, the lodgment of calculi, or from ulceration.

Hæmaturia due to parasitic lodgment in the walls of the bladder is exceedingly rare in this country. In 1883 a young man of white parents—a native of Natal, Africa—came under my care on account of chronic hæmaturia. He was at this time twenty-six years of age, and had had bloody urine at intervals for thirteen years. His health was not seriously impaired. The urine was faintly acid; specific gravity 1.020, with only a trace of albumen, which was readily accounted for by the slight amount of blood. About the middle and toward the last stage of the act of mic-

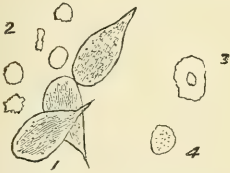

FIG. 580.—1, Ova of *Bilharzia hæmatobia*. 2, Crenated blood-disks. 3, Epithelium. 4, Pus-cell. (From the author's case.)

turition, a few strings of clotted blood were discharged. Placing these under the microscope, I discovered a number of bodies (Fig. 580) shaped much like a watermelon-seed, except that the small end was more pointed. These were evidently the eggs of the parasite known as *Bilharzia hæmatobia*, the hæmaturia resulting from the rupture of capillaries caused by the presence of nests of these ova in the mucous membrane of the bladder. This disease is frequent in Africa and Asia, but almost unknown in North America. The body of the male

parasite is about four lines in length, thread-like, and flattened anteriorly (Aitken); the female a little shorter and more delicate. They inhabit by preference the portal vein and the walls of the bladder. In treating my patient I saturated him with large doses of santonin for a week, and injected the bladder daily with alcohol, beginning with a 1-to-20 solution, and increasing it to the extreme degree of tolerance by the bladder. The patient improved in every respect, but the hæmaturia was not entirely arrested when he returned to Africa in November, 1883, since which time I have not heard from him.

The parent distoma is killed by high febrile movement, and with its death the hæmaturia ceases.

The *treatment* of hæmaturia must be directed to the disease of which it is a symptom. The patient should be required to remain in the recumbent posture. The administration of the fluid extract of ergot, ʒj-ij, is highly recommended without regard to the source of the bleeding. Large doses of citrate of potash will prove beneficial in rendering the urine less irritating. Opium is advisable, not only on account of the relief from pain it affords, but because it secures complete quiet, which is essential, and prevents the too frequent evacuation of the bladder.

When the hæmorrhage is from this organ, and does not yield to the measures above given, the injection of cold or hot water, or of astringent solutions, may be employed. If villous growths are present, they should be removed by cystotomy.

STONE IN THE BLADDER.

Urinary calculi may form in any portion of the kidney, in the pelvis or ureters, in the bladder or urethra. They are concretions of the various inorganic substances which are common to the urine. Organic

particles, such as epithelia, mucus, and various inflammatory products, often enter into the formation of calculi. When an aggregation of the urinary salts occurs within the kidney-tubules, the probabilities are that the stone so formed will remain imprisoned in this organ (renal calculus) until removed by ulceration or operation. Forming in the larger straight tubes of the pyramids, a urinary concretion may, while yet minute, escape into the calix and pelvis, and pass down the ureter into the bladder, or remain lodged in the pelvis or excretory duct.

It is, moreover, probable that the majority of calculi found in the bladder, or passed by the urethra, originate as concretions in the straight tubes, calices, or pelves of the kidneys, whence they drift outward to the bladder, and there by continued accretion become large enough to attract attention, even if the transit along the ureter was unnoticed. Undoubtedly a fair proportion of vesical calculi are formed in this organ proper, and the greater number of these may be grouped in the class of calculi which form around nuclei composed of foreign substances, or animal matter, such as epithelia, inflammatory products, etc. Conversely, it is admitted that animal matter may form the nucleus of a kidney or pelvic concretion, while a bladder calculus may also be formed by accretion of the purely inorganic elements of the urine.

A calculus is rarely of uniform composition, more frequently combining two or more inorganic as well as organic elements in its formation. In the nomenclature it is the practice to give to the stone the name of the preponderating element.

That most commonly observed is composed principally of *uric acid* and the urates. These stones are of fair consistency, yellowish or light-brown in color, not very smooth when single, yet not so rough as oxalate-of-lime concretions. They may attain a diameter of two or three inches. As a rule, they form in urine which is distinctly acid in reaction.

The *mulberry* or oxalate-of-lime calculus is next in order of frequency, and relatively more so in children than in adults. They may exist in all sizes, and vary greatly in color. The smaller concretions are light in color and fairly smooth; the larger are exceedingly rough, with jagged edges, and are dark-brown in color, in rare instances white. Oxalate-of-lime calculi usually commence in the kidney, and pass as small particles to the bladder. The most severe forms of "renal colic" are due to the slow and painful passage of these rougher concretions along the ureters.

Phosphatic calculi come next in order of frequency, and are divisible into three classes: the *ammonio-magnesian* and *phosphate-of-lime* (*fusible*) calculus, *neutral phosphate of lime*, and *ammonio-magnesian* calculus.

Fusible calculi are more often met with than the other two forms of phosphatic concretions. They are gray or white in color, readily friable, and light. The hardness is proportionate to the lime phosphate present. They attain large size, and conform themselves to the shape of the bladder.

The *neutral phosphate-of-lime* calculus is rare. It may form in the kidney, though it originates chiefly in the bladder. All the phosphatic calculi are chiefly vesical in origin, being found with ammoniacal urine, which is present with chronic vesical catarrh. The *ammonio-magnesian* phosphatic concretion is equally rare, and differs very slightly in its chemical and physical characters from that just described.

Other and still rarer forms of urinary concretions are the following :

Cystin.—This variety is usually smooth, occasionally corrugated, yellow in color when fresh, inclining to a greenish hue when long removed. They break readily, do not show a marked concentric arrangement, and are somewhat greasy to the feel.

Xanthic or uric-oxide calculi have only been reported in two or three instances. They are of concentric formation, smooth and greasy to the feel, and vary in color from gray to brown.

Carbonate-of-lime calculi are usually multiple, and are light-gray in color and chalky in consistence.

Organic calculi, consisting of epithelia, blood, etc., are not infrequent as nuclei for other varieties, but exceedingly rare as independent forms.

Stone in the bladder is a misfortune that may befall every age and condition of human life, from the foetus *in utero*, to the old and decrepit. The period of greatest exemption is from twenty to fifty years of age. It is comparatively frequent in children, and here must be of renal origin and due to the excess of inorganic elements in the urine, since obstruction and inflammatory diseases of the urinary tract rarely exist at this age. After fifty, when prostatic, cystic, and urethral obstruction are more frequently met with, the formation of calculi, vesical in origin, is more common. As to sex, stone is more frequent in males. It was formerly argued that there was no difference in the frequency of stone in the sexes, but that the short and dilatable urethra of the female allowed a ready escape to the concretion before it became sufficiently large to produce any organic disturbance. When, regardless of the statistical evidence which shows that the number of deaths in males from urinary calculus is ten times greater than in females, we consider that one of the most frequent causes of stone is the gouty diathesis, and that gout is more frequent in men; and, again, that prostatic and urethral obstruction is peculiar to this sex—it must be conceded that the conditions for the formation of calculi are more frequently present in males.

In the *ætiology* of stone in the bladder two great factors are recognized: The one includes all conditions of the economy which favor precipitation of the inorganic elements of the urine; the second all obstructive and inflammatory lesions which produce decomposition of the urine in the bladder, the detachment of epithelia, and the accumulation of other organic elements which serve as nuclei around which the salts of the urine are congregated.

In the first category are hereditary tendencies, such as gout and rheumatism. Certain conditions of mal-nutrition undoubtedly lead to a precipitation of the urinary salts, for children poorly fed and cared for are

much more apt to suffer from calculus than those which are well fed and comfortably clothed and sheltered.

It can scarcely be doubted that residence exercises a causative influence upon the formation of calculus. In the United States, Northern Alabama, Tennessee, and Kentucky afford a large number of this class of cases, while in New York and the New England States stone in the bladder is exceedingly rare.

In the group of local causes may be classed all cystic diseases in which the products of inflammation collect in the bladder and form nuclei, around which concretions occur; prostatic enlargement inducing retention, cystitis, and decomposition of urine; stricture, and all obstructive and inflammatory lesions of the urethra which may involve or affect the integrity of the bladder; the presence of any foreign matter in the bladder, or paralysis of the bladder from any cause.

The Symptoms and Diagnosis.—It may be stated at once that, however much has been and may be said of the value of the various symptoms of stone, the diagnosis rests upon one simple expedient, the introduction of a metallic instrument into the bladder, and in contact with the stone. For this purpose the ordinary steel sound is usually sufficient. The bladder should be allowed to contain about half a pint of fluid, and when the instrument is introduced it should be manipulated so that the convexity of the curve will glide over the floor of the bladder back and forth from the neck to the posterior wall of the organ, at the same time depressing the bladder toward the rectum. By this manœuvre the stone will be induced to gravitate to the deeper portions in contact with the instrument, or so close to it that a sharp, quick turn to right or left will bring the calculus and metal into appreciable contact. In certain cases of prostatic hypertrophy the calculus may remain concealed immediately behind the enlarged organ, and in such a position that the sound can not be brought in contact with it. Under such conditions Thompson's searcher (Fig. 581) will be found useful. The objection to this instrument is the



FIG. 581.—Thompson's searcher.

difficulty of its introduction from the abrupt nature of the curve near the tip. When once introduced its value is readily appreciated. Turning its point downward and moving as if to withdraw it, there is no portion of the floor that it will not thoroughly search.

When a stone can not be appreciated with a full or half-filled bladder it may be felt if this organ is completely emptied. Not only is the calculus driven toward the neck of the bladder when it is emptied of urine, but the hardness and weight are more readily appreciated, since it is held in the grasp of the organ, and can not slip away when the sound touches it. In some forms of vesical calculus the stone becomes partially or completely *encysted* in some portion of the bladder-wall. The calculus may drop into an abnormal pouch in the bladder; it may sink by a pro-

cess of ulceration into the walls, and be partially or completely surrounded by a newly formed inflammatory tissue, or it may have been lodged in the ureter near its termination.

Again, a stone may be caught in the upper portion of the bladder without being sacculated. In sounding for stone in adults, ether narcosis is not always required, especially where there are no symptoms of severe cystitis and tenesmus. In children an anæsthetic should always be employed. When the calculus can not be felt after careful search, it is at times a successful expedient to introduce the finger into the rectum and make upward pressure upon the base of the bladder, and firm pressure downward upon the abdomen, just above the symphysis pubis.

Vesical calculus may be suspected in a patient who has had renal colic, or has passed by the urethra particles of gravel, and afterward develops a cystitis. Not infrequently, however, a concretion goes from the kidney into the bladder without attracting the attention of the patient. If it lodges here, and increases slowly in size, it may remain for months or years without giving any symptoms of cystitis, or marked annoyance. Usually, however, when a stone is present, and is so light and smooth that it does not affect the mucous membrane of the bladder, it attracts attention by mechanical interference with the escape of urine, dropping at times into the orifice of the urethra, and suddenly shutting off the flow during micturition.

When a stone, by reason of its size, weight, and roughness, begins to cause cystitis, frequent micturition is a prominent symptom. A burning or smarting pain, referred to the end of the penis, is a frequent symptom in this, as in idiopathic inflammation of this organ. At times the pain is referred to the scrotum, penis, uterus, and other organs, or along the nerve-tracts in the lower extremities. In any jolting movement, as in riding on horseback, or in vehicles without springs, or in walking about, the pain is increased. Tenesmus is often violent toward the end of urination, when the stone is grasped by the contracting bladder. The urine almost always contains pus, and blood is frequently present. Hæmaturia, with calculus, occurs chiefly during the waking hours, when the patient is moving about. It is more apt to be met with in oxalate-of-lime calculi than in the other varieties. In the rare instances in which stone exists with villous growths of the bladder, hæmorrhage is often excessive. When a calculus is of large size, it may by pressure produce pain and symptoms of disturbance in other organs, as the vagina, uterus, or rectum. The size and character of a stone in the bladder may, in a measure, be determined by exploration with the sound, as well as by palpation.

A large stone is usually felt as soon as the sound enters the neck of the bladder. The sense of resistance is greater, and a fair idea of its proportions may be made out by passing the metallic sound along its surfaces. A small stone is often with difficulty recognized. Pressure above the symphysis pubis, and intra-vaginal or rectal exploration, are not without value in estimating the size of a calculus. If the click of the sound is sharp and clear, and if the surface is rough and grating to the sense of touch conveyed along the instrument, an oxalate-of-lime stone

may be suspected, and, if the patient is a child, the suspicion is strengthened. Hæmaturia, and all the symptoms of cystitis, are, as a rule, increased with this form of calculus. In patients with the gouty or rheumatic diathesis, *uric-acid* stone is the rule. The acidity of the urine in a measure excludes phosphatic calculus. In the exceptional instances in which a portion of the surface of the bladder has become incrustated with the inorganic elements of the urine, this condition may be determined by the immobility of the concretion when the sound is brought in contact with it. The absence of a spherical calculus can be determined by digital exploration through the rectum or vagina, combined with pressure from above the symphysis pubis.

Treatment and Prognosis.—The attempts to dissolve vesical calculi by the administration of remedies by the mouth, or by solutions thrown into the bladder, have not met with encouraging success. While there is little doubt that the correction of a dyscrasia which is favorable to the formation of stone may prevent or retard the further growth of an existing concretion, there is no evidence to prove that a stone in the bladder was ever removed by this plan of treatment.

The proper treatment of stone in the bladder may be divided into the *curative* and *palliative*. To the former belong the operations of *lithotomy* and *lithotrity*; to the latter are systematic medication and hygiene, together with the employment of all local means calculated to relieve pain and prolong life. In determining upon the proper method to be adopted, the following points should be duly considered :

In male patients under the age of seventeen the cutting operation is preferable, for the reasons that (1) the caliber of the urethra is usually too small to admit of the instrumentation necessary to lithotrity ; (2) the mortality rate after lithotomy in this class of patients is very low—about 5 per cent. After this period, as between lithotomy and lithotrity, the former operation is demanded (1) in all cases of stricture of the urethra, where the caliber of this tube is narrowed to such an extent that the repeated introduction of the lithotrite and washing-apparatus is difficult or impossible ; (2) in prostatic disease, with hypertrophy to such an extent that it offers an impediment to the introduction of the instruments, and renders the seizure of the stone or fragments difficult of accomplishment ; (3) when the stone is more than one inch in diameter ; (4) when it is so hard (oxalate of lime) that it can not be crushed by the employment of a reasonable degree of force ; (5) when chronic cystitis and vesical intolerance exist ; (6) in a patient suffering from any form of nephritis.

Lithotrity.—If the symptoms are not so distressing as to demand immediate interference, from ten days to two weeks should be devoted to the careful preparation of the patient. It is not only important to improve the general condition, but also to accustom the urethra to the introduction of the sound.

The instruments required are the lithotrite and an apparatus for washing out the detritus.

Of the various crushing-instruments which have been introduced, that of Sir Henry Thompson is to be preferred (Figs. 582–585). It is com-

mendable for its lightness, strength, and smooth action. With the heavier instruments the sense of touch is not so delicate and acute. The lighter lithotrite is strong enough to crush any calculus which may be safely removed by this operation. Moreover, it is especially to be commended for the fenestrated jaw in the female blade (Fig. 582), which allows the male blade to pass entirely through, and thus avoids the danger of choking and fouling. It consists

of a male blade (Fig. 583), or sliding rod, which fits into a fixed or female blade (Fig. 584), which is deeply hollowed out for its reception.




FIG. 582.—Fenestrated jaws of Thompson's lithotrite.




FIG. 583.—Male blade of Thompson's lithotrite.



FIG. 584.—Female blade of Thompson's lithotrite.

The seizing and crushing action of the lithotrite is double. When the male blade is carried through the hollow handle into the slot in the female blade, a simple and rapid to-and-fro movement can be executed by pushing or pulling on the male blade with the right hand, while the left



FIG. 585.—Thompson's lithotrite adjusted.

steadies the female blade, to which the handle is attached. This movement can be made very effective in seizing the stone and in crushing the smaller fragments without taking the extra time in sliding the catch which throws on the screw-motion of the instrument.

When, however, a stone is caught in its grasp by the sliding movement just described, and is so solid and resisting that a sufficient and safe crushing force can not be employed, the catch on the top of the handle is slipped upward. The sliding movement is now impossible, and the more powerful screw-motion substituted. By turning the wheel at the end of the male blade to the right, the stone can be felt to give way under the crushing force.

In the removal of vesical calculi by this operation two procedures are recognized, viz., *complete* and *incomplete* lithotripsy.

In the former, or Bigelow's method, ether narcosis is required; the stone is entirely crushed, and the fragments washed out at a single

operation. In the latter, anæsthesia is not employed; the calculus is only partially comminuted, and the fragments are left to pass off with the urine.

Complete lithotrity has almost entirely superseded the older operation. It is preferable in all cases where the condition of the patient justifies the risk of shock from a capital operation under ether narcosis.

Operation.—The patient, being narcotized, is placed upon the operating-table, in the dorsal decubitus, with the pelvis raised about half a foot, by pillows placed under the sacrum. If the bladder has not been emptied just before the operation, the urine is now drawn off and about one pint of tepid water injected, thus distending this organ and rendering the mucous membrane less liable to injury from being picked up by the instrument. The lithotrite, having been properly warmed, oiled, and tested as to its working capacity and strength, is now prepared for introduction, by sliding the male blade completely down until its tip passes into the fenestra of the female blade. As the convexity of the male blade is serrated, great care must be taken not to push the rough surface beyond the level of the female blade, since the introduction of the instrument, improperly adjusted, would do unnecessary violence to the floor of the urethra.

A right-handed operator should stand at the patient's right side. The instrument is locked and carried into the bladder by the same manœuvres as given for the introduction of the sound or metal catheter. When the beak is well into the bladder, it is carried along the floor, with the tip pointing upward, until it meets with the resistance of the posterior wall of the bladder, when it should be slightly withdrawn. The handle should now be elevated, in order to depress the floor of the bladder with the convexity of the curve. Held firmly in this position, the lithotrite is opened by withdrawing the male blade about two inches. The operator should now strike the handle of the instrument with the knuckles or hand, hard enough to carry the concussion to the bladder, in order to dislodge the calculus and allow it to fall into the lowest portion of the organ, and within the grasp of the lithotrite, which is now closed by pushing the male blade down. If the stone is seized, it will be made evident by the failure to close the blades, and, when caught, it should be firmly held, the screw-movement adjusted, and the wheel rotated slowly. Having thus secured the stone, the instrument should be moved to and fro, in order to assure the operator that the wall of the bladder is not caught. In crushing a calculus, the rapidity with which it is done should be determined by the sense of resistance experienced. It is not safe to employ force sufficient to spring the blades. A stone which can be safely crushed will yield perceptibly under a few turns of the screw. Phosphatic stone can often be rapidly comminuted without adjusting the screw. Uric-acid calculi require more power, while the oxalate-of-lime at times can not be crushed at all.

If the manœuvre above described fails after being several times carefully repeated, search must be made in other quarters. Holding the instrument beak upward, the convexity still upon the floor of the blad-

der, separate the blades, turn the shaft half over to the right, and then close the blades. If the stone is seized, hold it steady, adjust the screw-motion, tighten the grip by a slight turn of the wheel, and carry the instrument back to the middle line with the beak pointing upward. If it does not move freely, the indication is that the bladder has been picked up, and of course the blades must be separated and another effort made. With the instrument shown there is little danger of this accident. The same manœuvre may be tried on the opposite side. If there is prostatic enlargement, it may be necessary to turn the beak downward into the pocket on the floor of the bladder. If, after a half-hour's search, the seizure has not been effected, the operation should be discontinued.

When the stone has been seized and broken once, the same manœuvres should be carefully yet rapidly repeated until no large pieces remain. It will usually be found easy to crush the smaller pieces by the sliding movement alone. The instrument should

now be closed until the blades have the same relation as when introduced, and then withdrawn. The *evacuator* consists of a rubber bulb capable of holding about one pint. At the upper end is a funnel and stop-cock for filling and closing the apparatus. Below is attached a glass globe, in which the particles of stone gravitate as fast as they are drawn into the evacuator. Between this and the rubber bulb is a second stop-cock, and a place for attaching the catheter. It is advisable to insert a piece of rubber tubing, about five inches in length, between the catheter and the evacuator, in order to prevent the jarring motion imparted to the bulb from being conveyed to the instrument in the bladder. The catheters (Fig. 586) are of different sizes and shapes, ranging from No. 14 to No. 25, U. S. The evacuation is much more rapid with the larger instruments. However, the urethra should not be over-distended. In general,

the catheters which are only slightly curved near the tip, with the eye at the extremity, are preferable. In filling the bulb, in order to exclude the air, the glass ball is first detached, filled with clean warm water, and readjusted. Both stop-cocks are now opened, the end of the tube closed with the finger, and water poured into the funnel until the bulb and tube are filled to overflowing. The cocks are then closed, and the instrument intrusted to an assistant. The catheter, well oiled, is carried into the bladder, and as the water is escaping the lower end of the rubber tube attached to the evacuator is slipped over the end of the instrument. The bulb is grasped between the thumbs and fingers of both hands and squeezed, thus forcing the greater part of its contents

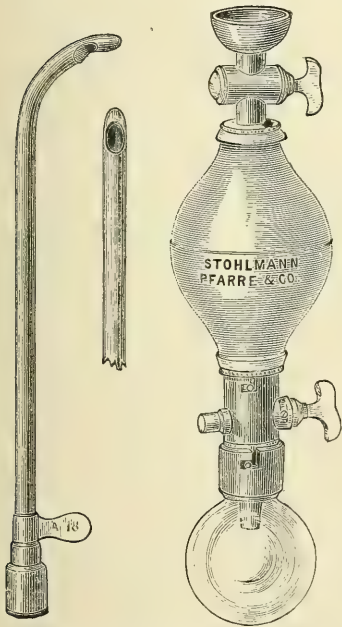


FIG. 586.—Thompson's improved evacuator and catheters.

into the bladder. It is now allowed to expand, the water rushes back out of the bladder and brings with it the smaller particles of stone which fall down into the glass sphere. This part of the operation may be expedited by rapidly half emptying the bulb into the bladder, and as rapidly allowing it to expand. When it is seen that particles of the calculus cease to fall into the receiver, the catheter should be withdrawn, the lithotrite reintroduced, and a second crushing done. The bladder is again washed out, and these operations should be alternated until all detritus is removed, unless alarming symptoms should supervene, when of course all operative measures should be discontinued. If the glass receiver becomes filled, it should be detached and emptied. At times particles of calculus become lodged in the catheter or tube, and require to be dislodged with a stylet. From one to two hours may be allowed for this operation from the commencement of the anæsthesia. The prognosis will be more favorable with the shorter period, but it is wiser to proceed carefully and remove the stone thoroughly, even if a longer time is required. The absence of all fragments can be recognized by placing the ear over the bladder at the symphysis while the evacuator is being worked. The click of any fragments against the catheter can be distinctly heard. The introduction of a sound will also determine the presence of any pieces.

In the after-treatment opium is essential to relieve pain and tenesmus. Citrate of potash, grs. xx, three or four times a day, with flaxseed-tea, will render the urine less irritating. The soft catheter may need to be employed to evacuate the bladder.

In incomplete lithotripsy the crushing is done in the same manner as just described. A fair degree of anæsthesia may be secured by the employment of cocaine. The lithotrite is only introduced once, and not more than five or ten minutes are consumed in the operation. The evacuator is not employed, the detritus being expelled in the act of urination.

Cystotomy or Lithotomy.—Cutting into the bladder for the removal of stone is performed through the perinæum or through the abdominal wall, just above the symphysis pubis. Incision through the rectum in males is no longer a recognized procedure, while the vesico-vaginal operation is rarely indicated.

Supra-pubic cystotomy, or the *high operation* (as distinguished from perineal cystotomy), is performed as follows:

The pubes should be shaved and thoroughly disinfected, the pelvis raised on a cushion so that the intestines will gravitate toward the diaphragm. The bladder should be several times washed out with warm Thiersch's solution, or a solution of boracic acid, grs. v to water ℥j, throwing about eight to ten ounces in through a soft catheter and allowing it to escape. A rectal bag or Barnes's dilator should now be well lubricated and pushed into the rectum and distended with six ounces of water. From eight to twelve ounces of warm Thiersch solution should then be forced into the bladder, the catheter withdrawn and a ligature immediately tied around the penis to prevent escape of the liquid. In females

the urethra may be plugged. These two procedures lift the bladder upward, render it tense, and aid in displacing upward the fold of peritonæum which drops down in front of the anterior wall of the bladder.

An incision in the linea alba, extending from three inches above the symphysis to one half an inch below the upper margin of the pubic bones, is next made, and the tissues separated in the median line until the layer of fat which lies between the bladder-wall and the pubes is in sight. It is always advisable to snip with the scissors a half-inch of the attachment of the muscles to the pubes on either side of the wound. All bleeding should be arrested and this prevesical areolar tissue lifted upward by the finger-nail or a dry dissector. Should the peritonæum dip down low, it will be lifted by this manœuvre. A dull retractor placed beneath this tissue and traction made toward the umbilicus should now be used, and two similar instruments to separate the wound laterally. The anterior wall of the distended bladder is now in plain view for about two inches in its long axis. Occasionally at this step of the operation one or two good-sized veins are seen crossing the proposed line of incision in the bladder. These should be secured by passing a curved needle armed with catgut around them and tying on each side of the line of incision.

The next step is to introduce into the wall of the bladder, on each side of the line of the incision about to be made, a loop of small Chinese twisted silk. This may be done by means of a curved needle, leaving the thread double and tying it in a long loop, so that it may be removed in three or four days without disturbing the wound.

These threads are now held steady, the operator makes out distinctly the spot where he proposes to puncture, and, carrying the knife through, back of the blade downward, he enters the bladder a little below the level of the pubic rim and cuts upward about one inch exactly in the long axis of the organ. The water rushes out at once, and the finger is carried into the bladder, traction being made on the threads to prevent the separation of the wall of the bladder from the fascia in front. This is of great importance in preventing the occurrence of an obstinate pocket or fistula which not infrequently follows this operation.

If the operation is for *stone* or a *foreign body*, the removal may be effected either with the finger or a delicate dressing forceps. The opening may be stretched, if required, or enlarged by incision. If a *tumor* is present, it will usually require a freer incision through the abdominal wall in order to thoroughly inspect the bladder, or to apply the cautery to the pedicle of any neoplasm which may be removed. To accomplish this, a transverse incision just at the level of the pubes should be made, extending to either side of the median line one and a half to two inches. The attachments of the recti muscles are divided, but care should be taken *not* to extend the incision far enough laterally to divide the *internal pillar* of the *inguinal canal*. The long retractors now inserted into the bladder will stretch the opening and allow a free inspection of the entire inner surface. When the light is not good, the electric arc will be of great service in illuminating the interior of this organ.

The detachment of tumors may be effected with a Volkmann's spoon, or better with the Spencer Wells fenestrated ovarian sac forceps. When thus torn, cut, or twisted off to the level of the bladder-wall, the point of attachment should be carefully seared with the cautery.

The after-treatment of supra-pubic cystotomy will depend upon the condition of the bladder at the time of and immediately after the operation.

If there is a chronic cystitis, or if a neoplasm has been removed and bleeding can not be altogether arrested, drainage is indicated. If the bladder is not inflamed, it should be sutured at once.

Drainage is secured by inserting a Trendelenberg's soft rubber T-shaped tube (Fig. 586 A). The ends of the cross-piece should be folded back, grasped in the jaws of a delicate dressing forceps, and, while the bladder is firmly fixed by traction on the threads, the tube is carried to the floor of this organ. As the forceps open, the cross-piece expands and prevents the easy withdrawal of the tube. After thorough irrigation, the wound around the tube should be closely packed with long ribbons of iodoform gauze, and over this sublimate or carbolic-gauze protective and a bandage.

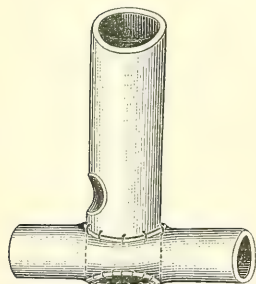


FIG. 586 A.
T-tube, for drainage after supra-pubic cystotomy.

The patient is put to bed, resting on the side. By means of a piece of glass tubing, a long rubber tube is connected to the end of the T-drain, and this channel conducts the urine, as fast as it enters the bladder, into a vessel at the bedside. Irrigation with warm Thiersch solution should be made every three or four hours for the first two days, and every six hours for two more days, or until the discharge is clean. This is accomplished by uncoupling the glass pipette and injecting through the T-drain two to four or six ounces, and allowing it to escape at once through the tube. The tube should be removed as soon as the condition of the bladder will permit, because the longer it is allowed to remain the greater the danger of a troublesome persisting fistula. Four to eight days will be the limit in most cases. Of course, in bad cases of cystitis, drainage must be kept up until the disease is cured, if this takes weeks or months. The urine escapes through the tube and then through the wound until this begins to be narrowed by granulation. The dressing is continued until cicatrization is complete. When pockets form, they must be opened up, scraped, and packed. When fistula persists, it may have to be split up and scraped. In two instances I have had to dissect out the indurated tissues and again open into the bladder to effect a cure of fistulæ.

When the bladder is to be closed at once, proceed as follows: Irrigate thoroughly and pull the edges of the incision in the bladder-wall as well up into the wound as possible. A half-curved needle armed with

fine catgut, should now be introduced about one eighth inch from the edge of the incision in the bladder, and carried through and out on the cut edge just where the mucous membrane rests on the bladder-muscle (not into the cavity). It should be made to enter at the same level on the opposite side and to come out one eighth of an inch from the edge. These sutures should be about one eighth to three sixteenths of an inch apart, and when tied should be cut off short. The abdominal wound may now be closed in part from the ends, but not over the line of sutures in the bladder. Light iodoform gauze packing should fill in the opening, and a sublimate gauze dressing over all. The patient should rest on the back, and the urine allowed to flow out constantly through a soft catheter, fastened in through the urethra. Should distention occur, urine would very probably escape through the wound. In any event, as the abdominal wound is open, there is no danger should leakage happen.

To this date (January 1, 1890) the author's experience in suprapubic cystotomy is included in the following synopsis of cases :

CASE I.—Male, aged 40. Operation, July 7, 1888. Seven months before, hæmaturia, chills, and fever. Diagnosis, cancer of bladder. Operation, large epithelioma removed. Ordinary T-drainage tube; removed eighth day. Urine ceased to escape through wound sixteenth day. Recovery. Six months later, death from general metastasis and exhaustion.

CASE II.—Male, aged 36. Operation, July 20, 1888. Small sessile tumor removed from floor of bladder. Tube removed sixth day. Wound had closed eighteenth day. Recovered.

CASE III.—Female, aged 20. Tumor of urethra growing back into bladder. Operation, March 26, 1889. Wound in bladder closed with catgut. Catheter worn for ten days. Recovered.

CASE IV.—Male, aged 67. Operation, September 4, 1888. Tumor of prostate and vesical, calculus removed. Drainage-tube removed sixth day. Wound had closed fifteenth day. Recovered.

CASE V.—Male, aged 46. Operation, September 28, 1888. Large stone removed. Tube discontinued eighth day. Fistula persisted four weeks; later this was scraped out, and it then closed. Recovered.

CASE VI.—Male, aged 41. Operation, July 25, 1888. Piece of catheter removed. Tube discontinued fifth day. Wound healed by fourteenth day. Recovered.

CASE VII.—Male, aged 40. Operation, December, 1888, for chronic cystitis. Drained for three weeks. Recovered.

CASE VIII.—Male, aged 68. Operation, September 2, 1888, for closure of fistula, which was easily cured. Recovered.

CASE IX.—Male, aged 48. Operation, September, 1889. Tumor of prostate and vesical calculus removed. Drainage. Recovered.

CASES X and XI.—Male, aged 54. Operation, October, 1889. Tumor of bladder just behind urethral opening removed. Drainage removed eighth day, and wound healed. Cystitis, with alarming elevation of temperature, recurred in this case, and three weeks later a second operation without anæsthesia was done. Recovered.

CASES XII and XIII.—Male, aged 4. Severe cystitis, with paralysis of bladder, due to compression myelitis. Tube removed on the fourteenth day. The cystitis recurred, and the operation was repeated. Drainage-tube still in position. Recovered.

CASE XIV.—Female, aged 43. Operation, December, 1889. Valvular fold of hypertrophied mucous membrane stretched partially over exit of urethra. Removed. Wound in bladder closed at once. Recovered.

CASE XV.—Male, aged 60. Operation, December, 1889. Piece of catheter four inches long, incrustated with stone, removed. Drainage tube discontinued on fifth day. Recovered.

Supra-pubic cystotomy has, at various times in the history of surgery, been brought prominently before the profession, but to achieve a short-lived popularity, and be relegated to comparative obscurity.

Under the impulse of modern aseptic practice and an improved technique, it has gained a position not heretofore accorded it, and it is safe to say from which it will not again recede.

To *perineal cystotomy* it should be preferred—1. For the removal of all forms of neoplasms. 2. For the removal of foreign bodies, so shaped or so large that they can not be withdrawn by means of the lithotrite. 3. For stone, when, (*a*) by reason of urethral or prostatic lesions, the lithotrite and washing-tubes can not be freely and safely employed; (*b*) when, from chronic prostatitis, great hypertrophy of this organ with elongation of the neck of the bladder has occurred, rendering the calculus difficult of access by this route; (*c*) when a stone so hard or so large that it can not be rapidly comminuted and removed by the lithotrite; (*d*) when vesical calculus is complicated with chronic nephritis.

While it is difficult to specify the exact size of a stone to be removed by the high operation, it would be safe to include those the smallest diameter of which would measure more than one inch.

In adult males under fifteen, on account of the distensibility of the prostate and neck; and in children, by reason of the difficulty in keeping this class quiet in bed, the perineal operation is preferred.

In females, for persistent cystitis vesico-vaginal fistula may be made, as this allows the adjustment of a urinal, and permits of out-of-door life. For stone, either lithotritomy or the high operation should be performed.

Perineal lithotomy, or the *low operation*, may be done by three methods—the *lateral*, *bilateral*, and *median* operations. A combination of the median and lateral incisions is sometimes performed, and is known as the *medio-lateral* procedure.

Lateral lithotomy is thus performed: Two hours before the operation the rectum should be emptied by a free enema of tepid water, and the perinæum cleanly shaved. The patient should be placed upon the back, the sacrum resting near the edge of the table, the thighs flexed toward the abdomen, slightly abducted, the feet brought down and secured to the hands and wrists by several turns of a roller. Each leg is intrusted to an assistant, while a third, selected for his special fitness, and upon

whom the duty of holding the guide devolves, stands beside the patient's abdomen, facing the operator.

If the bladder is not fairly distended with urine, a Nélaton's catheter should be introduced, and about a pint of fluid injected. A Fergusson's guide, grooved laterally (Fig. 587), is next carried into the bladder. The probabilities are that the stone will be felt by the sound. If the calculus has been recognized within a day or two, and if in the mean time the urine has been carefully watched and no

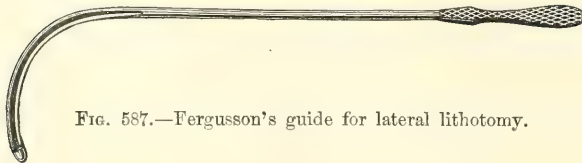


FIG. 587.—Fergusson's guide for lateral lithotomy.

solid substance has escaped by the urethra, no prolonged effort should be made at this juncture to demonstrate its presence.

The proper position for the guide is shown in Fig. 588. The shaft is held about perpendicular to the surface of the table, the point well into the bladder, while the convexity of the curve rests against the perinæum. The scrotum is now lifted directly upward, and the primary incision is made with the sharp scalpel (Fig. 53). It

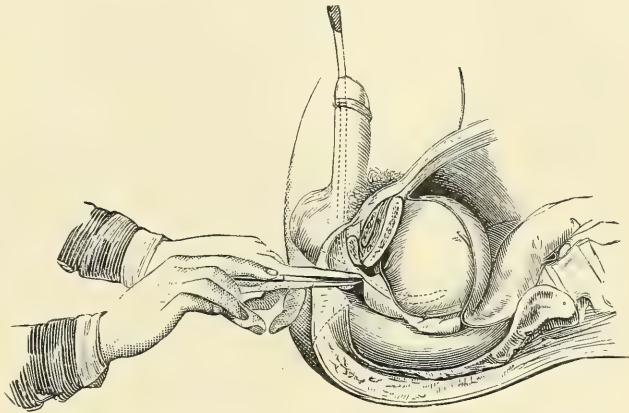


FIG. 588.—Guide in position in lateral lithotomy. (After Bryant.)

commences in the median line about one inch and a half directly in front of the anus, and is carried downward and outward as far as the

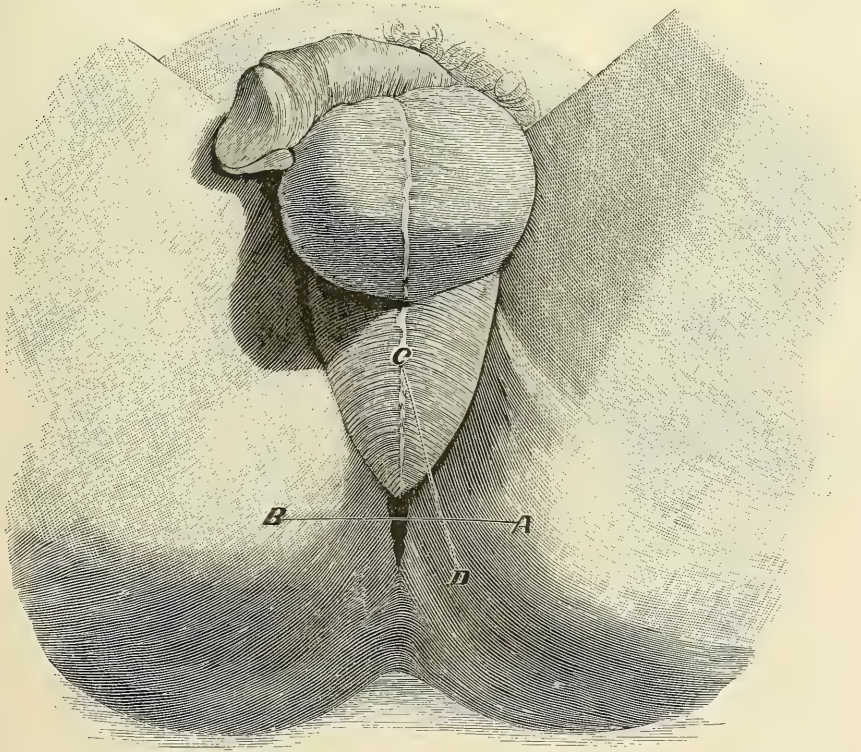


FIG. 589.—*C D*, Line of incision in lateral lithotomy. *B A*, Imaginary line between the tuberosities of the ischia. (After Maclise.)

posterior margin of the anus, passing half-way between the inner surface of the patient's left *tuber ischii* and the anal margin (Fig. 589).

The integument and fasciæ having been divided, the operator proceeds through the upper half of the wound by cutting down upon the guide, which may be readily felt with the finger. When this is nearly reached, the groove in this instrument will be made out, and, by pressing the nail of the left index-finger into it, the point of the knife can be guided through the urethral wall into the groove, making an opening about half an inch in extent.

With the finger-nail kept steadily in the groove, the scalpel is laid aside, and the long probe-pointed lithotomy-knife (Fig. 54) taken up and its point guided into the groove of the guide. At this stage of the operation the sound is slightly lifted up, so that the pressure which has heretofore been made upon the floor of the urethra will be transferred to its roof. While doing this the probe-point of the knife should be firmly and steadily pressed upward against the instrument, for, unless this precaution is observed, it may slip out of its proper place. The operator now seizes the shaft of the sound with the left hand to assure himself, by moving this instrument slightly, and also by sliding the knife along the groove, that the two instruments are in actual contact, and then, turning the cutting edge of the knife obliquely toward the patient's left side, and more nearly parallel with the transverse than with the antero-posterior diameter of the patient's body, pushes it along the grooved guide into the bladder. In executing this manœuvre it is necessary to tilt the point of the knife upward and press it very firmly into the groove lest it slip out and cause confusion. When the probe-point arrives at the end of the groove and catches, the incision through the left lobe of the prostate may be lengthened by pushing the sound with the knife in the proper direction. As the incision is being made, a gush of urine takes place. The knife is now withdrawn, the finger carried into the bladder, and the stone located before the sound is removed. The size of the calculus should be determined, and, if necessary, the lower portion of the primary incision may be enlarged. While this is being accomplished, it is advisable to carry the index-finger into the rectum to avoid wounding this gut.

The forceps (Fig. 590) should now be introduced and the stone removed. This instrument can not always be carried in through the wound if the finger is allowed to remain, and is at times difficult of introduc-

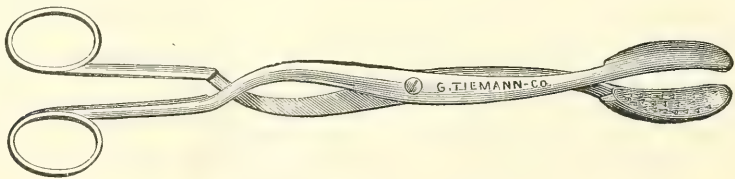


FIG. 590.—Lithotomy-forceps.

tion without a guide. To prevent delay, the conductor (Fig. 591) should be passed along the finger into the bladder and allowed to remain after the finger is withdrawn. If the blades of the forceps are now closed upon the flange of the conductor, the instrument can be made to slide

accurately along the guide into the bladder, after which the conductor should be removed.

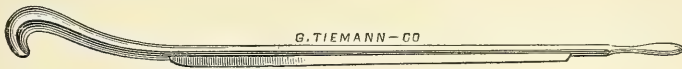

FIG. 591.—Scoop and conductor.

In removing a stone with the forceps two precautions are essential: 1, not to pick up the wall of the bladder with the calculus; and, 2, not to employ force enough in grasping the stone to crush it.

When the stone is grasped, if the instrument can be moved freely within the bladder, it is evident that this organ is not caught.

With small calculi the extraction is easily accomplished. When the stone is large, a certain amount of force is justifiable and necessary to stretch the wound to its utmost; but this force should never be used unless the operator is satisfied that the stone and jaws of the forceps

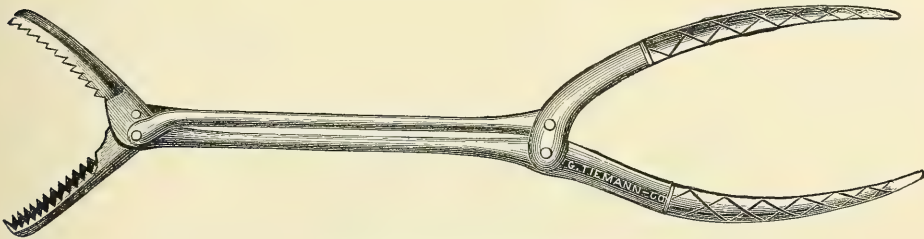


FIG. 592.—Gouley's lithoclast.

can be brought through the wound without serious injury to the bladder and prostate. If the stone can not be extracted whole, it should be crushed with the forceps or lithoclast (Fig. 592), and removed in frag-



FIG. 593.—Lithotomy-scoop.

ments. The larger pieces may be caught with the forceps, the smaller with the scoop (Fig. 593). A stream of water should also be forcibly

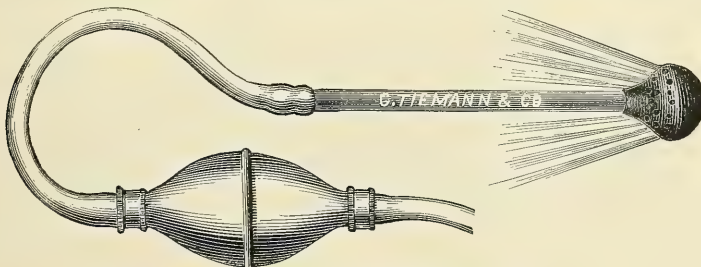


FIG. 594.—Van Buren's debris-syringe.

thrown in through the wound, in order to bring away any small particles which may have escaped notice (Fig. 594). Finally, a sound should

be introduced and search made for a second stone or any fragments lodged in the more remote portions of the bladder.

Among the accidents which may complicate perineal lithotomy, in addition to that of wounding the rectum, which has been mentioned, is

hæmorrhage from the artery of the bulb and other vessels of the perinæum. The ligature will control all superficial bleeding, and, should a deep vessel be divided, it may be transfixed with a tenaculum and tied, or the hook allowed to remain in the wound for a day or two. If the oozing is free and general, an umbrella-compress (Fig. 595)

should be made by tying a piece of oiled silk or rubber tissue to a canula or bougie. This is carried into the wound and compression made by packing sponges beneath the cloth which is brought in contact with the bleeding surface.




FIG. 595.—Umbrella-compress.

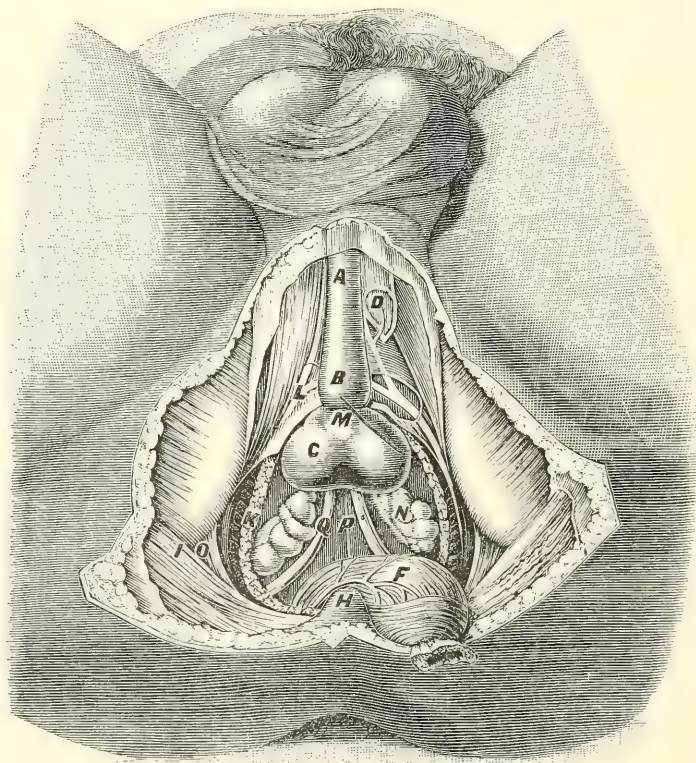


FIG. 596.—*A B*, Bulbous portion of the urethra. *C*, Right lateral lobe of the prostate. *M*, The line of incision in lateral lithotomy. *D*, Corpus cavernosum. *F*, Rectum. *N*, Vesicula seminalis. *Q*, Vas deferens. *L*, Artery of the bulb. (After Maclise.)

The after-treatment of lateral lithotomy is simple. The wound is left open and unmolested. The urine passes through this for a few days or

weeks, and gradually resumes the urethral channel as the incision closes by granulation. In some cases the urine passes through the urethra uninterruptedly. The patient should remain in bed for two or three weeks.

The anatomical relations of the parts involved in this operation are shown in Fig. 596.

Bilateral Lithotomy.—In performing this operation a curved incision is made, beginning half-way between the tuberosity of the ischium and the anus on one side, and terminating at a corresponding point on the other. The incision crosses the median raphé of the perinæum from one half to three quarters of an inch in front of the anus. The guide used in this operation should be grooved deeply in the middle of its convex surface. As soon as this instrument is reached, the urethra is opened in the membranous portion, and the finger-nail carried into the groove on the sound. The bisector—a probe-pointed two-edged lithotome—is introduced by sliding the tip of the instrument along the nail into the groove. The operator now takes hold of the staff, depresses the handle of the bisector, and, keeping the probe-point in the groove, pushes the knife into the bladder directly in the median line. In this operation the prostate is divided equally on both sides of the urethra.

Median Lithotomy.—The position of the patient is the same as in the two preceding operations. The best staff or guide is that of Prof. Little (Fig. 597), which has a deep, wide groove.




FIG. 597.—Little's lithotomy-staff.

It is introduced and held in such a position that the shaft is perpendicular to the plane of the body, the tip well in the bladder, with the convexity of the instrument pressing firmly and steadily toward the perinæum. The finger is now carried into the rectum in order to guard against puncture of the anterior wall of this organ. The knife (Fig. 53) is entered just about a half-inch anterior to the anus in the median line, the edge of the blade directed upward, and is pushed straight inward until the point strikes into the concavity of the groove in the staff at the anterior limit of the prostate. It is then made to cut forward and upward until the membranous portion is divided, and, as it is withdrawn, the incision in the perinæum is lengthened in all about one and a half inch. The finger is now introduced, the sound withdrawn, and the wound, prostatic portion of the urethra, and neck of the bladder dilated until the stone can be felt and extracted with a slender forceps.

Of the four methods of cutting for stone just described, the lateral and supra-pubic operations are preferable. The bilateral procedure is

at this time rarely performed. In the extraction of an ordinary stone the incision through one lobe of the prostate will be sufficient. When the calculus is so large that a wider incision is required, the right lobe may be readily incised through the lateral wound. The median operation is objectionable on account of the danger of injuring the prostate and neck of the bladder, in the necessary dilatation, or in efforts at extraction. It is only applicable to the removal of the very smallest calculi in children or youths in whom a lithotrite and evacuating-catheter can not be introduced. Even in this class of cases the lateral operation should be given the preference. The supra-pubic incision has, within late years, become a more popular operation. It is applicable (1) when the stone is of large size—from one and a half to two inches and over in diameter—the removal of which by a perineal incision would involve an extensive incision or laceration of the neck of the bladder and prostate; (2) where the calculus is lodged high up behind the pubes, either with or without enlargement of the prostate and concentric hypertrophy of the neck and base of the bladder, since in these conditions a stone can be reached through the perinæum only at great depth and with much difficulty. On the other hand, it is readily found through a supra-pubic incision. The high operation is indicated in deformity of the pelvis, with narrowing of the inferior strait. The difficulty and danger of this procedure are increased in corpulent and fat persons.

Stone in the Bladder of Females.—Vesical calculi are not met with in females as frequently as in males. Many conditions which conduce to the lodgment or formation of stone in the male bladder, and are common in this sex, are either impossible to, or rarely occur in, females. Among these causes may be mentioned hypertrophy of the prostate with obstruction, and chronic cystitis and organic stricture of the urethra.

Another explanation of the comparative infrequency of stone in females is the short and dilatable urethra, allowing the escape of many small concretions which in men would lodge in the *cul-de-sac* behind the prostate. The symptoms do not differ from those given in stone in the bladders of males. The *diagnosis* rests upon exploration with a searcher, combined with digital exploration *per vaginam*, and direct pressure over the pubes.

Treatment.—The large majority of calculi found in the bladders of females may be readily removed by lithotritry. The short and distensible urethra permits of the introduction of the largest evacuating-catheter, and greatly facilitates the operation. The crushing operation is preferable in small stones to the older method of dilatation or divulsion of the urethra and extraction in mass by forceps. A much larger stone may be crushed and removed from the female bladder than can possibly be done from the male organ within the limit of safety at a single operation. When lithotomy becomes necessary, the operator must choose between the *vesico-vaginal* and *supra-pubic* incision. In the former a second operation for vesico-vaginal fistula is essential. In case the patient is very fat, the low operation will be advisable. In ordinary sub-

jects the supra-pubic operation, carefully and properly done, offers the best prospect of speedy relief.

Foreign Bodies.—Foreign substances in the bladder are usually introduced through the urethra. Less frequently they pass through the walls of this organ, as in gunshot-wounds, etc. In exceptional instances foreign matter finds its way into this organ through a fecal or vaginal fistula. In several cases of this character worms have escaped from the intestines and found an exit through the urethra.

The symptoms are usually those of stone in the bladder, with cystitis in a varying degree. The diagnosis may be evident from the history of an accidental or intentional introduction of the foreign substance. The matter can usually be recognized by the searcher. If a few weeks have elapsed, the substance will probably be coated with a deposit of urinary salts, and will impart to the sound the grating or click peculiar to stone.

The *treatment* consists in removal of the offending substance as soon as possible. If it is small, round, and smooth, it may be extracted through the urethra, with the lithotrite. For this purpose the smallest instrument should be employed. If it is too large to be brought out in mass, it may be chopped up or crushed, and then extracted piecemeal, in the jaws of the lithotrite, or washed out through the evacuator. Fig. 598 represents an English gum catheter which was removed in this

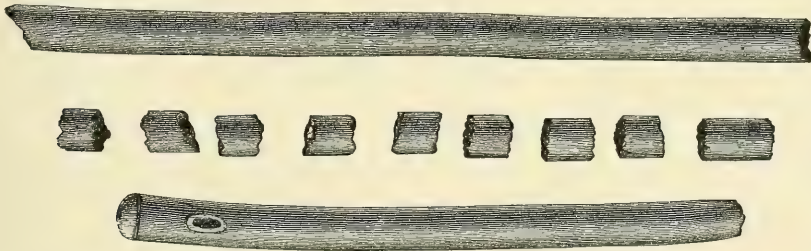


FIG. 598.—Gum catheter removed from the bladder by the lithotrite. (The author's case.)

manner. The two larger pieces were grasped by the end and drawn out; the remainder was caught in the lithotrite, and brought out one piece at a time.

When the substance is so large or of such a shape that it can not with safety be brought through the urethra, cystotomy is imperative. In determining upon the method of opening into the bladder, the same rules will apply as given for lithotomy.

The Prostate Body.—Disease of the prostate is almost always a condition of adult life. This organ is rudimentary in childhood, and while, from direct injury, as in catheterization, lithotomy, or any form of violence, or by the extension of any of the rarer forms of disease which affect the bladder or urethra of children, this body may be involved, it only assumes its true importance after it has taken on its functional activity.

Prostatitis.—Inflammation of the prostate may be partial or complete, as well as acute and chronic. It may affect the epithelial and glandular,

or muscular and connective-tissue structure of this complex organ. Prostatitis rarely originates in the substance of this body, being usually involved by extension of an inflammation from the bladder, urethra, or other organs and tissues in its immediate neighborhood. Urethritis, cystitis, epididymitis, and proctitis are among the more common causes of prostatitis. To these may be added excessive venereal excitement, all forms of traumatism, whether by violence applied to the rectal or perineal regions, or by instruments in the urethra, and the presence of calcareous or amylaceous concretions.

The *symptoms* are usually well marked. Pain in the acute form of inflammation is usually intense and burning in character. There is a sense of fullness and throbbing in the organ. With the finger in the rectum its enlargement may be appreciated, together with abnormal heat and throbbing of the arteries along its base. Pain is increased by direct pressure in the perinæum or rectum, and also in the act of urination. Fever is present in proportion to the severity of the local process. Suppuration and the formation of abscess are usually indicated by exacerbations of temperature and by interference with micturition.

The first indication in the *treatment* of this painful affection is rest in the recumbent posture. The bowels should be kept open. The ice-bag to the perinæum will be found agreeable and of value. If retention of urine occurs, it should be relieved by the use of the smaller soft catheter. Supra-pubic aspiration may be demanded in severe cases. Scarification of the perinæum and the application of cups are highly recommended as local measures. If abscess exists, it should be evacuated by the aspirator.

Rupture may occur into the urethra, or the abscess may find an opening through the perinæum or rectum.

Hypertrophy.—Chronic progressive enlargement of the prostate occurs in about one third of all males who live through the period from fifty to seventy-five years of age. The increase in volume is not a true hyperplasia, for the glandular functions, as well as the muscular power of the organ, decrease with the hypertrophy. In some portions of the mass the muscular tissue is increased, but the bulk of the enlargement is due to the presence of newly formed connective tissue. The induration is in

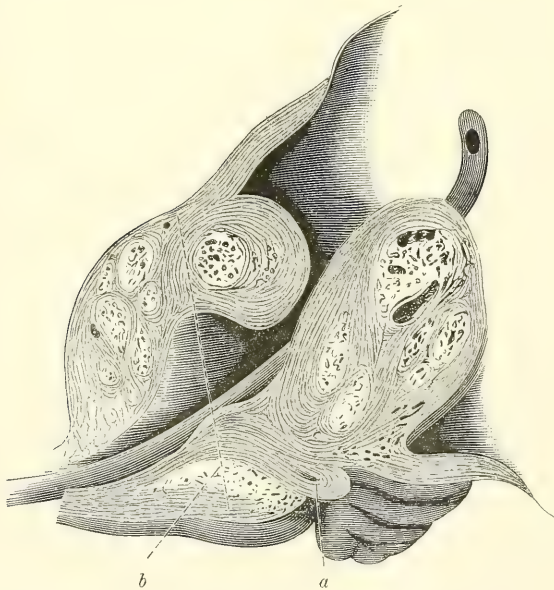


FIG. 599.—Longitudinal section of hypertrophied prostate, in a patient seventy-four years of age; showing a false passage tunneled by a catheter. *b*, Line of transverse section shown in Fig. 600. *a*, Duct of vesicula seminalis. (After Socin.)

proportion to the excess of the new tissue over the normal muscular and glandular elements. In some instances, though rarely, the glandular elements are increased; but this is, in great probability, only observed in the earlier stages of hypertrophy, before the connective-tissue elements are in sufficient quantity to cause atrophy of the glandular apparatus. The enlargement may be local or general. In general hypertrophy, while the increase in size is in all directions, it is more marked in the posterior portions, where it encroaches upon the neck of the bladder. Not infrequently one lateral lobe is greatly enlarged, or the hypertrophy may be central, resulting in the development of a middle or third lobe, which, by progressive enlargement, not only changes the axis of the normal urethra, but occludes, in a variable degree, the outlet of the bladder. This last condition is well shown in Fig. 599, and that of general hypertrophy of the muscular, fibrous, and glandular tissues, with narrowing of the urethra, in Fig 600.

Symptoms.—The increase in size is usually so gradual that the condition of hypertrophy does not attract the attention of the patient until interference with the flow of urine occurs. As a result of retention the bladder is distended, the contractility of its muscular walls is diminished, and chronic cystitis inevitably ensues. The changes which take place in this organ—thickening of the walls, occasional sacculcation, the formation of calculi, dilatation of the ureters, etc.—have been given. In severe cases the functions of the rectum may be interfered with.

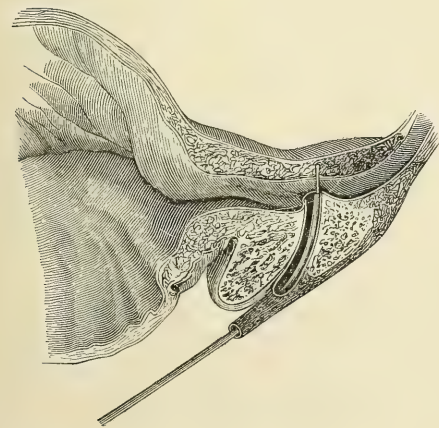

FIG. 601.—Showing the relations of the floor of the bladder to the prostatic urethra in the normal condition of this body. The bristle is passed from the ejaculatory duct into the urethra. (After Socin.)

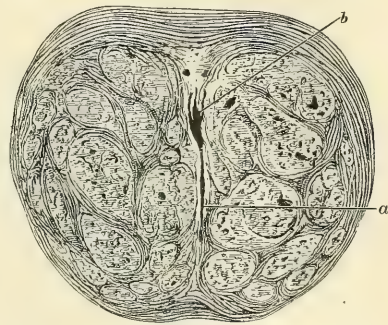


FIG. 600.—Transverse section through the center of the prostate of a patient seventy-four years old. Hypertrophy of fourteen years' duration. a, Urethra. b, Caput gallinaguinis. (After Socin.)

The *diagnosis* may be determined by the presence of the symptoms just given, by digital exploration by the rectum, and the introduction of a sound or bougie by the urethra.

The *treatment* is chiefly palliative. When recognized early in its history, every source of irritation should be removed from this organ. The bowels should be kept open, the irritability of the urine diminished by the administration of alkaline diluents, and all venereal excitement prohibited. In those affected with gout or rheumatism, judicious diet and medication may arrest, or at least retard, the progress of the disease in the prostate.

When symptoms of obstruction to the escape of urine supervene, operative interference is frequently called for. If the hypertrophy is general, and the caliber of the urethra is encroached upon, dilatation by means of the olive-pointed French bougies or the conical steel sounds

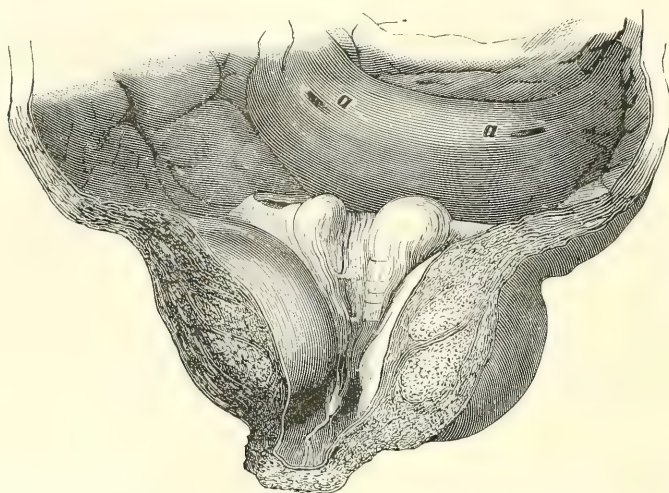

FIG. 602.—Hypertrophy of the prostate, showing the asymmetrical development of the middle or third lobe. *a a*, Openings of ureters. (After Socin.)

may be required. When the enlargement is chiefly in the posterior portions of the organ, dilatation is not indicated. In order to prevent cystitis, it is important that every effort should be made to thoroughly empty the bladder at each act of urination.

The relation of the urethra to the base of the bladder, in the normal condition of the prostate, is well shown in Fig. 601. The impediment to the complete evacuation of the bladder in enlargement of the posterior and middle portions of this body may be more readily understood by referring to Figs. 602 and 603.

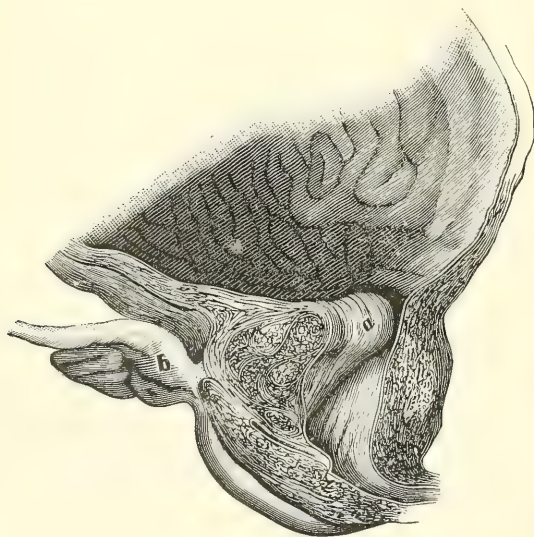

FIG. 603.—Antero-posterior section of the same specimen.

may be overcome and benefit gained by evacuating the bladder, with or without the catheter, in the knee-shoulder position. The introduction

If the sitting or standing posture is maintained, it is evident that a certain quantity of urine will remain in the *cul-de-sac*, behind the prostate, even if the ball-valve formed by the hypertrophied middle lobe is held back by the catheter. In many cases this difficulty

of the catheter in prostatic hypertrophy is such an important feature in the treatment of this disease, and at times is surrounded with such difficulties, that it becomes important in each case to study the condition of the neck of the bladder and urethra, to determine, with as much accuracy as possible, the deviation of this channel from the normal.

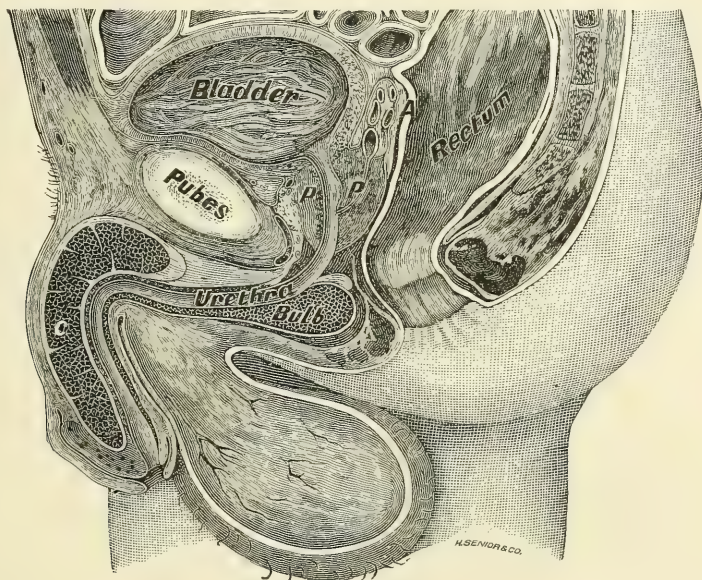


FIG. 604.—The normal urethra of a male adult. From a frozen section. Reduced from life size. (After Braune.)

The normal curve of the urethra is shown in Figs. 604, 605. When hypertrophy of the prostate occurs, the distortion is practically an elongation and exaggeration of the natural curve from the triangular ligament back to the opening into the bladder (Figs. 606, 607).

In the exploration an olive-pointed black French catheter, in size about No. 14 (U. S. scale), will be found to be a safe and satisfactory instrument. If warmed and oiled, it will usually pass to the neck of the bladder without resistance, and, in a majority of instances, the obstruction may be overcome by pushing steadily upon the catheter. No harm can arise from this procedure. If, however, the bladder is not entered, the instrument should be withdrawn, armed with the wire stilet, bent to suit the curve of the deep urethra, and again introduced. A careful degree of force may now be employed to overcome the obstruction,

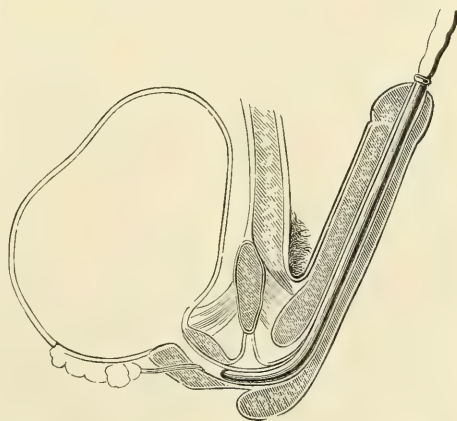


FIG. 605.—The sound passing around the normal curve of the urethra. (After Van Buren and Keyes.)

but undue violence must be avoided. The distal end of the catheter and stylet should be well depressed in the effort to pass by the obstruc-

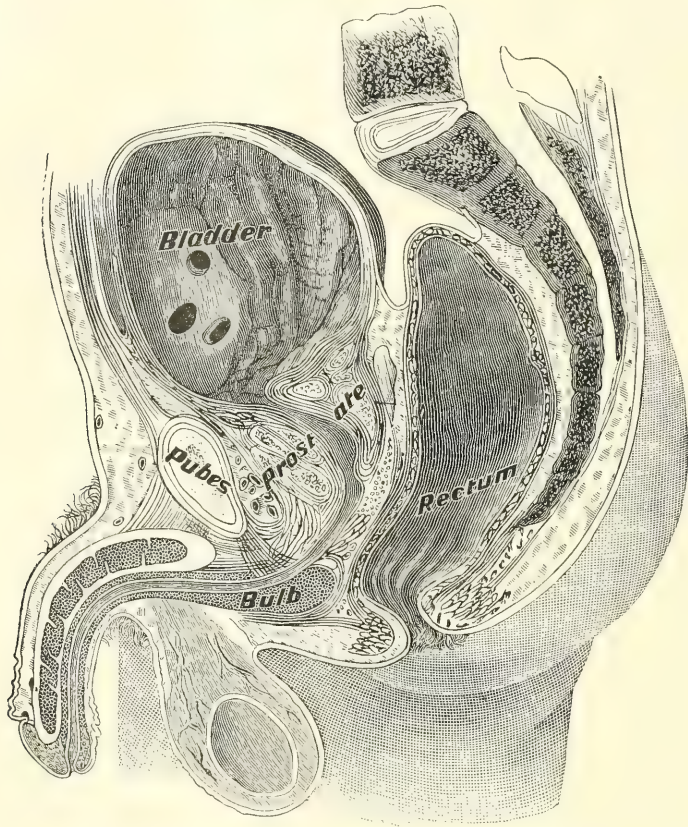


FIG. 606.—The change in the direction of the urethra caused by hypertrophy of the prostate. (After Socin.)

tion. If the manœuvre is successful, the stylet is withdrawn, leaving the catheter in position until the bladder is emptied. If the introduction can not be effected, supra-pubic aspiration may be done, and

the patient should be put to bed and narcotized with morphia. Under the quieting influence of this remedy spasm of the muscular fibers of the prostate and vesical neck is allayed, frequently resulting in temporary relief from retention. Its value can scarcely be overestimated in the management of obstinate cases of retention and cystitis caused by prostatic hypertrophy.

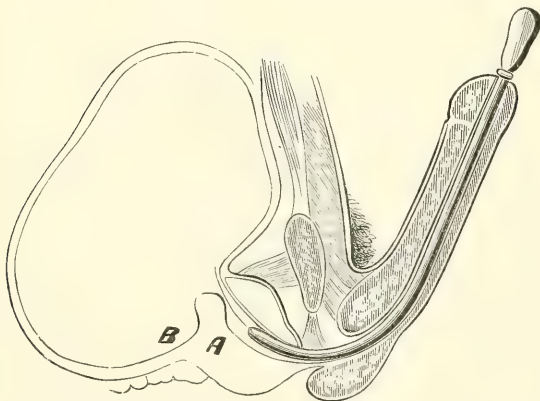


FIG. 607.—Showing the increase in the curve of the urethra in prostatic hypertrophy, and the necessity of a longer curve in the catheter. (After Van Buren and Keyes.)

The propriety of operative interference, beyond catheterization or puncture of the bladder, may be entertained in a certain proportion of cases. It is especially indicated when intense urethritis is caused by the necessary and repeated catheterization. Under such conditions, *cystotomy* may be done, or an effort may be made to destroy the hypertrophæ by Mercier's instrument.

Supra-pubic cystotomy offers the most accessible route to this cause of obstruction, and is not attended with great danger. In one of the author's cases, the hypertrophy was identical with that shown in Fig. 608, and was readily removed. The patient was sixty-nine years of age, and for seventeen years had used the catheter. After the operation, the urine could be passed *per urethram*.

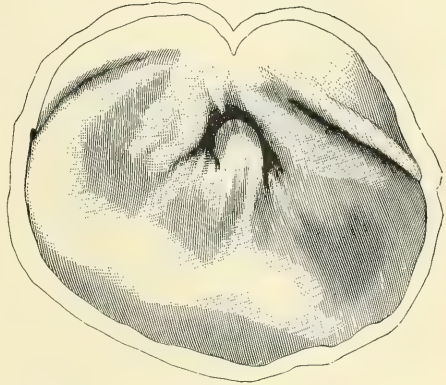

FIG. 608.—A ridge of hypertrophied prostate seen from within the bladder. (After Socin.)

Mercier's excisor is shown in Fig. 609. In construction it resembles the lithotrite, with the exception that the beaks are shorter and are not serrated. The mechanism of the instrument is practically the same. The operation is performed as follows: The kiotome is closed, oiled, and

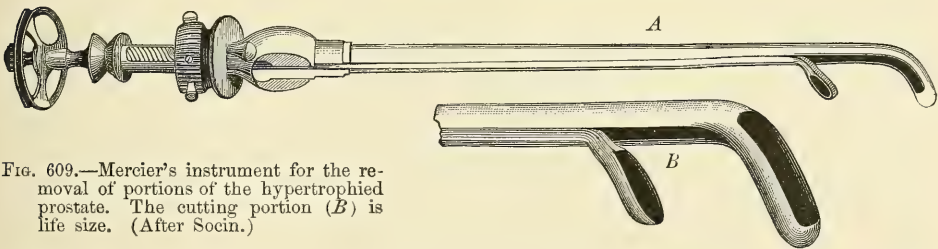


FIG. 609.—Mercier's instrument for the removal of portions of the hypertrophied prostate. The cutting portion (B) is life size. (After Socin.)

carried into the bladder, which should be fairly distended. The operator should move the instrument about freely, and turn it on its axis, in order to be assured that it is well within the organ. It is then withdrawn, with the beak pointing upward, until it is felt to be arrested at the opening into the urethra. While in this position the blades are separated a half-inch, the instrument forced to one side (the patient's right), then steadily turned to the left and closed. If the obstruction is seized by this manœuvre the screw-movement is adjusted, and the part grasped is cut off and withdrawn with the closed instrument. Mercier's procedure, although not frequently performed, has met with a success which justifies its repetition. In well-selected cases it can not but be useful, and when the urethra and bladder are carefully accustomed to the use of a catheter, it gives little pain or inconvenience. The employment of an anæsthetic is not indicated, the sensation of the patient being of value in aiding the surgeon to determine when the tissue is grasped.

In hopeless cases of cystitis resulting from obstruction of the urethra, from prostatic hypertrophy, cystotomy, with the establishment of a permanent urinary fistula, may become necessary. The various methods of performing this operation have already been described.

Prostatorrhœa.—Chronic prostatitis, or catarrh of the prostate, in a majority of cases follows an acute inflammation of this organ. Its chief cause is, therefore, an extension of a cystitis or urethritis to the epithelial lining of the glandular portions of this body. In a certain proportion of cases it originates as a subacute inflammatory process located in the glandular substance. It is in this form most frequently seen in weak, scrofulous, or tubercular adults about the period of puberty. Prostatorrhœa is a symptom of general hypertrophy of this organ in the earlier stages of enlargement, gradually diminishing as the connective-tissue hyperplasia encroaches upon and destroys by compression the glandular apparatus.

The leading symptom of this disease is the discharge of a small quantity of bluish-white fluid from the meatus. It is noticed particularly by the patient before the first micturition in the morning, having accumulated during the night. A drop or two may be squeezed from the urethra by pressure along the under surface of the penis from the perinæum forward. It is carried out with the first flow of urine, and, if not observed previously, usually escapes notice. In the severer type of cases the prostatic fluid may be seen immediately after urinating or during the intervals of micturition, as a bluish mucus, moistening the meatus and prepuce, and slightly tenacious and stringy when wiped off. This fluid is also frequently observed when the contents of the rectum are discharged, especially if the fæces are hard and fully formed. Prostatorrhœa occurs in excessive or prolonged venereal excitement.

The *diagnosis* of this affection depends upon the exclusion of spermatorrhœa and urethritis. The symptoms of spermatorrhœa are in general so similar to those of prostatorrhœa, that a positive differentiation can only be made by microscopical examination. The fluid which escapes may be examined alone, or the first ounce or two of urine passed after a comparatively long interval in urinating may be caught in a separate vessel, allowed to settle, and a drop of the sediment placed upon the slide. The presence of spermatozoa will confirm the diagnosis of spermatorrhœa. The urine first passed after a discharge of semen should not be examined, since under such conditions these elements are found in perfectly normal subjects. In differentiating between prostatorrhœa and gleet, the exploration of the urethra will be necessary. The absence of a stricture or of marked tenderness in the canal in front of the prostatic portion will exclude urethritis, with the exception of a rare form of chronic follicular urethritis, which, as will be seen further on, may or may not be preceded by a gonorrhœa or stricture. In follicular urethritis, tenderness is not marked. If a large-sized bulbous wire bougie is carried back to the membranous portion of the urethra, and is then withdrawn while the urethra is held in close contact with it, the yellow-

ish-white flakes or plugs of cheesy material will be squeezed out of the follicles and be seen adhering to the bulbs.

Treatment.—The correction of any diathesis which predisposes to a catarrhal condition of the mucous membranes is an important step in the general treatment of prostaticorrhœa.

Among the local measures, distention of the prostatic urethra by the introduction of steel sounds, is advisable. The larger sizes should be employed, and if the meatus is so narrow that it will not admit No. 20 or 21 (U. S.), it should be incised up to this point as a preparatory measure. When stricture exists, internal urethrotomy should be performed. The dilatation may be commenced with No. 17 and increased to No. 21 at a single operation; or, if the procedure is attended with pain of a severe nature, the larger numbers may be used at the third or fourth introduction. The point of the sound should not be carried farther than the neck of the bladder, which is between seven and eight inches from the meatus. The operation should be repeated from two to three times a week—not often enough to cause a general urethritis.



FIG. 610.—Van Buren's cupped sound.

Local medication is at times of great value. The cupped sound (Fig. 610), which consists of an ordinary instrument with from six to eight spoon-shaped depressions just beyond the curve, is a valuable instrument. In employing it, a stiff salve must be made by mixing the medicine required with simple cerate. Lard melts too rapidly, and is therefore objectionable. The cups are filled just to the level of the surface, the instrument thoroughly lubricated and rapidly carried down to the prostate, where it is allowed to remain for several minutes, until the heat of the part melts the salve. Tannic acid (grs. x-xx or xxx to ζ j) or acetate of lead or nitrate of silver, in proper proportions, may be thus employed.

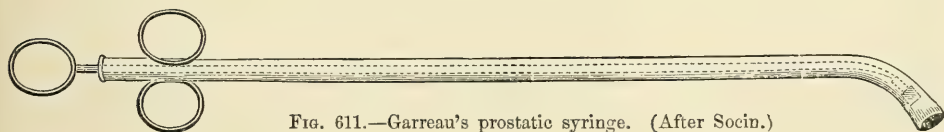


FIG. 611.—Garreau's prostatic syringe. (After Socin.)

Another method is the introduction of silver nitrate or other escharotics or astringents by means of the canulated sound (Fig. 611), which consists of a metal tube shaped like a catheter, through which a stylet-piston plays. A sufficient quantity of the ointment is placed in the cylinder near its open end, and the piston introduced. When the tip of the instrument arrives at the prostate, it is emptied by forcing the piston down, at the same time slightly withdrawing the catheter in order to distribute the contents over the entire prostatic surface.

It is readily understood that, locally applied, no agent is carried to the deeper portions of the glandular substance, but the inflammation precipitated in the more superficial glands and the ducts of those more deeply situated, may readily travel along the epithelial lining until the entire gland-tissue is involved.

Beyond the danger of a temporary elevation of temperature which may occur in patients subjected to urethral exploration, the additional dangers of cystitis and epididymitis should not be disregarded. The use of the double-current closed catheter, with hot or cold water, is one of the most satisfactory and safe methods of treating this disease. Its employment will be described in the treatment of chronic follicular urethritis. The prognosis in prostatorrhœa should be guarded, for many cases obstinately resist the most careful and energetic measures of treatment.

Spermatorrhœa.—This term is used to designate the escape of semen from the ejaculatory ducts without an orgasm. This fluid may find its way into the bladder, but usually escapes by the meatus. The symptoms of this disease do not differ materially from those given in prostatorrhœa. The diagnosis can only be made certain by the recognition of the spermatozoa with the aid of the microscope. It occurs at times in conditions of great physical prostration, as a result of excessive and unnatural venereal indulgence, and from interference with the function of the muscular elements of the prostate.

The *treatment* is general and local. Measures looking to the improvement of the moral and physical condition of the patient should be adopted. The local treatment is the same as that given for prostatorrhœa.

Aspermatism.—The spermatozoa are wanting in adults whose testicles have been removed or destroyed by disease, in patients in whom both organs have failed to descend and have undergone atrophy; in all cases of complete obstruction of the *vasa deferentia* or ejaculatory ducts, and in certain cases of senile atrophy of these organs. These conditions are rarely amenable to surgical treatment.

Tuberculosis of the Prostate.—Tubercular disease of this organ, though rarely observed, may be primary, or more frequently is secondary, to tubercular deposit in other viscera, as the testis, epididymis, lungs, etc. It is more apt to occur in the young and middle-aged than in the old. The diagnosis can not, as a rule, be easily made. In some cases there are no symptoms of tuberculosis. If with a subacute or chronic lesion of this organ there is a history of phthisis, the deposit of tubercular matter may be suspected. When the febrile movement, hectic, profuse sweats and emaciation of this disease are present, a correct diagnosis is readily made. The enlargement and nodular character of the prostate may be made out by digital exploration by the rectum. The treatment is altogether palliative.

Carcinoma.—Cancer of the prostate is also rare. It is more apt to occur primarily than by metastasis. Primary cancer of this organ is more frequently seen in young adults than in the old. In the middle-

aged and old it is more likely to occur by invasion from a neighboring organ, as the rectum.

In the earlier stages the symptoms of this disease do not differ materially from those of simple hypertrophy. As simple hypertrophy is rare in the young and middle-aged, the presence of a tumor of this organ at this time of life should be regarded with a suspicion of malignancy. The absence of the symptoms of abscess is in some degree a confirmation of this suspicion. If the tumor develops rapidly, carcinoma or sarcoma may be diagnosticated, for, although the disease may continue for one or two years, or even longer, the invaded organ soon assumes a size not met with in non-malignant hypertrophy. Hæmorrhage of a profuse character is apt to follow the introduction of a sound or catheter when carcinoma or sarcoma is present.

Sarcoma is also rare in this organ (Fig. 612). It is more apt to occur in the young than in the middle-aged and old. The symptoms differ in no essential feature from those present in cancer. The *prognosis* of both diseases is grave, and the treatment palliative.

Prostatic Concretions.—Concretions in this organ are of two kinds—the *corpora amylacea* and *calculi*.

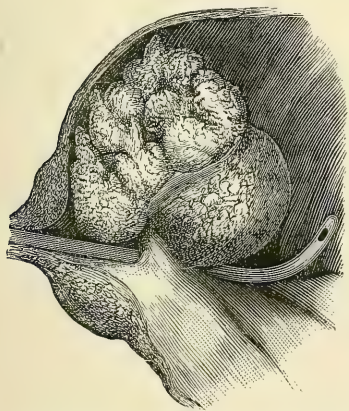

FIG. 612.—Sarcoma of the prostate and neck of the bladder, with obstruction. The catheter has tunneled the neoplasm. (After Socin.)

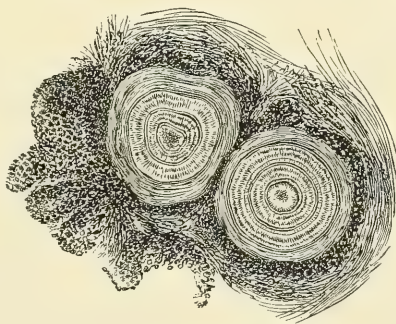


FIG. 613.—Calculi in the prostatic follicles. (After Socin.)

The former are small bodies which frequently exist in the follicles of the prostate. Their mode of origin is unknown. They give the well-known amyloid reaction with iodine. Stone in the prostate may originate in the deposit of inorganic elements from the blood and fluids of this organ, either in the follicles originally (Fig. 613) or as accretions upon the amyloid bodies just described.

The *symptoms* of prostatic concretions are chiefly those due to the inflammation or enlargement which they produce. *Corpora amylacea* not infrequently exist in the prostate, causing little or no discomfort. When of large size, especially when they grow by reason of a deposit of inorganic substances, they cause inflammation of the follicles and destruction of the glandular epithelia. A positive *diagnosis* can only be made by bringing a sound or catheter in contact with the concretion. When the stone is situated in the deeper portions of the organ, it will

escape detection by this method, but the tumefaction it causes may be recognized by digital exploration *per rectum*.

The interference with the escape of urine caused by calculi of the prostate is analogous to that which occurs with general hypertrophy of the body of this organ. The stream of urine is diminished, but remains about the same size, and escapes steadily throughout the act of urination. There is no sudden and complete interruption of the current, as in stone in the bladder, or in enlargement of the middle lobe of the prostate. Calculi of this organ may escape into the urethra and lodge there, or work their way back into the bladder, or pass out at the meatus.

The *treatment* is palliative until operative interference is necessitated on account of dysuria. An exploration should be made by the suprapubic incision and an effort made to remove the concretion from this side. Failing in this, a perineal incision is necessitated, but the prostate should not be incised if it can be avoided. The stone may be removed with the scoop or narrow forceps.

Neuralgia of the prostate and neck of the bladder is occasionally met with. Pain is present in this organ when no symptoms of inflammation are discoverable. It is usually exaggerated during and immediately after micturition, and after a seminal emission. The introduction of a sound shows great tenderness of the deep urethra. The instrument carried into the bladder does not produce the tenesmus and pain common to cystitis. An examination of the urine will demonstrate the absence of pus, which will also serve to exclude inflammation of the bladder or prostate. The causes of this affection are as a rule obscure. Irregular or excessive venereal indulgence is considered to be one of the most frequent causes of neuralgia in this organ. The treatment involves the removal of every possible source of irritation. The constitutional measures recommended in neuralgia in other parts of the body should be employed. Locally the galvanic current is especially indicated. If the urine is extremely acid and burning, benefit will be derived from the administration of large quantities of alkaline and diluent drinks.

THE URETHRA.

Urethritis.—Inflammation of the urethra may be traumatic or idiopathic, specific or non-specific, local or general. Among the more frequent causes of traumatic urethritis are direct violence from without, applied to the perinæum or penis; violent and excessive sexual intercourse; the introduction of instruments or corrosive substances; and the lodgment of foreign bodies carried in from without, or of vesical or prostatic calculi, etc. It is usually of short duration, mild in character, and involves only a limited portion of the canal.

The treatment demanded is rest, the removal of the cause of the irritation, and the dilution of the urine by the exhibition of alkalies and diuretics.

Specific urethritis (gonorrhœa) is a violently contagious disease affect-

ing the mucous membrane of this canal, at times extending into the bladder and seminal vesicles, and along the vasa deferentia to the epididymis and testicle.

The agent of contagion is now believed to be a specific micro-organism, the *gonococcus*. If the purulent discharge of an acute specific

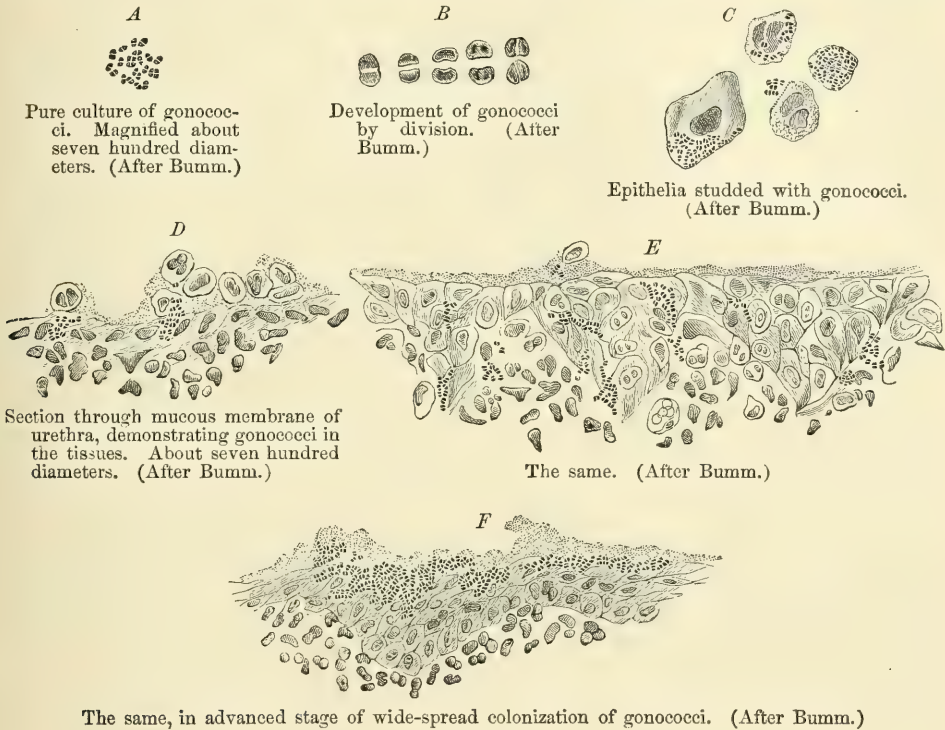


FIG. 613 A.

urethritis is examined under the microscope, in the pus corpuscles chiefly and in the cast-off epithelia are seen numerous dark granular bodies (Fig. 613 A). The epithelial lining of the urethra and the peri-urethral tissues, as shown in Fig. 613, F, become deeply invaded by these organisms where they rapidly multiply, producing deep and wide-spread destructive inflammatory changes. The epithelia are destroyed and cast off; schools of leucocytes crowd into the inflamed area, and are thrown off in the transuded *liquor puris*. As the intensity of the process subsides, repair takes place, by restoration of the epithelial lining in mild cases, by cicatrization and consequent narrowing of the urethral caliber in severe cases, producing *organic stricture*.

The demonstration of these facts in the pathology of *specific urethritis* should have great weight in the application of the therapeutic measures to this disease, for it is evident that no local remedial agent which does not destroy the mucous membrane of the urethra, and thereby add to the inflammatory process, can destroy the cocci imbedded in the submucous tissues.

When the virus is brought into contact with a mucous surface, the

period of time which elapses before the local symptoms of inflammation are noticeable will vary in different individuals, and even in the same patient at different inoculations. It is very probable that the condition of the mucous membrane at the time of the contact has more to do with the rapid appearance of the inflammation than any variableness in the quality of the virus. The period of incubation may range from a few hours to several days, and in some very exceptional instances as much as two weeks have elapsed between the contact and the recognition of the inflammatory process. The limit between twenty-four hours and three days will include a large majority of cases of specific urethritis.

Usually the earliest symptom of gonorrhœa is a burning sensation at the meatus, which is more acute as the urine is escaping. The lips of the meatus soon become swollen and unusually prominent and red. If carefully separated, a film of muco-pus will be seen to coat over the mucous membrane.

The *first stage* of the disease may be considered as beginning with the date of contact with the virus, and ending with the first appearance of the suppuration. The average duration of this stage is from two to ten days. From this period the inflammatory symptoms increase for from three or four days to as much as two weeks. The quantity of pus discharged varies from a few drops to several drachms in the twenty-four hours. It is increased by exercise as well as by improper diet. The color varies from the bluish-white hue of the first few drops to the yellow or yellowish-green tinge of that discharged during the height of the inflammatory process. In some instances it becomes stained with blood, as a result of the rupture of capillaries in the engorged mucous membrane.

The *second stage*, or that of *increasing inflammation and suppuration*, lasts usually about twelve days, and is followed by the *third stage*, or that of *decreasing inflammation and suppuration*, the duration of which period is usually from three to six weeks.

In addition to the purulent discharge and the pain which characterizes the second stage of this disease, there is also a diminution in the size of the stream of urine, due to the swollen and puffy condition of the mucous membrane of the urethra. In the milder forms of gonorrhœa no other symptoms are present in the second stage. Not infrequently, however, the inflammatory process extends into the prostatic urethra, and thence to the bladder or along the seminal ducts to the vesicles and testes. Infiltration of the vascular erectile tissue of the corpus spongiosum occurs in a varying degree in all instances, and occasionally the exudation extends into the corpora cavernosa. A more frequent complication of gonorrhœa is inflammation of the glans penis (*balanitis*) and of the prepuce (*posthitis*), due not only to the mechanical effects of the discharge, but to direct invasion by contagion. As a result of such extensive infiltration, the penis is subjected to various deformities, painful in an extreme degree, and not without danger to the integrity of this organ.

Chordee, or bowing of the penis, is a common symptom. The organ

is in part or wholly erected, and on account of the infiltration of the vascular spaces of the corpus spongiosum with the embryonic inflammatory tissue, it fails to expand with the corpora cavernosa.

Balano-posthitis, in the case of a long and tightly fitting prepuce, becomes at times an annoying if not a serious complication. Complete *phimosis* may occur as a result of the swollen condition of the prepuce, or, when the foreskin is slipped behind the corona glandis, *paraphimosis* may ensue. If not relieved, gangrene in most cases is imminent.

These complications are as a rule a part of the second stage of gonorrhœa, occurring within the first eighteen days of an attack, and gradually disappearing during the third stage.

Pathology.—Strictly speaking, the morbid process is an inflammation of the mucous membrane of the urethra and the submucous connective tissue. The extension to other organs is purely accidental. It commences at the meatus and travels backward. The epithelium is swollen, there is marked hyperæmia of the submucous tissue, with the escape of leucocytes and the formation of the common embryonic tissue of inflammation. In milder cases the products of inflammation undergo retrogressive changes, and are absorbed; while in other instances connective-tissue development is precipitated, ending in cicatrization and the formation of stricture. The organic elements of gonorrhœal pus are leucocytes, embryonic cells, epithelia, and blood-corpuscles.

The *diagnosis* of specific urethritis may be made out from the succession of symptoms given. It can rarely be mistaken. It is at times necessary to differentiate gonorrhœa from simple or non-specific urethritis. The latter disease lacks every symptom of virulence which is characteristic of the former. Within the first few days of an attack it is not always easy to make a positive diagnosis, but after the first week is passed the symptoms are evident.

Treatment.—Gonorrhœa is a self-limited disease, running a given course, and under favorable conditions ending in recovery without the aid of medication.

Efforts to abort the disease by the injection of corrosive substances are not justifiable. Any substance capable of destroying the virus of gonorrhœa is also capable of doing damage to the urethra, more serious in its consequences than those of the worst forms of the disease left without medical interference.

When specific urethritis is recognized in its earlier stages, the patient should be impressed with the importance of rest, and the regulation of his diet and manner of living. It is important that the danger of inoculation of the conjunctiva, or other mucous surfaces, with the virus, should be emphasized. If necessity compels the patient to take the increased risk which exercise implies, the physician should relieve himself of this much of responsibility by insisting upon the minimum of physical exertion. The diet should be nutritious yet simple, and stimulating beverages, as coffee and the alcoholic group, should be forbidden. Tea is not so objectionable as coffee, except when it induces sleeplessness. The bowels should be kept open by the use of fruits and

the administration of the mild, laxative waters. The administration of citrate of potash, in doses of grs. xx, four or five times a day, will have a beneficial effect upon the urine and the urethra. It may be conveniently taken in a glass of water to which the juice of half a lemon has been added. A hip-bath in warm water every night and morning not only insures a degree of cleanliness which is desirable, but is not without value as an antiphlogistic.

In addition to these general features of treatment to be carried out during the first and second stages of gonorrhœa, certain local measures are equally important. One of the chief of these is to secure free discharge of the pus from the urethra and prepuce. The penis should be kept pendent, and, if possible, the prepuce worn so as to leave the gland exposed. The common practice of stuffing a piece of lint or a tuft of absorbent cotton over the meatus and beneath the prepuce, and then pressing the foreskin over this to hold the plug in place, thus stopping up the urethra when free drainage is essential, and holding the acrid discharge in contact with the glans and prepuce when these should be protected, is exceedingly objectionable. Scarcely less so is the habit of tying rags, lint, or cotton about the penis, for these dressings interfere with the circulation in this organ.

A bag of oiled-silk, rubber tissue, or, if these can not be obtained, of ordinary cloth, should be made large and long enough to fit loosely over the penis. It is held in place by strings which pass up to a belt worn around the waist. A pellet of absorbent cotton in the bottom of this bag suffices to catch the pus which drips from the meatus. It is usually necessary to have two of these bags, for purposes of cleanliness. The various complications of gonorrhœa, as cystitis, prostatitis, epididymitis, orchitis, etc., have been, or will be, considered under their respective heads.

For the control or relief of chordee the following rule of practice will suffice: The patient should be advised to refrain from sleeping on the back, and should be directed to empty his bladder at more frequent intervals than ordinary. When the attack is precipitated, standing with the naked back in contact with the wall, or some cold surface, will often cause the erection to disappear. The same may be said of the local use of ice or cold water. A full dose of bromide of potassium and chloralhydrate at bedtime, and repeated at intervals, if necessary, is, however, the surest way to control the more annoying and obstinate cases.

Injections of the urethra in gonorrhœa should be made with great care. They are contra-indicated in the acute inflammatory and suppurative stages of this disease. Deep injections, which necessitate the introduction of a catheter down to the cut-off muscle, are not advisable. The germs of this disease are in great part lodged in the sub-mucous tissues and beyond the contact of any agent intended for their destruction. The harm done by the invasion with a foreign body is not counterbalanced by any good effect of the injection. Usually, from the tenth to the twentieth day after suppuration is noticed, if the foregoing measures have been faithfully carried out, the character of the discharge is changed from the

yellow, thick, and profuse pus of acute gonorrhœa, to the scant, whitish, milky fluid of the later stages of the inflammation, and, with this, the painful symptoms have also disappeared. It is not until this period is reached that the use of an injection should be entertained. Nitrate of silver, locally applied, possesses more curative properties than any other agent, but it is objectionable on account of the discoloration it produces. The injection which is least objectionable is composed of acetate of zinc in dilute solution of subacetate of lead. From gr. j to iij of the zinc

may be used to \bar{z} j of the lead solution. The weaker preparation is in general to be preferred. The urethral syringe should be selected with



FIG. 614.—The proper syringe for gonorrhœa.

great care. Fig. 614 represents a proper instrument. It contains about \bar{z} ij, has a conical nozzle, and can be used with one hand. The long-nozzled, pointed syringe should never be employed. In its use the point strikes against the mucous membrane, causing an exaggeration of the inflammatory process at this point, not infrequently resulting in stricture.

An injection should be performed as follows, and each patient should be thoroughly schooled before he is intrusted with its employment upon himself: The bladder should not be emptied. The bottle containing the injection-fluid should be shaken, and a quantity sufficient to fill the syringe twice emptied into a cup, and drawn into the instrument as needed. The syringe is now held with the point upward, and the piston pushed up until the air which may have entered with the fluid is expelled. A small quantity of oil or vaseline is rubbed upon the tip of the syringe, the patient lies upon his back, the glans penis is held between the fingers of the left hand, and the index-finger is carried through the ring on the end of the piston, while the cylinder is grasped between the thumb and middle finger. The conical end of the syringe is now introduced into the meatus, and pressed in with sufficient firmness to prevent the escape of the fluid while the contents of the cylinder are slowly emptied into the urethra. With a syringe of this capacity there is little danger of overcoming the resistance of the compressor-muscle, and thus forcing the injection-material back into the bladder. Should this accident occur, the urine which is in this organ will dilute the zinc so freely that its irritating properties will be lost. In making an injection the urethra should be well distended, so that all parts of the mucous surface, as well as the follicles, may be brought in contact with the fluid. After holding the injection in the urethra for from one to three minutes it may be allowed to run out, and the patient directed to empty his bladder. A second quantity, about one third less than the first, is again injected. These injections should be repeated night and morning, and, if convenient, at noon. Upon the supervention of any marked symptoms of irritation, as cystitis or an increase of the urethral inflammation, or epididymitis, etc., they should be immediately discontinued. The period in the history of a gonorrhœa when internal medication may be used with advantage varies

from the third to the fifth week of the disease. In the acute stages, while the inflammatory symptoms are prominent, they are contraindicated. The oil of sandal-wood and balsam of copaiba are the more useful remedies of this class. The former, in doses of five to ten drops, from five to ten times a day, is more readily borne by the stomach, and does not cause the rash which not infrequently follows the administration of copaiba. These remedies, however, very often can not be taken, and should not be persisted in when they interfere with the functions of the stomach. Even when thus carefully managed, the annoying symptoms of gonorrhœa continue for from four to eight weeks, and in most cases there is a slight watery or mucous discharge for several weeks after the case passes out from the immediate notice of the practitioner. Upon the whole, the effect of treatment upon the duration of this disease is not entirely satisfactory.

Among the unpleasant *complications* of gonorrhœa are balanitis, posthitis, paraphimosis, prostatitis, cystitis, epididymitis, orchitis, bubo, ophthalmia, and retention of urine.

Balanitis and *posthitis*, inflammation of the glans and prepuce, are conditions existing in a varying degree in almost all cases of gonorrhœa. Among the circumcised, or those with short and retracted foreskins, posthitis need not occur, but the acrid discharge will always affect the epithelial covering of the glans in the immediate neighborhood of the meatus. When the foreskin is long and adherent, or not readily drawn behind the glans, it usually becomes swollen and tense, retains the irritating discharge, and inaugurates an exceedingly painful and annoying condition of phimosis. Even when thus swollen, if the prepuce can be retracted, it is apt to be caught behind the corona and become irreducible, with ensuing strangulation, if not relieved by operative interference. Preputial sloughing will occur in a certain proportion of neglected cases.

In the treatment of gonorrhœa certain measures were detailed looking to the prevention of these complications. When, however, they are present in a mild degree, balanitis and posthitis disappear with proper attention to cleanliness. The glans and prepuce should be irrigated by being submerged in a vessel of warm water. Soap should not be employed. The hip-bath, already given as useful in the general management of the disease, is especially so in this complication.

The inflammatory phimosis of gonorrhœa, as of non-specific *balanoposthitis*, demands active measures of treatment. In milder cases it may suffice to maintain cleanliness by the frequent sub-preputial injection of tepid water. For this purpose a syringe with a delicate dull point or nozzle, about an inch in length, is needed. It should be oiled, carefully introduced between the glans and prepuce, and the contents slowly discharged. An irrigating apparatus may also be attached to the nozzle, and a continuous current applied, which does away with the irritation of repeated introductions of the nozzle. If these milder measures do not relieve the pain, tension, and threatened strangulation, an incision should be made. The prepuce may be nicked in several places, or a director

introduced in the median line above, along the groove of which a bistoury is carried, and the division effected.

When inflammatory paraphimosis exists, adhesions rapidly occur at a point just behind the corona, on the dorsum penis, rendering a reduction impossible unless these transverse bands are divided. The reduction of a paraphimosis is undertaken in this manner: The organ is held in a vessel of cold water for a few minutes, or cold cloths are wrapped loosely over and around the swollen parts. When removed, the glans and prepuce are thoroughly lubricated, and the organ grasped so that while the soft parts of the thumbs press the glans backward, the fingers are drawing the prepuce to the front. Or the penis may be grasped by the thumb and finger of the left hand, and the foreskin drawn forward while the glans is pushed backward by the thumb and fingers of the opposite member. When the reduction is accomplished, the patient should be directed to make every effort to prevent a recurrence of the accident.

If the efforts at reduction fail, the contractions on the dorsum, behind the glans, should be divided by one or more incisions in the long axis of the penis. Œdema of the prepuce, especially of the lower portion, is apt to occur, even in cases of recent paraphimosis, and, when the condition has existed for a day or two, infiltrations occur, which may persist for a long time after the constriction is relieved.

Prostatitis and cystitis, occurring with gonorrhœa, require treatment not differing from that already given. *Retention* must be relieved by the small soft catheter, or by supra-pubic aspiration. *Epididymitis*, or inflammation of the vas deferens and the globus major and minor, is one of the most painful complications of gonorrhœa. Perfect physical quiet, with support of the scrotum and testicle, are essential. The last of these measures may be secured by using the handkerchief sling, which is made as follows:

Attach a belt or piece of roller around the waist, above the pelvis; fold a good-sized silk handkerchief in a triangular shape, carry the center of the long side of this triangle beneath the scrotum, at

the perineo-scrotal junction, attach one of the long ends to the belt, near the anterior superior spine of the ilium, on either side, and bring the short piece directly upward, in front of the scrotum and penis, and pin it to the belt in the median line; or the ends may be tied just above the root of the penis (Figs. 615, 616).

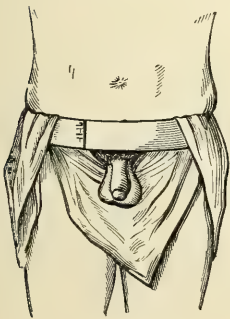


FIG. 615.

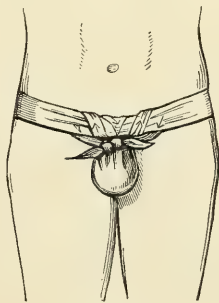


FIG. 616.

Handkerchief suspensory. (After Hill.)

Another method is to place a three-cornered cushion beneath the scrotum, close up to the perinæum, and allow the testicles to rest upon

this support; or two thickly folded towels may be pinned together and carried tightly around the thighs, at the level of the perinæum.

At times the tension of the parts is so great that, not only to relieve pain, but to prevent suppuration or possible gangrene, puncture or incision is imperative. The most immediate relief will follow this operation. A sharp narrow blade is preferable, and, if the instrument is not made for this especial purpose, it may be extemporized by projecting the point of an ordinary sharp-pointed bistoury half an inch beyond the surface of a cork through which the knife is thrust. With this guard attached, the punctures may be made rapidly and without danger of penetrating too deeply.

Although the procedure is very painful, it is usually so rapidly accomplished that an anæsthetic is not necessary. The injection of a 2-per cent cocaine solution will afford a fair degree of anæsthesia. The operator holds the scrotum and testicle so as to make tense the skin over the epididymis and to expose it properly to view, and then by well-directed and rapid thrusts punctures the organ in from two to four or six points, scattered over the induration. A free discharge of dark or black blood usually follows, and in from twenty to thirty minutes the pain is greatly if not entirely relieved. The antiseptic precautions should be carried out in this procedure.

Partial or complete *orchitis* is not infrequent in gonorrhœa with epididymitis. The treatment is in general similar to that of the last-named disease. The diagnosis is readily made out by the touch, for, when hydrocele does not coexist, the induration of the organ can not well be mistaken. Poultices of tobacco have long enjoyed a reputation in the treatment of orchitis and epididymitis, but when warm applications are indicated, well-saturated and frequently changed warm cloths will be found equally satisfactory in the effect produced, and much more cleanly than the poultices. In the majority of instances, cold will be more agreeable than heat. The ice-bag may be utilized in the following manner with great satisfaction: A bladder or rubber bag is filled with crushed ice, placed upon the three-cornered perineal cushion, and the inflamed organ allowed to rest upon it. If the cold is too great for comfort (and the patient may usually be relied upon to determine this), a layer or two of lint or cotton may be interposed. It occasionally becomes necessary to puncture or incise the tunica albuginea in orchitis somewhat after the fashion given in puncture for epididymitis. Two methods are employed, namely: to carry a sharp-pointed, long knife through a single puncture of the scrotum down to the testicle, and incise the fibrous capsule in one or more places parallel with its long axis and along its anterior surface; or to use an instrument similar to that employed in epididymitis, and make several punctures through the scrotum and the anterior portion of the capsule.

Inguinal adenitis, or *bubo*, occurs in a considerable proportion of cases of specific urethritis, and is apt to be bilateral. The disease is readily recognized by the swelling in the groin. The inflammatory process is usually so rapid in its invasion that the different glands in

this group of lymphatics can not be made out, the entire group being matted together in one mass of embryonic cells infiltrating the tissues around the glands as well as involving their substance. The gonorrhœal bubo tends naturally to suppuration. In mild cases, and where the proper measures are taken at the early appearance of the adenitis, this disaster may be averted; but in others, partly owing to the unfavorable condition of the tissues and to the continued irritation from motion, pus-formation can not be prevented.

In the treatment of acute inflammatory bubo, perfect rest is imperative, and the dorsal decubitus should be maintained. Local medication is of little value. The employment of cold will be found agreeable in the earlier stages, and may serve to prevent suppuration. The ice-bag may be employed by laying it upon a circular pad placed around the bubo. In this way the pressure is entirely taken off the inflamed surface. After the formation of pus is inevitable, warm cloths or poultices should be substituted. When pus is formed, a free incision under cocaine anæsthesia should be made.

Chronic suppurative adenitis of the inguinal glands occasionally persists long after the gonorrhœa which caused it has disappeared. The only remedy is to dissect out the diseased glands with the curved scissors, or scrape them out with Volkmann's spoon.

Gonorrhœal *proctitis* is a rare affection, and does not call for especial consideration.

Ophthalmia, resulting from the inoculation of the conjunctiva with the virus of specific urethritis, has been considered with lesions of the eye.

Gonorrhœal Rheumatism.—In a certain proportion of individuals suffering from gonorrhœal inoculation at a period varying from five or six days to several weeks from the date of the attack, symptoms not unlike those occurring in gout or rheumatism make their appearance in the joints, tendons, and bursæ, and less frequently in the nerves and eye. The parts involved become more or less swollen and painful. The pain, however, is less than in ordinary rheumatism. The febrile movement is not high, and the character of the urine is unchanged, in both of which features it differs from ordinary rheumatism (Fournier). Neuralgia occasionally supervenes in the course of this disease. In a certain proportion of cases the eye is affected, but the ophthalmia here in no ways resembles that of gonorrhœal conjunctivitis. The pathology of this disease is not understood, and the treatment is entirely expectant.

Gonorrhœa in females is usually less severe than with males, and yields more readily to treatment. The chief seat of the inflammation is in the vagina. The urethra and bladder may also become involved. In the treatment, quiet is of first importance. The warm hip-bath should be employed several times a day, and the vagina irrigated at regular intervals with warm water thrown in from a fountain-syringe. As soon as the acute symptoms have subsided, injections of dilute subacetate of lead, with acetate of zinc (grs. ij-iv to ʒj), should be employed.

Simple Urethritis.—There is occasionally met with in practice an acute inflammation of the urethra, attended by a slight muco-purulent

discharge, in patients who have not been subjected to the specific contagion of gonorrhœa. It is well established that urethritis in the male may be caused by exposure to cold, and by the irritation of a vaginal or uterine discharge in a woman not affected with gonorrhœa. Simple urethritis differs in many respects from the specific disease. In color, the pus is white, and in consistency it is thinner, and resembles rather the discharge of gleet. The itching or burning sensation of the more violent affection, if not entirely absent, is much less annoying in simple urethritis.

Chordee, epididymitis, orchitis, and cystitis are rarely present, and, when occurring, are milder in degree than when these affections complicate a gonorrhœa. The history of the disease is short, even when left without treatment. In the treatment of simple urethritis, mild astringent injections are usually indicated in the earlier stages of the inflammation, unless the process is more than ordinarily violent, under which conditions the measures advised for the first stage of specific urethritis should be adopted. The warm hip-bath should be advised, and alkaline drinks administered. Dilute subacetate of lead, ℞j, with acetate of zinc, gr. j, will be about the proper strength for the injection. The oil of sandal-wood should be given after the fourth or fifth day. The duration of simple urethritis varies from three or four days to two weeks.

Gleet, or Chronic Urethritis.—Gleet is a name given to the prolonged discharge from the urethra of a variable quantity of muco-purulent, bluish-white fluid. This discharge is a transudation from the mucous and glandular epithelia of the urethra. In gleet, all or any limited portion of this tube may be affected. The pathological change is a puffiness of the lining membrane, due to hyperæmia of the sub-epithelial vascular area, with a tendency to embryonic and connective-tissue formation. In some points patches of erosions or tissue-necrosis occur. The epithelia lining the glandular apparatus—as those of the prostate, Cowper's glands, and the urethral follicles—become more or less involved. Not infrequently the outlets to these follicles become obstructed by the superficial inflammatory process, resulting in the formation of one or more retention-cysts, which project into the lumen of the tube.

Any form of acute urethritis may pass into this chronic condition of gleet, or a urethritis, subacute in its character from the beginning, may continue as a gleet.

Although chronic urethritis may exist without the presence of stricture of the urethra—as in follicular urethritis—the exceptions to this rule are extremely rare. Any chronic interference with the normal caliber of the urethra serves to induce a catarrhal condition of the mucous membrane of this canal, which, commencing near the seat of stricture, may involve any portion of the tube.

The *treatment* of gleet involves, primarily, the removal of the cause. Taking stricture as the chief cause, urethrotomy with dilatation, or dilatation without cutting, is demanded. In mild cases without close organic stricture, the introduction of the steel sound will often effect a cure.

The methods of procedure will be given in full in the treatment of stricture of the urethra.

In chronic follicular urethritis a most excellent method of treatment is the application of cold by means of the double closed silver catheter

(Fig. 617). This instrument has the ordinary curve of the male catheter, is hollow, with a central partition which does not quite extend to the tip, and it is completely closed, so that the water

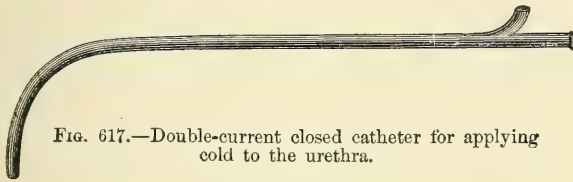


FIG. 617.—Double-current closed catheter for applying cold to the urethra.

passes down one side and up the other without coming in contact with the mucous membrane.

It is advisable to employ a catheter large enough to fairly distend the urethra. Nos. 14, 16, and 18 (U. S. scale) will be more generally useful. It should be oiled and introduced as far back as the prostatic urethra. A rubber tube leading from an irrigator filled with cracked ice and water is attached to one of the two outer mouths of the catheter. A second tube is fastened to the other opening and leads into a basin. The water is turned on slowly at first, and is allowed to run in from five to ten minutes, and the catheter is then removed. The sensation is slightly painful for a few seconds, but anæsthesia soon supervenes. The operation may be repeated in from three to six days. If the reaction is severe, the interval may be longer between the applications.

Stricture of the Male Urethra.—Strictures of the urethra may be divided into two classes: *true* or *organic*, and *false* or *spasmodic*.

A permanent diminution of the caliber of this canal, as a result of an inflammatory process, constitutes a true or organic stricture. A spasmodic stricture exists when the normal caliber is diminished as a result of contraction of the voluntary or involuntary muscular elements connected with the urethra.

Congenital non-inflammatory narrowing of the meatus does not constitute a stricture. The normal contraction of the compressor-urethræ or "cut-off" muscle is also excluded in the definition of spasmodic stricture.

An organic stricture may be *annular*, *tortuous*, *single*, or *multiple*.

In annular, or ring stricture, the cicatricial contraction involves the entire circumference. It may vary in width from a line to one inch.

In tortuous, or irregular stricture, an inch or more of the urethral canal is involved.

Two or more annular or lateral strictures may unite to form a tortuous or irregular stricture.

The *pathology* of stricture of the urethra is that of an inflammation of variable intensity involving the epithelial and submucous basement membrane of this canal, together with the deeper tissues of the corpus spongiosum, and occasionally of the corpora cavernosa. This process

usually begins from within, but may originate in the deeper tissues of the penis and involve the urethra secondarily.

In a typical case there is first an increased vascularity of the submucous area, followed by emigration of leucocytes and cell-proliferation. The lining membrane becomes puffy and swollen, and the diameter of the canal is diminished. As the acute inflammation subsides, the puffiness disappears, but the caliber of the tube is again diminished by the contraction which takes place in the newly formed connective-tissue elements (cicatrization).

Causes.—Among the causes of stricture, specific urethritis ranks first, and it is highly probable that the precedence which gonorrhœa enjoys in the ætiology of stricture is due rather to the improper management of the urethritis than to the effects of the inflammation proper. The employment of corrosive and irritating injections, the introduction of instruments (syringe-nozzles, bougies, etc.) upon an inflamed surface, together with the unnecessary exposure of the person in the uninterrupted pursuit of business or pleasure, combine to make gonorrhœa one of the most dangerous of the venereal diseases.

Any violence inflicted upon the urethra, either from without, as by a blow upon the perinæum or penis, or from within, as by the reckless use of instruments, the lodgment of calculi or other foreign bodies, may also cause a stricture.

Chancroidal ulcer within the meatus is a rare cause of this lesion. Certain medicines, as cantharides, if administered in large doses and for a prolonged period, induce inflammation of the urinary tract, and thus may cause stricture.

Location.—The most frequent seat of organic stricture is in that portion of the urethra limited behind by the compressor-urethræ muscle, and in front by the suspensory ligament at the junction of the penile with the perineal urethra. Next in order is the first inch within the meatus. Stricture in the prostatic portion is rare. As stated in the consideration of diseases of the prostate, it may occur in general hypertrophy of this organ.

Diagnosis.—The symptoms of stricture are a gleet discharge, interference with the escape of urine or semen, and pain. A muco-purulent discharge continuing for several months is almost pathognomonic of this lesion, and justifies exploration in order to determine the presence of stricture. Interference with the escape of urine from the bladder when atony of this organ and hypertrophy of the prostate are eliminated, are also symptoms of importance. A twisted or forked stream, when not of diminished volume, has no significance, for this may exist with a perfectly normal canal. Pain is not often a symptom of organic stricture, but, when present, is not without value as an indication of localized inflammation.

No matter what symptoms may exist, a diagnosis can only be arrived at by instrumental exploration, which can be done without pain, and by which means the exact location and character of the stricture can be made positive.

For this purpose the bulbous bougie is invaluable. These instruments are of two kinds—the elastic or gum bougie of Dick (Fig. 618), and the oval-tipped wire bougie of Otis (Fig. 619). They should be made of all sizes, commencing with No. 6 and ending with Nos. 21 or 23 (U. S. scale). For practical purposes every alternate size, from Nos. 6 to 23 inclusive, will suffice. The gum bougie is a safer

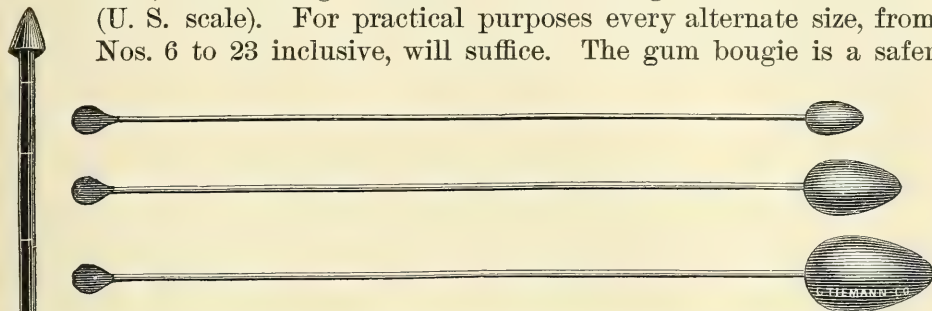


FIG. 619.—Otis's oval-tipped wire bougie, for locating strictures of the urethra.

instrument than that composed of metal, since it is incapable of doing harm under any circumstances. It is objectionable, however, on account of its liability to be spoiled by heat, and of becoming fragile from age. It should always be slowly warmed to about the temperature of the body before being introduced. The wire bougies are thoroughly satisfactory instruments, and incapable of injury to the urethra if ordinary care is taken. The bulbs are oval, the wire is flexible, and is screwed into the bulb for security. The sizes are the same as for the gum bougies just given.

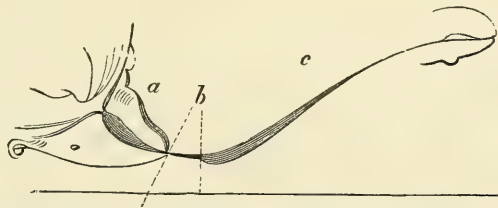


FIG. 620.—Longitudinal section of the urethra, showing the diameter of the canal at various points. *a*, Prostatic; *b*, membranous; *c*, penile portion. (After Thompson.)

FIG. 618.
Dick's
gum
bougie,
with
oval tip.

In the effort to locate a stricture, the different diameters of the normal urethra at various points in this canal must be borne in mind. The meatus is least dilatatable, and the membranous portion next in order. Immediately behind the meatus there is an expansion into the fossa navicularis, and from this point to the suspensory ligament (the junction of the penile and perineal urethra), the diameter is about the same. From the suspensory ligament to the anterior layer of the triangular ligament, the diameter gradually increases. This, the bulbous portion, is the largest part of the canal. Behind the membranous portion there is a second expansion in the prostate (Fig. 620).

The patient should be placed upon the table or bed in the dorsal decubitus. In order to secure insensibility, from twenty to thirty minims of a 4-per-cent solution of cocaine should be thrown into the urethra.

This may be done with the ordinary hypodermic syringe, to which Otis's cocaine-tube (Fig. 621) is attached. For searching the anterior four fifths of the urethra, it is not necessary to carry the point more than one inch beyond the meatus, when the syringe is emptied and the patient directed to grasp the glans and retain the injection after the tube is removed. When the membranous portion and neck of the bladder are to be examined, the cocaine-tube should be carried just beyond the cut-off muscle, and about fifteen minims of the solution thrown in here. In five minutes local anæsthesia is obtained. A bulb of medium size is selected and properly warmed and oiled. The wire is not curved in exploration of the urethra anterior to the membranous portion. The penis should be held at about a right angle to the plane of the body, and, as the instrument is being introduced, the organ should be elongated in order to obliterate any folds in the mucous membrane. This membrane is not so closely attached to the connective tissue of the corpus spongiosum but that it can be perceptibly displaced up and down and doubled upon itself if sufficient force is applied. If no stricture of caliber smaller than the bulb is encountered, it will glide smoothly and uninterruptedly down to a point about five inches from the meatus, where it will be arrested, having reached the end of the bulbous portion and

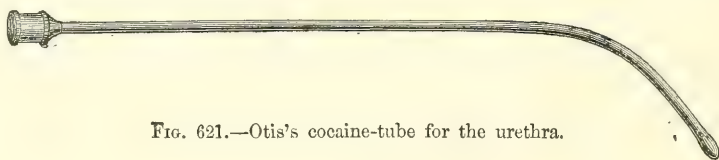


FIG. 621.—Otis's cocaine-tube for the urethra.

lodged in a pocket just in front of the anterior layer of the triangular ligament. Withdrawing the instrument, it will in all probability return as smoothly as it entered. If, however, a stricture exists, and the bulb used is about the size of the lumen of the stricture, as it is carried into the urethra a slight resistance will be felt. As the instrument is withdrawn, the broad shoulder of the oval will come in contact with the obstruction, where it will be arrested. The penis should now be allowed to retract, and the thumb and finger of the left hand slipped down to the level of the meatus, where the wire is grasped and slightly bent. The instrument is steadily drawn through the stricture, and, as soon as the resistance ceases, the wire is again bent at the level of the meatus. The distance between the two points at which the wire is bent represents the extent of the stricture.

When it becomes necessary to search the urethra beyond the bulbous portion, the wire should be bent to correspond to the normal curve of the deep urethra. The handle of the instrument should be bent in an opposite direction in order to prevent the possibility of getting the point of the bougie turned toward the perinæum. It is introduced in the same way as the catheter or steel sound. When the triangular ligament and compressor-urethræ muscle are encountered, by depressing the handle toward the thighs of the patient, the bulb is

made to rise out of the pocket in front of the anterior layer of the ligament and to pass into the membranous portion. If a stricture is present the resistance, if not felt as the bulb goes through, will certainly be appreciated as it is withdrawn, if the instrument is large enough. If the patient is not narcotized, spasmodic contraction of the compressor muscle may arrest the bulb, and, in a certain sense, simulate stricture.

In the resistance of the muscle there is a roundness, smoothness, and elasticity which differs from the rough surface of cicatricial tissue and the inelastic grip of a stricture. When the obstruction is felt, the same method of measurement and location is to be observed. A stricture may be roughly estimated by the introduction of a catheter, ordinary bougie, or steel sound, but it can not be intelligently or satisfactorily defined without the oval bulbs.

Not infrequently it will be found that the meatus is too narrow to admit a bulb of sufficient size to define the stricture, necessitating division of the meatus (*meotomy*). This operation may be done with an ordinary scalpel or bistoury, but with nothing like the exactness and freedom from pain which is secured when the urethrotome is employed. The incision should be made in the median line, and should correspond to the floor of the urethra. It should not extend deep enough to wound the artery of the frænum, nor should it be any deeper than is sufficient to admit the larger bougies.

If the bistoury is employed, the operator grasps the glans between the thumb and finger of the left hand, introduces the knife, cutting-edge downward, a distance of a half-inch, and cuts carefully outward. The injection of cocaine solution into the tissues of the part incised will render the operation perfectly painless. The urethrotome of Dr. E. A. Banks, in addition to its usefulness in dividing deeper strictures, is especially serviceable in performing meotomy. It consists of a handle, shaft, and a series of bulbs. The shaft is graduated and hollow, and has extending through it a rod connecting with the blade. The bulbs are of various sizes, are fenestrated, and are screwed on to the tip in such a way that the window falls directly over the blade which is to be projected through it. Upon the handle is a sliding-knob for sheathing or projecting the knife, and, at the end, a screw-gauge which sets the blade for cutting to any desired depth (Fig. 622).



FIG. 622.—Dr. E. A. Banks's urethrotome. *a*, Screw-gauge. *b*, Sliding-knob. *c*, Bulb. *d*, Knife.

The operation is performed as follows: A bulb is selected which will fit the meatus fairly tight, and screwed on to the shaft. The gauge should next be set to allow the knife to cut one eighth of an inch in depth. The blade is now concealed, the bulb oiled and introduced until the knife, pointing directly to the middle line of the floor, is half an inch from the meatus. While the glans is held tightly between the

thumb and finger of the left hand, the blade is projected as far as the gauge will allow, and the instrument quickly pulled out of the urethra. Even when cocaine is not employed, this incision gives scarcely any pain. The bulbous bougie should now be introduced, and, if the meatus is still too narrow, the incision should be made deeper. When in this operation—as will not infrequently happen—the artery of the frænum is divided, the bleeding may be readily controlled by plugging the meatus, and pressing into the line of incision a small strip of iodoformized gauze. The patient should also be directed to restore this dressing should bleeding occur after urination, when the plug is removed or during an erection. In order to prevent a recontraction of the opening, it is necessary to dilate the meatus at intervals of from two to four days for five or six weeks after the operation.

In strictures of very small caliber, and in long and tortuous strictures, the oval bulbs can not be used. The extent of such strictures can not be made out with accuracy until, by the use of filiform bougies and careful dilatation, the smaller searchers can be introduced. The method of employing these bougies will be given in the treatment of stricture of the urethra.

Treatment.—The treatment of organic stricture of the urethra may be by *division* or *dilatation*. In the former operation the stricture is incised from within (*internal urethrotomy*), or from without (*external urethrotomy*). In the latter, the stricture is gradually dilated by the introduction of bougies or sounds. Dilatation may be *continuous* or *interrupted*. Immediate dilatation, or *divulsion* of a stricture, as compared to urethrotomy, is an unscientific and unsafe procedure, and is rarely, if ever, justifiable. With the urethrotome, the contraction is divided with accuracy and precision; with the divulsor, the force is blindly applied, and the depth and direction of the tear is not safely within the control of the operator.

It is difficult to lay down any rule for the selection of the method of treatment to be followed in any given stricture. In general it may be said that *internal urethrotomy* is preferable in all strictures anterior to the membranous portion, and some form of *dilatation* in those situated in this portion, or in the rare cases behind it. The exceptions to this rule will be presently considered.

The method of interrupted dilatation by the frequent introduction of sounds or bougies may be successfully applied to narrow annular strictures of comparatively recent date, but division of the stricture and subsequent dilatation not only offers the quickest and surest means of relief, but is much less painful than dilatation without incision. The employment of cocaine in urethral surgery has removed two great obstacles to the cutting operation, namely—the patient's dread of pain on the one hand, and that of ether narcosis on the other.

Many strictures are, however, of such small caliber that a urethrotome can not be introduced, and it becomes necessary to dilate them up to a size sufficient to admit the urethrotome, or to divide the stricture by cutting down upon it through the integument, an operation known as *external urethrotomy*.

Internal Urethrotomy.—In performing this operation a sufficient degree of anæsthesia can be obtained by the use of cocaine in the vast majority of cases. When the stricture is of small caliber, requiring a deep incision from one to two or more inches in length, ether narcosis is advisable.

Operation.—Having injected about 3 ss. of 4-per-cent cocaine into the urethra, the stricture should be accurately located, and its diameter and extent determined by the bulbous wire bougies, as just described. If it is of small caliber, thus necessitating a deep incision, a greater degree of insensibility may be required than can be obtained by cocaine applied to the mucous membrane of the urethra. This is readily obtained by carrying a delicate hypodermic needle into the tissues in the line of incision, and injecting from twenty to thirty minims of a 4-per-cent solution. The distance from the meatus to the posterior boundary of the stricture is then measured on the urethrotome, beginning at the point where the knife is projected, and extending toward the handle. One fourth of an inch should be added to this distance in order to make it certain that the knife is carried well behind the posterior limit of the contraction. This point on the instrument is indicated by a small ring clipped from the end of a rubber tube and slipped over the shaft. It is now ready for introduction.

In the selection of a urethrotome, the instrument of Otis will be found to fill all the indications more satisfactorily than any other (Fig. 624). It




FIG. 624.—Otis's dilating urethrotome, with the author's cog-wheel attachment.

consists of a shaft, handle, and blades. The shaft is composed of two bars, which can be separated or closed by turning a screw at the handle, where there is arranged a dial which registers the exact degree of dilatation effected by the separation of the bars. In the upper bar of the shaft is a slot or groove, along which the knife is carried. When it arrives near the point of the shaft, the blade sinks into a depression and disappears.

I have added to this instrument a cog-wheel apparatus, attached near the handle, by the use of which the knife is carried steadily forward or backward, and is made to cut with mathematical precision.

The operator should stand to the right side of the patient, who is resting on the back, with the legs fully extended. The knife should be carried forward until it disappears near the tip of the urethrotome, the bars of which are now closed and oiled as far as it is to be introduced. The glans penis is grasped between the thumb and finger of the left hand, the organ held in the same position as when the stricture was located, and the instrument carried in until the rubber ring touches the meatus. The left hand, releasing the penis, is made to grasp the handle

of the urethrotome and steady it, while with the right the dilating-screw is turned until the arrow on the dial indicates a separation of the bars equal to the diameter of the bulb which located the stricture. By turning the cog-wheel the knife is now made to travel through the more superficial portions of the stricture from behind forward and along the median line of the roof of the urethra. The incision should commence a quarter of an inch behind the stricture, always in the roof of the urethra except for meotomy, and should terminate the same distance in front of the anterior boundary. Without changing the position of the urethrotome, the knife is rapidly run back to its original position, the dilatation increased one size more, and the knife again carried more deeply through the track of the first incision. This manœuvre is repeated until the stricture is divided up to Nos. 21 to 23 (U. S.). A wide dilatation with the urethrotome should be made just before it is removed. The instrument is now withdrawn after the knife is concealed and the blades half-closed. If the bars are brought closely together, the mucous membrane may be caught between them. In order to demonstrate a perfect division of all the bands, the larger bulbs should be introduced, and, if these catch at any point, a further incision is required. Or a full-sized sound (Nos. 21 to 23) may be carried through the stricture, and any undivided fibers torn or stretched.

Hæmorrhage after internal urethrotomy is usually slight. When the incision has been made in the pendulous part of the urethra, it may be readily arrested by turning the penis up on the belly, laying a handful of cotton or gauze over the organ, and strapping it down with a bandage carried around the pelvis. Behind this portion, a compress along the perinæum, or a large gum bougie in the canal, will control the bleeding. The patient should be put to bed at once, and required to remain quiet for several days.

Not infrequently within twenty-four hours after urethrotomy, or the introduction of a sound or other instrument into the urethra, the patient is seized with rigors or a pronounced chill, followed by a variable rise in temperature, or the fever may occur without any premonitory chill. When the thermometer registers 100° F., it is a wise precaution to administer antipyrin in doses of from grs. x-xx, and repeat this every hour until the decline in temperature is below 100°. If the pulse is correspondingly increased, tincture of aconite-root should be given at the same time.

The repeated introduction of steel sounds or gum bougies is essential to the successful after-treatment of internal urethrotomy. If there is no marked febrile movement, the dilatation should be commenced on the second or third day after the operation. If fever exists, the use of the sounds should be postponed. Cocaine should be employed, for, as a rule, the introduction of the sound is more painful than the incision. The urethra should be stretched to the full size of the sound introduced after the cutting. It is well to begin with No. 17, and follow this with Nos. 19, 20, and 21, or higher, if the urethra is unusually capacious. This should be repeated every second or third day for a period of about

three weeks, every fourth or fifth day for the same period of time, then once a week for three weeks, and twice a month for three or four months. It is essential to keep the walls of the incision apart until they are lined with new-formed epithelia.

If cystitis, epididymitis, or orchitis ensue after urethrotomy, all operative measures should be discontinued until these symptoms disappear.

The *prognosis* after urethrotomy should be guarded. Many cases do not recur, but a stricture of long standing, with extensive induration, no matter how thoroughly divided and carefully treated, tends to recur. It thus becomes necessary to employ dilatation, either with a sound in the hands of the surgeon, or a soft bougie if this duty is intrusted to the patient, at intervals of every two or three months, and in some instances oftener, during the life of the individual. That the milder forms of annular stricture may be permanently cured by judicious treatment is satisfactorily established.

In a certain proportion of cases the stricture will be found so *close* or *tight* that the urethrotome can not be passed through it, and before the division can be effected it is necessary to dilate the constriction until this instrument can be introduced. In accomplishing this purpose two excellent methods are at the disposal of the surgeon, by either of which, if patiently and skillfully utilized, the necessity of external urethrotomy may be obviated in all but a very limited class of cases. The methods are, in order of excellence, (1) immediate dilatation with Banks's dilating filiform bougies, and (2) continuous dilatation by inserting and leaving in the urethra one or more whalebone filiforms, or a larger gum bougie. Of the procedures of Dr. E. A. Banks and Sir Henry Thompson, the former is by far the most satisfactory. Its adoption has left only a small proportion of strictures for continuous dilatation.

The dilating filiform bougie (Fig. 625) is thus employed: The urethra is elongated by pulling upon the glans, and a small syringe of sweet-




FIG. 625.—Banks's dilating filiform bougies.

oil is thrown into the canal. The filiform is introduced, and, when any resistance is encountered, it is slightly withdrawn and again pushed in. By this manœuvre the small tip of the instrument may be insinuated through even a long and tortuous tight stricture. Once engaged in the opening, it should be carefully pushed down until it is felt in the grasp of the constriction, and then forced steadily through until the full dilating capacity of the largest part of the bougie has traveled through the stricture. A larger size should be at once introduced, or the urethrotome may be carried through the opening.

This bougie may be employed with perfect safety. When fully introduced, the filiform portion passes into the bladder, and, if this organ is empty, it curls upon itself from the resistance of the vesical wall. It is especially adapted to close strictures of the deep perineal and membranous urethra.

If, after careful trial, it is impossible to get the filiform into the opening, the patient should be put to bed and given the benefit of a full dose of quinia and morphia. If the urine can not be passed, supra-pubic aspiration is indicated. After from twelve to twenty-four hours it will usually be discovered that the filiform will slip readily into the bladder. As soon as the dilatation is sufficient to admit the urethrotome, the operation of internal urethrotomy should be performed.

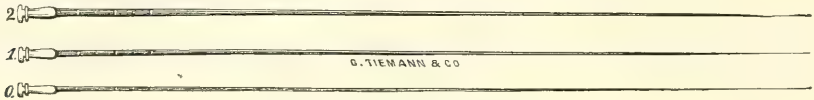


FIG. 626.—Gum filiform bougies.

In *continuous dilatation*, the filiform bougie (Figs. 626, 627), or a small gum bougie, is insinuated through the stricture and tied in position in the urethra by fixing a narrow strip of adhesive plaster around the prepuce behind the corona glandis, and attaching from this to the end of the bougie three or four silk threads (Fig. 628).




FIG. 627.—Whalebone filiform bougies.

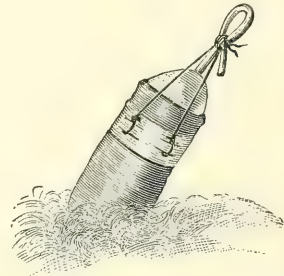

FIG. 628.—Bougie tied in for continuous dilatation.

The walls of the stricture break down under the constant pressure of the whalebone or elastic instrument, and it will be found that a bougie, with difficulty introduced and tightly held by the stricture soon after it is carried through, will, within twenty-four hours, become loose and easily movable, and a larger instrument will readily pass into the same opening. As soon as the dilatation has proceeded to the required extent, the urethrotome should be employed and a division effected.

Strictures of the Membranous Urethra.—Strictures of the deep urethra are amenable to treatment by *modified internal urethrotomy* and by *external urethrotomy* or *perineal section*.

The former method consists in the rapid dilatation of the stricture with the dilating filiform bougie until the Otis urethrotome can be introduced. The straight instrument shown in Fig. 624 can be readily employed in this portion of the urethra. It is carried into the stricture until the knife is at its posterior limit, when, without separating the bars of the urethrotome—that is, without dilatation—the blade is care-

fully drawn along the roof of the urethra, making a shallow incision in the wall of the stricture. It should now be concealed, and the dilating power of the urethrotome employed. These shallow incisions may be made on the lateral aspects of the canal as well as along its roof. By this operation the stricture is nicked and then dilated. If the incision were made when the bars of the urethrotome had put the stricture on the stretch, the large vessels of this part of the urethra would be endangered. The steel sounds should be used as advised after internal urethrotomy in the anterior portion of the canal.

External urethrotomy, or *perineal section*, is an operation for the relief of close organic stricture of the bulbous or membranous portions of the urethra which can not be reached through the urethra. With the exception of those cases where urinary fistula or chronic abscess exists as a result of stricture, the conditions which justify this operation are rare.

It is performed with or without a guide. When a sound or bougie can be carried through the obstruction into the bladder, the procedure is much simplified. Without this guide the operation is surrounded with considerable difficulty. In external urethrotomy, the patient is placed in the lithotomy position, being prepared as for this operation. After the anæsthesia is complete, a careful and final effort should be made to carry a filiform or soft bougie through the stricture and into the bladder. If this can not be done, a good-sized sound should be carried down to the obstruction, and this will serve to guide the operator to the commencement of the stricture.

An incision is then made exactly in the median line, the anterior limit being slightly in front of the ascertained commencement of the stricture, the posterior extending toward the anus a sufficient distance. In making this incision the scrotum should be held up by an assistant, who is directed not to displace the median raphé to either side. The legs must also be held in the same relative position.

The bleeding is usually considerable, as the vascular tissue of the bulb is divided. All vessels should be secured; but the oozing, which is general, need not retard the operation. As soon as the sound or filiform, at the anterior margin of the constriction, is seen, the division should continue along the guide until the healthy urethra is reached beyond the stricture. If no guide has been introduced, the dissection should be carried back in the known direction of the base of the bladder, guided by the location of the prostate with the finger introduced into the rectum. The first indication that the canal is reached behind the stricture will be a gush of urine. On account of the obstruction, the urethra between it and the bladder is widely dilated, and for this reason is more readily found. It is essential to the success of this operation that all cicatricial tissue be dissected out. A large-sized steel sound should now be introduced through the meatus and into the bladder. If any difficulty is met with in introducing this instrument, a flexible bougie may be substituted. It is not advisable to leave the instrument in the urethra. In order to prevent bleeding, the wound

should be packed temporarily with sublimate gauze, held in position by a T-bandage. A fatal hæmorrhage occurred in one of the author's cases, the packing having become loose while the patient slept.

The urine usually escapes through the wound for the first few days, and afterward partly through the wound and urethra. In rare instances it escapes uninterruptedly through the urethra. The after-treatment consists in the introduction of the sounds or bougies (as above directed) through the urethra as far as the neck of the bladder. This operation should be repeated every three or four days until the urine ceases to escape through the wound, and once a week thereafter for several months.

Interrupted Dilatation.—In the treatment of stricture of the urethra by this method, there are required *steel sounds* and *flexible bougies*. Steel sounds are of two patterns, the straight and curved. The former are preferable for dilating strictures anterior to the membranous portion, while beyond this point the curved instruments are necessary. The most satisfactory instruments are those constructed upon the United States scale,* which commences with the smallest steel instrument, $\frac{9}{10}$ of an




FIG. 629.

inch in diameter, and increases $\frac{1}{50}$ of an inch in diameter for each successive sound to No. 25 inclusive, equal to $\frac{25}{50}$ of an inch. Nos. 1 to 8, inclusive, are filiform and elastic bougies.

A *straight sound* should be six inches in length clear of the handle, slightly conical from the tip, back for a distance of one and a half inch. This conicity should increase one size for every half-inch for this distance. Thus, a sound which measures No. 17 at the tip increases to No. 18 one half inch back, to No. 19 at one inch, and is No. 20 at one and a half inch from the point, and continues this size for the entire shaft.

A *curved sound* should be nine inches long clear of the handle. The curve should involve only the last two inches. The conicity extends also one and a half inch from the tip, increasing one size for every half-inch until the full size is reached at one and a half inch from the point.

* The unit of the French scale is one third of a millimetre (about $\frac{1}{75}$ of an inch), and each size up to No. 30, inclusive, increases one third of a millimetre in diameter. Divide any given number of this scale by three, subtract the quotient, and the remainder approximates the corresponding size on the above scale. Thus, No. 30, French, divided by 3 = 10; 30 - 10 = 20; or, No. 30, French = No. 20, U. S.

Thus, an instrument the shaft of which measures No. 20, is 17 at the tip, 18 at one half inch, and 19 at one inch farther back.

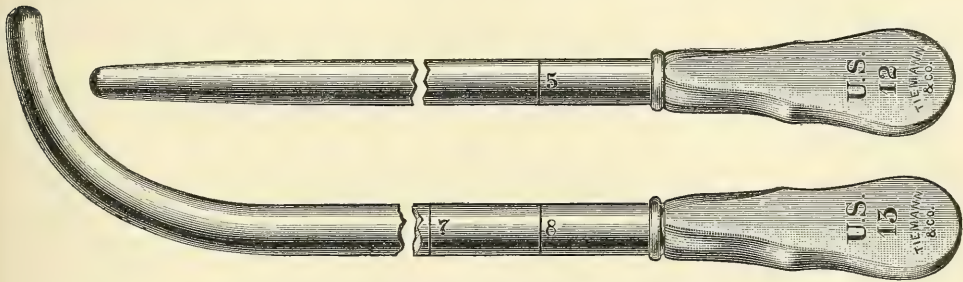


FIG. 630.—Curved and straight conical sounds.

The curve should be made to correspond to that of the normal deep urethra, which is that of a circle with a diameter of three and a quarter inches; "and the proper length of arc of such a circle to represent the sub-pubic curve is that subtended by a chord two and three quarters inches long" * (Fig. 631).

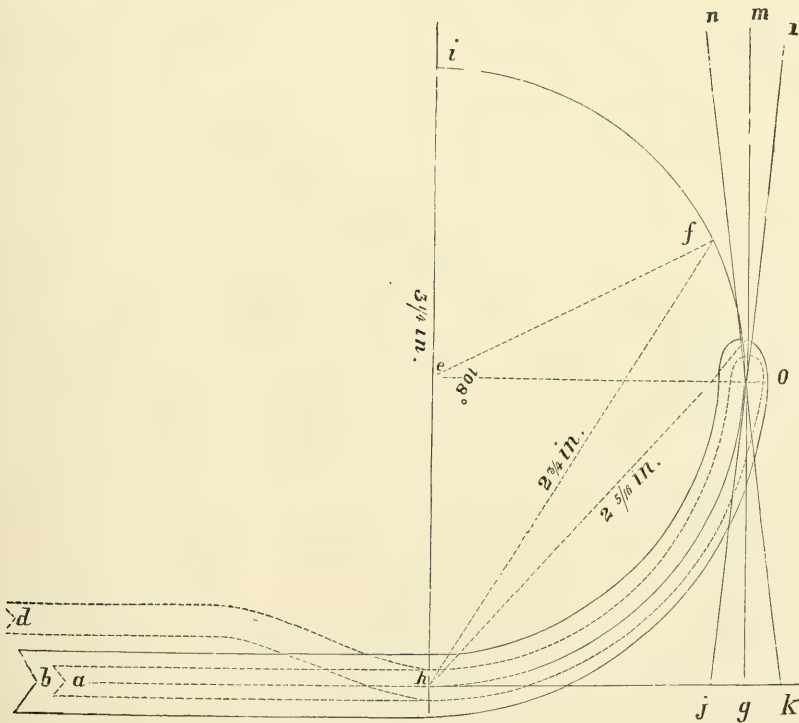


FIG. 631.

Flexible bougies are of various sizes, being conical for two or three inches, and olive-pointed (Figs. 632–635). They are exceedingly useful instruments, and, when warmed before introduction, are incapable of injury to the urethra, even when an unusual degree of force is em-

* Van Buren.

ployed. The black French bougie is preferable. The filiform instrument has already been described.

In dilating a stricture with the conical steel sound, the method of introduction is identical with that given in using the metal catheter. In the interrupted dilatation a mild degree of force is exercised, and the *séance* is repeated on every second, third, or fourth day. The length of the interval between the introductions must be determined by the symptoms in each case, the object being to accomplish moderate divulsion at each sitting with-



FIG. 632.



FIG. 633.



FIG. 634.



FIG. 635.

out producing marked inflammation. The sound should never be carried beyond the point where its full dilating power is applied to the stricture. In this way irritation of the prostatic urethra and neck of the bladder may be avoided in all save the deepest variety of strictures.

The dilatation of strictures by the use of conical steel sounds should be limited to those cases in which the stricture is of sufficient caliber to admit at least No. 15, U. S., and is narrow or linear in character, so that it may be made to give way without the employment of too great force. The smaller sounds are capable of penetrating the walls of the urethra unless they are used with great skill and carefulness, while the larger instruments will not, within the limit of safety, succeed in the dilatation or rupture of a broad or tortuous stricture. Incision with the urethrotome is a safer and less painful operation, and the sounds serve an admirable purpose in the after-treatment.

In using the soft bougies in the anterior portion of the urethra, they may be passed in straight; but, when the deeper portion is invaded, they should be curved as much as possible, to correspond to the sub-pubic curve of this canal.

Foreign Bodies in the Urethra.—Calculi occasionally lodge in the urethra, and substances introduced through the meatus—as fragments of a catheter, etc.—may require removal by the surgeon. The diagnosis will be evident from the symptoms of obstruction to the escape of urine, by recognition of the body by digital pressure along the canal, and by exploration through the meatus. Stone may be made out by the grating sound which is emitted, or by the sense of friction upon a rough and hard surface which is conveyed to the fingers along the sound. A metallic substance may also be recognized by the peculiar click which is elicited when it is brought in contact with the exploring instrument.

Removal may be effected through the meatus, or by incision directly through the floor of the urethra at the point of lodgment. It is always

desirable to avoid incision through the urethral wall when, by the use of forceps or any mechanism, the extraction can be effected by the meatus without doing too great violence to this canal. If the substance is nar-

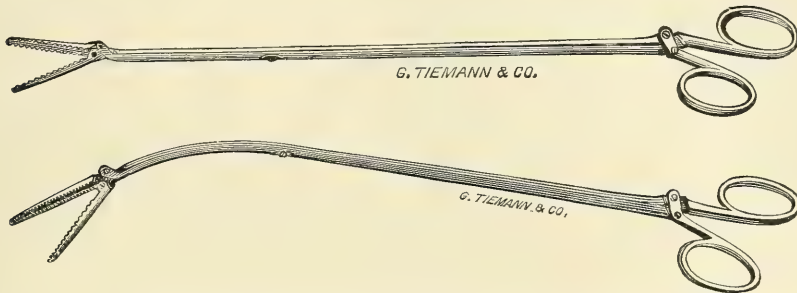


FIG. 636.—Straight and curved alligator-jawed urethral forceps.

row and smooth, it may be seized with the forceps (Figs. 636, 637) and extracted. The straight alligator-forceps, or the instrument of Hale, is preferable for the anterior portion of the urethra, while for the deeper



FIG. 637.—Hale's instrument for removing foreign bodies from the urethra. (After Linhart.)

part the curved instrument is more suitable. For a round body, the scoop or curette will prove more satisfactory (Fig. 638).

In using the forceps, the instrument closed should be carried down until its beak strikes the foreign substance, when the jaws should be slowly separated and pushed farther in, so that they may pass between the lining membrane of the urethra and the body. They should then be firmly closed and cautiously moved a slight distance to and fro in order to determine whether the mucous membrane has been caught in

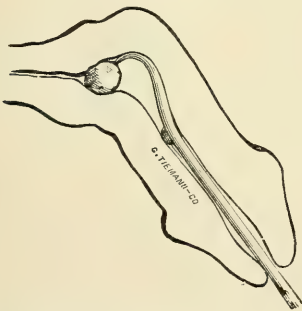


FIG. 638.—Curette, or scoop, for the removal of calculus in the urethra. (After Van Buren and Keyes.)

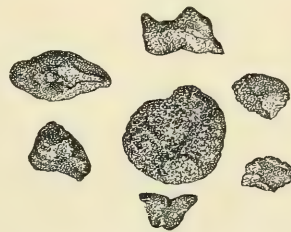


FIG. 639.—Calculi removed from the urethra. (The author's case.)

the instrument. This danger will in great part be obviated if, just at the moment when the jaws are applied to the foreign substance, the urethra is put upon the stretch by pulling upon and elongating the penis. The canal should be lubricated by an injection of sweet-oil. If stricture exists, urethrotomy may be necessary before the substance can

be extracted. In a case which came under my care, two strictures were divided with the urethrotome. From behind the first constriction two calculi were removed, and several after the second stricture was divided (Fig. 639). In this operation a scoop proved more serviceable than the forceps.

In a second operation I found it necessary to perform external urethrotomy, cutting directly down upon the calculi (two in number), which were easily removed through the incision. The direct injection of cocaine into the tissues secured complete anæsthesia. The wound should be left to close as in the ordinary operation of perineal urethrotomy.

Urinary Fistula communicating with the Urethra.—In congenital or acquired urinary fistula communicating with the urethra the following operative measures are indicated: When the fistula opens in the perinæum or lower surface of the penile urethra, the method of Szymanowski offers the surest prospect of success. It is essential that all inflammation in and about the field of operation be allayed, sinuses slit up and healed, and all strictures divided, or stretched and cured. The bowels should be well emptied for two or three days before the operation. For perineal fistula the lithotomy position is preferable; the parts should be shaved and disinfected. Proceed as follows: Let the dark spot at *F* (Fig. 640) represent the opening of the fistula. A straight incision *AB* is made, passing along one edge of the fistula, extending three quarters of an inch each way from the opening. This incision passes through the skin and superficial fascia. The edge of this incision is raised, and,

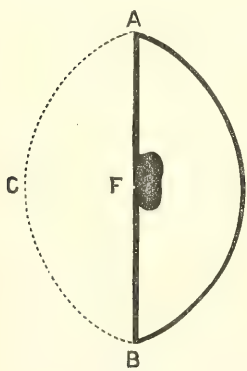


FIG. 640.

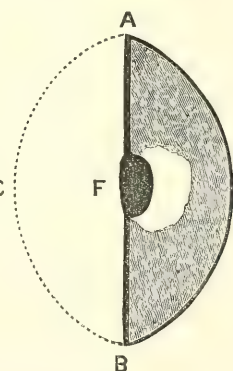


FIG. 640 A.

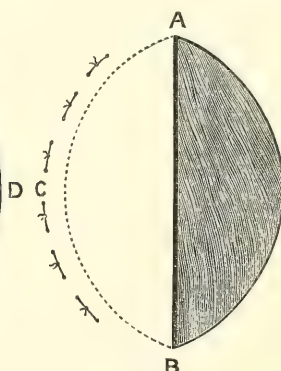


FIG. 640 B.

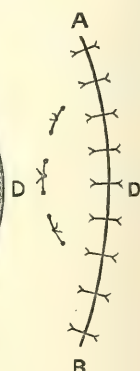


FIG. 640 C.

dissecting away from the fistula, the skin is lifted to form a pocket, the bottom of which is the dotted curved line *ACB* (Fig. 640), and the lifted edge or entrance to this pocket the straight incision *AFB*. On the opposite side, corresponding accurately with the attached bottom of the pocket *ACB*, a curved incision *ADB* (Fig. 640) is made, the greatest depth of the flap being from three quarters to one inch (McBurney).* From this flap, with a pair of small scissors curved on the flat, remove the epidermis, except over an area amply sufficient to

* "New York Medical Journal," November 6, 1886, p. 514 *et seq.*

cover the fistulous opening. (This area is represented in white between *F* and *D*, in Fig. 640 A.)

The flap *A D B* (Fig. 640 A) is now dissected up, taking with it a generous allowance of subcutaneous fat and fascia, down to about an eighth of an inch of the original straight incision *A F B*, this attachment being left to give it a sufficient blood-supply. As this *A D B* is turned over toward *C*, it hinges on the attached edge *A, F B*, and, as it is slipped beneath the pocket *A C B F*, it will be seen that the undened (white) portion suffices to form the new floor of the urethra. It being ascertained that the flap fits accurately, it is brought out again and a series of five or six loops of fine catgut sutures are inserted by carrying the needle through the skin one eighth inch from the curved dotted line *A C B* into the bottom of the pocket, and beneath the integument, directly opposite and through the free edge of the flap *A D B*, and back again, being brought out finally one quarter inch from the point of entrance *A C B* (Fig. 640 B). As these sutures are tied, the flap is inverted and secured. It now remains to close the open wound by sutures of fine silk, which snugly approximate the lines *A B* and *A D B* (Fig. 640 B). The result is shown in *A D B* (Fig. 640 C). It is important to keep the bowels from moving and the patient quiet with morphia for several days. Every three or six hours the soft Nélaton catheter should be inserted, the urine drawn off, and the bladder washed out with four or five ounces of warm boracic-acid solution, gr. x- $\bar{3}$ j. On withdrawing the catheter the end should be closed in order to prevent the escape of even a few drops of its contents in the urethra. The silk sutures should be removed about the seventh day, and the use of the catheter discontinued only when the wound is thoroughly united. In rare instances the floor of the prostatic and posterior part of the membranous portion of the urethra may be destroyed, and the fistula open directly into the rectum.

The following case which came under my care will serve to illustrate this form of fistula : *

The patient, twenty-seven years of age, merchant, came under my care in August, 1887. He came of healthy stock, and had had no sickness of a serious character until 1883, when symptoms of vesical calculus supervened, for which a left lateral lithotomy was done in August, 1886. The stone removed was reported to be the size of a hen's egg.

A urethro-perineal fistula remained after this operation, and from August, 1886, to August, 1887, four attempts were made to close this opening, without success. In the last of these operations, a drainage-tube, about one and one half inch in length, was inserted in the perineal opening, and left with the deep end in the urethra. This tube, about three sixteenths of an inch in diameter, was lost sight of, the surgeon and patient supposing it had escaped externally and had been thrown away with the dressings. The last operation was followed by considerable pain, which was persistent. In the course of three months an

* Read before the Ontario Medical Association, at Toronto, June, 1888.

abscess opened into the rectum through the anterior wall, and the urine began to flow freely in this new channel. About this time the perineal opening closed and an abscess formed in each tunica vaginalis. These were incised, and when I first saw the patient were entirely healed. At this date (August, 1887) nearly all the urine passed through the rectum. The patient suffered greatly, and had to be kept constantly under the influence of opium.

An examination per rectum revealed the presence of a stone, the end of which was on a level with the anterior surface of the rectum, about one inch beyond the anal aperture. The opening was slightly dilated, and the stone was removed through the rectum by means of strong forceps. It had formed in and upon the drainage-tube, and is seen in natural size in Fig. 641. After consultation with Dr. Edward L. Keyes, it was determined to prepare the patient for operation, which was done, and on September 13, 1887, I operated as follows:



FIG. 641.—Calculus formed on a piece of drainage-tube as a nucleus. (Actual size.)

The patient, in ether narcosis, was placed in the Sims position, and a large Sims vaginal speculum was introduced. The opening through the anterior wall of the rectum measured three fourths of an inch in length, with an irregular width of from one eighth to one fourth of an inch. It led directly into the urethra near the junction of the membranous and prostatic portions. The floor of the urethra was entirely destroyed. The right edge (patient's right) of the opening was seen to be undermined, as shown by the dotted surface *B* (Fig. 642).

I determined to attempt the formation of a new floor to the urethra by turning the mucous membrane of the rectum into this position. The operation performed was a modification of the method of Szymanowski. Two crescentic incisions were made, as shown at *A A* (Fig. 642), being about parallel with the edges of the opening, but approaching more closely at its upper and lower angles. These incisions went deep into the wall of the rectum and included the mucous and muscular layers. The two lateral flaps were dissected up, the left to within an eighth of an inch of the edge of the opening; the right could not be carried so far on account of the pocket which undermined this side.

The flaps were now turned toward each other and their raw edges made to meet in the middle line, while the raw surfaces looked into the rectum, and the mucous surfaces into the urethra (Fig. 643). Sutures of silk-worm gut were inserted, as shown at *D* (Fig. 643). These sutures were about three sixteenths of an inch apart, and were so inserted that they did not penetrate to the cavity of the urethra. On

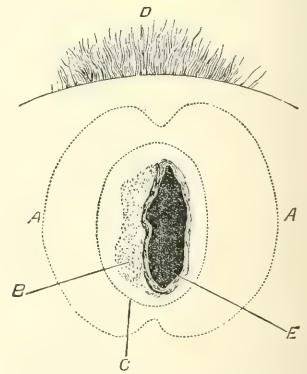


FIG. 642.—Showing the anterior wall of the rectum, and opening into it at *E*, a sinus from the membranous and prostatic urethra. *B*, Cul-de-sac, which undermined the right margin of the opening. *A A*, Line of incision, along which the flaps were dissected as far inward as *C*. For their nutrition the two lateral flaps depended upon the limit between the dotted line *C* and the margins of the opening *E*. *D*, The perinæum.

account of the thinness of the flap at one point, I was compelled to pass one suture into the urethra.

A Nélaton catheter was carried through the meatus and urethra into the bladder, and through this the urine ran out at intervals. Whenever the urine accumulated enough to create a desire to expel it, about six ounces of Thiersch's solution were thrown in to dilute it; and when this, with the normal contents of the bladder, were evacuated, the same quantity was thrown in again and immediately expelled. In this way the wound was kept practically free from irritation by the urine. Divulsion of the sphincter ani removed all danger or annoyance from spasm of this organ. The bowels were kept quiet for nine days, and liquid diet was enforced. The patient had been placed on liquid diet for ten days prior to the operation.

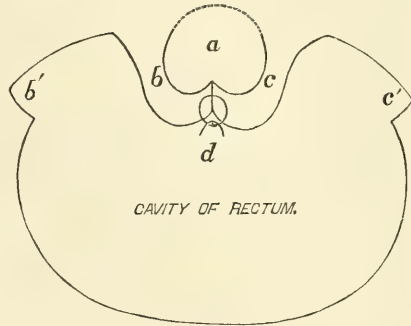


FIG. 643.—Schematic. Transverse section through the urethra and rectum, showing the method by which the flaps were turned from the mucous membrane of the rectum to make the floor of the urethra. *a*, Urethra. *b*, The right flap dissected from *b'*. *c*, The left flap from *c'*. *d*, The silk-worm gut suture in position (not entering the cavity of the urethra).

The sutures were left *in situ*. The wound healed promptly, and the patient left for his home in three weeks after the operation. In April, 1888, seven months later, he returned, complaining of slight irritation in the rectum, and said he thought, at rare intervals, a few drops of water escaped into the bowel. On examination, three of the sutures were still in position, but no opening could, by most careful search, be discovered. The sutures were removed, and in a few days the patient was discharged.

Congenital Malformations of the Urethra.—In exstrophy of the bladder the urethra is absent, and, in certain rare anomalies, it may open into the groin, upon the side of the glans penis, in the median line of the dorsum penis (epispadias), in the median line below at any point on the corpus spongiosum (hypospadias).

Hypospadias is the most common of the congenital deformities of the urethra. When the opening is within one inch of the normal position of the meatus, operative interference for the purpose of establishing a new urethral canal is not indicated. It will, however, in many instances be found necessary to enlarge the abnormal opening in order to permit the free escape of urine. When the false meatus is so far back that in sexual intercourse the semen can not be ejaculated into the vagina, a plastic operation may be undertaken. The chances of failure are always so great that it is scarcely ever justifiable to undertake this operation in the effort to establish an artificial channel for the urine, for, even when the opening is as far back as the perinæum, soiling may be prevented by urinating in the squatting posture. When, on account of absence of the corpus spongiosum (the corpora cavernosa being well developed), painful bowing occurs during erections, operation may be advised.

The operation for the relief of hypospadias consists in introducing a long, delicate knife at the apex of the glans, and carrying it directly back along the normal position of the corpus spongiosum until it emerges in the anterior limit of the urethra at the abnormal opening. This artificial channel should be large enough to admit a straight catheter, which is now introduced through it and well into the urethra beyond the hypospadias.

In closing the abnormal meatus the operation of Szymanowski just given should be made. Interrupted dilatation with the straight steel sounds should be made every three or four days for several months after the catheter is removed.

Neoplasms.—Papillomata and fibromata are occasionally met with growing from the mucous membrane of the urethra. They produce symptoms of obstruction varying with their shape, size, and point of attachment. When situated near the meatus, they may be observed by means of the urethral speculum (Fig. 644). When deeply located, the

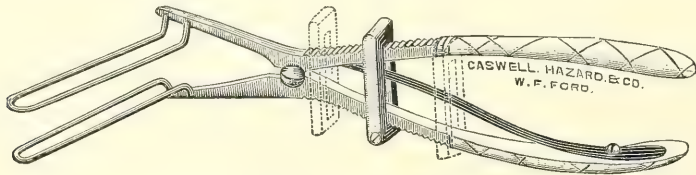


FIG. 644.—Urethral speculum of H. Marion-Sims.

obstruction may be recognized by the bulbous bougie. The only treatment is removal, which may be done by the wire snare or by torsion with forceps. In extreme cases, a longitudinal incision may be required in the median line of the floor of the penis in order to effect removal.

Cancer may originate in this canal, or more frequently extend here from malignant disease of the prepuce and glans. Tuberculosis also occasionally attacks the urethra.

The Penis.—The congenital malformations of the urethra just given may be included with deformities of the penis. The corpus spongiosum is at times arrested in development, while the corpora cavernosa are fully formed, causing the organ to bow when an erection occurs. One cavernous body is, in rare instances, not fully formed, and, when an erection takes place, the curve is lateral, with the concavity toward the affected side. The penis is occasionally double, with separate urethræ. In hermaphrodites it is rudimentary.

Inflammation of this organ is rare, except as a result of traumatism. It occasionally becomes involved by the extension of a phlegmonous or erysipelatous process from the scrotum or abdomen, or from urethritis and posthitis. The organ becomes greatly swollen, and a painful condition of chordee is almost constant. Retention of urine may occur, as well as suppuration or gangrene.

In the treatment of mild inflammation of this organ, local applications will usually prove sufficient. The tendency to erection should be controlled by the use of opium or chloral and potassium bromide in full

doses. When gangrene is threatened, free incisions in the long axis of the organ should be practiced.

Wounds of the penis, involving more than the integument, always bleed profusely. Hæmorrhage may be controlled by direct compression with a roller, or by throwing a few turns of an elastic ligature around this organ near the pubic junction. When the urethra is divided in whole or in part, it is best to stitch the separated walls together by close sutures of delicate silk. Catgut, though more desirable in one sense, is too readily absorbed to hold the edges of the wound in contact for a length of time sufficient to secure union. It is not usually necessary to insert a catheter, and it is best to dispense with this on account of the irritation it causes. Any tendency to stricture may be treated later. When the dense capsule of the corpus cavernosum is divided, this should be included in the sutures which are carried through the wound in the integument. A guarded prognosis should be made in all deep injuries of the penis. Distortion during erection, and stricture, are frequent results of such lesions.

Fracture of the *corpora cavernosa*, an accident which occurs in rare instances as a result of great violence to the erected organ, is a difficult injury to treat. Deformity, with more or less loss of function, is apt to ensue. The organ should be laid up on the abdomen, and kept in a condition of as perfect quiet as possible. Cold applications are indicated, and, in case of *strangulation* from effusion of blood or from any other cause, free longitudinal incisions may be necessitated.

Carcinoma.—Epithelioma of the penis is not an uncommon affection. It commences as a small pimple or erosion on the mucous surface of the prepuce or on the glans, gradually spreading until, if left alone, the entire organ is involved and destroyed. The margins of the ulcer are indurated, elevated, sinuous, and slightly everted. The induration, as a rule, is confined to the immediate borders of the sore, not extending into the deeper tissues unless inflammation supervenes. As the disease progresses, the center of the surface becomes studded with

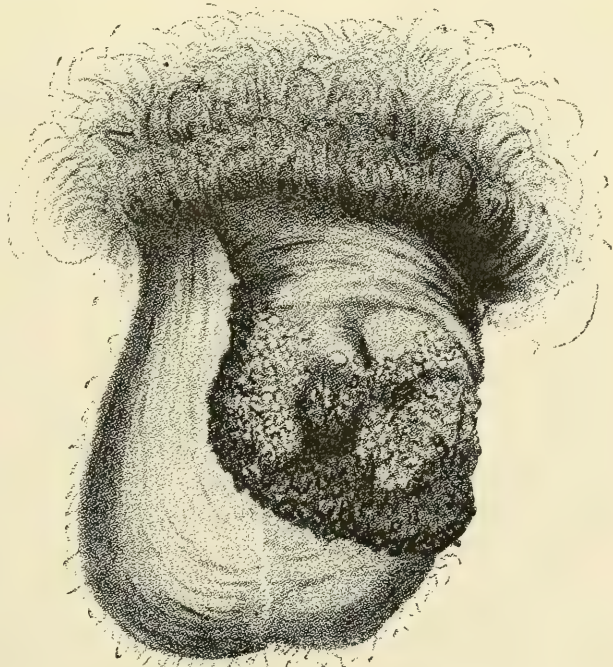


FIG. 645.—Carcinoma of the penis. (From a case in Mount Sinai Hospital.)

buds of newly formed cells and capillaries, giving it an appearance not unlike a cauliflower (Fig. 645). Ulceration occurs at various portions of the mass, and a dirty quality of pus is exuded. The odor from the decomposing tissues is peculiarly penetrating and offensive.

Within a period of time, varying from two to six or eight months, enlargement of the inguinal glands is observed. This enlargement may be inflammatory or metastatic. As a rule, metastasis is not rapid in epithelioma of the penis, and induration of the glands does not, on this account, preclude the hope of cure after amputation.

The principal cause of epithelioma of the penis is prolonged irritation of the glans and prepuce from retained secretions. All the cases which have come under my observation have occurred in patients with unusually long and tight prepuces.* It is usually met with in the middle-aged and old, although it sometimes occurs in early adult life.

The *diagnosis* of epithelioma is not very difficult after ulceration takes place. The indurated sinuous and everted borders of the ulcer, the red, cauliflower-like appearance of the mass, and the steady progress of the disease in the destruction of all the tissues in its path, are symptoms not met with in any other lesion of this organ. Warty growths (papillomata), when not seen early in their development, may at times simulate epithelioma, especially when these vegetations are luxuriant, are undergoing ulceration, are covered with purulent matter, and are the seat of repeated hæmorrhages. No matter how wide-spread the papillomatous neoplasm may be, at the outskirts of the mass will be found tufts or minute warts sufficiently isolated to be recognized. In the very earliest stages of development of the ulcer of epithelioma, it is scarcely possible to make a positive diagnosis between it and chancroid, or even a simple ulcer of the prepuce and glans penis.

Treatment and Prognosis.—The only justifiable treatment of epithelioma of the penis is an immediate excision of the neoplasm by amputation. The line of amputation should always be wide of the limit of the disease. If the induration of the ulcer is well defined, and is limited closely to the margins of the erosion, the amputation may be made with one inch of sound tissue intervening. If the inguinal glands are enlarged, and if the surgeon has reason to be satisfied that the enlargement is due rather to inflammatory engorgement than to metastasis, the operation is still advisable, and the prognosis not altogether unfavorable. When metastasis of the glands is unmistakable, amputation may be done to rid the patient of the foul and ulcerating mass, although a favorable prognosis can not be entertained. In the earlier development of the growth, where a sufficient extent of healthy tissue intervenes between the induration and the line of excision, amputation offers a strong hope of permanent relief. In the earlier period of development of the ulcer, if doubt exists as to its character, it is advisable to administer the

* In an experience of several years in attendance at Mount Sinai Hospital, I have not met with a case of epithelioma of the penis in an individual upon whom in early life circumcision had been performed.

iodide of potassium, together with protoiodide of mercury, for a number of weeks. In this way the differentiation between the later manifestations of syphilis and epithelioma may be assured.

Operation.—Amputation of the penis may be performed by two methods: 1, simple amputation; 2, amputation with transplantation of the urethra to the perinæum. In the selection of the method, the operator must be guided by the nearness of the disease to the pubes and scrotum. Ordinarily, when the induration is limited to the glans, a simple amputation may be made at a point about one inch posterior to this. If the line of amputation must be chosen at or very near the level of the pubes, the second method will be preferable, for the reason that retraction of the stump will always occur, and the urine escaping over the scrotum will keep up a constant and annoying excoriation and condition of uncleanness. In the operation with transplantation of the urethra, the urine is voided in the squatting posture, and escapes freely behind the scrotum.*

Simple Amputation.—Having shaved and thoroughly cleansed the pubes, scrotum, and penis, throw an elastic ligature around the organ at the level of the pubes. If the line of amputation is very near the ligature, this may be prevented from slipping by transfixing the penis with a large needle just in front of the tourniquet. Seize the mass with a double hook, and, holding it steady, with a long, thin-bladed knife cut the organ smoothly off at a point at least one inch behind the disease. A tenaculum should be in readiness to prevent the erectile tissue from retracting. The tube of the urethra should now be dissected up for half an inch, and the tissues of both cavernous bodies again divided on a level with the point to which the dissection of the spongiosum has been carried. The urethra is now split by passing the knife through its roof and floor, and a silk suture carried through the end of each lateral half. A thread is also passed through the dense capsule of the corpora cavernosa to prevent their retraction when the elastic ligature is removed. All vessels which may be recognized before loosening the rubber band should now be secured with catgut ligatures, and the remaining bleeding points caught up as the tourniquet is gradually loosened. The sutures passed through each half of the urethra are now carried through the edge of the incision in the skin to which it is sewed. A simple dressing completes the operation.

Humphrey's Operation.—The elastic ligature is carried around the penis close up to the level of the pubes, as in the preceding operation, and the organ severed as near the ligature as possible. The vessels in the corpora cavernosa should be tied at once. An incision should now be made through the skin along the under surface of the corpus spongiosum, back to and splitting through the base of the scrotum, so as to expose the tube of the urethra for about two and a half inches. This

* I have performed this, the operation of Humphrey, three times, and in none of these patients has any unpleasant symptom followed. Two of the cases are still under observation three years after the operation.

tube is carefully dissected out from its attachment beneath and between the two corpora cavernosa for this distance, and is turned down on to the perinæum through the slit in the posterior wall of the scrotum. The urethra should next be split along the median line of its roof for a

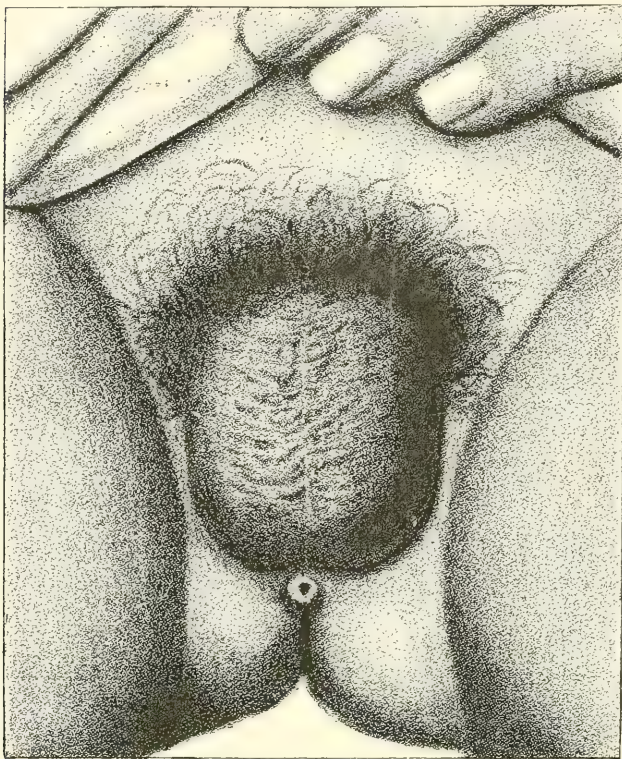


FIG. 646.—Humphrey's operation. (From a case of the author's, at Mount Sinai Hospital.)

distance of half an inch back from the end, and the edges stitched to the margins of the wound in the integument of the perinæum. The operation is completed by closing the posterior slit through the scrotum, and stitching the margin of the wound in the skin of the anterior wall of the scrotum to that of the belly at the root of the penis, so as to cover in and include the stump of the amputated corpora cavernosa. The appearance of the parts after this operation is shown in Fig. 646.

Sarcoma of the penis exceedingly rare.

It may be recognized

by its rapid development, the absence of glandular enlargement, the general invasion of the cavernous bodies—in certain cases producing a continuous and painful erection of the organ—and by its resemblance to the well-known appearance and behavior of sarcomatous tumors in other portions of the body. The treatment should consist in immediate amputation.

Phimosis, or inability to retract the prepuce behind the corona glans, is a frequent condition of childhood, and occasionally met with in adult life. It is both a congenital and an acquired affection, and may be partial or complete. The prepuce may be adherent to the glans, or phimosis may exist without adhesions, the opening in the foreskin being so narrow that retraction is impossible. A prepuce ordinarily retractile may become irretractible as a result of any inflammatory process of the glans and foreskin. This condition is not infrequently met with in gonorrhœa and with chancroid.

Congenital phimosis is an unfortunate affection, preventing perfect cleanliness by retention and decomposition of the retained secretions

and urine, and inducing a condition of irritation which it were better to avoid by timely operative interference. Inflammatory or acquired phimosis always requires careful attention, and very frequently a surgical operation, to prevent gangrene or to expose a subpreputial chaneroid.

The operative measures may include: 1, amputation of the prepuce (circumcision); 2, dilatation of the preputial orifice with forced retraction; 3, incision of the anterior portion of the prepuce and retraction.

The first of these procedures should be preferred in all cases in which there is no inflammatory process present, while the latter is advisable in phimosis with acute balanoposthitis.

Operation.—In adults, circumcision may be done with perfect freedom from pain by the proper employment of cocaine. In children under six years of age, chloroform narcosis is advisable.

In adults, proceed as follows: Cleanse the parts to be operated upon with 1-to-5000 sublimate solution, and throw an elastic ligature around the penis at the level of the pubis. From m xx-xxx of a 4-per-cent cocaine solution are now injected by inserting the needle at the margins of the preputial orifice, and carrying it back between the mucous membrane and integument of the prepuce a little behind the proposed line of section. In the middle of the dorsum three or four minims are forced out of the syringe, the needle *partially* withdrawn and carried a half-inch to right and left of this point, and a like quantity is injected, and so on until the entire line of amputation is anæsthetized. As a rule, it will suffice to insert the needle once in the median line above, and once at the frænum, and from these two locations it may be thrust beneath the skin to either side until the prepuce is completely encircled.

In selecting the line of incision, the best rule is to allow the parts to assume their normal relations, and mark the foreskin, by repeated punctures with the scalpel, parallel with and one fourth of an inch anterior to the outline of the corona of the glans. A dull-pointed, grooved director should now be passed between the upper surface of the glans and the prepuce, in the median line, until the point is at the line of amputation. A sharp-pointed bistoury is next slipped along the groove in the director, thrust through, and the foreskin split by cutting from

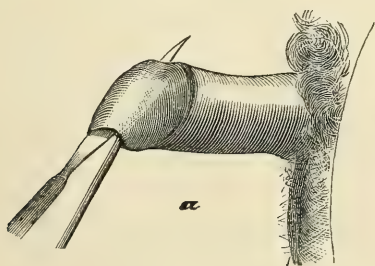


FIG. 647.

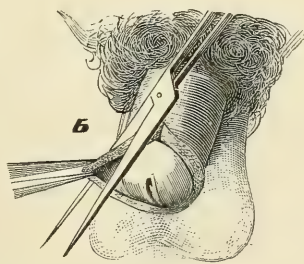


FIG. 648.

behind forward (Fig. 647). Or this incision may be made from before backward with a pair of straight scissors. The edges of the flaps are now seized with a pair of mouse-tooth fixation-forceps, and trimmed

off with scissors, being careful to follow the line already indicated (Fig. 648).

When these incisions are completed, it will be observed that the edge of the divided mucous membrane remains at the level of the incision—namely, a quarter of an inch in front of the outline of the corona glandis—while the skin retracts beyond the corona. The mucous membrane should now be turned back, and its edge stitched to that of the incision in the skin. Fine catgut should be used, and an interrupted or continuous suture employed. The former is somewhat more accurate, although it requires much more time in its insertion than the latter. It is important, in the effort to secure immediate union, that at all points the approximation is carefully made between the margins of the integument and mucous membrane. After the sutures are inserted, the

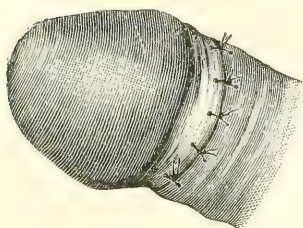


FIG. 649.—(After Malgaigne.)

mucous membrane rolls back, leaving the stitches behind the corona (Fig. 649). The elastic ligature is now removed, and a light dressing applied over the line of sutures. This operation is entirely bloodless. The patient should be directed to prevent the urine from getting into the wound. The sutures disappear by absorption, and the union is complete in from four to ten days.

When the prepuce is adherent to the glans, it will be found impossible to introduce the grooved director as above

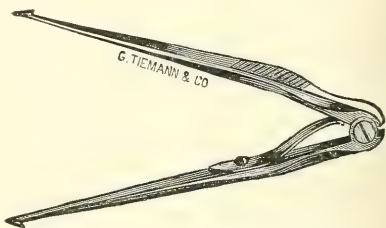


FIG. 650.—Girdner's phimosi-forceps.

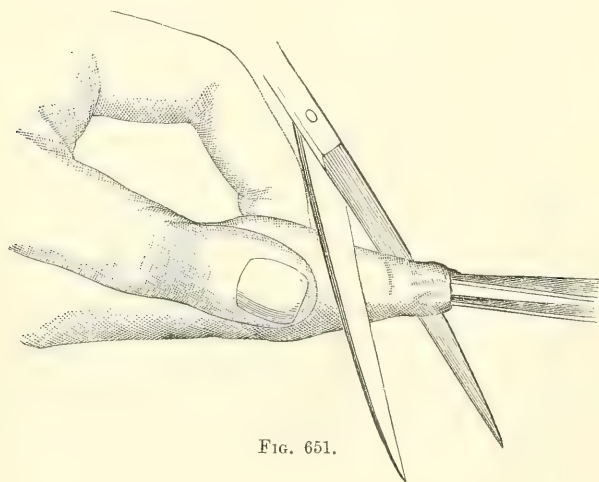


FIG. 651.

unless the adhesions are first broken up. Under these conditions, the following operation should be performed: Carry the phimosi-forceps (Fig. 650) into the opening of the prepuce, and allow the blades to expand so that the hooklets at the tip will catch in the mucous membrane. The foreskin is now drawn well to the front by an assistant, while the operator slips the thumb and finger of the left hand along the penis and grasps the

foreskin just in front of the meatus. In young children, considerable care is necessary to prevent cutting off a portion of the glans with the pre-

puce. The foreskin is next amputated with the scissors just in front of the finger and thumb (Fig. 651). As retraction takes place, it will be seen that the line of section in the skin is near the corona, while that in the mucous membrane is only a little back of the meatus. This should be seized with the mouse-tooth forceps, and the adhesions broken loose or divided with the scissors. The mucous lining should now be pared back to a sufficient distance, and, if necessary, a second division of the prepuce made. The sutures are applied as in the preceding operation.

Dilatation or *divulsion* of the prepuce is rarely, if ever, indicated. It is performed by introducing the point of a small, closed dressing-forceps into the opening of the foreskin, and stretching or tearing this by forced separation of the blades. The operation is completed by retracting the prepuce and breaking up all adhesions. In the after-treatment it is essential to move the foreskin back and forth over the glans once or twice daily to prevent the re-formation of adhesions.

Incision limited to the anterior half-inch of the foreskin, and in the median line of the dorsum, is a more advisable operation when circumcision is contraindicated. Retraction should be immediately effected.

Ulcers of the Penis.—Sores may occur upon the integument of the penis, usually near the prepuce; upon the mucous lining of the foreskin; the glans; within the meatus; and along the urethra. Venereal sores are occasionally met with upon the integument of the scrotum, abdomen, perinæum, and thighs. Ulcers of the penis only will be considered here. They are divisible into two classes—namely, the non-specific and the specific ulcer. To the former belong the sores which follow abrasions and the eruption of herpes. They are more or less phagedenic in character, the extent and rapidity of the process of necrobiosis being due to the degree of virulence of the inoculating pus-corporuscles, the thoroughness of the inoculation, and the impoverished condition of the tissues attacked. The *chancroid* belongs to this group. In the second class belongs the specific ulcer of syphilis.

Non-specific Ulcers.—A *simple* ulcer of the penis is extremely rare. It may occur here, as in other parts of the body, as a result of traumatism, or an inflammatory process not due to the inoculation of a virus. Thus, the molecular death of a variable extent of tissue may follow a simple abrasion if the part involved is not kept free from all irritation, and if there prevails a condition of impaired nutrition, in which, as is well known, the tissues yield readily to the destructive process. Under more healthful conditions, an abrasion of the glans or prepuce undergoes the simple process of repair seen in similar lesions of the integument and mucous surfaces elsewhere. Abrasions usually occur on the sides of the penis, close to the attachment of the prepuce, just behind the corona or near the frænum. The glans is rarely involved, although the meatus, especially at its lower angle, may be torn. Bleeding sufficient to attract the attention of the patient is rare, unless extensive laceration has occurred.

The *ulcer of herpes* is usually situated upon the surface of the mucous lining of the prepuce, less frequently upon its cutaneous surface,

and the glans. It begins as a vesicular eruption. There may be one or many. Multiple herpetic vesicles may be scattered or in clusters, linear, semilunar, or circular in arrangement. In the recent state the herpetic vesicle is round at its base, measuring from one twelfth to one twenty-fifth of an inch in width. It consists of a thin investing membrane resting upon a slightly red and irritated base, and containing a clear, serous fluid, which often escapes by rupture of the membrane before the vesicle is observed. Upon the skin they rapidly dry on account of evaporation of the fluid contents, and the floor of the patch becomes covered over with a light incrustation. Upon the mucous and moist surfaces, incrustation does not occur. The circumference of the base exposed after rupture of the vesicle is usually round, with well-defined walls leading perpendicularly down to the bottom of a shallow excavation.

In typical cases of genital herpes, the morbid process ends here, the sore healing without suppuration. Not infrequently, however, the floor becomes covered with a layer of pus, the walls are undermined and break down, forming an ulcer which is phagedenic in character. The character of the pain varies. In some instances there is a stinging, burning, sensation felt in the part affected; in others there exists total insensibility.

Herpes is a neurosis due to a local irritation of the nerve terminations in the part attacked. In some instances a severe neuralgia of the branches of the sacral or lumbar plexuses exists at the time of the eruption on the glans and prepuce. Uncleanliness is a frequent cause of this disease. Any irritation of the glans or prepuce may induce it, and one attack is apt to be followed by a second.

In mild and ordinary cases it runs its course in from ten days to two or three weeks. In other forms, especially when inoculation occurs, it may last for a number of weeks, and is usually complicated by lymphangitis and adenitis.

Phagedenic ulcer of the genital organs was formerly held to be the result of the inoculation of a specific poison—the virus of “chancroid”; but, since ulcers which in appearance and behavior do not differ from the so-called chancroidal ulcer have been produced by inoculation with corpuscles taken from the pustules of acne, from gonorrhœal pus, etc., the specific nature of this virus can not be maintained. Even the specific ulcer of syphilis will, as a result of repeated and prolonged irritation, take on a phagedenic character.

This ulcer results most frequently from direct contagion, the pus-corpuscles which contain the virus being lodged in an abrasion of the integument, prepuce, or glans. The period of incubation—that is, the length of time between the date of the contact and the recognition of the sore—will vary in different individuals. It has been seen within twenty-four hours, and, in rare instances, as much as twenty days have elapsed. In a very large majority of cases the inflammation is observed within the first nine days after the inoculation. The rapidity of its appearance depends in part upon the quantity and virulence of the pus, but chiefly upon the thoroughness with which it is brought into con-

tact with the tissues in an abrasion. The spread of the ulcer and its phagedenic character also depend upon the virulence of the poison and the condition of the tissues at the time of the invasion. The ulcer is usually located on the side of the penis, just behind the corona glandis at the preputial attachment, at the points where abrasions are most frequent. It may be on the cutaneous surface of the prepuce, upon the body of the penis, the scrotum, or within the meatus. There may be one or more, owing to the number of abrasions and the distribution of the virus. A single ulcer may result from the confluence of several contiguous points of inoculation. It is first noticed as a light redness or flush, usually circular or elliptical in shape, or, if the abrasion is irregular in outline, it will conform to this. Within a few hours after the appearance of the redness, its center becomes elevated and a pustule is formed, which soon breaks down, discharging a small quantity of matter.

If the sore is not seen early, the pustule may escape observation. When the inoculation occurs upon a surface denuded of its mucous membrane or epidermis, a pustule is not formed. The walls of a phagedenic ulcer are usually precipitous. At times the superficial layers of the skin resist disintegration longer than the deeper layers and subcutaneous tissues, giving the edges an undermined appearance. It tends to spread in width rather than in depth, although in a certain proportion of cases extensive destruction of tissue may occur in all directions. The floor of the ulcer is covered with pus and broken-down tissues in various stages of decomposition. A small quantity of matter of creamy consistence may be removed with a pellet of cotton. A membrane or film of a yellowish-brown color usually adheres to the floor with considerable tenacity.

A zone of redness extends along the edges of the ulcer in advance of the tissue-destruction. In many ulcers this is not more than a line in width. If the sore is subjected to irritation, the inflammatory redness and induration may spread widely into the surrounding tissues.

Pain, which is always present, varies, as a rule, with the extent of the inflammatory process.

In a typical phagedenic ulcer of the penis, lymphangitis and adenitis of the inguinal glands are always present in a varying degree. In the simpler forms, adenitis does not occur, although the lymphatic channels in the neighborhood of the sore may be involved. Inguinal bubo is always a painful complication. It may be lateral or bilateral. If the sore is in the median line, or if there are ulcers on both sides, both groups of glands will be affected. Suppuration of the inguinal bubo of phagedenic ulcer is not uncommon. The violence of the inflammatory process here is subject to the same conditions as given for the primary ulcer. One or more glands may be involved and suppurate. In severe adenitis, the inflammation extends to the tissues immediately surrounding the glands. The mass appears as one large swelling, over which the integument is red and œdematous, and to which it is adherent. Phagedenic bubo is apt to follow a virulent phagedenic ulcer of the penis.

Treatment.—Simple ulcer of the penis, if left without interference, usually heals within a few weeks; the ulcer of herpes is usually more obstinate. The process of repair may be greatly facilitated by a careful removal of all sources of irritation. Strict cleanliness is essential, no matter what form the ulcer may assume. Soaking the part in warm black wash (calomel ʒj to lime-water Oj) two or three times a day is an excellent method of treatment. The local use of liquor plumbi subacetatis dilutum is also advisable.

In addition to the foregoing, it is essential to keep the sore uncovered by the prepuce, which should be worn back behind the corona. Circumcision may at times become necessary to obtain a permanent cure. If the simpler remedies just given do not succeed, the local use of the nitrate-of-silver pencil is indicated.

In phagedenic ulcer, as a rule, more vigorous measures are necessary. The severity in local treatment will depend, however, upon the rapidity of molecular death which the poison is causing in the tissues. If its progress is slow, and the inflammation mild in character, recovery may be brought about by the treatment laid down for simple and herpetic ulcer. If within the first few days of its appearance the spread of the sore is rapid, or if, when first brought to the notice of the physician, it is more than a quarter of an inch in diameter, and the zone of redness spreads well out into the tissues, it should be treated as follows: By the introduction of a delicate hypodermic needle through the sound tissues, after which its point should be carried under the base of the ulcer, from fifteen to twenty minims of a 4-per-cent solution of cocaine should be injected, by which means complete anæsthesia may be secured. The pus should now be removed from the bottom of the sore with a pellet of absorbent cotton on the end of a small piece of wood. The parts immediately about the ulcer should be coated over with vaseline or oil, to protect them from excoriation. A small quantity of carbonate of soda should be on hand to neutralize any excess of acid. In applying pure nitric acid, the ulcer should, if possible, be held so that it will contain the acid without letting it run over the edges. It is best applied by means of a wooden match or tooth-pick dipped in the acid, and the point immediately carried into the floor of the ulcer. It should be conveyed into every portion of the sore, and allowed to remain in contact with the virus for one or two minutes. The excess may now be soaked out with the cotton pellets, and the ulcer filled with soda. A piece of lint moistened in vaseline will serve as a dressing. When nitric acid can not be had, the actual cautery should be employed.

Iodoform may be dispensed with, on account of the disagreeable odor of this substance.

When phagedenic ulcer occurs beneath an irretractible prepuce, this should be incised and the sore treated as above. Ulcer of the meatus should also be burned with nitric acid. Complete rest is essential, and constitutional measures looking to the improved nutrition of the tissues are strongly indicated. If suppuration occurs in the glands of the inguinal region, free incision should be made and free drainage estab-

lished. Phagedenic bubo should be treated in the same manner as the phagedenic ulcer.

The Specific Ulcer (Chancre)—Syphilis.—Syphilis is a disease affecting in a varying degree the nutrition of all the tissues of the human body. It is caused by the introduction into the blood of a specific virus. In practice, two distinct forms are met with, namely, the *acquired* and the *inherited*.

Acquired syphilis ensues when the specific virus is carried into the lymph or blood-channels of a human being not syphilitic at the time of inoculation. Although no demonstration of a specific germ of this disease is as yet widely accepted, the "*bacilli*" discovered by Dr. Sigmund Lustgarten in the primary, secondary, and tertiary lesions of syphilis, if not the carriers of this virus, are clearly in intimate relation with the inflammatory changes occurring throughout the disease.

While it is generally believed that an abrasion of the skin or mucous surface is essential to the absorption of the syphilitic virus, it is extremely probable that, if it is brought and kept in contact with the thin unbroken skin or mucous membranes, absorption may occur. A disease the germs of which are transported within the spermatic elements, and with such potency that the impregnated ovum is affected, can, under favorable conditions, in all probability be transmitted from unbroken cutaneous or mucous surfaces through which it is demonstrable that the absorption of other elements occurs.

The chief source of the contagion is in the fluid which transudes from the surface of the initial lesion or ulcer (chancre), and, next in order, that from mucous patches. The blood of a syphilitic patient also carries the poison and produces the disease if injected into or inoculated upon the tissues of another. The same is true of the matter or fluid from the cutaneous lesion of the secondary stage of syphilis. It is doubtful if the lesions of tertiary syphilis are capable of reproducing the disease.

Saliva from a syphilitic subject, unmixed with the discharge from mucous patches, fails to produce syphilis. Seminal fluid from a syphilitic man, in any of the stages of the disease, is held to be not directly contagious. However, the mother may acquire the disease from a child *in utero*, the child being syphilitic from the spermatozoa. Milk from a woman in any stage of syphilis will not produce the disease if injected into the tissues or ingested as food.

The transudation from a fissure in the nipple of a syphilitic nurse will, if lodged in an abrasion upon the lips, tongue, or buccal wall of the child, produce the specific disease in a non-syphilitic subject. On the other hand, a syphilitic child may inoculate a healthy nurse. The urine, tears, and sweat of syphilitic patients do not convey the specific virus. Pus from a vaccine pustule on a syphilitic subject does not convey the virus of this disease even when the vaccination is successful. If, however, blood or the fluid from any early syphilitic lesion is mingled with the pus, syphilis results.

While the most frequent seat of inoculation is upon the genital organs, or in their immediate vicinity, it may occur at any part of the

body. The contagion may be direct or indirect. In the former, the virus of a specific ulcer is brought directly in contact with an abrasion upon a non-syphilitic subject. In the latter, the poison adheres to some intermediate agent, and thence is conveyed to the abrasion.*

The clinical history of a typical case of acquired syphilis left without treatment, and in a certain proportion of cases in which treatment is instituted, is divided by usage into three stages—primary, secondary, and tertiary. In a majority of cases, when properly managed, the later manifestations may be eliminated, and the secondary stage made shorter and less severe.

The *primary stage* includes: 1, absorption of the virus; 2, the ulcer; 3, local lymphangitis and adenitis.

The symptoms which belong to the *second stage* are the cutaneous eruptions, mucous patches, fever, arteritis, condylomata, alopecia, iritis, and general adenitis. In the *tertiary stage*, the pathological changes are chiefly confined to the arteries, viscera, bones, the integument, and the subcutaneous and submucous connective tissues. This is the period of gummy tumors, connective-tissue formations, arterial occlusion, and deep ulcers of the skin and mucous membranes.

The usual duration of the first stage is from six to nine weeks. Secondary symptoms may, however, appear at the fifth or sixth week from the date of inoculation. On the other hand, in rare instances, they may be delayed to between the third and sixth month. The limitation of the stages of this disease is in great part arbitrary.

The duration of the second stage varies from the fifth or sixth week (or in delayed cases the sixth month after contact) to about the end of the first year after the inoculation.

The tertiary stage begins at the end of the preceding stage, and may last indefinitely.

First Stage.—When the specific virus is brought in contact with a broken cutaneous or mucous surface, absorption may begin at once or be delayed for a considerable period. The abrasion may be so insignificant that the patient's attention is not attracted to it, and, although the virus is lodged in it, it may heal over within a few days. If subjected to irritation by friction, or the simultaneous inoculation with the virus of phagedenic ulcer or other virus, inflammation supervenes, and an ulcer more or less phagedenic in character appears.

Absorption takes place chiefly through the lymphatics. It may occur through the blood-vessels, and it is possible that in those cases in which constitutional symptoms appear with great rapidity and severity, the dissemination of the virus takes place in this way.

The rapidity of lymphatic absorption varies. There is usually a period of about three weeks from the time of lodgment of the virus until

* In one of my cases the inoculation occurred in a fissure of the lip in the person of a merchant who was using a glass in common with a customer in sampling wines. In 1883 a patient presented himself at the clinic who had had a specific ulcer and syphilis resulting from being tattooed upon the arm. The operator moistened the point of the needle with saliva in which the virus from mucous patches was mingled, and thus conveyed it into the integument.

the local inflammatory process is recognized. That the specific virus has passed into the neighboring lymph-channels before the appearance of the ulcer (chancre) seems satisfactorily proved in the repeated experiment of freely excising the initial lesion at its earliest appearance, in which cases constitutional infection was not retarded or prevented.

The *ulcer* of syphilis always appears at the point where absorption of the virus took place. From the inoculation to its appearance, the lapse of time is usually about three weeks—not less than ten days; occasionally delayed as many weeks. Its duration varies from two to ten weeks, occasionally longer. It often begins as a small papule, from the covering of which a clear serum escapes, or from the beginning it may exist as an erosion. There may be one or many, owing to the number of points simultaneously inoculated.

An uncomplicated initial lesion, not subjected to irritation, does not tend to ulcerate. It is usually circular or oval in outline, is shallow, increasing gradually in depth from the periphery toward the center, and its surface is covered with a yellow serous transudation.

Grasped between the thumb and finger, it is found to be indurated, not painful. The induration is closely limited to the sore, and terminates rather abruptly, not fading off gradually in a wide infiltration of the skin or neighboring tissues.

When the specific ulcer of syphilis is inoculated with a virus which induces phagedena, its peculiar character is lost, and it becomes in appearance and behavior a non-specific sore. If from friction or the application of corrosive substances, or the cautery, an acute inflammation is precipitated, the specific character of the lesion also disappears.

Local lymphangitis and adenitis always occur in syphilis during the formation and existence of the initial ulcer. Commencing in the lymph-channels immediately around the lesion, the process travels in the direction of the nearest glands. If the sore is well on one side, the glands of that side are usually first affected. When situated in the median line, or if ulcers exist on both sides, the adenitis is apt to be bilateral. In very exceptional cases, ulcer of one side is followed by unilateral adenitis on the opposite side of the body. Dating from the appearance of the sore, from eight to fourteen days usually elapse before enlargement of the inguinal glands is noticed. Less frequently, three or four weeks intervene.

From one to seven distinct glandular nodules may be felt. They are hard, yet slightly elastic to the touch, not painful under ordinary pressure, and freely movable beneath the skin. The size varies from those which are so small as scarcely to be recognized up to a half-inch or more in diameter. There is no periadenitis, and, unless an acute or phagedenic inflammatory process is superadded, the glands do not become matted together in one hard, painful lump, nor does the integument become red and painful, as in the adenitis of phagedenic ulcer or gonorrhœa.

The primary adenitis continues into the second stage, in which induration of the glands is general.

When the ulcer is situated upon the lips, tongue, or mouth, the sub-maxillary plexus becomes enlarged. Adenitis of the epitrochlear and axillary glands follows inoculation upon the fingers, hand, or forearm.

Second Stage.—Cutaneous and mucous lesions, alopecia, fever, headache, arteritis, lymphangitis, adenitis, iritis, and osteitis.

The cutaneous lesions of syphilis (*syphilides*) may be macular, papular, vesicular, pustular, and tubercular. Of these forms of eruption, some are peculiar to the secondary period, others to the tertiary, while, as will be seen, some are met with in both the second and third stages.

The *macular* syphilide is usually first seen occurring as indistinct spots or stains, not elevated, and varying from a light red to a slate or copper color. They appear very frequently at the limit of the first stage of syphilis, about the sixth or seventh week after the ulcer occurs, but often later than this period. The portion of the body where the maculæ are usually first seen is upon the abdomen, whence they may extend over the entire cutaneous surface. In size they vary from a pin-head to round or oval spots a half-inch or more in diameter.

The *papular* syphilide occurs in several forms which may be present in the secondary or tertiary period. The mucous surfaces, as well as the integument proper, are affected. Not infrequently the papulæ are preceded or accompanied by maculæ. The papulæ assume various shapes, some being small and pointed, others broader at the base and flat on top, in shape like a truncated cone. Upon mucous surfaces the papular character of the eruption may be observed if seen early in its appearance; but, on account of the moisture present, the papules soon disappear, leaving patches which may be elevated or depressed. *Mucous patches*, when recent, are red in color, but later become covered with a grayish film.

The papular syphilide, which occurs near the junction of the skin and mucous surfaces, or in the deep folds, as those below the mammary glands in women, and the thighs and gluteal regions in fleshy individuals of either sex, not infrequently, as a result of uncleanliness and irritation, becomes developed into papillary or warty growths known as *condylomata* (Fig. 652).

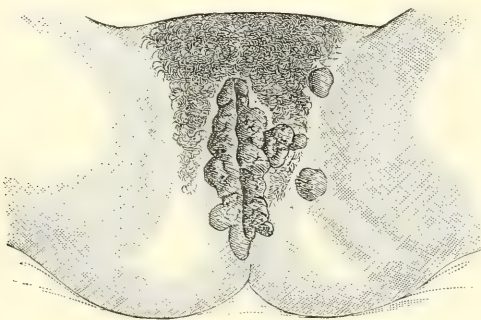


FIG. 652.—Vegetating condylomata of the vulva.
(After Bumstead and Jullien.)

The eruption comes out in some cases over the entire body; in others the face is exempt. The palms of the hands and the soles of the feet are not infrequently invaded. At times the

trunk is chiefly occupied; the face, hands, and feet escaping. The margins of the papulæ are well defined, varying in size as did the maculæ, and also in color. In the main they are darker, and the pigmentation

is more marked. The eruption disappears by absorption of the cells which have infiltrated the papillæ and corium, and this may occur with or without desiccation or scaling. The *scaling syphilide*, or so-called *psoriasis syphilitica*, is at times with difficulty differentiated from true psoriasis, especially when the venereal inoculation is denied.

The *vesicular syphilide* is peculiar to the second stage, and is seldom observed. The vesicles, like the papules, may be small, pointed, and gathered in clusters, as in herpes; or larger, like the vesicles of chicken-pox, and scattered at varying intervals over the entire body. Commencing as vesicles, they may become pustules, which, as evaporation occurs, are covered with small crusts or scabs.

The *pustular syphilide* may be met with on all parts of the body, and may originate as a pustule, or, as stated above, become pustular from a vesicular or papular origin. This variety of cutaneous lesion, while most common in secondary, is not infrequently seen in tertiary syphilis. The smaller-sized, more superficial pustules, belong naturally to the earlier period; those with wide bases and more extensive tissue-destruction, to the later manifestations.

The pustular syphilide originates around and in the hair-follicles. In mild cases, and when of small size, the limit of infiltration and pustulation is immediately around the follicle. In other cases the infiltration is wider, and the destructive process more extensive.

Scabbing, with underlying ulceration varying in extent, is the common history of all pustular syphilides, although extensive molecular death of tissue is less apt to occur in the secondary than in the tertiary stage. The color of the crusts varies from black to a brownish-copper color. If the scab is removed, the walls of the ulcer will be seen to be precipitate and curvilinear in outline, while the floor is covered with a varying amount of fluid and detritus.

The *tubercular syphilide* is so rarely a lesion of secondary syphilis that it will be described with the symptoms of the third stage of this disease.

It is exceedingly rare to observe all of the foregoing syphilides in any single individual. The macular and papular eruptions are frequently met with together, while the pustular syphilide usually exists alone.

Alopecia occurs in a varying degree in most cases of syphilis. Though noticed chiefly in the scalp and beard, all the hairy portions of the body are involved. Except in the case of the pustular syphilide, the follicles are rarely destroyed, so that, as the violence of the attack is diminished, the hairs are reproduced. Alopecia, from general seborrhœa, is one of the later manifestations of syphilis.

Fever.—Elevations of temperature occur in the second stage of syphilis in a large proportion of cases. In mild attacks it may not be observed, but in many instances the thermometer will register from one to two or three degrees above the normal. The febrile movement usually begins when the virus has passed through the first network of lymphatics and is being disseminated throughout the tissues. It may precede

the eruption or occur with it, and, as a rule, continues after the eruption fades away.

Headache, usually referred to the frontal region, at times to the vertex or base, occurs during the period of fever, and is generally proportionate to the intensity of the febrile movement.

Arteritis, *lymphangitis*, and general *adenitis* occur in the second stage, and, in neglected cases, continue until the third stage. *Iritis* is not uncommon in secondary syphilis. It is usually unilateral, and may be recognized by immobility of the iris, photophobia, and by the injection of the membrane.

Pathological changes in the bones do not occur, as a rule, in the earlier stages of syphilis. Pain, usually mild in character, is present in some cases in the second stage, but lesions of the osseous structures belong especially to the last stage of this disease.

Third Stage.—The lesions of *tertiary* syphilis manifest themselves not earlier than the second year of the disease. Once present they may continue for a while, and disappear, to return at varying intervals during the life of the individual. No tissue or organ is exempt from the grave pathological changes induced by the syphilitic virus in this stage.

Skin.—Externally, the changes in the skin are chiefly those of ulceration. Nodules, resulting from cell-proliferation and accumulation in the deeper layers of the skin, and at times in the subcutaneous tissues (*gummata*), appear, and after existing for a variable period of time may, by interference with the nutrition of the part, lead to molecular death of the adjacent tissues, or, failing in this, undergo fatty metamorphosis and absorption. If an ulcer exists, it has the usual shape of the syphilitic sore—round, oval, or curvilinear, with regular edges, not ragged or indented. When granular degeneration of the new tissue occurs, the skin immediately over the tubercle has a stretched or glazed appearance, and is slightly discolored.

A not infrequent pustular cutaneous lesion of the third stage of syphilis is known as *rupia syphilitica*. In very rare instances a pustular syphilide, similar in appearance and with difficulty differentiated from *rupia*, occurs as a secondary lesion. I presented one such case, with an unmistakable history of acute syphilis, to the New York Pathological Society in 1884. The pustules in *rupia syphilitica* are usually circular or oval in shape, appear as slight elevations or blebs, which soon break open. The sero-purulent contents ooze out; evaporation and scabbing occur; the crusts, by reason of the new deposit underneath, are gradually lifted, and give to the scab a laminated, rough appearance, not unlike that of an oyster-shell. The crusts have a dark-brown or slightly greenish hue.

When the late cutaneous lesions of syphilis attack the fingers, the nail or matrix is affected (*paronychia*), causing a roughened condition of the nail and a swollen matrix, leading frequently to temporary, and occasionally to permanent, loss of the organ. In like manner, permanent alopecia may occur from destruction of the hair-follicles.

Nervous System—Brain.—*Paralysis* is one of the more frequent lesions of tertiary syphilis, and may result from one of several causes, namely—pressure of a gumma developed within the brain-substance proper or upon the investments; pressure from syphilitic exostosis of the skull; destruction of brain-cells by connective-tissue hyperplasia in the neuroglia, with consequent cicatrization and contraction; more or less complete occlusion of the arteries (*endarteritis obliterans*).

Hemiplegia, partial or complete, is the rule. Occasionally the center of language is alone affected. Dementia may ensue as a result of softening or pressure, and epilepsy may be classed among the late manifestations of this disease.

Chronic *meningitis* is an occasional symptom of late syphilis. It is accompanied by headache, dull and persisting in character, impairment of intellect, interference with the functions of one or more of the cranial nerves by extension of the morbid process, resulting at times in ptosis, strabismus, or impairment of vision, hearing, taste, smell, etc. The more serious cases progress gradually to coma and death. There is in all an elevation of temperature, loss or impairment of appetite, and derangement of the entire digestive apparatus.

The *spinal cord* and its *membranes*, though less frequently attacked than the brain, may be involved as a result of similar pathological conditions. Paraplegia more or less complete ensues, involving at times the bladder and rectum. In milder cases co-ordination is disturbed, with little or no loss of muscular power. Pain may be present, referred to the back at or near the seat of the lesion, or along the distribution of the sensory nerves, or anæsthesia may occur.

One or more of the *nerves*, sensory or motor, may in like manner be affected as a result of the development of gummata, or connective-tissue changes in the neurilemma, or the pressure of exostoses or other neoplasms.

Bones.—*Periostitis* and *ostitis*, especially in those portions of the skeleton most exposed to sudden changes in temperature and to direct violence, are among the more frequent lesions of tertiary syphilis. The bones of the skull, the spine of the tibia, and the clavicle, are more often involved. The swelling caused by the inflammatory exudation may be readily appreciated by palpation, and pain or tenderness is present on direct pressure. The tumefaction results from the formation of new bone (exostosis), which in some instances persists indefinitely.

Gummata are developed upon or beneath the periosteum, forming soft, semi-fluctuating swellings, usually circular in shape, and from a half-inch to an inch or two in diameter. These tumors or *nodes*, while not very painful under ordinary pressure, are the seat of exacerbations of pain which are usually experienced at night. They frequently break down in a process of ulceration which involves the underlying bone.

When the inflammatory process is violent, extensive necrosis may occur. A peculiar type of ostitis in the later manifestations of syphilis is that known as osteitis rarefaciens, in which there is no suppuration or

exfoliation, a portion of the bone-substance undergoing absorption, giving to the part involved a porous or worm-eaten appearance.

Hypertrophy of the bones, even to a remarkable degree, is not uncommon, and may be due to the development of compact substance beneath the periosteum, or the entire cancellous portion may be replaced by this eburnated tissue. On the other hand, the hypertrophy is in some cases entirely cancellous in character, the bone taking on two or three times its natural thickness.

Joints.—The pathological changes in bone may also be accompanied by like changes in the articulations.

Synovitis, with thickening of the membrane and surrounding capsule, is present, accompanied by impairment of motion and pain of a dull character. In severer cases, the cartilages and bones become involved, leading to osteo-arthritis and destruction of the joint.

Heart and Vessels.—Fatty degeneration of the heart-muscle, following syphilitic myocarditis, and the formation of gummata upon the pericardium or within the muscular walls, are the chief lesions of this organ in the tertiary period. The pericardium may also be affected, and in like manner the endocardium, which may undergo atheromatous degeneration or give rise to vegetations. Of the vessels, the capillaries always affected in the first and second stages, are not so seriously involved in the last stage as the arteries. The veins are rarely affected. Arteritis, especially the variety known as *endarteritis obliterans*, is one of the most common and grave lesions of chronic syphilis. While the larger trunks are involved, the more characteristic changes occur in the terminal arteries and arterioles. The cerebral vessels are especially susceptible.

Lymphatics.—Gummatous deposits occasionally take place in the lymphatic glands in tertiary syphilis. The superficial set may break down and discharge their contents. The deep glands undergo granular degeneration with absorption, or the gummatous material undergoes the caseous or calcareous degeneration.

Respiratory System—Nose.—The mucous membrane may be thickened, or may be more or less destroyed by ulceration. The cartilage and bony framework of this organ are very often destroyed.

Larynx.—The mucous membrane of the larynx may also be thickened, or the seat of ulcers or vegetations. Chondritis and perichondritis are not infrequent; and, as a result of the chronic inflammation, stricture and stenosis, more or less complete, may occur from cicatricial contraction. It may also be the seat of gummata. The trachea and bronchi are subject to similar lesions, inducing stricture.

In the lungs the principal lesions are—(1) chronic interstitial or fibrous pneumonia; (2) more or less widely disseminated gummatous deposits, usually in the lower portions of these organs.

Digestive System—Mouth.—Superficial ulcers of the walls of the buccal cavity are not infrequent; deep, destructive ulcers are rare. This can not, however, be said with truth concerning the palate, where, as a result of gummatous deposits or general infiltration, the most rapid and irreparable destruction of tissue may occur. The curtain of the soft

palate is frequently destroyed, the bony septum between the mouth and nose is perforated, while in extreme cases the pillars of the fauces and the pharynx are involved. Other lesions of the *pharynx* do not differ from those of the buccal cavity.

Tongue.—Gummatous deposits may occur in any portion of this organ, causing local or general tumefaction. Whether superficial or deep, they tend to break down, giving rise to ulcers varying in size and depth. The other principal lesion of the tongue in the tertiary period is more or less widely diffused connective-tissue hyperplasia, giving rise to a varying degree of enlargement. As the new-formed tissue contracts it gives to the organ a lobulated appearance, the boundaries of the lobules being well-marked fissures in the line of the contracting bands.

Œsophagus.—Partial or complete occlusion of the œsophagus may occur from—(1) connective-tissue hyperplasia in its walls, or the contraction following ulcer (organic stricture); (2) the mechanical obstruction from gummatous deposits in the walls or in the immediate neighborhood of the œsophagus; (3) pressure from exostoses, aneurisms, enlarged glands, etc. Syphilitic ulcers of the stomach and alimentary canal have been observed, though rarely. Gummata form here, however, with a certain degree of frequency, and stricture of the pylorus, and of the intestinal canal above the rectum, is known to occur in a certain proportion of cases. The *rectum* is especially liable to become seriously involved in the late manifestations of syphilis. Here, as elsewhere, stricture may result from fibrillation and contraction of the inflammatory tissue with which the walls of this organ and the peri-rectal tissues may become infiltrated. Again, ulcers originating within the gut, or extending from a like inflammatory process about the anus and the external tissues, or the presence of gummatous material, may all induce more or less serious contraction of the lumen of the rectum. Of the solid abdominal viscera, the *liver* is most seriously affected. The pathological changes are—(1) connective-tissue hyperplasia or chronic interstitial hepatitis or syphilitic cirrhosis, which may be general or local; (2) gummata in any portion of the organ; (3) waxy degeneration from long-continued general sepsis.

The *spleen* may undergo similar changes. Slight enlargement may occur from the excess of white corpuscles (leucocythæmia), which is the rule in this disease.

The *pancreas* is rarely affected.

Genito-urinary System.—Amyloid degeneration of the kidneys occurs as a result of the long-continued sepsis of syphilis, as with other chronic forms of blood-poisoning. In like manner, under conditions favorable to connective-tissue hyperplasia, the fibrous stroma of this organ becomes thickened, with consequent atrophy of the excretory or glandular elements (chronic interstitial nephritis).

Gummata of the kidney is not as common as in other viscera.

Orchitis, although occurring while some of the secondary symptoms may be present, is essentially a late manifestation of this disease. It is important to recognize it, since several varieties of sarcocele require im-

mediate surgical interference. Syphilitic orchitis should be suspected in all cases of tumor of this organ in which there is a history of specific infection. In syphilis, the enlargement is apt to occur in both organs about the same time. The growth is smooth and spherical, and when lifted conveys the sense of unusual weight. It is not painful, excepting always the sense of dragging, which is at times annoying. Slight hydrocele not infrequently accompanies this form of orchitis.

The testicles are not exempted from gummatous deposits. In rare instances these break down, causing more or less destruction of the substance of these organs. The penis is occasionally the seat of syphilitic infiltration in the later stages of this affection.

The Eye.—Syphilitic iritis has been given as occurring in the second stage of this disease. It may also occur as a later manifestation. Inflammation of the sclera, choroid and ciliary bodies, lens and capsule, retina, and (though rarely) of the optic nerve, are of varying frequency in the tertiary period. Lesions of the muscles may be due to connective-tissue new formations between the fasciculi, resulting in granular degeneration of the muscle-substance and contraction of the new tissue. It may occur in the second as well as the third stage of this disease. These contractions, if not relieved, may result in ankylosis of the joint in immediate anatomical relation to the muscles involved. Gummata are not of frequent occurrence. They terminate by suppuration or by absorption. Inflammation in the tendons and their sheaths may also occur.

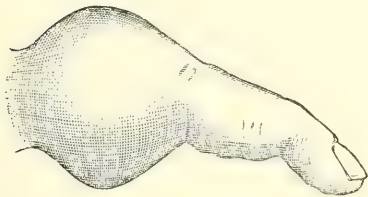

FIG. 653.—Syphilitic dactylitis.
(After Bergh and Bumstead.)

Fingers and Toes.—The fingers and toes, during the tertiary period of syphilis, in a certain proportion of cases become the seat of gummatous deposits, the skin and subcutaneous tissues may be infiltrated, or the bones and cartilages may be involved. When the infiltration is confined to the soft parts, the entire organ will appear swollen and purple or reddish in color. When the bone is the

seat of the deposit, it may be limited to a single phalanx (Fig. 653) or invade all the bones of the finger. The process terminates in ulcer, necrosis, or granular degeneration of the cells of the new tissue, and absorption.

Pathology of Syphilis.—The chief feature in the pathology of syphilis in all of its stages is the proliferation of an embryonic tissue, usually of a type so low that it is not capable of organization into a definite tissue. From the initial lesion and the primary lymphangitis and adenitis to the final lesions of the viscera, this cell-proliferation continues, and the different effects witnessed in different individuals, or in the same individual, in the various stages of the disease, depend chiefly upon the degree of impairment in the nutrition of the tissues. The cell-accumulation in and around the capillary loops of the cutaneous papillæ, which produce a macular or papular syphilide in one individual whose tissues are in a condition of perfect nutrition, will produce a squamous or vesic-

ular eruption in another, or a pustular syphilide in a third who has the unfortunate inheritance of a gouty, scrofulous, or tubercular dyscrasia. Or a papular lesion of the first stage, in which the process of nutrition in the tissues is normal, may be replaced by a rupia in the tertiary period when assimilation is less perfect.

If the initial lesion of syphilis is excised and examined with the microscope, the following conditions will be observed: The epidermis in the immediate vicinity of the ulcer is more or less completely destroyed. The membrane which covers the floor of the ulcer is composed of pus-cells, fragments of epidermal cells, cells of the Malpighian layer, and fragments of connective-tissue and other detritus. These elements vary in proportion as the process of necrobiosis is limited or extensive. In the deeper portions of the Malpighian layer, and in and around the papillæ where these layers are not wholly destroyed, and in the connective-tissue layer of the skin, there is a general infiltration with the embryonic cells of the syphilitic process.

The arterioles, veins, and capillaries are more or less completely occluded. The cell-proliferation is especially marked in the arterioles, the adventitia and intima are thickened, the thickening being more marked in the latter, while the lumen of the vessel is more or less encroached upon by the new-formed tissue. The venules undergo analogous changes. The walls of the lymph-channels are thickened, and many of these vessels are crowded with cells. The infiltration is, however, limited to the immediate borders of the ulcer, and the line between this and the uninvaded tissue is sharply defined. As the mass of cells gradually obstruct the vessels, the nutrition of the new tissue is interfered with, and it either undergoes granular metamorphosis or breaks down more rapidly as a slough. The absence of pain in the chancre is also explained by the gradual pressure upon the terminal nerves and the comparative dryness of the typical sore to the arterial occlusion.

The *lymphatics* immediately around the ulcer, and those leading from it to the nearest glands, are more or less filled with the new cells, and their walls appear thicker than normal.

The changes which occur in the glands in the earlier stages of syphilis consist in a hyperplasia of the connective-tissue cells of the stroma and thickening of the fibrous framework, together with an increase in the cell-elements of the gland-substance proper.

The *cutaneous* lesions of secondary syphilis result from the more or less complete obstruction of the capillary loops of the papillæ by the cells of this indifferent tissue. The walls of the capillaries undergo degeneration; the coloring-matter of the blood escapes, causing the peculiar staining of the syphilides. In the macular syphilide the abnormal cell-accumulation is less than in the papular eruption. The changes which occur in mucous patches differ very slightly from those described in the cutaneous lesions. The epidermis soon breaks down; the Malpighian layer and papillæ are infiltrated with the cell-elements; while the capillaries, arterioles, and lymphatic vessels undergo changes almost identical with those described in the initial lesion.

In the later or tertiary lesions of the skin in syphilis, the infiltration is deeper. Cutaneous gummata consist of aggregations of the cell-elements heretofore described, which are crowded into the subcutaneous areolar tissue, into the connective tissue of the true skin, in the walls of and just outside the vessels, while the endothelia of these vessels undergo proliferation and aid in their occlusion. Ulceration ensues from the rapid arrest of nutrition, and the process of necrobiosis is aided by the depressed condition of the tissues which usually exists in the tertiary stage of syphilis. The tertiary lesions of the mucous surfaces are analogous to those of the integument.

The pathology of visceral syphilis presents two distinct morbid processes: (1) the hyperplasia of the connective-tissue stroma of the organs (cirrhosis); and (2) the aggregation of the syphilitic embryonic cells (gumma). The character of these changes in the different organs has been given.

Diagnosis.—In a typical case of acquired syphilis a diagnosis may be made upon the following symptoms: 1, an ulcer in appearance and behavior like that described as belonging to the initial lesion of this disease, the sore occurring not less than ten days, and usually about the twentieth day, after an exposure; 2, induration and enlargement of the nearest lymphatic glands occurring in from eight to fourteen days after the appearance of the ulcer; 3, after from two to four weeks of seeming arrest of the infection, the development of headache, pain in the back, slight febrile movement, with an eruption (sixth to seventh week after the appearance of the sore) over all or a portion of the body, accompanied with an unusual sense of dryness or soreness of the mouth, pharynx, or fauces; 4, following or occurring with these symptoms, general adenitis.

In the majority of cases, excluding even those in which the sore is concealed, as in the urethra, etc., little value can be placed upon the appearance of the ulcer at the point of infection. The classical "initial lesion" of syphilis, with its well-defined margin of induration, feeling like a "split pea" or piece of cartilage when grasped between the thumb and finger; the absence of pain and peripheral inflammation; the peculiar "scooped-out" concavity of the sore, the surface of which is covered with a scanty, serous transudation, is so frequently absent in cases in which the later and unmistakable signs of this disease are developed, that it alone can not be relied upon in arriving at a diagnosis. As stated heretofore, the syphilitic virus may be lodged in and absorbed from a phagedenic ulcer in which not a single feature of the specific sore is present. The same is true of the herpetic ulcer, or that resulting from traumatism or the inoculation of any form of virus. All of these ulcers are grouped under the heading of "mixed sores."

Induration of the glands is more reliable in a diagnostic sense. When the typical initial lesion is present, the ensuing adenitis is also typical. In the inguinal region one gland of the group after another is enlarged and becomes indurated. The process is slow and deliberate. There is no periadenitis, the glands do not adhere to each other and the interven-

ing tissues, nor to the integument. Each body may be distinctly made out by palpation and moved beneath the skin independently. There is no tenderness, and the gland is leathery to the touch. Even when the sore is *mixed*, if the phagedenic or inflammatory process is not severe, the adenitis is more apt to be specific than inflammatory, and will possess the features of syphilitic bubo in a sufficient degree to admit of recognition. When the specific infection is complicated with a typical phagedenic ulcer or gonorrhœa, the resulting bubo does not possess a single appreciable feature of syphilitic adenitis.

The eruption of syphilis is, of all the symptoms of this disease, the most reliable. When the sore is mixed, and the character of the adenitis doubtful, the early cutaneous and mucous lesions are, in the vast majority of cases, appreciable and unmistakable. Headache, rise in temperature, pains in the back, etc., are confirmatory symptoms, but independently of no value. The same may be said of dryness or soreness of the mouth, pharynx, and fauces. Lastly, general adenitis, which occurs in a varying degree in all cases of syphilis in which mercurialization has not been effected at a very early date, is a strong confirmatory symptom, and of great value in diagnosis if all the other lesions have escaped observation. The greatest importance is attached to induration of the epitrochlear, and to the occipital and post-mastoid glands. The former can scarcely be recognized in their normal state. In general adenitis a single body, feeling like a small bean in shape, may be recognized at the inner aspect of the arm just above the elbow, where it lies superficial, and internal to the basilic vein. When any inflammatory process exists in the member beyond the elbow, the enlarged gland possesses no specific diagnostic value. In like manner lesions of the scalp, face, or mouth may cause enlargement of the occipital or mastoid lymphatic glands.

A diagnosis of syphilis in the tertiary period must depend upon a careful study of the history of the case and the presence of one or more of the lesions which belong to this stage, and which have been fully described.

Prognosis.—A favorable prognosis in syphilis will depend upon—1, the physical condition of the individual affected at the time of inoculation; 2, the recognition of the disease within the first two or three months after the appearance of the ulcer; 3, the faithful and energetic co-operation of the physician and patient in carrying out the measures to be given.

That syphilis is a curable disease there can be no doubt. Under favorable conditions the symptoms disappear, leaving little or no trace of the infection. In common with all diseases, its severe or fatal results are seen in patients with an inherited or acquired dyscrasia, and in those whose nutrition is seriously impaired. Even in the worst class of cases the prognosis is not wholly unfavorable if proper treatment is instituted and maintained.

The recognition of the disease and the institution of treatment at the time of, or immediately after, the appearance of the eruption, is impor-

tant in securing a favorable result ; for, if this is done, the violence of the infection may be modified and the deeper lesions rendered less severe.

Treatment.—The treatment of syphilis is divided into—1, measures which tend to destroy the potency of the virus and aid in absorption of the inflammatory products of this disease ; and, 2, those which tend to improve the nutrition of the tissues. Both are essential to the successful management of this formidable affection.

To the former belong the preparations of mercury and iodine in combination with potassium ; to the latter tonics, the careful regulation of the habits of living, nutritious diet, and healthful and moderate exercise.

Nothing is more satisfactorily demonstrated in scientific medicine than the power of mercury to neutralize and destroy the virus of syphilis. Its administration should usually begin with the positive recognition of the disease at the appearance of the eruption (usually about the sixth or ninth week). It is always advisable to wait until the diagnosis is assured, rather than to begin treatment with the recognition of the sore or bubo. It has been stated that these symptoms are often not reliable, while the early cutaneous and mucous lesions are practically pathognomonic. The greatest objection to the early institution of treatment is the doubt which may be left in the mind of both physician and patient of the correctness of the diagnosis by the early disappearance of the initial lesion and the local adenitis. The individual affected, as well as the practitioner, is too often lulled into a sense of security by the rapid disappearance of the early symptoms ; treatment is either discontinued or carelessly carried out until, after several weeks or months, it is discovered that the disease has taken a firm hold upon the tissues.

Commencing with this date, the management of a case of syphilis should be carried on for a period of two years.

It is of the utmost importance that the person affected should be impressed with the gravity of the situation and the certainty of disaster if the rules laid down by the medical adviser are not strictly obeyed. With the proviso of obedience, the prognosis should be as encouraging as possible. Responsibility for the result of treatment in this disease should not be assumed unless the patient consents to keep himself under observation for the period above given. All excesses should be prohibited. The use of tobacco should not be permitted. Alcohol in any shape is scarcely allowable. In certain cases, where digestion and assimilation are impaired, a small quantity of whisky, claret, or sherry may be taken with the heaviest daily meal. Sexual indulgence, if from no other than humanitarian motives, should cease for at least a year from the appearance of the initial lesion. The child of parents, either of whom is within the first year of syphilitic inoculation, becomes the victim of a dyscrasia which, if not fatal to life, is fatal to the perfect usefulness of its possessor.

In addition to the danger of direct inoculation during the prevalence of the chancre, is that of infection to the mother from the fœtus *in utero* or the child in the act of parturition. A patient under treatment for syphilis should retire early and at a regular hour, avoid excessive use

of the eyes, especially at night, sudden changes in temperature, and all articles of diet which are not readily digestible.

Of the preparations of mercury, preference should be given to the protoiodide. It is conveniently administered in pills of one-quarter grain each. To begin with, one of these pills should be given three times a day one hour after eating. The indications for a diminution in the quantity are pain of a cramp-like nature in the stomach or bowels, with or without diarrhœa, and the occurrence of salivation. If diarrhœa results, it will be advisable to administer about one-quarter grain of opium with each pill of protoiodide, or to reduce the daily number of the pills. Under such conditions, inunctions with mercurial ointment are of great value. Salivation may be guarded against by careful observation of the gums. At the earliest indications of tenderness felt when the teeth are firmly pressed together, or when direct pressure is made upon the alveolus, the dose should be diminished, or, if necessary, discontinued for a few days.

It will usually suffice to administer one-quarter grain three times a day for the first month, and at the expiration of this time to increase the daily quantity to gr. j. It will rarely be necessary to give more than this quantity, although in some cases the full beneficial effects of the remedy may not be realized until a larger daily dose is given. The mercury should be continued without interruption—excepting for the reasons just given—for the first six months after commencing the treatment. At the expiration of this period it is a good plan to discontinue the protoiodide for two weeks, and then administer the iodide of potassium in doses of grs. x-xx three times a day for one month. This should in time be stopped, and the pills resorted to for a period of two months, and so on, alternating these two remedies to the end of the first year of treatment. For the first six months of the second year the alternation should be equal—i. e., one month of the potassium salt, and the next the protoiodide. For the last six months of treatment a greater proportion of the iodide of potassium should be given.

In addition to the foregoing it is of great importance that tonics should be administered from the commencement of the disease, and especially in delicate patients. In carrying out this part of the treatment much better results will be obtained in the alternate exhibition of several tonics rather than in the continued use of a single remedy. A preparation of iron, quinia, and strychnia on one day, given in the proper dose immediately after each meal; an emulsion of cod-liver oil with the hypophosphites of lime and soda, each gr. j to the tablespoonful on the next day; and tincture of the chloride of iron on the third day, will be found a convenient and useful method of rotation.

When protoiodide of mercury can not be obtained, the biniodide, in doses of gr. $\frac{1}{16}$ to $\frac{1}{12}$, or chloride of mercury (corrosive sublimate), gr. $\frac{1}{20}$ — $\frac{1}{16}$ — $\frac{1}{12}$, may be substituted.

If, for any reasons, mercurial inunctions become necessary, proceed as follows: Take about a teaspoonful of mercurial ointment and rub it well into the skin of the groin and under the arms. Or spread the oint-

ment on lint and apply it to these parts, holding it in place by lightly fitting clothes or bandages. It should be used only at night, and removed upon rising by washing with warm water and soap.

The hypodermic injection of corrosive sublimate in the treatment of syphilis is objectionable on account of the annoyance produced by the insertion of the solution beneath the integument. It is an unnecessary practice, for the best results can be obtained from the internal administration of the protoiodide.

In the treatment of the tertiary lesions of syphilis, practically the same rule of practice should be adopted as just given for the second year following the appearance of the initial lesion. The employment of iodide of potassium in full doses hastens the absorption of the inflammatory products of this stage, while the protoiodide destroys the potency of the virus. Both remedies should be administered in doses as large as can be borne without interfering with the functions of the digestive organs or producing any serious constitutional disturbances.

Inherited Syphilis.—The fœtus may become syphilitic from a syphilitic father or mother. If pregnancy occurs within the first year, and especially in the first six months of the disease in the mother, the child becomes inoculated, either dying *in utero*, or, if carried to term, usually perishes within a few weeks after its birth. If, however, the disease is recognized and proper treatment instituted, a more favorable prognosis may be made.

In the second year after infection, if properly treated, a mother may bear a non-syphilitic child, although the chances are against complete immunity. During the third and each succeeding year, under judicious management, the prognosis is still more favorable.

A female patient should be advised of the great danger of pregnancy within the two years immediately following inoculation. When she has been under constant and proper treatment for this length of time, and has been perfectly free from symptoms for one year, the gravity of the danger is diminished. If she has not been treated, she should under no circumstances be made liable to pregnancy. In case such a woman should become pregnant, she should be treated carefully for syphilis, and in this way the infection of the child may be modified, if not prevented.

The virus of syphilis may be conveyed by the spermatic elements, and the embryo thus become inoculated.* The prognosis is more favorable in proportion to the length of time which has elapsed after the initial lesion, and to the thoroughness of the treatment instituted. A syphilitic man should not beget a child within two years after the initial sore, nor at any later period unless thorough treatment has been instituted and one year has elapsed since the disappearance of all symptoms of the disease.

* As heretofore stated, a non-syphilitic mother may be inoculated from a syphilitic child in the act of parturition. That the mother is also subjected to the influence of this virus from carrying the offspring of a syphilitic father is proved by *Colles's law*, which is, that a previously healthy mother of such a child can nurse it without danger of chancre of the nipple and syphilitic infection, while a non-syphilitic nurse will become inoculated.

Symptoms.—The symptoms of specific infection in the child manifest themselves usually within the first eight or twelve weeks after birth. Occasionally the disease is latent, and the symptoms do not appear until a variable period has elapsed. Even puberty may be reached before it is evident. Excepting the chancre, the local lymphangitis and adenitis, the evolution of the symptoms of inherited syphilis is not unlike those of the acquired form. The lesions are cutaneous, mucous, and visceral.

The macular or papular syphilide occurs in most cases, and may be distributed over the general surface or confined to certain limits. It is usually first seen upon the abdomen, and from this starting-point it becomes more or less widely distributed. At the muco-cutaneous margins, and in the folds of the skin where irritation is greater and moisture exists, condylomata are not infrequent, and are often persistent. Vascular, pustular, and tubercular syphilides occur in a certain proportion of cases. The tubercular form is rare. The pustular form (syphilitic pemphigus) indicates a low order of tissue vitality, and justifies an unfavorable prognosis.

Lesions of the mucous surfaces occur either before or with the cutaneous lesions. Papules and excoriations (mucous patches) are found in the buccal cavity, on the tongue, fauces, and pharynx. Fissures of the lips are not uncommon, and especially in the angles of the mouth. The infection of the mucous membrane of the nose and air-passages leads to the distressing coryza and cough so often noticed in syphilitic infants. Gummata of the skin and of all organs occur in the same manner and with the same pathological significance as in the acquired form.

Treatment.—The preparations of mercury antagonize the virus in this as in the acquired form of syphilis. The careful mercurialization of the mother during pregnancy is important in preventing the development of the disease in its severer forms. Inunction with the ointment of mercury should be first faithfully tried in the treatment of syphilis in the newly-born. One drachm of mercury to one ounce of lard is the proportion recommended by Brodie. This is spread upon a soft flannel belt and worn continuously around the patient's waist. The ointment should be renewed as needed. If the beneficial effects of the mercury are not secured by this method, the internal administration may be resorted to, but in no case until after a thorough trial of the inunctions. The biniodide of mercury, in doses of $\frac{1}{200}$ grain, in combination with one-quarter grain of the iodide of potassium, is advisable to begin with. The dose may be carefully increased if necessary. The nourishment of the child should be most carefully attended to, and it should have the benefit of pure air and comfortable surroundings.

Scrotum.—*Wounds* of the scrotum should be treated as similar lesions elsewhere. On account of the great vascularity of the tissues, repair is usually rapid. The contractility of the dartos and cremaster muscles will prevent early union unless the stitches are closely applied. If the testicle is protruded, it should be disinfected with 1-to-10000 sublimate, returned to its normal position, and the cavity of the tunica vaginalis also washed out with the sublimate solution. In closing the wound

with catgut sutures, the edges of the opening in the tunica should be included. A small bone or catgut drain should be inserted into the cavity and emerge at the lower angle of the incision.

Contusions should be treated by rest in the horizontal posture, cold applications and mechanical support beneath the posterior aspect of the scrotum.

Edema of the scrotum occurs with general anasarca and with ascites. The integument is tense, pale, and doughy; pits upon pressure, and, after puncture with the hypodermic needle, a clear, watery serum escapes. Besides the indications for constitutional treatment directed to the disease proper, puncture with the lancet in several points will temporarily relieve the tension and danger of gangrene.

Eczema and other cutaneous lesions of the scrotum do not demand especial consideration. The same general principles of treatment apply with equal force to all the cutaneous surface. The prognosis is unfavorable on account of the irritation to which this organ is subjected from friction with the clothing and thighs, and especially owing to the peristaltic movements of the dartos and cremaster muscle.

Cysts, due chiefly to the retention of sebum, are occasionally seen in the scrotum. They are usually situated near the raphé, or laterally and posteriorly upon the base of the scrotum. When large enough to cause inconvenience, incision and extirpation of the sac are demanded.

Erysipelas, although rare in this portion of the body, is met with, and is often obstinate under treatment. *Gangrene* is one of the chief dangers, and must be guarded against by free incision as soon as the tension is great. *Phlegmon* of the scrotum should be treated by warm applications, poultices, etc., and by early incisions to relieve tension and give escape to septic matter. Free drainage and sublimate irrigation are indicated.

Elephantiasis scroti, comparatively of rare occurrence in the temperate and colder zones, is frequently met with near the equator; and in some of the West Indies and the islands of the South Pacific Ocean it occurs with great frequency.

The pathology of this form of connective-tissue hyperplasia has been given. The cause is undoubtedly one of prolonged irritation. The only treatment is extirpation with the knife. No fixed rule of operating can be laid down. The penis is at times buried in the neoplasm, and should be carefully dissected out. The incisions should be made so as to give a cutaneous flap in front and behind sufficiently large to contain the testes and cord without pressure after the connective-tissue new formation has been dissected out. When the penis is included in the new growth, the integument should be saved, to cover this organ. If this can not be done, flaps may be turned from the thighs and abdomen.

The hæmorrhage in this procedure may be controlled by working between fixation-forceps, or by the adjustment of an elastic tourniquet around the scrotum near its attachment to the perinæum.

Angioma of the scrotum is rare, and demands treatment similar to that advised in the chapter on these vascular formations.

Epithelioma is more frequently seen than either of the foregoing neoplasms, and calls for immediate excision.

Fistula, or *sinuses* of the scrotum, may be caused by abscess of the tunica vaginalis testis, or by any lesion of the testicle. Abscess of the perinæum or urinary fistula may also cause fistula of the scrotum. Stony concretions are occasionally met with in fistulæ of the scrotum through which the urine makes its escape.

The treatment should be directed to a relief of the cause of the fistulous tracks. If this is accomplished, the sinuses should be laid open and allowed to close by granulation.

Hæmatoma.—Extravasation of blood may occur either in the tunica funiculi, in the tunica vaginalis testis, or in both. In the former it may be *diffuse* or *circumscribed*. It is usually diffuse, the extravasation extending from the abdominal opening to the epididymis. When only a portion of the sheath is involved, the hæmatoma is generally confined to the upper segment.

The chief causes of extravasation are rupture of one or more vessels by direct traumatism, or by over-distention from prolonged strain, which retards the return circulation, causing rupture of a vein.

Hæmatoma of the tunica vaginalis testis is rare, except as a complication of chronic *periorchitis serosa* (hydrocele) or direct violence.

The diagnosis of hæmatoma in either of these positions depends upon its sudden development, the tendency to enlarge progressively, and pain from the sudden distention. The tumor is not translucent. The exact nature may be determined by aspiration.

Serous effusion (hydrocele) into the sheath of the cord or testis progresses slowly and painlessly. The tumor is translucent. Exploration with the hypodermic needle and syringe is a safe, painless, and positive means of diagnosis.

Hernia may be eliminated by a consideration of the history of the case and the absence of impulse in the tumor upon coughing.

Treatment.—Hæmatocele may be treated by the expectant method, or by surgical interference.

Simple and limited extravasation requires rest in the dorsal decubitus, and the ice-bag locally. After the hæmorrhage is arrested, absorption may be expedited by judicious and well-applied pressure by strapping. When the extravasation is extensive, an incision should be made under strict antisepsis, the clot turned out, the bleeding-point ligated, drainage secured, and the wound closed. Death has followed in some instances where operative procedure has been too long delayed.

Periorchitis and Perispermatitis.—Inflammation of the serous investments of the spermatic cord and testicle may be circumscribed or diffuse. An inflammation commencing from a lesion of the external or scrotal layer usually involves the entire sac, as does the similar process beginning on the visceral reflection of the tunica.

Perispermatitis may be acute or chronic. A type of the acute inflammation is seen in severe forms of epididymitis, or as the result of direct violence. The transudation of serum may be limited, and, as in

pleurisy, adhesions may occur with obliteration of the sac, or suppuration may ensue; or, passing into a subacute and chronic stage, a condition of true hydrocele of the cord ensues (*perispermatitis chronica serosa*).

Effusion into the sheath of the cord may communicate with the cavity of the tunica vaginalis testis (Fig. 654), or with the peritoneal cavity

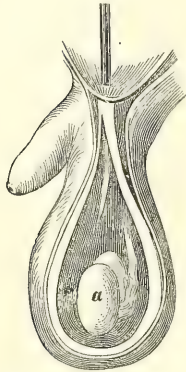


FIG. 654.—Hydrocele of the cord communicating with the tunica vaginalis testis. The instrument is passed through the membrane which separates the fluid from the peritoneum. *a*, Testis. (After Linhart.)

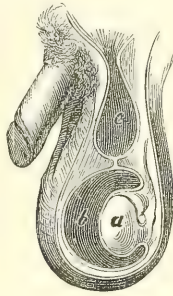


FIG. 655.—*c*, Hydrocele of the cord communicating with the peritoneal cavity. *a*, Testis. (After Linhart.)

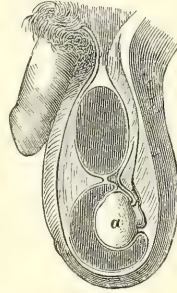


FIG. 656.—Encysted hydrocele of the cord.

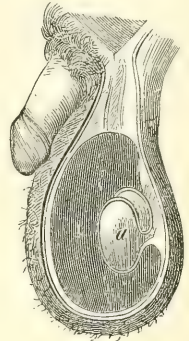


FIG. 657.—Hydrocele of the tunica vaginalis testis. (After Linhart.)

(congenital hydrocele) (Fig. 655), but these conditions are rare. It is usually confined to the *tunica funiculi* (Fig. 656).

The *diagnosis* of this form of hydrocele rests upon the recognition of a fluctuating tumor in the line of the cord, and the exclusion of hæmatocele, varicocele, and hernia.

The symptoms of hæmatocele have just been given. The peculiar feel of a varicocele, so well compared to the sensation felt in grasping a mass of earth-worms between the fingers, can scarcely be mistaken. If the recumbent posture is assumed, the varicose veins are emptied and the tumor disappears. This can not occur in cyst of the cord. A hernial tumor gives the characteristic impulse upon coughing; a cyst does not. A reducible hernia will disappear in the recumbent posture, and if, when reduced, the finger is pressed into the internal ring, it will not recur, while, despite this precaution, a varicocele will reappear. Exploration with a hypodermic needle will disclose the character of the contents. The treatment of hydrocele of the spermatic cord is practically the same as that for hydrocele of the tunica vaginalis testis.

Periorchitis may also be acute or chronic. In acute inflammation the quantity of serous transudation may be large or small. When the inflammatory process is acute, and the transudation of serum so limited that the opposing surfaces of the two walls are not kept apart, adhesions may occur, with partial or complete obliteration of the sac.

The causes include all lesions of the scrotum, the testicle, and epididymis, the process naturally extending to the delicate lining membrane.

Chronic epididymitis and orchitis should rank as first in the ætiology of hydrocele. The interference of the return circulation here will produce the transudation of fluid in the same way as ascites occurs in cirrhosis of the liver. In like manner varicosities in the veins of the spermatic plexus may induce hydrocele. The pathological changes consist in a general thickening of the visceral and parietal layers of the tunica, due to the development of connective-tissue elements in which new vessels are formed.

Not infrequently little pearl-like bodies are seen attached to the visceral surface of the thickened tunica, or they may be found floating free in the fluid of the sac. They are made up of connective-tissue and flattened epithelial elements. Occasionally they undergo the calcareous metamorphosis. The sac of a hydrocele of the tunica vaginalis testis is almost always unilocular (Fig. 658), but in rare instances it is bilocular, with a narrow opening of communication between the sacs (Fig. 659). The dividing septum is made up of the products of inflammation.

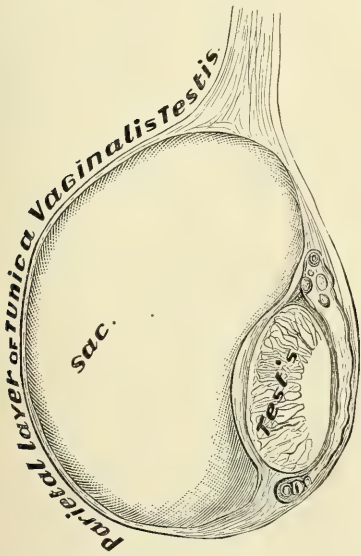


FIG. 658.—Usual form of hydrocele.
(After Kocher.)

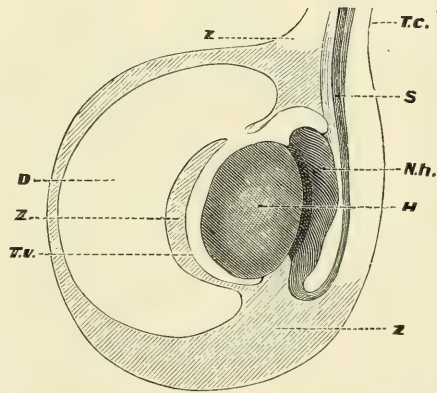


FIG. 659.—Bilocular hydrocele. *Tc.*, Parietal layer of tunica. *S.*, Spermatic cord. *Nh.*, Epididymis. *H.*, Testis. *D.*, Cavity of diverticulum. *Tv.*, Cavity of the tunica vaginalis proprius. *Zz.*, Inflammatory new formation between the visceral and parietal layers. (After Kocher.)

The fluid of hydrocele is amber in color, or, if blood has been extravasated and mixed with it, it may be brownish-black or red. Under the microscope it is seen to contain compound granular corpuscles, leucocytes, swollen endothelia, and at times crystals of cholesterin and red-blood disks.

Symptoms.—Hydrocele of the tunica vaginalis testis is usually single—at times double. In shape the tumor is usually pyriform or oval, with the largest diameter of the swelling below. It may, however, assume a conical shape, with the apex downward, as shown in Fig. 660. The history is generally that of a slow and painless swelling, first noticed in the lower portion of the scrotum, and gradually extending upward. In size it may vary from a mass having a long diameter of an inch or two,

to as much as ten or twelve inches. In recent cases the walls are thin, fluctuation is easily made out, and the testicle may be recognized in the lower posterior portion of the swelling. In old cases the walls may measure half an inch or more in thickness, and are so tense and inelastic that to the touch the tumor seems wholly solid. The differentia-

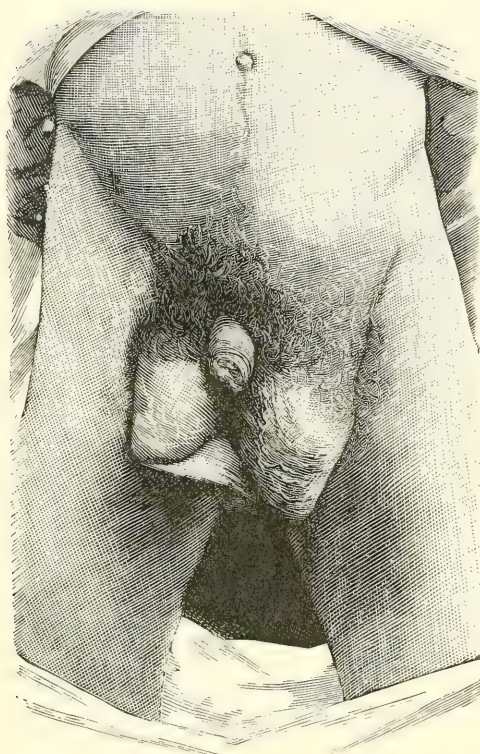

FIG. 660.—Double hydrocele of the tunica vaginalis testis. (From a patient operated upon at Mount Sinai Hospital.)

tion includes hydrocele of the cord, encysted hydrocele of the testis, hernia, varicocele, and various neoplasms or swellings of the testis and epididymis.

Hydrocele of the cord is oblong or spherical in shape, usually of small size, and gives a history of a swelling commencing above the testicle, which organ can be made out by palpation below the tumor. Encysted hydrocele of the testicle can only definitely be made out by puncture with the aspirator-needle and examination of the contents with the microscope. The presence of the spermatozoa will determine the encysted character of the tumor. In hernia the swelling begins at the inguinal ring, and travels progressively downward. If reducible, it can be made to disappear by assuming the dorsal decubitus, while a hydrocele would be unaffected by this manoeuvre. Percussion upon an in-

testinal hernia will yield resonance, while that upon the tumor of hydrocele gives dullness. Omental hernia is doughy to the feel, while hydrocele is tense and resisting. Varicocele can be eliminated by the peculiar impression conveyed to the fingers when the worm-like veins are grasped. The solid character of neoplasms of the testis or epididymis can be recognized by palpation. Of most importance, however, is the employment of the exploring aspirator, which safely and easily demonstrates the liquid character of the contents of hydrocele.

Treatment.—The cure of hydrocele is effected in almost all cases by operative interference. The transudation of serum into the cavity of the tunica vaginalis testis, symptomatic of specific disease, or any acute local affection, may disappear by absorption under proper medical treatment, or after the disappearance of the acute trouble. These cases are, however, exceptional; and, if absorption does not occur within the first few weeks of the history of the affection, operation is demanded.

The operative procedures are two in number—1, by *injection*, and 2, by *incision*. The former method should be preferred in all cases of recent formation, in which there is not great thickening of the walls, and in which the sac is not very large. It may be safe to include in this category all cases in which the long diameter of the tumor is not more than five inches, and in which the depth of tissue between the integument of the scrotum and the cavity of the sac is not more than half an inch. If this procedure fails, it should be repeated once or twice before the more formidable procedure known as Volkmann's operation is undertaken.

First Method—Levis's Operation.—Shave the tumor on its anterior aspect, and cleanse the integument thoroughly. Inject from ℥ x-xv of a 4-per-cent cocaine solution in such a way that local anæsthesia will be obtained through the depth of the wall of the sac throughout an area of half an inch in diameter. Twenty minims of pure carbolic acid should now be placed in the syringe, and a long needle attached. Place the patient upon the back, separate the thighs, have a pus-basin convenient, support the tumor with the left hand, making the parts tense by pressure; take a trocar-canula in the right hand, firmly seized between the thumb and finger one inch from the point (so that it may not possibly be thrust in farther than this limit); remember that the testicle is behind and below, and with a quick and accurate thrust carry the instrument through the anæsthetized zone into the cavity of the sac. The point of entrance should be about one third of the distance from the lower portion along the anterior aspect to the upper, and the direction of the shaft of the trocar should be upward and somewhat backward. Upon removal of the stylet the liquid rapidly escapes through the canula, any remnant being forced out by compression. Care must be taken not to shift the canula from its first position. When the fluid is emptied, carry the hypodermic needle into the canula, and force the carbolic acid into the sac; withdraw the needle, and then the canula, and knead the scrotum and sac so as to distribute the acid over the entire surface. This operation is almost without pain. In some instances a slight sense of faintness is experienced just as the acid is injected. The patient should be kept quiet on the day of the operation, but with proper suspension of the scrotum he may be allowed to move about after twenty-four hours. On the day following, and for about a week afterward, the tumor swells up as if it were refilling, and is solid or doughy to the feel. After this it begins to decrease until the sac is obliterated and a permanent cure is effected. A scrotal wall and the investing serous membrane of the testicle which is once thickened becomes somewhat thinner after the cure of the hydrocele, but never entirely resumes its natural thickness.

Second Method—Volkmann's Operation.—Shave the scrotum and pubes, narcotize the patient with ether, and over the anterior middle line of the side affected make an incision varying in length with the size of the tumor and the thickness of the wall. Usually an incision from two to four inches in length will suffice. Cut directly down until the

sac is reached, and incise this to about the same extent as for the wound in the integument, allow the fluid to escape, and, with a good-sized cat-gut continuous suture, stitch the cut edge of the parietal layer of the tunica vaginalis testis to the edge of the wound in the skin, making an opening not unlike a button-hole. Irrigate the sac with 1-to-3000 sublimate solution, and insert a rubber drainage-tube into the upper and lower portions of the cavity, and apply a sublimate-gauze dressing.

In all antiseptic dressings about the penis it is essential to isolate this organ so that the urine or the usual unclean condition of this organ may not infect the wound. To do this after the drainage is secured and the first gauze is placed around the tubes along the edges of the button-hole, make a hole in all the layers of sublimate gauze and the sheet of protective large enough for the penis to pass through without constriction. Lastly, tuck the dressing well up under the scrotum close to the perinæum, to keep the gases and fecal discharges from infecting the wound. This operation will cure any case of hydrocele which will not yield to the more conservative procedure of Levis. It can only be dangerous by neglect of careful drainage. In very large sacs a counter-opening should be made through the lower portion. Such wounds rarely require more than one or two changes in the dressings, and only then, as in all surgical wounds, when the discharge soils the dressings, escapes beyond the area of antiseptis, and becomes offensive by decomposition, or when the rise in temperature indicates the presence of septic absorption.

Bone-drains may be used in the smaller tumors, but rubber gives a better guarantee of perfect drainage.

Suppurating periorchitis, or pus in the cavity of the tunica vaginalis, may be treated by two methods: If the temperature is high, the sac painful, and the scrotum swollen, the indications are for free incision, irrigation, and drainage. Under less threatening conditions, the aspirator may be employed, the sac emptied and repeatedly injected and washed out with 1-to-5000 sublimate solution, and compression applied afterward. In this way obliteration of the sac may be achieved, as in the treatment of cold abscesses.

Varicocele.—Varicosities of the veins of the spermatic plexus are not uncommon. Varicocele is chiefly caused by gravity and the mechanical interference with the return of blood through the spermatic veins. It occurs with greater frequency on the left side, where the vessels are pressed upon by the sigmoid flexure of the colon with its almost constant weight of fecal matter. In addition to this, the greater length of the left spermatic vein, which enters the renal vein at a right angle to its axis, and is poorly protected by valves, are causes which serve to produce varicosities upon this side more frequently than in the right plexus. Any occupation which necessitates the erect posture is apt to add to the susceptibility of this disease. Hereditary tendencies must be considered in its aetiology, for frequently members of a family through several generations will be affected.

The earlier *symptoms* are a feeling of heaviness or dragging down on

the side affected, with the appearance of a small swelling in the line of the cord. Pain is variable, and is sometimes referred to the cord or to the inguinal region or down the leg. The testicle hangs lower than natural, and along the cord can be felt a network of turgid veins extending from the epididymis toward the external ring. To the touch they seem not unlike a knot of earth-worms. The swelling is apt to be largest at the lower extremity (Fig. 661).

The *diagnosis* is not difficult.

The swelling of inguinal *hernia* is spherical, and, when composed of intestine, it is resonant on percussion. If the hernia is reducible, and is returned into the cavity of the abdomen with the patient in the recumbent posture, and if the index-finger is carried into the internal ring and held there while the patient is made to stand erect, the veins will again refill and demonstrate the varicocele, while the hernia will be prevented from descending. Hæmatoma, or hydrocele of the cord, can be recognized by aspiration with the hypodermic syringe.

Treatment.—Very few cases of varicocele require operative interference. A well-adjusted suspensory apparatus constantly worn while in the erect posture will obviate the necessity for an operation in the vast majority of instances. This bag may be made to include and support only one half the scrotum and a single testicle, or the double elastic apparatus may be employed. When no palliative measures are effectual, operative interference is demanded. The procedures are two in number, namely, *subcutaneous ligature* (Keyes), or *incision and ligature by the open method, with or without ablation of the redundant scrotum*. Of these two operations the latter is preferable. It is an open operation, radical, and invariably successful when properly done.

First Method—Keyes's Operation.—Shave the scrotum and pubes, and thoroughly wash these surfaces with ether and sublimate solution. The patient is made to stand erect, with the legs separated, in order to distend the veins. In cold weather it may be necessary to have him sit in a tub of hot water to induce full relaxation. By the injection of cocaine, local anæsthesia should be obtained in the parts where the ligature is to be inserted. From π x-xx of a 4-per-cent solution will suffice.

The ligature should be of Chinese twisted silk, not too large, but capable of bearing all the strain which will ordinarily be brought against

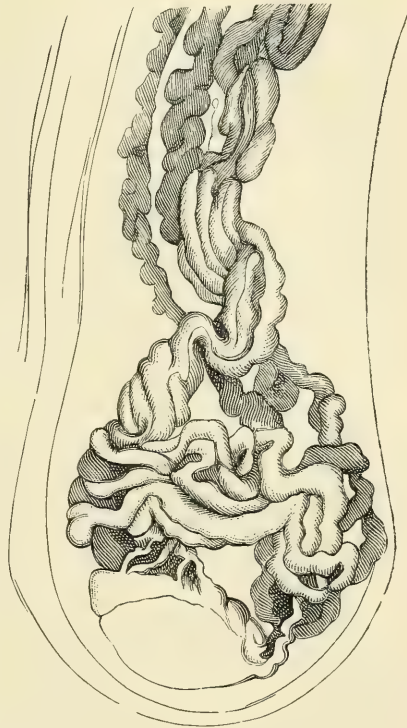

FIG. 661.—Varicosities of the spermatic plexus of veins, with atrophy of the testicle. (After Kocher.)

it. This should be thoroughly soaked in 1-to-2000 sublimate solution for several hours before it is to be used. For passing the ligature around the mass of veins, Keyes's needle (Fig. 662) should be preferred. It is better, as will be seen, to have two of these instruments. If these can not be obtained, the long needle of Peaslee, or an ordinary darning-needle, may be substituted. With everything in readiness, proceed as



FIG. 662.—Keyes's varicocele-needle.

follows: The operator, by careful manipulation, finds the vas deferens as it is located in the posterior part of the cord near the level of the scrotal attachment to the perinæum, separates it from the mass of veins, and, by tightly pinching the scrotal walls between the thumb and finger of the left hand, holds this important duct behind and to the inner side of the veins.

The vas deferens may be recognized by its dense and leathery feel. It is, as a rule, smaller than the veins, but, while these may be effaced by pressure, the vas deferens is so thick that it can not be obliterated, but will jump from between the thumb and finger when tightly squeezed. Once eliminated and secured behind the veins, pressure should not be interrupted until the threaded needle is passed entirely through both walls of the scrotum from before backward between the vas deferens and the plexus of veins. If two needles are on hand, the one now passed through should be left in position, and the pressure with the thumb and finger of the left hand being no longer needed, this hand may be used to facilitate the second step in the operation. The second needle, without being threaded, should now be made to enter by the side of and in the same opening with the first, and as soon as the point is well within the dartos—but not deep enough to puncture the veins—it should be carefully worked between the veins and dartos, around the mass to the outer side, and made to emerge behind at the same opening with the other instrument. The thread is now disengaged from the first needle and carried through the eye of the second, which, upon being withdrawn, completes the circuit of the ligature around the mass. It should now be tied slowly and securely. The single knot is preferable, since the friction of the double knot is so great that the thread may break in the effort to draw it tight enough to constrict the veins (an accident which has twice happened to myself). The first needle should not be withdrawn until the ligature is secured, since, should the thread break, the second needle will alone have to be inserted. As the first loop of the knot is tightened, the mass within its grasp should be held by an assistant to prevent its slipping before the second loop is finished. When completed, the ends are cut close to the hole of entrance, and the walls of the scrotum separated when the knot and ends disappear inside the dartos. A light sublimate dressing is required. The patient should remain in bed one day, and keep quiet about the house for four or five more.

Little or no pain is experienced after the operation, and none in its performance, if a few minims of cocaine solution are injected near the point where the needles enter and emerge. The ligature becomes encapsuled and remains harmless. Inflammation and suppuration are scarcely possible where the antiseptic details are properly carried out. The tissues around and below the thread are indurated within a few hours, and remain so for a number of weeks, the coagulated blood undergoing gradual absorption. Catgut is not reliable as a ligature in this operation, on account of the danger of too rapid absorption. In one case I failed with this material, afterward effecting a cure with silk, which was employed at the suggestion of Prof. Keyes.

Second Method—Ligature through an Open Wound.—Anæsthetize the patient, shave the parts thoroughly, and expose the cord by an incision several inches in length made along its anterior lateral aspect from the external inguinal opening downward. Search for the vas deferens, which can be easily recognized, after the skin is turned aside, by its cartilaginous feel; have this held to one side, and, with an aneurism-needle armed with good-sized catgut ligatures, tie the veins separately in three or four different places, beginning at the external inguinal ring and ending at the epididymis. The wound should be closed with catgut, and a bone drain inserted.

In a majority of cases the scrotum will be so elongated that amputation of the redundant portion is necessitated after the veins are tied.

In performing this operation Henry's or King's clamp will be found of great service; which, if properly adjusted, allows the amputation

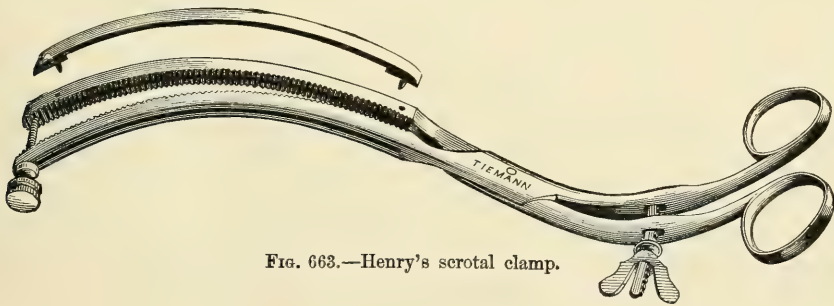


FIG. 663.—Henry's scrotal clamp.

to be made and the edges of the wound sewed with close silk sutures while the instrument is in position, thus avoiding all hæmorrhage and the necessity for a single ligature in the line of amputation. If this instrument can not be obtained, the testicles may be pushed up into the rings and the amputation effected by cutting across the scrotum below the fingers of an assistant which, by grasping the tissues properly, control all bleeding.

The Vesiculæ Seminales and Vas Deferens.—The seminal vesicles are occasionally wanting, from failure of development, or from atrophy as a result of inflammation. Wounds of these organs are rare. If incised or punctured, temporary fistula may result, with subsequent atro-

phy. *Inflammation* of the vesiculæ seminales occurs by extension from the urethra or from the epididymis and vas deferens, or with prostatitis or proctitis. Occlusion of the ejaculatory duct induces over-distention of these organs. Several cases of calculus of the duct have been recorded.

The *diagnosis* in dilatation, hypertrophy, or inflammation of these cysts depends upon careful rectal exploration.

The *vas deferens* is more or less involved in all inflammatory processes which occur in the epididymis. It is also subject to invasion by inflammation from the urethra and prostate. Tuberculosis of this vessel may follow tuberculosis of the testes and epididymis. Lesions of this organ require no especial consideration.

Epididymis.—Neoplasms of the sheath of the spermatic cord are rare. In his excellent monograph, Kocher mentions isolated cases of lipoma, fibroma, or myxo-fibroma and sarcoma.

Epididymitis results occasionally from direct violence, but is chiefly due to urethritis and the extension of the inflammatory process along the vas deferens. Metastatic or "sympathetic" inflammation of this organ is very rare. It may be acute or chronic. The inflammatory process may be confined to the epididymis or invade the testicle. Acute epididymitis always involves the tunica vaginalis (with which it is in contact), and very frequently the testicle. Specific urethritis stands first in order in the causation of epididymitis. The introduction of a sound or catheter, the lodgment of a calculus in the urethra or prostate, stricture, cystitis, and prostatitis may also cause this disease.

The *symptoms* of acute epididymitis are a sense of uneasiness or pain, varying in intensity in the organ affected, or in the cord or groin. It is increased by pressure, when the erect posture is assumed, or in walking.

In severe cases a chill or rigors occur, followed by a marked rise in temperature. Upon inspection there will be more or less induration along the posterior border of the testicle, with heat, redness, and tension. The testicle is more or less enlarged, and very frequently there is a serous transudation into the cavity of the tunica vaginalis testis.

The pathological changes consist chiefly of hyperæmia and infiltration of the connective-tissue framework with embryonic cells. The epithelial lining membrane is also thickened and injected.

The *diagnosis* depends upon the symptoms above given. The *prognosis* is usually favorable. One attack, however, predisposes to another. In some instances occlusion of the efferent apparatus results from contraction of the products of inflammation, and sterility follows. Spermatic fistula is the rule in these cases.

The *treatment* consists in the administration of saline laxatives in order to empty the alimentary canal. The patient should be placed upon his back, and the inflamed organ supported by either a three-cornered pillow between the thighs, or a towel pinned around both thighs just below the base of the scrotum. Upon this a small bladder filled with crushed ice may be placed, and the inflamed organ allowed to rest upon it. If cold is not grateful, warm cloths or a poultice may be sub-

stituted. The application of from three to six leeches will at times relieve the local congestion.

Usually rest in bed will alone suffice to effect a cure. In some instances operative interference is indicated. When the tension is great and the pain extreme, the happiest results will follow multiple puncture. Proceed as follows: Take a sharp, narrow knife and push it through a cork until from a quarter to half an inch of the point is exposed. Hold the organ in the left hand so as to expose the posterior aspect of the epididymis and make the skin fairly tense, and plunge the blade in up to the cork in from two to six or ten points along the most swollen and indurated portions of the tumor. A free escape of dark blood follows. The operation is very painful, but the relief is marked and immediate. A suspensory bandage should be worn during convalescence. The treatment of chronic epididymitis will be considered with that of orchitis.

The Testicle.—Wounds of this organ do not demand especial consideration. Hernia of the tubules not infrequently occurs from incision or puncture of the tunica albuginea. Reduction is practically impossible. The protruded portion should be tied off with a catgut ligature, the excess of substance beyond the thread cut off, and the organ returned to the normal position.

Inflammation of the testis (orchitis) may result from direct violence, from the extension of an epididymitis, or from metastasis. Orchitis is frequently met with as a symptom of "mumps," but the relation between these two processes is not understood.

The *symptoms* are enlargement of the organ, with pain usually intense. The swelling is slow on account of the great resistance offered by the tunica albuginea. The skin over the organ is tense and reddened, and at times œdematous, especially when an epididymitis precedes the inflammatory process in the testicle.

In severe cases gangrene may ensue, and the tunica vaginalis and scrotal walls may become involved. In mild cases the *pathological* changes are chiefly hyperæmia and the formation of a limited amount of embryonic tissue along the blood-vessels and in the connective-tissue septa of this organ. In the severer forms this process is greatly exaggerated, and as a result of the extensive hyperplasia the circulation is arrested, and death of the tubular structure ensues. Or, if gangrene does not occur, atrophy of the secretory apparatus follows as a result of contraction of the products of inflammation. In some instances the swelling subsides, leaving no marked changes in the organ.

The *prognosis* is in exact relation to the symptoms. Mild cases, especially in the forms occurring with urethral epididymitis, generally terminate in one or two weeks in recovery and restoration of the organ to its normal condition. In cases where the symptoms are severe from the start, the prognosis is grave unless early relief is afforded, and even then it is not always favorable.

Treatment.—Rest in the dorsal decubitus should be insisted upon in even the mildest cases, for not infrequently dangerous orchitis is provoked by neglect of this precaution.

The position of the testicle should be elevated, as in epididymitis. The local application of cold is grateful and advantageous in most cases. The organ is, however, so sensitive that no pressure is tolerated. This can be obviated by making a ring of cloths wrapped around a small hoop, leaving a lumen large enough to include the scrotum and penis. The ice-bag is laid upon this ring, which prevents any pressure upon the inflamed organ.

When the effusion is rapid, causing dangerous tension of the fibrous capsule, surgical interference is imperative.

The operation consists in seizing the organ with the left hand, so as to render it steady and the skin tense, puncturing the scrotum and parietal layer of the tunica vaginalis testis, and thus subcutaneously making a series of incisions through the tunica albuginea on its anterior and antero-lateral aspects. The incisions should be about half an inch in length, and are much preferable to simple puncture.

The danger of hernia testis does not contraindicate this procedure.

Chronic orchitis, not due to syphilis, is comparatively rare. When it occurs, it usually follows an acute inflammation. The pathological change consists in a thickening of the tunica albuginea and of the connective-tissue septa. Embryonic cells, collected in groups or nests, in various stages of development, are crowded along and around the blood-vessels and seminiferous tubules, as well as scattered about in the inter-tubular spaces. As the process continues, the tubules disappear under the pressure of the new inflammation-tissue. In a certain proportion of cases cysts form in the following manner: The peripheral cells of one or more foci of the embryonic tissue organize into connective tissue and aid in forming the investing capsule. The cells within this new capsule undergo granular metamorphosis, and later liquefaction, by absorption of fluid from the surrounding vessels. In other cases foci of suppuration (multiple abscess of the testicle) may remain from an acute inflammation and be present in chronic orchitis long after the acute symptoms have subsided. The contents of these foci may also undergo caseous degeneration.

The *symptoms* of chronic orchitis are those of progressive enlargement of this organ. In some instances pain is wanting, in others it is present, though less intense than in the acute form, while in a third category may be classed cases of chronic orchitis with intercurrent attacks of acute inflammation and the accompanying exacerbations of pain. The organ varies in size from two to four or five inches in its greatest diameter. Much annoyance is occasioned in the larger tumors by the dragging upon the cord.

The *diagnosis* is between hydrocele of the tunica vaginalis, inflammation of the walls of this cavity, with exudation and thickening and adhesion to the testicle, syphilitic orchitis, and tuberculosis testis. Hydrocele is easily excluded by fluctuation, translucency, and aspiration. In periorchitis with exudation and adhesions, differentiation will at times be difficult. The obliteration of the cavity of the tunica vaginalis renders the superficial tissues less freely movable upon the body of the testis.

In orchitis the surface of the enlargement is smooth, spherical, and of like consistence at all points; often in periorchitis ridges of new tissue can be made out; there are soft spots or depressions which can be recognized by careful palpation.

If syphilitic orchitis is suspected (even if the history of this disease is denied), it will be advisable to administer the protoiodide of mercury and the iodide of potassium for several weeks. The marked diminution of the tumor will be confirmatory of the suspicion of the syphilitic dyscrasia. The extraordinary weight of a syphilitic testicle should be borne in mind.

Tuberculosis testis is usually preceded by the deposit of tuberculous matter in the epididymis. Pain in this affection is insignificant and entirely disproportionate to the rapidity of the infiltration and enlargement. Moreover, orchitis and epididymitis may usually be traced to some direct and exciting cause which is absent in tubercular disease.

The indications in *treatment* are, first of all, to remove every cause of irritation, to keep up the tone of the system by judicious feeding and medication, and to support the heavy organ by suspension. When these measures fail to arrest the disease, or when the pain becomes so great that the patient's comfort is interfered with, or when the disintegration of the organ is threatened, castration may be entertained. Before carrying out such an extreme measure, the precaution should be taken to explore the organ through an incision in the scrotum, in order to determine its exact condition before removing it.

Tuberculosis of the Testicle and Epididymis.—True miliary tuberculosis of the testicle and epididymis is comparatively rare. Many cases which have been recorded as tuberculosis must, upon analysis, be classed with a non-tubercular inflammation, the embryonic tissue of which has undergone caseous degeneration.

Tubercular disease of the testicle alone is the exception. The epididymis is usually first invaded, and from this point the new tissue spreads into the testicle, and not infrequently along the vas deferens to the seminal vesicles, as well as to the tunica funiculi and tunica vaginalis testis.

While it may be slow in some instances, as a rule the invasion is rapid, occupying from two to eight weeks in a general infiltration of both organs. The *symptoms* are, upon the whole, obscure. One point of great diagnostic value is that the pain is entirely disproportionate to the rapidity and extent of the tumefaction. In simple orchitis and epididymitis, pain is extreme and pressure unbearable. In *tubercular* orchitis pain is, as a rule, slight, and may not be present at all. In a certain proportion of cases there will be sudden and recurring exacerbations of pain, indicating a circumscribed acute orchitis, the result of irritation from the presence of the cell-elements of the tubercular process. Ulceration and the formation of fistulæ occur in a certain proportion of cases.

In simple orchitis and epididymitis, the cord is not involved, while not infrequently in tuberculosis the deposit rapidly travels along the

vas deferens. Grasped between the fingers, the tubercular organ is felt to be hard, and its surface uneven and nodular.

The initial morbid change is the deposit around the seminiferous tubes of clusters or nests of lymphoid cells. Within the tubes the endothelia are thickened and undergoing granular or caseous metamorphosis. Later, the connective-tissue septa become infiltrated with the new cells. The process ends in compression and destruction more or less complete of the tubules. The centers of these clusters of cells farthest removed from the vascular network undergo granular or caseous metamorphosis, forming at times cyst-like caverns, or at other times abscesses and fistulæ.

Treatment.—The prognosis of tubercular disease of these organs is so grave that when an early diagnosis can be made out, extirpation of the diseased tissues should be considered. If only one side is involved, and the other organ is fully developed, there should be no hesitation in advising the operation of castration.

When the diagnosis is doubtful, it will be wise to keep the patient under constant observation, with especial regard to the advance of the disease along the cord, and when this is evident, and when there is no positive evidence of tubercular deposits elsewhere, extirpation is indicated in order to prevent invasion of the prostate and general dissemination. When both organs are involved, the question of complete castration is one of doubtful propriety.

Enchondroma of the testicle is not altogether infrequent. It occurs most often after injury. While it is prone to originate in the organ, it may spread from the epididymis to the testicle. The volume of the organ varies, at times reaching a large size. *Enchondroma testis*, as with almost all forms of neoplasm seated in this structure, is apt to undergo cystic degeneration.

The *diagnosis* must be based upon the hard, elastic feel peculiar to this form of tumor.

The treatment is either expectant or operative, as circumstances may demand. Castration is indicated when the disease is unilateral, and when the size of the tumor is such that the function of the opposite organ is threatened.

Adenoma testis occurs chiefly from the twentieth to the fortieth year of life. It has so far not been observed during childhood.

The development of the tumor is usually rapid, attaining a diameter of three or four inches or more. Only one organ is usually affected. Pain is not a prominent symptom in the earlier history of this neoplasm, but, after the growth attains a sufficient bulk, it causes more or less pain by pressure and weight. To the touch it is soft and compressible. The formation of cysts in various portions of the neoplasm is frequent (cysto-adenoma) (Fig. 664).

Under the microscope the epithelia of the seminiferous tubules are seen to be swollen, while their caliber is more or less completely occluded with the round cells of the new (adenoid) tissue.

The *prognosis* is not favorable, and the *diagnosis* difficult. Since the function of the organ is wholly impaired, and since the rapid develop-

ment of the tumor is of itself an indication of the gravity of the lesion, the matter of exact recognition of adenoma is not important. In all of these rapid and threatening neoplasms, especially when a single testicle or epididymis is involved, the safest course is in early and prompt excision.

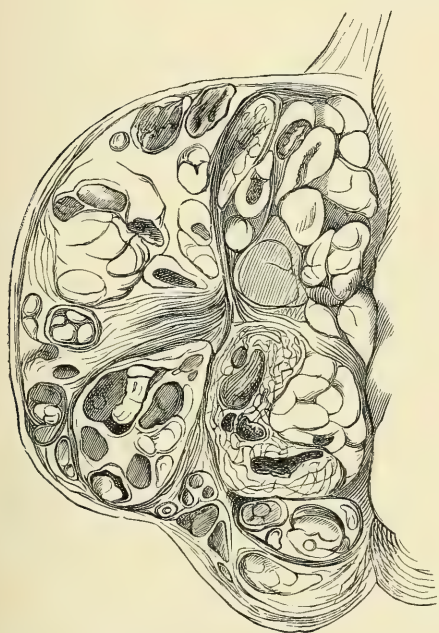


FIG. 664.—Cystic degeneration of adenoma of the testicle (cysto-adenoma). (After Kocher.)

Carcinoma.—Both scirrhus and medullary cancer may develop primarily in the testicle or epididymis. The encephaloid variety is most frequently encountered. The microscopical characters of these different varieties of cancer will be given in the chapter on tumors.

Carcinoma of the testis is apt to occur about the age of puberty, although it may be met with later in life. One organ is affected as a rule. It is more apt to begin in the testicle than in the epididymis. In the early stages of the development cancer of the testes is not painful, but as the disease advances the suffering may be intense. Early removal offers the only hope of cure, and this, unfortunately, is not great.

Sarcoma testis occurs at all ages, but is chiefly confined to childhood and early manhood. Following the general law of sarcomata, that of the testicle is rapid in growth, attaining at times an enormous size. This is one of the chief diagnostic points of this tumor, which is hard, usually pyriform in shape, and of comparatively smooth contour. Castration offers the only hope of relief.

It will be seen from the foregoing that accurate diagnosis of the various neoplasms which develop in the testicle is difficult and often impossible. Almost all of these morbid processes lead to destruction of the organ and loss of function, and immediately or remotely threaten the life of the individual.

Thus tuberculosis, adenoma, carcinoma, and sarcoma may be classed as malignant. Enchondroma, although not intrinsically malignant, leads to loss of function, and in this particular justifies operative interference. The same applies with greater force to cystic degeneration of this organ, since cysts often develop in malignant neoplasms of the testicle. In view of these facts, when only a single organ is involved, it will be advisable in the early history of any neoplasm of this organ to consider the propriety of castration.

The operation is thus performed: Shave the scrotum and pubes, and make an incision extending from the external abdominal ring along the anterior surface of the cord and testicle to the base of the scrotum.

When the morbid process involves the scrotal tissues, and even when there is a suspicion of involvement, the primary incision should be carried well away from the suspected tissue into the healthy structures.

Two points of importance are suggested in the removal of this organ. The first is to make an incision into the mass in order to clear up the diagnosis; the second is to secure the vessels by the ligature applied near the external ring, and thus prevent the danger of forcing septic or metastatic matter in the lymph channels or vessels leading toward the center. The cord should be exposed at the ring, the vas deferens isolated, and a large, double catgut ligature thrown around so as to include the entire cord except the vas deferens. This is twisted around the cord while the exploratory incision is being made, and, if the diagnosis is confirmed, the catgut is tied and the cord divided between the two ligatures. The diseased organ is then dissected out, the hæmorrhage arrested, a drainage-tube introduced, and the wound closed with catgut sutures. A single dressing will usually suffice. When the vas deferens is divided, the accompanying artery will have to be separately tied.

Malposition.—One or both of these organs may be absent from the normal position in the scrotal sac. The descent from the abdominal cavity may be prevented by narrowing or closure of the inguinal rings, or the inner ring may be passed, the testicle being arrested at the outer opening, and thus imprisoned in the canal; or, passing both rings, it may lodge beneath the skin near the pubic crest, or in the perinæum or groin. Occasionally the testicle remains entirely within the abdominal cavity. Another rare form of malposition is when the organ is turned obliquely or crosswise in the scrotum.

Misplaced testicle does not usually give rise to great inconvenience until the approach of puberty, when its normal development is interfered with by compression. If it is lodged in the inguinal canal, where it is acted upon by muscular contraction, it may cause pain at an earlier period. The descent of a hernia upon a testicle thus imprisoned gives rise to considerable annoyance. An imprisoned testicle is occasionally the seat of a neoplasm. The symptoms are those of pain, neuralgic in character, and the diagnosis must depend upon the absence of the organ from its normal place and its recognition in the position of the abnormal swelling.

Misplaced testicle requires no special treatment until it becomes a source of inconvenience or annoyance, or is the seat of some new formation. Extirpation is then demanded.

Supernumerary testicle does not occur. In several instances a cyst or other neoplasm has been mistaken for an extra organ.

CHAPTER XX.

THE GENITO-URINARY ORGANS IN FEMALES.

Lesions of the Vulva and Perinæum—Wounds.—*Incised or lacerated* wounds of the vulva are frequently accompanied by profuse hæmorrhage, especially when the venous plexuses which compose the *bulbs of the vestibule*, on either side of the vaginal orifice, or the large *connecting veins* which extend upward to the clitoris, are divided. Incision or rupture at or near the median line, the *posterior commissure* of the vulva, is not followed by hæmorrhage, as a rule, since the vascular network does not extend so low.

Bleeding may be arrested by direct compression with a pledget of gauze or lint, or, in case of extensive injury, by the ligature. The employment of styptic cotton is objectionable on account of the inflammation which it may cause.

Contusions of this part of the genital apparatus may be followed by *hæmatoma* or

abscess. Hæmatoma also occurs in rare instances in pregnant women from over-distention and rupture of the veins without direct violence.

In this variety of swelling operative interference is not advisable, unless the tumor is so large that it seriously interferes with the comfort of the patient, or unless sloughing is imminent or suppuration supervenes. When *abscess* occurs, it should be incised and drainage established. Abscess here is most frequently situated in the region of Bartholin's gland, between the vaginal orifice and the *erector clitoridis* muscle. *Boils* are not infrequent in this same location, and require to be opened,

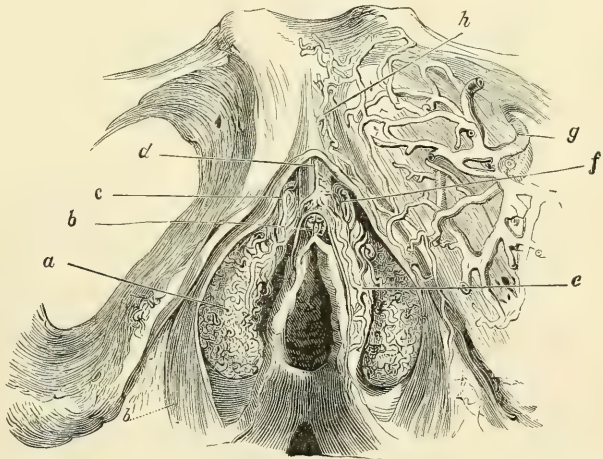


FIG. 665.—Showing arrangement of the erectile tissue and venous plexuses about the vulva. *a*, Bulb of vestibule. *b*, Clitoris. *c*, Connecting veins. *d*, Dorsal vein of clitoris. *e*, *f*, Deeper veins. *g*, *h*, Communication between obturator and vulvar vessels. (After Quain.)

kept clean by constant care, and when sluggish in healing should be touched thoroughly with lunar caustic.

As a result of injury, and occasionally as a congenital affection, *adhesions* of the labia exist. This condition should not be mistaken for the *hymen*, which membrane is situated farther inward. The treatment required is a careful separation of the adhering surfaces in the median line and the insertion of a plug of gauze or a glass cylinder, which is allowed to remain until the raw surfaces become covered with epithelia.

Rupture of the Posterior Commissure of the Vulva and Perinæum.—Rupture of the perinæum may be *partial* or *complete*. In *partial* rupture, the laceration may involve the tissues down to or partly through the *sphincter-ani* muscle. *Complete* laceration extends through to the anus and involves more or less of the recto-vaginal septum and wall of the rectum. In very rare instances, the laceration is *central*, in which case a sinus is developed, extending from the inferior vaginal wall or floor to some point on the perinæum, the *fourchette* and *sphincter ani* remaining intact.

Rupture of the perinæum may occur at any stage of the child-bearing period. The frequency of this accident is in general proportionate to the size of the child, the rapidity of delivery, and the age of the mother at the period of first confinement.

A breech presentation, in which the head and arms are crowded together through the vagina and vulva is apt to produce severe laceration, especially when, in order to prevent too prolonged pressure on the

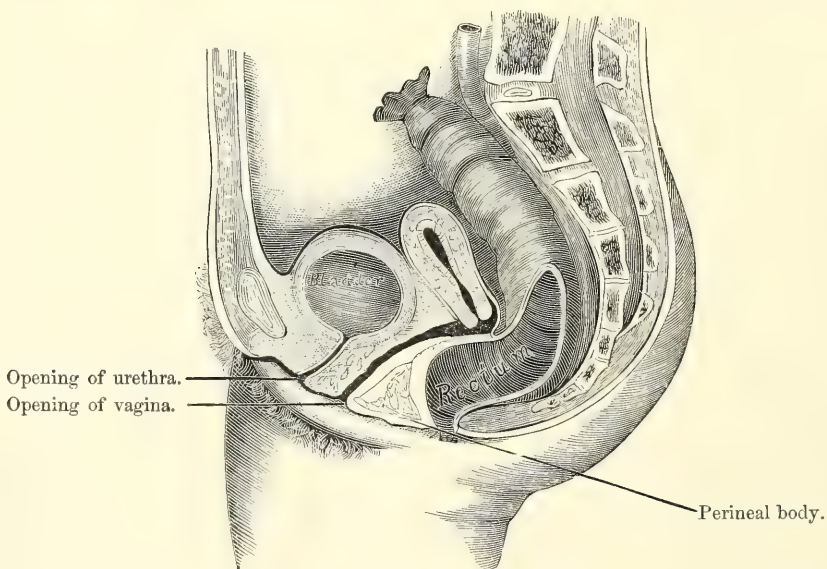


FIG. 665 A.—Showing in perpendicular section the perineal body, and its support to the bladder, vagina, and rectum. (After Thomas.)

chord, rapid delivery is necessary. Rapid expulsion of the child by the first few and violent uterine contractions, or by the use of forceps before natural dilatation has been effected, will add greatly to the danger of

rupture of the perinæum. Parturition occurring for the first time after the thirtieth year of life is also more apt to be attended with laceration of the perinæum than at an earlier period, when the tissues are more yielding.

There may result from perineal lacerations: *hæmorrhage*, and *loss of function in the sphincter-ani muscle*, *rectocele*, *cystocele*, *proctitis*, *cystitis*, *prolapsus*, and *other displacements* of the uterus and its appendages (Fig. 665 A and Fig. 665 B).

Treatment.—The indications are to restore as near as possible the normal relations of the separated tissues. In *incomplete* rupture, or even when the laceration extends barely into the anal margin, the *best time* to operate is immediately after the delivery of the placenta. The contra-indications to operative interference here are exhaustion by reason of hæmorrhage, or a prolonged and difficult labor.

In complete rupture of the *recto-vesical septum* the operation is of necessity so prolonged that it is advisable to wait until involution has taken place, and the patient's vigor is restored.

Operation for Old Incomplete Rupture of the Perinæum.—Prepare the patient by emptying the alimentary canal of fecal matter, for six days before the operation. Fluid extract of cascara sagrada ℥ x-xxx , three times a day, or *Hunyadi water* before breakfast, will secure free discharges. Liquid diet should be ordered for the last three days of preparation, and a copious enema given on the morning of operation. No laxatives should be administered within twenty-four hours of the operation.

The instruments and material required are a pair of sharp-pointed scissors curved on the flat, a tenaculum or good tissue forceps, a strong needle-holder, some strong round needles, without cutting edges, with a half-curve near the point, varying from about one and a half to two inches in length, each armed with a loop of fine strong Chinese twisted silk, for carrying the wire through, some silver-wire sutures, one foot long each (No. 27 for deep, No. 33 for superficial sutures), a piece of small-sized rubber tubing. By holding the end of the silver wire over a spirit-lamp, it melts and is easily shaped into a shot, which prevents it from being accidentally jerked through when introduced.

Place the patient upon the table on the back, the sacrum near the

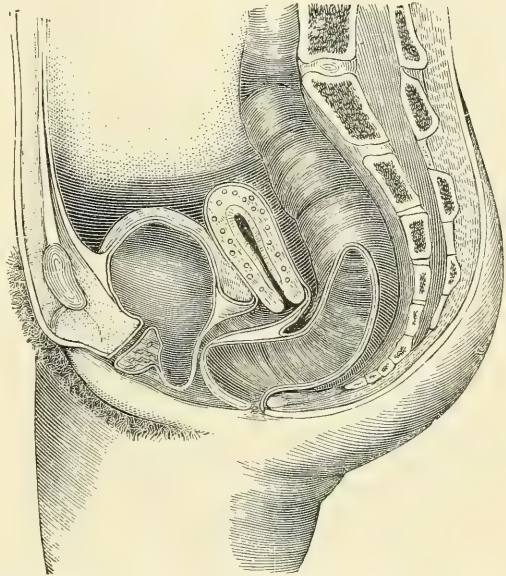


FIG. 665 B.—Rectocele and cystocele following destruction of the perineal body. (After Thomas.)

edge, the legs flexed on the thighs, and the separated thighs flexed on the abdomen, and held by two assistants, who also separate the labia.

Irrigate the vagina, vulva, and anal region with 1-to-3000 corrosive sublimate solution and thoroughly dry these organs with sponges. A close inspection of the torn surfaces should now be made, so that the full extent of the laceration may be realized. This will not be difficult to determine, since the peculiar, glistening, smooth surface of the cicatrix is readily made out. By carefully approximating these surfaces before using the scissors, the extent of denudation may be appreciated. The clover-leaf shape of the denuded area is well shown in Fig. 665 c, extending upward along the labium of either side and well up

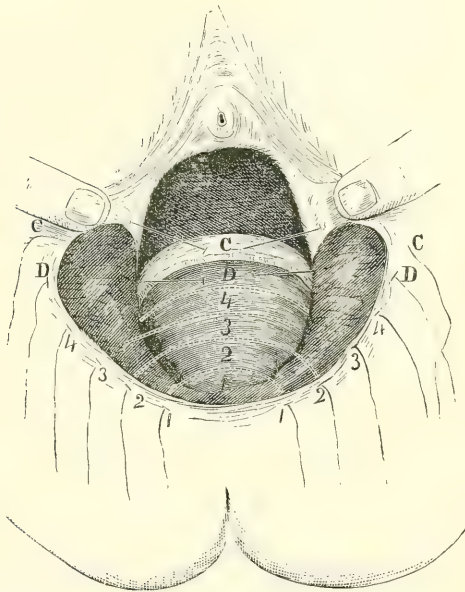


FIG. 665 c.—Operation for diminishing the vaginal outlet by external sutures after rupture of the perineum. (After Emmet.)

into the depression or angle, where the floor of the vagina and labium come together. Upon the floor of the vagina the denudation should extend backward to the crest of the rectocele or elevation formed by the bulging forward of the floor of the vagina. The tissue to be removed in freshening the torn surfaces should be picked up by the tenaculum or forceps, and shaved off with the scissors. It is advisable to commence at the lowest portion of the scar by taking up a strip from the patient's left directly across the perineum to the right (from *C* to *1*, *1* to *C*, Fig. 665 c). In this way the parts yet to be lifted are not obscured by the bleeding.

Denudation of the vaginal floor can be most rapidly accomplished by inserting one or two fingers into the rectum and making tense and elevating the surface to be freshened over the ends of the fingers.

The sutures are now introduced, commencing with No. 1 (Fig. 665 c), near the *sphincter ani*. They should be inserted about one fourth of an inch apart and the needle should enter the same distance from the edge of the wound. It is well to include a liberal quantity of tissue. As the needle is carried through from the (patient's) left to right side, it should be carefully guided, so that it does not emerge at any point on the denuded surface (nor by any mishap penetrate into the rectum), and finally be brought out through the integument of the right side at a point exactly opposite its entrance. As each suture is passed, the finger in the rectum will enable the operator to guide the needle safely through the recto-vaginal septum. After two or three sutures are passed, on account of the distance across the denuded area, it may be necessary to

bring the needle out in the middle line. It should be reintroduced at the same point, so that the suture will not be exposed.

The suture next to the last (*D*, Fig. 665 c), after passing through the labium, is not made to pass into the recto-vaginal septum until the needle approaches the middle line of the septum, where it is passed through this for about the extent of one inch.

The uppermost suture of all (*C*, Fig. 665 c) enters at the upper limit of the freshened surfaces, passes through the labium, comes out in the cavity of the vagina, and then, just above the limit of the denudation on the recto-vaginal septum, it is made to traverse this for about one half of one inch (an auxiliary or supporting suture). As each wire is drawn through, the ends should be loosely twisted to prevent being pulled out by accident. When all are inserted, the wound should be thoroughly cleansed and disinfected with sublimate solution and the wires twisted, commencing with the lowest, No. 1. The twisted ends are left about two inches long, are gathered together in a bundle (Fig. 665 d), and included in a piece of soft rubber tubing held in place by a bit of thread.

The patient's thighs should be bandaged together. She may rest on the back or side as preferred, and the catheter should be employed every five or seven hours, in cases where the urine can not be naturally voided. It should be the operator's aim to permit no movement of the bowels for two or three days, and when this occurs an enema of warm water should be employed to secure a soft or liquid discharge. The passage of solid matter will seriously endanger the success of the operation.

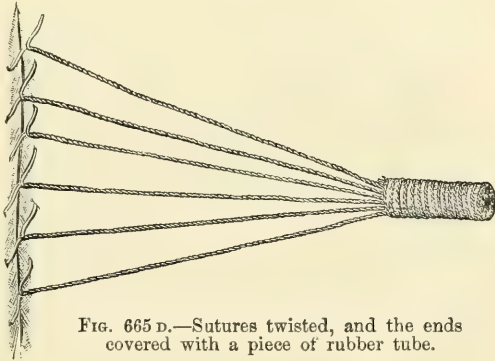


FIG. 665 D.—Sutures twisted, and the ends covered with a piece of rubber tube.

The sutures should be removed in eight or ten days. The most suitable position is with the patient on the back, the thighs held together and flexed well upon the abdomen. The lowest wire is first disengaged and gently pulled upon until the right side (patient's left) of the buried loop is seen, when the scissors' point is passed beneath and made to divide it. Care should be taken not to separate the barely united surfaces, and this is best avoided by drawing the twisted stub of the divided suture toward the side on which it was cut. Abduction of the thighs should not be allowed until about the fourteenth day.

Immediate Perinæorrhaphy.—After the placenta has been expelled, the uterus should be firmly compressed in order to cause rapid and thorough contraction, and also to force out any remaining clots of blood. The vagina should then be irrigated with warm 1-to-3000 sublimate solution, and a soft, small-sized sponge inserted to prevent the descent of any fluids from the uterus while the sutures are being passed. These are inserted in the same way as just described for secondary perinæorrhaphy,

and the freshly lacerated surfaces untouched by the scissors are at once approximated. The vaginal sponge tampon is now removed. The after-treatment does not differ from that above given.

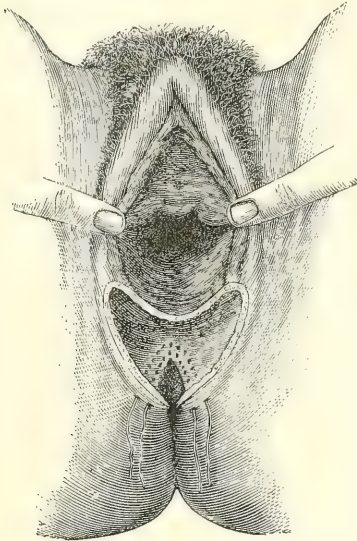


FIG. 665 E.—Surface denuded in complete perineal rupture, and the first two sutures in position. (After Thomas.)

Secondary Operation for Complete Laceration of the Perinæum.—The most rigid preparatory treatment should be carried out, the object being to empty the entire alimentary canal of all solid matter, and to prevent, as far as possible, the accumulation of gas. To this end a liquid diet should be ordered for one week before the operation, a copious enema of warm water and inspissated ox-gall should be given daily, and on alternate days a free laxative, discontinuing the latter twenty-four hours before the operation.

The chief objects of this operation, given in order of importance, are: (1) restoration of the functions of the *sphincter-ani* muscle, and (2) restoration of the perineal body. The denudation should extend along the triangular cicatricial surface of each half of

the divided perinæum and entirely along the edges of the rent in the recto-vaginal septum. For the first suture, the needle is introduced just at the margin of the anus and one quarter of an inch from the denuded surface. It is now directed through the recto-vaginal septum to the angle of the rent, then back along the opposite side, and made to emerge at a point corresponding to its insertion (Fig. 665 E). Great care should be taken to prevent the needle entering the rectum. A second suture is passed parallel with this. The remaining sutures are inserted as in the operation for incomplete rupture. The bowels should not be allowed to move for four or five days after the operation, and then an enema should be *administered by the physician*. Should gas accumulate in the rectum, it may be removed by the careful insertion of a small soft catheter.

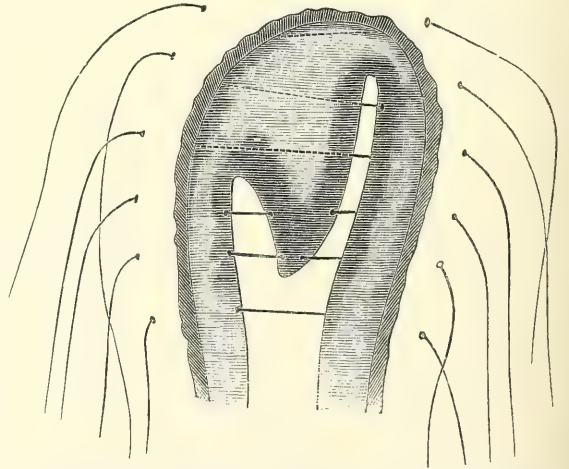


FIG. 665 F.—The direction of the sutures in a cleft laceration through the recto-vaginal septum. (After Emmet.)

When the rent in the recto-vaginal septum is bifid (a rare occurrence)

the edges should be correspondingly freshened, and the sutures inserted as shown in Fig. 665 F. The sutures should be removed on the eighth or tenth day (Emmet).

When the laceration is *central*, it is advisable to incise the strip of tissue between the sinus and the fourchette, pare the edges of the laceration, and insert sutures as in the operation for incomplete rupture.

Diseases of the Vulva.—The vulva and adjacent cutaneous surfaces may be the seat of syphilitic, chancroidal, tubercular, and epithelial ulcers, of ulcers resulting from abrasions or fissures which have been in contact with gonorrhœal virus, a leucorrhœal discharge, or the urine; and of warty excrescences (condylomata).

The primary lesion of *syphilis* and the *chancroidal ulcer* in this location do not differ materially from those already given. *Tubercular* ulcers follow a chronic course; they are irregular in outline, and are characterized by a deeper infiltration of the subcutaneous tissues than in the acute forms of ulcers. *Epithelioma* of the vulva possesses the same characteristics as given for this condition on other muco-cutaneous surfaces. Condylomata have already been considered.

Treatment.—A typical syphilitic ulcer requires no local treatment. Whenever any ulcer of this region takes on a phagædenic character it should be at once thoroughly cauterized. I prefer the red-hot wire or Pacquelin's cautery. If these agents can not be employed, pure nitric acid will suffice. The injection into the tissues beneath and around the ulcer, of from gtt. v–xx of a 4-per-cent solution of cocaine hydrochlorate, renders the free use of the cautery painless. After destroying the ulcer, an ointment of cocaine hydrochlorate, gr. ij, iodoform gr. j, morph. sulph. gr. ss., olei theobrom. q. s., may be applied as an emollient local anæsthetic.

Lupoid or *tubercular* ulcers should be dissected out, or deeply injected with pure liquid carbolic acid, until sloughing is produced. Mild forms of this ulcer may be cured by scraping with a sharp spoon or ring-scoop, and repeating this procedure at intervals of two weeks, until cicatrization ensues. *Epitheliomata* should be freely excised. *Papillomata* may be radically destroyed by clipping them off with curved scissors and burning the stump with nitric acid. In all forms of ulcer of the vulva complicated with vaginal discharge, repeated irrigation of this canal with warm sublimate solution 1-to-5000 should be practiced.

Vulvitis from direct injury should be treated by complete rest, aided by the sitz-bath of warm water and by emollient applications.

Gonorrhœa in the female is not infrequently confined to the vulva and meatus urinarius, but may extend to the vagina, uterus, and tubes, and to the bladder. The symptoms of inflammation supervene, as a rule, rapidly after the contact, there being first noticed a sense of burning over the meatus and along the urethra, especially severe during and immediately after micturition. There soon follows a purulent and occasionally a bloody discharge from the urethra and vagina. The diagnosis of gonorrhœa in the female is not so easily made as in the male, since a vaginal discharge not specific in character may conceal the true nature of the

disease. The discharge directly from the meatus is the most direct symptom of gonorrhœa. In the *treatment*, complete rest is indicated. The warm sitz-bath is of great importance. Irrigation of the vagina with warm 1-to-5000 sublimate solution (or a weaker mixture, should this prove painful) should be performed two or three times a day. If commenced early in the disease, the invasion of the uterus may be prevented; this is of vast importance, since serious lesions (*sterility, pyosalpinx*, etc.) may result from gonorrhœal inflammation of the uterus and Fallopian tubes. I do not think injections of the urethra are indicated, certainly not in the early stages. The administration of Vichy water, alkaline diluents, citrate of potash, etc., will suffice to irrigate this channel by increasing the flow of urine.

Boils are not infrequently met with in the labia, and should be treated as when occurring elsewhere.

Pruritus vulvæ is a distressing and often an obstinate disease. The sense of itching, burning, or fomication may be felt at the vulva, in the vagina, or over the entire pudendal region. It is paroxysmal in character; the attacks may occur at all times, but more frequently are severest immediately after the patient goes to bed. This condition is met with in females of all ages, but is more apt to occur about the cessation of the menses. In addition to superficial lesions of the genital organs, displacement of the uterus, chronic inflammation of the vagina, or any disorder of the deeper organs, may cause pruritis of the vulva. The indications in treatment are to correct any existing pathological condition. Grailly Hewitt advises a mixture of one part of chloroform to six of almond-oil.

Hernia of the labium may be recognized from the history of the case, the tumor having first been noticed above at the canal of Nuck, descending more or less gradually into the labium.

Cystic tumors here originate in the substance of the labium.

Hernia of the *ovary* occasionally is met with. The *diagnosis* may be made as follows: In hernia of the bowel or omentum an impulse will be transmitted on coughing; it may be reducible; it is first observed in the canal of Nuck, extending subsequently into the labium. A prolapsed ovary is painful on pressure, giving a peculiar sensation not met with in compression of a cyst or loop of intestine. The character of a cyst may be positively determined by exploration with a very fine and thoroughly aseptic hypodermic needle and syringe. An exacerbation of pain in a tumor in this locality, about the menstrual period, would suggest the presence of a misplaced ovary.

The treatment of hernia in the female is given elsewhere. A prolapsed ovary should be extirpated, and a cyst of the labium or canal of Nuck should be removed.

The Vagina—Vaginitis.—Inflammation of the vagina, whether *traumatic* or *idiopathic*, should be treated by rest, irrigation, and the sitz-bath. In the acute form, warm boracic-acid solution (Thiersch) is preferable. The patient should lie on the back, the sacrum resting upon a bed-pan, and the solution applied by means of a fountain irrigator from

a height sufficient to give the stream considerable force. As soon as the more acute symptoms have subsided—and in all forms of chronic vaginitis—the thorough application of nitrate of silver, $\frac{3j-iij}{\text{water } \frac{3j}{\text{ij}}}$ is indicated. The irrigation should be resumed in about thirty-six hours after the nitrate-of-silver solution has been brushed over the surfaces of the vagina. This application may be repeated in from five to eight days, as needed. Before introducing the stronger solution, it is advisable to cover the external genitals with vaseline to prevent the burning which would otherwise occur on the exposed surfaces.

Vaginismus, or “spasm of the vagina,” is chiefly due to an abnormally sensitive condition of the vaginal orifice. Vaginitis is not usually present. Upon introducing the finger, the *hymen* will often be found tense and resisting. An effort to carry the finger into the vagina will be extremely painful, and will cause spasm of the sphincter-vaginæ muscle.

Treatment.—Place the anæsthetized patient on the back, with the sacrum resting on the edge of the table, the thighs separated and held by assistants. With the hymen exposed by holding the labia apart, seize this membrane with a mouse-tooth forceps and dissect it

out close to its vaginal attachments. Introduce two fingers, dilate the vagina, and with the knife make two parallel incisions on the lateral aspects of the vaginal wall throughout its length. These




FIG. 665 G.—Sims's glass vaginal plug.

incisions should extend about through the vaginal wall. Then introduce the Sims's glass vaginal plug (Fig. 665 G), adjusting the instrument so that the urethra will fit into the concavity on its upper surface. It should be removed in six or eight hours, the vagina irrigated and the cylinder reintroduced. After the first twenty-four hours it may be worn three or four hours daily. This should be kept up for two or three weeks, or until all trace of the vaginismus has disappeared.

Stricture of the Vagina.—Occlusion of the vagina may be *partial* or *complete*, and may be *congenital* or *acquired*. The diagnosis is readily made by digital examination or by inspection. Imperforate or partially obliterated hymen need not be mistaken for true stricture, when it is borne in mind that this membrane is situated just at the entrance to the vagina, while stricture proper occurs beyond this point in a large majority of cases. The exact situation of the obstruction may be readily appreciated by making a digital exploration of the rectum, thus locating the cervix uteri, while the other index-finger is introduced *per vaginam* as far as the stricture. In complete obstruction (*atresia*), the absence of the menstrual discharge should be considered in arriving at a diagnosis.

Treatment.—In partial occlusion, due to bands or a membrane, these should be divided or ruptured, a thorough dilatation accomplished, and the glass cylinder of Dr. J. Marion Sims introduced, as in the treatment of vaginismus. When there is a narrowness of this canal, without well-

marked contracting bands, it will suffice to dilate with bougies, gradually increasing in size until a cure is effected. The operation may be repeated two or three times a week, or less frequently should any severe inflammation supervene.

When the opening is so small that the finger can not be introduced, a probe-pointed bistoury may be carried through and the obstruction divided in several directions, after which forcible dilatation should be practiced.

When complete occlusion exists, the canal should be opened up by cutting through the adherent walls in the ascertained direction of the *cervix uteri*. By dilating the canal as wide as possible to the point of obstruction, then locating the cervix with the index-finger of the left hand in the rectum, and the sound kept constantly in the urethra and bladder as an additional guide, the dissection may be safely accomplished. The Sims glass cylinder should be employed in the after-treatment.

Narrowing the Vagina.—As a result of over-stretching during labor, and especially when the perineal body has been ruptured, the posterior wall of the vagina, with or without the contiguous wall of the rectum and the anterior wall of the vagina, with the bladder, protrude into the vagina. The former condition is known as *rectocele*, the latter *cystocele*.

The uterus and its appendages are also more or less dragged downward, the cervix approaching the *ostium vaginae* and in extreme cases protruding between the labia—*prolapsus uteri*.

It is important to correct each or all of these conditions at the earliest possible moment. The operation for the cure of *rectocele* consists in removing the mucous membrane from the posterior wall of the vagina over an area sufficiently large, and then introducing sutures of silver wire to hold the freshened surfaces together until union has occurred. Since *rectocele* exists so frequently with laceration of the perinæum, the two conditions should be corrected by a single operation. The method

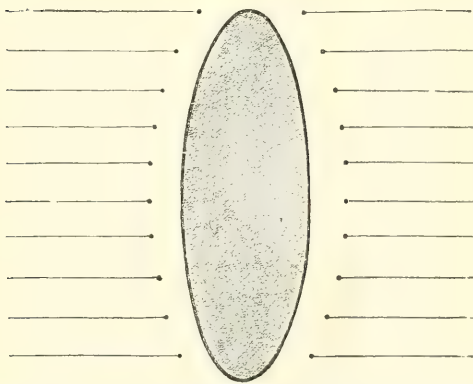


FIG. 665 H.—Oval denudation for the cure of rectocele, with sutures passed. (After Thomas.)

of procedure for partial *rectocele* has been given with perinæorrhaphy.

The extent of denudation may be determined by approximating the sides of the floor of the vagina with tenacula. The mucous membrane should now be trimmed off with sharp-pointed scissors curved on the flat. The freshened area may be oval in shape, as in Fig. 665 H, or may vary to suit any particular operation, bearing in mind the object to be attained, namely, a uniform narrowing of

the tube so as to render descent of the uterus or rectal wall impossible. It is advisable to begin the denudation at the vulva and work upward,

for in this way the blood does not obscure the field of operation. The mucous membrane may be rapidly pared off by lifting the posterior wall of the vagina forward by means of one or two fingers introduced into the rectum. Sutures of silver wire are next introduced, as shown in Fig. 665 H. While this is being done, the finger should be kept in the rectum, so that the needle may not enter this cavity. On account of the pain caused in its removal, silver wire is objected to by some operators and chromicized catgut sutures have been in late years substituted. Properly prepared, these sutures will hold the raw surfaces in apposition for eight or ten days and secure good union. Greater quiet should be demanded, however, than is necessary when wire is employed. When the perinæum is torn and perinæorrhaphy is necessitated, silver sutures should be employed for this part of the operation.

For *cystocele* a similar operation is performed on the upper or anterior wall of the vagina. In order to prevent the possibility of wounding the urethra or bladder, or allowing the needle to enter while the sutures are being inserted, a large sound should be kept in the bladder during the operation. When rectocele exists with a cystocele, associated with partial prolapse of the uterus, the operation on the posterior wall by restoring and holding the uterus in its proper place may also relieve the cystocele. Unless this latter condition exists in a severe form, it is advisable to await the result of the operation for rectocele before operating on the anterior wall.

Vesico-Vaginal Fistula.—A fistulous opening from the bladder into the vagina may be *surgical* or *accidental*.

In order to secure drainage of the bladder for the relief of chronic cystitis, or for other purposes, *kolpo-cystotomy* may be demanded. Section of the bladder-wall should be in the median line, and should as nearly as possible bisect the triangle formed by the orifices of the ureters and urethra. A sound introduced into the bladder should be employed to make prominent the floor of this organ, while with the Sims speculum, the patient being in the Sims position, the section may be readily accomplished by a long-curved bistoury. For drainage of the bladder by this method the T rubber tube employed in supra-pubic cystotomy should be used. The end may project out of the vulva into the urinal. For the removal of calculi so large and hard that lithotrity is contra-indicated, and for all neoplasms of this organ, *supra-pubic cystotomy* is preferable.

The details of the operation do not differ materially from those in this operation on males. The water-bag for lifting the bladder is placed in the rectum, or the finger in the vagina may sufficiently lift the organ toward the pubes. If the bladder will not retain enough water, pressure of the urethra against the pubic arch will secure retention.

The form of vesico-vaginal fistula most difficult to deal with, and therefore of greatest surgical interest, is that which follows sloughing of the vesico-vaginal septum during difficult parturition. Fortunately, the increased skill of the accoucheur and the wider dissemination of practical knowledge in midwifery have greatly diminished the number of cases.

In closing a fistula here, the following general points are important: The vagina and bladder should be got into the best possible condition by rest and irrigation of these organs for some days before the operation. When well-marked bands of cicatricial tissue exist in the neigh-

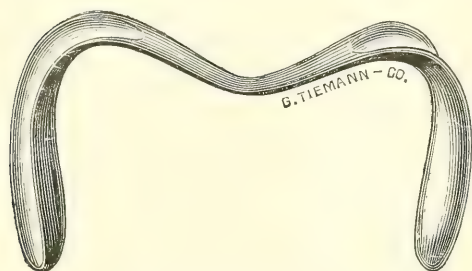


FIG. 665 I.—Sims's speculum.

borhood of the margins of the fistula, these should be divided, and a bulb or glass tube of large size should be introduced to keep the vagina distended. This cylinder should be worn for the few days preceding the operation. With the patient in the Sims position and a large Sims speculum (Fig. 665 I) introduced, the operation is commenced by paring the

edges of the fistulous opening. This is done by curved scissors or the bistoury, the former being preferable. If any portion of the sinus is left unfreshened, the wound will fail of union. All cicatricial tissue should be dissected away, for only fairly healthy tissue will unite. The section extends through the mucous membrane of the vagina and directly through the vesico-vaginal septum, beveling this down to *but not*

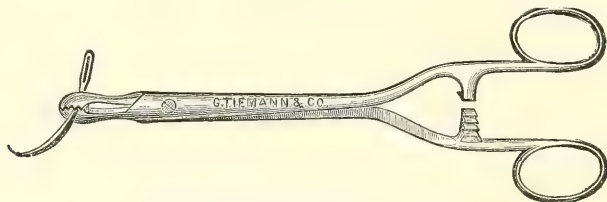


FIG. 665 J.—Sims's needle forceps.

through the mucous membrane of the bladder. The sutures should next be introduced, the needle entering one fourth of an inch from the edge of the wound, and coming out so as not to include the mucous membrane of the bladder. Dr. J. Marion Sims, who originated this operation, insists that the sutures should be close together—from one eighth to three sixteenths of an inch apart. The sutures are of the best silver wire, No. 28 or 29, and are carried into place by a silk loop with which the needle is threaded. When the wire is being introduced, in order to



FIG. 665 K.—Sims's fork for approximating the silver sutures at the level of the wound.

prevent the suture tearing through, it is advisable to use the fork (Fig. 665 K), to take the strain off the soft parts. When all the wires are introduced, the margins of the wound are approximated by gentle traction on the two ends of the wire, the fork is carried down to the level of the wound, and the wire twisted upon this, as shown in Fig. 665 L. The ends are clipped about three quarters of an inch from the wound. A

Sims sigmoid catheter or a soft Nélaton catheter should be secured in the urethra and bladder. The sutures are removed about the eighth day, the patient being in the same position as for the operation.

After the operation the patient should be kept quiet in bed, resting by preference upon the side. The urine should be drawn at regular intervals, when the stationary catheter is not employed.

In the closure of recto-vaginal fistulæ the same operative measures are indicated.

Cervix Uteri.—Lacerations of the cervix may be classified as unilateral, bilateral, anterior, posterior, and stellate. They are also complete or incomplete. The bilateral variety is most frequent, the unilateral next, the remaining forms being comparatively rare. In a complete laceration, the tear extends through all the tissues of the cervical wall into the vaginal vault; the incomplete variety extends into but not through the wall of the cervix.

The principal indications for operative interference are, pain, constant in character, either local or reflex, hypertrophy or thickening of the tissues of the cervix, as a result of granulations along the line of the laceration, cystic degeneration of the cervix, sterility from occlusion of the internal os, inability to carry the fœtus to term, etc. The danger of epithelioma, resulting from prolonged irritation of a fissured surface, should never be lost sight of. The preparation of the patient is practically the same as for any other operation about the rectum or genito-urinary organs. When the narcosis is complete, she is placed in the Sims position and a large Sims speculum introduced. The vagina should then be thoroughly irrigated with 1-to-3000 sublimate solution, and this canal and the cervix thoroughly cleansed. A strong tenaculum should now be hooked securely into the sound portion of the cervix and the uterus drawn toward the vulva. A second tenaculum is firmly inserted at the edge of the rent, the edge of which is now trimmed off with the Sims adjustable knife, or, if this is not at hand, Emmet's cervix-scissors. In freshening the edges of the laceration, the section should extend thoroughly into the angle of the tear, and all cicatricial or granulating surfaces should be most carefully removed. When the tissue along the line of the tear is densely cicatricial, it must be deeply excised for a successful union, as restoration of the cervical canal can not be accomplished when the cicatrix remains.

When a bilateral laceration exists, the denuded area should extend well out to the vaginal surface of the cervix and inward to the level of the internal os, or remaining cervical canal. It is usual to leave unrefreshed a space of about one fourth of an inch wide, as shown at *aa*, Fig. 665 M, which space corresponds to the canal to be restored by the opera-

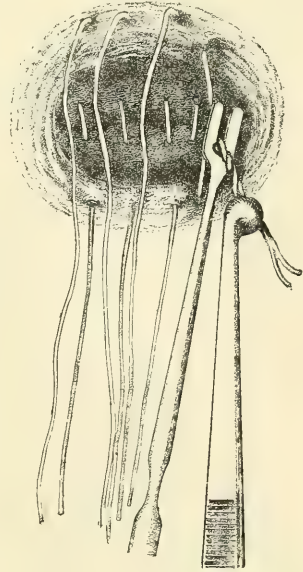


FIG. 665 L.

tion. The opposite fissure is prepared in the same manner, and the wire sutures are then inserted. The most suitable needle is a short, strong needle with a slight cutting edge on one side, this cutting edge limited to the first one fourth of an inch from the point. This needle, armed with the silk which serves to carry the wire, is passed through the vaginal portion of the cervix, one fourth of an inch from the edge of the wound, and brought out barely within the undenuded area *aa* left to form the walls of the canal (1, 1, Fig. 665 M). The deep suture—that in the

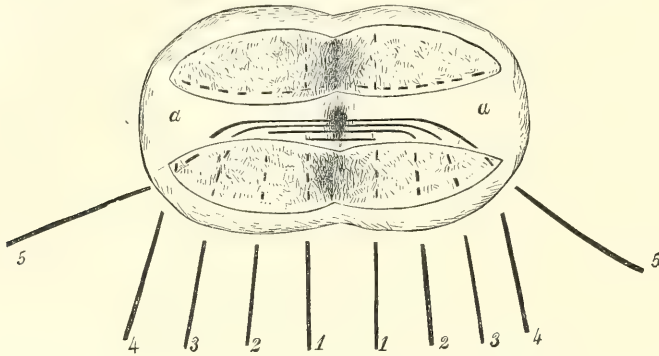


FIG. 665 M.—Showing the area of denudation, and the method of passing sutures in bilateral laceration of the cervix. (Mundé.)

angle—should be first inserted. When all the sutures are passed, they should be twisted in the order of insertion. It is important to bring the freshened surfaces accurately together, taking care not to twist the wire too tight, for fear of strangulating the tissue in its grasp.

After the sutures are all twisted, they should be cut at one fourth of an inch from the line of union and a sound introduced, to see that the canal is not by accident occluded. Whenever this is too narrow, or whenever for any reason the entire mucous membrane of the cervical canal is of necessity removed, a glass or hard-rubber stem should be inserted and worn for several weeks, until the walls of the new canal shall be covered by epithelium.

The patient is put to bed and kept perfectly quiet. The suture may be removed on the eighth or tenth day. This is accomplished by placing the patient in the same position as for operation, cleansing the parts thoroughly, lifting the deepest suture with the forceps until one side of the deeper and diverging wire is seen, and then dividing this with the sharp-pointed wire scissors. Great care and considerable skill are necessary to prevent the tearing apart of the freshly united surfaces. The patient should remain in bed for a week or ten days longer.

Excision and Amputation of the Cervix.—On account of cystic degeneration of the cervix, or for the removal of granulating surfaces of long standing, or the presence of epithelioma, the removal of a portion or all of this part of the uterus may be required. Excision is best performed with the knife, the blade of which should be long and slender (Fig. 665 N). Securing the cervix with a hook fastened near the anterior margin, the blade is carried up the cervical canal to a point high

enough to reach all the diseased tissue, then forced into the wall a sufficient depth, and is carried around so as to remove a cone-shaped

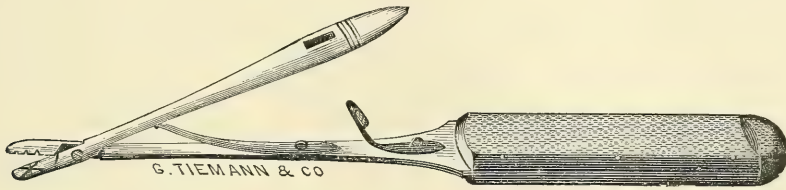


FIG. 665 N.—Sims's adjustable knife-holder.

mass, the center of which is the old canal of the cervix. The walls of the shell which remains should now be brought together by a row of silver-wire sutures on either side (arranged in the same manner as for a laceration), leaving a roomy canal in the median line into which the stem should be inserted and worn until an epithelial lining is developed upon the surfaces of this new canal.

When a more extensive excision or *amputation* is required, proceed as follows: If it is intended to remove the cervix at or near the internal os, it should be seized with the tenaculum, and drawn toward the vulva and cut squarely off with the

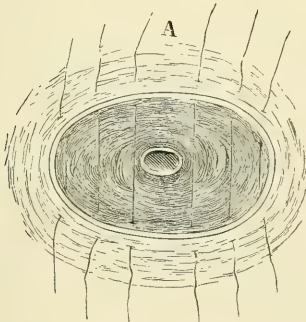


FIG. 665 O.
The stump after amputation of the cervix.

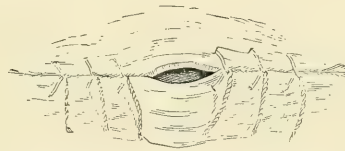

FIG. 665 P.—Flaps secured by sutures.

scissors or knife. If considerable bleeding occurs, the vessels should be immediately secured. The contiguous vaginal tissue should now be dissected up, and wire sutures inserted on either side of the canal, so that when tightened the vaginal tissues are drawn over and form a covering for the stump (Figs. 665 O and 665 P).

Vaginal Hysterectomy.—For incipient malignant disease of the uterus, the extirpation of this organ is indicated, and this may be done through the vagina or by abdominal section. In the selection of a method the size of the uterus, as a result of the neoplasm, or from any cause whatever, should be carefully considered. If this organ is about of normal size, vaginal hysterectomy properly performed offers at this date a lower mortality rate than the high operation.

*J. B. Hunter's Method.**—In order to complete the hysterectomy more rapidly, forceps are applied to the principal vessels and bleeding points as the operation proceeds, and these are left in position for periods

* "Medical Record," February 9, 1889, p. 147.

varying from twenty-four to forty-eight hours; the time otherwise lost in applying ligatures is thus materially shortened. The patient is placed on the back, the sacrum at the edge of the table, and the legs held up and out of the way by assistants or supported by the crutch. The pelvis may be slightly elevated, to allow gravitation to carry the intestines toward the diaphragm. Irrigate thoroughly with 2-per-cent creoline, or 1-to-5000 sublimate solution. A large Sims speculum and lateral retractors are required, and the uterus is drawn well downward and backward by a long tenaculum. With curved, blunt-pointed scissors the dissection is begun at the junction of the cervix and vagina in front, keeping a sound in the bladder all the time to avoid the danger of cutting into this organ. Proceed in this direction until the peritonæum is reached, but this should not yet be opened. Draw the uterus forward and make a similar dissection on the rectal surface. As the lateral attachments are next to be separated, it is necessary to proceed very cautiously, using the scissors so as not to divide much tissue at a single stroke, for fear of severing the larger vessels. When these are reached, the forceps are applied and the tissues divided between the instrument and the uterus. The handles of the forceps should be tied with silk to prevent their being dislodged. A second instrument is applied beyond the first, and secured in like manner, until the broad ligament of each side is divided. As the peritonæum is dissected away, by traction on the fundus uteri the utero-sacral ligaments may be put on the stretch, forceps applied to these, and the ligaments divided. All minor bleeding points should be secured by forceps, and many of these may be removed as soon as the operation is over. If the tubes and ovaries come plainly into view, they should be tied off with strong silk and removed. The uterus being entirely dissected out, is readily introverted and cut off at the vaginal junction. The parts are sponged dry, no irrigation employed, the forceps on the important vessels left in position, the entire cavity packed with creoline gauze, the pieces of which are attached to silk threads to facilitate removal. A tuft of cotton is placed around the handles of the forceps. The bladder should be emptied at regular intervals, and the bowels moved on the third day by the administration of calomel triturates, half grain doses, repeated three or four times. Some of the forceps on the less important vessels may be removed after twenty-four hours, those on the larger arteries in from thirty-six to forty-eight hours. The peritoneal surfaces unite readily, and the entire wound heals by granulation.

Irrigation should not be employed earlier than the third day, and fluids should not be forcibly thrown into the wound. The most careful antisepsis is demanded, both during the operation and at the dressings.

Hysterotomy and Abdominal Hysterectomy.—*Hysterotomy*, or cutting into the uterus for the extraction of the fœtus from the living mother, is an operation which has been greatly perfected within the last few years, chiefly owing to the labors of Saenger, Leopold, and Tait. It is indicated when at full term it is found impossible, on account of insurmountable disproportion between the diameters of the pelvic outlet

and the child, to effect delivery by the vagina. When this condition is evident, proceed as rapidly as possible in the following manner:

If the membranes are not already ruptured, break them. Disinfect the vagina and genitals with sublimate solution, 1-to-3500. Prepare the abdomen as for an ovariectomy, and make a long abdominal incision, controlling all bleeding with catgut ligatures as the operation proceeds. Having entered the abdominal cavity and made the opening large enough, place three or four silk sutures at the upper end of the wound in order to narrow the opening as soon as the uterus is drawn out of the incision, thus avoiding extrusion of the intestines. Drag the uterus outside the abdominal cavity, and close the upper portion of the wound by tightening the sutures already in position. If the intestines should be protruded, protect them with warm towels wrung out of Thiersch's solution, and beneath the uterus pass a piece of rubber cloth, disinfected in the same solution, to protect the abdominal cavity from the entrance of blood. Around the cervix uteri pass a stout piece of elastic tubing, and draw it tight, thus arresting the circulation in the uterus. Immediately incise the uterus in the median line and in its long axis, limiting the incision below to the peritoneal reflection, thus avoiding the large circular sinuses about the os internum, and extending it upward if necessary. Remove the child, and hand it to an assistant to resuscitate. The uterus will now usually contract. Introduce the hand into the uterus and remove the placenta. The uterine cavity is next to be disinfected with a 1-to-5000 sublimate solution. Unless the cervical canal is widely dilated (and this should be ascertained before the operation), the use of a utero-vaginal drainage-tube is indicated, and this latter must be of stiff rubber. The next step in the operation is the insertion of the sutures in the wall of the uterus. First ascertain whether the peritoneal covering of this organ is sufficiently movable to allow it to be folded in between

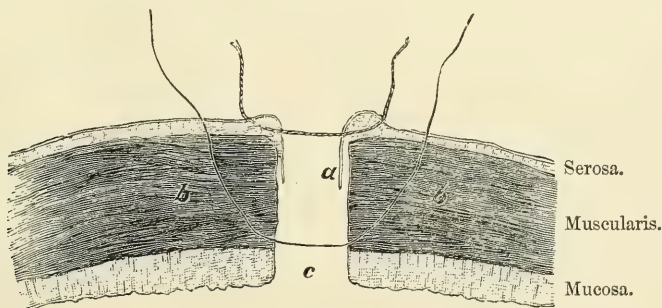


FIG. 665 Q.—Sutures in Cæsarean section. Method of passing the sutures in closing the wall of the uterus after hysterotomy. *a*, The peritoneal covering dissected up along the edge of the incision and inverted by the catgut suture, after the method of Lembert. *b*, The muscular substance, with the silver-wire suture passed through. *c*, Decidua. (Drawn by Dr. W. R. Pryor.)

the sides of the incision. If need be, dissect it up from its attachment to the muscular fibers a slight distance. The peritonæum is next folded in between the lips of the wound, and the deep sutures are passed (Fig. 665 Q). These should be of silver wire, because they are cleaner and held more unyieldingly than silk. They should be close enough to control

hæmorrhage and secure accurate adjustment of the sides of the wound. They should enter the peritoneal covering about half an inch from the edge of the wound, and pass through it and the muscular wall to the decidua, which must not be included in the suture; then across to the other side through the muscular and serous coats. After twisting the silver sutures, the superficial sutures of fine silk are introduced. These are to be from twenty to thirty in number, and are employed to secure perfect coaptation of the serous edges of the incision. They are introduced in the same way as Lembert's suture of the intestine. Lastly, the twisted silver wires are cut off about one-half inch from the level of the incision in the uterus, and the ends turned down parallel with the surface of this organ.

The incision in the abdominal wall is closed, as after ovariectomy. There are certain conditions which can only be determined by inspection through the incision in the abdominal wall which may contraindicate the operation just given, and necessitate a modified procedure.

If the patient has been long in labor, and considerable time has elapsed after the membranes have ruptured; if there is a putrid discharge from the vagina; if the symptoms of septic fever are present, with the perimetrium dulled and adherent to the muscular wall of the uterus, the operation of amputation of the uterus at the os internum is indicated. If malignant disease of the cervix is present, Freund's operation is to be preferred. If the pregnant uterus be the seat of a fibro-myoma, and so situated as to render delivery impossible, or if a rupture of the walls of the uterus has occurred, which is so ragged in outline that it can not be sutured, hysterectomy is indicated. The objects aimed at in all operations for the artificial delivery of children at term are, preservation of the mother's life and future health, with, if possible, the non-mutilation of her generative organs and the delivery of a living child.*

Porro's Operation.†—*Hysterectomy during Pregnancy.*—The abdominal incision is similar to that just given. It must not be overlooked that the bladder is high up and in good part uncovered by the peritonæum. As soon as the uterus is exposed it should be drawn out of the abdomen. Place around the cervix a large piece of rubber tubing if an *écraseur* or clamp is to be used; or a rubber ligature, if that is to be permanent. Protect the intestines with warm towels wet in Thiersch's solution. Under the uterus and over the abdominal incision spread a large piece of rubber cloth, protecting the peritoneal cavity from the entrance into it of blood, etc. Tighten the rubber ligature around the cervix, and immediately incise the uterus and rapidly extract the child. The incision in the uterus may be made in any direction convenient, although, as a rule, the median linear incision is preferable. The next step is to cut off the uterus close to the ligature. Curette out the cervical canal, or burn it and the stump with the cautery. Cleanse the peritoneal sac of blood and serum. See

* As regards statistics, Saenger gives thirty Cæsarean sections performed as above described, with a mortality of 26·7 per cent.

† The mortality after this operation is greater than that after hysterotomy.

that no blood has collected between the cervix and pubes. Transfix the stump with long steel pins just above the ligature, and otherwise treat the stump as should be done after hysterectomy for fibro-myomata. If it is deemed necessary to employ drainage, the Sims tube (see Fig. 667) should be employed in these cases. The stump should be dusted with iodoform, as heretofore directed.

The method recommended by Tait is practically as follows: An abdominal incision is made large enough to admit the hand. A piece of strong rubber tubing is thrown around the uterus near the vaginal junction and tightened to arrest the circulation. An opening partly by incision and tearing is next made in the median line and long axis of the uterus, through which the child and then the placenta are extracted. The organ, rapidly contracting, is brought out through the wound, transfixed with two skewers just above the rubber cord, and the amputation made. After a careful toilet of the peritoneal cavity the wound is closed, the cord being left in position, and the stump stitched to the edges of the incision. When a simple hysterotomy is intended, the opening in the uterus should be incised, not torn, and sutures applied as directed in the preceding page.

Freund's Operation.—Removal of the uterus for malignant disease of this organ is thus performed: The patient is prepared as for an ovariectomy. The vagina is cleansed and rendered aseptic. The abdomen is opened, the uterus found and drawn up to the incision. It is then pulled to one side, and the broad ligament of the opposite side ligated in such a way that the ovarian artery, Fallopian tube, and round ligament are included in the grasp of the ligature. The ligament of the other side is in the same way tied off. The uterine arteries are next deligated by means of a ligature passed through the fornix vaginæ. If it be desired to remove the entire organ, the bladder is separated from the cervix, and the tissues around the cervix are cut through. Freund originally left the ligatures long, and brought them out of the vaginal opening. If it is desired to make a stump of the cervix, as in the case of cancer of the fundus uteri, the uterus is cut off just above the utero-vaginal junction, the two lips of the cervix brought together with deep sutures, the peritonæum carefully adjusted over them, the ligatures cut short, and the peritoneal cavity closed.

Hysterectomy for the Removal of Fibro-myomata—Schroeder's Operation.—After opening the abdomen the uterus and fibroids are freed from adhesions. A temporary elastic ligature is tied around the cervix, and the tumors and uterus cut away, leaving the stump in the shape of a V. The blood-vessels are now ligated with catgut (Schroeder does not insist upon this), and the sides of the cone brought together by layers of close sutures which begin at the bottom of the cavity. This mode of suturing is continued until the top is reached, when the peritonæum is carefully adjusted over the stump and the elastic ligature removed. Or the pedicle may, if small, be transfixed, ligated, and dropped. The peritonæum is cleansed of blood, etc., and the abdomen closed. If the myoma is pedunculated and the uterus itself is not the seat of multiple

growths, the tumor is cut off, and the suturing done at the point where the tumor grew. Or, if the tumor is sessile, so that the elastic ligature can not be employed, it is advised to incise the capsule, enucleate the tumor, and bring the flaps together as above directed. Keith and Hegar have the smallest mortality after hysterectomy, and it is their custom to treat the pedicle by the extra-peritoneal method. But there are tumors which can not be so treated; these Schroeder enucleates as described.

Hysterectomy for Fibro-myoma; the Stump being brought out at the Wound and attached there.—After the organ is exposed and all adhesions tied with double ligatures and divided between these, or broken loose where the double ligature can not be utilized, the elastic ligature should be thrown around the uterus at the cervix, the rubber passing under the ovaries and compressing the broad ligament against the cervix. This ligature is drawn tight and tied, the second part of the knot being over a coarse silk thread. When the last knot of the elastic ligature is made, the silk thread is tied around this to prevent slipping.

The fibroid is then held up and cut off above the elastic ligature. The stump is next grasped by strong forceps and trimmed. Sutures are then passed, first through the parietal peritonæum near the incision and then through the stump below the ligature, in such a way that when drawn tight the lower part of the incision will surround the stump just below the ligature, with the peritoneal surface of the incision fastened to that of the stump. Steel pins or skewers should be passed through the stump above the ligature.

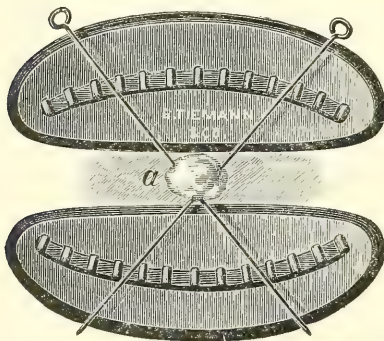


FIG. 665 R.—Sims's skewer-shields.

The sutures around the stump are then drawn tight, the wound closed as after ovariectomy, the stump dusted freely with iodoform, and the dressing applied. When the sutures are all inserted, the hard-rubber plates or shields (Fig. 665 R) should be placed between the ends of the skewers and the skin. The indications for pelvic drainage will be the same as after an ovariectomy. The cervical canal in the stump should be cut-retted before passing the steel pins; otherwise, a fistulous opening may persist through the vagina, uterine stump, and the line of incision. Frequently the fibroid is attached to the un-enlarged uterus, and has a narrow pedicle. In such a case, the uterus and appendages are left, and the new growth removed, forming the stump where the tumor joined the uterus.

Surgical Diseases of the Fallopian Tubes—Salpingitis.—Inflammation of the Fallopian tubes may demand surgical interference when peritonitis is precipitated, or when from occlusion the products of inflammation are retained, and the tube is distended, forming a cyst-like tumor.

The most prominent symptom of salpingitis is pain. When peritonitis does not exist, it is confined to the affected side. It is usually continuous, with exacerbations of severity, which are especially marked just

before, during, and after the menstrual flow. In some instances, when the flow is established, the suffering is less intense. The menstrual discharge is, as a rule, increased in quantity. Salpingitis, in the vast majority of cases, results from the direct extension of some inflammatory process from the uterus. Endometritis or metritis following gonorrhœa, abortion, normal parturition, or that resulting from a chronic inflammation due to malposition of this organ or other cause, are the chief conditions which precede this affection.

By direct palpation over the abdomen of the affected side, it will be seen that the muscles of this side are abnormally tense, and that acute pain is present confined to a limited and well-marked area, which corresponds to the normal position of the tube. In the vagina, a leucorrhœal discharge is usually observed, and diligent examination will reveal great tenderness near the cervix, upon the side involved. The uterus may be normally situated, but is laterally displaced when the tumor is at all large. With bimanual examination, often necessary under ether, there will be found an elastic, if not fluctuating, tumor, springing from one or the other uterine cornu, and directly attached to the uterus; perhaps bulging into the vagina; sausage-shaped when moderately large, but round when as large as an orange; often movable, but almost always with false attachments. This tumor may be but a part of a general inflammatory mass filling up the pelvic cavity and rendering fluctuation hard to obtain. In such a case, the uterus is fixed to this mass. As a rule, the tube is prolapsed, and drags with it the ovary, the latter being external to and above the cyst. In many cases the diagnosis is easy, but in others it is difficult.

Treatment.—When the diagnosis is satisfactorily determined, and the symptoms are urgent, removal by abdominal section is indicated. The preparation of the patient and for the operation are the same as for ovariectomy. When the peritonæum is opened, the tumor may be distinctly felt, and should be removed without rupture of the cyst-wall when this is possible. Adhesions to the neighboring organs will be found to exist, in a varying degree, in all cases. Some of these, which are vascular and of good size, require to be tied with double large-sized catgut ligatures and divided, while others may be torn off. The silk ligature should be passed around the tube, close to the surface of the uterus, tied, and the mass removed. The stump beyond the ligature should be carefully disinfected and seared with the actual cautery. If rupture should occur, or if there is a considerable amount of oozing, the Sims's drainage-tube should be used.

The Ovaries.—Removal of the ovaries may be necessitated on account of—1, cystic degeneration; 2, cirrhosis; 3, abscess; 4, cystic, and 5, solid tumors.

In cystic degeneration the ovary is enlarged, and the interior of the organ is filled with small cysts with dense, fibrous capsules. They can in some cases be seen through the investing membrane, and, if punctured, will give exit to a fluid usually clear, but at times brown, or even decidedly stained with blood. The tumor is elastic to the touch, usually

spherical, and rarely attaining as much as a diameter of two inches. The fimbriated extremity of the Fallopian tube is often adherent to the diseased ovary. In rare instances the broad ligament and tube may surround the cystic tumor. The left organ is affected more frequently than the right, for the same reasons as given for the more frequent occurrence of varicocele in the left scrotum (see VARICOCELE). The pathology of this affection is not yet definitely settled.

In *cirrhosis* the ovaries are usually small, and have a furrowed or withered appearance; occasionally they are found normal in size, or even slightly enlarged. The normal Graafian follicles are entirely destroyed in well-marked cases.

In more recent cirrhotic disease of these organs the cavities of the follicles are distended with a bloody fluid. This condition is almost always due to a connective-tissue hyperplasia, resulting from a subacute inflammatory process in the ovary.

In *abscess* of this organ it is enlarged, and may contain one cavity or several separate collections of pus. When the abscesses are small and multiple, the gross appearances of the organ are not unlike those of an ovary with cystic degeneration. Suppurating salpingitis (or pyo-salpinx) may be present with abscess of the ovary, and, in rare instances, by reason of fusion and rupture of the contiguous walls, there results a large single abscess. Multiple extravasation of blood may occur in abscess of this organ. If not relieved by operation, the pus may eventually find an exit through the vagina, bladder, or intestine. Adhesions, as a rule, occur between the ovary and one or more of the contiguous organs, or to the pelvic fascia.

Symptoms.—In *cystic degeneration* and *cirrhosis*, dysmenorrhœa is the most prominent symptom. It is more severe with the former, but is severe in the cirrhotic ovary. The pain usually precedes the menstrual flow from a few hours to several days, and in extreme cases may continue from one period to the next. It is usually referred to the groin of the affected side, and thence the painful sensations may radiate over the abdomen and down the extremity. Hysterical convulsions are very apt to be present in the more severe cases. The menstrual flow is scanty or normal in amount when the ovaries are cirrhotic; but with cystic degeneration the flow is generally increased, and hæmorrhage may be the most prominent and dangerous symptom. The uterus is apt to be slightly above the normal size, with the ovaries in cystic degeneration, and somewhat smaller when these organs are cirrhotic. Not infrequently retroversion is observed as a symptom of cystic ovary, in which case this last-named organ is prolapsed. The uterus is commonly free and movable, unless hæmatocele or peritonitis has occurred. If cystic, the ovary is easily felt, often low down in Douglas's pouch. If cirrhotic, it is hard to find. From clinical manifestations it appears that cystic degeneration is due to a degree of inflammatory action more severe than that which leads to cirrhosis, because peritonitis and pelvic hæmatocele more often accompany the former. Cystic and cirrhotic ovaries are always sensitive to pressure.

In *ovarian abscess* there is usually a history of gonorrhœa, puerperal septicæmia, an acute exanthema, or a severe attack of metritis or peritonitis. When the abscesses are small, the symptoms do not greatly differ from those of cystic ovaries; but when at all large, the patient has hectic fever and rigors. The pain in the pelvis is constant, but is liable to exacerbations. Repeated attacks of pelvic peritonitis follow each other. When the ovary is converted into one large abscess, and the tube is not affected, dysmenorrhœa is not a constant symptom, and there is an absence of the nervous phenomena observed in the other forms of ovarian inflammation.

The uterus is usually drawn to the affected side as a result of the pelvic peritonitis which usually accompanies these cases. The lateral fornix of the vagina is encroached upon when the abscess is large, and then fluctuation can be obtained. The abscess, whether large or small, is usually but part of the mass of inflamed tissue which occupies the pelvis on the affected side. The ovary is enlarged and low down. An abscess of the ovary does not often occur alone, and as the sole lesion of the pelvic organs and tissues, the symptoms which appear are partly due to the intercurrent diseases—salpingitis, hæmatocele, peritonitis, etc. When an ovarian abscess ruptures into the peritoneal cavity, a fatal general peritonitis is the result. If it opens into the vagina, it usually does so just below the cervix in the posterior wall, at the bottom of Douglas's pouch, where the vaginal wall is thinnest.

Treatment.—If the ovarian abscess is but part of a pelvic inflammation which unites together rectum, bladder, uterus, and broad ligament into one mass, and if the abscess is low down, fluctuation being obtained in the vaginal roof, it may be opened *per vaginam* and drained. But in cases of pelvic abscess it is better to try to remove them by abdominal section. Exploratory incision has but little mortality. A certain and positive knowledge of the condition of the parts in these cases can be obtained by abdominal section only, and by it only can a radical cure and extirpation of the abscess be effected. These are the most difficult cases the surgeon has to deal with, especially when associated with pyo-salpinx or hæmatocele. The drainage-tube should be employed whenever rupture of the abscess occurs in the efforts at removal, and when there is much oozing after the adhesions are broken up. The operation is similar in its *technique* to that of removal of the tubes. Cystic and cirrhotic ovaries are to be removed by abdominal section when, all conservative measures having failed, the patient's health or reason is seriously threatened. The objection of sterility can not be maintained, for these women are already sterile. The operation may also be performed in cases of acute mania and epilepsy which appear to be due to ovarian disease and which are incurable by other means. The operation is simple. An incision large enough to admit two fingers is made in the median line. The lower angle of this wound should be about two inches above the os pubis. The ovary and tube are freed from false attachments, brought toward the incision, and the broad ligament transfixed close to the uterus with a double ligature. The ligatures

are crossed—one is tied above the tube close to the uterus, the other below the ovary; the tube and ovary cut off, and the ligatures cut short. The abdominal wound is closed as heretofore given. Drainage is rarely indicated.

Large Cystic Tumors of the Ovary and Broad Ligaments.—Cystic tumors of the ovary are occasionally unilocular. In the vast majority of instances they are multilocular. The pathology and pathogenesis of these neoplasms are not yet definitely settled, and, since a discussion of the various theories advanced is scarcely permissible in a text-book, the student is referred to the various standard works upon pathology.

The most common form of ovarian tumor—the *cyst-adenoma*—is always multilocular. The surface of such a tumor is glossy, often silver-white. The sac is usually firm, its contents being a thick fluid, with a grayish-brown or reddish tint. The outline of the cyst may be perfectly symmetrical and round; or it may have one main cyst, and numbers of smaller ones springing from it; or two or three cysts of about equal size may constitute the entire mass. But, be the shape what it may, secondary cysts will always be found in some part of the tumor. At one or more points the cyst-wall may be exceedingly thin or softened as a result of the rupture of inter-cystic walls, those of the secondary cysts being thinner than that of the larger. Softening of the wall may also occur when the neoplasm is malignant; or as a result of interference with its nutrition from twisting of the pedicle; or from suppuration in the cyst-wall. In exceptional instances in old cysts there sometimes exists a communication between the cyst-cavity and the bowel or bladder as a result of necrotic changes where the two have become adherent.

In size cysto-adenomata of the ovary may vary from a few inches in diameter up to those of enormous size, weighing many pounds, and filling the entire abdomen. The veins lie both superficially as distinct vessels and deeply in the cyst-wall as sinuses; the arteries are more deeply situated and are large. This tumor may be generally adherent to the peritonæum and other organs with which it comes in contact, or connected at various points by isolated bands. In rarer instances no adhesions may be met with. The pedicle of an adeno-cystoma may be attached to both sides of the uterus, two distinct tumors having met and coalesced. At times the tumor derives its nourishment from bands uniting it to the abdominal parietes or viscera, its own pedicle having been twisted off.

A form of multilocular cyst, connected with the ovary, known as "*Rokitansky's tumor*," has been observed in a few instances. It consists of a series of cysts containing a clear fluid. The cysts hang in bunches and are connected with each other by delicate fibrous bands. The entire mass does not usually reach a size larger than the fist.

Dermoid cysts are not altogether infrequent in the ovary. These tumors have thick walls, are dark-colored, are filled with a dark fluid in which are found particles of hair, teeth, bone, etc. They may be multilocular, or they may contain but one cyst.

Hanging from the fimbriated extremity of the Fallopian tube, or just beneath it, is also found a small, thin-walled cyst, with clear contents, called by some the "hydatid of Morgagni." If examined carefully while it is floated in clear water, it will be seen to be a continuation of the horizontal tube of the *parovarium*.

Cyst of the Broad Ligament.—There is also met with a cyst of considerable size, with perfectly clear contents and very thin walls, which is sometimes pedunculated, but generally with a broad attachment located either upon the broad ligament or the uterus. A small cyst of a similar nature may spring from the covering of the Fallopian tube and be pedunculated, or arise just beneath the Fallopian fimbriæ, and be either sessile or pedunculated.

Solid Tumors.—Fibro-myomata appear as smooth, firm bodies. They do not, as a rule, contract adhesions with neighboring structures.

Sarcomata have about the same clinical appearance, except when very vascular, in which state they are softer and more elastic than are fibro-myomata. Carcinomata of the ovary are very nodular, and when large they may contain one or more cavities in their interiors. Secondary deposits in other viscera are found with these tumors. The symptoms of all solid tumors are so obscure that the exact character of any of these neoplasms can scarcely be determined, excepting by microscopic examination.

Symptoms.—Tumors of the ovary are usually first noticed upon one side of the pelvis. The ordinary cysto-adenoma is not painful until it is so large that it presses upon the pelvic and abdominal viscera. If inflammation supervenes from any cause, pain is a prominent symptom. Amenorrhœa is the rule, although in a certain proportion of cases menstruation is normal. Menorrhagia is rare. If left without interference, pressure upon and displacement of the neighboring viscera is the rule, and, if peritonitis does not ensue, death ultimately results from asthenia. Not infrequently adhesions are formed between the bladder and the neoplasm to such an extent that, as the tumor grows, the bladder is dragged upward to the neighborhood of the umbilicus. In large tumors, dyspnoea, œdema of the lower extremities, enlargement of the superficial abdominal veins, and nephritis occur as a result of pressure.

Upon examination, it is usually easy to detect the presence of the tumor. The uterus lies in front of the cyst, or is displaced laterally if the tumor be large enough to crowd it out of its normal position. The uterus is not increased in size, and is movable independently of the neoplasm. The latter is an important feature in differentiation, and may be best determined with the aid of the elevator carried into the uterus. When the cyst is large, the uterus is dragged high up and fixed against the symphysis pubis. The bladder may lie over the front of the tumor as high as the umbilicus. But when the tumor is so large as to have completely risen out of the pelvis, the bladder reaches, even when not adherent to the cyst, a point somewhat above the suprapubic notch. The enlargement of the cyst gives to the abdomen a rotundity not seen with distention from ascites alone. Ascites commonly coexists with

large cysts. If not large and non-adherent, the tumor can be raised out of the pelvis without the uterus. It may also be depressed in the pelvis. When the secondary cysts are large and project from the surface of the main cyst, they may be quite readily distinguished. If one hand is laid flat upon one side of the mass and the other side is given a sharp tap with the fingers, the fluid character of the contents of the neoplasm may be easily appreciated. When the walls of the tumor are very thick and the distention marked, fluctuation may not be felt.

In *solid ovarian neoplasms* pain is apt to be present early in the history of the growth, and the general health of the patient may show signs of deterioration before there is any marked increase in the size of the tumor. This is especially true of malignant new formations.

Fibro-myoma of the ovary is so often associated with similar changes in the uterus that the slight menorrhagia which occasionally accompanies these cases may reasonably be ascribed to uterine hyperplasia. Upon abdominal palpation, with vaginal exploration, a hard and usually movable tumor may be appreciated. At times it is attached to the surrounding structures to such an extent that mobility is absent. The uterus is not enlarged, is often displaced backward, and is generally freely movable with small tumors. When malignant, the tumors are of rapid growth. Ovarian fibro-myoma grows slowly, gives little pain, never immediately influences the general health; is generally smooth, or with but a few nodules; not very sensitive, and is usually freely movable independently of the uterus. Dermoid tumors may appear clinically as cystic or solid, according as their fluid or solid contents predominate. Adenocystomata and dermoid cysts are occasionally met with in young children.

LAPAROTOMY FOR THE REMOVAL OF TUMORS OF THE OVARY AND FALLOPIAN TUBE.

The removal of a tumor of the ovary, broad ligament, or Fallopian tube, cystic or solid, is performed as follows:

Preparation of the Patient, and Operation.—For several days before the operation the patient should be put on a fluid diet, and have a movement of the bowels every day for at least a week. For twelve hours before taking ether, the stomach should be kept perfectly free from any solid food or milk. About two ounces of whisky in an equal quantity of water should be taken a half-hour before the anæsthesia is commenced. All the details of the antiseptic method heretofore given should be carefully carried out. In hospital practice, and in the dusty season of the year, the carbolic-acid spray should be kept going in the operating-room for a half-hour prior to the entrance of the patient. The pubes and abdominal wall through which the incision is to be made should be shaved and disinfected, and the bladder emptied before the inhalation is begun, unless the nervous condition of the patient renders it advisable to postpone this part of the preparation for the operation until she is unconscious. The legs, arms, and chest should be carefully wrapped in warm flannels or blankets. The patient should rest upon

the back, with the legs fully extended, or, as many operators prefer, with the sacrum resting near the end of the table, and the feet in a chair, with the thighs abducted and held by an assistant seated, between the feet, in the chair. The incision should be in the median line, about three inches in length, and should commence about five inches above the os pubis. The recti muscles should be separated and all bleeding arrested by catgut ligatures before the peritonæum is opened. When the parietal layer of the peritonæum is reached, catch a small point of this membrane with a tenaculum or forceps, grasp this point between the thumb and finger, to make sure that no omentum or intestine is picked up, and make a small incision with the scissors. Through this opening introduce the broad-grooved director, and further divide the peritonæum. Two fingers should now be carried into the abdomen, and a careful exploration made. A blunt, round instrument (a No. 20 United States urethral sound will suffice) carried in and swept over the tumor will demonstrate the presence of any adhesions between it and the anterior wall of the abdomen. If the tumor is free, drag it up to the incision; and, if it is cystic, hold it so that with the aid of sponges placed around the margins of the incision none of the fluid can escape into the peritoneal cavity. Introduce the large trocar and evacuate the fluid contents. As the sac is being emptied, drag it farther out of the incision, and, when all the fluid escapes, free the tumor of all adhesions to the intestines or other structures. All large adhesions may be tied with the double catgut ligature, and cut between, while small adhesions, or those so situated that the ligature is impossible, should be torn through. Great care is required in separating the sac from the wall of the intestine. As soon as the pedicle is freed, the sac should be grasped with a long-jawed pedicle forceps (Spencer Wells's sac-forceps) and cut away. The pedicle should be transfixed near its middle with an aneurism-needle armed with a large double silk ligature and the two threads drawn through. In tying the threads on either side of the pedicle cross them, as shown in Fig. 666, and tie firmly. If the pedicle does not bleed, the ligatures should be cut short. The ovary of the opposite side should be examined. The cavity of the peritonæum should be carefully washed out with Thiersch's solution, with the aid of sponges on holders, and the wound closed as directed in laparotomy for intestinal obstruction. If a solid

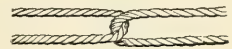

FIG. 666.—Showing the manner in which the two threads of a double ligature should be crossed in the center of the pedicle.

tumor is encountered, and when a cystic tumor has such thickened walls that it can not be readily brought out at the wound, the incision may be enlarged. It is, however, advisable to keep the abdominal wound as small as possible when the small size of the opening does not interfere with the safe manipulation within the abdomen. *Dermoid cysts* are usually so solid that they are removed without an effort at tapping.

A *cyst* of the *broad ligament*, in which there is no pedicle, requires to be stripped out of the capsule, the capsule stitched to the margins of the abdominal incision, the cyst-wall beyond the line of sutures cut away, and a drainage-tube inserted.

The tube of Dr. H. Marion-Sims is a most satisfactory apparatus for draining the pelvis after laparotomy for any purpose for which after-drainage is indicated (Fig. 667).

“It consists of a large and a small tube made of hard rubber.



FIG. 667.—Dr. H. Marion-Sims's drainage-tube.

The smaller tube is inside of the larger one, running along the posterior wall and terminating about an eighth of an inch from the bottom. The large tube is perforated on the sides and curved at the top, so that, when in the abdominal wound, the top of the tube projects nearly over the symphysis pubis. To this a rubber tube of sufficient length to carry the fluid used in washing out the abdomen into a convenient vessel is attached. The injection-fluid is forced in by a Davidson's syringe, the tube of which is slipped over the end of the small pipe *B*; or a fountain irrigator may be preferred. As the wound fills, the fluid escapes through the larger tube, and the irrigation should be continued until the water comes out clear. By the siphon action of this apparatus the discharge from the greater tube will be continued after the injection is stopped. Just as the stream is about to stop, the tubes should be closed, and in this way the entrance of air is prevented. The lower end,

C, of this tube should be placed in the most dependent portion of the cavity, usually in Douglas's *cul-de-sac*.”

The greatest care is required in employing drainage in the peritoneal cavity, especially during the first twenty-four hours, until adhesions form, which practically close the peritoneal opening. The end of the drain should be well covered with sublimate gauze, and during the dressings for the first twenty-four hours it would be advisable to use the carbolic-acid spray, to prevent the possibility of infection.

CHAPTER XXI.

DEFORMITIES.

DEFORMITIES OF THE SPINAL COLUMN.

ANY noticeable deviation from the normal curvatures of the vertebral column constitutes a deformity. They are *congenital* and *acquired*, *temporary* or *permanent*. They are divisible into two great classes, namely, those due to lesions of the column (bones or cartilages), and those due to lesions of the soft tissues (muscles and ligaments). To the former belong dislocations, fractures, destructive ostitis, and spina bifida; to the latter, muscular torticollis, lateral or rotary-lateral curvature (*scoliosis*), stoop-shoulder (*cyphosis*), curvature from pleuritic adhesions, collapse of the lung, contractions of cicatrices following burns, scalds, phlegmon, etc.

Lateral and Rotary-lateral Curvature.—Simple lateral curvature of the spine—that is, a bowing to one side without rotation of the vertebræ—is extremely rare. It may occur in any portion of the column to a slight extent, although rotation is very apt to take place with the curvature. It is more often observed in the cervical region than elsewhere, and is known as *torticollis*, or “wry-neck.”

The causes of wry-neck are—1, loss of parallelism, or balance of power between opposing muscles, and 2, cicatricial contractions.

Muscular torticollis is by far the most frequent form, and, in common with all deformities resulting from lesions of the muscles, the right side is usually affected. The right sterno-mastoideus muscle is the principal seat of tonic spasm, causing this organ to stand out in relief; the right ear is drawn down toward the clavicle of that side, while the chin points well to the left (Fig. 668). The trapezius not unfrequently is contracted with the mastoid muscle. The splenius, scalmi, platysma myoides, or levator-anguli scapulæ, are less frequently involved. Loss of equilibrium between the muscles of the two sides occurs chiefly in chlorotic patients in which the normal muscular tone is greatly diminished, rendering the organs of the left (or



FIG. 668.—Muscular torticollis.
(After Sayre.)

non-preferred) side unable to resist the more developed muscles of the right half of the body. In other cases the lesion may be situated in the central nervous ganglia, or in the track of the nerve.

Inflammation of the muscular substance (myositis), or of the tendons or sheaths of the muscles, is an occasional cause of wry-neck. Any inflammatory process may lead to shortening of the muscles, and to contractions in the fasciæ and connective tissues of the neck. Muscular torticollis is met with most frequently in the young, may exist at birth, is seen in females oftener than in males, and in this class of cases is apt to occur about the age of puberty. In some instances, in addition to the tonic spasm of the muscles involved, a clonic or irregular convulsive movement occurs.

Diagnosis.—The recognition of torticollis is usually free from difficulty. The elimination of caries, dislocation, fracture, and wry-neck caused by cicatricial contractions, is determined from the history of the case and by inspection and manipulation.

When one sterno-mastoid muscle is contracted, the chin is pointed to the opposite side, and the occiput made to approximate the clavicle of the side corresponding to the contracted muscle. The splenius capitis draws the mastoid process downward and backward toward the spine of the seventh cervical vertebra.

The *prognosis* in muscular torticollis is usually favorable—less so in clonic than in tonic muscular spasm. In wry-neck due to contractions of the fasciæ, tendons, etc., the deformity is with difficulty relieved.

Treatment.—*Chlorosis*, or any dyscrasia, should be treated by tonics and internal medication, by properly selected diet and out-of-door life. The development of the muscles of the left (or weaker) side is essential. Kneading, massage, and electricity will be found useful adjuvants. Mechanical appliances should be used in overcoming the contractions in the offending muscles. Artificial muscles, composed of elastic bands or rubber tubing, more nearly fulfill the indications. The origin and insertion should correspond to that of the normal muscle. A thoracic belt or jacket of plaster of Paris, leather, or silicate of soda, properly adjusted, will serve for the points of fixation of the lower end of the elastic material. The upper insertion near the occiput is best secured

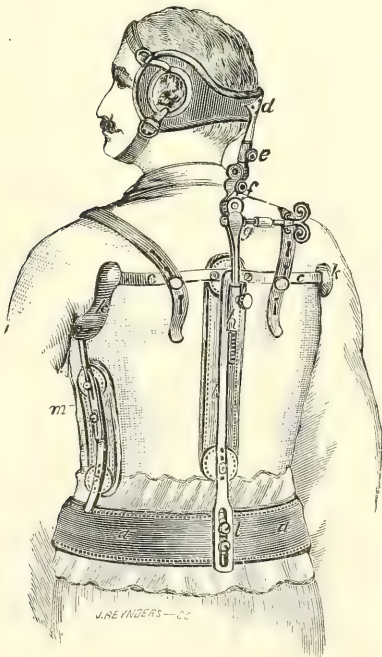


FIG. 669.—Reynders's apparatus for the correction of muscular torticollis.

by a stall carried around the head above the ears and across the forehead. In order to prevent it from slipping, the portion which rests

upon the skin of the forehead should be made of strong adhesive plaster (as advised by Prof. Sayre). The tension on the rubber muscle may be increased from day to day, if necessary. If this method does not succeed, the apparatus of Reynders & Co. (Fig. 669) should be tried. The mechanism is well shown in the accompanying cut, the correction of the deformity being effected by means of a series of joints situated at the back of the neck, which are worked by a key, and can be fixed at any angle of flexion and rotation.

The operative procedures include stretching or division of the muscle or muscles affected, tenotomy, neurectomy, division of the fascia, and the free dissection of cicatricial tissue. Of these operations, tenotomy of the sterno-mastoideus is most frequently demanded. A puncture is made a little to the outer side of the clavicular tendon of this muscle, and a long, probe-pointed tenotome slid flatwise (the cutting-edge downward) upon the outer anterior surface of the clavicle. As soon as the point of the instrument has passed between the clavicular and sternal origins, the edge is turned outward, making the muscle tense, and the tendon is divided subcutaneously. The sternal origin is divided by an additional puncture. After tenotomy the prothetic apparatus should be employed until recovery is complete. In dividing the body of this muscle, or the trapezius, splenius, or levator-anguli scapulæ, the open method should be followed.

Violent and sudden stretching of the muscles, with or without anæsthesia, is not advisable. Exsection of that portion of the spinal accessory nerve which is supplied to the sterno-mastoid and trapezius muscles is occasionally performed in order to paralyze the permanently contracted muscles. It is preferable to a simple division or to stretching of the nerve, for the reason that a divided nerve may reunite, and, after stretching, the function of the nerve is only temporarily impaired.

In order to expose this nerve, make an incision about four inches in length, following the posterior border of the sterno-mastoideus muscle, and commencing on a level with a point half-way between the lobule of the ear and the angle of the jaw. The fibers of the muscle should be sought, and, recognizing these, the posterior edge is exposed. By keeping the wound dry, and working close to the under surface of the muscle, the vessels will be avoided and the nerve will be seen running obliquely downward and outward, and passing into the muscle. One or two superficial nerves are sometimes seen radiating from the cervical plexus. From one half to one inch of the nerve should be excised. After this operation, mechanical treatment should be instituted for a short time.

In torticollis due to cicatrices, simple division of the contracting tissue affords only temporary benefit. The only legitimate method is to dissect out the offending tissue, slide sound skin over the wound thus made, and use mechanical treatment until the deformity is overcome.

Deformities due to *dislocations* and *fractures* of the cervical vertebræ have been considered, and those resulting from *caries* of this portion of the spine will be given hereafter.

Lateral and Rotary-lateral Curvature of the Dorso-lumbar Spine.—Simple lateral curvature of the dorso-lumbar spine is exceedingly rare. It is complicated in almost all cases by rotation of the vertebræ upon each other, and in deformity here from muscular causes, the rotation precedes the lateral curvature.

Lateral curvature is usually caused by an inequality in the length of the lower extremities. Fig. 671 was taken from a boy in whom the right extremity was one and a half inch shorter than the left. With both soles on the same plane, marked lateral curvature (convexity to the right) was observed. By placing the foot of the short side upon a book of the required thickness, the deformity disappeared (Fig. 672).



FIG. 670.—Lateral curvature after recovery from lumbo-sacral spondylitis.

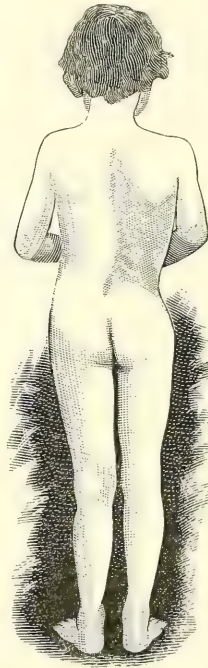


FIG. 671.




FIG. 672.

Inequality in the length of the lower extremities is not uncommon, even in individuals who have not suffered from injury or disease. A difference of as much as one inch has been noted, while from one half to one fourth inch is quite common.

Cicatricial contractions on one side of the chest or abdomen, as after extensive burns or in chronic pleuritic adhesions with collapse of the lung, also produce this deformity. The treatment will be considered with that of rotary-lateral curvature.

Rotary-lateral Curvature.—Rotation of the bodies of the vertebræ upon each other, and upon the sacrum and subsequent or simultaneous lateral curvature, is one of the most difficult deformities to correct. The chief cause is loss of the normal equilibrium of the muscles of the two sides of the trunk. The tendency to deformity is increased by the habit

of sitting sidewise at the table or desk, with one shoulder drooping while the other is elevated. A large majority of those affected are chlorotic girls, between thirteen and eighteen years of age. This deformity is occasionally met with in porters or laborers who habitually carry heavy weights upon one shoulder. The rotation most frequently commences in the lumbar region. The spines twist to the right, while the anterior aspect of the bodies of the vertebræ are made to look toward the left. The convexity of the curve is to the left, the right shoulder is prominent, the apex tilted outward, the angles of the ribs on this side project abnormally, and there is a folding in or wrinkling of the skin between the iliac crest and the thorax (Fig. 673).

The chief agent in this distortion is believed to be the latissimus-dorsi muscle. Acting upon the tips of the long spines of the lumbar vertebræ from its insertion in the humerus (and indirectly through the pectoralis major, from the clavicle and sternum), the spines are twisted to the right, causing the rotation of the bodies to the left; the shoulder-blade is tilted outward, and the ribs are bent under the contraction of this long and comparatively powerful muscle.

In some instances the abdominal muscles take part in the unilateral contraction, while in others the deformity commences with the rotation of the dorsal vertebræ by the action of the serratus-magnus and rhomboidei muscles. No matter where the primary curve takes place, a second or compensatory curve follows in all chronic cases.

The *diagnosis* of rotary-lateral curvature will depend upon the prominence of the shoulder-blade, bulging of the ribs, and the approximation of the crest of the ilium and thorax of the right (or affected) side. Caries of the spine may be eliminated by the absence of abnormal temperature, freedom from pain when direct pressure is made from the head along the vertebral column, and absence of symptoms of compression of the cord or nerves in the intervertebral notches. Psoas abscess is present in a certain proportion of cases of ostitis of the vertebræ.

In *simple lateral* curvature the ribs are not projected, as when rotation occurs, nor is the tip of the shoulder-blade so prominent.

The *prognosis* varies with the character of the lesion. In recent lateral curvature, due to inequality of length in the extremities, it is favorable. In rotary-lateral curvature, within the first few months of the lesion, a cure may be effected. In old cases, while the deformity may be arrested, it is difficult and often impossible to restore the normal contour of the spine and ribs.

Treatment.—When the lesion is due to loss of equilibrium in the

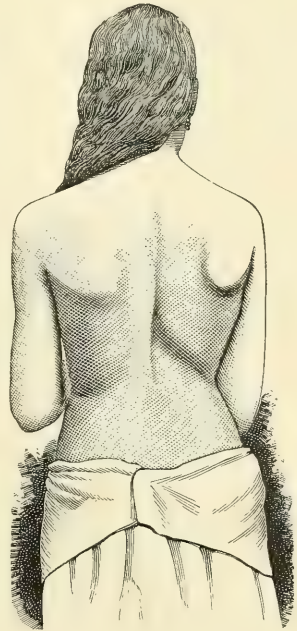

FIG. 673.—Rotary-lateral curvature in a girl fifteen years of age.

muscles of the two sides, especial attention should be directed to the development of the organs of the weaker side, and at times it is necessary to impair the nutrition of the muscles of the stronger half of the

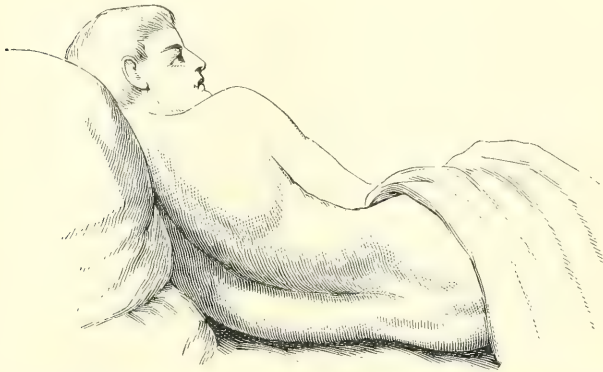


FIG. 674.—Patient lying in a position to overcome contraction of the muscles of the *left* side of the abdomen and thorax. (After Reeves.)

trunk. When the deformity is on the right side, the muscles of the left arm and side should be exercised by the use of the dumb-bells, elastic strap, swing, or horizontal bar. It is often advisable to place the right arm and hand in a sling, to prevent the further development of these muscles. Massage or kneading, confined to the left half of the body, and the gal-

vanic current to the same region two or three times a week will be advisable. Tonics, judicious feeding, and out-of-door life are essential features of treatment. The patient should be directed to sit squarely upon

the buttocks, and not to droop or loll to one side. In reclining, the body should be placed in such a position that the offending muscles are put upon the stretch (Fig. 674). The deformity is temporarily overcome by the employment of Wolff's cradle (Fig. 675). The belt passes over the projecting ribs and shoulder-blade, thus

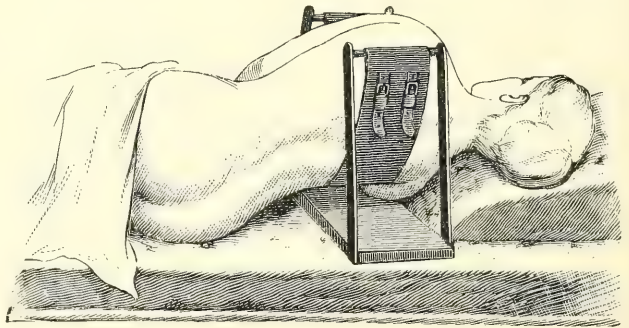


FIG. 675.—Wolff's suspensory cradle. Patient in position when the contraction is on the right side (with the right shoulder-blade and ribs projecting. (After Reeves.)

bringing the weight of the trunk upon these parts, while gravity aids in overcoming the curvature in the lumbar region.

In a certain proportion of cases, mechanical support of the thorax is indicated, especially in those cases where from muscular weakness it is almost impossible to hold the spine erect. For this purpose the plaster-of-Paris jacket or the perforated corset may be used. The latter (Figs. 676, 677) I have found very satisfactory. It is to be commended, for the reason that it can be readily removed at night, and is more cleanly than a permanent plaster jacket. When the gypsum is applied it should be split down the front, taken off and fixed for lacing so that it may be removed when necessary.

This perforated corset is made as follows: A plaster-of-Paris jacket is applied as hereafter directed, and as soon as this hardens (in from ten to thirty minutes) it is split down the median line in front, removed from the body, and the cut edges placed and held in apposition by a bandage carried around and over the entire jacket. This shell is to be used as a mold in which a cast of the deformed thorax is to be made. It is thoroughly greased on its inner surface, placed upon the floor, and filled with stiff plaster-mortar. When this hardens, the shell is removed, leaving an exact cast of the thorax, upon which the corset is to be built.

The materials needed are white glue, ordinary muslin rollers, flat




FIG. 676.—Corset made after Vance's method.



FIG. 677.—The same, applied.

spring steel about one eighth of an inch wide and very thin, and one yard of Canton flannel. Place the flannel with the soft plush next to the plaster, and stitch this tightly to the model, so that it is not wrinkled. It should be sewed only along the middle line in front. The glue should now be dissolved in warm water. Strips of bandage about two feet long and two inches in width are dipped in the glue and laid on the flannel which is around the model. As soon as a single thickness has been applied, strips of the steel wire, cut not quite as long as the corset, are placed one inch apart over its entire surface, and held in place by a string wound around as they are laid on. A long, dry roller is next carried around the model from above downward, and drawn so tight that the steel springs are made to conform exactly to the surface of the corset. Upon this two additional layers of the short strips of roller dipped in glue are laid. The corset should be left for several hours in the hot sun, or by a fire, until it is thoroughly dried. It is then split down the front, removed, and the edges bound with chamois-skin. Hooks for lacing should be fastened along the edges

in front. Perforations may be made between the springs with a wadding-punch. This apparatus, when properly made, fits accurately about the body in the most favorable position for the correction of the deformity. It can be removed at night upon retiring and for bathing, changes of clothing, massage, and electricity. It is lighter and cleaner than the plaster-of-Paris jacket. When the necessary materials can not be had, the plaster jacket should be employed.

Operative interference in muscular scoliosis is rarely called for. In extreme cases, when the latissimus dorsi of one side is greatly shortened and increased in development, correction of the curvature may be expedited by the subcutaneous division of this muscle.

When lateral or rotary-lateral curvature of the spine results from inequality in the length of the lower extremities, the first indication in treatment is to elevate the shoe of the short side, and thus bring the plane of the iliac crests at a right angle to the axis of the vertebral column. If the deformity is not entirely corrected by this plan, the measures just detailed should be also employed.

When the deformity is caused by superficial cicatricial contractions, their division is essential. In pleuritic adhesions, with collapse of the lung, the treatment given for rotary-lateral curvature due to muscular asymmetry should be adopted.

Anterior and Posterior Curvature of the Spine.—Anterior curvature, or “stoop-shoulder,” usually occurs in the dorso-cervical regions; occasionally the entire column is involved. It may be caused by—1, partial or complete paralysis of the erector muscles of the back; 2, tonic spasm of the abdominal muscles; 3, from inadvertence, as in the habit of allowing the shoulders to droop forward, with or without the carrying of burdens; 4, cicatricial contractions in the anterior thoracic and abdominal regions; 5, heredity.

Complete paralysis of the muscles of the back is exceedingly rare. Unilateral paresis is not altogether uncommon. The most frequent condition is one of general impairment of muscular tone, the head and

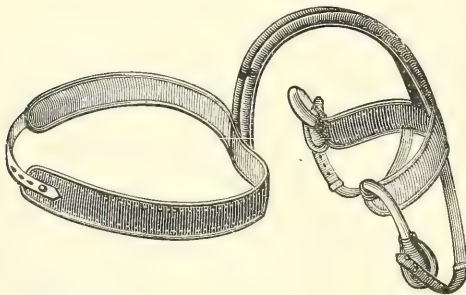


FIG. 678.—Nyrop's spring-brace. (After Reeves.)

upper spine gravitating forward as the muscles yield, until the posterior ligaments are elongated and the anterior margins of the intervertebral disks narrowed by compression. The habit of carrying a heavy burden upon one shoulder is more likely to induce rotary-lateral curvature than *cyphosis*. The indications are to correct the deformity by the use of braces, and to increase the tone

of the muscles the nutrition of which is impaired.

To meet the former, in mild cases a double elastic brace, such as is shown in Fig. 678, will be sufficient. Massage, electricity, tonics, and out-of-door life are also essential features of treatment.

Posterior curvature of the spine, *lordosis* or "sway-back," is far less frequent than the condition just described. It occurs almost always in the lumbar region. In the later months of pregnancy it is a common condition, and is met with in individuals with unusual development of the stomach and abdominal viscera, or in cases of chronic abdominal tumor (fibroid, etc.).

Spondylitis.—Destructive ostitis of the vertebræ, commonly known as Pott's disease, occurs usually between the third and fifteenth year of life. In exceptional instances it is observed prior to three years of age, while not more than one fifth of all cases occur after the fifteenth year. It is therefore eminently a disease of the growing period, when rapid nutritive changes are taking place in the bones.

While no portion of the spine is exempt, the disease is much more frequent in the dorsal vertebræ, which are involved in about two thirds of all cases. The lumbar and cervical portions of the column are about equally liable to destructive ostitis. Occipito-cervical disease is rare. Ostitis in the lower cervical region is apt to involve the upper dorsal by extension, and the same is true of ostitis of the lower dorsal in their relation to the lumbar vertebræ. Lumbo-sacral disease is not altogether uncommon. Destructive ostitis of the spine is divided into *occipito-cervical*, *cervical*, *cervico-dorsal*, *dorsal*, *dorso-lumbar*, *lumbar*, and *lumbo-sacral*, according to the recognized location of the disease.

Causes—Predisposing and Exciting.—Any disturbance of the normal process of nutrition in the tissues in general—as in the syphilitic, tubercular, gouty, or rheumatic dyscrasia—or the impairment of vitality resulting from any acute disease, predisposes to inflammatory changes in the bones, and especially in the cancellous tissue of the vertebræ.* These bones, together with the sternum and ribs, are the last to take on the changes which occur in the adult bones—the bones of completed growth and full development. In the pathology of ostitis it has been pointed out that the medulla of these bones remains in its red or embryonic condition long after that in the other bones has undergone the adult change, and that, consequently, they are for a prolonged period liable to accidents consequent upon rapid nutritive changes, and especially to capillary rupture and extravasation.† How much more liable to accident and disastrous inflammation are these structures when they are weakened in the general impairment of nutrition? The chief exciting cause is violence, either directly or indirectly applied. A fall upon the feet, buttocks, or hands, or violent flexion or extension of the vertebral column, a blow upon the sternum or ribs, or a penetrating wound, may each lead to destructive ostitis. Carcinoma, sarcoma, and aneurism may also cause destruction of one or more vertebræ. It is believed that as

* "Les tubercules des os s'observent habituellement dans les tissu spongieux des os longs et dans les os courts, mais leur siège de prédilection est le corps des vertébrés, le sternum et les côtes."—CORNIL ET RANVIER.

† "Les os des jeunes sujets et ceux qui chez l'adulte contiennent encore la moelle fœtale comme le sternum et les corps vertébraux sont particulièrement exposé aux troubles pathologiques nutritifs ou formateurs."—CORNIL ET RANVIER.

between the predisposing and exciting causes of Pott's disease, the former deserve by far the greater consideration.

Clinically, destructive ostitis is met with in two forms—the dry and the suppurative. The latter variety is more common. In dry ostitis the bone-cells undergo granular metamorphosis, and, together with the inorganic salts of this tissue, are absorbed. Suppuration, if present, is limited, and the products of inflammation undergo fatty degeneration. In these cases the breaking down of the bodies of the vertebræ, to the extent of marked deformity, may occur without recognized febrile movement. In the suppurative form the destructive process is more rapid, and is accompanied by the formation of a variable quantity of embryonic tissue, the bone breaks down in bulk, and particles varying in size appear in the pus which results from the inflammatory process. The earliest pathological change in such cases is in the cancellous tissue of the body. In rarer instances the lesion commences as a synovitis in the costo-vertebral or interarticular joints, whence the disease may invade the intervertebral disks and bodies. Primary inflammation of the intervertebral fibro-cartilage is believed to be very rare. As the destructive process continues, the cancellous tissue of the body, and chiefly of the anterior portions of the column, breaks down (Fig. 679), causing abnormal

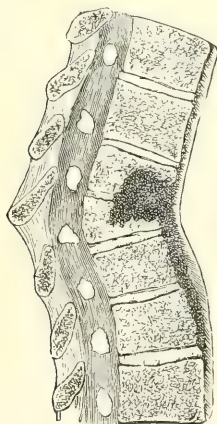


FIG. 679.—Destructive ostitis of the anterior portion of the bodies of the vertebræ. (After Noble Smith.)

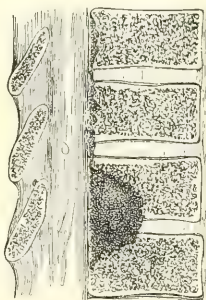


FIG. 680.—The same process in the posterior portion of the bodies of the vertebræ. (After Noble Smith.)

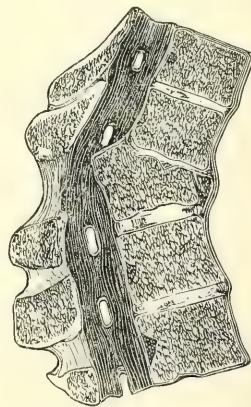


FIG. 681.—Deformity resulting from fracture of a vertebra. (After Noble Smith.)

curvature, with sharp projection of the spinous processes. The angular deformity is less apt to be present when the disease attacks the posterior portion of the body, where the superincumbent weight in great part falls upon the articular processes (Fig. 680).

Symptoms.—The clinical history of Pott's disease may be divided into two stages: The *first stage* includes all the phenomena which occur up to the time when deformity is recognized; the *second stage* embraces all the changes met with after deformity. The usual symptoms of the first stage are pain and muscular rigidity, with varying exacerbations of temperature. *Pain* may be elicited when the patient assumes the erect posture, by direct pressure upon the spines of the vertebræ involved,

and by concussion of the column transmitted from the head downward. When the bodies alone are involved (the usual condition) it may be lessened or made to disappear entirely by suspension of the patient from a portion of the column above the lesion; by bending the spine backward, thus throwing the weight upon the healthy articular processes; or by laying the patient face downward across the surgeon's lap, and making extension by separating the knees.

Muscular rigidity is recognizable in a majority of instances, and in children may be observed as a symptom of pain, when the presence of pain is denied. Fixation of the dorsal muscles is evident in the stiff and unusual manner in which the back is held as the patient moves about, and in the awkward posture assumed while sitting down. If directed to bend the vertebral column, as in stooping to pick up something from the floor, the movements are cautious and constrained, altogether lacking in the celerity and suppleness which are seen in flexion and extension of the vertebral column in health. In the earlier stages pain is dull and steady in character, and is usually local, being confined to the neighborhood of the part affected.

Elevation of temperature may be present at any stage of Pott's disease. It is, as a rule, the index of the extent and rapidity of the inflammatory and destructive processes. The thermometer may register from the normal as high as 101°-102° F., and only in exceptional instances as high as 104°. In a fair proportion of cases in the early stages, and especially in the dry form of ostitis, no elevation of temperature can be detected.

The *second stage* of the disease, that of deformity, may be present in the course of a few weeks after the appearance of the first stage, or several months may elapse. All of the symptoms of the preceding stage are present in the second stage of Pott's disease. If proper treatment has not been instituted, interference with the functions of the cord at and below the seat of lesion, or of the nerves which pass out between the diseased vertebræ, is apt to occur, from displacement of the bones or as a result of inflammatory products pressing upon the spinal cord and nerves. Paralysis of motion and sensation, in a varying degree, occurs in a certain proportion of cases.

When deformity occurs the convexity of the curve is posterior in about 95 per cent of all cases. The "knuckle" may consist of a single spinous process (Fig. 328), or several spines may project, as in Fig. 670.

The degree of deformity depends upon the location of the disease, its extent, and in part to general relaxation of the erector muscles. It is greater when the lower cervical and upper dorsal vertebræ are involved (Fig. 681 A). The formation of pus and the resulting abscess and sinuses belong chiefly to the last stage of ostitis of the spine. The abscess may travel along the psoas muscle, opening near the middle of the groin above or beneath Poupart's ligament, the pus may escape through the inguinal canal, over the iliac crest, or through the sacrosciatic notch; or it may be arrested at a higher point and escape recognition, unless careful examination is made under ether narcosis.

Spinal abscess is usually single, occasionally double. When occur-

ring in the upper dorsal region it may be arrested by the diaphragm, or pass behind this into the sheath or fascia of the psoas muscle. Abscess in osteitis of the bodies almost always travels downward on one or the other side of the antero-lateral aspect of the spine. When the articular processes or laminae are involved, the pus may penetrate the dorsal muscles and point posteriorly.

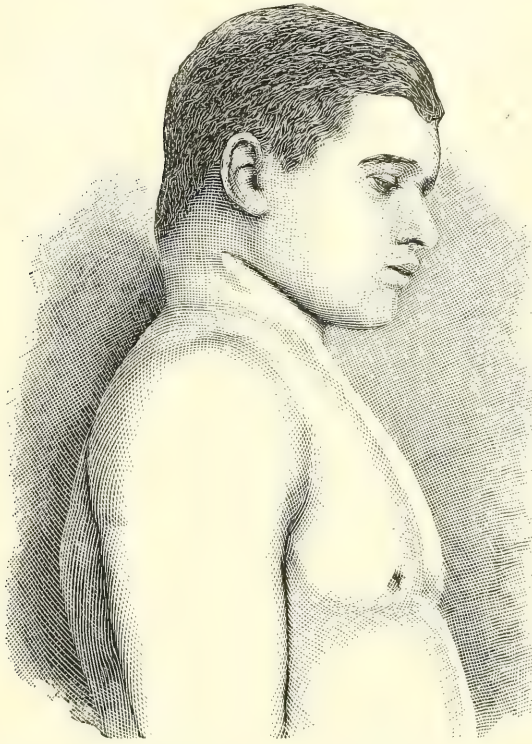


FIG. 681 A.—Caries of the bodies of the third, fourth, and fifth cervical vertebrae.

In occipito-cervical or upper cervical spondylitis, the pus collection often appears at the posterior wall of the pharynx (*retropharyngeal abscess*). Interference with deglutition and phonation is not infrequent. The contents of an abscess resulting from destructive osteitis of the cervical vertebrae may also descend along the deep fascia of the neck and pass into the thorax or the mediastinum. In this manner it occasionally finds its way into the pericardium.

Amyloid changes of the viscera are among the late symptoms of chronic spondylitis.

Diagnosis.—In general the recognition of the disease will depend upon a

history in accordance with most of the symptoms just detailed. As to the portion of the column involved, the appreciation of localized pain by direct or indirect pressure is an indication of value. When the efferent nerves are involved by pressure from the products of inflammation, certain disturbances in their course or distribution are of diagnostic importance. Spasm of the larynx, pharynx, diaphragm, pain down the arm, etc., naturally attract attention to the points of exit of the nerves supplying these parts. When tenderness in the region of the psoas muscles is evidenced by habitual indisposition to extend the thighs, lumbar osteitis may be suspected. When the gibbosity is recognized, a diagnosis is no longer doubtful. The early recognition of abscess in the abdominal region is possible only by palpation under profound narcosis.

If the articular processes are diseased, bending of the spinal column backward will increase the pain. Placing the patient on the abdomen, with the head and lower extremities depressed, will diminish it. When the bodies and intervertebral disks are involved, bending the spine backward will relieve the pressure symptoms.

Treatment.—In the mechanical treatment the indications are to secure fixation of the spinal column in the position of least discomfort to the patient. Judicious medication, good food, and pure air are the indications in the constitutional treatment. The character of the mechanism to be used will depend in good part upon the portion of the vertebral column involved. It is essential, in order that any apparatus may fully meet the indications, that not only shall the diseased bones and the healthy tissues be held practically immovable, but the superincumbent weight must in whole or part be lifted. Fixation may be accomplished by any form of well-adjusted apparatus, but lifting the weight of the body, which is above the seat of disease, is a more difficult undertaking.

The downward pressure upon the bodies when, as is usual, these structures are involved and breaking down, can be in great part obviated by extension or backward bending of the spine, in which manœuvre the pressure is transferred from the bodies and intervertebral disks to the articular processes and pedicles.

Much of the apparatus devised for the arrest and cure of Pott's disease is based upon this principle. Another method is based upon the principle of lifting the parts above the seat of the lesion, and removing the pressure in a greater or lesser degree, not only from the bodies but also from the articular processes (extension and counter-extension, or suspension).

To accomplish the former the spinal braces of Drs. Davis, Taylor, and Shaffer have been constructed. For complete extension or lifting, the plaster-of-Paris jacket or the jury-mast of Prof. Sayre, and the suspension-carriage of Dr. Meigs Case, more nearly meet all the indications.

In appropriate cases each of these forms of apparatus, if properly adjusted and intelligently worn, will accomplish all that is possible in the mechanical treatment of Pott's disease. Much of the discredit which is brought upon particular apparatus can justly be charged to the lack of judgment in the selection of cases, want of skill in the adjustment of the instrument, and failure on the part of the attendant or patient in persisting in its use a sufficient length of time.

The selection of the apparatus best adapted to succeed will depend upon the location of the disease and the age and conformation of the patient. Clinically the spinal column is divisible into three regions: 1, embracing the occipito-cervical articulation, the cervical vertebræ, and down to the third dorsal; 2, from the third to the tenth dorsal; 3, from the tenth dorsal to the sacro-lumbar articulation.

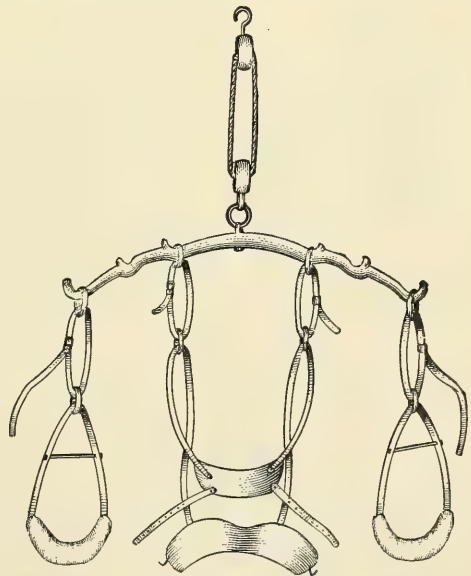


FIG. 682.—Suspension apparatus for applying plaster-of-Paris jacket. (After Sayre.)

The lower region is more amenable to treatment, the upper next, while the middle region, which is most frequently involved in osteitis, is the most difficult to manage.

Third Region.—In the mechanical treatment of Pott's disease in the third region, Sayre's plaster-of-Paris jacket, of light make and properly adjusted, is preferable. In its application the following articles are essential :

1, A suspension apparatus ; 2, a tight-fitting, seamless, knit shirt ; 3, plaster-of-Paris bandages. The suspension apparatus of Reynders & Co.

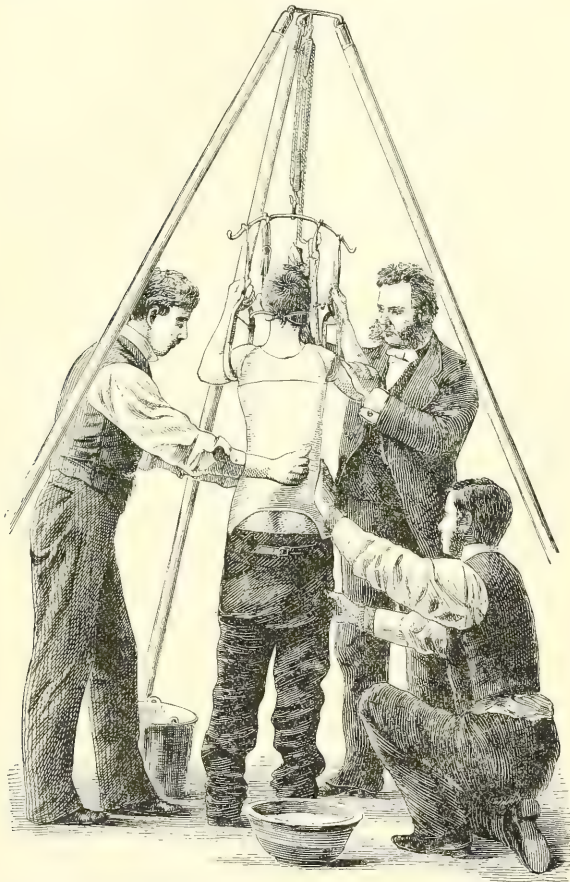


FIG. 683.—Suspension apparatus and tripod in position for lifting.
(After Sayre.)

(Fig. 682) gives perfect satisfaction. It consists of an iron cross-bar from which are suspended padded loops for each axilla, and a chin and occiput swing for lifting from these points. The cross-bar is attached at its center to a block and pulley. After the knit shirt is applied, the arms of the patient are slipped through the padded loops, while the collar is buckled around beneath the chin and occiput. The center and lateral suspension-straps should be adjusted so that when the lift is made the tension will be equally distributed. The block of the pulley apparatus may be fastened to a hook in the ceiling or to the tripod (Fig. 683). The plaster bandages—the method of preparing which is given on page 11—should be perfectly fresh and well made, for a good deal of success

depends upon the quality of the gypsum and the thoroughness with which it is worked into the meshes of the crinoline. As the direction for applying this jacket, as given by Prof. Sayre—to whom the profession is indebted for bringing it so prominently into use—can not be improved upon, I give it in his language :

“ Before applying the plaster bandage, I place over the abdomen, between the shirt and the skin, a pad composed of a towel folded up so as to form a wedge-shaped mass, the thin edge being directed downward.

This is intended to leave room, when removed, for the expansion of the abdomen after meals, and so I call it the 'dinner-pad.' It is important to make it thin where it comes under the lower edge of the jacket, or else the jacket would fit too loosely about the lower part of the abdomen. It should be taken out just before the plaster sets. It is always a good plan to get the patient to eat a hearty meal before the jacket is applied, but this precaution of allowing room for meals should never be neglected.

"If there are any very prominent spinous processes which, at the same time, may have become inflamed in consequence of pressure produced by instruments previously worn, or from lying in bed, such places should be guarded by little pads of cotton or cloth, or little glove-fingers filled with wool placed on either side of them. Another detail, which I have found to be of practical value in some cases, is the application under the shirt, over each anterior iliac spine, of two or three thicknesses of folded cloth three or four inches in length. If these little pads be removed just before the plaster has completely set, such bony processes will be left free from pressure.

"If the patient be a female, and especially if she be developing at the time, it will be necessary to apply a pad under the shirt over each breast before the plaster bandage is put on. These pads should be removed just before the plaster sets, and at the same time slight pressure should be made over the sternum for the purpose of indenting the central portion of the plaster jacket, and of thus giving form to the body, and of removing pressure from the breasts.

"The skin-fitting shirt having been tied over the shoulders, and then pulled down, and kept stretched by means of tapes applied, one in front, the other behind, near its lower edge, and tied tightly over a handkerchief placed on the perinæum, the patient is to be gently and slowly drawn up by means of the apparatus until he feels perfectly comfortable, and *never beyond that point*, and while he is retained in this position the plaster bandage is to be applied. A prepared and saturated roller, which has been gently squeezed to remove all surplus water, is now applied around the smallest part of the body, and is carried around and around the trunk downward to the crest of the ilium, and a little beyond it, and afterward from below upward in a spiral direction, until the entire trunk from the pelvis to the axillæ has been incased. The bandage should be placed smoothly around the body, not drawn too tight, and especial care taken not to have any single turn of the bandage tighter than the rest. Each layer of bandage should be rubbed most thoroughly with the hand by an assistant, that the plaster may be closely incorporated in the meshes of the crinoline, and bind together the various bandages which make up the jacket, thus making it much stronger than if attention is not paid to this particular. If you notice any spot which seems weak or likely to give way, pass the bandage over it, and then fold it back on itself, and do this until you have placed several thicknesses of bandage over this point, being careful to wet all well together, and then pass a turn completely around the trunk to retain any ends which might have a tendency to become detached.

“In a very short time the plaster sets with sufficient firmness, so that the patient can be removed from the suspending apparatus, and laid upon his face or back on a hair mattress, or—what is preferable, especially when there is much projection of the spinous processes or sternum—an air-bed. Before the plaster has completely set, the dinner-pad is to be removed, and the plaster gently pressed in with the hand in front of each iliac spinous process, for the purpose of widening the jacket over the bony projections. In the case of a young child with a small pelvis it may happen that the circumference of the body at the umbilicus is as great as around the pelvis, but, as the soft parts in the lumbar region allow us to mold the plaster as we choose, you can still obtain a point of support at the pelvis; if, as the jacket hardens, you will press it in at the sides above the ilium, and in front and rear above the pubes, the antero-posterior diameter above will be the longer, while below it will be the transverse one.”

When the angular projection is extreme, or when an ulcer exists, it will be advisable to cut a hole in the jacket at this point, large enough to prevent any undue pressure. In case of abscess, a window of sufficient size to allow free drainage, and a frequent change of dressing, should be made.

The commendable features of this plan of treatment are the extension obtained by suspension, fixation by the plaster while in the most favorable position, and the cheapness and readiness with which it may be employed.

The objections are, uncleanliness by reason of the immovable nature of the apparatus, and the excoriations which are a cause of considerable complaint. The first objection may be met by splitting the corset down in front, and reapplying it while the patient is suspended, and making it tight by a roller carried around the body several times. As for excoriations, it may be said that no apparatus which grasps the body tight enough to secure fixation is free from this danger. When they occur with the plaster jacket, the fault generally lies either in the improper manner of its application or carelessness on the part of the attendant.

Second Region.—When the middle or dorsal region is involved, the plaster jacket is not so serviceable as in ostitis of the vertebræ in the lower region of the spine, although much good will be accomplished by the partial fixation of the thorax as high as to the level of the axillæ. The efficacy of this method diminishes the higher the diseased process is located, and, when the lesion invades the sixth dorsal, or above this point, the jacket without head-suspension is almost useless. In all cases of Pott's disease above the tenth dorsal, suspension of the head is an essential feature of treatment. A favorable result would be achieved in a greater proportion of cases if this point were insisted upon, and the prejudice against the suspension apparatus overcome.

In its application the patient should be suspended as just described, and a plaster jacket applied from just above the trochanters up as high as the axillæ. After two layers of the plaster bandages have been applied, the jury-mast is adjusted, and its framework covered in with the

succeeding layers of bandage. The jury-mast (Fig. 684) consists of a back-piece, in shape not unlike the inverted letter U, made of soft iron, which enables it to be accurately molded to fit the surface to which it is applied. To this are fastened two or three strips of tin, made rough by a series of perforations with an awl. To the upper end of the back-piece a curved bar of light steel is attached, in such a manner that it can be raised or depressed at will. At the end of this crane is a light cross-bar, hooked at each extremity, from which the collar is suspended. After the first two layers of plaster bandages have hardened, the apparatus is bent to fit the surface of the back, and is adjusted to the jacket, with the middle-piece or crane exactly in the median line of the back of the neck and occiput, and its extremity over the center of the top of the head, so that traction by the strips will be directly upward. It is

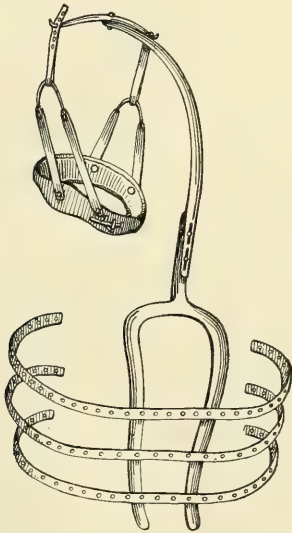


FIG. 684.—Sayre's jury-mast head-swing.
(After Sayre.)

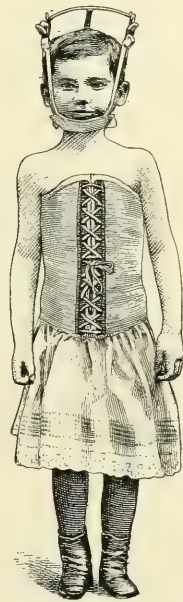


FIG. 685.—Jury-mast apparatus applied.
(After Sayre.)

fastened by carrying plaster rollers over the tin strips and back-piece, and working in plaster-mortar. When the plaster hardens the apparatus is immovably incorporated into the jacket. The suspension-collar should now be buckled beneath the occipital protuberance, and the strips tightened enough to lift the weight of the head from the neck. The jacket may be converted into a movable corset, by splitting it along the middle line in front and attaching hooks for lacing (Fig. 685). If the jury-mast can not be applied, in ostitis involving the vertebræ between the third and ninth dorsal, Shaffer's modification of Taylor's brace should be preferred.

“It consists (Fig. 686) of the pelvic band, *A*, to which are riveted two perfectly plain uprights, *B B*, of annealed bar-steel, which uprights extend to the shoulder-pieces, *D D*, and are steadied at a point opposite

the scapulæ by the cross-pieces, *E E*. The pads at *C C* are simple rolls of Canton flannel stitched to the uprights by transverse threads, shown in the engraving. *P* represents the location of the deformity, and *F F F F* shows the plaster zone securing the uprights in firm contact with the tissues lying over the transverse processes.

“ Fig. 687 illustrates the anterior appearance of the apparatus. *F F* are the shoulder-straps, passing from the ends of the shoulder-pieces, *D D* (Fig. 686), to the buckles, *H H* (Fig. 686). *J* is a piece of padded webbing crossing the anterior and superior wall of the thorax. It is secured at *G G* (Fig. 686). *L* is also a piece of padded webbing, which

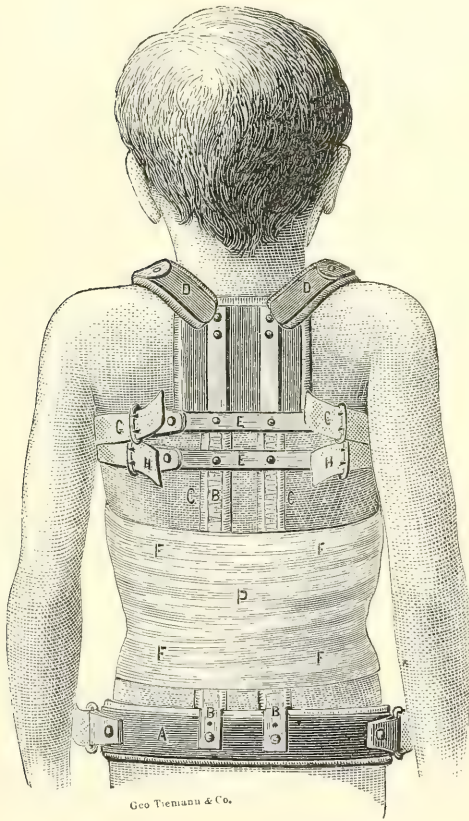


FIG. 686.—Shaffer's apparatus.
(After Shaffer.)




FIG. 687.—Front view of Shaffer's apparatus.
(After Shaffer.)

completes the circumference of the pelvis by fastening at the buckles attached to the pelvic band *A* (Fig. 686). *K* represents the anterior appearance of the plaster zone.

“ At *D D* (Fig. 686) and at *S S* (Fig. 687) are the shoulder-pieces, which prevent pressure and serve as points of attachment for the axillary straps, so that these axillary straps, in passing over the shoulders, shall not exert undue downward pressure. Being annealed, these shoulder-pieces may be bent in any direction desired; and they should be curved so that a very little space exists between them and the subjacent parts. The

pelvic base forms a sufficient support for the apparatus, and it becomes quite frequently necessary to apply perineal pads to prevent the moving upward of the apparatus, rather than to adjust shoulder-pieces to keep the appliance from slipping down.

“To prepare and adjust the apparatus: 1. Take two light bars of annealed steel, of a length which corresponds to the distance between the commencement of the anal commissure and the spinous process of the second dorsal vertebræ. These form the uprights. 2. A piece of sheet-steel, about one inch wide and long enough to reach from the top of one trochanter major to the other; bend it to correspond with the transverse sacro-iliac region, and cover with chamois or other soft material. This forms the hip-band. 3. Two cross-pieces, four or five inches long, which are riveted to the uprights at points which correspond to the lower border of the axilla and the inferior angle of the scapula. 4. Two small pieces of light bar-steel, about two and a half inches long, which are covered and riveted to the upper end of the uprights, at an angle of about 45°, and bent as shown in the engraving. Buckles are now attached to the ends of the shoulder-pieces, the cross-pieces, and the pelvic band. The distance between the uprights should be about one inch and a quarter, or sufficient to avoid any pressure upon the spinous processes. These component parts being riveted together, two rolls of Canton flannel, about three eighths of an inch thick, and a little wider than the upright bar, are now prepared. They should reach from about one inch above the pelvic band to the lower cross-piece. Two broad webbing-bands, as shown at *J* and *L* (Fig. 687), are then made ready.*

“The patient is placed upon two tables of equal height, and the tables are then separated so that the parts selected for the zone may be freely accessible from all sides. One assistant grasps the patient under the axillæ, the other makes steady but easy traction at the thighs. While the patient is in this prone position, the operator fits the uprights to the line of the transverse processes; in other words, adjusts the apparatus to the deformity. A pair of ‘monkey-wrenches’ may be easily used as a pair of levers with which to bend the annealed steel uprights into *any* position. It takes but a few moments to adapt the uprights to the deformity. In the mean time the patient is quiet. He does not struggle nor cry. The traction is affording relief, and is not producing any injury. While he lies quietly, and the Canton flannel pads are sewed on, we pass a piece of Canton flannel, or merino gauze, around the body over the projection. Then, the plaster bandages and everything being in readiness, the apparatus is laid on the back accurately, traction is steadily maintained, the thoracic and pelvic straps are fastened, and the plaster zone is snugly applied. The axillary straps are left until the plaster is hardened, and

* “Messrs. Tiemann & Co., No. 67 Chatham Street, New York, will furnish this apparatus at a cost of from five to seven dollars, according to size. It would also be well, in sending the measurements, to inclose an outline of the spinal column, from the spinous process of the second dorsal down. This may be done by placing a strip of lead along the spinous processes, and molding it accurately to the outline presented. By transferring this lead carefully to a sheet of paper, an accurate profile of the spine may be obtained with a lead-pencil tracing.

the patient is ready to sit up. When the operation is complete, the patient is firmly secured in an apparatus which affords a support that can be maintained by the thoracic, axillary, and pelvic straps, and the uprights are held, without undue pressure, in their position by the plaster zone."*

The value of this apparatus consists in the fair degree of fixation which it secures, but chiefly in the fact that, when properly applied, the dorsal spine is extended, that is, bent backward to such a degree

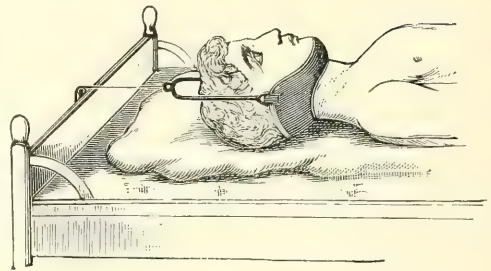


FIG. 688.—Extension in the recumbent posture. (After Reeves.)

that the weight from above is removed from the diseased bodies and transferred to the sound articular processes and pedicles. If this position is properly maintained, relief will usually follow in those cases where the bodies alone are involved. Instead of the plaster zone, a broad canvas or soft leather belt may be used.

First Region.—In otitis of the vertebral column, from the third dorsal to the occipito-atloid articulation, the treatment should be by suspension from the chin and occiput. In accomplishing this end the jury-mast, applied and worn as just described, is entitled to the first consideration. Much good may be obtained from the judicious use of extension in the recumbent posture (Fig. 688). This apparatus may be worn at night, when the head-



FIG. 689.—Dr. Meigs Case's suspension-carriage, for both the standing and sitting postures.

* "Pott's Disease," etc., N. M. Shaffer, M. D. G. P. Putnam's Sons, New York, 1879.

stall of jury-mast is removed. In the worst class of cases it is advisable to employ the extension in bed until the symptoms of paralysis are relieved. Instead of the block and pulley, with weight, the extension may be made by elastic bands attached to the chin-and-occiput collar and the head of the bed, while, if necessary, fixation may be secured by elevating the head of the bed six or eight inches.

The suspension-carriage of Dr. Meigs Case, which lifts from the axillæ, chin, and occiput (Fig. 689), is a valuable apparatus in the treatment of Pott's disease in the cervical and upper dorsal region. If the degree of elastic suspension from the chin and occiput which it affords during the waking hours is continued during sleep, by the method of extension in the recumbent posture above given, success would be achieved in the majority of cases. It is chiefly objectionable by reason of its high price, which places it beyond the reach of many who can obtain the jury-mast.

The successful management of Pott's disease depends not only upon a thorough practical knowledge of the construction and application of the mechanical apparatus required, but upon the careful and constant attention of a competent surgeon during the entire time, from the incipiency of the spondylitis until several months have elapsed after consolidation is effected. The prevention of chafing and sores, the opening and drainage of abscesses, the renewal or tightening of the apparatus, require just as much skill as in the diagnosis and first adjustment of the mechanism. As regards abscess in osteitis of the vertebral column, it may be said that incision and drainage are generally indicated, whether occurring on the back, in the way of the apparatus, or pointing near the groin (psoas abscess). Fresh air, well-selected articles of food, and tonics, are essential. In the severer cases, in which a myelitis is developed from compression by the products of inflammation, potassium iodide, in full and continued doses, is recommended by Professor Gibney. In all cases where the recumbent posture is assumed, an effort should be made to keep the patient on the back, with a pillow so arranged that the spinal column is bent well backward, and the pressure on the bodies in this way partially relieved. The suspensory cradle of Reeves (Fig. 690) will accomplish this end more successfully. A splint or shell is made of gutta-percha or sole-leather, and molded accurately to the back, from the sacrum to the neck. With this held in position by a roller, the patient, while lying down, is supported by the swing, as shown in Fig. 690.

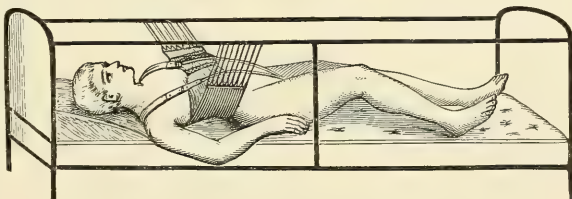


FIG. 690.—Reeves's suspensory cradle. (After Reeves.)

Spina Bifida.—This condition results from a failure of development in the laminæ and spines of one or more of the vertebræ. Through the opening left by this incomplete closure of the bony canal the membranes of the cord are protruded, forming a sac of variable size, which is dis-

placed in various positions, and is often the seat of inflammation and suppuration. It is sometimes associated with other congenital defects of the spine, such as scoliosis or curvature of the spine, and is often accompanied by paralysis of the lower limbs.

tended by the cerebro-spinal fluid. The cord itself may be wholly or in part spread out, and compressed against the sac.

Spina bifida is met with most frequently in the lumbo-sacral region, next in frequency in the neck, rarely elsewhere. One fissure may exist below and one above in the same child, though it is very rarely multiple.

The tumor may vary in size from one inch to six or eight inches in the longest diameter, and may be sessile or pedunculated. It is elastic to the touch, and is usually covered by the integument, which is thinner than normal. In some instances the skin is wanting over the mass, the protruding *dura mater* forming the outside covering of the mass.

The character of the swelling may be recognized by its congenital origin, its location in the median line of the back, almost always in the lumbo-sacral region, its smooth contour, elasticity, and chiefly by its variable size. It becomes larger and more tense during the act of crying, and by pressure its contents may in part be forced back into the spinal cord and ventricles of the brain. Convulsive movements may follow too great and prolonged compression of the tumor. The prognosis is, as a rule, very unfavorable. Ulceration of the integument over the mass, followed by rupture of the sac, is apt to occur, usually ending in death. A recovery after this accident is rare, although such cases are reported. Or the tumor may remain indefinitely in about the same condition as at birth. Paralysis, more or less complete, in the lower extremities, is the rule.

The palliative treatment of spina bifida consists in the application of moderate compression over the tumor, at the same time protecting the integument from all irritation and injury. This plan of treatment should be followed out for one or two years, unless more radical measures are indicated by the failure of this method to arrest or greatly retard the growth of the swelling. When the tumor is suddenly increased in size and tension, temporary benefit may be obtained by drawing off a small quantity of the fluid. From ℥j to ℥j may be withdrawn by the aspirator. The smallest needle should be employed, and the contents slowly evacuated. The quantity of fluid to be removed will vary with the size and tension of the tumor, and the effect produced by the aspiration. Two or three drachms will usually suffice. The operation may be repeated as often as the symptoms demand. It is advisable to introduce the needle through the side of the tumor rather than in the middle line. In spina bifida when the tumor is well pedunculated and the communication between the sac and membranes of the cord is not large, a cure may be effected by the method of Morton, which consists in the injection of the following solution: iodine, grs. x; iodide of potassium, grs. xxx; glycerine, ℥j. From ℥ss to ℥j or more of the fluid is withdrawn from the sac, and from ℥ss. to ℥iij of the iodine solution injected, and the puncture covered with collodion. This operation may be repeated if necessary. When the communication between the sac and the spinal cord is wide, and the tumor is sessile, operative interference is not indicated.

DEFORMITIES OF THE LOWER EXTREMITY.

The deformities of the lower extremity may be divided into those—1, of the coxo-femoral region; 2, of the shaft of the femur in its entirety; 3, of the condyles; 4, of the tibia and fibula; 5, of the tarsus and metatarsus; and, 6, of the phalanges.

In this classification, distortions of the pelvis, such as in malacosteon and rachitis, are excluded, since they concern the obstetrician rather than the surgeon.

At the *hip* there may exist preternatural mobility, or partial or complete immobility with malposition. Preternatural mobility may be due to the following causes: Arrest of development in the bones which form the acetabulum; congenital failure of development of the head of the femur, or atrophy of this portion; to both of these conditions combined; abnormal length of the capsular ligament, and absence of the ligamentum teres.

Immobility with malposition results from inflammation of the joint and ankylosis, with or without destructive ostitis and loss of substance. Contraction of the psoas and iliacus or other muscles about the hip which are not overcome before ankylosis ensues is the chief cause of deformity. Dislocation with failure at reduction always induces deformity, and the same is true of fracture when not properly treated.

In preternatural mobility at the hip-joint (congenital dislocation) the symptoms are chiefly a peculiar rolling gait, or oscillation to right and left in the act of walking, especially when the deformity is bilateral. While standing erect, the trochanters will be closer to the iliac crest than normal, which condition can be accurately determined by Nélaton's or Bryant's test. In these cases the anterior convexity of the curve in the lumbar region is exaggerated, giving the patient a sway-back appearance. If extension is made from the feet, while the trunk is fixed in the recumbent posture, the length of the patient will be considerably increased over that measured in the erect position. Absence of the head of the femur may be determined by palpation with outward rotation. Perforation of the acetabulum may also be made out by digital exploration *per rectum*.

Treatment.—Locomotion in some cases may be much improved by persistent effort on the part of the patient to train the muscles to hold the femur well up in the acetabulum in the act of walking. In this manner the rolling character of gait may be in great part corrected. One important indication in the treatment of these cases in children is to keep the head of the femur from too great pressure against the soft structures placed in the bottom of the cavity of the acetabulum. The double hip-splint of Dr. Sayre will accomplish the necessary extension, while locomotion may be effected by crutches, or Dr. Case's carriage.

In ankylosis at the hip with malposition the thigh is generally flexed upon the abdomen and adducted with outward rotation. When destructive osteo-arthritis has occurred the trochanter will be seen nearer to the

iliac crest than on the sound side, a condition which does not exist when the ankylosis is simply due to muscular contractions.

On account of muscular rigidity the exact condition of ankylosis can not usually be determined without ether narcosis. A certain degree of mobility is present as a rule.

Treatment.—When the malposition is such that usefulness is impaired, or comfort interfered with, an effort to relieve the deformity by operation is justifiable, provided that all local inflammatory symptoms are absent and that the general condition of the patient is such that no risk is incurred by the procedure. Under ordinary conditions the operation is not attended with danger.

In osteotomy at the hip for the relief of deformity three procedures may be entertained: Section of the neck of the femur, just above the great trochanter (Adams, Fig. 691); the inter-trochanteric section of Sayre (Fig. 692); or the sub-trochanteric operation of Gant (Fig. 693).

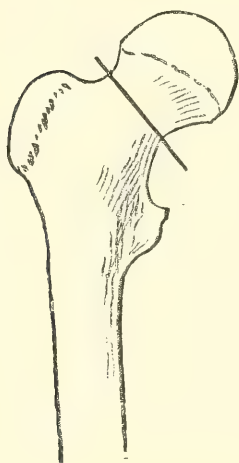


FIG. 691.—Adams's line of section. (After Poore.)

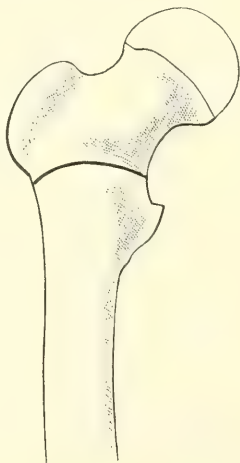


FIG. 692.—Sayre's inter-trochanteric line of section.

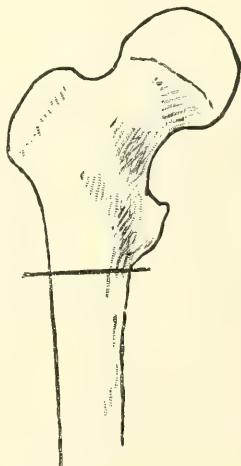


FIG. 693.—Gant's sub-trochanteric line of section. (After Poore.)

The objections to Adams's line of section is that often, on account of disappearance of the head and neck of the bone, it is impossible; and, secondly and chiefly, if disease has existed at the joint, this line of section is so near the old seat of osteo-arthritis that the process of inflammation may be re-established. In ankylosis, without osteo-arthritis at the hip, it is to be preferred. In the vast majority of cases, Gant's section—just at the lower portion of the lesser trochanter—is preferable. The objects to be accomplished are, a section of the bone at this point at a right angle to the axis of the shaft, rotation of the femur into its normal position, and abduction.

Sub-trochanteric Osteotomy at the Hip.—The patient is placed on the sound side, so that the femur to be divided is well exposed. The strict details of antisepsis should be carried out.

The upper surface of the great trochanter is felt, and the femur grasped between the thumb and finger. Upon the outer portion of the

femur an incision is made, commencing about one inch below the most superior surface of the trochanter major, and extending downward about one inch and a half. When the bone is exposed, the wound is held open by retractors, and the bluntest of Macewen's bone-chisels introduced flatwise with the incision until the bone is reached, when it is turned so that the cutting edge is across the axis of the femur. In a child twelve years old the lower portion of the lesser trochanter (the line of section) is about one and a half inch below the tip of the great trochanter.

While the limb is steadied by an assistant, a few blows with the mallet drives the chisel through the outer rim, when a thinner chisel is inserted and the bone cut from one half to three fourths through. Grasping the thigh near the knee with one hand, while the other steadies the part above the section, the remaining portion is readily fractured by carrying the thigh toward the median line. The wound is now thoroughly irrigated and closed with catgut sutures, leaving a bone-drain out at the lower angle. A sublimate dressing is applied. The thigh is rotated slightly inward, abducted to about five degrees from the axis of the spine, and flexed on the abdomen so that the axis of the femur joins that of the body at an angle of fifteen degrees (Fig. 694). If in the position of deformity the thigh is abducted—a condition which rarely exists—the corrected position should be that of adduction about five degrees beyond the normal. The after-treatment is the same as for fracture at this point, namely, Buck's extension and Hamilton's long splint (page 310).

In order to secure the necessary five degrees of abduction, the padding to the splint should be made several inches thicker opposite the acetabulum than at the knee, and the thigh and leg should be elevated upon pillows enough to secure the fifteen degrees of flexion required. When consolidation occurs with the extremity in this position, locomotion is good and more comfort experienced in the sitting posture than when the leg is perfectly straight. At the end of four or five weeks the patient may be allowed to go about on crutches, and in eight or ten weeks to walk without them.

The result to be achieved is osseous reunion at the point of fracture with the limb in the improved position. A false or new joint is not desirable. Esmarch's bandage is not essential in the performance of the operation, although it may be employed if desired. The hæmorrhage is usually slight, and a few catgut ligatures readily control all bleeding

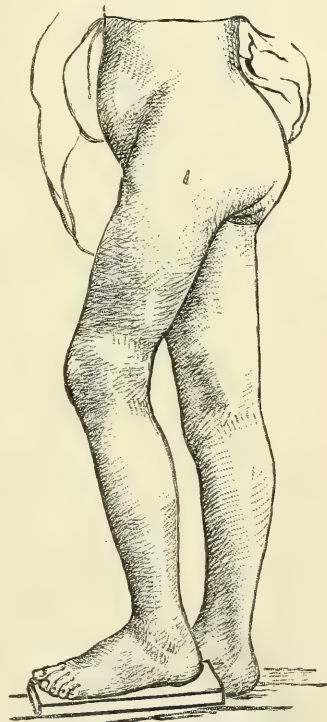


FIG. 694.—The proper position of the extremity after sub-trochanteric osteotomy. (After Poore.)

points. The free incision advised is safer than to use the osteotome through a narrow wound. Forcible breaking up of adhesions or fracture at the joint is not permissible. Adams's section is made through an incision in the line advised for hip-joint exsection. Its center should correspond to a point just above the great trochanter. The chisel should be preferred to the saw in making the section, on account of the bone-dust and detritus left by this latter instrument.

Sayre's line is half-way between Adams's and Gant's lines. The bone should be divided squarely across. The attempt to form an artificial ball-and-socket joint by making a concavity in the upper fragment, or rounding off the upper extremity of the lower fragment, is not justifiable, because it prolongs the operation, and is apt to be followed by necrosis, with ultimate ankylosis. It is better to accomplish reunion at once.

The deformities of the shaft of the femur are also congenital and acquired. An occasional congenital malformation is due to failure of development of this bone in its long axis. The femur may not be more than six inches in length, while the tibia and fibula are normal in development. As a consequence of rickets, the femur is occasionally curved outward, causing *genu varum*, or bow-legs, although, as will be seen later, the bones of the leg are chiefly involved in this deformity.

Shortening, with or without angular malposition, is sometimes seen after badly united fractures.

For the relief of these deformities osteotomy and osteoclasts may be done when the deformity is sufficient to justify the operation. In osteotomy the incision should be along the anterior and external aspect of the thigh farthest removed from the vessels. The only artery of importance here is the descending branch of the external circumflex. Osteoclasts is not permissible unless the fracture can be effected by manual force. In recent and badly united fractures, and in rachitic subjects, this may be done. The osteotome is preferable to the osteoclast. In overlapping fractures, with marked shortening (two to five inches), if the union is not angular, the deformity may be corrected and lateral spinal curvature obviated by a compensating high shoe. If for æsthetic reasons the patient insists upon it, a section may be taken from the sound femur and the ends brought together, as was done by Weir in one instance. The conditions which will justify this procedure are, however, rare.

Occasionally overlapping and badly united fractures of the thigh will be met with in which the callus, which persists, is so extensive that operation at the seat of fracture is impossible.

The deformities of the lower extremity of the femur are those of hypertrophy or elongation of one or the other condyle. The outer condyle is only exceptionally enlarged. The consideration of these pathological changes belongs properly to *genu valgum* and *varum*.

Genu Valgum.—When a normal subject stands erect, the inclination of the femur of each side is inward and toward its fellow, until the internal condyles are almost in contact. In other words, by actual measurement in a descent of eighteen inches from the head to the condyloid

extremity, a separation of seven inches between the acetabula is reduced to three and a half inches from center to center at the knee. This obliquity is slightly increased in females, owing to the broader development of the pelvis.

If the articular facets of both tibiae are brought firmly and evenly in contact with the condyles of the femur, it will be seen that the axis of the tibia is parallel with that of the spine.

Any outward deviation of this parallelism of the tibia with the axis of the body constitutes the deformity known as *genu valgum*, knock-knee, or in-knee (Fig. 695).

Knock-knee may occur on one or both sides, in both sexes and at all ages. In exceptional instances *genu valgum* may ex-

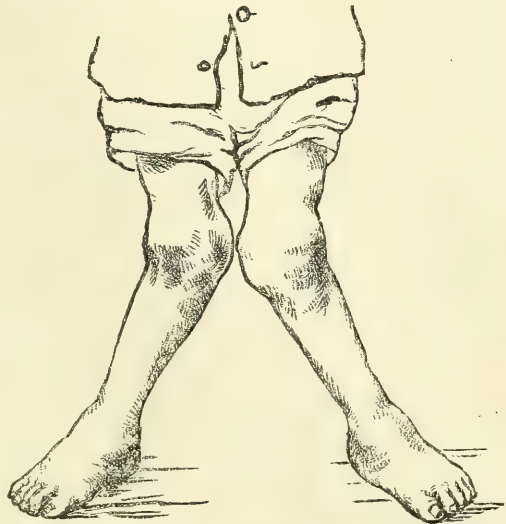


FIG. 695.—Genu valgum—Knock-knee or in-knee. (After Poore.)



FIG. 696.—Genu valgum and varum in the same patient, in Mount Sinai Hospital.



FIG. 697.—The same, after osteotomy of both femora. (The author's case.)

ist on one side and varum on the other, as shown in Figs. 696 and 697. *Knock-knee* is usually *acquired*; occasionally *congenital*. It is most frequently seen in children and young adults suffering from an acquired

or hereditary dyscrasia. As to the *causes*, we must look chiefly to changes in the bones at or near the knee-joint. Any interference with the normal processes of nutrition and development in the bones will account for most cases of knock-knee, and the chief pathological condition is either that of rachitis, or one so closely allied to it that a distinction is difficult.

The most classical osseous lesion in genu valgum is the enlargement of the internal condyle as compared to the external, and the resulting increase of the normal obliquity of the tibio-femoral articulation. This increased obliquity may be due to hypertrophy of the inner condyle; or to hypertrophy of the inner half of the upper tibial epiphysis; to atrophy of the outer condyle, or atrophy of the outer half of the upper tibial epiphysis; to a combination of two or more of these conditions; to a curve of the femur (convexity inward) from rickets, and to a like curve of the tibia and fibula.

There is no anatomical reason why the internal condyle should enjoy a better nutrition and greater development than the outer. There is, however, a very good mechanical explanation in this, that by reason of the marked obliquity of the femoral axis and the perpendicular direction of the tibial shaft when the subject is standing erect, the line of gravity brings the greater weight upon the outer facet of the tibia and the corresponding condyle of the femur. The distribution of this pressure equally over the entire articular surface belongs to the muscles controlling this joint; but owing to the excessive number and greater power in the adductor as compared to the abductor group, the internal obliquity is maintained and the pressure upon the outer articular surfaces increased. In the rachitic condition the bones are softened, and become distorted under pressure, and as a result of muscular action, while such deformities are resisted by the normal bones.

Knock-knee from incurvation of the shaft of the *os femoris* alone is exceedingly rare. When not due to abnormal changes in the condyles, the cause of this deformity will usually be found in rachitic disease of the tibia and fibula, in which these bones are bent inward at the middle or lower third. The principal changes in the soft parts are elongation of the internal lateral ligaments, and a contracted condition of the biceps and popliteus muscles.

Symptoms.—The symptoms of knock-knee vary in different stages of the deformity. The approximation of the knees is a less noticeable feature than the divergence of the tibiae. With the lower extremities fully extended, and the knees in contact, it will be noticed that the inner malleoli are separated from a few inches to a foot or more. When the lesion is due to changes in the inner condyle of the femur, it will be observed that, if the leg is flexed upon the thigh at an angle of 90°, the deformity is less apparent; and if complete flexion is made in mild cases of in-knee, it will disappear altogether; i. e., the tibia in extreme flexion will be parallel with the femur. The patella is displaced outward, and locomotion is more or less impaired. Pain is often present, from the unnatural strain upon the tissues, and fatigue with the slightest exertion is often noticed.

The *diagnosis* rests upon the recognition of the symptoms just detailed, and the *prognosis* is generally favorable when judicious and persistent *treatment* is instituted. Constitutional remedies and mechanical appliances are indicated early in the disease, and operative interference is justifiable when mechanical treatment can not effect a cure.

The first indication is met in out-of-door life, good food, diversion, tonics, cod-liver oil, and the hypophosphites of lime and soda.

The mechanical treatment should be insisted upon in all cases of children in which the deformity is not exaggerated, and should be persisted in for several years, if necessary. Any mechanism which is applicable in this deformity must afford a fixed point, opposite to and on the external aspect of the region of the knee-joint, from which constant traction may be made. The apparatus of Prof. Sayre (Fig. 698) will be found of great use in meeting the chief indications. It consists of a pelvic belt of steel, padded so as not to excoriate, and a bar of steel hinged at the knee, and passing down from the belt to the sole of the shoe, where it is fastened, as in the long hip-splint already described.

Opposite each knee, and just above and below the joints—in order to distribute the pressure over a wider area, and thus prevent chafing or excoriations—are padded belts or bands which surround the limb; these are attached to the side-bars, and may be tightened at will in exercising the required traction to overcome the deformity. Elastic tension by means of rubber bands or webbing may also be utilized in this manner. The hinges at the knees allow the patient to bend these joints in walking and when it is desired to assume the sitting posture. The instrument should be worn during the waking hours, and at night it will be advisable to make extension from both legs by Buck's method. The cost of this apparatus places it beyond the reach of many patients, and in this class of cases renders early operative interference more justifiable.

Osteotomy of the femur for the correction of chronic cases of genu valgum is an operation practically free from danger, and yields excellent results. The section should be made above the joint, and away from it a sufficient distance to avoid all danger of entering the articulation or injuring the epiphysis. Linear section should be preferred, since it is simpler than cuneiform osteotomy, and is equal to the correction of all cases excepting those in which there is extreme angularity at the seat of deformity. Such conditions rarely, if ever, occur in the femur. The older operations of Ogston, Reeves, Chiene, and Macewen, which involved the joint, are practically discarded. They are objectionable in this, that they invade the joint and endanger the functions of this im-

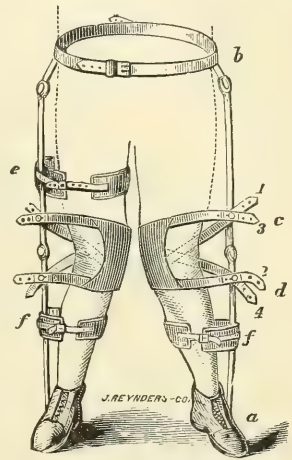


FIG. 698.—Sayre's apparatus for the correction of knock-knee. (After Sayre.)

portant articulation.* Transverse section above the epiphyseal line, from the outside (MacCormac) or inner side (Macewen), should be preferred (Fig. 703).

Macewen's Operation.—In this procedure it is intended to divide the femur at a right angle to its axis through two thirds to three fourths of its thickness, at a point well above the level of the lower epiphysis. In a child ten years old the line of section should be one and three quarter inch above the most dependent portion of the articular surface of the internal condyle, and in an adult two and a half inches.

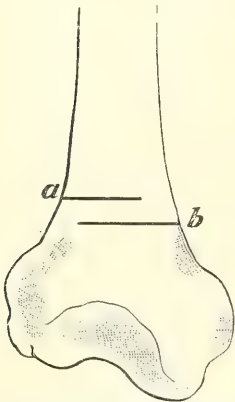


FIG. 703.—*a*, MacCormac's line. *b*, Macewen's line.

Strict antiseptic precautions should be taken. If Esmarch's bandage is applied as high as the middle of the thigh, the wound will be kept dry and the operation greatly facilitated. Flex the leg on the thigh and rotate the thigh outward so as to bring the inner aspect of the joint upward. Make an incision one inch long, following the direction of the internal condyloid ridge. The center of this incision should be opposite the point of section above given. The internal sphenous vein and the anastomotica magna artery should be avoided, and the tubercle for the insertion of the tendon of the adductor magnus felt. As soon as the bone is reached the chisel is carried down to it, parallel with the incision, and immediately turned with its cutting edge at a right angle to the axis of the femur. The inner and anterior shell of compact tissue should be first divided, and when the posterior portion is cut through the osteotome should be directed to the front so that when struck with the mallet it will be carried away from the vessels. As soon as the bone is cut through two thirds of its thickness, the remaining piece may be fractured by grasping the limb above and below the section, and using the other hand for a fulcrum and the leg as a lever, which is carried outward. As soon as the bone snaps, the leg is handed to an assistant, who is directed to steady

the leg. The internal sphenous vein and the anastomotica magna artery should be avoided, and the tubercle for the insertion of the tendon of the adductor magnus felt. As soon as the bone is reached the chisel is carried down to it, parallel with the incision, and immediately turned with its cutting edge at a right angle to the axis of the femur. The inner and anterior shell of compact tissue should be first divided, and when the posterior portion is cut through the osteotome should be directed to the front so that when struck with the mallet it will be carried away from the vessels. As soon as the bone is cut through two thirds of its thickness, the remaining piece may be fractured by grasping the limb above and below the section, and using the other hand for a fulcrum and the leg as a lever, which is carried outward. As soon as the bone snaps, the leg is handed to an assistant, who is directed to steady

* Figs. 699–702. (After Poore.)

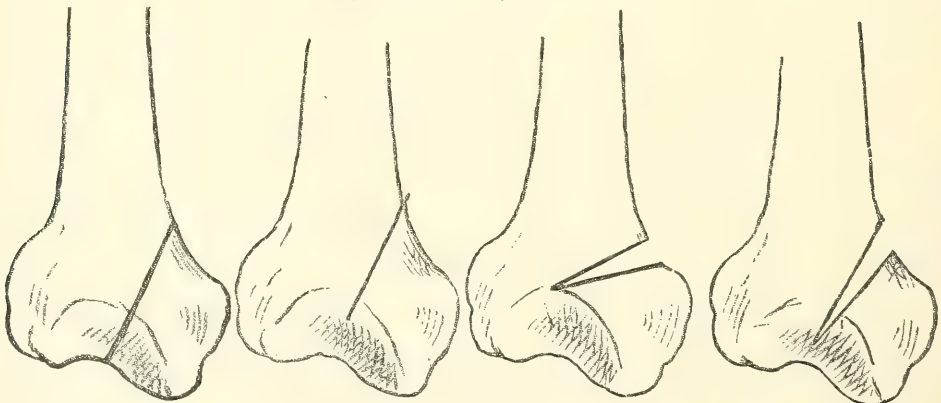


FIG. 699.—Ogston.

FIG. 700.—Reeves.

FIG. 701.—Chiene.

FIG. 702.—Macewen.

it by making strong extension. The wound should now be irrigated with 1:3000 sublimate, a sponge applied as a compress, held in place by a roller, and the tourniquet removed. In five minutes, if no bleeding of importance occurs, the sponge may be removed and a dressing of iodoform and sublimate gauze applied. The limb should be brought into the straight position by extension, and steadily held until a plaster-of-Paris bandage is put on and hardened. This dressing is allowed to remain for four or five weeks, as in simple fracture, when it is removed, and passive motion made at the joint. It is reapplied for a week longer, and then, as a rule, may be discontinued. MacCormac's procedure is practically the same as the above, with the exception that the section is made from the outer side of the femur. Of these two operations the incision from the outer side (MacCormac's) is preferable, for the reason that there are no vessels in the way. On the inner side the long saphenous vein and the anastomotica magna artery are endangered. Moreover, it does not matter from which side the bone proper is divided, as far as the correction of the deformity is concerned. When the tibia and fibula are involved in the deformity, section of these bones may be required at the same or a subsequent operation.

Genu Varum.—In bow-leg, or outward curvature of the lower extremity, one or both members may be involved. The bones of the leg are usually alone involved, although in some instances the femur may take part in the deformity (Fig. 704).

The principal cause of bow-legs is rickets, the softened bones yielding to the weight of the body or to muscular contractions. *Genu varum* is usually met with in childhood, but may occur in adults who are rachitic. In *treatment*, the indications are the same as for knock-knee. The adjustment of any mechanical apparatus is, however, more difficult. Splints should be adjusted to prevent further deformity, or the patient should be prevented from bringing the weight of the body upon the diseased bones. In the mean while every effort should be made to correct the dyscrasia. As long as the bones remain in the softened condition of rickets, operative interference is not indicated. Osteotomy of the tibia and fibula at the point where the outward curve is most pronounced will, in the majority of instances, correct the deformity. In extreme cases it may be necessary to make sections at two or more points. If the femur is involved it should also be divided, although this complication will rarely be met with. The details of the operation and the after-treatment are practically the same as for *genu valgum*.

Osteoclasis should be substituted for osteotomy only in those cases

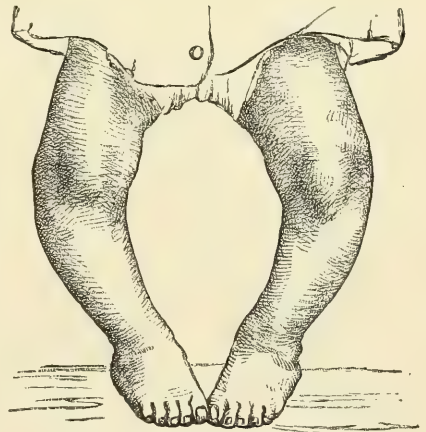


Fig. 704.—*Genu varum*, or bow-legs.
(After Poore.)

in which the fracture may be accomplished with little force and with the hands of the operator. It is objectionable when performed with the osteoclast, for the reason that the soft tissues are bruised to an extent which does not occur in osteotomy. Moreover, the line of fracture can not be directed with the same accuracy as in cutting with the chisel. The necessity for the exclusion of air no longer exists in the use of sublimate irrigation and the antiseptic dressing.

Anchylosis at the Knee, with Malposition.—For the correction of this deformity osteotomy is at times performed. When the degree of malposition is extreme, it may become necessary to divide the femur at a point from three to four inches above the most dependent portion of the articular surface of this bone. If after this section the limb can not be brought out straight, division of the tibia just below the tuberosity may be done. Exsection of the knee is, however, a preferable operation; and, since in modern practice the danger of this procedure is so greatly diminished, it is believed that the operation through the articulation will supersede section of the bone in continuity.

Talipes.—Club-foot is a deformity in which there exists either an abnormal relation between the bones of the foot to each other, or to the tibia and fibula. There are six simple and several compound forms of talipes. The simple varieties are *talipes equinus*, *calcaneus*, *varus*, *valgus*, *cavus*, and *planus*. Among the compound forms are those of equino-valgus, equino-varus, calcaneo-valgus, calcaneo-varus, etc.

In *talipes equinus* the heel is drawn up, and the weight of the body falls upon the plantar aspect of the metatarsus, the toes and phalanges; the gastrocnemius and soleus are shortened, the tendo Achillis tense, and in extreme cases the heel can not be brought down to the ground.

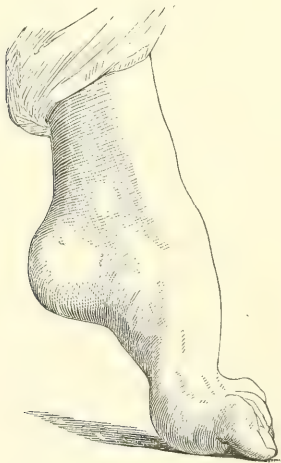

FIG. 705.

Congenital talipes equinus. (After Churchill.)

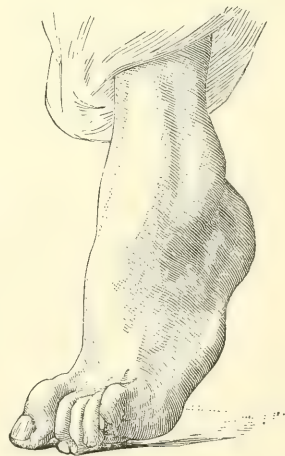

FIG. 706.

Callosities are formed upon the sole of the foot along the metatarso-phalangeal line. When paralysis of the anterior muscles of the leg has taken place, the toes are turned under, as in Fig. 708. In this condition

there are atrophy and complete loss of power in the tibialis anticus, peroneus tertius, extensor longus digitorum, and extensor pollicis muscles.

Simple talipes equinus is not of very frequent occurrence, since it is

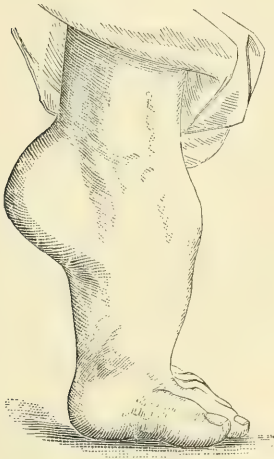


FIG. 707.

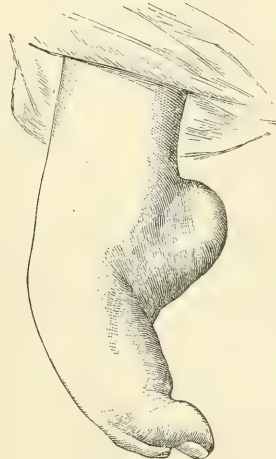

FIG. 708.

Acquired talipes equinus. In Fig. 708 there has occurred complete paralysis of the extensor muscles. (After Churchill.)

almost always complicated with inward rotation of the tarsus, or talipes equino-varus.

Treatment.—When complete paralysis has not occurred, and if taken early, talipes equinus, whether congenital or acquired, may be cured, or marked deformity prevented, by the institution of proper treatment. Section of the tendo Achillis is rarely necessary when the case has not been neglected. The propriety of tenotomy can be determined by the degree of resistance met with in the effort to bring the sole of the foot to a right angle with the axis of the leg. If this can not be accomplished, or if, when the tarsus is firmly flexed on the leg, pressure upon the sural muscles produces a painful and marked spasm (Sayre), tenotomy is indicated, especially in those patients who can not afford the long-continued expense of mechanical treatment, and who of necessity can not remain long in the hands of an experienced surgeon. In simple equinus the indications are to overcome the muscular contraction by artificial appliances, and to restore the normal tonicity and power to the anterior tibial group of muscle.

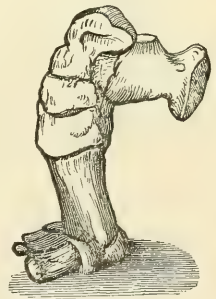


FIG. 709.—Bones of the foot of an adult with talipes equinus. (After Chance and Noble Smith.)

When a child is born with talipes equinus (and all forms of congenital club-foot should be treated from birth), deformity of the bones of the foot, and the too great stretching or elongation of the anterior muscles, may be prevented by the following simple means: Cut a piece of light board as wide as the sole, and a little longer than the foot, and cover it

with adhesive plaster in such a way that the sticking surface is next to the skin. This is laid along the sole of the foot, to which it is fastened by adhesive strips, and a light bandage, leaving the end of the board to project a little beyond the toes. From the end of the board traction may be made by a strip of plaster carried upward and fastened along the front of the leg near the knee, sufficient tension being exercised to draw the foot into its natural position. Or, if deemed necessary, artificial muscles (rubber tubing) may be attached from the tip of the board to insertions fastened near the knee on the antero-lateral aspects of the leg. The apparatus must be carefully readjusted whenever it becomes loose or causes pain.

When the patient is able to walk, simple cases of equinus may be corrected by wearing a stiff, solid, and well-constructed laced shoe, which will hold the instep well down and keep the sole of the foot in close contact with the sole of the shoe. The weight of the body, falling upon the anterior portion of the foot, will aid in carrying the heel to the ground with each step.

In more obstinate cases the Sayre shoe (Fig. 710) more nearly meets the mechanical indications than any other apparatus. When there is no inversion of the foot (varus), the lateral rubber muscle *JG* is unnecessary. In ordering this shoe it is advisable to send to the instrument-maker the shoe at the time worn by the patient, and with this the distance from the sole of the heel to the upper articular margin of the tibia, as well as the circumference of the leg at this point. To this may be added the measurements around the foot, at the bases of the toes, and around the malleoli. In all cases of talipes in walking children and adults, it is important that all excoriations be healed before any appliance is adjusted.

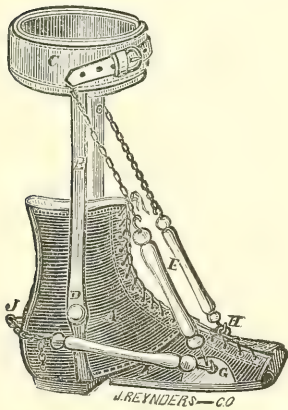


FIG. 710.—Sayre's club-foot shoe.
(After Sayre.)

The idea must not, however, be entertained that the simple application of the shoe, or any mechanical appliance, will correct the deformity.

The after-treatment is a most important feature in these cases. Electricity and massage are important adjuvants. The weaker galvanic current should be preferred, the positive pole being placed along the track of the nerve which supplies the affected muscles, while the negative sponge is carried over the bellies of these muscles. The application should be made about twice each week, while massage should be employed twice daily.

In those cases where tenotomy is deemed advisable; the operation is performed as follows: The patient being placed under the influence of an anæsthetic, the tarsus is flexed forcibly upon the leg, in order to place the tendo Achillis and plantar fascia upon the stretch; a slight puncture of the skin is then made, a little anterior to the tendon, and on the inner side of the leg, slightly above the malleolus; this opening is now carried

to the edge of the tendon by traction upon the integument, and the tenotome introduced, with its flat surface toward the tendon. The tension upon the tissues is now relaxed, and the edge of the knife turned toward the parts to be divided; the tarsus is flexed strongly upon the leg, and the tendon again made tense, when the knife is pressed forward and outward through the tendon, which separates with a very audible snap. The thumb of the operator being placed over the tendon externally, acts as a guide and support, preventing the blade from passing through the integument and causing an open wound, an accident which should be carefully avoided. As soon as the division of the tissues is effected, the blade of the knife should be withdrawn, flatwise, and the thumb of the operator slipped over the slight puncture, which is at once covered with one or two strips of adhesive plaster; the plantar fascia can be divided in a similar manner, if desirable, the whole foot being then enveloped in cotton, and a snug roller bandage applied. The foot is now secured, by mechanical appliances, at a right angle to the leg, as heretofore described. Division of the extensor tendons of the toes is not often required. The best point of section is just over the metatarso-phalangeal articulation.

Talipes Calcaneus.—In this rare form of club-foot the toes are drawn upward and the tarsus flexed upon the tibia; impairment of function exists in one or more of the sural muscles; the tibialis anticus, peroneus tertius, extensor longus digitorum, and pollicis are shortened. This deformity may be either congenital

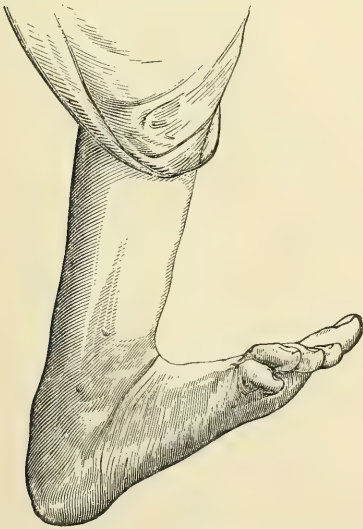


FIG. 711.—Congenital talipes calcaneus.
(After Churchill.)

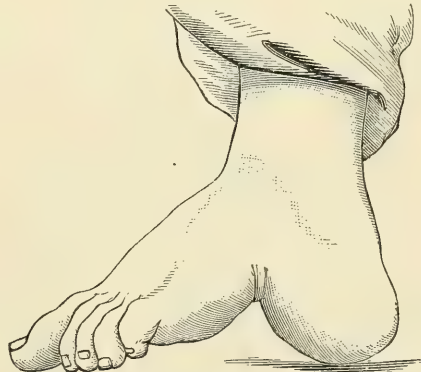


FIG. 712.—Acquired talipes calcaneus.
(After Churchill.)

or acquired (Figs. 711, 712). It is usually met with in children, or may occur at any period of life, from rupture of the tendo Achillis, or paralysis of the muscles of the calf of the leg, ununited fracture of the os calcis, etc. In this condition the mechanical and surgical appliances and treatment are exactly opposite to those of the preceding variety. An ununited section of the tendo Achillis should be corrected by cutting down upon this tendon at the seat of the division, freshening the divided

ends, and sewing them together with silk sutures. Mild cases of calcaneus may be relieved by the wearing of a well-fitting, laced shoe, the weight of the body aiding in correcting the deformity. When the toes can not be brought down without the aid of additional pressure, the apparatus in construction similar to the one recommended for flat-foot can be applied. The object to be obtained is to elevate the heel and depress the toes by mechanical means. For this purpose, the shoe as devised by Dr. Sayre (Fig. 713) is admirably adapted. This is a strong, laced shoe, with steel rods running up on either side of the leg to a collar below the knee, the rods being hinged at the ankle to allow of free motion at this joint; from the heel of the shoe a small steel spur is seen, to which is secured a strong piece of elastic, passing up to the collar around the leg. This rubber artificial muscle, taking the place of the gastrocnemius and soleus muscles, if made of sufficient tension, will elevate the heel and restore the foot to its normal position. There are, however, various instruments for the correction of this deformity, the surgeon modifying the shoe as may be required to suit each case. In addition to the mechanical appliances, the after-treatment, by electricity, massage, etc., should be car-

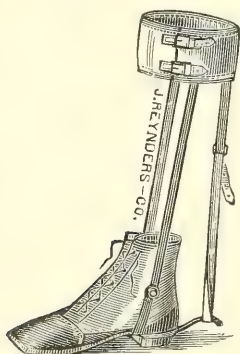


FIG. 713.—Sayre's shoe for talipes calcaneus.
(After Sayre.)

ried out as in other forms of club-foot where atrophy of the muscles and loss of power exist.

Talipes Varus and Equino-Varus.—These deformities consist of an inward rotation of the foot, and are the most common forms of talipes (Figs. 714-717). The majority of cases are those in which spastic contraction of the sural muscles also occurs (equino-varus). Talipes varus and equino-varus are more often congenital, but are frequently acquired, one or both feet being involved. The degree of deformity varies from slight inversion of the foot

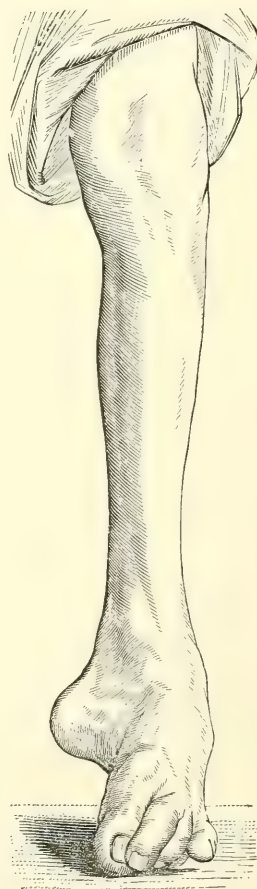


FIG. 714.—Talipes equino-varus in an adult.
(After Churchill.)

to the most exaggerated form in which the sole looks upward, while in the act of walking the dorsum rests upon the ground.

The changes which the structures of the foot undergo are shortening of the plantar fascia and the internal lateral ligaments, together with

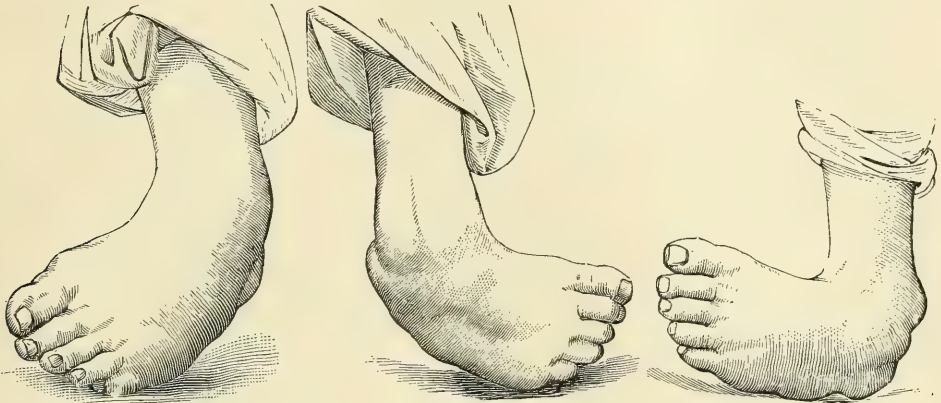


FIG. 715.

FIG. 716.

FIG. 717.

Three grades of talipes varus. (After Churchill.)

a contracted condition of the tibialis anticus and posticus muscles. This deformity, therefore, places those muscles and ligaments upon the stretch which are situated upon the outer aspect of the leg, and results from complete or partial paralysis of the peronei muscles. The displacement of the bones of the tarsus will correspond to the extent of the deformity; the astragalus being tilted downward, the scaphoid is displaced inward and downward by the action of the tibialis posticus, the tubercle on this bone becoming very prominent; there is in addition marked rotation at the astragalo-scaphoid and calcaneo-cuboid junctions, the displacement being especially marked in this last-named articulation.

When the deformity exists at birth, if not corrected early, the bones will become ossified, and the deformity permanent. In these cases tarsotomy and exsection are the only means of bringing the foot into its normal position.

The treatment of talipes equino-varus in the infant consists in the application of small rubber bands or pieces of tubing, which will make constant and gradual traction in the line of the weakened or paralyzed muscles. This (*Barwell's*) method is as follows:

Cut a piece of strong adhesive plaster into the shape of a fan, which is split into four or five strips converging toward the apex of the fan (Fig. 718). "The apex of the triangle is passed through a wire loop with a ring in the top (Figs. 718, 719), brought back upon itself, and secured by sewing. The plaster is firmly secured to the foot in such a manner that the wire eye shall be at a point where we wish to imitate the *insertion* of the muscle, and that it shall draw evenly on all parts of the foot when the traction is applied. Secure this by other adhesive straps and a smoothly adjusted roller.

“The artificial *origin* of the muscle is made as follows: Cut a strip of tin or zinc plate, in length about two thirds that of the tibia, and in width one quarter the circumference of the limb (Fig. 720). This is shaped to fit the limb as well as can be done conveniently. About an

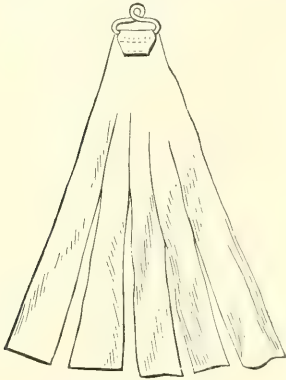


FIG. 718.—(After Sayre.)



FIG. 719.—(After Sayre.)

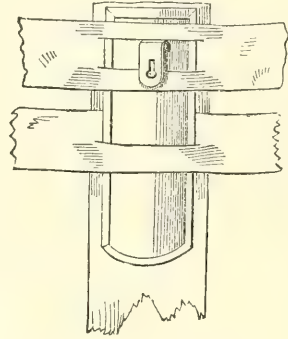


FIG. 720.—(After Sayre.)

inch from the upper end fasten an eye of wire. Care should be taken not to have this too large, as it would not confine the rubber to a fixed point. The tin is secured upon the limb in the following manner: From stout (mole-skin) plaster cut two strips long enough to encircle the limb, and in the middle of each make two slits just large enough to admit the

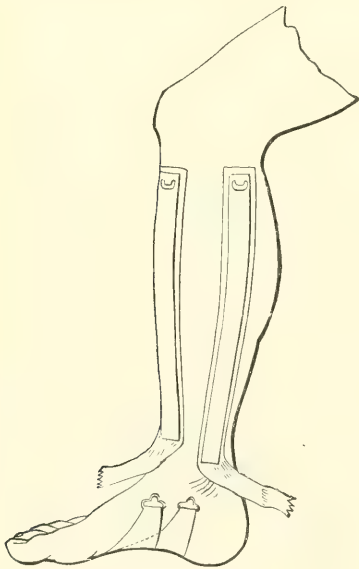


FIG. 721.—(From Barwell.)

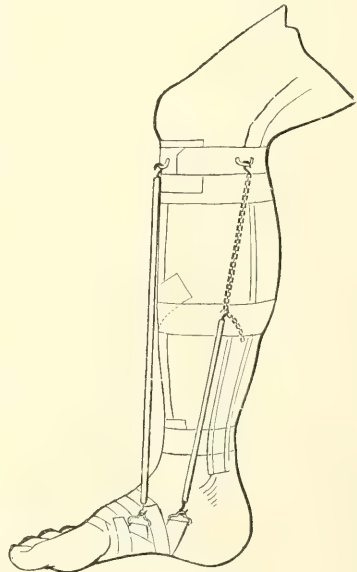


FIG. 722.—(From Barwell.)

tin, which will prevent any lateral motion; then cut a strip of plaster, rather more than twice as long as the tin, and a little wider: apply this smoothly to the side of the leg on which the traction is to be made, beginning as high up as the tuberosity of the tibia. Lay upon it the tin,

placing the upper end level with that of the plaster (Fig. 721). Secure this by passing the two strips above mentioned around the limb (Fig. 722), then turn the vertical strip of plaster upward upon the tin. A slit should be made in the plaster where it passes over the eye, in order that the latter may protrude. The roller should then be continued smoothly up the limb to the top of the tin. The plaster is again reversed and brought down over the bandage, another slit being made for the eye, and the whole secured by a few turns of the roller. A small chain, a few inches in length, containing a dozen or twenty links for graduating the adjustment, is then secured to the eye in the tin.

“Into either end of a piece of ordinary India-rubber tubing, about one quarter of an inch in diameter and two to six inches in length, hooks of the pattern shown in Fig. 723 are fastened by a wire or other strong ligature. One hook (Fig. 722) is fastened to the wire loop on the plaster on the foot, and the other to the chain above mentioned, the various links making the necessary changes in the adjustment.

“The dressing, when complete, is shown in Fig. 722.” (Sayre.)

A roller should now be carefully and smoothly applied over the plaster and between the leg and the artificial muscles.

When the muscles can not be obtained, and in mild cases, in which the foot may be brought readily into position, a correction may be effected by means of one or more strips of adhesive plaster as follows: One end of the strip is laid upon the dorsum of the foot, near the bases of the third and fourth toes, whence it is carried in a slightly spiral direction to the inner border of the sole, and across the sole to the outer margin of the foot. As the foot is now brought into a normal position by the hand of the operator, the strip of plaster is laid along the outer and anterior aspect of the leg and thigh, and firmly secured by encircling strips of the same material. A bandage over all will hold the dressing in position.

When the patient is able to walk, the club-foot shoe (Fig. 710) will give the greatest satisfaction. The rubber muscles should be applied and regulated in such a way that they will imitate as nearly as possible the normal action of the muscles they are intended to assist. A less expensive instrument, one which yields good results in the milder forms of talipes equino-varus, and which may be readily made by any ordinary worker in iron, is shown in Fig. 725. It consists of a sole-piece of sheet-iron, which is riveted to a heel-piece of the same material, and is roomy enough to hold the heel of the patient without chafing. It should be nicely padded, to prevent the danger of excoriations. To this heel-piece is attached, by a hinge-joint with limited forward and backward motion, an iron bar which extends to the padded iron collar around the leg, near the knee. The foot of the patient is secured to the sole-piece by adhesive plaster, with the aid of the



FIG. 723.



FIG. 724.

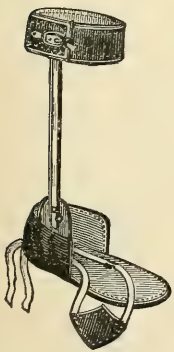


FIG. 725.—Iron shoe for talipes varus and equino-varus.

instep-strap shown in Fig. 726, and a flannel roller carried over all. As the perpendicular bar is now carried parallel with the leg, and held in this position by buckling the collar around the leg at the knee, the foot is turned outward and held in its normal position. An ordinary lacing-shoe should be worn over the brace.




FIG. 726.—Iron shoe for talipes varus and equino-varus in position. The adhesive strips and bandage have been omitted in the cut.

An apparatus, the mechanism of which is somewhat similar to this, is highly recommended by Mr. Reeves, and is shown in Fig. 727.

The modification of Scarpa's shoe (Fig. 728) possesses some advantages over the iron shoe above described, and should be preferred to it when it can be obtained.

Tenotomy and *fasciotomy* will be found necessary in a large proportion of cases of talipes equino-varus, and, when not essential to ultimate success, it will greatly expedite the permanent restoration of the member to its normal position. The application of Esmarch's bandage from the toes to above the knee, though not essential, renders the operative procedure more rapid and easy of execution. The tendo Achillis is divided as heretofore directed. In addition, the tibialis anticus and the tibialis posticus will, as a rule, require to be divided. The tendon of the tibialis anticus should be cut subcutaneously about one inch above its insertion into the internal cuneiform bone by introducing the tenotome beneath it from the middle line of the foot. It can be made prominent by forcible eversion of the foot. Division of the tendon of the tibialis

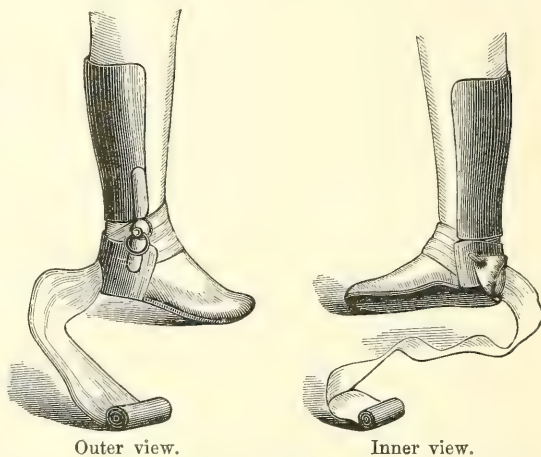


FIG. 727.—Reeves's universal shoe, as it is being applied in the treatment of talipes equino-varus. (After Reeves.)

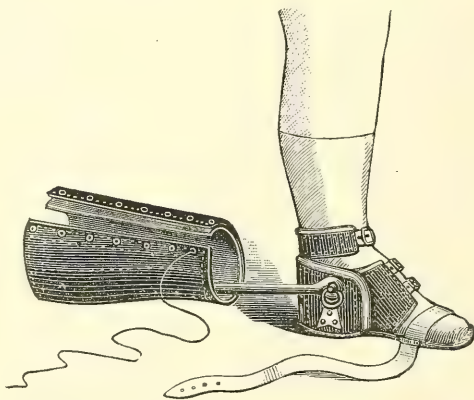


FIG. 728.—Modified Scarpa's shoe for talipes varus and equino-varus. (After Reeves.)

posticus is best effected by an incision parallel with the inner border of the tibia just above the internal malleolus, where it lies in close relation to this surface of the bone. As soon as it is exposed, an aneurism-needle should be passed beneath it, when it can be drawn out through the wound and divided with the scissors. Subcutaneous section of this tendon is a very difficult and uncertain procedure, while no mistake is possible through an open wound. If careful antisepsis is practiced, and if the wound is at once closed with catgut sutures, no suppuration can occur. The plantar fascia should be divided by introducing the tenotome flatwise under the fascia from the inner border of the foot, turning the edge outward, and cutting the fascia as it is made tense. Several lines of section through this fascia may be made when necessary. Bits of adhesive plaster should be placed over each puncture.

Tarsotomy.—In exaggerated and chronic cases of congenital talipes equino-varus, a wedge-shaped exsection of a portion of the tarsus will at times permit a restoration of the foot to its normal position, and serve to restore in great part the usefulness of the member. In two recent cases in which I performed this operation, the most gratifying results were obtained. In each case the patient walked with the dorsum of the foot on the floor, and, in one instance, the toes pointed directly backward.

After Esmarch's bandage has been applied, a free incision is made along the fibular side of the foot, extending from below the external malleolus to the tarso-metatarsal junction. All the tissues should be lifted from the bones by the periosteal elevator, and the wedge-shaped section of the tarsus removed by the gouge or chisel. The anterior portion of the astragalus will require to be removed, and as much of the tarsus should be exsected as is needed to permit the restoration of the foot to the natural position; for it is not only necessary to evert the foot, but to make at the same time a marked rotation of that part of the member anterior to the line of section. The tendo Achillis should now be divided, and, as soon as the proper position is obtained, the wound should be irrigated with sublimate solution, the incision closed and covered with iodoformized gauze, and a light sublimate dressing and compression-bandage applied tight enough to arrest all oozing. A plaster-of-Paris dressing is now put on, and the foot held in position until this hardens. This last procedure can be facilitated by adjusting two strips of adhesive plaster, one of which will serve to hold the foot at a right angle to the axis of the leg, and the other to keep it rotated outward while the plaster is being applied and is hardening. The dressing may be removed not earlier than the fifteenth day, and should not be disturbed for a month unless from soiling or smelling it is necessitated.

Talipes Valgus.—In this deformity the normal arch of the foot is lost, and the foot is everted (Figs. 729, 730, 731, 732). The contracted muscles are the peroneus longus and brevis, while the paralysis, as a rule, affects the tibialis posticus, anticus, and flexor muscles. When the tarsal arch gives way, the plantar fascia, calcaneo-cuboid ligaments, and

short flexors become stretched, and the tibialis anticus is elongated. The yielding of these muscles may be due to paralysis, or to strain from the habit of carrying heavy weights.

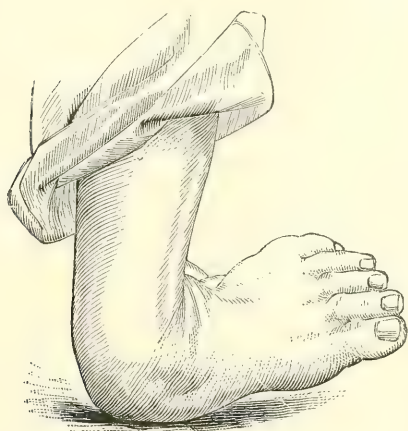


FIG. 729.—Congenital talipes valgus.
(After Churchill.)

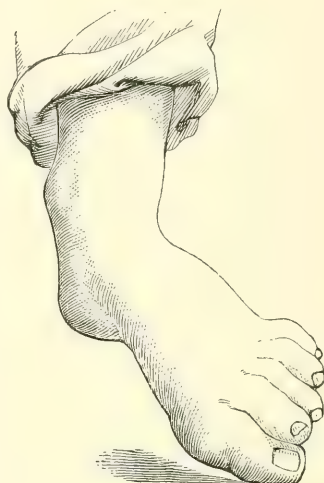


FIG. 730.—Acquired talipes valgus.
(After Churchill.)

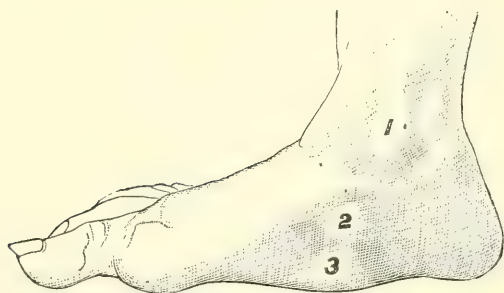


FIG. 731.—Inner view of a severe valgus of the right foot.
(After Reeves.) 1, Inner malleolus. 2, Inner surface of head of astragalus. 3, Tubercle of scaphoid.

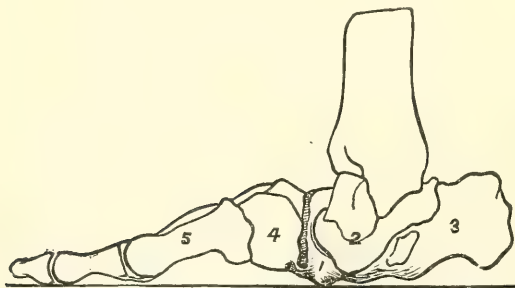


FIG. 732.—Inner view of the bones of a severe valgus.
(After Reeves.) 1, Tubercle of scaphoid. 2, Astragalus. 3, Os calcis. 4, Internal cuneiform bone. 5, First metatarsal.

er malleolus. To the inner side of the sole, near the heel, is attached a strong piece of elastic webbing, by which inversion of the foot is effected by buckling the strap to the collar near the knee.

Treatment.—In talipes valgus in an infant the eversion may be corrected by means of the adhesive strips applied as in the treatment of varus. The direction of traction is of course opposite. The artificial muscles, after the method of Barwell, are also as applicable here as in varus. The iron shoe (Fig. 725), made with the bar to come upon the inner side of the leg, is as serviceable in mild cases of valgus as in varus or equino-varus. This apparatus is always worn inside of an ordinary shoe. Nyrop's boot (Fig. 733) is highly recommended by Mr. Reeves. It consists of a stiff-soled lacing-shoe, with a leg-collar and iron or steel bar attached to the outer side of the shoe, with a lateral hinge opposite the out-

When tenotomy of the peronei muscles is indicated, they should be divided subcutaneously from three quarters to one and a half inch (owing to the age of the patient) above the external malleolus. Cuneiform tarsotomy may be applied to the correction of this deformity in exaggerated cases in adults. When the bones are thoroughly ossified it will be impossible to change the shape of these organs and restore the normal shape of the part by any mechanical apparatus, no matter how persistent in its use. The incision is made along the inner side of the foot, and the apex of the conical section must be at the outer border of the tarsus. The details of the operation and the after-treatment are practically the same as given for equino-varus.

Talipes Cavus.—Hollow-foot is almost always an acquired deformity, although it may be congenital. It occurs with talipes calcaneus, equinus, and, in a mild degree, may complicate varus and equino-varus. In this deformity the antero-posterior arch of the foot is exaggerated, the plantar fascia and the muscles of the plantar region which have their origin behind the medio-tarsal joint, and are inserted anterior to this articulation, are shortened. The plantar fascia and the calcaneo-cuboid ligaments are also shortened. The sole of the foot no longer rests upon the floor, as in the normal condition (Fig. 734), but touches only at the heel and along the metatarso-phalangeal line.




FIG. 734.—Showing the surface of the sole which rests upon the floor in a normal foot. (After Sayre.)

Any inflammatory process of the plantar region may induce contraction of the fascia or ligaments; or spastic contraction of the muscles of this region from local or remote causes may produce this deformity. Commencing before the bones are softened, the distortion of the foot is apt to become permanent unless exsection or crushing is performed. Of these two procedures, tarsoclastis is the most readily accomplished; but, when the tarsoclast can not be had, section through the tarsus, with a thorough division of the plantar fascia, will be justifiable. Fortunately, few instances will occur where such harsh procedures will be called for.

In recent cases the deformity may be relieved by wearing a plain shoe with a low, broad heel and straight, thick sole. The plantar fascia should be divided in all cases which do not readily yield to mechanical treatment.

Talipes Planus.—Flat-foot has been partially considered with talipes valgus, with which condition it is almost always associated. The antero-posterior arch of the foot is more or less obliterated, and in severe cases the anterior portion of the sole spreads out or widens in its transverse diameter (Fig. 735).

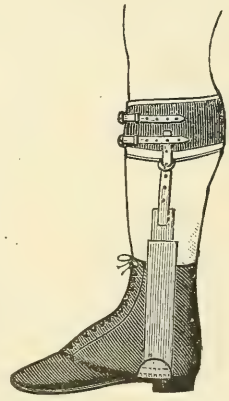


FIG. 733.—Nyrope's shoe for talipes valgus. (After Reeves.)

The plantar fascia and calcaneo-cuboid ligaments are stretched, the internal lateral ligaments of the ankle-joint are generally involved, while the tibialis anticus and the antero-posterior muscles of the plantar aspect of the foot are elongated. The principal cause of this deformity is the habitual carrying of heavy burdens, or pressure of the superincumbent weight of the body upon the arch of the foot, together with lack of tonicity in the muscles, and of strength in the ligaments and fascia.

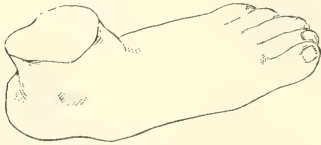


FIG. 735.—Cast of the right foot in a case of *talipes planus*, at the Polyclinic.

Treatment.—It is exceedingly difficult and in the majority of cases impossible to correct this deformity. The best method is to support the arch of the foot by a comfortable adjustment of pressure by inserting a piece of felt in the sole of the shoe, just beneath the arch.

The *deformities of the toes* are congenital and acquired. The congenital deviations from the normal are the presence of one or more supernumerary toes (*polydactylus*), or the absence of one or more of these members (*syndactylus*).

In *polydactylus* the most frequent supernumerary toe is one connected with the great-toe, attached usually on its inner or tibial aspect, near the junction of the metatarsal bone and phalanx. In a rare case of this deformity, reported by Prof. Sayre, there were eight toes on the right and ten on the left foot.

Treatment.—All minor deformities the removal of which does not endanger the life of the individual, or diminish the usefulness of the member affected, demand amputation within the first year or two of life, before the patient is old enough to become conscious of possessing a deformity.

Syndactylus is a term applied not only to the partial or entire absence of one or more fingers, but also to the condition known as congenital *web-toe*.

Web-toes may be treated in the same way as web-fingers. If neglected until the child is old enough to become accustomed to the deformity, operation is of doubtful propriety.

When one or more toes are missing, as in Fig. 736, even when the deformity is offensive to the sight, the question of operative interference (except for relief from pain) should depend upon the degree of usefulness enjoyed by the deformed member. An important principle in the surgery of the foot is to save every particle of surface for the support of the body. This conclusion gains additional force in the ability to conceal the deformity by a properly constructed shoe.

The acquired deformities of the toes result in almost all cases from improperly adjusted shoes. The displacement may be in all directions, although those of the great and little toes are usually toward the median

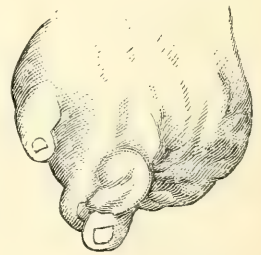

FIG. 736.—Syndactylus in the right foot of a boy. (After Reeves.)

line of the foot. The middle toes may be flexed in one joint, extended in another, or crossed over each other.

Hallux valgus, or displacement of the great-toe toward the fibular or outer side of the foot, is a common deformity (Fig. 738). In exaggerated instances mechanical or surgical interference is demanded. Hallux valgus is caused chiefly by shoes which are pointed at the tip and are too short for the foot. It may also occur with club-foot, and generally with talipes varus and planus. The action of the muscles inserted into the base of the great-toe must not be altogether overlooked in the ætiology of this deformity. Of the five muscles which arise from the tarsus and metatarsus and are inserted into this toe, all but one tend to carry it toward the fibular side of the foot.

In being displaced, the great-toe usually is carried above the second or third toe, occasionally beneath it. The phalanx is more or less completely dislocated from the original articular surface of the metatarsal bone, being twisted around to its outer lateral aspect. The cartilage of the old portion disappears, and a new joint-surface is developed on the external aspect of the metatarsal bone. From pressure, a callosity of varying thickness develops over the tip of the metacarpus, adding greatly to the appearance of deformity.

Treatment.—Mild cases of hallux valgus may be cured by elastic tension steadily applied, as follows: A soft kid or chamois-skin cover is made for the affected toe, and to the end of this a piece of thin elastic webbing is attached. To the webbing a strip of adhesive plaster is stitched, and this is carried around the heel and is made to adhere along the

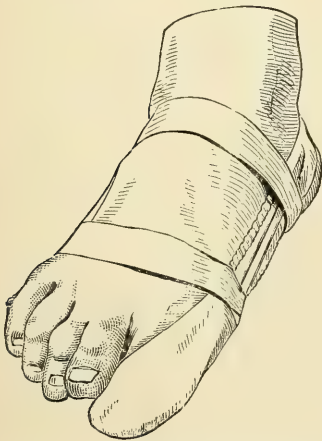


FIG. 737.—Sayre's method of treating hallux valgus. (After Sayre.)

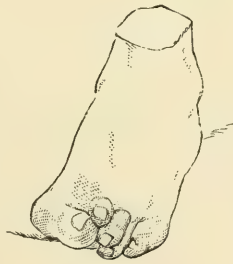

FIG. 738.—Hallux valgus. (From a patient at Mount Sinai Hospital.)

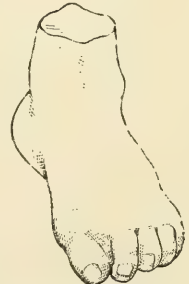

FIG. 739.—The same, after operation.

outer side of the foot in such a way that the webbing is made to draw the toe outward (Fig. 737).

In severe cases, operative interference can alone restore the toe to its normal position. The operation consists in an incision made along the inner side of the foot, the center of which is over the angular projection at the end of the metatarsal bone. The callosity should be removed, the joint opened, a wedge-shaped segment removed from the end of the metatarsal bone and the phalanx. Enough should be removed with the exsector or metacarpal saw to permit the bones to be brought into proper

position, where they should be held by a silver-wire suture passed well into the bone a half-inch from the cut surface; or the bones may be held in apposition by transfixion with small steel drills. Fig. 738 is from a cast taken from a patient at Mount Sinai Hospital upon whom I did this operation in both feet. The degree of correction is shown in Fig. 739.

This operation is preferable to that of osteotomy of the first metatarsal bone just behind the articulation, for the reason that the callosity and projection opposite the joint can only be removed by excision.

Hallux varus, or pigeon-toe, is a much rarer deformity, and occurs usually as a result of cicatricial contractions or from spastic action of the abductor-pollicis muscle. The treatment consists in adjusting a well-made shoe which will push the toe into its proper position. Division of any cicatricial tissue or the tendon of the abductor muscle may be necessary.

Displacement of the little toe is usually inward and beneath the fourth. The same treatment may be applied in this deformity as given for *hallux valgus*.

Flexion of the toes may be complete when there is paralysis of the extensor muscles. The most usual form is that in which the first phalanx is tilted upward, that is, seemingly extended, while the distal phalanx is drawn downward, so that the nail is to the front, and the tip of the toes rests upon the ground. This condition is also known as *hammer-toes*.

The cause is chiefly one of improper shoeing, by which the toes are not allowed to be fully extended, and, being held in this cramped position by the shoe, the muscles and fasciæ become permanently shortened. The plantar fascia is usually involved in chronic cases. The extensor muscles become shortened as well as the flexors, which are, however, the principal agents in producing the deformity.

Extension of the toes beyond the normal line is a rare condition. It could only be caused by paralysis of the flexors.

Treatment.—In mild cases of incipient hammer-toes a cure may be effected by wearing a shoe long enough to allow these members to be extended. In more chronic and obstinate cases, a metal sole should be adjusted so that an ordinary shoe can be worn over it. Just beneath the middle of the toes is a series of perforations in the sole, through which loops are passed. The toes are straightened by traction on the loops, which are tied below (Fig. 740). In some instances tenotomy of the long flexor and extensor muscles and of the plantar fascia is essential.

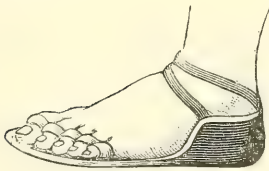


FIG. 740.—Apparatus for hammer-toes. (After Reeves.)

The tendons of the extensor digitorum should be subcutaneously divided just over the bases of the toes; the flexor tendons near the middle of the plantar surface of these members.

Bunions are callosities resulting from intermittent pressure upon certain portions of the foot.

Corns are both *hard* and *soft*. A hard corn differs from a bunion only in size. Soft corns are small ulcers situated between the toes or in

the fissures on the under surface. They are caused by friction of opposing surfaces and moisture.

Bunions and hard corns are to be treated by relieving the unnatural pressure which caused them. Comfortably fitting, yet not necessarily loose shoes, of soft leather, should be worn. Pieces of Canton flannel, cut into rings and laid upon each other so that the pressure will be distributed to the surfaces near the corn, will be advisable, in simple cases, even when loose shoes are adopted. A small tuft of cotton dipped in vaseline will aid in softening the hard covering. Soft corns may be readily cured by inserting pellets of absorbent cotton moistened with borax dissolved in glycerine, and applied so as to protect the raw surfaces and prevent friction.

In-growing nail is one of the commonest affections of the feet, and is almost always met with in the great toe. The palliative treatment is to cut away portions of the nail near the inflamed surface and protect this by a small pellet of lint moistened in the borax and glycerine mixture. The employment of cocaine, however, enables the surgeon to remove the offending nail without a particle of pain, and in this way a permanent and radical cure is readily effected. I have performed this operation repeatedly after the following method: The foot and toes should be cleansed and thoroughly disinfected. An elastic ligature should be thrown around the toe, as close to the metatarsal junction as possible. The anæsthesia is effected by introducing the hypodermic needle of the cocaine-syringe beneath the skin on the dorsum of the toe, half an inch behind the nearest surface of the nail—i. e., just about the posterior border of the matrix. Three or four drops of a 4-per-cent solution are forced out here and the needle pushed under the skin, to right and left, until from fifteen to twenty minims have been injected across the toe and on either side of the nail toward the tip of the toe. The line of this injection is in the shape of a horseshoe. The needle should now be removed, and reinserted through the anæsthetized skin, and carried thence subcutaneously until the anæsthesia is complete at all points around the nail. Forty minims of a 4-per-cent solution may be employed, although half this quantity will generally suffice. In from three to five minutes insensibility is perfect. An incision is first made from the middle of the posterior margin of the nail directly backward for half an inch. A second incision across the top of the toe, extending as low down as the most inferior portion of the nail, on either side, uniting with the central end of the perpendicular cut, gives the entire wound a T-shape. The two quadrilateral flaps of skin are now dissected up, turned one to the right and one to the left side, and held away by the weight of an artery-forceps or by retractors. The nail should next be split from before backward in the middle line, the incision extending through the matrix as far back as the transverse incision through the skin. Both halves and the matrix should be thoroughly extirpated, all granulation-tissue scraped out, and the foot dipped into a basin of warm sublimate solution, 1-to-2000. At this juncture the elastic tourniquet should be removed, and the wound allowed to bleed for a minute. By this means the excess of cocaine solu-

tion is washed out of the tissues. The ligature should then be reapplied. The flaps are now brought into position, the space formerly occupied by the horny part of the nail packed with sublimate gauze, and the entire toe enveloped in the same material. A narrow bandage should be applied firmly enough to hold the gauze in place, and to exercise sufficient compression to prevent bleeding. Over this a generous piece of protective should be thrown and a second bandage applied. When, in applying this bandage, the elastic ligature is reached, it should be taken off and the roller carried on to the foot. A single dressing usually suffices, and it need not be removed for ten days or two weeks. When the nail has cut into the soft parts only on one side, a less radical procedure is advisable. The cocaine is injected along the line of the in-grown nail, and a long wedge-shaped strip of skin and subcutaneous tissue removed with the scalpel. As the wound heals by granulation, the soft parts are retracted below the level of the nail.

Deformities of the Upper Extremity—Clavicle.—Congenital absence of portions of one or both of these bones may exist. No case of complete absence of the collar-bone is as yet on record. The partial deficiency may occur on one or both sides, and is usually at the inner extremity. The indications in *treatment* are to use a figure-of-8 brace around the shoulders to prevent them from being approximated in part by the actions of the pectoral muscles.

Paralysis of the deltoid and serratus magnus muscles imparts to the shoulder a deformed appearance. In deltoid paresis the shoulder

is flattened, and the acromion process more prominent and easily recognized. The arm is incapable of being lifted to a right angle with the spine. It may be due to injury of the circumflex nerve, or to a central nervous lesion. When the serratus magnus is paralyzed, the vertebral border of the scapula is tilted outward in a position of unusual prominence. Neither of these injuries is amenable to surgical treatment.



FIG. 741.—Congenital fusion of the radius and ulna.
(From a case at the Polyclinic.)

Anchylolysis of the shoulder is more amenable to the operation of exsection than to forcible breaking up of the adhesions. This last procedure may be employed in cases of partial anchylolysis in which no inflammatory process

is going on. In *anchylosis* of the *elbow-joint* the same treatment is advisable.

Deformities of the forearm are comparatively rare. Of the congenital variety, occasionally there exists a fusion of the two bones. The length of the forearm is normal, as is the motion at the elbow-joint, but supination and pronation are impossible. In the only case I have ever seen, from which Fig. 741 is taken, the hands were in the prone position. Operative interference was not indicated in this instance.



FIG. 742.—Deformity resulting from subperiosteal exsection of the entire radius for ostitis. (From a case operated on at the Polyclinic.)

Distortions due to rickets are at times met with, and may result from the action of the muscles upon the softened bones, or to pressure from the habitual carrying of burdens in the hands. In destruction of one of the bones of the forearm by ostitis, or after its removal, deformity usually results, the deviation of the hand being toward the side of the missing bone (Fig. 742).

Treatment.—In deformity after rickets, correction by osteotomy is justifiable after the disease is arrested. In the distortions due to loss of substance there is little hope of relief. If the loss on one side is limited,

exsection of a portion of the sound bone and reunion of the divided surfaces by wire sutures might be entertained.

Club-Hand.—Distortions of the hand, not unlike those already detailed as occurring in the foot, yet far less common, may be met with. The deformity may be at the wrist-joint, in the intercarpal or carpo-metacarpal articulations, and may be due to failure of development in the bones of the forearm or hand, to muscular paralysis, to fracture, dislocations, or cicatricial contractions.

In the congenital deficiencies, the radius is more often wanting, or only partially developed, allowing the hand to be carried toward the radial side. The carpus is occasionally deficient. Not infrequently the congenital cases are symmetrical, and the lower extremities are also involved.

The muscles are deficient in some of these cases of osseous malformation. The usual condition in paralysis is that of flexion of the carpus and metacarpus upon the forearm.

This variety is termed *palmar*; the opposite, *dorsal club-hand*. When the displacement is lateral it is called *radial* or *ulnar*, as the hand is carried outward or inward. As in club-foot, there are compound forms of club-hand.

As to frequency in the congenital types, the radius being chiefly at fault, the *radial* distortion is most frequent. When from any cause the equilibrium between the muscles is impaired, the hand is usually flexed upon the forearm, and the condition is known as palmar club-hand. With this there may be radio-palmar or ulno-palmar deformity.

Fracture of the radius (Colles's), or epiphyseal separation, may induce a mild form of radial club-hand. Unreduced dislocations will, of course, cause deformity. Deformities due to cicatricial contraction, as after burns (Fig. 148), extensive phlegmons, etc., are occasionally met with.

The treatment of all these different varieties of club-hand will depend upon the particular cause. In the worst form of congenital deformity, amputation at or shortly after birth should be performed. Other and milder cases may be improved by mechanical apparatus constructed to meet the indications.

In muscular paralysis the same general rules of practice as laid down in club-foot due to this cause should be followed. *Tenotomy* may be necessary. The extensors may be subcutaneously divided about the middle of the metacarpal bones. The flexors slightly above the wrist-joint. The lateral deformities also will justify in some cases division of the contracting muscles. The rule to be followed is to do subcutaneous tenotomy when the tendon to be divided is far enough away from any important nerve or vessel to allow a perfectly safe and sure division of the tendon; if not, the tendons should be exposed by incision under strict antisepsis, and each one picked up on an aneurism-needle and divided in plain view.

The propriety of breaking up adhesion in ankylosis with malposition, or of resection, should be determined by the condition of the parts and of the patient, and the necessities of the case.

The Fingers and Hand.—Among the *congenital* deformities of the fingers are polydactylus, syndactylus, and web-finger, or fusion of two or more digits. The *acquired* deformities are due to contraction of the palmar fascia, of the muscles and tendons, to paralysis of certain muscles, and to osseous and articular lesions, both traumatic and idiopathic.

Supernumerary Finger (Polydactylus).—The usual location of one extra finger is on the radial side of the thumb or ulnar aspect of the little finger, near the metacarpo-phalangeal junction (Fig. 743). It may or may not possess phalanges or cartilages. If the phalanges exist, a synovial cavity will be found at the junction with the metacarpal bone, or with the phalanx of the normal member.

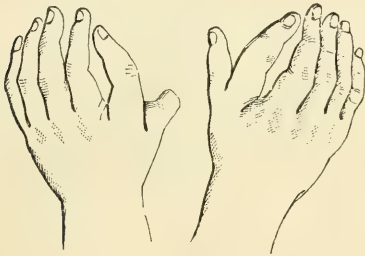


FIG. 743.—Supernumerary digits. (After Reeves.)

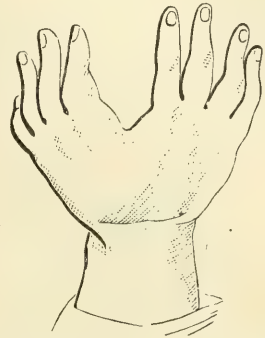

FIG. 744.—Double hand. (After Reeves.)

A rare form of supernumerary fingers is shown in Fig. 744, in which there is practically a double hand. Amputation of the supernumerary members should be made soon after birth.

In syndactylus, all or a portion of one or more fingers may be wanting (Fig. 745). Amputation of the deformed portion is usually advisable.

Web-finger is usually congenital, although it may be acquired. In mild cases, where the union between the contiguous surfaces is slight,

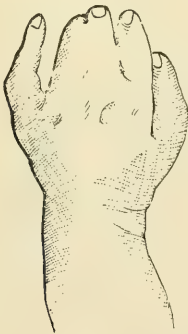

FIG. 745.—Stunted and webbed hand. (After Reeves.)

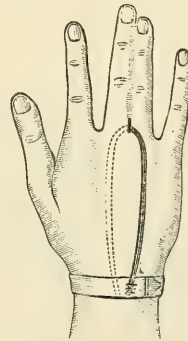


FIG. 746.—Elastic ligature passed through the web. (After Fort and Noble Smith.)

and the web is thin, the following method will succeed: A round elastic ligature or cord is carried through the web just in front of the metacarpo-phalangeal articulation, and the ends are turned back and attached to a band around the wrist (Fig. 746). This is allowed to remain for three

or four weeks, until the hole made by the ligature is lined with epidermis. A second puncture should now be made about one inch in front of the first, the ligature passed through this, and the ends tied. The constant traction of the elastic gradually cuts through the web, yet so slowly that the track of the wound becomes covered with epidermis. This procedure should be repeated until all the web is divided.

When the fingers are solidly united, the method of Didot should be preferred. An incision is made down the palmar surface of one finger (the index, Fig. 747) and along the dorsal surface of the adjoining member (the middle finger). The flaps are dissected up so that the one removed from the palmar surface of the index-finger remains attached to the middle finger, while the posterior flap is attached along the dorsum of the index-finger. They are then sutured in position (Fig. 748).

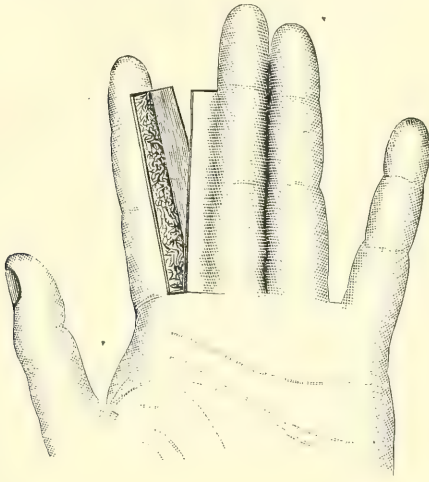


FIG. 747.—Didot's method of operating for web-fingers. (After Fort and Noble Smith.)

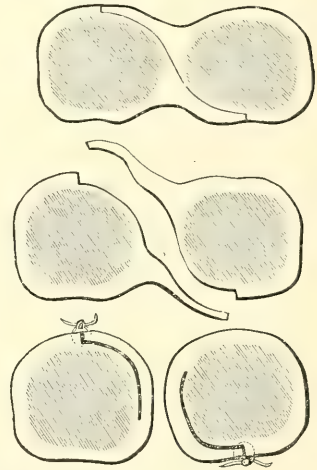


FIG. 748.—Transverse sections of the webbed fingers, showing in the upper figure the line of separation between the two flaps; in the middle, the outline of the separated flaps; below, the sutures are applied. (After Fort and Noble Smith.)

In those cases in which the bones are only slightly united, the line of union may be sawed through. When the bones are fused into one solid mass, an operation is not indicated.

Chronic flexion of one or more fingers may result from paralysis of the extensor muscles, spastic contraction of the flexors, or to contractions of the palmar and digital fascia. Paralysis of the extensors may be temporary or permanent. Lead-poisoning not infrequently leads to temporary impairment of the function of this group of muscles.

In neglected cases of chronic extensor paralysis, permanent shortening of the opposing muscles, with contraction of the palmar fascia, occurs.

The indications in treatment are to restore, if possible the functions of the paralyzed muscles, and to prevent deformity by the adjustment of an apparatus which will keep the fingers extended.

Contraction of the palmar fascia, as a result of any inflammatory pro-

cess, gives rise to the most common deformity of the fingers. Penetrating wounds of the palm, or idiopathic phlegmon, are exceedingly apt to result in fascial contraction and chronic malposition of the fingers.

This process takes place at times in persons of the gouty or rheumatic diathesis without any marked symptom of local inflammation. The tendons are not affected, as a rule,

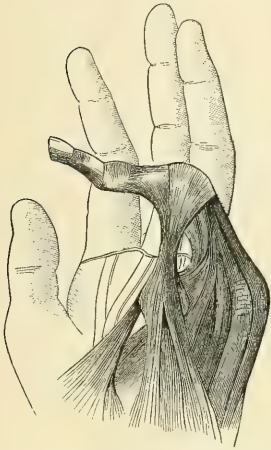


FIG. 749.—Dupuytren's contraction in the fascia of the palm and of the little finger. (After Noble Smith.)

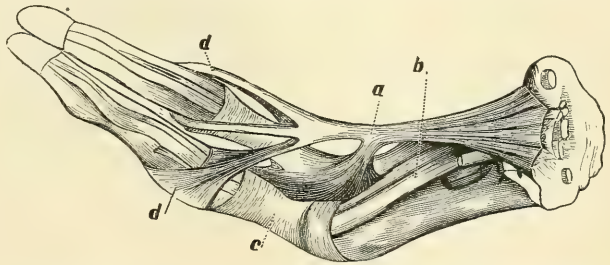


FIG. 750.—The same, in the middle and ring fingers. *a*, Contracted band of palmar fascia. *b*, Flexor tendons (not involved). *c*, Sheath of tendons. *d*, Digital prolongations of palmar fascia. (After W. Adams and Noble Smith.)

in the earlier stages of *Dupuytren's* contraction. In old cases the muscles are shortened. The fascial contractions are well shown in Figs. 749 and 750.

Treatment.—In mild cases, taken early in the commencement of the affection, a cure may be effected by repeated stretching of the fascia by fully extending the fingers involved. The instrument shown in Fig. 750 A, devised by Dr. Battey, of New York, will be found very useful in such cases. In obstinate cases fasciotomy is demanded. Division of

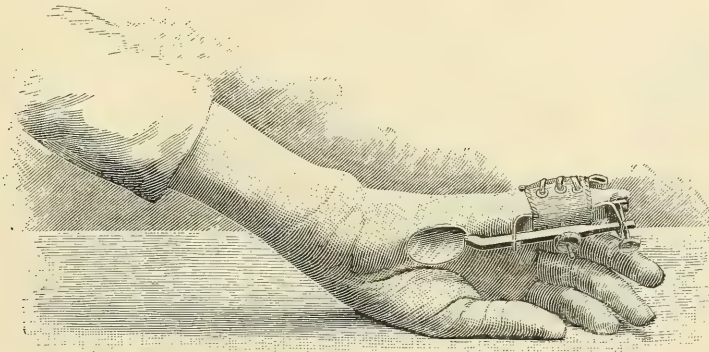


FIG. 750 A.

the palmar fascia should be done as follows: The hand should be rendered thoroughly aseptic by washing in sublimate solution, and made bloodless by Esmarch's bandage. The hypodermic injection of 4-per cent cocaine solution renders the operation painless. The delicate fascia-knife (Fig. 59) should be introduced beneath the bands of fascia, which can be made prominent by extreme extension of the fingers, the

edge turned upward, and a thorough division effected, taking care not to allow the knife to cut through the skin. Every resisting band should be divided until the fingers can be readily brought into a position of over-correction. Two or three lines of section may be made in the palm and one or two through the digital prolongations of the fingers involved. By carefully inserting the knife closely beneath the fascia, the vessels of the palm and fingers may be avoided. The palm should be covered with a thick layer of sublimate-gauze, and a splint applied in order to keep the fingers perfectly straight. This should be worn for two or three weeks, at which time passive motion should be made and the splint reapplied for another week. After it is removed, thorough extension should be practiced at least once a day for several months.

Snap- or Jerk-Finger.—This name has been used to designate a condition in which free extension and flexion of one or more fingers is more or less interrupted. As the affected digit is being flexed or extended, motion is arrested in a certain position, and, if a violent effort is made, or if flexion is continued by aid from the other hand, a perceptible jerk occurs as the obstruction is overcome. A nodular swelling, to the touch resembling the ganglia often met with on the back of the wrist, may be felt along the line of the tendon at or near the metacarpo-phalangeal joint. Snap-finger may be due to a circumscribed thickening of the tendon, or a disproportion between the size of the tendon and sheath for a limited area. This condition is believed to exist, especially in the thumb, where the jerk occurs in one third of all cases. Mr. Reeves thinks that in the fingers it is chiefly due to the synovial fringes catching upon the transverse process of the palmar fascia. This may occur not only “from thickening of this process of fascia, but also from rolling up or displacement of the synovial sheaths.”

Snap-finger may be traumatic or idiopathic in origin. Strains on the tendons and fascia in the act of lifting, direct violence, as well as the gouty and rheumatic inflammations, are noted in the ætiology. The treatment consists in passive motion, and internal medication to correct any dyscrasia. If relief does not follow ordinary measures, an incision should be made and the enlargement dissected out.

In certain cases in which adhesion of the tendons to their sheaths and to the palmar and digital fascia occur chiefly as a result of penetrating wounds, it will—in order to relieve the deformity—be required to make an open dissection and divide the adhesions in plain view. Such operations can be done with impunity, and with an extraordinary degree of success, if the strict antiseptic precautions are observed. Esmarch's bandage is essential to the operation, and cocaine anæsthesia I have frequently demonstrated to be perfectly satisfactory in these procedures. The wound should be closed at once with fine silk sutures. Catgut is not sufficiently reliable in this region. The danger of inflammation and contractions of the fascia from opening into the hand under sublimate irrigation and careful antiseptics are exceedingly remote. Even the most extensive injuries of the hand may be made to heal with as little deformity as often follows a simple wound in which inflammation and suppu-

ration are established. Figs. 751 and 752 are taken from a hand one year after the receipt of a gunshot-wound. The muzzle of the piece was in contact with the skin at the time of the explosion, and the charge of

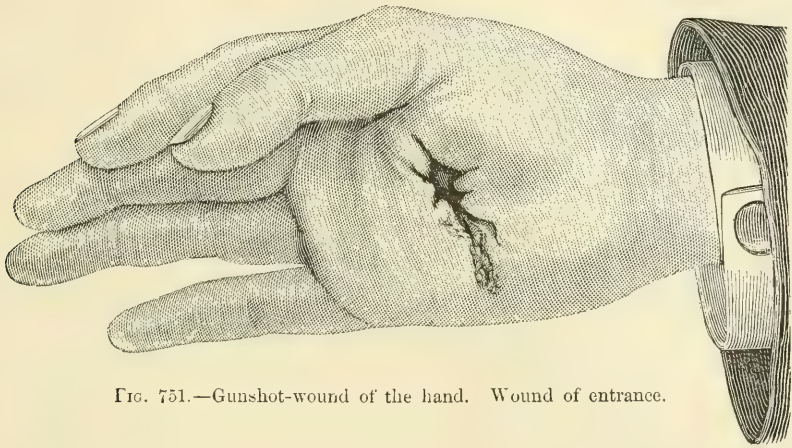


FIG. 751.—Gunshot-wound of the hand. Wound of entrance.

small shot and wadding entered at the palmar aspect of the little finger, and passed out through the metacarpal bone of the index-finger and to the ulnar side of the thumb. The third and fourth metacarpal bones

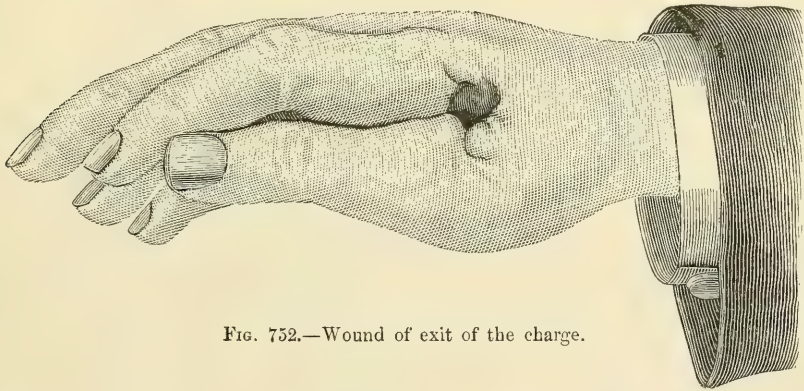


FIG. 752.—Wound of exit of the charge.

were broken, while the second was comminuted and almost all of it blown away. The flexor tendons and fascia of the palm were torn and divided. The treatment consisted in immersion of the member in 1-to-2000 sublimate solution, thorough removal of powder and all foreign matter, reposition of attached fragments of bone and shreds of tendons, fascia, and muscle in as near their normal relation as possible, and applying a sublimate-gauze dressing, placing the hand in the natural position and holding it there with a splint and roller. In this case motion was secured in every finger, and no contractions of the fascia have taken place.

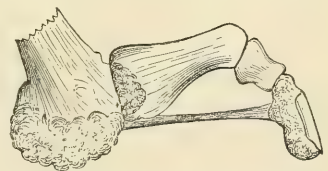


FIG. 753.—Deformity resulting from exostosis. (After Annandale and Noble Smith.)

When the tendons are divided, either in the forearm near the wrist, or in the palm or along the fingers, it is essential that the divided ends be stitched together with silk sutures. Cocaine anæsthesia and Esmarch's bandage should be employed.

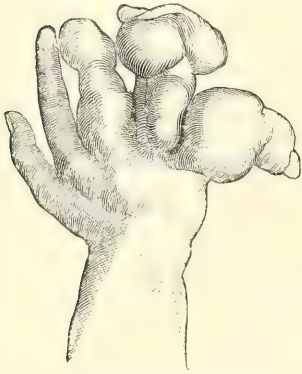


FIG. 754.—Deformity resulting from chondroma of the phalanges.

Deformities of the hand and fingers also result from exostosis and new formations of cartilage in the digits (Figs. 753 and 754). Amputation is indicated in the latter condition, while in exostosis relief may be obtained by direct incision and removal of the offending bone.

Phlegmon of the Hand and Fingers.—Phlegmon of the fingers is an exceedingly painful affection. Occurring, as it usually does, in the terminal phalanx, a knowledge of the arrangement of the fascia here is essential to proper treatment. Fig. 754 A shows the intimate attachment of the connective-tissue fibers to the integument of the palmar aspect of the digit and to the matrix of the nail, the separation of the various layers to form spaces in which are contained quantities of fat. The general convergence of these bundles of connective tissue toward the center is well illustrated in the cut. They are intimately attached to the sheath of the tendon in front and to the periosteum posteriorly. The lymph-channels follow the layers of fascia from the skin toward the bone. Phlegmon of the finger (“*felon*,” or “*whitlow*”) may originate in the bone or periosteum, but most frequently begins in the soft tissues. On account of the arrangement of the fascia and lymphatics, the inflammation rapidly extends to the tendon or periosteum. The dense structure of the tissues here, which prevents their yielding to the pressure of the inflammatory infiltration, will account for the unusual degree of pain present in this affection.

Phlegmon of the palmar aspects of the thumb or little finger, not relieved by early incision and disinfection, may extend along the sheaths of their tendons and invade the entire palmar fascia. Conversely, central phlegmon of the palm of the hand may radiate to these digits (Fig. 754 B).

By reason of the anatomical arrangement of the sheaths of the ring, index, and middle fingers, closing as they do in blind extremities at the

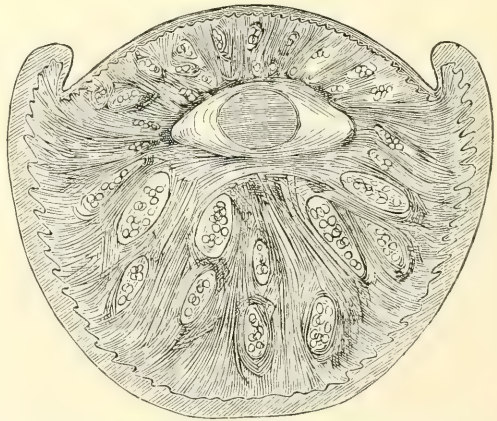


FIG. 754 A.—Showing the converging arrangement of the dense connective-tissue bundles in the finger around the last phalanx. (After Vogt.)

metacarpo-phalangeal articulations, the inflammatory process does not extend, as a rule, into the large synovial sac beneath the palmar fascia (Figs. 754 B and 754 c). Upon the back of the hand and fingers phlegmon behaves as it does beneath the skin in other parts of the body.

In the *treatment* of *whitlow* the first indication is to relieve tension at the earliest moment by puncture or incision. The

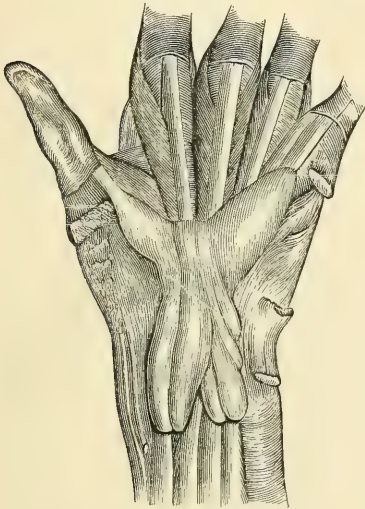

FIG. 754 B.—Showing by injection the continuity of the synovial sheaths of the little finger and thumb with the large sac beneath the palmar fascia. (After Vogt.)

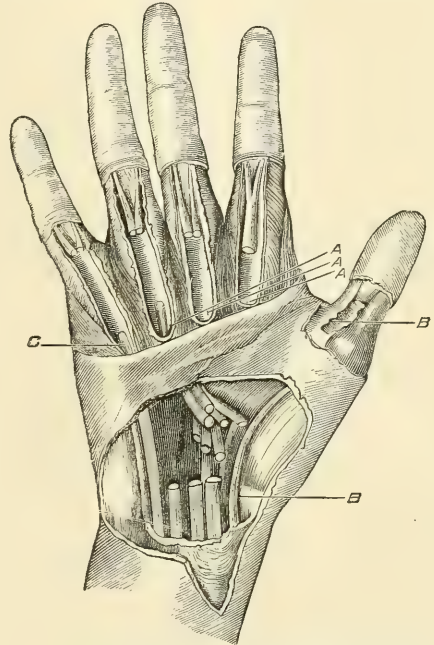


FIG. 754 C.—Showing at A A A the sheaths of the ring, middle, and index fingers ending in blind extremities toward the palmar sac. (After Vogt.)

exact point of inflammation in the earliest stage of phlegmon may be recognized by direct pressure with a small pointed instrument, as a probe or director. Cocaine may be utilized to prevent pain when the incision is made. A rubber ligature tied around the finger to arrest the circulation, and a few minims injected into the line of incision, will deaden all sensibility. The incision should be free, and down to the tendon or bone, to insure relief of all tension. The part should then be submerged in warm sublimate solution, the ligature removed, and, after a minute or two of bleeding under water, an iodoform strip should be packed into the wound, and a moist aseptic dressing applied.

When pus has formed and can be evacuated in this manner, the opening should be made upon the lateral aspects of the finger, in order to avoid the sheath of the tendon.

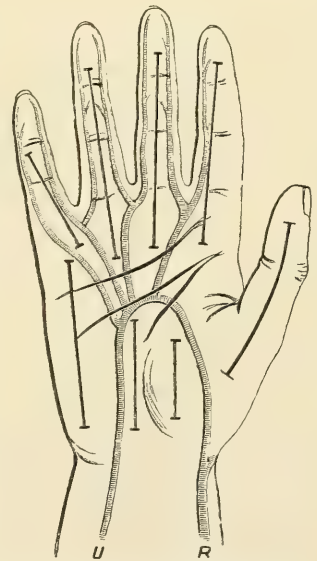


FIG. 754 D.—Showing outline relation of arteries, and line of incision which may avoid the more important vessels. (After Vogt.)

In phlegmon beneath the palmar fascia the same principles of incision and drainage should be applied, avoiding the larger vessels when possible (Fig. 754 D).

Ganglion.—Ganglion is due to the localized collection of a variable quantity of synovial fluid in the sheaths of the tendons, or bursæ on the dorsum of the hand or wrist. Excision and dissection under cocaine anæsthesia, and strict asepsis, I have found to be the most satisfactory means of effecting a cure. They may be made to disappear by absorption, after subcutaneous rupture from a sharp blow with the back of a book or padded hammer.

CHAPTER XXII.

TUMORS.

THE word *tumor* (from *tumere*, to swell) was formerly applied to any abnormal formation or collection of matter within the body. The over-accumulation of fecal matter in the colon, the swelling due to extravasation of blood, or to the retraction of a muscle after rupture of its tendon; an abscess, a retention-cyst, a hernia, a floating or displaced kidney, as well as all the recognized non-inflammatory neoplasms, as sarcoma, fibroma, lipoma, carcinoma, etc., were ranged under the comprehensive heading of *tumors*.

Of late years the application of the term has been more restricted. A tumor is now defined to be a *circumscribed, non-inflammatory mass, composed of new-formed elements which, having their type in the normal embryonic or adult tissues, are dependent upon these for nutrition, and yet are not amenable to the laws regulating and limiting the development of the normal structures.*

Circumscribed, because a general or wide-spread hypertrophy or hyperplasia does not convey to the eye or touch the idea of a swelling or tumor. The accumulation of fat in obesity can not be called a tumor, yet the fat so deposited over a wide area differs in no essential particular from that which forms a lipoma.

Non-inflammatory, for the reason that this most clearly separates true neoplasms from the cell-proliferation of the ordinary inflammatory process, with its characteristic *heat, pain, and redness*, as well as *swelling*.

New formations in this, that although the law established by Johannes Müller—that the elements of all tumors, no matter how changed from the normal, spring from and have their types in the normal tissues of embryonic or adult life—stands unquestioned, yet these elements, in their changed conditions, tend to persist or to grow indefinitely, in utter disregard of the laws of limitation in the development of normal tissues.

The efforts at classification of tumors upon a histological basis have not been generally satisfactory. Virchow, Foerster, Cornil and Ranvier, and other pathologists, with the same end in view, have arrived at conclusions scarcely reconcilable. A discussion of these various classifications belongs more properly to special works on pathology. Clinically, they admit of division into two heads—the *malignant* and *non-malignant*.

Malignancy in a tumor means its tendency to become multiple by metastasis; the tendency of the elements of which it is composed to travel along the lymph- or blood-channels, and, thus disseminated, to reproduce the parent tumor; or its tendency to invade and destroy the tissues in its vicinity, and to recur *in loco* after extirpation.

Strictly speaking, the tendency of a neoplasm to induce death has nothing to do with the question of its malignant character, for certain tumors, as fibro-myomata of the uterus and simple ovarian cysts, tend to produce death as well as carcinomata and sarcomata.

The malignant neoplasms are grouped under two headings—*carcinoma* and *sarcoma*.

The non-malignant are as follows: *lipoma*, *fibroma*, *myxoma*, *osteoma*, *enchondroma*, *angioma*, *neuroma*, *myoma*, *adenoma*, *papilloma*, and *lymphoma*.

Carcinoma.—A cancer may be defined to be a tumor, composed of *embryonic cell-elements* of varying shape and proportions, collected in groups, which groups or clusters are partially separated by a well-defined *stroma*.

While the elements of the carcinomata do not always differ so widely from those of the sarcomata (especially the more embryonic cells of this last neoplasm), the alveolar structure of the stroma of cancer will always render it easy of recognition.

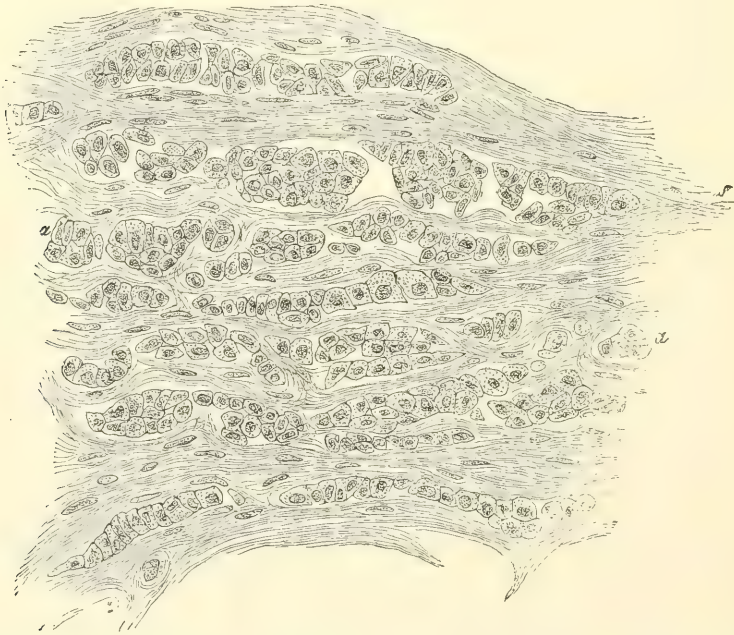


FIG. 755.—Development of carcinoma. *s*, Bundles of fibrous tissue containing occasional connective-tissue corpuscles. *a*, Cancer-cells in groups or rows between the stroma. (After Cornil and Ranvier.)

Cancer-cells vary greatly in shape and dimensions, being round, flat, ovoid, fusiform, polygonal, and measuring from $\frac{2}{500}$ to $\frac{1}{1200}$ and $\frac{1}{500}$ inch in diameter. Each cell may contain one or many nuclei. The nucleus

is often of large size, at times occupying the greater portion of the cell-space. The nucleoli are especially prominent. The cell-elements of carcinoma are contained within the alveoli, and float in or are in contact with a juice of varying quantity and consistence.

The walls of the alveoli are composed of a fibrillated structure of modified connective tissue. In old tumors the fibers of the stroma are closely packed together, while in more recent neoplasms connective-tissue corpuscles are frequently observed between the clusters of cells (Fig. 755). The alveolar arrangement of the stroma is well shown in Fig. 756, in which the cancer-cells have been removed.

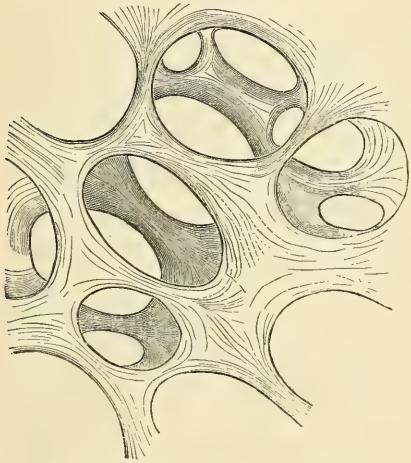


FIG. 756.—Stroma of cancer from which the cell-elements have been removed. (After Cornil and Ranvier.)

The alveoli are not isolated cavities, but communicate more or less freely. In the connective-tissue walls of the alveoli the blood-vessels and lymph-channels are lodged. In the development of a carcinoma the proliferation among the cells proper of the neoplasm excites a similar condition in the connective-tissue cells of the neighboring and involved tissues, and, coincident with the multiplication

of the cancer-elements, the connective-tissue elements are developed. In this way the stroma is formed around and among the cancer-cells, and in rare instances this proliferation is so rapid that clusters of adipose cells are caught within the neoplasm and remain as such in the process of growth in the tumor.

Carcinomata spread by direct invasion of contiguous tissues, and along the route of the lymph-channels.

It is not uncommon (as established by Cornil and Ranvier) for induration and hypertrophy of the ganglia of the nearest lymph-plexus to occur before metastasis has taken place, a fact of great interest to the surgeon. This early glandular hyperplasia is due to the irritation caused by the neoplasm, and though less acute is not unlike the adenitis of an ordinary inflammatory process.

Three chief varieties of cancer are recognized—the *scirrhous*, *encephaloid*, and *mucoid* or *colloid*. *Epithelioma* will also be included under this heading.

Scirrhous, or hard cancer, is distinguished by the greater proportion and thickness of the *stroma*, in comparison with the cell-elements. Many of the cells in this variety of neoplasm, especially those more deeply situated, undergo extensive granular metamorphosis, and appear as granular corpuscles, having lost all the characteristics of the cancer-elements.

Encephaloid, soft, or medullary cancer is rich in cells and cancer-juice, while the stroma is very thin. It is more vascular, and in gross appearance is like broken-up brain-matter; hence the name encephaloid.

Owing to the embryonic character of the new-formed blood-vessels and the lack of resistance from the scantily developed stroma, aneurismal dilatations of the vessels are common, and rupture frequently occurs.

Colloid cancer is characterized by the presence within the alveoli of a fluid rich in mucin, which substance also appears in all the foci that may be developed by metastasis. Many of the cells disappear, and those which remain are unusually large and swollen. The alveoli are also distended and the walls more translucent than in scirrhus.

The changes which cancers undergo are chiefly granular metamorphosis and ulceration. The cells of the deeper portions of the neoplasm, deprived of sufficient nourishment by reason of their central position, break down in a granular detritus, which is absorbed and carried away in part by the blood-vessels, but chiefly by the lymph-channels. In older tumors this gradual loss of cellular elements is followed by contraction of the stroma and sinking in or retraction of the integument. Inflammation and ulceration of a cancer may result from direct irritation from without, or may occur as a result of the growth of the neoplasm, which thus often cuts off its own nutrition. The process is not unlike ulceration in the normal tissues, only the granulations are often very exuberant and the death of tissue rapid. All forms of carcinoma are subject to the deposit of pigment, and under such conditions have been termed *melanotic* cancer.

Causes.—Cancer is a disease of adult and of late adult life. Scirrhus, encephaloid, or colloid cancer, under twenty years of age, is exceedingly rare. It occurs chiefly in the period of life between thirty and sixty. Women are more frequently attacked than men. The influence of heredity upon the production of carcinoma is believed to be established, although its importance has been greatly overestimated. Prolonged irritation is undoubtedly the chief exciting cause of the development of this neoplasm. In evidence of this conclusion is the fact that those portions of the body which are subjected to the greatest amount of irritation are most often affected. The mammary gland, pylorus, rectum, and uterus, are the more common locations of cancer.

Diagnosis.—The recognition of cancer is positive only by microscopic examination, and depends in part upon the peculiar characters of the cells already noted, but chiefly upon the appearance of the stroma. Clinically, the diagnosis will depend upon the age of the patient, the location of the tumor, its consistence, immobility, and the condition of the lymphatic glands in the line of the vessels toward the center. A tumor occurring between the ages of thirty and sixty, of a mildly painful character, the pain sharp and lancinating, and increased when firm pressure is exercised; steadily, although at times slowly, enlarging, movable, it may be, beneath the skin or within the substance of the organ or part in which it is located, yet not freely so, should be looked upon with suspicion. If it has existed for several months, and there is retraction of the integument over a portion of the mass, together with induration of the nearest lymphatic glands, the diagnosis of cancer is almost positive. As between the three different forms of cancer, it may

be said that scirrhus is much the more common, is slower in growth, and harder to the feel. Colloid is also hard, and grows slowly, and from palpation and inspection can not be differentiated from scirrhus with any certainty. It is comparatively rare. Encephaloid is a soft, elastic tumor, not always of uniform consistence, but generally of smooth surface, and always of rapid growth. Its vascularity is therefore much more noticeable than that of either of the other varieties, and metastasis is more rapid. As between sarcoma, the chief diagnostic points are the age of the patient, sarcoma being more common in the young, cancer in the old and middle-aged; the lymphatics are not involved in sarcoma, except when extensive ulceration and septic absorption occurs; in general, the superficial veins of sarcoma are more dilated and perceptible, and the tumor more elastic.

As far as the treatment is concerned, the differentiation between carcinoma and sarcoma is not essential. The indication, when operative interference is at all justifiable, is extirpation of the mass by a dissection which should be well away from the limits of the neoplasm. In cancer the neighboring lymphatic glands should be extirpated if metastasis has occurred, while in sarcoma this is not indicated. In fact, in all neoplasms not positively innocent, removal should be made imperative. The slightest doubt of the character of the tumor is entitled to the interpretation of malignancy, the justification of this conclusion being found in the well-established fact that an innocent neoplasm may become malignant.

The excision of a portion of a tumor for microscopical examination for purposes of diagnosis will rarely be justifiable. Any irritation of the mass is reprehensible, since metastasis is more apt to occur under such conditions.

Epithelioma.—An *epithelioma* may be defined as a neoplasm, the embryonic elements of which assume, in a varying degree, the shape and arrangement of the normal epithelium. Developing usually in the skin or mucous membranes, they at times originate in tissues remote from them, as in the bones.

Malignant epitheliomata may be divided into two classes: 1, the lobular; 2, the tubular. Tubular epithelioma may consist of (*a*) flat or round cells, (*b*) columnar or cylindrical cells.

The first variety is by far the more common, and of greatest clinical interest. It occurs by preference upon the muco-cutaneous surfaces, as the lips, prepuce, anus, vulva, etc., but may appear either upon the skin or mucous surfaces, remote from any line of union of these coverings, as the tongue, cheek, face, etc.

Epithelioma usually begins as a nodule or induration of small size, slightly reddened at its margin, the center of which very early in its history breaks down into a dirty ulcer which, when kept fairly clean, is reddish in color, and, when not cleansed, is covered with a grayish mass of pus and broken-down tissue, either solidified into a crust or scab, or in a softened state. The margins of the ulcer are sinuous, hard, and everted. It may limit itself to a small area, or develop steadily, and sometimes with great rapidity until, after extensive destruction of the

tissues in its neighborhood, death ensues from hæmorrhage, sepsis, or metastasis. Pain is always a symptom of this disease. Lymphatic engorgement may occur in the first few weeks, but usually from four to eight months, and even a longer time, may elapse.

Examined microscopically, this form of epithelioma is seen to be composed of flattened cells, containing one or several nuclei, with a tendency on the part of the elements to form themselves in concentric layers (Fig. 757). In the center of these spheres of flattened epithelia are frequently seen a few cells which have undergone the colloid change. Farther out the surrounding cell-elements are more embryonic in character, cylindrical, spherical, or polygonal from lateral compression, the mass being limited externally by a stroma of connective tissue, varying in quantity, which separates one epithelial nest from the others composing the entire neoplasm. In the process of ulceration an epithelioma is surrounded by a zone of embryonic tissue due to the cell-proliferation of the inflammatory process.

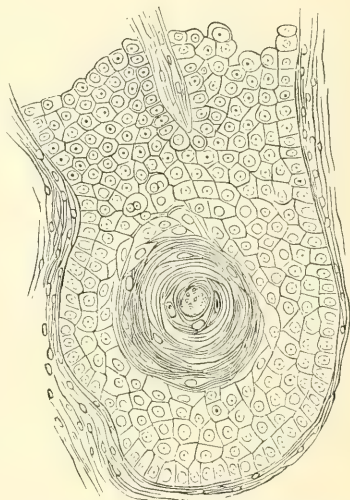


FIG. 757.—Lobular or spherical epithelioma, 250 diameters. (After Cornil and Ranvier.)

Flat or Round, and Columnar or Cylindrical-Cell Epithelioma.—Tubular epitheliomata are somewhat less malignant than the lobular or bird's-nest variety just described.

After reaching a certain stage in their development, they may remain stationary; but, in the majority of instances, the tendency is to grow, as well as to recur after removal. They are usually situated upon the skin, where they originate in the sweat-glands or upon the mucous membranes, where they spring from the follicles of these surfaces. The antrum maxillare is occasionally the seat of this variety of neoplasm.

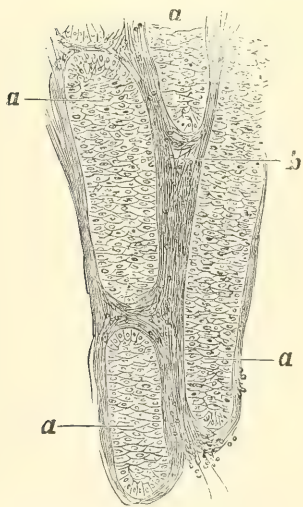


FIG. 758.—Tubular epithelioma. *a*, Tubules or cylinders cut obliquely. *b*, Connective-tissue stroma. (After Cornil and Ranvier.)

Microscopically, the flat-celled epitheliomata are composed of pavement or tessellated cells, crowded in tubules or cylinders, which are long, more or less irregular in shape, at times anastomosing with each other, and are held together by a stroma of connective tissue (Fig. 758).

The general shape of these neoplasms is oval or round. They grow more slowly than the preceding variety.

Columnar-celled cylindrical epithelioma is met with in the deeper organs, as the alimentary canal and other abdominal viscera, uterus,

ovaries, etc. It differs from the preceding in the shape of the epithelia which line the tubules. The cells are columnar, set on end, contain one or more nuclei, and may exist in a single layer or as several rows of cells piled on each other. The framework or stroma is composed of connective tissue, which may have a fibrillated arrangement, or it may remain in an embryonic condition (Fig. 759).

The prognosis of these tumors is unfavorable. They are rarely recognized at a period early enough in their history to allow of a thorough removal. Those of the os and cervix uteri, ovaries, rectum, and nose are most easily removed.

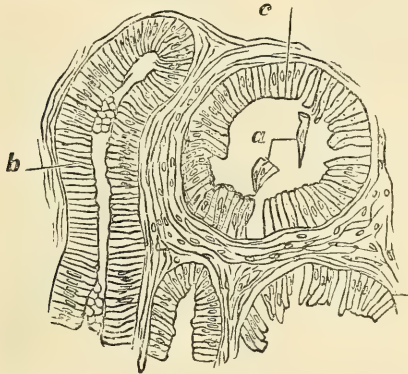


FIG. 759.—Tubular epithelioma with cylindrical elements. *a*, Tubule cut across. *b*, Tubule cut in its long axis. *c*, Cylindrical epithelia. (After Cornil and Ranvier.)

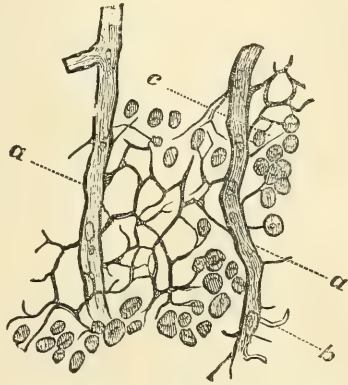


FIG. 760.—Reticular structure of a lymphatic intestinal follicle. *a b*, Capillary vessels with nuclei in their walls. *c*, Meshes of the reticular structure containing lymphatic corpuscles. (After Frey.)

Lymphadenoma.—This variety of neoplasm is entitled to be classed with the malignant tumors. It consists of new-formed lymphatic gland-tissue, and may occur in pre-existing glands or in any of the tissues of the body. The liver, spleen, and kidneys, the testicle, the alimentary canal, the bones and integument, may all be the seat of these new formations. Coincident with the development of these neoplasms, the proportion of white blood-corpuscles in the volume of blood is enormously increased, until death ensues from leucocythæmia. These tumors may be of any size, from a millet-seed up to several inches in diameter, are soft to the touch, and usually not well defined. They can not be diagnosed from other gland-tissues unless examined microscopically, when they are seen to consist of a connective-tissue framework or reticulum, along the fibrillæ of which run the capillaries, and in the meshes of the reticulum the lymph-corpuscles are situated (Fig. 760).

The prognosis is grave, and the condition does not justify surgical interference.

Sarcomata.—A sarcoma is a tumor the elements of which have their type in the normal connective tissues. The cells of a sarcoma may be purely embryonic, or may, in a certain sense, resemble the more developed elements. They are, however, not capable of organization into a permanent tissue.

Classified according to the shape and size of the cell-elements which

preponderate in their composition, they are called—1, *round*; 2, *spindle*; 3, *giant-cell* sarcoma.

The cell-elements of the sarcomata not only vary in size and shape, but in the number of their nuclei, of which there may be from one to thirty or more. In the more fully developed or spindle-celled neoplasm, the elements are arranged in bundles which run in all directions. These tumors possess little or no intercellular substance, the elements resting in contact or separated by the blood-vessels which freely permeate them. The richness of the blood-supply and the proportion of the tumor occupied by these channels are well shown in Fig. 761.

The size and number of the blood-channels depend upon the structure of the tumor, the round-cell sarcoma being most vascular, while the vessels are less numerous and of smaller caliber in the spindle-cell variety.

The intercellular substance also varies in quantity, being scarcely perceptible in the round-cell tumor, and more distinct in the spindle or fusiform variety. In some of the sarcomata normal connective-tissue fibers may exist, and these are believed to have been caught in the development of the neoplasm.

The sarcomata in general develop with great rapidity, and tend to invade or infiltrate the structures in their immediate neighborhood. In this the different forms of tumor also differ. The round-celled neoplasm grows more rapidly than the others, and is more apt to invade the surrounding tissues than the fusiform-cell variety. It is not the rule for these neoplasms to become encapsuled, although this may occur in the spindle- or giant-cell variety.

The three varieties of cells may exist in the same tumor. According to Cornil and Ranvier, a careful search will reveal the presence of giant cells in varying numbers in almost all sarcomata.

The retrogressive changes which these tumors undergo are fatty and calcareous degeneration. The deeper cells of tumors of considerable size—in other words, those farthest removed from the supply of nutrition—very commonly undergo the fatty or granular metamorphosis. Not infrequently this granular metamorphosis proceeds so rapidly that the blood-vessels of the tumor become occluded with the fatty detritus (granular infarction). In this way the nutrition in certain portions of the growth is interfered with, increasing the area of fatty metamorphosis, or inducing gangrene from a sudden arrest of the blood-current.

Calcareous degeneration occurs in certain of the sarcomata irrespective of their being situated in the neighborhood of bone. Pigmentation occasionally occurs, and this form is at times separately classified as me-

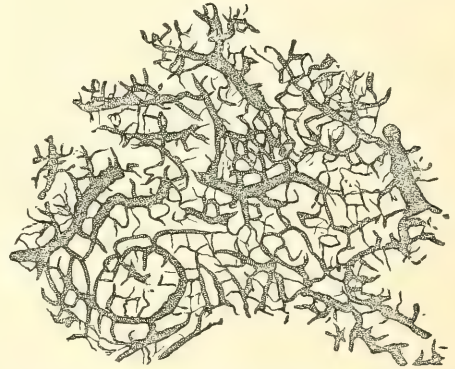


Fig. 761.—Injection of the vascular network of an osteo-sarcoma. (After Billroth.)

lanotic sarcoma. It is apt to take place in the small, round-cell tumors. Acute inflammation in a sarcoma is almost always followed by the proliferation of an exuberant granulation-tissue, with more or less extensive gangrene and death of the mass. Excessive and at times fatal hæmorrhage may occur in the process of sloughing.

A common accident in the evolution of a sarcoma is the extravasation of blood from rupture of the walls of the new-formed vessels. Such is the crude condition of these tumors that even the cells which compose the vessels are embryonic, and readily give way, allowing the escape of blood among the cell-elements and intercellular spaces. The more nearly the development of the cells approaches a normal tissue, the less probability there is of extravasation. The blood thus escaped may be absorbed or become encapsuled by pressure upon the cells near the point of rupture and become converted into a blood-cyst.

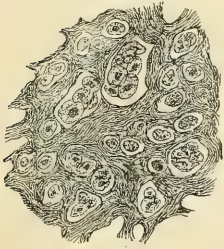


FIG. 762.—Alveolar sarcoma. (After Green.)

Mucoid degeneration is also occasionally met with in these neoplasms. The cells of certain portions of the tumor disappear, leaving cysts or alveoli varying in size from the smallest up to as large as two or three inches in diameter in large tumors. The cysts are occupied by an amber-colored or reddish-brown fluid, which, examined with the microscope, demonstrates the presence of blood-corpuscles in various conditions of degeneration. Chemically, the fluid yields *mucin*. The name *alveolar* sarcoma (Fig. 762) has been given to this form of tumor.

Clinical Features.—Sarcomata may be met with in all conditions and at any period of life. Comparatively speaking, they are rare in old age, occurring chiefly in children and adults under thirty. Occasionally they are congenital. Both sexes are equally liable to be attacked. They are, as a rule, idiopathic in origin, in rare cases being due to, or at least following, an injury to the part involved in the neoplasm. Sarcomata are among the most malignant new formations, not only recurring *in loco* after removal, but tending to be disseminated by the blood-vessels. Unlike the carcinomata, they have no lymph-channels, and metastasis must occur by the blood-vessels which enjoy free anastomoses with the caverns and sinuses of the neoplasms.

The degree of malignancy of a sarcoma is, in general, in proportion to the embryonic character of the elements of which it is composed. Thus, the round-celled tumors of rapid development are most malignant, the spindle-celled next, the giant-celled last in this order.

As to location, no tissue is exempt. They are frequently met with in the skin and subcutaneous tissues (Fig. 763); also the osseous tissues, especially the long bones, furnish a favorite seat for them. Those developing from within are chiefly the myeloid or giant-celled variety; those of periosteal origin are round- or spindle-celled.

Sarcoma of the bones, according to Prof. S. W. Gross, who has written a most exhaustive paper upon this subject, is exceedingly malignant, being only second to cancer of the soft tissues.

From the foregoing it is evident that the prognosis in any of the varieties of sarcoma is unfavorable. The gravity is increased with the duration of the tumor, its location near the trunk, and with the rapidity of its growth.

The round-celled, especially those which have undergone the *melanotic*, *mucoïd*, or *alveolar* change, are most dangerous; next, the spindle-celled, and, lastly, the myeloid or giant-celled variety.

The Treatment.—Situating superficially, or in the soft parts, they should be excised as soon as observed. The incision should always be wide of the suspected limit, and the skin and all the tissues should be removed well beyond the tumor. When a bone is the seat of the new formation, no effort should be made to preserve the periosteum. The bone should be divided as far beyond the lesion as may be deemed consistent with the safety of the patient and the preservation of the function of the part involved.

When a sarcoma is developed upon an extremity, if it be small or of very recent date, a wide extirpation should be undertaken; but, if there is at any time thereafter an indication of recurrence, amputation should be considered.

Sarcoma of the bones of the extremity calls for immediate amputation. If the tibia is involved, disarticulation at the knee is indicated. If the neoplasm is located in the femur below the middle, the bone should be removed at the hip. If the soft parts are not involved, a long flap should be made, and the femoral vessels divided as low down as possible.

Special Forms of Sarcoma—Round-Cell Variety.—

The cells are analogous to the embryonic elements of the ordinary inflammatory process from which they can not be distinguished. They possess one or more nuclei and nucleoli, and are spherical, or with slightly irregular outlines from reciprocal pressure. The intercellular substance is homogeneous, and either very scanty or entirely absent (Fig. 764). The vessels and blood-channels have been described. This variety of sarcoma occurs every-

where. In the neuroglia of the brain and the neurilemma elsewhere it has been called *neuro-sarcoma* or *glioma*.

Spindle-Cell Sarcoma.—The cells of this variety are elongated or fusiform in shape, containing usually one, at times several, nuclei. The ends of the spindle may be single or bifurcated (Fig. 765). The cells vary in size from $\frac{1}{2500}$ to $\frac{1}{400}$ of an inch in diameter, and are arranged in bundles running in various directions (Fig. 766).

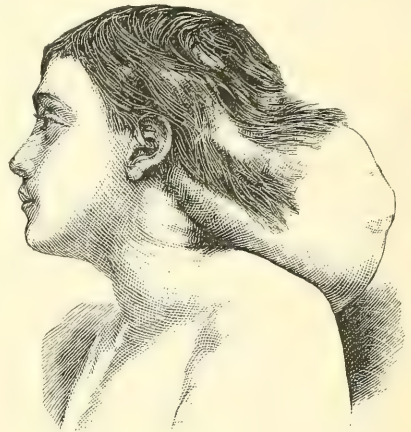

FIG. 763.—Sarcoma of the scalp and neck.

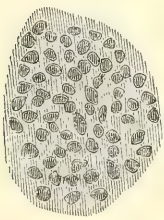

FIG. 764.—Round-cell sarcoma. (After Green.)

Clinically, this is the most common form of sarcoma. They are slower in development, firmer to the feel, and less vascular, and of smaller dimensions than the preceding variety. As stated, they are somewhat

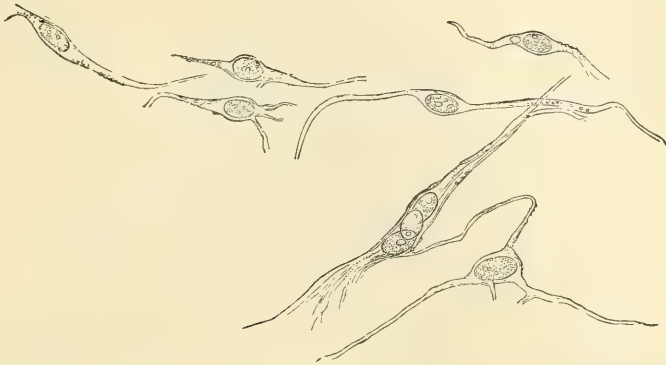

FIG. 765.—Multipolar cells of a sarcoma. (After Cornil and Ranvier.)

less malignant. They may, in rare instances, be encapsuled, although the rule is to invade the surrounding tissues. The favorite location for their development is the periosteum and in the substance of the bones.

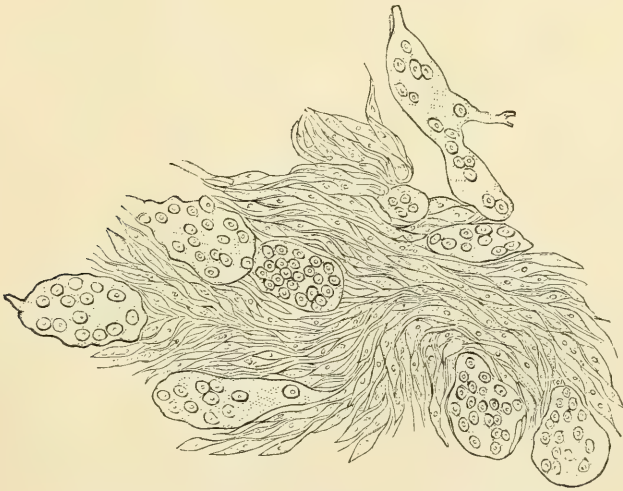

FIG. 766.—Spindle-cell sarcoma. (After Virchow.)

They attack the glandular structures, not infrequently affecting the breast. While developing here, the increased vascularity of the neoplasms induces hyperæmia of the glandular apparatus of the breast with consequent proliferation of the epithelia, a condition which has been termed by Billroth adeno-sarcoma.

Giant-Cell Sarcoma.—The cells of this neoplasm are of all sizes and shapes: spherical, fusiform, and irregularly oval, having at times one, at others thirty or more nuclei (Fig. 767). They closely resemble the cells of the normal marrow of foetal bones. Clinically, this form of sarcoma is met with usually in the bones, especially in the lower jaw and

the long bones. It may develop to an enormous size, remaining practically confined to a single bone; less frequently spreading to the surrounding soft parts. Bones so affected at times become friable, being readily fractured from the body-weight, or yield a crackling sound upon palpation.*

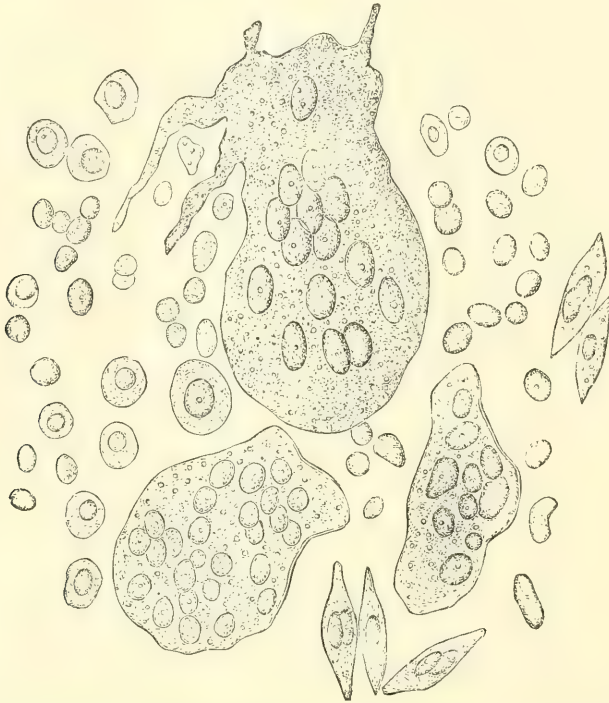

FIG. 767.—Giant-cell sarcoma. From a sarcoma of bone. (After Ordonez.)

NON-MALIGNANT NEOPLASMS.

The *non-malignant epitheliomata* are the dry, pavement, or pearl-like epithelioma, papilloma, the adenoma, and the cystic tumors.

The *pearl epithelioma* is of rare occurrence. Microscopically, it is found to be closely akin to the bird's-nest tumors, which are classed with the malignant growths. The cells of the non-malignant and rare neoplasm are, however, flat, and collected in little dry, pearl-like bodies, gathered in clusters, and held together, or surrounded by a connective-tissue stroma. Occasionally, cholesterine crystals are seen in these bodies, and this fact induced Müller to name this form of neoplasm "*cholesteatoma*."

The proper treatment is removal with the knife.

Papilloma.—A papilloma is a neoplasm, in structure not unlike the normal papillæ of the skin and mucous membranes. Each papilla pos-

* For a consideration of the various mixed varieties of sarcoma, viz., osteoid, neuro- and lipo-sarcomata, angiolithic sarcoma, etc., the student is referred to the text-books on pathology, and especially to the excellent work of Cornil and Ranvier, which the author has drawn from extensively.

sesses a connective-tissue framework which supports one or more new-formed vascular loops, and the whole is covered in with one or several layers of epithelia.

They may be met with upon the cutaneous, mucous, or serous surfaces.

The most frequent form of papilloma is the ordinary "wart." The hard or cutaneous wart is often seen upon the hands; the soft or mucous wart is frequently met with upon the prepuce, vulva, and anal margins. Corns are also classified as papillomata.

Mucous warts grow more exuberantly than those of the skin. Upon the prepuce, where they are kept moist and are subjected to irritating secretions and to friction, they form at times enormous masses. Hæmorrhage is a common accident, and sloughing, with the emission of a most offensive odor, is the rule in these larger neoplasms.

Essentially benign papillomata may, by long-continued irritation, be converted into, or replaced by, an embryonic neoplasm of a malignant type.

Treatment.—The indication is to destroy them at once. The best method to pursue is to grasp them with forceps, clip them off with scissors close to the attached margin, and apply nitric acid to the bleeding base of the neoplasm. Anæsthesia is obtained by moistening them for several minutes with a 4-per-cent solution of cocaine hydrochlorate. The nitric acid leaves a yellow stain, which is objectionable when the growth is situated upon an exposed surface.

Adenoma.—Adenomata are neoplasms the structure of which is analogous to gland-tissue. Following this analogy, they are of the racemose and tubular varieties. The racemose adenomata are extremely rare.

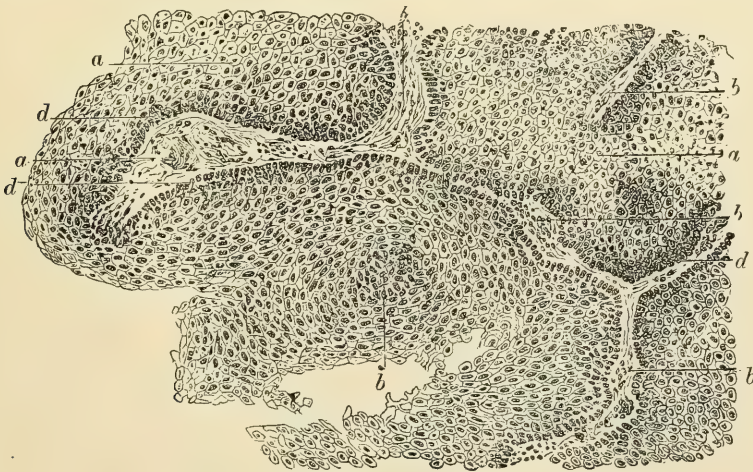


FIG. 768.—Nasal polypus. *a*, Pavement epithelia, of which the deeper layers, *d*, are cylindrical, and are arranged along the edges of the papillæ, *b*. A vessel is shown at *b*. (After Cornil and Ranvier.)

They are composed of collections of acini held together by a varying quantity of connective tissue, and lined with epithelium. They may develop in all parts of the economy where the racemose glands are

found. A favorite location is the mammary gland, occasionally in the parotid, the lachrymal gland, and the roof of the mouth. They are slow in growth, are spherical in shape, and are freely movable in the structure in which they develop.

Tubular adenoma is more frequently observed than the racemose variety. The tubules are in some cases separated by a layer of new-formed connective tissue, while in others there is no perceptible intertubular stroma. The tubules may be single, but are more frequently bifurcated, and, as in the normal glands, commence in blind extremities and open upon the mucous surface. They are lined with one or more layers of glandular epithelium. These tumors are seen in the rectum and colon, in the uterus, especially the cervix, and occasionally in the nose (Fig. 768).

They are spherical or pyriform masses, covered with mucous epithelium as long as they are contained within the cavities; but when, by reason of excessive growth, they are exposed to the air, the covering becomes hard and smooth, like the epidermis.

Cysts.—A cyst is a tumor composed of a limiting membrane or capsule of connective tissue, lined by epithelium and filled with fluid or semi-fluid contents. The contained matter may be mucoïd or colloid material, or sebaceous matter and epithelial cells in various conditions of degeneration.

Sebaceous cysts occur upon all portions of the external surface, and in rare instances develop in the deeper tissues.

The external sebaceous tumors are seen very frequently upon the face and scalp, and vary in size, measuring at times an inch or more in diameter. They are spherical or flattened tumors, soft and elastic to the touch, and freely movable upon the subcutaneous tissues.

The contents may be a white, cheesy matter or more fluid, and of an amber or brown color. Examined microscopically, it is seen to be composed of epithelial cells which have undergone a more or less complete granular metamorphosis, loose granules, compound granular corpuscles, cholesterine crystals, rudimentary hairs, etc. The wall of the cyst varies in thickness, being at times very thin and closely adherent to the surrounding structures, and at others thick and easily detached. Those upon the hairy scalp, commonly known as "*wens*," are usually filled with an amber-colored, jelly-like mass, which escapes upon section or puncture of the cyst. Upon the face, or other cutaneous surface, the contents are apt to be cheesy in character.

They are caused by cell-proliferation and the accumulation within the hair-follicle and communicating sebaceous gland of its normal secretion, which can not escape, owing to the partial or complete occlusion of the excretory duct. Cutaneous cysts, from direct violence, and often without any appreciable cause, may inflame and suppurate.

Dermoid cysts are closely analogous to the preceding, although situated in the deeper structures. They consist of a limiting membrane, and liquid and solid contents. In addition to the changed epithelial cells and granular matter, these tumors often contain tufts of hair, rudimentary

teeth, etc. They occupy by preference the ovary, but are met with in all parts of the body.

Mucous cysts are usually seen upon the lips, buccal cavity, vulva, and anus. They may occur in any portion of the alimentary or respiratory passages, or in any of the cavities lined by mucous membrane. The wall is thin, lined with epithelium, and adherent to the surrounding structures. The contents are a viscid mucus, resembling the white of an egg. The cause of the tumor is obstruction of the normal excretory duct. The character of the tumor may be suspected from the location and the spherical shape. A slight puncture, with compression, will reveal the mucous character of the contents.

Serous Cysts.—Cysts of the smaller serous cavities may result from hypersecretion of the normal fluid by the epithelia lining the serous membrane, in which the excess is not reabsorbed. The swellings often observed upon the back of the wrist and hand, and sometimes upon the dorsal aspect of the foot, are typical serous cysts, and result from hyperdistention of normal serous bursæ.

Lipoma.—A fatty tumor is a circumscribed collection of adipose tissue growing independently of the other tissues. Lipomata usually develop in the subcutaneous cellular tissue, and are frequently met with about the back of the neck and shoulders. From this location they occasionally are carried by gravity toward the sacrum, slipping downward between the integument and deep fascia. Situated superficially, they grow to be irregular and spherical or pyriform tumors of varying size; are usually single, but may be multiple. Less often they are met with in the glands, muscles, bones, and in the abdominal viscera.

Microscopically, they are composed of vesicles filled with oil or fat. The vesicles are connective-tissue corpuscles, the nuclei of which are displaced to the periphery and compressed against the investing membrane of the vesicle. These vesicles are held together in clusters of various size by a stroma of fibrous tissue, in the meshes of which the blood-vessels run. The whole tumor is in turn encapsuled.

Various names have been given to certain complex fatty tumors; when the inter-vesicular substance is myxomatous, *myxo-lipoma*; when the connective tissue is excessive, *fibro-lipoma*; in bone, *osteo-lipoma*; when very vascular, *angeio-lipoma*, etc.

Lipomata may undergo granular and calcareous metamorphosis, and may also become inflamed and break down as a very offensive and sloughing mass. They are altogether benign, and can only cause death by ulceration, sepsis, and hæmorrhage, or by pressure upon important organs.

The *diagnosis* depends upon the soft, uneven feel and the mobility of the mass. It is only to be differentiated from old abscesses or cystic tumors. If the history does not point to the diagnosis, the aspirator-needle will be of service.

The treatment is removal with the knife. The incision may be straight for a small tumor, but should be elliptical for large growths, in order to do away with redundancy after the tumor is turned out. The capsule

should be opened, and the tumor may be turned out almost wholly with the fingers.

Fibroma.—This variety of neoplasm is made up of fibrous tissue, the filaments of which are at times arranged in bundles which run in all directions; at others, there is little or no fascicular arrangement, the filaments being entangled in all directions. In the interstices of the bundles, or between the fasciculi, are found connective-tissue cells, the poles of which communicate with each other. The vascular supply is limited. Fibromata develop chiefly in the skin and subcutaneous tissues and periosteum, but may exist in any other portion of the body. They are usually single and small, occasionally multiple, and this form of tumor may attain an enormous size. In shape, those developing from the deeper tissues are spherical, and are hard to the touch. In the skin they are often pedunculated and pyriform. Fibromata may undergo a mucoid, granular, or calcareous degeneration, and are subject to inflammation and suppuration, as are other neoplasms. Not possessing a high degree of vascularity, the danger of hæmorrhage is not great, unless a rich granulation-tissue has sprung up as a result of prolonged irritation.

Simple fibroma is benign, and the indications in treatment are removal by the knife.

Myxoma.—This neoplasm is made up of primitive connective-tissue cells, similar to those observed in the umbilical cord at birth. The cell-elements are spherical and fusiform in shape. The former are isolated and float freely in the gelatinous-like intercellular substance. The latter may possess two or more poles, and anastomose freely with each other, forming a continuous network or stroma throughout the mass. The vascular supply is rich. These neoplasms occur, as a rule, in the skin and subcutaneous tissues and upon the mucous surfaces, especially in the nose (mucous or soft polypi). They may develop, however, in any portion of the body, and have been observed in the muscles, bones, and nerves, the mammary gland, kidney, brain, etc. In shape, they are usually spherical, of small size, and are soft and doughy to the touch, and not painful unless by accident the sensory nerves are pressed upon by the tumor. As a result of rupture of the blood-vessels, cysts frequently occur in this variety of neoplasm.

The treatment is early and complete removal. Pure myxoma does not tend to recur after a thorough removal. In some instances, owing to the peculiar location of the neoplasm, a thorough extirpation is impossible, and in these cases the tumor may rapidly recur. The cases of general metastasis after supposed myxoma were probably instances in which the sarcomatous nature of the growth had been overlooked.

Myoma is a tumor composed of new-formed muscular elements. There are two varieties, namely, those composed of *striated* or voluntary, and those of *non-striated* or involuntary muscular fibers.

The first variety are extremely rare, and are of less clinical importance than the non-striated myoma.

In two instances the striated myoma has been seen in a congenital tumor of the testicle, and in a few other instances of tumors developed

wholly or in part in the embryo or foetus. Dermoid cysts at times contain traces of striated muscle.

A *diagnosis* can only be made out by the recognition, under the microscope, of the characteristic striated muscular fiber. The *prognosis* is favorable, owing to the benign nature of the tumor, which, nevertheless, should be removed as soon as recognized.

In the non-striated myoma the fusiform elements are arranged in all directions, either in bundles or groups which interlace, or there may be a general interlacing of the separate elements without fascicular arrangement, as in many of the organs in which the smooth muscle is found. Between these bundles true connective-tissue cells exist, and in these spaces the vessels are found. The nuclei of these new-formed elements, as well as the muscle-elements proper, do not differ materially from the normal non-striated muscular fibers.

Non-striated myomata are often met with in the uterus. In many of these neoplasms there is a variable quantity of connective tissue, more or less organized, and for this reason the term fibro-myoma has been given to these tumors. They may grow from the wall of the uterus, toward the peritonæum (*extra-mural*), or develop in the substance of the uterine muscle, become encapsuled (*inter-mural*), or project from the internal surface into the cavity of this organ (*sub-mucous myoma, intra-mural*).

This variety of neoplasm has also been seen in various other localities, as the skin, alimentary canal at various points, the prostate, scrotum, etc. The diagnosis depends upon the recognition of the characteristic fusiform elements under the microscope. The method advocated by Cornil and Ranvier is to macerate the sections in azotic acid, twenty parts to one hundred of water, or caustic potassa, forty parts to one hundred of water. By this process the connective-tissue stroma is dissolved and the muscular elements liberated.

The prognosis in this form of myoma is favorable as far as recurrence is concerned when the removal has been thorough. They not infrequently produce death, either directly by pressure and interference with the normal functions of organs necessary to life, or indirectly by causing hæmorrhage, rendering the individual more likely to perish from some intercurrent affection.

Treatment.—They should be removed, when this can be done with a justifiable degree of safety.

Neuroma.—A tumor composed of new-formed nerve-tissue is rarely met with. Many so-called neuromata are connective-tissue neoplasms springing from the neurilemma. They may be made up of *nerve-cells* or *nerve-fibers* (Fig. 769).

The former are even rarer than the latter. Small particles of gray matter have been seen in dermoid cysts, and in a few instances neoplasms of this variety have been seen in the brain and spinal cord.

Fascicular neuromata may occur in the nerves. They exist as slight elliptical swellings or enlargements of the nerve involved, may be single, or there may be a succession of nodosities in the course of the nerve.

The *symptoms*, in addition to the tumor, which may at times be made

out by palpation, are those of pain or interference with the function of the part involved. A careful analysis with the microscope alone can determine an accurate *diagnosis*.

The *prognosis* is not grave, in so far as the life of the patient is concerned, but the removal of the neoplasm may of necessity involve an injury of the trunk in or upon which it is located, and in this manner may add an element of gravity to the result. They should be extirpated, and, where (as will almost always be the case) the positively benign character of the neoplasm is not evident, a section of the nerve below and above the tumor, as well as a portion of the surrounding tissues, should be removed.

Angioma.—The angiomata are tumors of new-formed vessels, capillaries, arterioles, or veins. They are frequently congenital, and may also appear at any period after birth.

Microscopically, the simple forms are made up of capillaries, arterioles, and veinules in plexuses richer than the normal, and held together by a connective-tissue stroma of varying thickness. In the more formidable tumors—*cavernous naevi*—the vessels are larger, with thickened walls of dense connective tissue, and at times a quantity of non-striated muscular fibers. The *vasa vasorum* are also met with in the walls of the sinuses.

The former variety appear as red or bluish spots or stains in the skin, of various sizes and shapes, at times rising above the level of the integument.

The method of *treatment* is fully described in the chapter upon diseases of the vascular system.

Lymphangioma.—Tumors composed of new-formed lymphatic vessels are

very rarely met with. In their construction they do not materially differ from the angiomata. The new tissue consists of a capillary network of lymph-channels, in arrangement analogous to the capillary vessels in the smaller angiomata.

In the case shown in Fig. 771, I removed by dissection a plexus of lymphatic vessels about as large as a hen's egg. The walls were saccu-

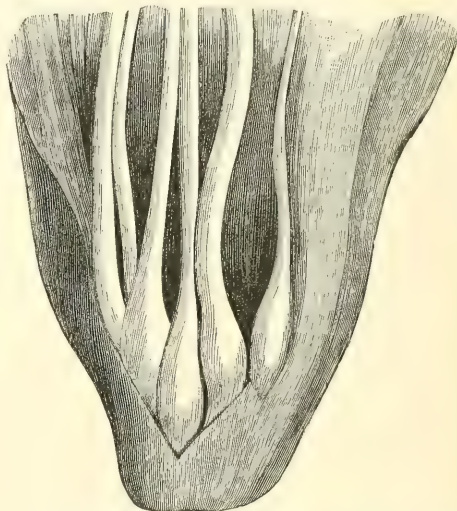


FIG. 769.—Neuromata developed in the divided nerve-tissues after amputation of the member. (After Corail and Ranvier.)

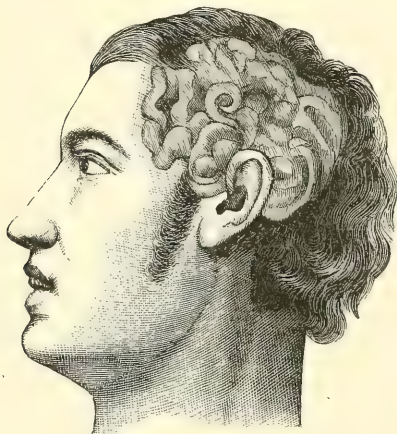

FIG. 770.—Angioma (cirroid aneurism) of the temporal region.

lated, and the vessels were distended with clear lymph. In other instances the lymph-canals have a cavernous arrangement comparable to the structure of the cavernous nævus described in the article on vascular tumors.

Lymphadenoma has been given under the heading of Malignant Neoplasms. Many forms of enlargement of the lymphatic glands are not true tumors, since they are not composed of new-made gland-tissue, are due to cancerous infiltration, to tubercle, to syphilitic adenitis, tubercular deposit, etc. Tubercular lymphomata should always be extirpated when tuberculosis of the deeper organs can be excluded, provided that the operation of removal does not involve a too great risk of life. The removal of enlarged glands from metastasis in cancer should also be done when there is a reasonable hope of cutting off the disease from the centers.



FIG. 771.—Lymphangioma of left buccal wall.

Chondroma.—New formations of cartilage develop in and from the connective-tissue cells of any portions of the body, excepting from car-

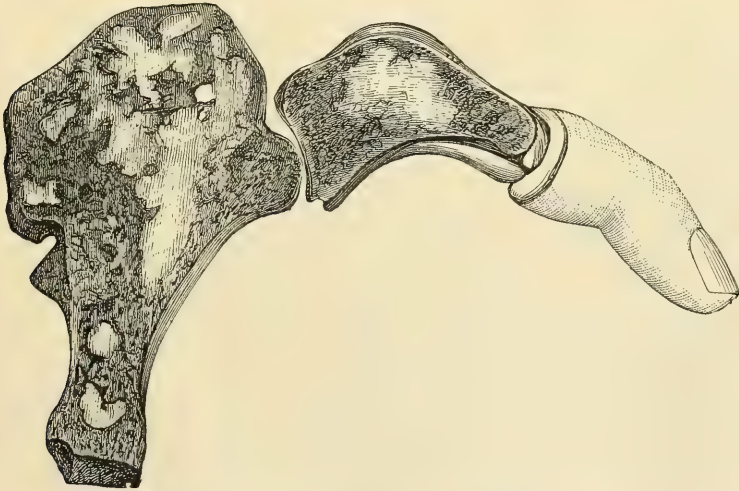


FIG. 772.—Diffuse chondroma of the phalanges and metacarpal bones. (After Nélaton.)

tilage proper. The bones and periosteum are favorite points of origin for these neoplasms. Developing from within the bone, a cartilaginous new formation is termed an *enchondroma*; if from the periosteum, a

perichondroma. Quite a number of chondromata have been observed in the testicles and in the parotid glands. They may assume all sorts of shapes, growing into more or less spherical tumors, or the new tissue may be generally diffused in the normal tissue.

In the bones of the hand and fingers they give rise to marked deformities and to considerable pain, from displacement of the normal structures, and interference with nutrition (Fig. 772).

The new formation of cartilage is preceded by an inflammatory process varying in intensity, usually of a mild nature, yet resulting in the proliferation of the cells of the part involved, and the formation of an embryonic tissue from which the cartilage is formed, as in the normal development of this tissue. Some of these cells become the cartilage-cells proper, and are collected in groups of different sizes, while others form a connective-tissue stroma around the collections of cartilage-cells. The vessels find their way along these bundles of connective tissue.

The proportion of connective-tissue stroma varies in different tumors. When the cartilage-cells and groups are plentiful, with a limited quantity of intervening fibrous tissue, the mass is strictly a *chondroma*. When the stroma preponderates, it is termed a *fibro-chondroma*. In certain forms of these tumors there is a paucity of connective-tissue fibers as well as cartilage-cells, although both are present in quantity sufficient for recognition. The mass of tissue may be *embryonic*, and, under such conditions, the tumor may be sarcomatous in character. Simple chondroma is benign, but a mixed chondroma of an embryonic-tissue type must be classed with the malignant neoplasms.

Chondromata may undergo fatty or granular degeneration, may ossify in part, may become infiltrated with calcareous matter, or undergo the mucoid change.

Treatment.—Removal is indicated when pain is unbearable, or when the sarcomatous nature of the neoplasm is evident.

Osteoma.—Tumors of new-formed bone-tissue may develop from the normal bone and periosteum, or in the tissues removed from the bones. There are three varieties—the *eburnated*, *compact*, and *spongy*.

In the first, or ivory-like neoplasms, the bone is exceedingly dense and hard, and contains bone-corpuscles and canaliculi which, though well marked, are more irregular in arrangement than in normal forms. This new-formed bone-tissue, however, does not possess blood-vessels. These tumors are especially apt to be observed upon the bones of the skull, notably those of the frontal and parietal regions.

The compact or spongy neoplasms are in structure analogous to the normal compact or spongy bone-substance. In the latter the bony framework is light, and the medullary spaces larger than normal.

An osteoma formed upon the outside of an old bone is called an *exostosis*; developed within the medullary space, an *enostosis*.

Exostoses grow as more or less well-rounded tumors beneath the periosteum, or as sharp spikes or thorns projecting out from the bone. Such spines are in the great majority of instances directed upward (stalagmites) in the axis of the tendon in and about which they develop. In

rare instances the direction is downward, as seen in the stalactite (Fig. 307).

Bony neoplasms may also develop in any of the cartilaginous tissues of the body, and this change is usually one of senility. Beyond this, bone may form in the muscles, choroid, the serous membranes in all locations, and in the integument.

Osteomata are always benign. If dangerous at all, it is from compression of important organs. Those developed from the internal surface of the cranial bones and along the vertebral canal are especially dangerous in this respect.

Treatment.—Interference is not called for, unless pressure upon important organs renders it necessary.

INDEX.

- Abbe. Intestinal anastomosis, 529; rings for, 546, 548, note.
- Abdomen, 586; abscess, 579, 586; affections of, 525; bandage for, 17; contusions, 586; gunshot injuries, 587; wounds, 586, 587.
- Abdominal aorta, aneurism of, 204, 228; ligation of, 264; in iliac aneurism, 229; section, 545, 589.
- Abscess, 63; abdominal, 579; acute, 63; after caries, 63; alveolar, 471; ano-rectal, 596; aspiration of, 63, 64; circumscribed, 63; chronic, 63; cold, 62, 63, 66; diagnosis of, 63, 204; diffused, 63; membrane, 61, 63; metastatic, 66; of antrum of Highmore, 471; of cornea, 411; of frontal sinus, 384, 445; of groin, diagnosis, 557; of jaw, 470; of joints, 63; of kidney, 620; of liver, 582; of mammary gland, 515; of neck, 492; of ovary, 773; of parotid gland, 470; of scalp, 383; of spine, 63; of spleen, 585; of testicle, 746; of thoracic wall, 521; of thyroid gland, 494; of tongue, 483; of tonsils, 489; of ventricles of the brain, 394; of vulva, 751; perirectal, 596; perityphlitic, 580; retroperitoneal, 581; retropharyngeal, 492, 507, 790; spinal, 789; subacute, 63; wall, 61, 63.
- Absorbable animal drains, 8.
- Absorbent dressings for wounds, 9.
- Acceleration of blood-current in inflammation, 54.
- Accidental amputation, 107.
- Accommodation, 425.
- Acetabulum, fracture of, 307.
- Acetate of lead, in prostaticorrhœa, 673; of zinc, in gonorrhœa, 681, 685.
- Acid, boric, 3; cotton, 9; for surgery of the eye, 397; carbolic, 3, 5; for angioma, 198; near eye, 397; for hæmorrhoids, 617; for wounds, 74; in erysipelas, 89; solution, 3, 5; chromic, for catgut, 2; nitric, in hospital gangrene, 105; in phagedenic ulcers, 716; oxalic, for sponges, 7; salicylic, 3, 5; salicylico-boric, solution, 5.
- Aconite, in erysipelas, 87; in inflammation, 60; in tonsillitis, 489; in urethral chills, 693.
- Acromion process, fracture of, 294.
- Active ulcer, 99.
- Actual cautery as a hæmostatic, 73.
- Acupressure, 73.
- Acupuncture for treatment of aneurism, 211.
- Acute gangrene, 100.
- Adams. Osteotomy of femur, 802.
- Adenitis, 164; acute, 164; axillary, in affections of mammary gland, 519; cervical, 492, 494; inguinal, 684, 715; syphilitic, 719, 722.
- Adenoma, 849; of intestine, 536; of kidney, 624; of lip, 455; of mamma, 515; of testicle, 748.
- Adeno-sarcoma, 847.
- Adhesions of intestine, 535; of labia, 752; of prepuce, 712.
- Adhesive plaster, in wounds, 76.
- Administration of chloroform, 34; of ether, 26; per rectum, 32.
- Advancement of insertion of eye-muscles, 426.
- After-treatment of patients after operation, 53.
- Agnew. Anthrax, 83; canalicula-knife, 406.
- Air-tumor of scalp, 383.
- Aitkin. Bilharzia hæmatobia, 645.
- Albumen in the urine, 642.
- Alcohol as an antiseptic solution, 3; for catgut, 2.
- Alcoholism, cause of arteritis, 173.
- Alexander. Case of aneurism, 228.
- Alimentary canal, obstruction of, 530; rupture of, 587.
- Alligator-forceps, 503, 701.
- Allingham. Ulcer of rectum, 600.
- Allis. Brain surgery, 393; ether-inhaler, 27.
- Alternating tonics in hospital gangrene, 105.
- Amaurosis, 424.
- Amblyopia, 424.
- Am Ende. Sponges, 7; sublimate gauze, 9.
- Ametropia, 426.
- Ammonio-magnesian calculus, 646.
- Amputation, 107; at ankle-joint, 139, 141; at calcaneo-astragaloid joint, 139; at carpo-metacarpal joint, 124; at carpo-radial joint, 126; at elbow-joint, 153, 158; at hip-joint, 154; at knee-joint, 148; at radio-carpal joint, 126, 127;

at shoulder-joint, 133; at tarso-metatarsal joint, 136; at tibio-tarsal joint, 142; by circular skin-flaps, 116, 129; by circular solid flaps, 110; by double crescentic flaps, 117; by double rectangular flaps, 118; by mixed flaps, 118; by modified circular flaps, 117; by oblique solid flaps, 115, 116; by oval flaps, 117; continuous irrigation for, 119; for malignant tumors, 846; in dislocations, 324; knives, 35; medio-tarsal, 139; methods of, 109 *et seq.*; of Bruns, 145; of Carden, 151; of Chopart, 139; of Dupuytren, 134; of Esmarch, 127; of Forbes, 139; of Gritti, 152; of Gunther, 145; of Hancock, 140; of Hey, 137; of Larrey, 134; of Lee, 148; of Le Fort, 143; of Lignerol, 139; of Lisfranc, 137; of Malgaigne, 139; of Mason, Erskine, 154; of Pirogoff, 143; of Sedillot, 148; of Smith, Stephen, 141 (Syme), 146 (leg), 150 (knee); of Syme, 139, 141; of Teale, 147; of Texton, 139; of arm, 130; of breast, 519; of cervix uteri, 764; of clavicle, 134; of fingers, 120; of foot, 141, 145; of fore-arm, 127; of hand, 120; of index-finger, 123; of leg, 146; of little finger, 124; of middle finger, 123; of mammary gland, 519; of penis, 709; of prepuce, 711; of ring-finger, 123; of scapula, 134; of superior extremity, 130; of tarsal bones, 138; of tarsus, 135; of thigh, 152; of thumb, 121, 122; of toes, 134; open method of treating, 118; special amputations, 120 *et seq.*; tibio-tarsal, 141.

Amussat. Colostomy, 577.

Amylaceous bodies in prostate, 675.

Amyloid degeneration of viscera, 790.

Anæsthesia, 22; by the rectum, 26; death from, 33; general, 24; local, 22; of male urethra, 689.

Anæsthetics, 22; chloroform, 25, 33; cocaine, 22; ether, 24, 25, 26; ice, 24; rhigolene, 24.

Anandale. Case of aneurism, 216.

Anatomical forceps, 43.

Anatomical relations of the arteries of lower extremity, 265-273; arteries of neck, 236-240, 249-252; arteries of upper extremity, bones of carpus, 368 (longitudinal section); bones of foot, 138, 820; large vessels of aorta, 254, 255; muscles of lower extremity, 149-160 (transverse sections); muscles of upper extremity, 128-132 (transverse sections); organs of female pelvis, 752, 753; organs of male pelvis, 551, 552, 554; organs of thoracic and abdominal cavities, 327; parts in the surgical triangles of neck, 243; parts of elbow, 378 (longitudinal section); parts of foot, 375 (longitudinal section); parts of groin, 555, 567; parts of hand, 380 (longitudinal section); parts of head, 394 (anterior-posterior section); parts of hip-joint, 370 (longitudinal section); parts of knee-joint, 311 (longitudinal section); parts of perinæum, 662; parts of shoulder-joint, 377 (longitudinal

section); parts of urethra, 689 (longitudinal section); parts of vulva, 751; parts of peritonæum and bladder, 631; rectum and anus, 591, 592; tunica vaginalis and peritonæum, 736, 737.

Anastomosis of intestine, 529-546.

Anchylosis of elbow, 827; of hip, 802; of knee, 809; of lower jaw, 476; of shoulder, 826.

Anderton. Case of aneurism of both vertebral arteries, 228.

Anel's method of treating aneurism, 207, 209; syringe, 407.

Aneurism, 179, 202; after wounds, 204; anastomotic, 195; arterio-venous, 232; aspiration of, 204; by anastomosis, 195; cirroid, 190; diagnosis of, 197, 204; diffuse, 202, 204; dissecting, 202, 204; false, 204; fibrillated fibrin in, 203; fusiform, 203; needle, 2; of abdominal aorta, 204, 228; of aorta, 204; of arch of aorta, 211; of axillary artery, 222, 224, 226; of brachial artery, 227; of carotid, 212; of common carotid, 220; of common iliac artery, 229; of descending aorta, 212; of external iliac artery, 229; of femoral artery, 230; of gluteal artery, 230; of iliac artery, 204, 229; of innominate artery, 204, 212, 216; of peroneal artery, 231; of popliteal artery, 231; of profunda femoris, 231; of radial artery, 227; of sciatic artery, 230; of subclavian artery, 222; of thyroid gland, 494; of thoracic aorta, 211; of tibial artery, 231; of ulnar artery, 227; of vertebral artery, 228; pressure of, on œsophagus, 509; prognosis of, 204, 205; sacculated, 202, 211; special forms of, 211; spherical, 202; symptoms of, 204; treatment of, 205; by acupuncture, 211; by Anel's method, 207, 209; by Antyllus's method, 207; by Brasdor's method, 207, 209; by compression, 207; by compression with instruments, 288; by compression with the finger, 207; by forced flexion, 210; by galvanopuncture, 210; by Hunter's method, 207, 209; by injection, 206, 211; by massage, 210; by Tufnell's method, 206, 227; by Valsalva's method, 207; by Wardrop's method, 207, 209; true, 202; varicose, 232; varieties of, 202.

Aneurismal varix, 203, 232.

Angelo's method of bleaching sponges, 7.

Angio-lipoma, 851.

Angioma, 195, 854; cutaneous, 195; diffuse, 197; encapsulated, 197; near the eye, 397; of ear, 438; of intestine, 536; of kidney, 624; of larynx, 506; of lower jaw, 474; of mammary gland, 513; of nipple, 513; of serotum, 734; plexiform, 195.

Animal ligatures in aneurism, 209; poisons producing inflammation, 54.

Ankle-joint, amputation at, 139, 141; dislocation of, 348; exsection of, 374; osteo-arthritis of, 365.

Anterio-posterior curvature of the spine, 786.

Anterior tibial artery, ligation of, 273.

- Anthrax, 83; bacillus of, 83.
- Antifebrin in inflammation, 60.
- Antipyrin in dissection wounds, 84; in erysipelas, 87; in inflammation, 60; in urethral chills, 694.
- Antiseptic dressings, permanent, application of, 54; solutions, etc., 3, 4.
- Antrum of Highmore, abscess of, 471; drainage of, 471; operative invasion of, 472; trephining of, 289.
- Antyllus. Aneurism, method of treatment, 207.
- Anus, absence of, 591; artificial, formation of, 593; atresia, 591; cancer, 605; eczema, 594; erythema, 594; fissure, 594, 599; fistule, 595; neoplasms of, 605; neuralgia, 608; pityriasis versicolor, 594; prolapse, 608; pruritus, 593; stricture, 601, 602; ulceration, 600.
- Aorta, abdominal, aneurism of, 204, 228; ligation of, 264; for iliac aneurism, 229; aneurism of, 211; compression of, for wounds, 73; of the ox, as ligation, 1.
- Aphasia, operation for, 391.
- Aponeurosis, palmar, contraction of, 830.
- Apparatus for cyphosis, 796; for holding ligatures, 2; for exstrophy of bladder, 628; for fracture of lower jaw, 291; for knock-knee, 807; for talipes equinus, 811; for torticollis, 780; for transfusion, 78.
- Arch of aorta, aneurism of, 203, 211; aneurism of transverse, 212.
- Areus senilis, 412.
- Arendt. Case of aneurism, ligation of innominate artery, 223.
- Arm, amputation of, 130; bandage for the, 14.
- Arrest of circulation, a cause of gangrene, 100.
- Arsenic in furuncle, 95.
- Arterial compression in wounds, 72 *et seq.*
- Arterial cutaneous tumor, 190, 195; cirroid tumor, 190; embolism, 188; occlusion in gangrene, 101; thrombosis, 188, 189; tumor, 190; varix, 190.
- Arteries, calcification of, 177, 179; ligation of, during operation, 51; surgical operations upon, 234 *et seq.*
- Arterio-venous aneurism, 232.
- Arteritis, 171; acute, 172; deformans, 179; idiopathic, 177; non-traumatic, 177; pathogeny of, 172; pathological anatomy of, 184; rheumatic, 187; sequelæ of, 173; syphilitic, 181, 187; traumatic, 172, 173; treatment of, 187.
- Artery, compression of iliac, 154.
- Artery, ligation and statistics of anterior tibial, 273; of aorta, 264; of ascending pharyngeal, 250; of axillary, 259; of brachial, 261; of carotid, common, 237; external, 244; internal, 242; of dorsalis pedis, 274; of facial, 250; of femoral, 269; of gluteal, 267; of iliac, common, 264; external, 266, 268; internal, 266; of innominate, 236; of intercostal, 262; of internal mammary, 255, 259; of internal maxillary, 253; of internal pudic, 267; of lingual, 248; of occipital, 250; of popliteal, 271; of posterior auricular, 252; of posterior scapular, 256; of posterior tibial, 272; of profunda femoris, 271; of radial, 262; of sciatic, 267; of subclavian, 253, 256, 258; of superior intercostal, 256; of superior thyroid, 248; of suprascapular, 256; of temporal, 253; of thyroid axis, 255, 259; of transversa colli, 255; of ulnar, 262; of vertebral, 255, 259.
- Arthritis, 351; tuberculous, 353.
- Articulations, surgery of the, 325.
- Artificial anus, 539, 569; respiration in ether narcosis, 30.
- Ascarides in the rectum, 595.
- Aspergillus in the auditory canal, 440.
- Aspermatism, 674.
- Asphyxia, artificial respiration in, 31.
- Aspiration of abscess, 63, 64; of abscess of abdomen, 579; of abscess of gall-bladder, 585; of abscess of liver, 585; of abscess of neck, 492; of abscess of spina bifida, 800; of abscess of tongue, 483; of aneurism, 204; of ankle-joint, 365; of bladder, 637; of joints for synovitis, 352; of kidney, 625; of knee-joint, 363; of knee-joint for patellar fracture, 315; of pleural cavity, 522; of shoulder-joint, 367.
- Aspirator, 65; for transfusion, 78; in ether narcosis, 29; Tiemann & Co's., 637.
- Assistants, distribution of, during operation, 50, 110.
- Asthenopia, 428.
- Astigmatism, 426, 427, 430.
- Astragalus, dislocations of, 349; diagnosis, 348; excision of, 376.
- Atheroma, 173, 177, 178.
- Atheromatous degeneration of arteries, a cause of gangrene, 103.
- Athletes, prone to arteritis, 175.
- Atresia ani, 591; recti, 591.
- Atropine, for ophthalmoscopic examination, 428; in iritis, 415.
- Atrophy of the optic nerve, 437; of the tongue, 483.
- Attrition due to aneurism, 204.
- Auchinclos. Case of aneurism, 224.
- Auditory canal, accumulations of cerumen in, 439; aspergillus in, 440; furuncles of, 439; foreign bodies in, 438; fungous growths in, 440; neoplasms in, 439; polypus of, 439.
- Auricle, adhesions, 438; cartilaginous tumors, 438; drooping, 438; hypertrophy, 438; instruments, 438; specula, 439; wounds, 438.
- Auricular artery, posterior, ligation of, 252.
- Auvert. Case of aneurism, ligation of subclavian artery, 224.
- Ayers. Case of ligation of subclavian artery, 257.
- Axillary artery, aneurism, 222, 226; ligation, 259.

- Bacillus of blue pus, 62; of glanders, 83; of tetanus, 83; saprogenes, 60.
- Bacteria in inflammation, 60.
- Balanitis, 678, 682.
- Balano-posthitis, 679, 682.
- Bandage, elastic, 41; figure-of-eight, 12; four-tailed, 20; handkerchief, 20; in inflammation, 57; knotted, 19; Martin's, 99; methods of applying, 11; plaster-of-Paris, 10; reverse, 12; roller, 10; spica, 17; spiral, 11.
- Bandages for the abdomen, 17; for the arm, 14; for the axilla, 15; for the breast, 17; for the chin, 18, 290; for the eye, 20; for the face, 20; for the fingers, 13; for the fore-arm, 14; for the foot, 15; for the hand, 13; for the head, 18; for the hip, 16; for the knee, 17; for the leg, 16; for the lower extremity, 16; for the shoulder, 14; for the thigh, 16; for the thorax, 17; for the toes, 15; for the upper extremity, 14; for ulcers, 99; for varix, 200.
- Bands, constricting the intestine, 535.
- Banks, E. A. Dilating filiform bougies, 692; urethrotome, 691.
- Barlow. Cases of aneurism, 215, 216, 217; operation for vascular tumor, 193, 194; syphilitic arteritis, 183, 187.
- Bartholow. Action of quinine on septic germs, 171.
- Barton's fracture, 301.
- Barwell. Cases of aneurism, ligation of carotid and subclavian arteries, 215, 217, 219; club-foot, operation for, 815; operation for vascular tumors, 193, 194.
- Basedow's disease, 497.
- Basilar artery, occlusion of, 183.
- Base of skull, fractures of, 284.
- Basin, pus-, 48.
- Bathey, Dupuytren's contraction, 831.
- Bavarian splints, 303.
- Bayer. Case of aneurism, ligation of subclavian, 224.
- Beall. Hernia cerebri, 385.
- Bee-stings, 81.
- Beer's keratome, 417.
- Belladonna in lymphadenitis, 164.
- Bell. Illustration of tetanus, 88.
- Berger. Cirroid tumor, 191, 193.
- Bickersteth. Case of aneurism, ligation of innominate, 219, 223.
- Biesiadecki. Syphilitic arteritis, 181.
- Bifid spine, 799.
- Bigelow. Dislocation of hip, 341, 342, 344; lithotomy, 651.
- Bilateral lithotomy, 663.
- Bilharzia hæmatobia, 632, 645.
- Biliary calculi in intestines, 531.
- Billroth. Adeno-sarcoma, 847; cavernous tumors, 196; excision of tongue, 487; varix, 199.
- Binz. Action of quinia on emigrant corpuscles, 171.
- Bischoff. Transfusion, 78.
- Bisector, 663.
- Bistouries, 35.
- Blackman. Ligation of carotid for vascular tumors, 192.
- Black wash, 716.
- Bland. Case of aneurism, 218.
- Bladder, affections of the, 627; aspiration of, 637; carcinoma, 640; drainage of, 630, 638; exstrophy, 627; foreign bodies in, 645, 665; gunshot-wounds, 629; hernia, 629; hypertrophy, 632; inflammation, 632; papilloma, 639; paralysis, 634; parasites, 632; puncture of, suprapubic, 637; through rectum, 638; rupture, 630; stone in, 645; tumors, 639; wounds, 629.
- Blasius. Cheiloplasty, 464.
- Bleaching sponges, 7.
- Blepharitis, 399.
- Blepharo-phimosis, 399.
- Blepharoptosis, 400.
- Blepharospasm, 399, 409.
- Blisters, in inflammation, 60.
- Blizzard. Lithotomy-knife, 36.
- Blood, in the urine, 643; transfusion, 77.
- Bloodless method in amputations, 107.
- Blood-letting, in inflammation, 57.
- Blue pus, 62.
- Boil, 97; of perinæum, 758; of vulva, 751.
- Boiled water for wounds, 74.
- Boiling as a disinfectant, 3.
- Bone-drains, 8; drills, 38, 372; forceps, 38; instruments, 37; metastatic abscess in, 67; plates, absorbable, 529; tumors, *vide* tumors.
- Bones, surgery of, 275; of the tarsus, dislocations of the, 350.
- Boracic acid, 3; in surgery of the eye, 397.
- Borated cotton, 9.
- Bothrop, 79.
- Bosworth. Cocaine, action of, on blood-vessels, 442.
- Bow-legs, 809.
- Bougie, Banks's, 695; bulbous, 689; dilating filiform, 695; flexible, 699; gum filiform, 696; œsophageal, 509; Otis's, 689; oval-tipped, 689; rectal, 603; silk, 636; urethral, 699; whale-bone, 696.
- Brachial artery, aneurism of, 227; ligation of, 261.
- Brain, abscess of, 388; compression, 284; concussion, 285; gunshot-wounds, 286; hernia of, 385; symptoms of injury to, 389; syphilis, 723; wounds, 393.
- Brasdor's method of operating for aneurism, 207.
- Braune. Frozen sections, 127; *vide* anatomical.
- Breast, *vide* mammary gland, abscess of, 515; amputation of, 519; bandage, 17.
- Breschet. Cirroid aneurism, 191.
- Briddon. Double tourniquet, 208.
- Broad-jawed forceps, 41, 52.

- Broad ligament, cyst of, 775.
 Broca. Case of innominate aneurism, 218; injections into vascular tumors, 193.
 Bromines in hospital gangrene, 105.
 Bronchi, foreign bodies in, 501.
 Bronchocele, 493.
 Brown. Case of aneurism, 231.
 Bruit in aneurism, 205, 211.
 Bruns. Amputation of foot, 145; cheiloplasty, 465.
 Bryant. Arteritis rheumatica, 187; cases of aneurism, ligation of carotid and subclavian, 216, 218; hernia in females, 550; phlebites, 168, 169; phlebolites, 200; pyæmia, 67; test for dislocation of femur, 801; test for fracture of neck of femur, 309; varix, 198.
 Bubnoff. Ligation of arteries, process of occlusion after, 189.
 Bubo, diagnosis, 557; gonorrhœal, 684; inguinal, 715; phagedenic, 715; syphilitic, 719.
 Buchanan. Excision of vascular tumors, 193.
 Buchu, in suppression of urine, 625.
 Buck's method of extension, 307, 309; for dislocations of knee-joint, 348; for fracture of thigh, 307; for osteotomy of femur, 802; rectum trocar, 638.
 Buds, vascular, forming capillaries in wounds, 69.
 Bufo vulgaris, venom of, 80.
 Bull. Case of aneurism, ligation of innominate artery, 223.
 Bullen. Case of ligation of subclavian, 257.
 Bullet-probe, Nélaton's, 43.
 Bunions, 824.
 Burns, 93.
 Burrows. Cheiloplasty, 462.
 Busch. Excision of vascular tumors, 192.
 Bursitis of shoulder, 366.
 Butcher. Case of aneurism, ligation of carotid and subclavian, 218.
 Butlin. Epithelioma of tongue, 484.
 Buzzard. Syphilitic arteritis, 183, 187.
 Cabinet, operating, 44, 47.
 Cæsarean section, 766.
 Calcaneo-astragaloid disarticulation, 139.
 Calcaneum, amputation, 139.
 Calcaneus, talipes, 813.
 Calcareous degeneration of arteries, 177, 179; degeneration of thyroid gland, 495; deposit in veins, 199.
 Calcification of arteries, 177, 179.
 Calcium sulphide in furuncle, 97; in hordeolum, 399.
 Calculous concretions of the gall-bladder, 584; of the prostate, 675; of the tonsils, 490.
 Calculus, biliary, 531; in the bladder, 645; in the prostate, 675; in the renal pelvis, 622; in the ureter, 621; mulberry, 622; renal, 620, 622, 626, 646.
 Callaway. Diagnosis of dislocation of humerus, 328, 331.
 Callender. Hyperdistention of abscess, 64.
 Callisen. Colostomy, 576.
 Callus, 282; pin-callus, 283.
 Calomel after hysterectomy, 765; in inflammation, 60; in ulcers of penis, 716.
 Campbell. Case of aneurism, 216.
 Canal, auditory, *vide* auditory.
 Canaliculus lachrymalis, obstruction of, 406.
 Canalization of cells to form capillaries in wounds, 69.
 Cancer, 838; *vide* also epithelioma and carcinoma.
 Cannabis Indica for rabies, 82; in tetanus, 90.
 Canthoplasty, 409.
 Canula for thyrotomy, 498.
 Capillaries, formation of, in inflammation, 69; in wounds, 69.
 Capillary cutaneous tumors, 195; hæmorrhage in wounds, how controlled, 74; thrombosis the cause of furuncle, 97, 98.
 Carbolic acid as an antiseptic, 3; for angeioma, 195; in hæmorrhoids, injection of, 616.
 Carbolized gauze, 9.
 Carbuncle, 97, 98; of lip, 445.
 Carcinoma, 838, *vide* also epithelioma; of antrum of Highmore, 471; of the anus, 605; of the bladder, 640; of the breast, 518; of the intestine, 536; of the kidney, 624; of the larynx, 506; of the liver, 583; of the mamma, 518; of the meninges, 385; of the œsophagus, 511; of the ovary, 775; of the parotid gland, 468; of the penis, 707; of the prostate, 674; of the testicle, 749; of the thyroid gland, 494, 497; of the tongue, 483; of the tonsil, 490; of the urethra, 706.
 Carden. Amputation at the knee, 151.
 Caries, 275; of the jaw, 470; of the spine, 787; of the teeth, 471; of the vertebræ, 492.
 Carotid, common, 212; aneurism of, 220; diagnosis, 228; ligation of, 237; statistics of, 242; for aortic aneurism, 213, 233; external, ligation of, 244; internal, ligation of, 242.
 Carpal bones, dislocation of, 337; excision, 379; fractures, 304.
 Carpo-radial joint, disarticulation of, 126.
 Cartilages, laryngeal, fractures of, 292.
 Cartilaginous tumors of the ear, 438.
 Case, Dr. Meigs, suspension carriage, 798, 801.
 Casts in the urine, 644.
 Castration, 749.
 Cataract, 418.
 Cat-bite, 81.
 Catgut, as ligatures and sutures, 1; chromic, as ligature, 2; as drainage, 8; ligature in aneurism, 210; in wounds, 73.
 Catgut-rings, Abbe's, 529.
 Catheter, double-current, 634, 687; French, 636; gum, 633; Nélaton, 633; silk, 636.

- Catheterization, 636.
- Cautery, actual, in rabies, 82; for arterial varix, 190; in hospital gangrene, 105; in inflammation, 60; in phagedenic ulcer, 716.
- Cavernous bodies, fracture of, 707.
- Cells, proliferation of, in fractures, 281; in inflammation, 55; in ostitis, 279; in syphilis, 726; in wounds, 68.
- Cellulitis, diffuse, 86; pelvic, 630.
- Centipede, venom of, 81.
- Cerebral localization, 390.
- Cerumen, impaction of, in auditory canal, 439.
- Cervix uteri, amputation of, 764; excision of, 764; lacerations, 763.
- Chalazion, 399.
- Chamberlain. Ligation of axillary artery, 260.
- Championnière. Localization of cerebral symptoms, 389; of Rolando's fissure, 391.
- Chancre, 717; of the anus, 600; of the rectum, 600, 601; of the vulva, 757.
- Chancroid of penis, 713, 714; of rectum, 600; of vulva, 757.
- Changes, tissue, in inflammation, 55; in wounds, 68.
- Charcot. Localization of brain symptoms, 389.
- Cheek, moles of, 455; nævus, 455; plastic operations, 465.
- Cheiloplasty, 462, 463.
- Chelius. Aneurismal varix, 192.
- Chest, foreign bodies, 524; gunshot-wounds of, 523; injuries of, 523; wounds, 523.
- Chevalier. Vascular tumors, 194.
- Chiene. Operation for genu valgum, 807.
- Chin, bandage, 21.
- Chisels, 38.
- Chloral hydrate in rabies, 82; in tetanus, 90.
- Chloride of iron in aneurism, 206; in erysipelas, 87.
- Chloride of zinc as an antiseptic, 3, 5.
- Chloroform as an anæsthetic, 25, 33; advantages of, over ether, 25; death from, 34; death-rate of, 25; in rabies, 82; in tetanus, 90; test for purity of, 34.
- Cholecystotomy, 584.
- Cholesteatoma, 848.
- Cholesterin crystals in pus, 62.
- Chondritis, 504.
- Chondroma, 855; of the finger, 834.
- Chopart's amputation through the tarsus, 139.
- Chordee, 678; treatment of, 680.
- Choroiditis, 416, 437.
- Chromic acid, as an escharotic in the larynx, 506; catgut, 2.
- Cicatrization in wounds, 70.
- Circular skin flaps in amputations, 110.
- Circumcision, 711; cocaine anæsthesia for, 24.
- Circumflex nerve, injury to, in dislocation of humerus, 333.
- Cirrhosis of ovary, 772.
- Cirsoid arterial tumor, 190.
- Citrate of potash after lithotrity, 654; calculus, 623; for hæmaturia, 645; for renal calculus, 623; for urethritis, 680; in cystitis, 633.
- Clamp for hæmorrhoids, 616; of Dupuytren, 570; scrotal, 743.
- Clavicle, absence of, 826; amputation, 134; dislocations, 326; excision, 134, 522; fractures, 292; ostitis, 522.
- Cleanliness, personal, 49.
- Cleansing the hands before operations, 49; of gunshot-wounds, 73; of parts in amputations, 109; of wounds, 73.
- Cleft palate, 478, 481; operation for, 23; instruments for, 35.
- Clover's inhaler, 28.
- Club-foot, 810.
- Club-hand, 828.
- Coagulation in inflammation, 55; in veins, 167, 168; in wounds, 68; necrosis in arteritis, 179, 180.
- Cobra venom, 78, 79.
- Cocaine anæsthesia, 22; for catheterization, 636; for incision of bubo, 685; for incision of furuncles, 97; for opening of abscesses, 64; in abdominal section, 588; in anal fissure, 599; in anal fistula, 597; in aspiration of gall-bladder, 584; in conjunctivitis, 407; in exploration of urethra, 689; in extraction of cataract, 420; in extraction of teeth, 477; in fasciotomy of hand, 831; in hæmorrhoids, 612, 617; in incomplete lithotrity, 654; in keratitis, 412; in laryngeal operations, 506; in ligation of varix, 200; in operation for cleft palate, 478; for hydrocele, 739; for ingrowing toe-nail, 825; for varicocele, 741; in operations on tendons of fingers, 832; in phalangeal amputations, 121; in phlegmon of finger, 835; in pruritus ani, 594; in removing moles, 201; in the surgery of external ear, 438; in tonsillotomy, 490; in urethrotomy, 692, 693; in venesection, 57; suppositories in anal affections, 602.
- Coccyx, dislocations, 608; fracture, 306; neuralgia, 608.
- Cod-liver oil in furuncle, 97; in morbus coxarius, 360.
- Cohnheim. Calcification of arteries, 180; cell proliferation in inflammation, 55; emigrant corpuscles, 171.
- Cold abscess, 62, 63, 66.
- Cold, action of, on animal tissues, 97; as an anæsthetic, 24; as a hæmostatic, 73; in inflammation, 58; in lymphangitis, 163; in tetanus, 90; in wounds, 73.
- Cold water in burns, 93.
- Colic, renal, 620, 623.
- Collapse in burns, 93.
- Colles. Case of aneurism, ligation of subclavian, 224; harelip, 460; fracture of radius, 301; transmissibility of syphilis, 732.
- Colloid carcinoma, 839; cysts, 850.

- Colon, exsection of, 546.
 Color-blindness, 424.
 Colostomy, 537, 576, 593.
 Colpo-cystotomy, 761.
 Columnar epithelioma, 842.
 Common carotid, aneurism of, 220; ligation of, 237; statistics of, 242.
 Common iliac artery, aneurism of, 229; ligation of, 264.
 Compound fractures, 280, 284; of leg, 321; of patella, 318.
 Compress, umbrella, 662.
 Compression in inflammation, 58; instrumental, in aneurism, 206; in synovitis, 352; of ankle, 365; in vascular tumors, 193; of the brain, 284, 387.
 Concretions, calcareous, in veins, 199; intestinal, 531; in the prostate, 675; of the gall-bladder, 584.
 Concussion of the brain, 285; diagnosis from compression, 285.
 Condylomata, syphilitic, 720.
 Congenital adhesions of prepuce, 712; hernia, 565; hydrocele, 736.
 Conjunctiva, anæsthesia of, by cocaine, 22.
 Conjunctivitis, erupous, 409; diphtheritic, 410; follicular, 407; granular, 408.
 Conoidal projectiles, 90.
 Constant irrigation, 7; in inflammation, 59.
 Constriction of arteries in inflammation, 58; of intestines, 535; of limbs for internal hæmorrhage, 77; of vessels in inflammation, 55; of vessels in wounds, 70.
 Contagion of anthrax, 83.
 Contagiousness of hospital gangrene, 104.
 Continuity and contiguity, terms used in amputations, 107.
 Continuous compression, for aneurism, 206; suture, 75.
 Contraction of the hand due to paralysis, 830; of the mouth, 446; of the palmar fascia, 830.
 Contrecoup, 284.
 Control of hæmorrhage from wounds, 71; in operations on the tongue, 486.
 Contused wounds, 68.
 Contusions of the abdominal walls, 586; of the face, 396; of the kidney, 619; of the scrotum, 734.
 Cooper. Case of aneurism (ligation of aorta), 223, 229; ligation of innominate, 235; treatment of dislocation of elbow, 336.
 Coote. Vascular tumors, 197.
 Copaiba balsam in gonorrhœa, 682.
 Copperhead, venom of, 79.
 Copper, sulphate of, for conjunctivitis, 408.
 Coracoid process, fracture of, 294.
 Cord, spermatic, affections of, 744; hydrocele of, 735.
 Corneitis, 412.
 Cornil and Renvier. Angioma, formation of, 196; arterial ligation, 189; arteries, histology of, 172; arteritis, 179; syphilitic, 183; cavernous tumors, 196; classification of tumors, 837; giant-cells in sarcoma, 844; induration and hypertrophy of glands, 839; metastasis, 839; ostitis, 277; permanent occlusion of arteries, 189; pathology of tumors, 837; phlebitis, 165, 167, 168; spinal tuberculosis, 787; structure of arteries, 172; varix, 197, 199; veins, histology, 165.
 Corning. Cocaine anæsthesia, 23.
 Corns, 824, 849.
 Coronoid process, fractures of, 300.
 Corpora cavernosa, fracture of, 707.
 Corpusele, compound granular, 62.
 Corrosive sublimate as an antiseptic, 3.
 Cotton, absorbent borated, 9.
 Cotton-batting in gangrene, 102, 103.
 Cotton, styptic, 73.
 Counter-irritants in inflammation, 60.
 Cradle, Reeves's suspensory, 799; swinging, for elevation, 57.
 Cramps, a symptom of gangrene, 103.
 Cranium, fracture, 284.
 Creoline as an antiseptic, 3, 4, 765.
 Crepitus in fracture, 280.
 Crinoline bandages, 10.
 Critchet, iridectomy, 414.
 Crosby. Aneurism, treatment of, 208; dislocation of the hip, treatment of, 343; fracture bed, 307.
 Cross-suture, 76.
 Crotalus, 76.
 Croup, laryngeal tubes in, 499; tracheotomy in, 499.
 Croupous conjunctivitis, 409.
 Crushing of stone in the bladder, 650.
 Cruveilhier, arterial varix, 190; case of ligation of subclavian and carotid, 257; phlebolites, 200.
 Crystalline lens, 418.
 Cuboid bone, amputation of, 146.
 Cuneiform bones, amputation of, 146.
 Cupped sound, 673.
 Curette, urethral, 701.
 Curvature, anterior, of the spine, 786; lateral, of the spine, cervical, 779; dorsal, 782; posterior, of the spine, 787.
 Cutaneous, angioma, 195; arterial tumor, 195; capillary tumor, 195; vascular tumors, 190; venous tumors, 195.
 Cyclitis, 416.
 Cylinder-celled epithelioma, 842.
 Cyphosis, 78.
 Cyst, 850; hydatid, *vide* hydatid; of antrum of Highmore, 471; of broad ligament, 774, 775; of conjunctiva, 410; of kidney, 623; of larynx, 506; of lip, 455; of lower jaw, 474; of mammary gland, 517; of neck, 493; of nipple, 513; of ovary, 774; of pancreas, 586; diagnosis, 622; of scalp, 382; sebaceous, 383; serous,

- 386; of scrotum, 734; of spleen, 586; diagnosis, 622; of testicle, 748, 749; of thyroid body, 494; of tongue, 483; of tonsil, 490; of vesiculæ seminales, 744.
- Cystadenoma of ovary, 774.
- Cystic degeneration of ovary, 771; dilatation of lymphatic vessels, 165; polypus of rectum, 607.
- Cysticercus of the tongue, 483.
- Cystine calculus, 647.
- Cystitis, 632; cause of pyelitis, 620.
- Cystocele, 629, 760.
- Cystoma of parotid gland, 468.
- Cystoscope, 640.
- Cystotomy, 654; of gall-bladder, 586; perineal, 630, 638, 658; supra-pubic, 654.
- Czerny-Lembert suture, 528, 542.
- Dacryo-adenitis, 406.
- Dacryo-cystitis, 406.
- Dacryoliths, 406, 443.
- Dactylitis, syphilitic, 726.
- Daniel. Curette, 411; spoon, 421.
- Davidson. Syphilitic arteritis, 183, 187.
- Davis. Spinal brace, 791.
- Davy. Treatment of external iliac aneurism, 230.
- Dawbarn. Exsection of intestine, 569.
- Death-rate in amputations, 107; in tetanus, 89.
- Dechamps. Aneurism, 209.
- Deformities, 779.
- Deformity of the femur, 804; of the fingers, 829, 834; of the hand, 828; of the knee, 804; of the lower extremity, 801; of the spine, 779; of the toes, 822; of the upper extremity, 826.
- Degeneration of arteries, 177, 179; of thyroid gland, 495; of ovaries, cystic, 771.
- De Lacerda. Serpent-wounds, treatment of, 80.
- Deligation, *vide* ligation; of arteries, *vide* artery; cause of arteritis, 173; for angioma, 197; for cutaneous vascular tumors, 192; occlusion of arteries by, 188.
- Delpsch. Ligation of axillary artery, 260.
- Demarkation, line of, in gangrene, 101.
- Demarquai. Injections for vascular tumors, 193.
- Demarre. Retractors, 411.
- Denis. Coagulation of blood, 167.
- Dennis. Emphysema of abdominal cavity, 587; open method of treating amputations, 119.
- Deposits, urinary, 641.
- Depression of cranial bones in fractures of the skull, 284.
- Dermatitis, 84, 163.
- Dermoid cysts, 850; of the mamma, 517; of the ovary, 774.
- Dermoplasty, 94.
- Destruction of skin by acids, etc., 97.
- Detachment of retina, 424.
- Deviation of nasal septum, 445.
- Diabetes mellitus, 642.
- Diachylon plaster for ulcers, 99; in burns, 94.
- Diaphragmatic hernia, 555; treatment, 573.
- Diarrhoea in hospital gangrene, 105.
- Dick. Gum bougie, 689.
- Didot. Operation for web-finger, 830.
- Dieffenbach. Amputation of hip, 155; rhinoplasty, 448.
- Digital compression in aneurism, 207.
- Digitalis for aneurism, 206.
- Diffuse aneurism, 202, 204.
- Diphtheria, laryngeal tube for, 499; tracheotomy in, 499.
- Diphtheritic conjunctivitis, 410.
- Dilatation of preputial orifice, 711, 713; of vessels in arteritis, 179; in inflammation, 55; of urethral stricture, 692.
- Diplopia, 433.
- Direct pressure, for aneurism, 208.
- Director, grooved, 43.
- Disarticulation at astragalus, 139; at calcaneus, 139; at carpo-metacarpal joint, 124; at carpo-radial joint, 126; at hip, 153; at knee, 148; at metatarsal joint, 136; at shoulder, 131, 133; at tarso-metatarsal joint, 135; at tibio-tarsal joint, 142; of finger-phalanges, 121; of toes, 135.
- Discission for cataract, 422.
- Diseases of the joints, 351.
- Disinfection in hospital gangrene, 106; of hands in amputations, 110; of instruments, 3.
- Dislocations, 325; complicated, 325; compound, 325; congenital, 325; diagnosis, 325; partial, 325; pathological anatomy of, 333; pathological, 340; primitive, 325; prognosis of, 346; secondary, 325; traumatic, 325, 340.
- Dislocation of the ankle, 348; backward, 349; compound, 349; forward, 349; inward, 348; outward, 348; of the astragalus, 349; of the clavicle, 326; of the elbow, 324; of the fibula, at ankle, 348, 349; of the fingers, 338; of the foot, 348; of the hand, 337; of the hip-joint, 338; congenital, 340; diagnosis, 340; iliac, 340, 344; pubic, 339, 345; reduction, 342; with pulleys, 344; sciatic, 340; statistics, 339; thyroid, 341, 344; of the humerus, 327; sub-acromial, 333; subcoracoid, 327; subclavicular, 327, 330; subglenoid, 330; subspinous, 333; of the jaw, 325; of the knee, 346; of the lower jaw, 325; of the metacarpo-phalangeal joints, 338; of the patella, 348; of the phalanges, 338; of the radial head (subluxation), 334; of the radius and ulna at elbow, 324; of the ribs, 350; of the shoulder, 327; subacromial, 333; subcoracoid, 327; of the spine, atlo-axoid, 350; occipito-atloid, 350; of the tarsal joints, 350; of the tarsus, 350; of the thigh, 338; of the tibia, 347; of the vertebrae, 350; of the wrist, 337.
- Displacements of abdominal organs, 586.
- Dissecting aneurism, 202, 204.
- Dissection wounds, 84.

- Distal ligature for aneurism of aorta, 213.
 Distribution of assistants and nurses during operation, 50.
 Diverticulum of intestines, 535; of œsophagus, 512.
 Division of urethral stricture, 692.
 Divulsion of anus, 599; of prepuce, 713; of urethral stricture, 692.
 Dobbel's solution, 444.
 Dog-bite, 81.
 Dorsalis pedis artery, ligation of, 274.
 Double crescentic flap, 117; rectangular flap, 118.
 Double-current catheter, 634, 687.
 Double-knot, 52.
 Double-needle suture, 76.
 Drainage of bladder, 630, 638; of skull, 394; in amputations, 109, 114; in carbuncle, 99; in fracture of skull, 394; in gunshot-wounds, 74; in osteomyelitis, 278; in suppuration of knee, 364; in wounds, 74; tubes, 7.
 Drains, bone, 7.
 Dressings, 1; apparatus used in, 1; application of, after operations, 53; after amputations, 114, 115; permanent, 53.
 Dressing-scissors, 42.
 Drilling for drainage of antrum of Highmore, 471; the trochanter in morbus coxarius, 362.
 Drills, bone-, 38, 372.
 Dropsy, abdominal, diagnosis, 622.
 Drum for testing edge of instruments, 417.
 Dry gangrene, 103.
 Duct of Steno, affections of, 466.
 Dugas. Dislocation of humerus, 328, 331.
 Dunglison. Phlebotomy, 200.
 Duodenostomy, 530.
 Duodenum, operations on, 530.
 Dupuytren. Case of aneurism, 220; contraction of palmar fascia, 830; operation for strangulated intestine, 570; method of amputation at shoulder-joint, 134.
 Dura mater, carcinoma of, 385; sarcoma of, 385.
 Durante. Permanent occlusion of arteries after deligation, 189.
 Dutoit. Case of aneurism, 227.
- Ear, adhesions, 438; cartilaginous tumors, 438; diseases and injuries, 438; drooping, 438; hypertrophy, 438; instruments for, 438; specula for examining, 439; wounds, 438.
 Eburnated osteoma, 856; osteitis, 276.
 Ecchymoma, 195.
 Echinococci, *vide* hydatid.
 Écraseur, in ablation of the tongue, 486.
 Ectropion, 401.
 Eczema of the anus, 594; of the eyelids, 405; of the nipple, 513; of the scrotum, 734.
 Edison. Electric illumination, 44.
 Effusion, serous, into sheath of cord, 735; into tunica vaginalis, 735; of joint, *vide* synovitis.
 Elastic bandage, Esmarch's, 41; fiber in veins, 165, 166; ligature, 41; for fistula ani, 598; silk for varix, 200.
 Elbow-joint, amputation at the, 128; ankylosis, 827; disarticulation, 334; dislocation at the, 334; exsection, 377; synovitis, 367.
 Electric arc in suprapubic cystotomy, 655.
 Elephantiasis, 200; nævoid, 196; of the head, 383; of the scrotum, 734.
 Elevation as a hæmostatic in wounds, 73; in erysipelas, 86; in gangrene, 102; in inflammation, 57; in phlebitis, 171; of parts of skull, 391.
 Elliot. Case of aneurism, of innominate artery, 217.
 Emboli, 167.
 Embolism, arterial, 188; fatty, 283.
 Embryonic tissue in inflammation, 56; in wounds, 69.
 Emergency tourniquet, 72.
 Emigration of leucocytes in inflammation, 55.
 Emmet. Cervix-scissors, 763; needles, 43; perinæorrhaphy, 757.
 Emmetropia, 426.
 Emphysema of abdominal cavity, 587; subcutaneous, in gangrene, 101.
 Emprosthotonos in tetanus, 89.
 Empyema, 552; diagnosis, 583; irrigation of, 4, 523.
 Encephalocele, 385.
 Encephaloid, 839; of mammary gland, 518; of rectum, 605.
 Enchondroma, 856; of ear, 438; of larynx, 506; of lower jaw, 474; of mamma, 516; of parotid gland, 468; of tongue, 483; of testicle, 748.
 Endarteritis, 171, 175; obliterans, 174; syphilitic, 723, 724.
 Endocarditis rheumatica, 187.
 Endophlebitis, 165.
 Endostitis, 275.
 Enostosis, 856.
 Ensor. Case of aneurism, of the innominate artery, 217.
 Enterocoele, 551.
 Enterolithes, 531.
 Enterostomy, 537.
 Entropion, 404.
 Enucleation of eye, 416; of tumor of mamma, 520.
 Eosine-test-gauze, 9.
 Epicanthus, 405.
 Epicystotomy, 654, 657, 664.
 Epididymitis, 744; chronic, 737; gonorrhœal, 683; tuberculous, 747.
 Epilepsy, operation for, 393.
 Epiphora, 405.
 Epiplocele, 551.
 Epispadias, 705.
 Epistaxis, 442.
 Epithelia in the urine, 643.

- Epithelioma, 839, 840; of the anus, 605; of the bladder, 640; of the breast, 519; of the intestine, 536; of the larynx, 506; of the lip, 453; of the mammary gland, 519; of the nipple, 513; of the nose, 444; of the œsophagus, 511; of the penis, 707; of the rectum, 536, 605; of the serotum, 483; of the vulva, 757.
- Equinia, 82.
- Equinus, talipes, 811.
- Erectile tumors, 195.
- Erichsen. Exarticulation of phalanges, 121.
- Ergot as a hæmostatic, 71; for aneurism, 206, 211; for angeioma, 197; for hæmaturia, 645; in abdominal hæmorrhage after rupture of organs, 587.
- Erysipelas, 84, 86, 163; dressings in, 87; isolation in, 86; local treatment, 86; of serotum, 734; phlegmonous, 86; precautions against, 87; prophylaxis, 86.
- Erythema, 85, 163; anal, 86; gyratum, 86; iris, 86; nodosum, 86; of anus, 594.
- Escape of leucocytes from blood-vessels in inflammation, 55.
- Escharotic, for angeioma, 197.
- Eserine in extraction of cataract, 421.
- Esmarch's bandage during irrigation, 3; for aneurism, 208; for wounds, 73; in amputations, 108; chloroform apparatus, 33; method of curing angeioma, 197; of exarticulation at shoulder-joint, 134; at carpo-metacarpal joint, 124; of exarticulation of phalanges, 121; of treating aneurism, 209.
- Esophoria, 433.
- Ether, administration of, by the rectum, 26; inhalation of, 25; inhaler, 28; in the reducing of fractures; 284; solution of iodoform in, 5; spasm of glottis in inhalation of, 29; spray, for local anaesthesia, 24.
- Evacuation of abscess, 64; of gas from intestine, 538; of liver, 583.
- Evans. Aneurism of innominate artery, 216.
- Eversion of the bladder, 627.
- Examination of urine, 641.
- Excision of astragalus, 376; of branches of fifth nerve, 473; of cervix uteri, 764; of hæmorrhoids, 616; of joints, 368; of malignant neoplasms, 846; of Meckel's ganglion, 472; of moles, 201; of the ankle-joint, 366, 374; of the breast, 519; of the carpus, 381; of the clavicle, 522; of the colon, 540; of the elbow, 377; of the eye, 416; of the gall-bladder, 589; of the hip-joint, 368; in coxitis, 360; of the inferior dental nerve, 476; of the interphalangeal articulations, 381; of the intestine, 539; indications for, 549; of the kidney, 626; of the knee-joint, 370; in suppuration, 364; of the larynx, 504; of the lower jaw, 475; of the maxillary nerves, 473; of the metacarpal articulations, 381; of the œsophagus, 511; of the parotid gland, 469; of the prolapsed rectum, 610; of the pylorus, 526, 529; of the rectum, 606; of the ribs, 521, 523; of the scapula, 523; of the shoulder-joint, 367, 376; of the speno-maxillary ganglion, 473; of the spleen, 586; of the submaxillary gland, 470; of the tarsus, 819; of the testicle, 749; of the thyroid gland, 496; of the tongue, 484, 485; of the tonsils, 490; of the upper jaw, 473; of the wrist-joint, 368, 379; of vascular tumors, 193; of wounds in rabies, 82.
- Exophthalmic goitre, 497.
- Exophoria, 433.
- Exostosis, 856; of the skull, 385; in fractures, 283.
- Expediency, amputations of, 107.
- Exploration of cranial vault, 391; of kidney, 625; of urethra, 689, *et seq.*
- Exsection, *vide* excision.
- Exsector, 39.
- Exstrophy of the bladder, 627; operation for, 628.
- Extension, after exsection of hip, 360; for morbus coxæ, 358; for synovitis of hip, 352; of knee, 362.
- External carotid, ligation of, 244.
- External iliac, aneurism of, 229; ligation of, 266, 268.
- Extirpation, *vide* excision; of angiomata, 197; of lymphatic glands, 164; of Meckel's ganglion, 472; of the eye, 416; of the fifth nerve, 473; of the kidney, 626; of the parotid gland, 469; of the spleen, 586; of the submaxillary gland, 470; of the thyroid gland, 496; of the upper jaw, 473.
- Extraction of cataract, 420; of foreign bodies through the urethra, 701; of the teeth, 477.
- Eye, 396; bandage for, 20; cysts, sebaceous, of, 398; enucleation of, 416; examination of the, 435; nævi near the, 397; new formations, 397; plastic operations near the, 397; tumors near the, 398; syphilis, 726; wounds, 397.
- Eyelids, affections of, 396, *et seq.*
- Fabrizzi. Rhinoplasty, 450.
- Face, bandage for, 20; contusions, 396; gunshot-wounds, 396; wounds, 395.
- Facial artery, ligation of, 250.
- Facial nerve, injury to, in extirpation of parotid, 469; in ligation of external carotid, 247.
- Fallopian tubes, inflammation of, 770.
- False aneurism, 202, 204.
- False knot, 52.
- Fascia-knife, 35.
- Fasciotomy in Dupuytren's contraction, 831; in pes equino-varus, 818.
- Fecal fistula, 549; diagnosis and treatment, 574.
- Fehleisen. Erysipelas-coccus, 84.
- Felon, 834.
- Femoral artery, aneurism of, 230; ligation of, 269.

- Femoral hernia, 554; diagnosis and treatment, 570.
- Femur, 307; dislocations, 338; fractures, 307, *et seq.*; osteotomy, 802, 804.
- Ferguson. Case of aneurism, 218, 227; lithotomy guide, 658.
- Fever of reaction, 53; syphilitic, 721.
- Fibrin, theory of formation of, 168.
- Fibro-chondroma, 856.
- Fibro-lipoma, 851.
- Fibroma, 852; of antrum of Highmore, 471; of bladder, 640; of intestine, 536; of larynx, 506; of lips, 455; of lower jaw, 474; of mamma, 516; of nipple, 513; of nose, 443; of parotid gland, 468; of tongue, 483; of tonsils, 490; of urethra, 706.
- Fibromyoma of intestine, 536; of lower jaw, 474; of ovary, 776.
- Fibrous union in fractures, 323.
- Fibula, dislocations of, at ankle, 348; fractures of, 318.
- Fifth nerve, excision of branches of, 473.
- Figure-of-eight bandage, 12.
- Fingers, amputation of the, 120; bandages for, 13; contraction, 830; deformities, 829; disarticulation, 121; jerk-, 832; snap-, 832; supernumerary, 829; syphilis, 726; webbed, 829.
- Fischer. Case of aneurism, 230; wounds of the heart, 524.
- Fissure of the anus, 594, 599; of the lips, 454; of the nares, 444; of the nipple, 513; of the palate, 479.
- Fistule, biliary, 584; dissecting out, 597; fecal, 549; diagnosis and treatment, 574; intestinal, 549; of the anus, 512, 595; operation for, 597; of the œsophagus, 512; of the scrotum, 735; salivary, 466; vesico-vaginal, 761.
- Fixation of knee, for suppuration, 364; of shoulder, 367.
- Flap, double crescentic, 117; double rectangular, 118; modified circular skin, 117; mixed, 118; oblique solid, by transfixion, 115; by cutting from the surface, 116; oval, 117; skin, circular, 116, 129; solid, circular, 110.
- Flaps, formation of, in amputation, 109, 116, 118.
- Flat-celled epithelioma, 842.
- Flat foot, 821.
- Fletcher. Serpent-venom, 79; treatment of serpent-bite, 79.
- Flexion of fingers, 830; of toes, 824.
- Flint. Fatality of rabies, 82.
- Floating kidney, 627.
- Fluhrer. Case of penetrating wound of skull, 387; swinging cradle, 57.
- Flour, for burns, 94.
- Foot, *vide* ankle; also amputations, dislocations, etc.; bandage for, 15.
- Forbes's amputation through the tarsus, 138.
- Forceps, anatomical-, 42; artery-, 41; bone-, 38; for extracting teeth, 477; for foreign bodies in trachea, 503; gouge, 39; hæmostatic, 41; lion-jawed, 39; lithotomy-, 660; mouse-toothed, 41, 43; needle-, 42, 77, 762; phimosi-, 712; sac-, 777; sequestrum-, 39; Sims's needle-, 762; urethral, 701.
- Fore-arm, amputation of, 127; bandage for, 14; fractures of, 300.
- Foreign bodies in the anus, 595; in the auditory canal, 438; in the bladder, 645, 665; in the bronchial tubes, 501; in the cornea, 411; in the intestines, 530, 539; in the larynx, 501; in the nose, 442; in the œsophagus, 442, 507; in the pharynx, 507; in the rectum, 531, 595; in the skull, 387; in the stomach, 527; in the trachea, 501; in the urethra, 700; in the vitreous humor, 423.
- Formation of capillaries in veins, 166; in wounds, 69.
- Forster. Pathology of tumors, 837.
- Foster. Cataract, 419; coagulation of blood, 161.
- Four-tailed bandage, 20.
- Fowl-bones as drains, 8.
- Fox-bite, 81.
- Fracture-box, 320.
- Fractures, 280; comminuted, 280; complicated, 280; compound, 280, 284; crepitus in, 280; direct, 280; fibrous union in, 323; impacted, 280; indirect, 280; of the acetabulum, 307; of the carpal bones, 304; of the clavicle, 292; of the coccyx, 306; of the corpora cavernosa, 707; of the femur, 307; condyles of, 313; great trochanter, 312; neck, 307; shaft, 312; of the fibula, 318; of the foot, 323; of the forearm, 300; of the head, 284; of the humerus, 295; condyles of, 297, 298; neck, anatomical, 295; surgical, 295; shaft, 297; tuberosities, 295; of the hyoid bone, 292; of the ilium, 307; of the inferior maxilla, 289; of the innominate bone, 306; of the ischium, 307; of the larynx, 292; of the leg, 318; compound, 321; of the lower jaw, 289; of the malar bone, 288, 289; of the metacarpal bones, 287; of the metatarsal bones, 323; of the nasal bones, 287; of the patella, 314; compound, 318; of the penis, 707; of the phalanges, 305, 323; of the pubes, 307; of the radius, 300; at inferior extremity of, 301; diagnosis, 337; at superior extremity, 300; of the ribs, 305; of the sacrum, 306; of the scapula, 294; at acromion process of, 294; at coracoid process of, 294; at glenoid process of, 295; at spine of, 295; of the skull, 284; at its base, 284, 395; with depression, 284; of the sternum, 305; of the tarsus, 323; of the tibia, 318; of the ulna, 300; at coronoid process, 300; at olecranon process, 299; of the upper jaw, 288; of the vertebræ, 305; at articular process, 306; at spinous process, 306; of the zygomatic process, 289; partial, 280; prognosis, 283; simple, 280; subcutaneous,

- from projectiles, 92; symptoms of, 281; treatment of, 283; ununited, 323.
- Franklin. Phlebotomies, 200.
- Freezing mixtures for local anæsthesia, 24.
- Freund. Hysterectomy, 769.
- Frey. Pathology of the veins, 166.
- Fricke. Heat in tetanus, 89.
- Friction-knot, 52.
- Frontal bone, gunshot-wounds of, 90.
- Frontal sinus, 445; abscess of, 384, 445.
- Frost-bite, 97.
- Fungi in inflammation, 60.
- Fungus hematodes, 195.
- Furuncle, 97.
- Fusiform aneurism, 202, 203.
- Galactocoele, 517.
- Galbanum in lymphadenitis, 164.
- Gall-bladder, 584; abscess of, 584; concretions, 584; distention of, diagnosis, 583.
- Galt. Trepine, 40.
- Galvano-cautery of tongue, 485.
- Galvano-puncture for aneurism, 210; for angioma, 197; for vascular tumors, 193.
- Ganglion, 830; of Meckel, excision of, 472.
- Gangrene, 100; after frost-bite, 97; hospital, 104; in chancre, 99; of scrotum, 734; of tissue in inflammation, 56; of tissue in wounds, 69; senile, 103.
- Gant. Excision of the tongue, 487; osteotomy of femur, 802.
- Garreau. Prostatic syringe, 673.
- Gases in gangrene, 100.
- Gastrectomy, 526.
- Gastro-enterostomy, 528.
- Gastrostomy, 510, 525.
- Gastrotomy, 525, note.
- Gauge for urethral instruments, 698.
- Gauze, disinfecting of, 3; preparation of, 9.
- Gay. Case of aneurism, 224; phlebitis, 169.
- Genito-urinary organs, affections of, in the female, 751; in the male, 619.
- Genu valgum, 804; varum, 809.
- Germ in hospital gangrene, 104; *vide* also micro-organisms.
- Gerster. Case of aneurism of innominate artery, 217.
- Giant-celled sarcoma, 844, 846.
- Gibney. Morbus coxæ, 354; Pott's disease, 799.
- Gibson. Excision of vascular tumor, 193.
- Gila-monster, venom of, 80.
- Girdner. Phimosi forceps, 712; skin-grafts, 95.
- Gland, lachrymal, etc., *vide* lachrymal, etc.
- Glanders, 82.
- Glaucoma, 417; fulminans, 417, 437.
- Gleet, 686; diagnosis, 672.
- Glendoid process, fracture of, 295.
- Glioma, 846.
- Glossitis, 482.
- Glottis, spasm of, in ether narcosis, 29.
- Gluteal artery, aneurism of, 230; ligation of, 267.
- Gluteal hernia, 555; diagnosis and treatment, 573.
- Goitre, 493; cystic, 494; exophthalmic, 497; operations for, 495.
- Gonococcus, 677.
- Gonorrhœa, 676; injections in, 680; in the female, 685, 757; syringe for, 681; treatment of, 679.
- Gonorrhœal bubo, 684; ophthalmia, 408; rheumatism, 685.
- Goodwillie. Hollow needle, 480; mouth-gag, 478; periosteal elevator, 27, 38.
- Gore. Case of aneurism, 223.
- Gosselin. Arterial cirroid tumors, 190, 191, 194.
- Gouges, 38.
- Gouging in arthritis of ankle, 366; of wrist, 368.
- Goujon. Experiments on tissue formation, 56.
- Gouley. Lithoclast, 661.
- Gout, cause of arteritis, 173.
- Gouty phlebitis, 168, 169.
- Gowan. Exsector, 40.
- Gown, operating, 49.
- Graefe. Case of aneurism, 223; excision of vascular tumor, 192; fixation forceps, 420; hare-lip, 460; iridectomy, 414; linear knife, 420; speculum, 420; strabismus-hook, 425.
- Grafting of skin for burns, 94; Thiersch's method of, 95.
- Granular, cells in wounds, 70; corpuseles, compound, 62; metamorphosis in wounds, 70.
- Graves's disease, 497.
- Green. Calcareous deposits in veins, 199; coagulation of blood, 168; endarteritis, 176, 187.
- Greenfield. Syphilitic arteritis, 183, 187.
- Gritti's amputation at the knee, 152.
- Grooved director, 44.
- Gross. Cavernous tumors, 196; ligation of internal jugular vein, 253; nævoid elephantiasis, 196; phlebitis, 168; phlebotomies, 200; sarcoma of bone, 845.
- Gruening. Depilating forceps, 407.
- Guéniot. Excision of vascular tumor, 193.
- Gum-lancet, 37.
- Gummata, 722; differential diagnosis from furuncle, 98; of tongue, 484.
- Gunderloch and Müller. Ligation of carotid for vascular tumor, 192.
- Gunshot missiles, 91; wounds, 68; hæmorrhage from, 71; of the abdomen, 587; of the alimentary canal, 588; of the bladder, 629; of the brain and membranes, 286; of the chest, 523; of the face, 396; of the hand, case of, 832; of the heart, 524; of the neck, 492; of the skull, 286.
- Gunther's amputation, 145.
- Gypsum bandages, 10; for fractures, 296, 311.
- Hæmatin, causing redness in inflammation, 55.
- Hæmatocele, 735.

- Hæmatoma of the cord, 741; of the tunica vaginalis, 735; of the vulva, 751.
- Hæmaturia, 619, 643.
- Hæmorrhage after extraction of teeth, 477; from moles, 201; in gunshot-wounds, 21, 92; in hospital gangrene, 105; in operations on the tongue, 485; method of controlling, 486; of the kidneys, 619.
- Hæmorrhoids, 198, 611; external, 64; internal, 611, 613; ulcers after, 600, 601.
- Hæmostasis, methods of, 51; in wounds, 71; in vessels wounded, 71, 73.
- Hæmostatic forceps, 41.
- Hairs on the lip 455.
- Hale. Urethral forceps, 701.
- Hall. Case of aneurism, 223.
- Hallux valgus. 823.
- Hamilton. Dislocation at elbow, 337; fracture of humerus, 298; of lower jaw, apparatus for, 291; of malar bone, 288; of olecranon, 299; of patella, 315; of radius, 303; of thigh, long-splint in, 309; head-stall, 326; long splint, for osteotomy of femur, 802; for morbus coxæ, 359; phlebitis, 168; sequestrum forceps, 39; treatment of dislocation of hip-joint, 343, 345, 346.
- Hammer, 38.
- Hammer-toe, 824.
- Hancock. Disarticulation at calcaneo-astragaloid joint, 140; operation for peritonitis, 578.
- Hand, amputation of, 120; bandages for the, 13; contractions of, 831; deformities, 829; disinfection of, 3; phlegmons of, 834.
- Handkerchief-bandages, 20.
- Harelip, 456; double, 457; operation for, 458; of Colles, 460; of Graefe, 460; of Koenig, 460; of Langenbeck, 459; of Malgaigne, 459; of Nélaton, 459.
- Harris. Tooth-forceps, 477.
- Hart. Excision of vascular tumor, 193.
- Hausmann. Epithelioma of intestine, 536.
- Hayden. Case of aneurism, 224.
- Head, bandages for, 18, 19, 20; gunshot-wounds, 387; injuries and affections, 382; net, 21; wounds, 386.
- Headache, syphilitic, 721.
- Healing of wounds, 78.
- Heart, 524; gunshot-wounds, 524; syphilis, 724; wounds, 524.
- Heart-failure in ether and chloroform narcosis, 32.
- Heat, as a hæmostatic in wounds, 73; bodily, in tetanus, 89; in inflammation, 54; treatment of gangrene by, 101; of inflammation by, 60.
- Heath. Case of aneurism, 215, 216, 217.
- Heine. Excision of vascular tumor, 192.
- Heitzmann. Structure of arteries, 172; of veins, 165.
- Heloderma suspectum, 80.
- Hemeralopia, 424.
- Hemianopsia, 424.
- Hemiglossitis, 482.
- Hemiplegia, operation for, 391.
- Henle. Prostatic muscle, 639.
- Henry. Scrotal clamp, 734.
- Hepatic abscess, 582.
- Hernia, 550; cerebral, 385; diagnosis, 556, 736; diaphragmatic, 555; treatment, 573; femoral, 553; diagnosis and treatment, 570; operation for, 571; gangrenous, 539; gluteal, 555; inguinal, 550; irreducible, 572; lumbar, 555; needles, 562; obturator, 555; of the bladder, 629; of the brain, 385; of the labium, 758; of the lungs, 524; of the ovary, 758; of the spleen, 586; omental, diagnosis, 738; operation for, McBurney's, 559; Macewen's, 562; radical cure for, 559; statistics of, 550; strangulated, 566; treatment of, 558; truss for, 558; umbilical, 554; diagnosis and treatment, 572; vaginal, 555; ventral, 554; treatment of, 573; vesical, 629.
- Herpes, corneal, 412; of anus, 594; of penis, 713.
- Heterophoria, 433.
- Hey. Modification of Lisfranc's amputation of the foot, 137; saw for elevation of cranium, 392.
- Heubner. Syphilitic arteritis, 183.
- Hewitt. Pruritus vulvæ, 758.
- Hewson. Case of aneurism, 219.
- Highmore. Antrum of, affections of, 471, *vide* antrum.
- Hilton. Case of aneurism, 227.
- Hip-joint, ankylosis of, 801; amputation at, 154, 158; bursitis of, 357; deformities, 801; disease, 353; treatment of, 358; dislocations, 338; exsection, 368; neuralgia, 357; osteotomy near the, 802; ostitis, 357; rheumatism of muscles of, 357; synovitis, 357; tuberculosis, 354.
- Hobart. Case of aneurism, 215; case of ligation of subclavian and carotid, 257.
- Hodges. Case of aneurism, 219.
- Hodgkins. Disease, 163.
- Hodgson. Phlebolites, 200.
- Holder. Lid, 402; needle, 42, 77; knife, 765; *vide* apparatus.
- Holding. Method of, scalpel, 51.
- Holmes. Arterial cirroid tumor, 191; case of aneurism, 216, 219, 226; elastic ball for compression in aneurism, 227; phlebolites, 200.
- Holmgren. Color tests, 424.
- Holt. Self-retaining catheter, 638.
- Homatropine, 428.
- Hood-bandage, 20.
- Hordeolum, 399.
- Horse-hair for drains, 78; in aneurism, 210.
- Hornet-sting, 81.
- Horns of the scalp, 383.
- Horsley. Brain-surgery, 391.

- Hospital gangrene, 104.
 Hot water for controlling hæmorrhage in the brain, 392.
 Howship's caverns in inflammation of bone, 275.
 Humerus, dislocations of, 327; fracture, 295.
 Humphrey. Amputation of the penis, 709.
 Hunter. Aneurism, ligation of arteries in, 207, 209.
 Hunter, J. B. Vaginal hysterectomy, 765.
 Hutchison. Case of aneurism, 219; shoe in morbus coxæ, 359.
 Hutchinson. Nævi, 197; phlebitis, 168, 169.
 Hutton. Case of aneurism, 218.
 Hyalitis, 423.
 Hydatids of the bladder, 640; of the gall-bladder, 584; of the kidney, 622, 623; of the liver, 583; of the mammary gland, 517; of the thyroid gland, 494, 497.
 Hydrocele, 735; diagnosis, 557; bilocular, 737; congenital, 736; encysted, 738; of the spermatic cord, 735; radical cure of, 739; symptoms, 737; treatment, 738.
 Hydrocephalus, 386; tapping for, 386.
 Hydrogen gas in intestinal wounds, 588.
 Hydroma, 165.
 Hydronephrosis, 621; diagnosis, 579.
 Hydrophobia, 81.
 Hydrops of antrum of Highmore, 471.
 Hydropyonephrosis, 621.
 Hydrorhachis, 799.
 Hyoid bone, fracture of, 292.
 Hyperæmia in inflammation, 54, 55.
 Hyperdistention of abscess, 64.
 Hypermetropia, 426, 428, 429.
 Hyperostosis of antrum, 471.
 Hyperphoria, 433.
 Hyperplasia of parotid gland, 468; of thyroid gland, 493.
 Hypertrophy of the auricle, 438; of the lips, 445; of the mammary gland, 515; of the mucous membrane, 443; of the nose, 446; of the parotid gland, 468; of the prostate gland, 666; of the skin, 201; of the thyroid gland, 493; of the tongue, 483; of the tonsils, 490; of the turbinated tufts, 444.
 Hypodermic injections of carbolic acid in erysipelas, 87; of cocaine, 22, 23; of ergot as a hæmodynamic, 77; of whisky, 27, 32; in syncope, 77.
 Hypodermic syringe, in diagnosis of abscess, 64; of synovitis of the knee, 362.
 Hypopyon, 412.
 Hypophosphites in furuncle, 97; in morbus coxæ, 360; in rhachitis, 279.
 Hypospadias, 705.
 Hysteria, 89.
 Hysterectomy, abdominal, 766; during pregnancy, 768; for fibro-myomata, 769, 770; vaginal, 765.
 Hysterotomy, 766.
 Ice-bag, 58.
 Idiopathic arteritis, 177; phlebitis, 168, 169.
 Ileocolitis after ether narcosis, 33.
 Ileocolostomy, 550.
 Iliac artery, common, aneurism of, 229; compression of, 73, 154; ligation of, 264; external, aneurism of, 229; ligation of, 266-268; for femoral aneurism, 230; internal, aneurism of, 229; ligation, 266.
 Ilium, fracture of, 307.
 Immediate amputations, 107; exsection of strangulated intestine, 569.
 Impactions of cerumen in the ear, 439; of fecal matter in the intestine, 530.
 Imperforate anus, 574.
 Incised wounds, 68.
 Incisions in anthrax, 84; in carbuncle, 98; in dislocations, 322; in erysipelas, 87; in furuncles, 97; in gangrene, 102, 103; in hospital gangrene, 105; in inflammation, 57; in lymphadenitis, 164; in lymphangitis, 163; in morbus coxæ, 360; in periostitis, 277; in phlebitis, 171; in suppurations of the knee-joint, 363; of the shoulder-joint, 367; in swelling after serpent-bites, 80; in tetanus, 89.
 Incision of abdomen for intestinal occlusion, 538; of cold abscess, 66; of prepuce, 713.
 Incontinence of urine, 638.
 Incubation of erysipelas, 84; of rabies, 82.
 Indications for amputation, 108; for change of dressings, 53, 115; for the substitution of chloroform for ether, 25.
 Index-finger, amputation of, 123.
 Indolent ulcer, 99.
 Infantile hernia, 553.
 Infected surfaces, iodoform on, 5.
 Inferior maxilla, dislocation of, 325, *vide* jaw.
 Inferior thyroid artery, ligation of, 259.
 Infiltration of urine, 630.
 Inflammation, 54; abscesses in, 63; acute, 54; bleeding in, 57; calomel in, 64; causes of, 54; cicatrization in, 54; cold applications in, 58; compression in, 58; constriction of arteries in, 58; counter-irritants in, 60; formation of capillaries in, 69; heat in, 54; in treatment of, 58; in bone, 275; local symptoms of, 34; of penis, 706; pain in, 54; phenomena of, 54; poultices in treatment of, 58; resolution in, 56; suppuration in, 67; swelling in, 54; symptoms of, 54; treatment of, 58; venesection in, 57; vesicants in, 59; warm applications in, 58; without sepsis, 60.
 Ingrowing nail, 825.
 Inguinal bubo, 684, 715.
 Inguinal hernia, 550; congenital, 553; diagnosis of, 556; symptoms of, 555; in the female, 570.
 Inhalers, ether-, 28.
 Inherited syphilis, 732.
 Injections, hypodermic, *vide* hypodermic; of carbolic acid in erysipelas, 81; of cocaine, 23.

- Injections, in aneurism, 210; in arterial varix, 190; in gonorrhœa, 680; in hydrocele, 738; in vascular tumors, 193.
- In-knee, 804.
- Innominate artery, aneurism of, 212, 216; ligation of, 235; for subclavian aneurism, 223.
- Innominate bone, fracture of, 30.
- Inoculation, for rabies, 82; in tetanus, 88.
- Instruments, surgical, 35; disinfection of, 3; trays for, 48.
- Intercostal arteries, ligation of, 262.
- Intercostal artery, superior, ligation of, 256.
- Interdental splints, 290.
- Intermediate suture, 543.
- Internal carotid artery, ligation of, 242; jugular vein, ligation of, 237, 253; iliac artery, aneurism of, 229; ligation of, 266; mammary artery, ligation of, 255, 259; maxillary artery, ligation of, 253; pudic artery, ligation of, 268.
- Interphalangeal amputations, 120; exsections, 381; joints, synovitis of, 368.
- Interrupted suture, 53, 57.
- Intestine, concretions in, 530; constriction of, 835; exsection of, 539; fistula of, 549; foreign bodies in, 331; gunshot-wounds of, 588; internal strangulation, 535; intussusception, 532; obstruction, 530; occlusion of, abdominal section for, 538; puncture of, in obstruction, 538; suture of, 528, 542, 543, 589; wounds of, 587.
- Intima, in endarteritis, 176; of arteries, 172; of veins, 162; rupture of, a cause of arteritis, 174.
- Intraperitoneal abscess, 579.
- Intratrocantalic section of femur, 802.
- Intravenous injections, 78, 620.
- Intussusception, 532, 539.
- Invagination of intestines, 532.
- Involucrum, 275.
- Iodides, in aneurism, 206; in furuncle, 97; in goitre (cystic), 495; in Pott's disease, 799; in syphilis, 730.
- Iodine in spina bifida, 800.
- Iodoform as an antiseptic, 3; for amputations, 110; gauze, 9; in war, 92; in hospital gangrene, 105; solution of, in ether, 5; suppositories, 602, 607; vaseline for burns, 94; for ulcers, 100.
- Iridectomy, 412, 415, 417; with extraction of cataract, 421.
- Iris-forceps, 417.
- Iris-scissors, 417.
- Iris, syphilis of the, 415, 722, 726.
- Iritis, 415; rheumatic, 415; syphilitic, 415, 722, 726.
- Iron, chloride of, in aneurism, 206, 211; in furuncles, 97; perchloride of, in phlebitis, 171; in vascular tumors, 193, 197.
- Iron-dyed silk for sutures, 3.
- Irrigation, continuous, 5; in amputations, 120; during operation, 52; in inflammation, 58; of knee-joint, 363; of wounds, 3, 51, 74; of gunshot-wounds, 92.
- Irrigator, 6, 7.
- Irritable ulcers, 100.
- Irritation, a cause of inflammation, 55; of malignant tumors, 840.
- Ischium, fracture of, 307.
- Isolation of patients for hospital gangrene, 106.
- Jaeger's keratome, 417; lid-holder, 402.
- James. Case of aneurism, 229.
- Janeway. Case of albuminuria, 642.
- Jarvis's snare, 443.
- Jaw, lower, 470; affections of, 474; ankylosis, 476; bandage for, 118; dislocation, 325; excision, 475; fracture, 289; necrosis, 471; phosphorus disease, 471; upper, 471; abscess, 470; excision, 473; fractures, 289; syphilis, 471.
- Jequirity in pannus, 412.
- Jerk-finger, 832.
- Joints, diseases of the, 351; surgery of the, 325; syphilis, 724.
- Jones, Sydney. Excision of vascular tumor, 193.
- Jones, Wharton. Ectropion, 402.
- Jugular vein, ligation of, 237, 253; wounds of, in ligation of the carotid, 238.
- Juniper-oil for bone-drains, 8; for catgut, 2.
- Jury mast, 791, 795.
- Jute, 9.
- Keen. Brain-surgery, 392.
- Keith. Hysterectomy, 770.
- Kelotomy, 566.
- Kelsey. Hæmorrhoidal syringe, 563.
- Keratitis, 411; diffuse, 411; herpetic, 412; phlyctenular, 413; secondary, 412; traumatic, 412; ulcerative, 412.
- Key. Case of aneurism, 219.
- Keyes. Operation for varicocele, 741; varicocele needle, 741; wire stylet, 636.
- Key-hole saw, 37.
- Kidney, 619; abscess of the, 620; calculi, 620, 622, 626, 646; carcinoma, 624; contusions, 619; cysts, 623; displacement, 627; dropsy, 621; encephaloid, 624; exploration of, 625; extirpation, 626; floating, 627; hæmorrhage from, 619; hydratids, 623; hydronephrosis, 621; tumors, 623; syphilis, 725; wounds, 619.
- King. Case of aneurism, 217; snake-bite, 79; scrotal clamp, 743.
- Kingdon. Hernia statistics, 550.
- Kiotome, 671.
- Knapp. Entropion clamp, 404.
- Knee, affections of, 362; amputation at, 150; ankylosis, 810; bandage for the, 16; dislocations, 346; exsection, 370; knock-, 804; osteoarthritis of, 363; synovitis, 362.
- Knife-holder, 765.
- Knives, amputating, 35.
- Knock-knee, 804.

- Knot, 52, 75; double, 52; friction, 52; in intestinal sutures, 543; in sutures, 75; surgeon's, 52; reef, 52.
- Knotted bandage, 19.
- Koch. Corrosive sublimate, 3.
- Kocher. Dislocation of humerus, treatment of, 328; excision of tongue, 487; myxœdema after goitrous tumors, 495; thyroidectomy, 497; tumors of epididymis, 744.
- Koenig. Harelip, 460; rhinoplasty, 448.
- Koller. Cocaine, 22.
- Krackowitz. Cirroid aneurism, 194; enterovesical fistula, 575.
- Kühl. Case of ligation of subclavian and carotid, 257; ligation of carotid for vascular tumor, 192.
- Kunkler. Snake-bite, 79.
- Labial hernia, 758.
- Labat. Rhinoplasty, 448.
- Lacerated wounds, 68, 75; of face, 396.
- Laceration of cervix uteri, 763.
- Lacerda. Treatment of snake-bite, 801.
- Lachrymal gland, affections of, 405; extirpation, 405.
- Lachrymal sac, abscess of, 405.
- Ladinski, operating table, 45.
- Lambert. Case of aneurism, 221.
- Lagophthalmus, 400.
- Lane. Case of aneurism, 219.
- Lange. Case of aneurism, ligation of common iliac, 230.
- Langenbeck. Harelip, 445; incision in exsection of wrist, 379; operation for tumor of antrum of Highmore, 472; rhinoplasty, 448.
- Laparotomy for occlusion of intestine, 538; for ovariectomy, 776.
- Larrey's method of amputating at the shoulder-joint, 133.
- Laryngeal symptoms in aneurism, 211; tubes, 499.
- Laryngectomy, 504; partial, 505.
- Laryngotomy, 498; for foreign body, 502.
- Laryngo-tracheotomy, 499.
- Larynx, 498; foreign bodies in the, 501; fracture, 291; syphilis, 724; tubes for, 499.
- Lateral curvature of the spine, 779; cervical, 779; dorsal, 782.
- Lateral deviation of the septum of the nose, 445; lithotomy, 658.
- Lawrence. Strabismometer, 425.
- Laxatives in erysipelas, 87.
- Lead and opium wash in lymphangitis, 163; in synovitis, 352; subacetate of, in ulcers of the penis, 716.
- Lediard. Case of aneurism, 215.
- Lee. Amputation of the leg, 147.
- Leeches, 57; in epididymitis, 745; in inflammation, 57.
- Le Fort. Amputation, 144.
- Leg, bandages for, 16; amputation of the, 146; fractures, 318.
- Lembert. Suture of the intestine, 528, 542, 589; for the uterus, 768.
- Leopold. Hysterectomy, 766.
- Lens, affections of the, 418.
- Leucocytes, behavior of, in inflammation, 55; formation of capillaries by, in wounds, 70.
- Leucocythæmia, 586.
- Leucoma, 414.
- Levis. Extrophy of the bladder, operation for, 628; hydrocele, operation for, 739.
- Ligation, arterial, 73, 234; in amputations, 113; knots in, 52; of hæmorrhoids, 614; of the abdominal aorta, 264; for iliac aneurism, 229; statistics of, 266; of the anterior tibial artery, 273; of the ascending pharyngeal, 250; of the axillary, 259; of the brachial, 261; of the common carotid, 237; for occipital lesions, 252; statistics of, 247; of the common femoral, 271; of the common iliac, 264; statistics of, 266; of the dorsal, of the foot, 274; of the external carotid, 244; for extirpation of the parotid gland, 469; for wounds of the face, 396; statistics of, 247; of the external iliac, 266, 268; of the facial, 250; of the femoral, 269; of the gluteal, 267; of the inferior thyroid, 259; of the innominate, 235; of the intercostal arteries, 262; of the internal carotid, 242; statistics of, 244; of the internal iliac, 266; statistics of, 267; of the internal maxillary, 253; of the internal pudic, 267; of the lingual, 248, 483; of the occipital, 250; of the pharyngeal, ascending, 250; of the popliteal, 271; of the posterior auricular, 252; of the posterior tibial, 272; of the profunda femoris, 271; of the radial, 262; of the sciatic, 267; of the subclavian, 134, 253 *et seq.*, 256, 258; statistics, 259; of the superior thyroid, 248; of the temporal, 253; of the ulnar, 262; of the vertebral, 259; of varicose veins, 200.
- Ligature, 1; as hæmostatic, 1; animal, 1; application of, 52; arteritis after, 188; broad, 1; during operation, 48; elastic, 41; for aneurism, 206, 209; for arterial varix, 190, 232.
- Lignerol. Disarticulation at calcaneo-astragaloid joint, 139.
- Lime-water and oil for burns, 93.
- Line of demarkation, in gangrene, 101.
- Lingual artery, ligation of, 248.
- Linhart. Rhinoplasty, 448.
- Linseed-oil and lime-water for burns, 93.
- Lion-jawed forceps, 39.
- Lip, carbuncle of, 455; cysts, 455; epithelioma, 453; fatty tumors, 455; fibroid tumors, 455; fissure, 455; hair on, 455; hare-, 456; hypertrophy of, 445; moles, 455; nævus, 455; phlegmon, 455; plastic operations on, 462; syphilitic ulcers, 453; ulcers, 453; wounds, 452.

- Lipoma, 851; of intestine, 536; of lip, 455; of neck, 493; of scalp, 383; of tongue, 483.
- Liquefaction of tissues by micro-organisms, 61.
- Liquor puris, 61.
- Liquor sodæ chlorinatæ for gauze, 9; for sponges, 5.
- Lisfranc. Amputation, 137.
- Liston. Case of aneurism, 224; ligation of subclavian and carotid, 257; treatment of dislocations of the elbow, 336.
- Lithiasis conjunctivæ, 411.
- Lithoclast, 661.
- Lithotomy, 654; bilateral, 663; forceps, 660; guide, 661, 663; instruments, 661; knives, 35; labial, 658; lateral, 658; median, 663; perineal, 658; scoop, 661; suprapubic, 654, 657, 664; vesico-vaginal, 664.
- Lithotrity, 650.
- Little. Case of aneurism, 217, 227; lithotomy-knife, 36; lithotomy-staff, 663.
- Little finger, amputation of, 123; disarticulation of, at carpo-metacarpal joint, 125.
- Littre. Colostomy, 576.
- Liver, 582; abscess of, 582; carcinoma, 583; diagnosis, 584; hydatids, 583; syphilis, 725.
- Lizard, venom of, 80.
- Lizars. Case of aneurism, 223; case of ligation of innominate, 237.
- Lobular epithelioma, 841.
- Local anæsthesia, 22, 24; *vide* cocaine.
- Localization of motor paralyses, in brain-centers, 389.
- Lock-jaw, 88.
- Loeffler. Glanders, 83.
- Lordosis, 787.
- Lower extremity, deformities of the, 801; jaw, *vide* jaw.
- Lucas - Championnière. Cerebral localization, 389.
- Lumbar hernia, 555.
- Lupoid ulcer of rectum, 500.
- Lupus, of cheek, 454; of conjunctiva, 410; of lip, 454; of nose, 454; of vulva, 757.
- Lustgarten. Syphilis bacilli, 717.
- Luxations, *vide* dislocations.
- Lymph-fistula, 165.
- Lymphadenitis, 164; syphilitica, 724.
- Lymphadenoma, 843, 855; of kidney, 624.
- Lymphangiectasis, 493.
- Lymphangioma, 165, 854.
- Lymphangitis, 84, 86, 162; acute, 162; chronic, 163; diagnosis, 163; in erysipelas, 86; of the penis, 715; subacute, 163; syphilitic, 719, 722; treatment, 163.
- Lymphatic glands, inflammation of, 164; vessels, diseases of, 162; inflammation of, 84, 162; wounds of, 165.
- Lymphoma, 165; of the neck, 493, 494; of the tonsil, 490.
- Lympho-sarcoma of neck, 495.
- Macewen. Fowl-bone-drains, 8; operation for genu valgum, 807, 808; operation for hernia, 562.
- Mackenzie. Tonsillotome, 490.
- Mackintosh, 9.
- Macnamara. Drilling in morbus coxæ, 361.
- Maculæ, 414.
- Macular syphilide, 700.
- McBurney. Operation for hernia, 559; urethral fistula, 702.
- McCarthy. Case of aneurism, 217.
- McCormac. Operation for genu valgum, 809.
- McCosh. Exsection of intestine, 569.
- McGuire. Case of aneurism, 229.
- Malarial fever, a cause of hæmaturia, 643.
- Malformations of the anus and rectum, 591; of the urethra, 705.
- Malgaigne. Case of aneurism, 217; disarticulation at calcaneo-astragaloid joint, 139; hooks for patellar fracture, 317; operation for hare-lip, 459.
- Malignant pustule, 83; tumors, 839.
- Mallet, 38.
- Malleolus, dislocations of, 348; fractures, 318.
- Malpositions of the testicle, 750.
- Mammary artery, internal, 255; ligation of, 259.
- Mammary gland, 513; abscess of, 514; adenoid tumors, 515; affections of, 513; amputation of, 519; angioma, 513; bandage for, 17; colloid, 518; cystic tumors, 517; defect, 513; encephaloid, 518; epithelioma, 519; fibroma, 516; hypertrophy, 515; inflammation, 513, 514; malignant tumors, 515; sarcoma, 517; scirrhus, 518; syphilis, 515; tuberculosis, 517; tumors, 515.
- Manual compression in the treatment of aneurism, 210, 227.
- Marion-Sims, H. Drainage-tube for pelvis after laparotomy, 778; ether-inhaler, 29; incontinence of urine, 639; urethral speculum, 706.
- Marsden's paste, 444.
- Martin. Bandage, 99; for varix, 200.
- Mask, for ether inhalation, 28.
- Mason, Erskine. Amputation at hip, 155.
- Mason, L. D. Steel drills in fracture of nasal bones, 287.
- Massage in the treatment of aneurism, 210, 227.
- Mastitis, 514.
- Mastoid cells, affections of the, 440, 441; drainage of the, 441.
- Mattress suture, 75.
- Maunders. Case of aneurism, 215.
- Maxilla, *vide* jaw; inferior, dislocation of, 325; fracture of, 289.
- Maxillary artery, internal, ligation of, 253.
- Meatotomy, 691.
- Mechanical compression in the treatment of aneurism, 208.
- Meckel, diverticulum of, 536; ganglion of, excision of, 472.

- Median lithotomy, 663; nerve, injury to, in dislocation of the elbow, 335.
- Mediastinum, 523.
- Medication before operation, 49; in inflammation, 60.
- Medio-tarsal amputation, 139.
- Medullo-cells in tissue formation, 56.
- Megalopsia, 424.
- Melanotic carcinoma, 840; sarcoma, 845, 846.
- Membrane, abscess, 61, 63; mucous, of the tympanum, 440.
- Meninges, carcinoma of, 385.
- Meningitis, syphilitic, 723.
- Meningocele, 385.
- Mercier. Excisor, 671.
- Mercury, bichloride of, as an antiseptic, 3; in lymphadenitis, 164; in syphilis, 730.
- Meriwether. Case of aneurism, 231.
- Mesarteritis, 171.
- Mesophlebitis, 165.
- Metacarpal bones, dislocations of the, 338; excision, 381; fractures, 304.
- Metacarpo-phalangeal joints, excision of, 381.
- Metacarpus, amputations at the, 124.
- Metastasis in septic inflammation, 67.
- Metastatic abscess, 66.
- Metatarsal bones, amputation of, 136; dislocations, 350; fractures, 323.
- Metatarso-phalangeal joints, amputation at the, 134; arthritis, 366; dislocations, 350.
- Metatarsus, amputation of the, 135, 137.
- Methods of dressing wounds, 1; of performing amputations, 109, 111.
- Metschnikoff. Phagocytosis, 67.
- Micro-coccus of erysipelas, 84.
- Micro-organisms, causing inflammation, 54; of blue pus, 62; of gonorrhœa, 677; of glanders, 83; of putrid infection, 60; of syphilis, 717; of tetanus, 83.
- Micropsia, 424.
- Middle-ear, 440.
- Middle finger, amputation of, 123.
- Misplaced testicle, 750.
- Mitchell, S. Weir. Snake-venom, 79.
- Mixed flaps in amputations, 118.
- Mixed sores, 728.
- Moccasin-snake, 79.
- Modified circular flaps, 118.
- Moist gangrene, 100.
- Molecular death of tissue, 100.
- Moles, 200; of cheek and lip, 455.
- Mollities ossium, 279.
- Monsel's solution for angioma, 197; for hæmorrhage after extraction of teeth, 478.
- Monteira. Case of aneurism, 229.
- Montgomery. Case of aneurism, 216.
- Moore. Fracture of clavicle, 293; of radius near carpus, 302.
- Morbus coxæ, 354; diagnosis, 357.
- Morgagni. Cataract, 419; hydatid, 775.
- Morgan. Case of aneurism, 227.
- Morphia, after operations, 53; in burns, 93; in cystitis, 633; in ether narcosis, 26; in inflammation 60; in renal calculus, 623.
- Mortification, 100.
- Morton. Spina bifida, 800.
- Motor-paralysis, operation for, 391.
- Mott, A. B. Case of aneurism, 216, 223.
- Mott, Valentine. Cases of aneurism, 218, 223, 224; case of ligation of innominate, 237.
- Mott-Heister, mouth-gag, 27.
- Mouth, contraction of, 466; syphilis, 724.
- Mucocele, 406.
- Mucoid carcinoma, 839.
- Mucous cysts, 851; membrane of tympanum, 440; patches, 720; surfaces, iodoform on, 5.
- Mulberry calculus, 646.
- Müller. Cholesteatomata, 848; malignant angioma, 197; pathology of tumors, 837.
- Mumps, 470.
- Murray. Case of aneurism, 229.
- Muscæ volitantes, 423.
- Muscles, artificial, 817.
- Muscular rheumatism at shoulder-joint, 367; spasm in diagnosis of hip-joint dislocation, 342.
- Musculo-spiral nerve, injury to, in dislocations of the elbow, 335.
- Musket-ball, 91.
- Muslin bandages, 10.
- Mussey. Cirroid arterial tumor, 191; operation for, 192.
- Mütter. Plastic operation on the cheek, 466.
- Mydriatics, 428.
- Myelitis in tetanus, 88, 89.
- Myeloplaxes in fractures, 281; in inflammation of bone, 276; in tissue formation, 56.
- Myocarditis syphilitica, 724.
- Myoma, 852; of the bladder, 640.
- Myopia, 426, 429.
- Myosin-coagulation in gangrene, 101.
- Myxœdema, 495.
- Myxo-lipoma, 852.
- Myxoma, 852; of the antrum of Highmore, 471; of the bladder, 640; of the lower jaw, 474; of the mamma, 516; of the nose, 443; of the parotid gland, 468.
- Nachet. Trial-glasses for testing vision, 431.
- Nævoid elephantiasis, 196.
- Nævus, cavernous, 195; of the cheek and lip, 455; of the head, 383; near the eye, 397; pigmentosus, 201; pilosus, 201; vulgaris, 201.
- Naiia tripudians, 79.
- Nail, ingrowing, 825.
- Narcosis, chloroform, 25; ether, 26.
- Nares, fissure of the, 444; occlusion, 452; plugging, 442.
- Nasal bones, fractures of, 288; pins, 445; septum, lateral deviation of, 445.

- Narrowing of vagina, 760.
 Natural amputations, 107.
 Nebula, 414.
 Neck, abscess of, 492; cysts, 493; gunshot-wounds, 492; wounds of, 491.
 Necro-biosis, in arteries, 177; in ulcers, 99.
 Necrosis, 100; of bone, 275; of calvaria, after nævus, 197; treatment of, 278.
 Necrotic process in carbuncle, 98.
 Needle, 43; aneurism, 37; cervix, 764; hernia, 562; holder, 42, 77; Sims's, holder, 762; hot, for angioma, 197; Peaslee's, 486; surgical, 43; suture, 77; varicocele, 742; wire suture, 43.
 Nélaton, bullet-probe, 43; catheter, 633; cirroid tumor, 193; harelip, 459; test-line for deformities of hip, 801; for fracture of femur, 309; for morbus coxæ, 356.
 Neoplasms, 8; malignant, 837; non-malignant, 848; of the frontal sinus, 445; of the intestine, 536; of the larynx, 505; of the nose, 443; of the pharynx, 507; of the urethra, 706.
 Nephralgia, 620.
 Nephrectomy, 626.
 Nephritis, a cause of arteritis, 173.
 Nephrolithotomy, 626.
 Nephrotomy, 626.
 Nerve, branches of fifth, exsection of, 473; inferior dental, exsection of, 476.
 Nerves, suture of, in wounds of neck, 491.
 Nettleship. Pannus, 412; trachoma, 408.
 Neuber. Bone-drains, 8; in amputations, 114.
 Neumeister. Case of aneurism, 218.
 Neuralgia, facial, surgical treatment of, 473, 476; of the prostate, 676; of the rectum, 608; of the shoulder-joint, diagnosis, 366; of sternomastoideus muscle, 781.
 Neurectomy, 472, 473.
 Neuroma, 853.
 Neuro-sarcoma, 848.
 Nichols. Case of aneurism, 224.
 Nicolaier. Tetanus bacillus, 88.
 Nipple, abscess of the, 513; eczema, 513; epithelioma, 513; fissure, 513; tumors, 513.
 Nitrate of silver in prostaticorrhœa, 673; in vaginitis, 759.
 Nitric acid, for angioma, 197; in hospital gangrene, 105; in phagedenic ulcers, 716.
 Nitrogenous food in gangrene, 101.
 Nitrous-oxide gas, in the after-treatment of fractures, 298; in extraction of teeth, 478.
 Norman. Case of aneurism, 223.
 Nose, affections of the, 442; bifid, 451; calculi, 443; deviation of septum, 445; epithelioma, 445; epistaxis, 442; fissure of, 444; foreign bodies in, 442; hypertrophy of, 446; of the mucous membrane of, 443; plastic operations on the, 446; plugging of the, 442; polypus, 443; syphilis, 724.
 Nussbaum. Case of aneurism, 218.
 Nutrition, before operations on the abdomen, 49; in hospital gangrene, 105; in lymphadenitis, 164; in phlebitis, 171.
 Nyctalopia, 424.
 Nyrop. Boot for talipes valgus, 820; spring brace, 786.
 Oakum, as a dressing for ulcers, 99.
 Oblique flaps in amputations, 115.
 Obstruction of the alimentary canal, 530.
 Obturator hernia, 555; diagnosis and treatment, 574.
 Occipital artery, ligation of, 250.
 Occlusion, intestinal, 538; of the alimentary canal, 530; of the basilar artery, 183; of the nares, 452.
 O'Dwyer. Laryngeal tube, 499.
 Œdema of the glottis, after tonsillar abscess, 489; of scrotum, 734.
 Œsophagectomy, 511.
 Œsophagotome, 509.
 Œsophagotomy, 508.
 Œsophagus, 507; carcinoma of, 511; diverticula, 512; epithelioma, 511; fistula, 512; foreign bodies in, 507; sounds, 507; stricture, 509; syphilis, 725; tumors, 511; wounds, 491.
 Ogston. Operation for genu valgum, 807.
 Oil of juniper, for catgut, 2.
 Oiled silk, 9.
 Olecranon, fractures of, 299.
 Opacities of the cornea, 436; of the lens, 436.
 Open method of treating amputations, 119.
 Operating cabinet, 47; gown, 49; room, 44; stool, 45; tables, 44.
 Operation for artificial anus, 576; for cleft palate, 478; for non-union of fractures, 324; for strangulated hernia, 566; place of, 44.
 Operations, plastic, of face, 397, 405, 446, *et seq.*; for burns, 95; near the eye, 397, 405; of the cheek, 465; of the lip, 456; of the mouth, 466; of the nose, 446; surgical, 35; method of conducting, 50, 108, *et seq.*
 Ophthalmia, gonorrhœal, 408; neonatorum, 409.
 Ophthalmitis, sympathetic, 516.
 Ophthalmoscope, Loring's, 435; mode of using, 435.
 Ophthalmoscopy, 435.
 Opium, after lithotrity, 654; in gangrene, 104, 105; in hæmaturia, 645; in intestinal obstruction, 533; in rabies, 82; in retention of urine, 636; in suppression of urine, 625.
 Opisthotonos, in tetanus, 89.
 Optic nerve, atrophy of, 437.
 Optic neuritis, 424, 436.
 Orchitis, 745; gonorrhœal, 684; in mumps, 470; syphilitic, 725; tuberculous, 747.
 Ordile. Case of aneurism, 216.
 O'Reilly. Case of aneurism, 224.
 Orfila. Vascular tumor, 194.
 O'Shaughnessy. Case of aneurism, 216.

- Os innominatum, fracture of, 306; hyoides, fracture of, 292.
- Osteo-arthritis of the elbow, 367; of the hip, 353; of the knee, 363; of the shoulder, 367; of the wrist, 367.
- Osteo-clasis of femur, 804, 809.
- Osteo-lipoma, 842.
- Osteoma, 856; of skull, 385.
- Osteomalacia, 279.
- Osteomyelitis, 276; in femur, 152.
- Osteo-plastic operation, for tumor of antrum of Highmore, 472.
- Osteosarcoma, 197.
- Osteotome, 38.
- Osteotomy of femur, 802, 804, 809; of fore-arm, 827.
- Ostitis, 275; at the hip, 354; caseosa, 276; cause of non-union after fractures, 323; fungosa, 276; of the clavicle, 522; of the frontal sinus, 444; of the lower jaw, 474; of the ribs, 515; of the skull, 383; of the spine, 787; of the sternum, 521; of the thorax, 521; of the upper jaw, 471; osteoplastica, 276; rarefaciens, 276; sclerosa, 276; syphilitic, 720, 723; tuberculous, 276, 353.
- Otis, F. N. Cocaine-tube, 690; location of stricture, 689; urethrotome, 693; wire bougie, 689.
- Otis, G. A. Statistics of shot-wounds of the face, 396.
- Otitis media, 440.
- Oval flaps in amputations, 117.
- Ovarian cysts, 622; multilocular, 774.
- Ovariectomy, 776.
- Ovary, abscess of, 773; carcinoma, 775; cirrhosis, 772; cyst-adenoma, 774; cystic degeneration of, 771; cystic tumors, 774; dermoid cysts, 774; fibro-myoma, 776; hernia of, 758; sarcoma, 775; solid tumors, 775.
- Oxalic acid for sponges, 7.
- Ozæna, 444; syphilitic, 444.
- Packing, as a hæmostatic, in wounds, 73; temporary, in wounds, 74.
- Paget. Case of aneurism, 227; connective tissue in wounds, 70; phlebitis, 168, 169.
- Pain, after operation, treated by morphine, 53; in aneurism, 204; in gangrene, 100; in inflammation, 54, 55.
- Palate, affections of the, 478; cleft of, 478; operation for, under cocaine, 23; instruments for, 35; hard, cleft of, 481; perforations of, 482; tumors of, 478.
- Pallor in gangrene, 100.
- Pancoast. Case of aneurism, 226.
- Pancreas, 586; cyst of, 587.
- Pannus, 412.
- Papilloma, 848; of antrum of Highmore, 471; of the bladder, 639; of the head, 383; of the kidney, 624; of the larynx, 505; of the lip, 455; of the nipple, 514; of the nose, 443; of the tongue, 483; of the urethra, 706; of the vulva, 757.
- Papular syphilide, 720.
- Paquelin. Caution, in hæmorrhoids, 616; in operations on the tongue, 483, 485; in prolapse of the rectum, 609; in ranula, 488.
- Paraglobin, relation of, to stasis, 55.
- Paralysis of muscles, causing contractures, 830; of respiratory muscles by cocaine, 22; of the bladder, 634; of the deltoid muscle, 826; of the serratus magnus muscle, 826; syphilitic, 723.
- Paraphimosis, 683.
- Parker. Case of aneurism, 224, 228; case of ligation of subclavia and carotid, 257.
- Paronychia, syphilitic, 722.
- Parotid gland, 466; abscess of, 470; duct of, 466; extirpation of; 468, 469; tumors of, 468.
- Parotitis, 470.
- Partridge. Case of aneurism, 224.
- Passive motion, after exsection of hip-joint, 361.
- Pasteur. Rabies, 81.
- Patches, mucous, 720.
- Patella, dislocations of, 348; fractures, 314.
- Pathogenic micro-organisms, 60.
- Pathology of syphilis, 726.
- Pearly epithelioma, 848.
- Peaslee. Needle, 486, 742.
- Peat, as an absorbent dressing, 9.
- Pedis dorsalis artery, ligation of, 274.
- Pelletan. Case of aneurism, 226.
- Penis, 706; amputation of, 709; carcinoma, 707; herpes, 713; inflammation of, 706; malformations, 706; sarcoma, 710; ulcers, 713; wounds, 707.
- Peptonized foods in hospital gangrene, 105.
- Perforation of the antrum of Highmore, 471; of the palate, 482.
- Periadenitis of neck, 492.
- Periarteritis, 171.
- Perichondroma, 856.
- Perineal cystotomy, 658; for wounds of bladder, 930; lithotomy, 658; section, for stricture of urethra, 697.
- Perineorrhaphy, 755.
- Perinephritis, 620.
- Perinæum, laceration of, 752; operations for, 753; rupture of, 752.
- Periorchitis serosa, 735; diagnosis, 746.
- Periphlebitis, 165.
- Periosteal elevator, 38.
- Periostitis, 275, 277; of upper jaw, 471; syphilitic, 723.
- Peri-rectal abscess, 596.
- Perispermatitis, 735.
- Perisplenic abscess, 586.
- Peritoneal abscess, 579.
- Peritonitis, 578; after burns, 93; laparotomy for, 578.

- Perityphlitic abscess, 580.
 Permanent dressings, 53.
 Permanganate of potassa, for serpent-wounds, 80.
 Peroneal aneurism, 231; artery, ligation of, 272; muscles, tenotomy of, 821.
 Petit. Arterial cirroid tumor, 192; fracture-box, 320; tourniquet, 73.
 Phagedenic bubo, 715; gangrene, 104; ulcer of penis, 714; ulcer of rectum, 600.
 Phagocytes, 67.
 Phalangeal joints, dislocation of, 338.
 Phalanges, dislocations of, 338; fracture of, 305.
 Pharyngeal artery, ascending, ligation of, 250.
 Pharynx, 507; abscess of, 492, 507, 790; affections of, 507; carcinoma, 507; foreign bodies in, 507; retropharyngeal abscess, 492, 507, 790; syphilis, 725; tumors of, 507.
 Phenomena of inflammation, 54.
 Phimosis, 710; operation for, 711.
 Phlebitis, 86, 165; acute, 163.
 Phlebolites, 195, 200.
 Phlegmon of fingers, 834; of hand, 834; of lip, 455; of the neck, 493; of the scrotum, 734.
 Phlegmonous erysipelas, 86.
 Phlyctenulæ, 413.
 Phorometer, 433.
 Phosphatic calculus, 646.
 Phosphorus disease of jaws, 471, 474.
 Pigeon-toe, 824.
 Pigment, in the skin, 201.
 Pilcher. Fracture of radius, 303.
 Piles, 611; capillary, 618; chronic, 612; external, 611; internal, 611, 613; ligation of, 614; treatment by the actual cautery, 616; Whitehead's operation for, 615.
 Pilocarpine, in suppression of urine, 625.
 Pin, hare-lip, 458; suture, 76.
 Pinguecula, 410.
 Pirogoff. Amputation at the ankle, 143; cases of aneurism, 218, 219, 223; etherization per rectum, 32; ligation of carotid for vascular tumor, 192.
 Pitha. Injections for vascular tumors, 193.
 Pitres. Cerebral localization of symptoms of motor paralysis, 389.
 Pityriasis versicolor, of anus, 594.
 Planus talipes, 821.
 Plaques, mucous, 720.
 Plasmin, 167.
 Plaster-of-Paris bandage, 10; in fracture of the femur, 311; of the humerus, 296; of the leg, 321, 322; of the patella, 317; in synovitis, 359, 365; in ununited fractures, 324.
 Plastic operations, for burns, 95.
 Plastic surgery, 95; near the eye, 397, 405; of the cheek, 465; of the lip, 456; of the mouth, 466; of the nose, 446.
 Playfair. Operation for peritonitis, 578.
 Pleuritis following burns, 93; following wounds of the chest, 524.
 Pleurosthotonos in tetanus, 89.
 Plexiform angioma, 195.
 Plug, vaginal, 759.
 Plugging of the nares, 442.
 Pneumatocele, 383.
 Pneumonia, syphilitic, 724.
 Pneumonitis, following burns, 93.
 Pneumothorax, 523.
 Poisoned wounds, 68, 78, 84.
 Polaillon. Cirroid aneurism, 191.
 Poland. Case of aneurism, 227.
 Politzer. Tympanum perforator, 440.
 Polydactylus, 822, 829.
 Polypus, cystic, 607; fibrous, of nose, 443; fibrous, of rectum, 607; gelatinous, 443; of the larynx, 506; of the nose, 443; of the rectum, 607; villous, of rectum, 607.
 Pope. Tarantula-bite, 80.
 Popliteal artery, aneurism of, 231; ligation of, 272.
 Porro's operation, 768.
 Porta. Case of aneurism, 218.
 Porter. Case of aneurism, 226.
 Port-wine mark, 201; of head, 383.
 Position of assistants during amputation, 110; of limb in gangrene, 101.
 Posterior auricular artery, ligation of, 252; tibial artery, ligation of, 272.
 Posterior curvature of the spine, 787.
 Posthitis, 678, 682.
 Posture, in the treatment of aneurism, 210.
 Potass, bromide of, for chordee, 680; citrate of, for renal calculus, 623; permanganate of, for bleaching sponges, 7; iodide, *vide* iodide.
 Pott's disease of the spine, 787; diagnosis, 790; fracture, 318.
 Poultices in carbuncle, 99; in furuncle, 97; in inflammation, 60.
 Powers. Treatment of dislocation of the humerus, 328.
 Preparation of antiseptic material, 1; of attendants, etc., for operation, 49; of patients, for narcosis, 26; moral, 48; physical, 49.
 Prepuce, adhesions of, 712; amputation, 711; dilatation, 713; divulsion, 713; incision, 713; phimosis, 710.
 Presbyopia, 432.
 Pressure symptoms, in aneurism, 211 *et seq.*
 Primary amputation, 107.
 Probang for œsophagus, 508.
 Probe, bullet, 43; Nélaton's, 43.
 Productive otitis, 276.
 Profunda femoris artery, aneurism or, 231; ligation of, 271.
 Projectiles, 91; varieties of, 91.
 Prolapse of the rectum, 608; of the uterus, 760.
 Proliferation of cells in endarteritis, 175; in inflammation, 55.
 Prostatic syringe, 673.
 Prostatitis, 665.

- Prostate body, 665; calculi of the, 675; carcinoma, 674; concretions, 675; dilatation, 668; excision of hypertrophy of, 671; exploration, 669; hypertrophy, 666; neuralgia of, 676; sarcoma, 675; tuberculosis, 674.
- Prostatorrhoea, 672.
- Prostration in hospital gangrene, 105.
- Protection of field of operation, 50; of patients during operation, 50.
- Protective, 9; for burns, 93; in amputation dressings, 115; on wounds, 74.
- Protiodide in lymphadenitis, 164; in syphilis, 731.
- Pruritus of the anus, 593; of the vulva, 758.
- Psoas abscess, 783, 790.
- Psoriasis, syphilitic, 721.
- Pterygium, 410.
- Ptomaines, action of iodoform on, 5; cause of septicæmia, 66; in tetanus, 88.
- Pubes, fracture of, 307.
- Pubic dislocation of the hip-joint, 339, 342, 345.
- Pudic, internal, artery, ligation of, 267.
- Pulsation in aneurism, 204.
- Pulse in tetanus, 89.
- Puncture of the bladder, 637; multiple, of the testicle for epididymitis, 684, 745, 746; for orchitis, 684.
- Punctured wounds, 68.
- Pure water for continuous irrigation in amputation, 120.
- Pus, 61; basin, 48; blue, 62; corpuseles, 61; in the urine, 643; liquor puris, 61.
- Pustular syphilide, 721.
- Pustule, malignant, 83.
- Putrefaction, in gangrene, 101.
- Putrid surfaces, iodoform on, 5.
- Pyæmia, 60, 66; after ligation of arteries, 175; metastatic abscess of, 67.
- Pyelitis, 620.
- Pylorectomy, 526.
- Pylorus, exsection of, 526; stricture of, 525.
- Pyogenic membrane, 526.
- Pyrogallic acid in lupus, 454.
- Quilled suture, 75.
- Quinia, in dissection wounds, 84; in erysipelas, 87; in inflammation, 60; in phlebitis, 171; in tonsillitis, 489.
- Rabid animals, wounds by, 81.
- Rabies, 81, 89.
- Racemose adenoma, 849.
- Rachitis, 279, 804, 809; treatment of, by osteotomy, 827.
- Radial artery, aneurism of, 227; ligation of, 262.
- Radical cure of hernia, 559.
- Radio-carpal dislocation, 126.
- Radius, fractures of, 300; subluxation of head of, 324.
- Radius and ulna, dislocations of, at elbow, 335.
- Railway fracture, 318.
- Ransohoff. Case of aneurism, 219.
- Ranvier, *vide* Cornil. Formation of capillaries in wounds, 69.
- Ranula, 488.
- Rattlesnake-bite, 79.
- Rectal puncture of the bladder, 638.
- Rectal urinary fistula, 703.
- Rectocele, 760.
- Rectum, abscess of, 596; administration of ether by the, 26, 32; ascariides in, 595; atresia of, 591; carcinoma, 605; chancre, 601; chancroid, 600; dilatation, 605; epithelioma, 536, 605; encephaloid, 605; exsection, 606; fistula, 595, 703; foreign bodies in, 595; lupoid ulcer, 600; neoplasms of, 605; neuralgia, 608; phagedenic ulcer of, 600; polypus, 608; prolapse, 608; treatment, 609; scirrhous, 605; speculum, 595; stricture, 601, 602; syphilis, 600, 725; ulcerations, 600.
- Rectotomy, 604.
- Redness in inflammation, 54.
- Reef-knot, 52.
- Reeves. Operation for genu valgum, 807; shoe for talipes, 818; snap-finger, 832; suspensory cradle, 799; talipes valgus, 820.
- Refraction of eye, 426.
- Regional surgery, 382.
- Reichert. Coagulation of blood, 168; serpent-venom, 79.
- Removal, *vide* excision, extirpation.
- Renal calculus, 620, 622, 626, 646; colic, 623; cysts, 623.
- Repair of tissues in inflammation, 54, 56; in venous inflammation, 167; in wounds, 70.
- Resection, *vide* excision.
- Resolution of fissure, 56.
- Respiration, artificial, in ether narcosis, 30; Sylvester's method of, 31.
- Rest in aneurism, 205; in inflammation, 56; in periostitis, 277; in phlebitis, 170; in synovitis, 365.
- Restoration of eyelids, 405.
- Resuscitation after ether and chloroform narcosis, 31.
- Retention of urine, 635; from nerve lesions, 635; from paralysis, 635; from spasm, 635; from stricture of the urethra, 635.
- Retina, 423.
- Retinitis, 423, 437; pigmentosa, 424.
- Retractors, 36; in amputations, 112.
- Retroperitoneal abscess, 581.
- Retropharyngeal abscess, 492, 507, 790.
- Retrosternal abscess, 521.
- Reverse in spiral bandage, 11.
- Reynders. Apparatus for torticollis, 781; suspension apparatus, 792.
- Rhabdomyoma of the kidney, 624.

- Rheumatic arteritis, 187; myositis at hip; diagnosis, 357.
- Rheumatism a cause of arteritis, 173; gonorrhœal, 685.
- Rhigolene as a local anæsthetic, 24.
- Rhinolites, 443.
- Rhinoplasty, 446; Hindoo method, 448; method of Dieffenbach, 448; of Fabrizzi, 450; of Koenig, 448; of Labat, 448; of Langenbeck, 449; of Linhart, 448; of Wutzer, 450; partial, 451.
- Riberi. Operation on Steno's duct, 467.
- Ribs, dislocation of, 350; excision, 522; fractures, 305, 523; osteitis, 521.
- Richardson. Atomizer, 24.
- Rickets, 279.
- Riegner. Case of ligation of common carotid, 242.
- Rifle-projectiles, 91.
- Rigen. Case of aneurism, 216.
- Rigors in inflammation, 56.
- Rindfleisch. Cavernous tumors, 196.
- Ring-finger, amputation of, 123.
- Robert. Ligation of carotid for vascular tumor, 192.
- Roberts. Operation on septum of nose, 445.
- Robertson. Ectropion, 400.
- Robin. Cirroid arterial tumor, 190.
- Robinson. Carbuncle, 98; lupus erythematosus, 454.
- Rodent ulcer of rectum, 600.
- Rodgers. Case of aneurism, 224; case of ligation of subclavian, 257.
- Rodgers and Van Buren. Ligation of carotid for vascular tumor, 192.
- Rokitansky. Cavernous tumors, 196; diverticula of œsophagus, 512; multilocular cyst of ovary, 774.
- Rongeur, 39.
- Rossi. Case of aneurism, 217.
- Rotary lateral curvature of the spine, 782.
- Round-celled epithelioma, 842; sarcoma, 844, 846.
- Rubber, action of sublimate on, 5; drains, 8; operating gown, 50; tissue, 9; tubing for application of cold in inflammation, 60; vulcanized handles for instruments, 35.
- Rupia, syphilitic, 722.
- Rupture of abdominal muscles, 586; of abdominal organs, 587; of the bladder, 630; of the œsophagus, 507; of the perinæum, 752; operation for, 753; primary, 755; secondary, 756; of the posterior commissure of the vulva, 572; of the spleen, 585.
- Sacculated aneurism, 203.
- Sacrum, fracture of, 306.
- Saenger. Hysterectomy, 766.
- Saline solutions for intravenous injection, 78.
- Salivary calculus, 466; fistula, 466.
- Salpingitis, 770.
- Sandal-wood, oil of, for gonorrhœa, 682.
- Sands. Case of aneurism, 214; ligation of carotid, 247; œsophagotome, 509; treatment of external iliac aneurism, 230.
- Santonin for Billharzia hæmatobia, 645.
- Sarcoma, 843; diagnosis, 840; of antrum of Highmore, 471; of bladder, 640; of dura mater, 385; of intestine, 536; of kidney, 624; of larynx, 506; of lower jaw, 474; of mammary gland, 517; of œsophagus, 511; of ovary, 775; of parotid gland, 468; of penis, 710; of prostate, 675; of testicle, 749; of thyroid gland, 494, 497.
- Sattler. Case of intraorbital aneurism, 222.
- Savage. Operation for peritonitis, 578.
- Sawdust as an absorbent dressing, 9.
- Saws, 37, 39; use of, in amputations, 113.
- Sayre. Apparatus for knock-knee, 807; artificial muscles for torticollis, 780; bandage for fracture of clavicle, 327; clavicle, fracture of, 292; bandage for, 327; double hip-splint, 801; exsection of hip, 368; halux valgus, 823; jacket, plaster-of-Paris, 792; jury mast, 791, 795; osteotomy of femur, 802; periosteal elevator, 381; polydactylus, 822; splint for morbus coxæ, 359; talipes calcaneus, 814; talipes equinus, 811; talipes varus, 817.
- Scalds, 93.
- Scale for urethral instruments, 698.
- Scaling syphilide, 721.
- Scalp, abscess of, 383; cysts, 382; tumors, 382; cystic, 383; fatty, 383.
- Scalpels, 35; method of holding, 50.
- Scalloped gouge, 38.
- Scapula, 523; amputation of, 134; excision, 134, 523; fractures, 294.
- Scapular artery, posterior, ligation of, 256.
- Scarification, 57; in inflammation, 57.
- Scarpa. Ligation of arteries, 189; shoe for talipes varus, 818.
- Schmidt. Coagulation of blood, 168, 203.
- Schroeder. Hysterectomy for fibro-myomata, 769.
- Schuh. Injection for vascular tumors, 193.
- Schütz. Glanders, 83.
- Sciatic artery, aneurism of, 230; ligation of, 267.
- Scirrhus, 839; of the bladder, 640; of the mammary gland, 518; of the rectum, 605.
- Scissor-clamp forceps, 41.
- Scissors, 42; dressing, 42.
- Scleritis, 415.
- Sclerotica, 415.
- Scoliosis, 779.
- Scoop, urethral, 701.
- Scoparius, in suppression of urine, 625.
- Scorpion-venom, 80.
- Scott. Case of aneurism, 218.
- Scraping-out for hospital gangrene, 105.

- Scrofulous dyscrasia, 163.
 Scrotal clamp, 743.
 Scrotum, 733; angioma of, 734; contusion, 734; cysts, 734; eczema, 734; elephantiasis, 734; epithelioma, 735; erysipelas, 734; fistula, 735; gangrene, 734; hæmatoma, 735; œdema, 734; phlegmon, 734; wounds, 733.
 Sebaceous cysts, 850; near the eye, 398.
 Secondary amputations, 107.
 Section, Cæsarean, 766; perineal, 697; trochanteric of femur, 802.
 Sedillot. Cheiloplasty, 465; method of amputating leg, 148.
 Selden. Case of fracture of neck of femur, 307.
 Senile gangrene, 103.
 Senn. Hydrogen gas for diagnosis of intestinal lesion, 588; intestinal anastomoses, 529, 546.
 Separation of epiphysis of humerus, 297.
 Sepsis rendering delay in operating dangerous, 49.
 Septic fever, 54.
 Septicæmia, 60, 66; treatment of, 67.
 Septicæmic symptoms in hospital gangrene, 105.
 Septum of nose, lateral deviation of, 445.
 Sequestrum, 275; forceps, 39.
 Serous cysts, 851.
 Serpent-bites, 78; venom, toxicity of, 78.
 Sexton. Ear-hook, 439; forceps, 439; probe, 438; snare, 439.
 Schaffer. Spinal brace, 306, 791; figure, 795.
 Shells, 90.
 Sheppard. Statistics of amputation at hip, 159.
 Shock, 92, 587; after gunshot-wounds, 92; symptoms and treatment of, 92.
 Shoulder-cap, in fracture of the humerus, 297.
 Shoulder-joint, amputation at, 133; ankylosis, 826; disarticulation, 133; dislocation, 327; exsection, 376; synovitis, 366.
 Sichels. Iris-knife, 411.
 Silk, 1; for sutures, 2.
 Silk-worm gut, 1; for cleft-palate operations, 480.
 Silver fork deformity of wrist, 302.
 Silver wire suture, 1, 75; in fracture of jaw, 291.
 Simes. Phlebitis, 169; syphilitic arteritis, 183.
 Sims, H. Marion-, *vide* Marion.
 Sims's fork for silver sutures, 762; glass tube for drainage of abdominal cavity, 589, 769; glass vaginal plug, 759; knife-holder, 765; needle-forceps, 762; rectal speculum, 595; scissors, 42; skewer-shields, 770; speculum, 762; sutures in vesico-vaginal fistula, 713.
 Simple ulcer of penis, 713.
 Sinapisms, in inflammation, 60; in pyelitis, 621.
 Sinus, frontal, abscess of, 384; of scrotum, 735.
 Skin-flap, 116, 129, 146.
 Skin-grafting, 94; in burns, 94.
 Skull, carcinoma of, 384; depression of, 285; encephalocele, 385; exostosis, 385; fractures, 286; gunshot-wounds, 387; meningocele, 385; net-bandage for, 21; osteoma, 385; otitis, 383; paracentesis, 394; penetrating wounds, 387; periostitis, 383; pneumatocele, 383; sarcoma, 385; wounds, 386.
 Sliding of skin for burns, 95; of palate, for fissure, 481.
 Smith. Hæmorrhoidal clamp, 616.
 Smith, Stephen. Amputation at knee, 150; of leg, 146; of Syme, 141.
 Smyth. Cases of aneurism, 223, 228.
 Snake-bites, 78; treatment of, 80.
 Snare, Sexton's, 439.
 Snap-finger, 832.
 Snellen. Entropion, 404; test types, 431.
 Soap, green, in lupus, 454.
 Solid flaps, 109.
 Solution, antiseptic, 3; boric-acid, 3; carbolic-acid, 3; of iodoform and ether, 5; oxalic-acid, 7; salicylic-acid, 3, 5; salicylico-boric, 5.
 Sore nipples, 513.
 Sound, cupped, 673; œsophageal, 507; steel urethral, 698.
 South. Case of aneurism, 229.
 Southam. Rabies, 82.
 Spasm of the sphincter ani, 603.
 Special amputations, 120.
 Speculum, rectal, 595; urethral, 706.
 Spence. Erectile tumor, 193, 194.
 Spermatorrhœa, 672, 674.
 Spheno-maxillary fossa, wounds of, 396.
 Spherical aneurism, 202.
 Sphincter ani, divulsion of, 599.
 Spica bandage, 15.
 Spina bifida, 799.
 Spinal column, deformities of, 779.
 Spinal cord, syphilis of, 723.
 Spindle-celled sarcoma, 844, 846.
 Spine, abscess of, 789; anterior curvature, 786; bifid, 799; dislocations, 350; lateral curvature, 779, 782; posterior curvature, 787; rotary lateral curvature, 782.
 Spiral bandage, 11.
 Spleen, 585; abscess of, 585; cyst, 586; excision, 586; hernia, 586; rupture, 585; syphilis, 725; wandering, 586.
 Splenectomy, 586.
 Splenic abscess, 585.
 Spondylitis, 787.
 Sponge-holders, 42.
 Sponges, compression with, during operation, 52; disinfecting of, 3, 6; manipulation of, 110.
 Spoons, sharp, 38.
 Spray, carbolic-acid, 4; before operations, 44; ether, 24; machine, 4.
 Squibb. Ether, 26.
 Stalactites, 857; in fractures, 283.

- Stalagmites, 856.
 Staphylococcus pyogenes, 60.
 Staphyloma of the cornea, 413.
 Staphylorrhaphy, 479.
 Starr. Symptoms in brain lesions, 389.
 Stasis, in the blood-current, in inflammation, 55.
 Statistics of amputations, 107; at hip, 159; of operations for aneurisms, 221, 224.
 Staton. Case of gastrotomy, 511.
 Steel sounds, 698.
 Stellate fracture of patella, 314.
 Steno's duct, 466.
 Sternberg. Poison of human saliva, 81.
 Sternomastoid muscle, neurectomy, 781; tenotomy of, 781.
 Sternum, exsection of, 521; fractures of, 305.
 Stevens's phorometer, 433.
 Stewart. Exsection of intestine, 569.
 Stimson. Case of aneurism, 217; fracture of femur, at neck, 307; through trochanters, 312.
 Stimulation, after gunshot-wounds, 92; guarded, after operations, 53; in gangrene, 102; in hospital gangrene, 105.
 Sting of insects, 81.
 Stokes. Case of aneurism, 229.
 Stomach, affections of, 525; exsection of, 526; foreign bodies in, 527; syphilis of, 725.
 Stone in the bladder, 645; in females, 664; lithotomy, for, 654; lithotripsy for, 650.
 Stool, operating, 45.
 Strabismus, 425.
 Strangulated hernia, 565; operation for, 566.
 Strangulation of the intestine, 535.
 Streptococcus pyogenes, 60.
 Stretching nerves in tetanus, 90.
 Stricture of the intestine, 536; of the œsophagus, 509; of the pylorus, 525; of the rectum, 601, 602; of the urethra, 677, 687; treatment of, 692; at the meatus, 691.
 Strychnia in tetanus, 89.
 Sty, 399.
 Styles, melanotic nævus, 197.
 Styptic cotton, 73.
 Subacetate of lead in synovitis, 352; in ulcers of the penis, 716.
 Subclavian artery, aneurism of, 222; ligation of, 253, 256, 258; for aortic aneurism, 213, 233; for dislocation of humerus, 333; synopsis of cases of, 224.
 Sublimate, action of, on rubber, 5; a preventive of hospital gangrene, 105; for irrigating abscesses, 66; gunshot-wounds, 92; wounds, 74; for poultices, 60; gauze, 9; for ulcers, 99; in amputations, 109, 114; in gangrene, 102; in ostitis, 278; solutions, 3, 4, 48.
 Sublingual gland, swelling of, in epithelioma of lip, 453.
 Subluxation of the head of the radius, 324.
 Submaxillary glands, 470; extirpation of, 470; swelling of, in epithelioma of lip, 453.
 Subperiosteal operation on lower jaw, 474.
 Subtrochanteric section of femur, 802.
 Suction for cataract, 423; in dissection wounds, 84; in snake-bites, 80.
 Sugar in the urine, 642.
 Superior maxilla, *vide* jaw.
 Superior thyroid artery, ligation of, 248.
 Supernumerary finger, 829; testicle, 750.
 Suppression of urine, 619, 624; diagnosis, 635.
 Suppuration, 60; in inflammation, 56; of hip-joint, 360; of knee, 363.
 Suprapubic cystotomy, 654, 657, 664; for vesicovaginal fistula, 761; in females, 664; puncture of the bladder, 637, 670.
 Supra-scapular artery, ligation of, 256.
 Surgical dressings, 1; method of applying, 53; operations, 35.
 Suspension apparatus, 792.
 Suspensory, 683.
 Sutton. Intermediate suture in exsection of the intestine, 542.
 Sutures, 1; antiseptic, 2, 3; continuous, 75; cross-, 76; Czerny's 528, 542; double-needle, 76; during operation, 48; in abdominal section, 545; in amputations, 114; interrupted, 75; intestinal, 528; in wounded intestine, 543; in wounds, 74; in wounds of the neck, 491; Lembert's, 528, 542, 598; mattress, 75; needles for, 77; of nerves, 491; pins for, 76; quilled, 75; silver wire, 3, 75.
 Swanzy. Cataract, 419; conjunctivitis, 408; ectropion, 401; eczema of lids, 405; herpes corneæ, 412.
 Swelling, in gangrene, 101; in inflammation, 54.
 Sylvester. Method of artificial respiration, 31, 491; for foreign body, 503.
 Symblypharon, 400.
 Syme. Amputation at the ankle, 139.
 Symptoms of inflammation, 56.
 Synchronism, 423.
 Syncope from hæmorrhage, 77; in ether narcosis, 32.
 Syndactylus, 822, 829.
 Syndesmitis, 351.
 Synecchia, 415; anterior, 414.
 Synovitis, 351; in dislocations, 325; of the ankle, 364; of the elbow, 367; of the hip, 356; of the knee, 362; of the shoulder, 366; of the wrist, 368; symptoms of, 352; syphilitic, 724.
 Syphilides, 720.
 Syphilis, 717; a cause of arteritis, 173; diagnosis of, 728; inherited, 732; symptoms of, 733; occlusion of basilar artery in, 182; of jaw, 471; of mammary gland, 515; of nose, 446; of rectum, 600; of tongue, 483; of vulva, 757; pathology of, 726; primary, 718, 728; prognosis of, 729; secondary, 720; tertiary, 722; transmissibility of, 732; treatment of, 730.

- Syphilitic adenitis, 719; arteritis, 171, 181; chancre, 717; phlebitis, 168, 169; ulcers of the penis, 717, 719.
- Syringe, *débris*, 661; for urethra, 614; prostatic, 611.
- Szaman. Transfusion, 78.
- Szymanowski. Urethra fistula, 702.
- Table, operating, 44.
- Tenia echinococcus, *vide* hydatid.
- Tait. Hysterectomy, 766, 769; operation for peritonitis, 578.
- Talipes calcaneus, 813; cavus, 821; equinus, 811; planus, 821; valgus, 819; varus, 814.
- Tamponade of nares, 287.
- Tannic acid in prostatitis, 673.
- Tapping of ventricles of the brain, 394.
- Tarantula-venom, 81.
- Tarsal bones, amputation of, 138; dislocation of, 350; excision, 138; fracture, 323.
- Tarso-metatarsal joints, amputation at, 135, 136; arthritis, 366.
- Tarsoraphy, 400.
- Tarso-tibial amputation, 141.
- Tarsotomy, 818.
- Tarsus, amputation through the, 138.
- Taylor. Spinal brace, 306, 791.
- Taxis, on strangulated hernia, 566.
- Teale. Method of amputation, 148; operation for symblepharon, 400.
- Teeth, 477; extraction of, 477.
- Telangiectasis, 195; of larynx, 506.
- Temperature, bodily, in tetanus, 89.
- Temporal artery, ligation of, 253.
- Temporary packing in wounds, 74.
- Tenaculum, 37.
- Tendo Achilles, division of, 811, 818.
- Tendons, inflammation of, 351, 365, 368.
- Tenesmus of the bladder, 638.
- Tenotomy in club-hand, 828; in talipes equinovarus, 818; in torticollis, 781; of eye-muscles, 425; graduated, 435; of peronei muscles, 821; of tendo Achilles, 811, 818.
- Testicle, 745; abscess of, 746; adenoma, 748; carcinoma, 749; cysts, 748; enchondroma, 748; excision, 749; hernia of tubules of, 745; hydrocele, encysted, of, 738; incarcerated, 557; inflammation, 745; malposition, 750; removal, 749; retained, 750; sarcoma, 749; syphilis, 725; tuberculosis, 747; wounds, 745.
- Testing vision for glasses, 431.
- Tetanus, 88.
- Textor. Disarticulation at calcaneo-astragaloid joint, 139.
- Thecitis, 351, 368; diagnosis, 365.
- Thermo-cautery, *vide* Paquelin.
- Thiersch's method of grafting, 95; salicylicoboric solution, 5; in vaginitis, 758.
- Thigh, bandage for, 16; amputation of, 152.
- Thompson. Continuous dilatation of stricture of urethra, 695; evacuator, 653; hæmaturia, 644; lithotrite, 651; method of locating hæmorrhage in urinary tract, 645; searcher, 648.
- Thomson. Case of aneurism, 223; color-blindness, 424.
- Thorax, 523; abscess of wall of, 521; bandage, 17; foreign bodies, 524; gunshot-wounds, 523; wounds, 523.
- Thrombosis, arterial, 188, 189; causes of, 190; in inflammation, 61, 67.
- Thrombus, in arteries, 190; in veins, 167.
- Thumb, amputation of, 121; disarticulation, 121, 122; at metacarpal joint, 125.
- Thyroid artery, ligation of, 259; axis, ligation of, 255; body, 493; cysts of, 494.
- Thyroidectomy, 496.
- Thyrotomy, 498, 506.
- Tibia, dislocation of, at ankle, 348; at knee, 347; fractures, 318.
- Tibial artery, aneurism of, 231; anterior, ligation of, 273; posterior, ligation of, 272.
- Tibialis muscles, tenotomy of, 818.
- Tibio-tarsal amputation, 142.
- Tiemann. Aspirator, 637; Shaffer's brace, 797; tonsillotome, 490.
- Tillanus. Case of aneurism, 216.
- Tillaux. Cirroid aneurism, 190.
- Toad-venom, 80.
- Toes, amputation, 134; bandage for, 15; deformities, 824; syphilis, 726.
- Toldt. Structure of arteries, 172.
- Tongue, 482; abscess of, 482; adhesion, 489; atrophy, 483; bifid, 489; controlling hæmorrhage from, during operations on, 486; cysts, 483; excision, 485; hypertrophy, 483; wounds, 482.
- Tongue-tie, 489.
- Tonsillitis, 489.
- Tonsillotome, 490.
- Tonsils, 489; abscess of the, 489; carcinoma, 490; excision, 490; hypertrophy, 490; inflammation, 489; sarcoma, 490.
- Torticollis, 779; tenotomy in, 781.
- Tortion of arteries, 73.
- Tourniquet, elastic, 41; emergency, 72; for prolonging cocaine anæsthesia, 23; method of hæmostasis with, 51; Petit's, 73.
- Toxicity of serpent-venom, 78, 79.
- Toxicophis, 79.
- Trachea, foreign bodies in, 501; neoplasms of the, 505.
- Tracheotomy, 499; for foreign body, 502; for glossitis, 482; high operation of, 500; in ether narcosis, 31; in excision of the tongue, 488; low operation, 501.
- Trachoma, 408.
- Transfixion, for angioma, 197; in forming flaps, 109, 116; in hip-joint amputation, 155.

- Transfusion of blood, 77; apparatus for, 78; for syncope, 77; in ether narcosis, 27.
- Transplantation of skin, *en masse*, 96; for burns, 94.
- Transverse cervical artery, ligation of, 255.
- Traumatic fever, 60; phlebitis, 170.
- Trays for instruments, 46, 48.
- Treatment of inflammation, 56; wounds, 70.
- Tremor in aneurism, 204.
- Trendelenburg. Compression of iliac artery, 154; tracheal canula, 505; T-shaped drainage-tube, 656.
- Trephining, in depressed fracture of skull, 285; in injuries of the head, 286; in otitis, 278; instruments for, 286; of antrum maxillare, 289; of frontal sinus, 445; of mastoid cells, 441; technique of, 391.
- Treves. Diverticula of intestine, 536; epithelioma of intestine, 536; intestinal obstruction, 532, 535; operative treatment of peritonitis, 578; stricture of intestine, 537.
- Trichiasis, 407.
- Trigonocephalus, 79.
- Trochanter of femur, fracture of, 312.
- Trommer. Test for sugar in urine, 642.
- True aneurism, 202.
- Truss for hernia, 558.
- Tubercular syphilide, 721.
- Tuberculosis of bone, 276; of epididymis, 747; of hip-joint, 354; of joints, 353; of lymphatic glands of neck, 494; of mammary gland, 517; of prostate gland, 674; of spine, 787; of testicle, 747; of thyroid gland, 494; of urethra, 706; of vesiculæ seminales, 744; of vulva, 757.
- Tubular adenoma, 850; epithelioma, 841.
- Tufnell. Aneurism, 206, 227.
- Tumefaction in inflammation, 55.
- Tumors, 837; cirroid, 190; cutaneous arterial, 190; capillary, 190, 195; venous, 190, 195; cystic, of ovary, 774, *vide* cyst; erectile, 195; of antrum of Highmore, 471; of the bladder, 639; of frontal sinus, 445; of head, 382; of larynx, 505; of mammary gland, 515; of neck, 493; of nose, 443; of œsophagus, 509; of parotid gland, 468; of pharynx, 507; of the prostate, 674; of the scalp, 382; of urethra, 706; vascular, 190; excision of, 192; ligation of, carotid for, 192; venous, 190; venous cutaneous, 195.
- Tunica funiculi, 736.
- Tunica vaginalis, 735; affected in epididymitis, 744; hæmatoma of, 735; hydrocele of, 735.
- Turbinated bones, 446.
- Twisting of intestines, 534.
- Tympanitis, 578.
- Typhlitis, 579.
- Ulcer, 99; herpetic, 412; of the prepuce, 713; of the anus, 600; of the cornea, 412; of the leg, 200; of the lips, 453; of the penis, 713; of the tongue, 483; of the vulva, 757; phagedenic, 714; serpiginous, of cornea, 413; simple, 713, 716; specific, 717; syphilitic, 717, 719; tertiary, of the skin, 722.
- Ullman. Ligation of carotid for vascular tumor, 192.
- Ulna, dislocation of, at elbow, 324; fracture, 299.
- Ulna and radius, dislocations of, 335.
- Ulnar artery, aneurism of, 227; ligation of, 262; nerve, injury to, from dislocations, 335.
- Umbilical hernia, 554; diagnosis and treatment, 572.
- Umbrella compress, 662; probang, 508.
- Undescended testicle, 750.
- Ununited fractures, 324.
- Upper extremity, deformities of, 826.
- Uræmia, 622.
- Urea, 641.
- Ureteritis, 620.
- Ureters, affections of, 627; compression, 627.
- Urethra, 676; carcinoma, 706; cocaine anæsthesia for, 689; fibroma, 706; fistule, 702; rectal, 703; foreign bodies in, 700; malformations, 705; neoplasms, 706; papilloma, 706; stricture of, 677, 678; of membranous, 696; treatment of, 692.
- Urethral forceps, 701; sounds, 698; speculum, 706.
- Urethritis, 676; a cause of pyelitis, 620; chronic, 686; chronic follicular, 687; non-specific, 679; simple, 685; specific, 676; treatment, 679.
- Urethrotome, Banks's, 691; Otis's, 693.
- Urethrotomy, 692; external, 697; internal, 693; modified, 696.
- Uric calculus, 646.
- Urinal, 628, 639.
- Urinalysis, 641.
- Urinary fistula, 702; rectal, 703.
- Urine, 640; examinations of, 641; incontinence, 638; infiltration, 630; physiology, 641; retention, 635; suppression of, 619, 624, 635.
- Uterus, Cæsarean section, 766; carcinoma, 765; cervix of, amputation of the, 764; excision, 764; laceration, 763; excision, abdominal, 766; of pregnant, 768; vaginal, 765; extirpation, 765; prolapse, 760.
- Uvula, affections of, 478; excision, 478.
- Vaccination for angioma, 197.
- Vagina, absence of, 756; atresia, 759; hernia into, 574; stricture, 759.
- Vaginal hysterectomy, 765.
- Vaginismus, 759.
- Vaginitis, 758.
- Valgum, genu, 804.
- Valgus, talipes, 819.
- Valsalva. Treatment for aneurism, 205, 206, 212.
- Van Arsdale. Action of iodoform on ptomaines, 5; subluxation of the head of the radius, 335.

- Van Buren. Curvature of steel sounds, 699; cupped sound, 673; *débris* syringe, 661; hæmaturia, method of determining source of, 644; urethral scoop, 701.
- Vance. Corset, 785.
- Varicocele, 198, 740; diagnosis, 556, 736, 738; radical cure, 741, 743; treatment, 741.
- Varicose aneurism, 232; veins, 198; ulcer, 99.
- Varicosities of lymphatic vessels, 165.
- Varix, 198; aneurismal, 203, 232; arterial, 190; treatment, 200.
- Varum, genu, 809.
- Varus, talipes, 814.
- Vascular formation in wounds, 69; system, surgery of the, 162; tumors, excision of, 192; ligation of carotid for, 192.
- Vas deferens, 744.
- Vaseline, iodoform, 95.
- Vein, internal jugular, ligation of, 237, 253; wounds of, in ligation of carotid, 238.
- Veins, hæmorrhage from, 71.
- Velpeau. Bandage for dislocation of clavicle, 327; fracture of clavicle, 294, 327; vascular tumor, 193.
- Venesection, 57; in aneurism, 205; in inflammation, 57.
- Venom, scorpion, 80; snake, 78; tarantula, 81; toad, 80.
- Venom-albumen, 79.
- Venom-globulin, 79.
- Venom-pepton, 79.
- Venous hæmorrhage, 71; occlusion in gangrene, 101; tumors, cutaneous, 190; varix, 198.
- Ventral hernia, 554; treatment, 573.
- Verneuil. Case of aneurism, 227; tapping of echinococcus sac of liver, 585; varix, 189.
- Vertebra, dislocation of the, 350; fractures, 305.
- Vertebral artery, 255; aneurism of, 228; diagnosis, 220; ligation, 259.
- Vesico-vaginal fistula, 761.
- Vesiculæ seminales, 743; inflammation of, 744; wounds, 743.
- Vesicular syphilide, 721.
- Vichy water in cystitis, 633.
- Villardebo. Case of aneurism, 218.
- Villous polypus of rectum, 607; tumors of bladder, 639.
- Violin-strings as ligatures, 1.
- Vipera, 79.
- Virchow. Phlebitis, 167; tumors, 837.
- Visceral syphilis, 184.
- Vision tests, 431 *et seq.*
- Vitreous humor, 423; foreign bodies in, 423.
- Volkmann. Foot-rest for fracture of femur, 310; operation for hydrocele, 739; scoop, 38.
- Volvulus, 534.
- Vulva, abscess of, 751; affections, 751; chancre, 757; contusions, 751; epithelioma, 751; hæmatoma, 751; lupus, 757; papilloma, 757; pruritus, 758; rupture of posterior parts, 752; syphilis, 757; tuberculosis, 757; ulcers, 757; wounds, 751.
- Vulvitis, 757.
- Wardrop. Case of aneurism, 218; case of erectile tumor, 191; operation for aneurism, 207.
- Wardwell. Calcification of arteries, 179.
- Warren. Case of aneurism, 224; vascular tumors, 196; excision of, 193; ligation of carotid for, 192.
- Wart, 849; of head, 383.
- Wasp-sting, 81.
- Wassilieff. Glanders, 83.
- Water, boiled, for irrigation of wounds, 74; pure, for continuous irrigation in amputations, 120.
- Watson. Case of aneurism, 229.
- Weber. Case of syphilitic arteritis, 181.
- Weber, O. Coagulation after arterial ligation, 189.
- Web-finger, 829.
- Webster. Hordeolum, 399; pannus, 412.
- Web-toe, 822.
- Weigert. Calcification of arteries, 180; coagulation necrosis, 180; inflammation, 67.
- Weir. Case of aneurism, 217; case of osteotomy of femur, 804; spray-machine, 4.
- Weitzer. Excision of vascular tumor, 193.
- Wells. Fenestrated forceps, 656; sac-forceps, 777.
- Wens, 382, 850.
- Whisky after burns, 93; for serpent-venom, 80.
- White. Arteritis syphilitica, 183; phlebitis, 169.
- Whitehead. Operation for hæmorrhoids, 612, 613, 615.
- White lead for burns, 93.
- Whitlow, 834.
- Wild. Ear speculum, 439.
- Wire, *écraseur*, 443; in the treatment of aneurism, 210.
- Wolf-bite, 81.
- Wolff. Cradle, 784.
- Wölfler. Gastro-enterostomy, 528, 529.
- Wolverton. Tooth-forceps, 477.
- Wood. Open method of treating for amputations, 119.
- Wood-wool as an absorbent dressing, 9.
- Wounds, 68; adhesive plaster in, 76; contused, 68; dissection, 84; dressings, 84; granulating process in, 69; gunshot, 90, *vide* gunshot; healing of, 69; incised, 68; insect, 68, 81; lacerated, 68; of ear, 439; of eye, 396; modes of dressing, 53; of the abdominal walls, 586; of the abdominal organs, 587; of the arteries, 204; of the bladder, 629; of the bowels, 587; of the chest, 523; of the cornea, 411; of the face, 395; of the heart, 524; of the kidney,

- 619; of the lips, 452; of the lymphatic vessels, 164; of the neck, 491; of the œsophagus, 491; of the penis, 707; of the scalp, 386; of the scrotum, 733; of the skull, 387; of the testicle, 745; of the tongue, 482; of the vesiculæ seminales, 743; of the vulva, 751; poisoned, 78; by dissection, 84; by glanders, 82; by insects, 68, 81; by malignant pustule, 83; by rabid animals, 81; by serpents, 78; punctured, 68; serpent, 78, 79; sutures in, 76; of scalp, 386; treatment, 70.
- Wrist, amputation at, 126; dislocations, 337; exsection, 368, 379; synovitis, 367.
 Wry-neck, 779.
 Wutzer. Rhinoplasty, 450.
- Xanthic calculus, 647.
 Xerosis, 411.
- Zinc, acetate of, in gonorrhœa, 681, 685; chloride of, as an antiseptic, 3.
 Zygomatic process, fracture of the, 289.

THE END.

